GRIFFITH

THIRD EDITION

DIAGNOSTIC ULTRASOUND

MUSCULOSKELETAL

ELSEVIER

GRIFFITH

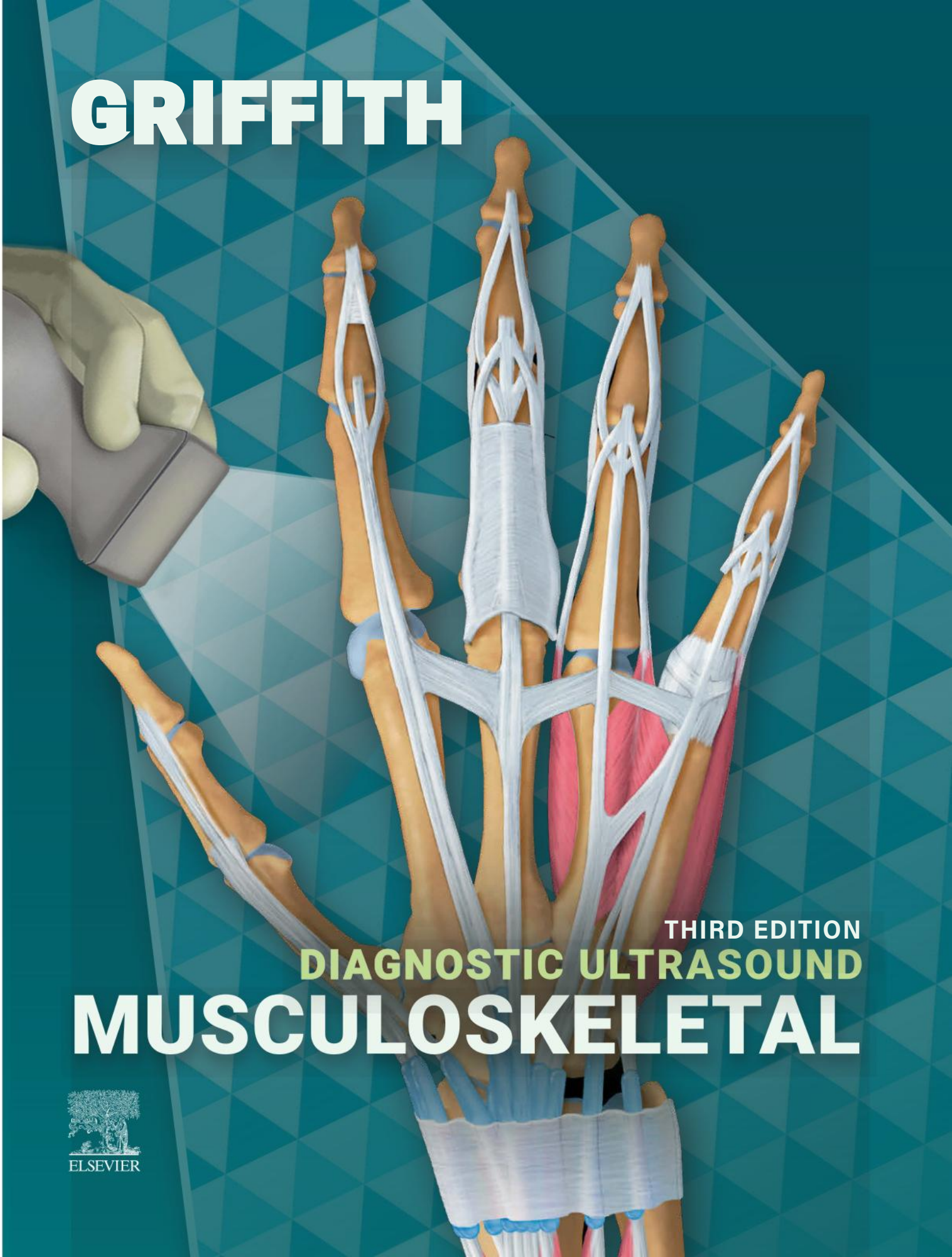

THIRD EDITION

DIAGNOSTIC ULTRASOUND MUSCULOSKELETAL

ELSEVIER

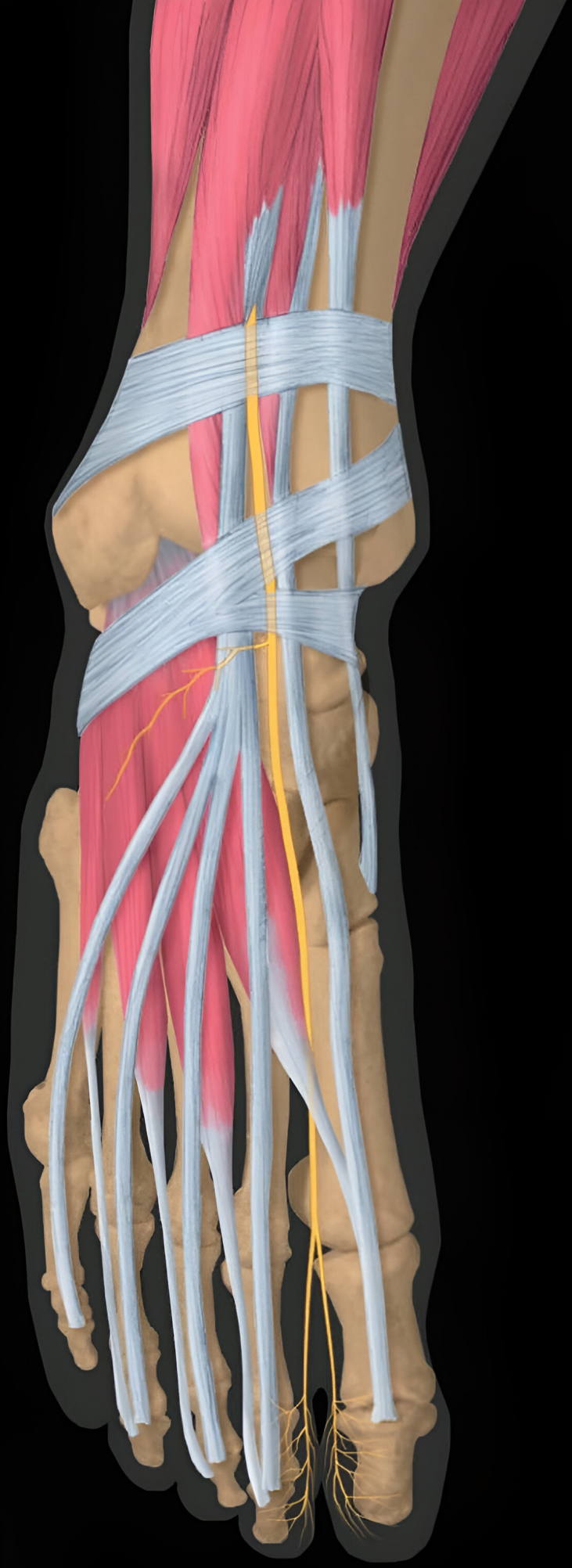

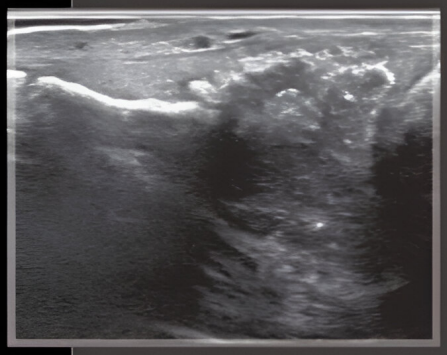

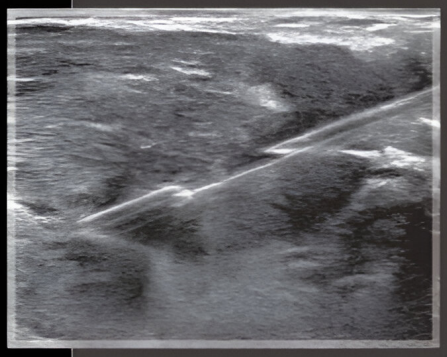

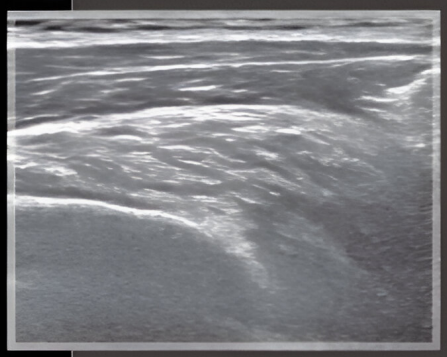

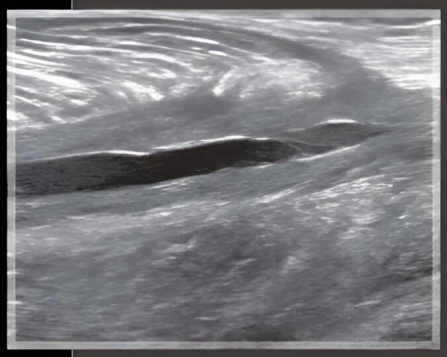

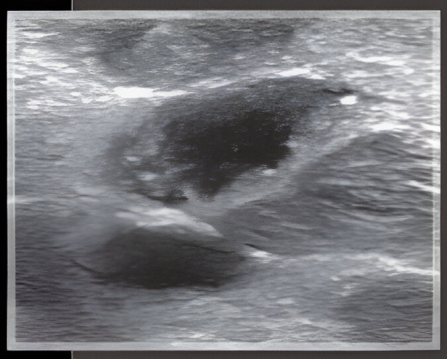

DIAGNOSTIC ULTRASOUND

MUSCULOSKELETAL

THIRD EDITION

James F. Griffith, MB BCh BAO, MRCP, FRCR, FHKCR, FHKAM (Radiology), MD (CUHK)

Professor and Chairman
Department of Imaging and Interventional Radiology
The Chinese University of Hong Kong
Hong Kong (SAR), China

Elsevier
1600 John F. Kennedy Blvd.
Ste 1800
Philadelphia, PA 19103-2899

DIAGNOSTIC ULTRASOUND: MUSCULOSKELETAL, THIRD EDITION

ISBN: 978-0-443-28564-6
Inkling: 978-0-443-28650-6

Copyright © 2025 by Elsevier. All rights reserved.

No part of this publication may be reproduced or transmitted in any form or by any means, electronic or mechanical, including photocopying, recording, or any information storage and retrieval system, without permission in writing from the publisher. Details on how to seek permission, further information about the Publisher's permissions policies and our arrangements with organizations such as the Copyright Clearance Center and the Copyright Licensing Agency, can be found at our website: www.elsevier.com/permissions.

This book and the individual contributions contained in it are protected under copyright by the Publisher (other than as may be noted herein).

All rights are reserved, including those for text and data mining, AI training, and similar technologies.

Notices

Practitioners and researchers must always rely on their own experience and knowledge in evaluating and using any information, methods, compounds or experiments described herein. Because of rapid advances in the medical sciences, in particular, independent verification of diagnoses and drug dosages should be made. To the fullest extent of the law, no responsibility is assumed by Elsevier, authors, editors or contributors for any injury and/or damage to persons or property as a matter of products liability, negligence or otherwise, or from any use or operation of any methods, products, instructions, or ideas contained in the material herein.

Previous edition copyrighted 2019.

Library of Congress Control Number: 2024950607

Printed in Canada by Friesens, Altona, Manitoba, Canada

Last digit is the print number: 9 8 7 6 5 4 3 2 1

ELSEVIER
Book Aid International
Working together to grow libraries in developing countries
www.elsevier.com • www.bookaid.org

DEDICATION

To my wife Clara, daughters Izzy and Olivia, Mum, Dad, and all my family.

JFG

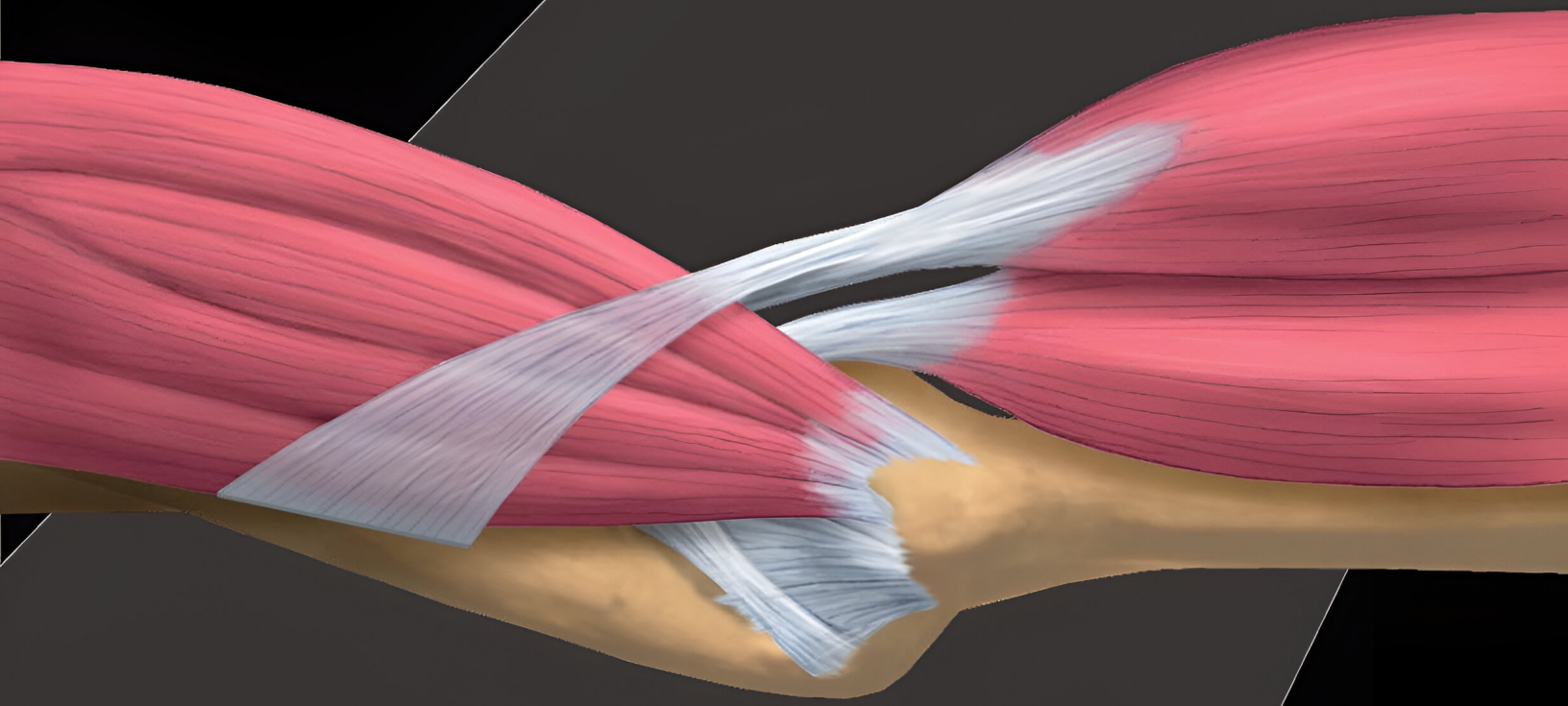

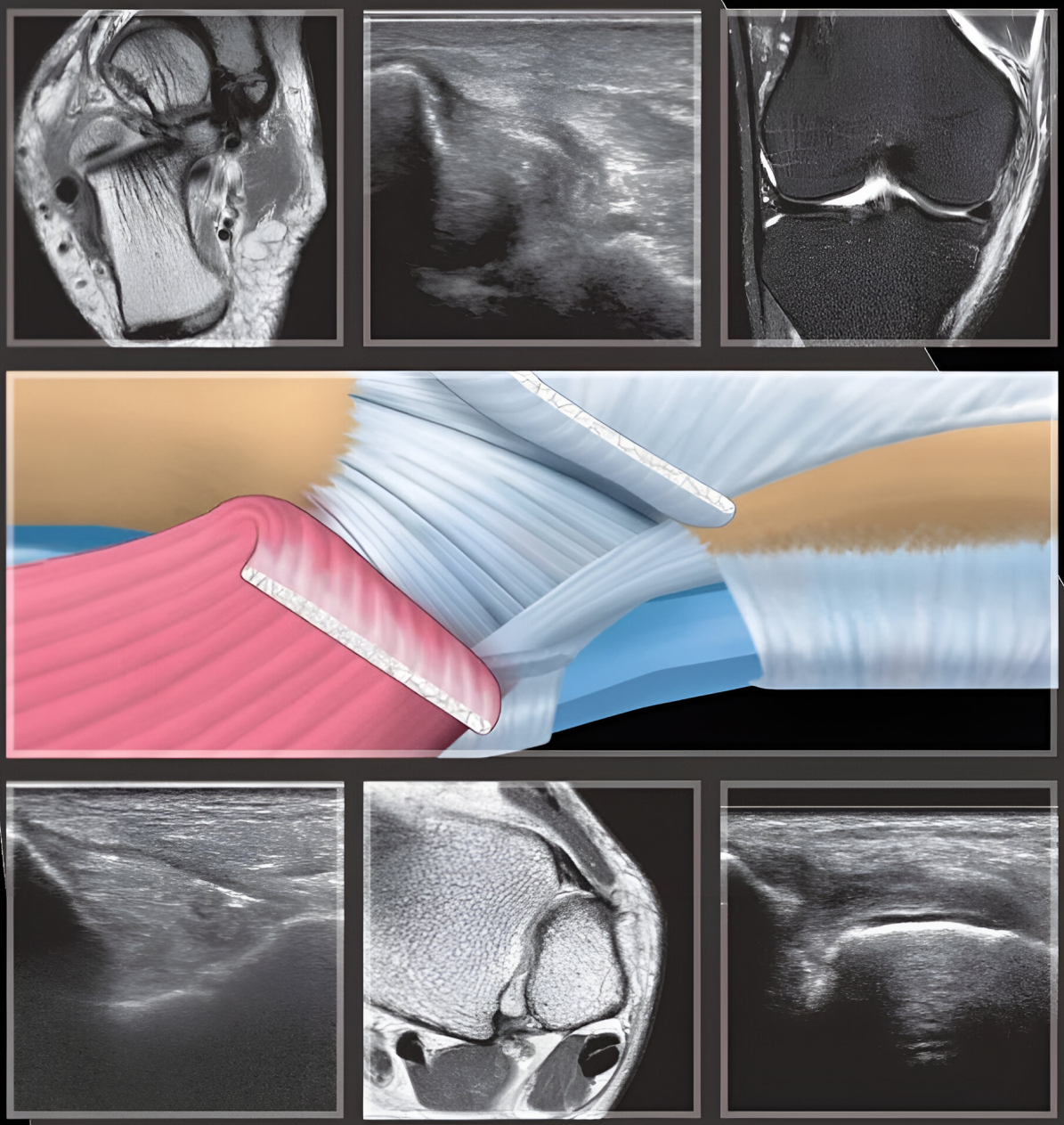

CONTRIBUTING AUTHORS

King Kenneth Cheung, MBBS, BSc, PhD, FRCR
Clinical Assistant Professor (Honorary)
Department of Imaging and Interventional Radiology
The Chinese University of Hong Kong
Hong Kong (SAR) China

Esther H. Y. Hung, MBChB, FRCR, FHKCR, FHKAM (Radiology)
Clinical Associate Professor (Honorary)
Department of Imaging and Interventional Radiology
The Chinese University of Hong Kong
Hong Kong (SAR), China

Nishith Kumar, MBBS, MD, DNB
Professor
Department of Radiodiagnosis and Interventional Radiology
Vardhman Mahavir Medical College & Safdarjung Hospital
New Delhi, India

Alex W. H. Ng, MBChB, FRCR, FHKCR, FHKAM (Radiology)
Clinical Associate Professor (Honorary)
Department of Imaging and Interventional Radiology
The Chinese University of Hong Kong
Hong Kong (SAR), China

Dharmendra Kumar Singh, MBBS, MD, FRCR
Professor
Department of Radiodiagnosis and Interventional Radiology
Vardhman Mahavir Medical College & Safdarjung Hospital
New Delhi, India

Cina S. L. Tong, MBChB, FRCR, FHKCR, FHKAM (Radiology)
Clinical Associate Professor (Honorary)
Department of Imaging and Interventional Radiology
The Chinese University of Hong Kong
Hong Kong (SAR), China

Carita Tsoi, MBChB, FRCR, FHKCR, FHKAM (Radiology)
Clinical Assistant Professor (Honorary)
Department of Imaging and Interventional Radiology
The Chinese University of Hong Kong
Hong Kong (SAR), China

Stefanie W. Y. Yip, MBBS, FRCR, FHKCR, FHKAM (Radiology)
Clinical Assistant Professor (Honorary)
Department of Imaging and Interventional Radiology
The Chinese University of Hong Kong
Hong Kong (SAR), China

ADDITIONAL CONTRIBUTORS

Ryan K. L. Lee, MBChB, FRCR, FHKAM (Radiology)

PREFACE

There is little doubt that musculoskeletal ultrasound will become the most influential and practical imaging modality for assessing musculoskeletal disease globally. It is already well on its way to becoming this ubiquitous megastar. Most musculoskeletal conditions, aside from the deeper joint structures, are fully accessible to evaluation by ultrasound. The clarity and precision with which musculoskeletal conditions can be analyzed continues to improve.

Ultrasound sets itself apart from other imaging modalities in that you alone have the power to tease the most out of every examination. An ultrasound diagnosis is formulated not just on a single imaging characteristic but on a myriad of ultrasound signs, suitably weighted, evaluated within a clinical context. As such, ultrasound imaging is a lifelong learning skill. No other imaging modality affords quite the capacity for continual improvement. Good quality ultrasound requires a pedantic approach, equipped with a good grasp of ultrasound anatomy, a meticulous technique, an appreciation of the pertinent ultrasound findings, and an awareness of possible differential diagnoses. Each of these aspects has been addressed in the third edition of *Diagnostic Ultrasound: Musculoskeletal.*

Anatomy, the key to good quality musculoskeletal ultrasound, is comprehensively covered in the first section. The next section, Ultrasound in Practice, provides a detailed account of how to undertake an examination of the main body areas, emphasizing those features most frequently examined by musculoskeletal ultrasound. Key elements to writing an ultrasound report are also addressed, as are musculoskeletal ultrasound artifacts. The third section, Diagnosis, looks at specific musculoskeletal conditions, the range of potential ultrasound appearances encountered, and the key facts required to make a correct diagnosis. The fourth section, Differential Diagnoses, looks at ultrasound diagnosis from the opposite perspective, outlining diagnoses to be considered when faced with a particular ultrasound scenario, such as hypervascular subcutaneous mass. The fifth section, Interventional Procedures, addresses the rapidly expanding and increasingly influential field of ultrasound-guided interventional techniques in treatment and diagnosis. At least 1/3 of the overall book content has been updated since the second edition, published in 2019.

Thank you to my colleagues and friends, Cina Tong, Esther Hung, Stefanie Yip, Carita Tsoi, Ken Cheung, and Alex Ng for your hard work and generosity in helping to write this book, and for your day-to-day dedication in maintaining a high standard of ultrasound and musculoskeletal clinical practice. I am deeply indebted to you for so willingly contributing your time and effort to update this third edition on top of your busy work schedules. Thank you also to my friends, Dharmendra Kumar Singh and Nishith Kumar, who kindly helped update the interventional ultrasound chapters.

Thank you to Megg Morin and Rich Coombs at Elsevier for your help in putting this book together. Your professional mastery, attention to detail, and desire to produce a top-quality educational ultrasound textbook is second to none and has been a tremendous help with this and previous editions.

Thank you also to all the academics around the world who continue to undertake good quality research to advance the science of musculoskeletal ultrasound. Your work is essential to improving the quality and scope of musculoskeletal ultrasound. We have tried hard to incorporate these new findings in this edition.

And to you, the readers, I do hope you enjoy this book and find it helpful in your daily practice. Please do persevere with enhancing your musculoskeletal ultrasound skill set. 100% guaranteed, you will not be disappointed.

James F. Griffith, MB BCh BAO, MRCP, FRCR, FHKCR, FHKAM (Radiology), MD (CUHK)
Professor and Chairman
Department of Imaging and Interventional Radiology
The Chinese University of Hong Kong
Hong Kong (SAR), China

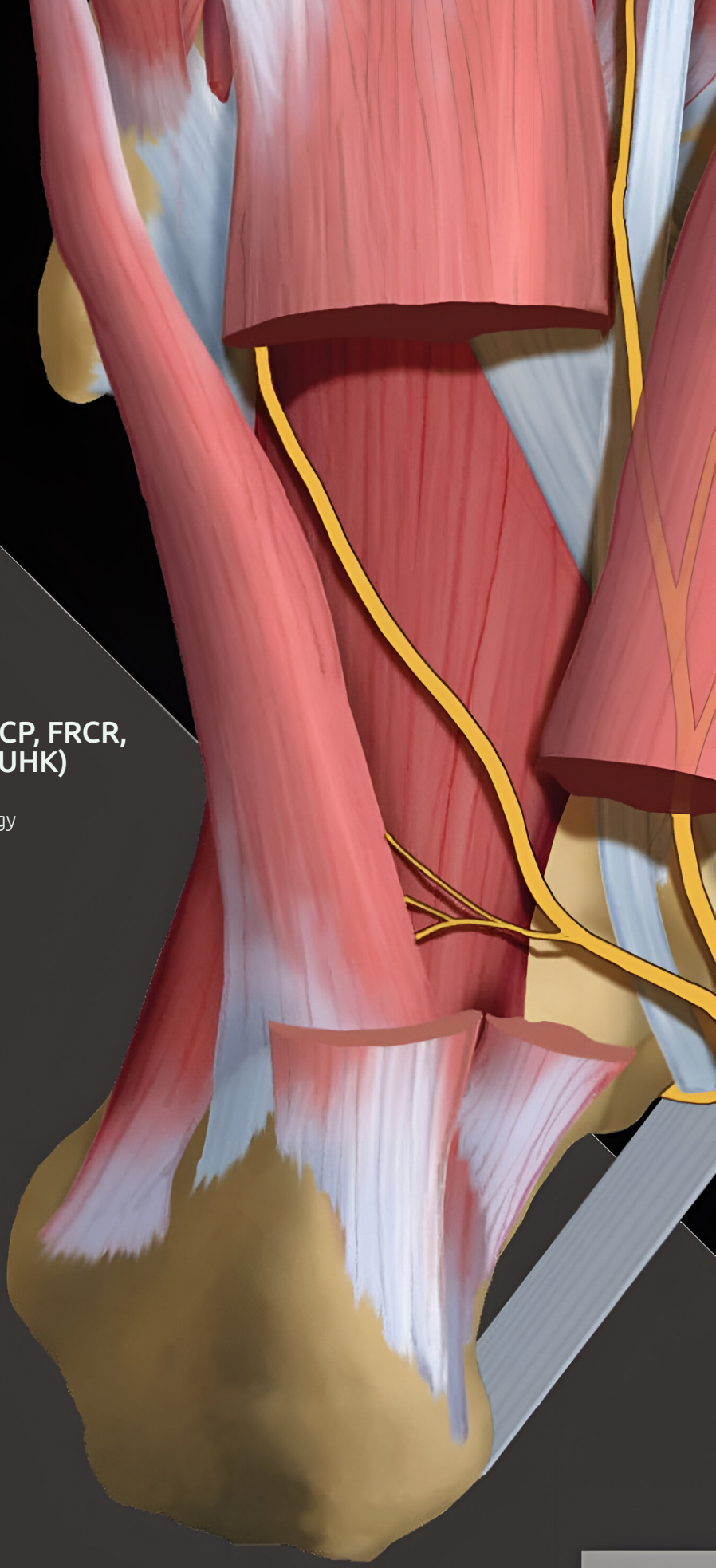

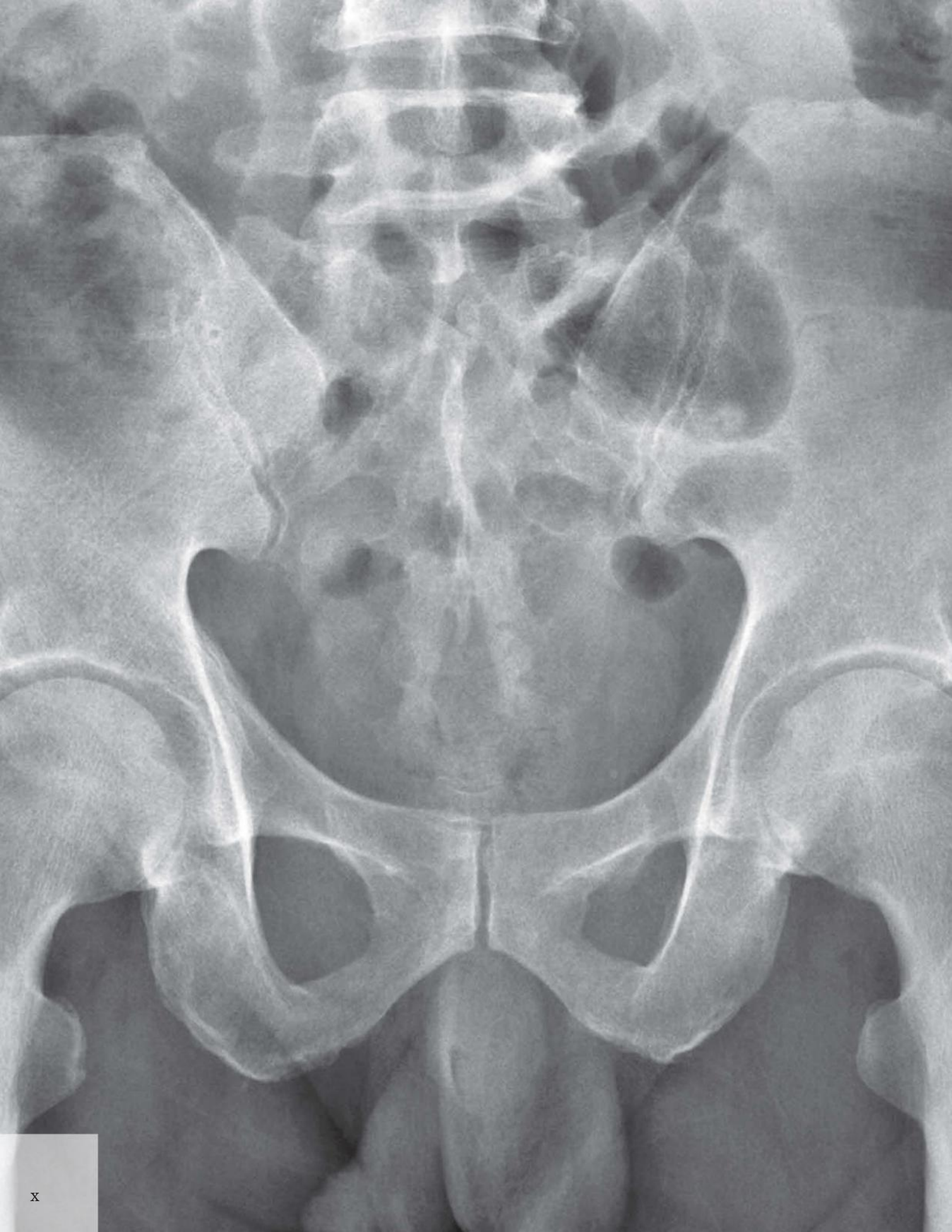

ACKNOWLEDGMENTS

LEAD EDITOR
Megg Morin, BA

LEAD ILLUSTRATOR
Richard Coombs, MS

TEXT EDITORS
Arthur G. Gelsinger, MA
Rebecca L. Bluth, BA
Nina Themann, BA
Terry W. Ferrell, MS
Kathryn Watkins, BA

ILLUSTRATIONS
Lane R. Bennion, MS
Laura C. Wissler, MA

IMAGE EDITORS
Jeffrey J. Marmorstone, BS
Lisa A. M. Steadman, BS

ART DIRECTION AND DESIGN
Cindy Lin, BFA

PRODUCTION EDITORS
Emily C. Fassett, BA
John Pecorelli, BS

ELSEVIER

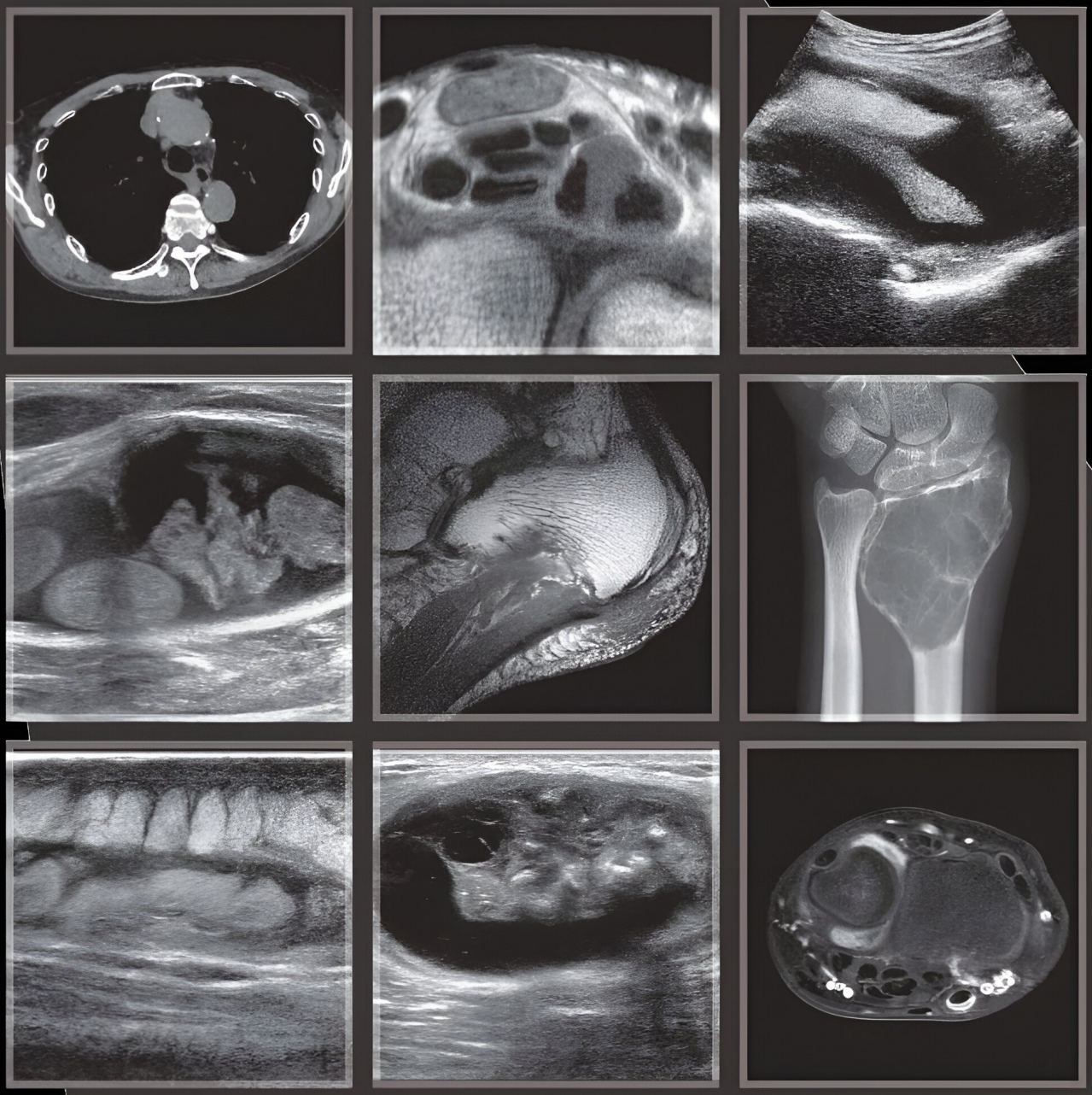

SECTIONS

PART I: Anatomy
SECTION 1: Upper Limb
SECTION 2: Trunk
SECTION 3: Lower Limb

PART II: Ultrasound in Practice
SECTION 1: Approach
SECTION 2: Technique

PART III: Diagnoses
SECTION 1: Tendon Disorders
SECTION 2: Soft Tissue, Bone, and Joint Injury
SECTION 3: Arthropathies
SECTION 4: Neurovascular Abnormalities
SECTION 5: Infection
SECTION 6: Articular and Paraarticular Masses
SECTION 7: Soft Tissue and Bone Tumors
SECTION 8: Hernia

PART IV: Differential Diagnoses
SECTION 1: General Lumps and Bumps
SECTION 2: Tendon Abnormalities
SECTION 3: Nerve, Fascia, and Bone
SECTION 4: Joint Abnormalities
SECTION 5: Chest and Abdominal Wall

PART V: Interventional Procedures
SECTION 1: Biopsy
SECTION 2: Joint Procedures

TABLE OF CONTENTS

Part I: Anatomy

SECTION 1: UPPER LIMB

4 **Sternoclavicular and Acromioclavicular Joints**
James F. Griffith, MD
10 **Shoulder**
James F. Griffith, MD
28 **Axilla**
James F. Griffith, MD
34 **Arm**
James F. Griffith, MD
42 **Elbow**
James F. Griffith, MD
62 **Forearm**
James F. Griffith, MD
72 **Wrist**
James F. Griffith, MD
88 **Hand**
James F. Griffith, MD
98 **Thumb**
James F. Griffith, MD
108 **Fingers**
James F. Griffith, MD
118 **Upper Limb Arteries and Veins**
James F. Griffith, MD
130 **Brachial Plexus**
James F. Griffith, MD
138 **Radial Nerve**
James F. Griffith, MD
146 **Median Nerve**
James F. Griffith, MD
156 **Ulnar Nerve**
James F. Griffith, MD

SECTION 2: TRUNK

168 **Chest Wall**
James F. Griffith, MD
174 **Abdominal Wall**
James F. Griffith, MD
182 **Paraspinal Structures**
James F. Griffith, MD
190 **Groin**
James F. Griffith, MD
200 **Pelvic and Thigh Nerves**
James F. Griffith, MD

SECTION 3: LOWER LIMB

214 **Gluteal Muscles**
James F. Griffith, MD
226 **Hip**
James F. Griffith, MD
236 **Thigh**
James F. Griffith, MD
248 **Lower Limb Arteries and Veins**
James F. Griffith, MD
264 **Knee**
James F. Griffith, MD
282 **Leg**
James F. Griffith, MD
294 **Leg Nerves**
James F. Griffith, MD
298 **Ankle**
James F. Griffith, MD
316 **Hindfoot and Midfoot**
James F. Griffith, MD
334 **Forefoot**
James F. Griffith, MD

Part II: Ultrasound in Practice

SECTION 1: APPROACH

346 **Approach to Musculoskeletal Ultrasound**
James F. Griffith, MD
350 **Musculoskeletal Ultrasound Artifacts**
James F. Griffith, MD
358 **Writing an Ultrasound Report**
James F. Griffith, MD

SECTION 2: TECHNIQUE

362 **Shoulder Ultrasound**
James F. Griffith, MD
370 **Brachial Plexus Ultrasound**
James F. Griffith, MD
374 **Elbow Ultrasound**
James F. Griffith, MD
382 **Wrist Ultrasound**
James F. Griffith, MD
390 **Hand Ultrasound**
James F. Griffith, MD
394 **Groin Hernia Ultrasound**
James F. Griffith, MD
402 **Hip Ultrasound**
James F. Griffith, MD
410 **Knee Ultrasound**
James F. Griffith, MD
418 **Ankle Ultrasound**
James F. Griffith, MD

TABLE OF CONTENTS

426 **Foot Ultrasound**
James F. Griffith, MD

Part III: Diagnoses

SECTION 1: TENDON DISORDERS

434 **Rotator Cuff/Biceps Tendinosis**
King Kenneth Cheung, MBBS and James F. Griffith, MD
446 **Rotator Cuff/Biceps Tendon Tear**
King Kenneth Cheung, MBBS and James F. Griffith, MD
454 **Nonrotator Cuff Tendinosis**
Alex W. H. Ng, MBChB and James F. Griffith, MD
464 **Nonrotator Cuff Tendon Tears**
Alex W. H. Ng, MBChB and James F. Griffith, MD
476 **Tenosynovitis**
Alex W. H. Ng, MBChB and James F. Griffith, MD
486 **Elbow Epicondylitis**
King Kenneth Cheung, MBBS and James F. Griffith, MD

SECTION 2: SOFT TISSUE, BONE, AND JOINT INJURY

496 **Fat Injury**
Esther H. Y. Hung, MBChB and James F. Griffith, MD
504 **Muscle Infarction**
Cina S. L. Tong, MBChB and James F. Griffith, MD
508 **Muscle Injury**
Cina S. L. Tong, MBChB and James F. Griffith, MD
518 **Hematoma/Seroma**
Alex W. H. Ng, MBChB and James F. Griffith, MD
526 **Ligament Injury**
Alex W. H. Ng, MBChB and James F. Griffith, MD
534 **Bone Fracture**
King Kenneth Cheung, MBBS and James F. Griffith, MD

SECTION 3: ARTHROPATHIES

546 **Osteoarthritis**
King Kenneth Cheung, MBBS and James F. Griffith, MD
554 **Inflammatory Arthritis**
King Kenneth Cheung, MBBS and James F. Griffith, MD
564 **Gout and Pseudogout**
King Kenneth Cheung, MBBS and James F. Griffith, MD
572 **Developmental Hip Dysplasia**
Alex W. H. Ng, MBChB and James F. Griffith, MD

SECTION 4: NEUROVASCULAR ABNORMALITIES

580 **Nerve Injury**
Cina S. L. Tong, MBChB and James F. Griffith, MD
590 **Carpal Tunnel Syndrome**
Alex W. H. Ng, MBChB and James F. Griffith, MD
598 **Cubital Tunnel Syndrome**
King Kenneth Cheung, MBBS and James F. Griffith, MD
602 **Brachial Plexus Pathology**
Stefanie W. Y. Yip, MBBS and James F. Griffith, MD
608 **Tarsal Tunnel Syndrome**
Cina S. L. Tong, MBChB and James F. Griffith, MD
614 **Nerve Sheath Tumors**
Carita Tsoi, MBChB and James F. Griffith, MD
626 **Vascular Dilatation or Inflammation**
Stefanie W. Y. Yip, MBBS and James F. Griffith, MD

SECTION 5: INFECTION

636 **Soft Tissue Infection**
Esther H. Y. Hung, MBChB and James F. Griffith, MD
644 **Bone Infection**
Stefanie W. Y. Yip, MBBS and James F. Griffith, MD
654 **Joint Infection**
Stefanie W. Y. Yip, MBBS and James F. Griffith, MD
660 **Postoperative Infection**
Stefanie W. Y. Yip, MBBS and James F. Griffith, MD

SECTION 6: ARTICULAR AND PARAARTICULAR MASSES

668 **Hemarthrosis and Lipohemarthrosis**
Carita Tsoi, MBChB and James F. Griffith, MD
672 **Baker Cyst**
Carita Tsoi, MBChB and James F. Griffith, MD
678 **Bursitis**
Alex W. H. Ng, MBChB and James F. Griffith, MD
690 **Ganglion Cyst**
Carita Tsoi, MBChB and James F. Griffith, MD
700 **Parameniscal Cyst**
Carita Tsoi, MBChB and James F. Griffith, MD
704 **Synovial Tumor**
Stefanie W. Y. Yip, MBBS and James F. Griffith, MD

SECTION 7: SOFT TISSUE AND BONE TUMORS

718 **Plantar Fasciitis and Fibromatosis**
Carita Tsoi, MBChB and James F. Griffith, MD
724 **Lipoma**
Esther H. Y. Hung, MBChB and James F. Griffith, MD
734 **Epidermoid Cyst**
Esther H. Y. Hung, MBChB and James F. Griffith, MD
740 **Pilomatricoma**
Esther H. Y. Hung, MBChB and James F. Griffith, MD
744 **Dermatofibrosarcoma Protuberans**
Carita Tsoi, MBChB and James F. Griffith, MD
748 **Vascular Leiomyoma**
Carita Tsoi, MBChB and James F. Griffith, MD
752 **Superficial Metastases, Melanoma, and Lymphoma**
Esther H. Y. Hung, MBChB and James F. Griffith, MD
758 **Vascular Anomaly**
Esther H. Y. Hung, MBChB and James F. Griffith, MD
766 **Foreign Body and Injection Granuloma**
Stefanie W. Y. Yip, MBBS and James F. Griffith, MD
774 **Lymph Node Abnormality**
Stefanie W. Y. Yip, MBBS and James F. Griffith, MD
780 **Soft Tissue Sarcoma**
Alex W. H. Ng, MBChB and James F. Griffith, MD
788 **Bone Tumor**
Cina S. L. Tong, MBChB and James F. Griffith, MD
800 **Local Tumor Recurrence**
Alex W. H. Ng, MBChB and James F. Griffith, MD

TABLE OF CONTENTS

SECTION 8: HERNIA

812 **Abdominal Wall Hernia**
Cina S. L. Tong, MBChB and James F. Griffith, MD
820 **Groin Hernia**
Cina S. L. Tong, MBChB and James F. Griffith, MD

Part IV: Differential Diagnoses

SECTION 1: GENERAL LUMPS AND BUMPS

828 **Hypoechoic Subcutaneous Mass**
Esther H. Y. Hung, MBChB and James F. Griffith, MD
834 **Hyperechoic Subcutaneous Mass**
Esther H. Y. Hung, MBChB and James F. Griffith, MD
840 **Hypoechoic Muscle Mass**
Stefanie W. Y. Yip, MBBS and James F. Griffith, MD
846 **Hyperechoic Muscle Mass**
King Kenneth Cheung, MBBS
852 **Cystic Soft Tissue Mass**
Cina S. L. Tong, MBChB and James F. Griffith, MD
858 **Calcified Soft Tissue Mass**
Alex W. H. Ng, MBChB and James F. Griffith, MD
862 **Hypervascular Soft Tissue Mass**
Esther H. Y. Hung, MBChB and James F. Griffith, MD

SECTION 2: TENDON ABNORMALITIES

870 **Peritendinous Mass**
Alex W. H. Ng, MBChB and James F. Griffith, MD
874 **Tendon Hypoechogenicity**
Alex W. H. Ng, MBChB and James F. Griffith, MD
878 **Tendon Hyperechogenicity**
Alex W. H. Ng, MBChB and James F. Griffith, MD
882 **Tendon Swelling**
Alex W. H. Ng, MBChB and James F. Griffith, MD

SECTION 3: NERVE, FASCIA, AND BONE

890 **Swollen Nerve**
Stefanie W. Y. Yip, MBBS and James F. Griffith, MD
896 **Fascial Lesion**
Stefanie W. Y. Yip, MBBS and James F. Griffith, MD
902 **Bone Surface Lesion**
Stefanie W. Y. Yip, MBBS and James F. Griffith, MD

SECTION 4: JOINT ABNORMALITIES

910 **Paraarticular Cystic Mass**
King Kenneth Cheung, MBBS and James F. Griffith, MD
916 **Synovial Swelling**
Stefanie W. Y. Yip, MBBS and James F. Griffith, MD
922 **Joint Effusion**
Stefanie W. Y. Yip, MBBS and James F. Griffith, MD

SECTION 5: CHEST AND ABDOMINAL WALL

928 **Chest Wall Lesion**
Cina S. L. Tong, MBChB and James F. Griffith, MD
934 **Abdominal Wall Lesion**
Cina S. L. Tong, MBChB and James F. Griffith, MD

Part V: Interventional Procedures

SECTION 1: BIOPSY

942 **Soft Tissue Biopsy**
Cina S. L. Tong, MBChB and James F. Griffith, MD
950 **Bone Biopsy**
Cina S. L. Tong, MBChB and James F. Griffith, MD
960 **Synovial Biopsy**
Stefanie W. Y. Yip, MBBS and James F. Griffith, MD

SECTION 2: JOINT PROCEDURES

968 **Joint Injection: Upper Limb**
James F. Griffith, MD and Ryan K. L. Lee, MBChB
978 **Joint Injection: Lower Limb**
James F. Griffith, MD and Ryan K. L. Lee, MBChB
986 **Shoulder Procedures**
Nishith Kumar, MD, Dharmendra Kumar Singh, MD, and James F. Griffith, MD
994 **Elbow Procedures**
Nishith Kumar, MD and James F. Griffith, MD
1000 **Hand and Wrist Procedures**
Nishith Kumar, MD and James F. Griffith, MD
1006 **Hip and Pelvis Procedures**
Dharmendra Kumar Singh, MD and James F. Griffith, MD
1014 **Knee Procedures**
Dharmendra Kumar Singh, MD and James F. Griffith, MD
1022 **Ankle and Foot Procedures**
Dharmendra Kumar Singh, MD and James F. Griffith, MD

This page intentionally left blank

This page intentionally left blank

GRIFFITH

THIRD EDITION

DIAGNOSTIC ULTRASOUND

MUSCULOSKELETAL

ELSEVIER

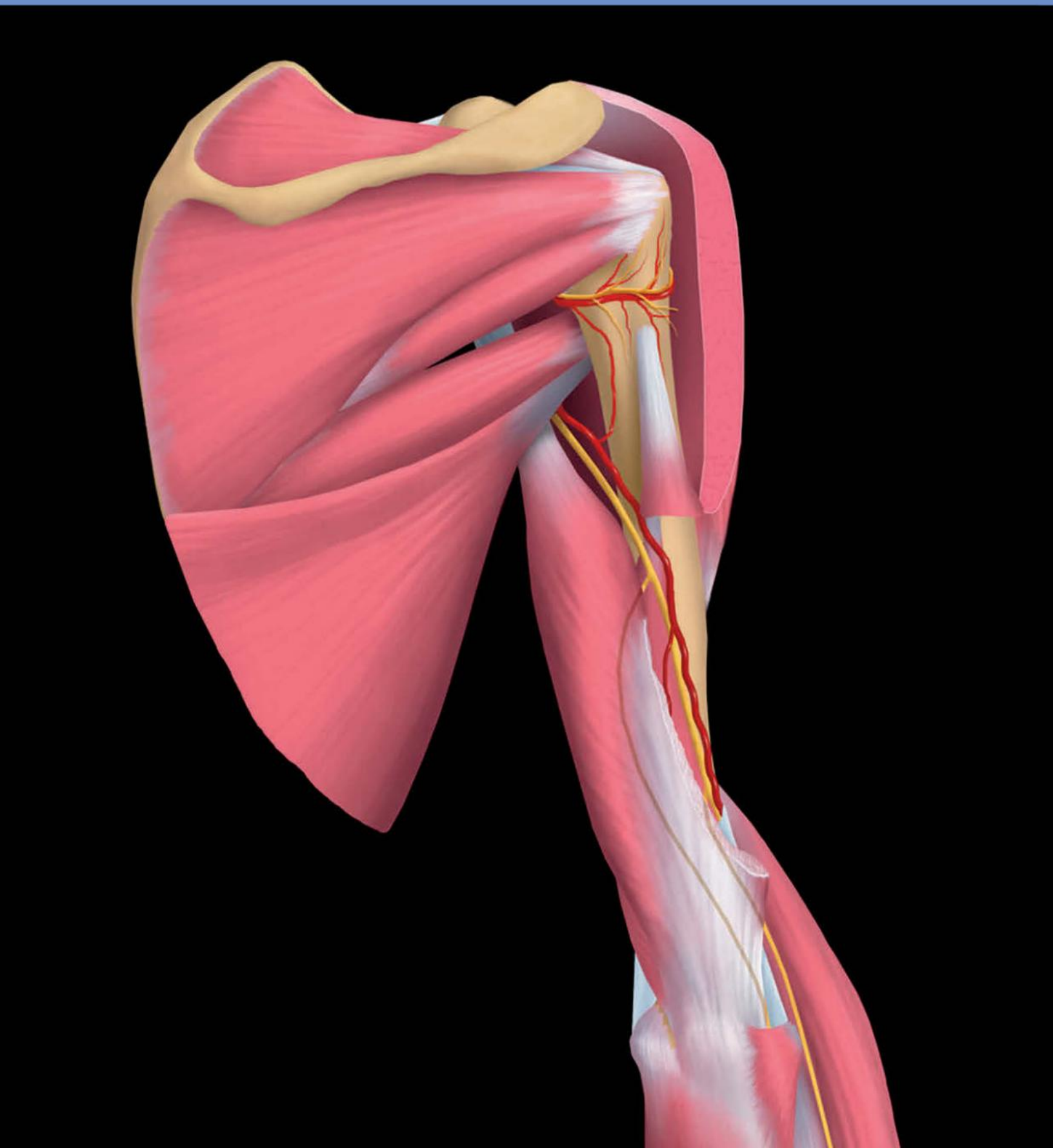

PART I
SECTION 1

Upper Limb

Sternoclavicular and Acromioclavicular Joints	4
Shoulder	10
Axilla	28
Arm	34
Elbow	42
Forearm	62
Wrist	72
Hand	88
Thumb	98
Fingers	108
Upper Limb Arteries and Veins	118
Brachial Plexus	130
Radial Nerve	138
Median Nerve	146
Ulnar Nerve	156

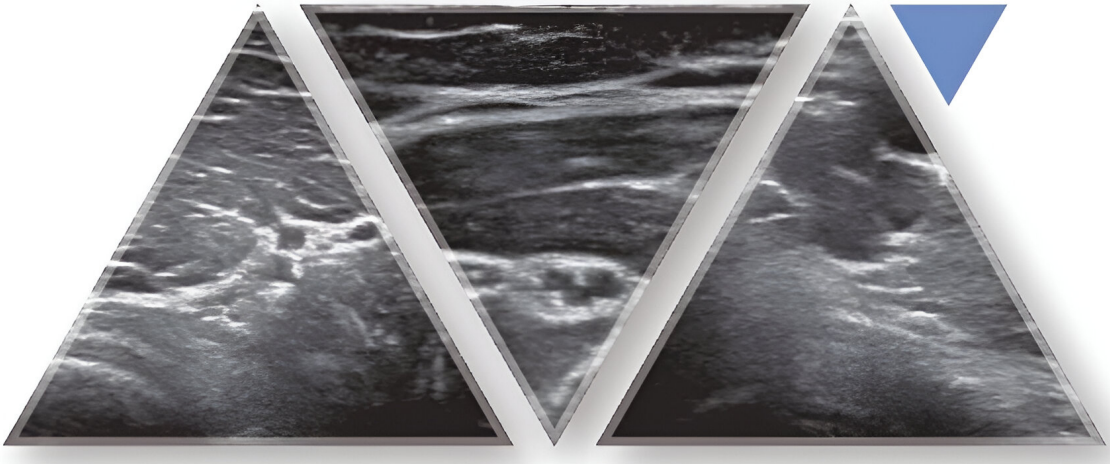

TERMINOLOGY

Abbreviations

- Sternoclavicular (SC) joint
- Acromioclavicular (AC) joint

GROSS ANATOMY

Sternoclavicular Joint

- Between medial end of clavicle & manubrium
  - Synovial sellar-type (saddle) joint
  - Medial end of clavicle is large & bulbous
  - Much larger than manubrial concavity
  - < 1/2 of medial clavicle articulates with manubrium
    - Capsuloligamentous structures provide stability
- Intraarticular disc
  - Attached to joint capsule anteriorly & posteriorly
  - Complete or incomplete ± perforations
  - Thickest posterosuperiorly (3 mm)
- Ligaments of SC joint
  - Capsular ligaments
    - Cover anterosuperior & posterior aspects of SC joint
    - Prevent upward displacement of medial clavicle, which may be caused by downward force on shoulder
    - Anterior stronger than posterior portion
  - Interclavicular ligament
    - Connects superomedial aspect of clavicle to capsular ligaments & upper manubrium
    - Covers anterosuperior & posterior aspects of joint
    - Prevents excessive upward motion of clavicle
  - Costoclavicular ligaments
    - Connect inferior surface of medial end clavicle to upper surface of 1st rib
    - Anterior fibers arise from anteromedial surface of 1st rib & resist upward motion
    - Posterior fibers arise lateral to anterior fibers & resist downward motion
- Muscle attachments to medial clavicle & sternum
  - Sternocleidomastoid from anterior aspect of medial 1/3 of clavicle (clavicular head)
    - Sternohyoid & sternothyroid muscles separate great vessels from SC joint
  - Pectoralis major from anterior aspect of medial 2/3 clavicle (clavicular head)

Acromioclavicular Joint

- Synovial joint between lateral end of clavicle & medial end of acromion
  - Articular surface of clavicle is oriented posterolaterally, while articular surface of acromion is oriented anteromedially
    - Inclination angle between opposing articular surfaces varies, with acromion articular surface tilting upward relative to clavicle (50%), vertical orientation between acromion & clavicle (25%), acromion articular surface tilting downward relative to clavicle (5%), & mixed pattern (20%)
    - Maximum width of normal joint on US = 5 mm if < 35 years & < 4.4 mm if > 35 years
    - Maximum thickness of capsule from bony surface = 2.7 mm if < 35 years & < 3.6 mm if > 35 years
- Intraarticular disc
  - Undergoes early degeneration beginning in 2nd decade to marked degeneration of disc by 4th decade
- Ligaments of AC joint
  - Superior AC ligament
    - Stronger & thicker (2.0-5.5 mm) than thin or absent inferior AC ligament
    - Inserts along lateral aspect of clavicle (8 mm) & medial aspect of acromion (10 mm)
  - Coracoclavicular ligaments (conoid & trapezoid)
    - Vary significantly in length & width
    - Conoid ligament located posteromedially
      - Inserts to conoid tubercle, which is located where middle 1/3 of clavicle curves into lateral 1/3 of clavicle
      - Mainly prevents upward movement of clavicle
    - Trapezoid ligament located anterolaterally
      - Inserts to trapezoid ridge, which runs along inferior surface of lateral 1/3 of clavicle
      - Mainly prevents lateral compression of clavicle against acromion
  - Muscles attached to lateral clavicle
    - Deltoid to anterior surface of lateral 1/3 of clavicle
    - Trapezius to posterior surface of lateral 1/3 of clavicle

ANATOMY IMAGING ISSUES

Imaging Recommendations

- Align transducer transversely along SC or AC joints
- Main clinical presentation of SC joint is painless lump
  - Even mild SC capsular thickening can present as mass clinically, since joint just beneath skin surface
    - Clinical swelling often due to relative forward positioning of apparently swollen SC joint due to axial rotation of upper trunk
    - Also, often due to mild capsular swelling ± mild subluxation secondary to SC osteoarthritis
  - Main clinical presentation of AC joint is pain due to osteoarthritis, AC joint impingement, inflammatory arthropathy, & subluxation/dislocation
    - Inflammatory osteoarthritis of AC joint is common
- AC joint laxity can be assessed by applying downward traction on arm while observing change in joint width on US
  - Compare with contralateral side
- AC joint index = AC joint width of uninjured side/AC joint width of injured side = 1.0 normally
- Determine whether AC joint is
  - Not subluxed (similar to opposite side): Grade 1
  - Partially subluxed (clavicle subluxed < 50% depth of AC joint): Grade 2
  - Severely subluxed or dislocated (clavicle subluxed > 50% depth of AC joint): Grade 3

Imaging Pitfalls

- SC or AC joints
  - Normal step-off between medial clavicle & manubrium &, to lesser degree, between lateral clavicle & acromion
    - Should not be interpreted as subluxation
  - Acromion normally elevates from rest position during arm adduction

STERNOCLAVICULAR JOINT

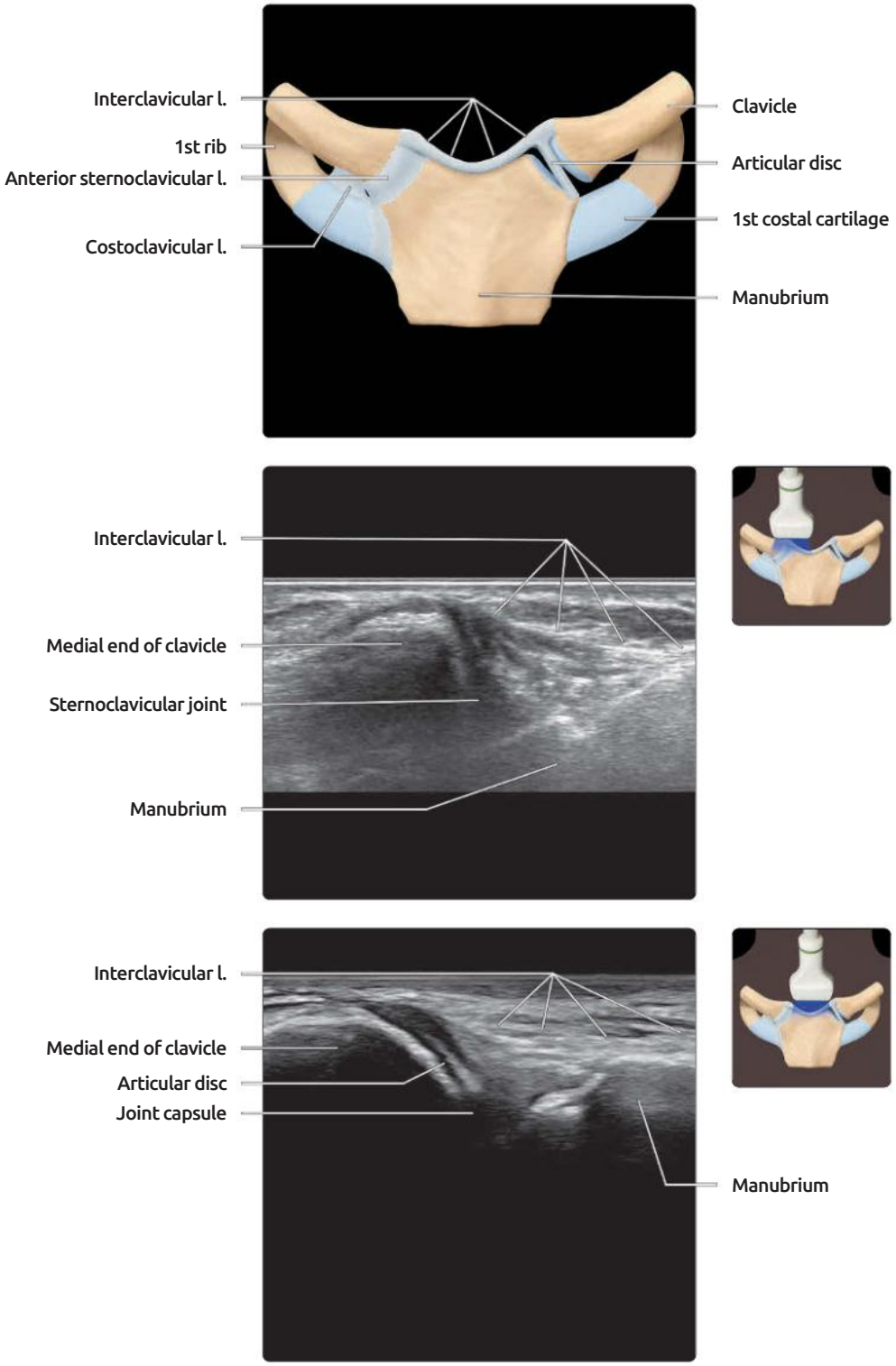

(Top) *Graphic shows the anterior aspect of the sternoclavicular joint. Note the joint capsule, articular disc, and interclavicular ligament.* **(Middle)** *Transverse US shows the anterosuperior aspect of the sternoclavicular joint. The medial clavicle is much larger than the articulating surface of the manubrium. The thin interclavicular ligament is closely applied to the superior aspect of manubrium, and its connection with the medial ends of the clavicle is depicted.* **(Bottom)** *Transverse US shows the echogenic fibrocartilaginous articular disc of the sternoclavicular joint. Visibility can be enhanced by anteropulsion of the ipsilateral shoulder joint.*

STERNOCLAVICULAR JOINT, SUPPORTING LIGAMENTS & MUSCLES

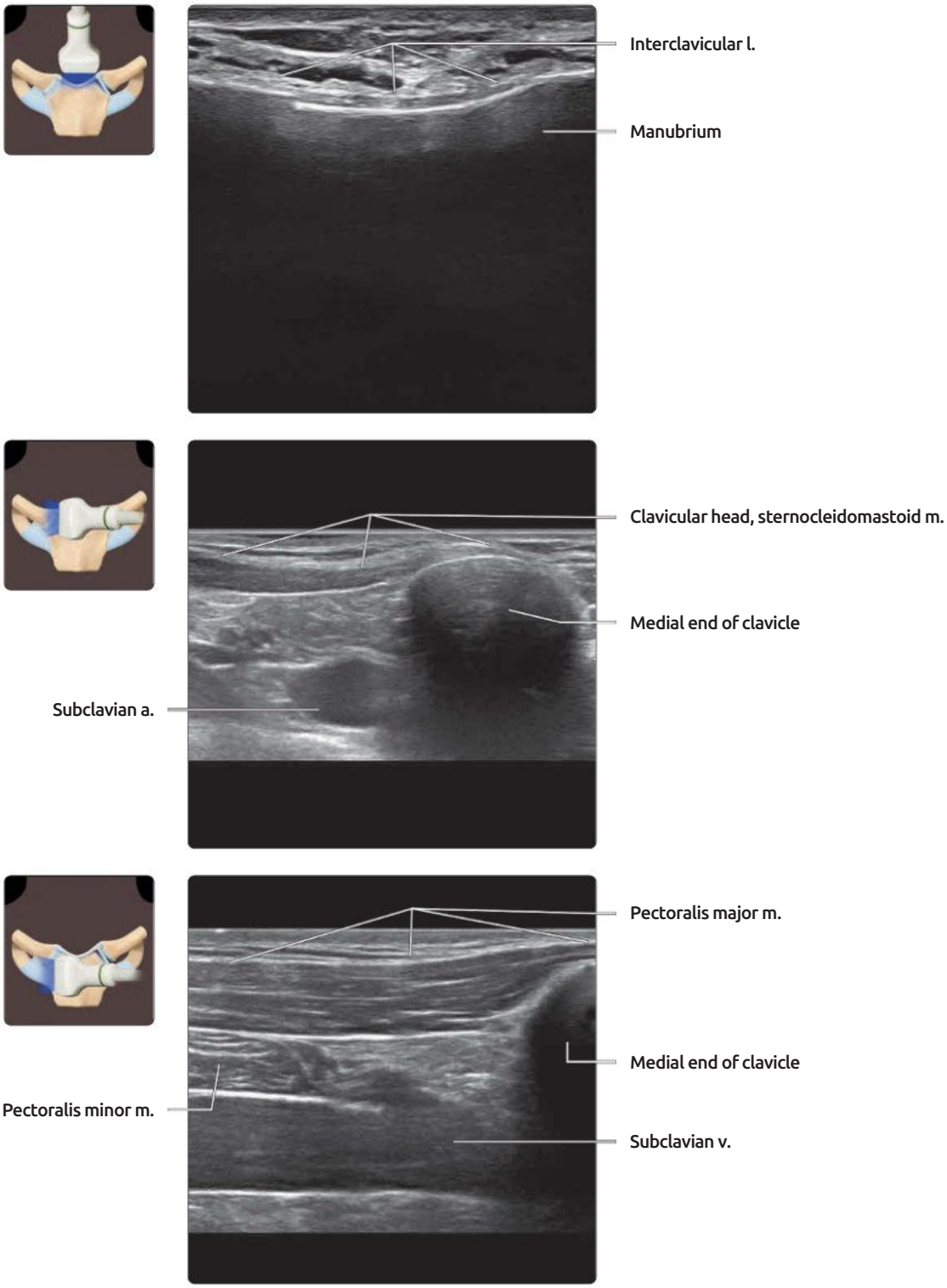

(Top) *Transverse US of the upper border of the manubrium shows the interclavicular ligament spanning the gap between the medial ends of both clavicles.* **(Middle)** *Longitudinal US of the medial end of the clavicle is shown. The sternocleidomastoid muscle is attached to the anterior aspect of the medial end of the clavicle as well as the anterior proximal surface of the manubrium (not shown). The sternohyoid and sternothyroid muscles (not shown) are attached to the posterior aspect of the sternum as well as to the clavicle and 1st costal cartilage.* **(Bottom)** *Longitudinal US shows the pectoralis major muscle attached to the anterior aspect of the clavicle as well as the sternum (not shown). Together, the sternocleidomastoid and the pectoralis major provide strong muscular support to the medial end of the clavicle.*

ACROMIOCLAVICULAR JOINT

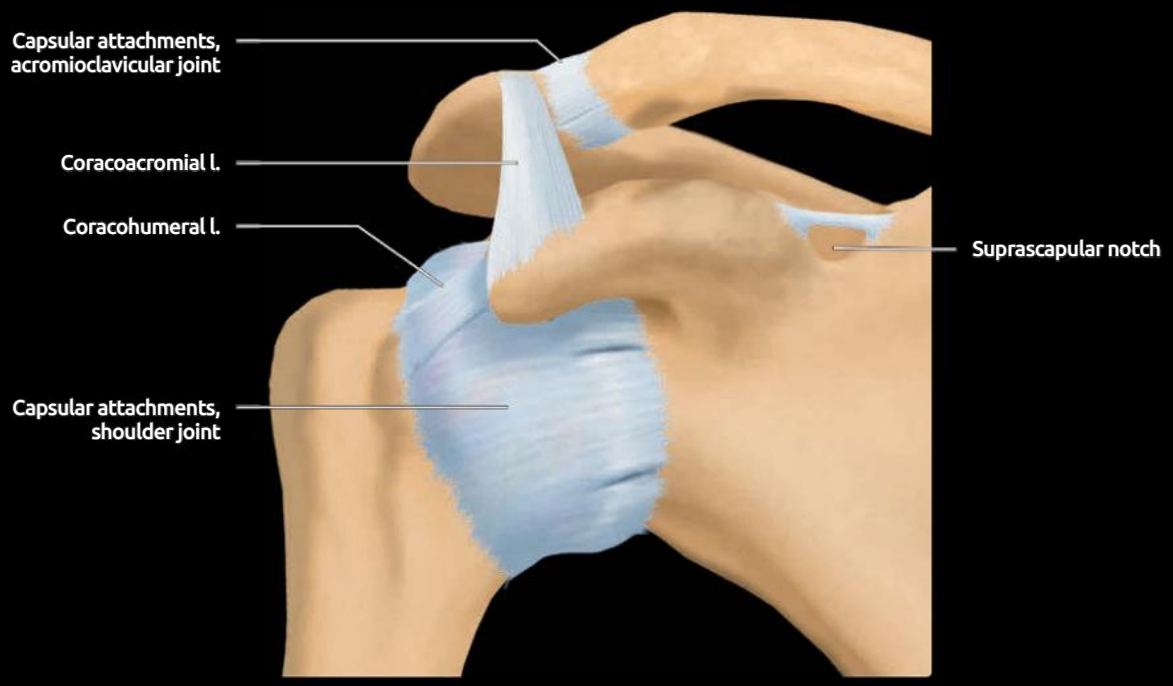

(Top) *Graphic shows the capsular ligaments of the acromioclavicular joint as well as the capsular attachments of the shoulder joint. The coracohumeral ligament and the acromioclavicular joint ligament, which provide additional support to the acromioclavicular joint, are also shown.* **(Bottom)** *Transverse US shows the strong superior acromioclavicular ligament at the superior aspect of the acromioclavicular joint. The remainder of the acromioclavicular joint capsule is quite thin. The capsule inserts onto a slightly larger area on the acromion than on the clavicle. The acromioclavicular joint is usually not vertically orientated. In this example, the articular surface of the acromion tilts downward slightly relative to the articular surface of the clavicle.*

ACROMIOCLAVICULAR AND CORACOHUMERAL LIGAMENTS

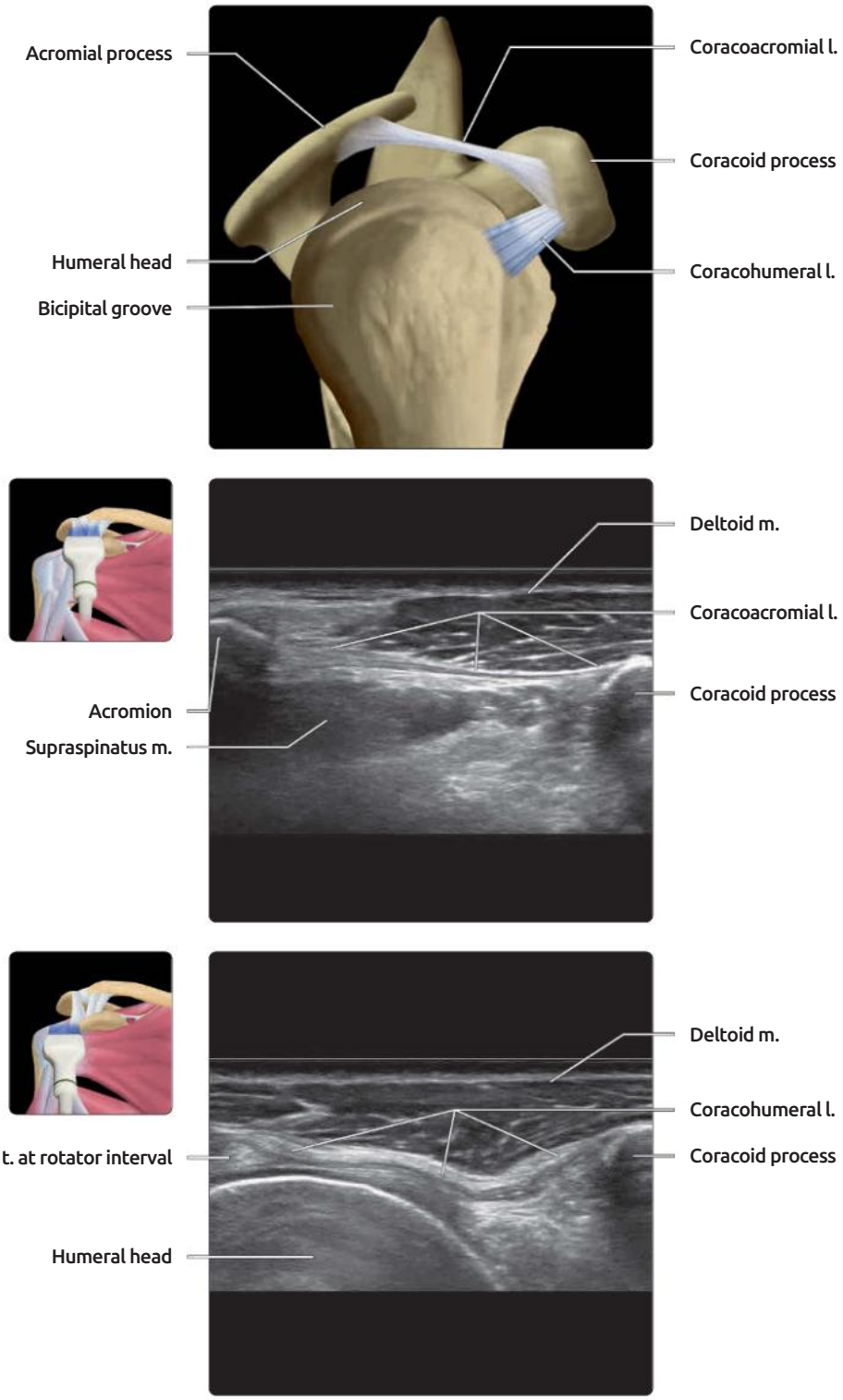

(Top) *Graphic shows the coracoacromial ligament (CAL), spanning the area between the undersurface of the acromion and the coracoid process. The coracohumeral ligament, extending between the coracoid process and the rotator interval, is also shown.* **(Middle)** *Transverse US shows the CAL spanning the area between the acromion and the coracoid process. The functional 'subacromial space' lies deep to both the acromion and the CAL ligament. The subacromial-subdeltoid (SA-SD) bursa and the supraspinatus musculotendinous junction lie deep to the CAL ligament. Both the SA-SD bursa and the supraspinatus tendon can impinge against the CAL during shoulder abduction.* **(Bottom)** *Transverse US shows the coracohumeral ligament extending between the coracoid process and the rotator interval. The ligament is lax in the neutral position, as shown here. It becomes taut on external rotation of the shoulder.*

CORACOCLAVICULAR LIGAMENTS

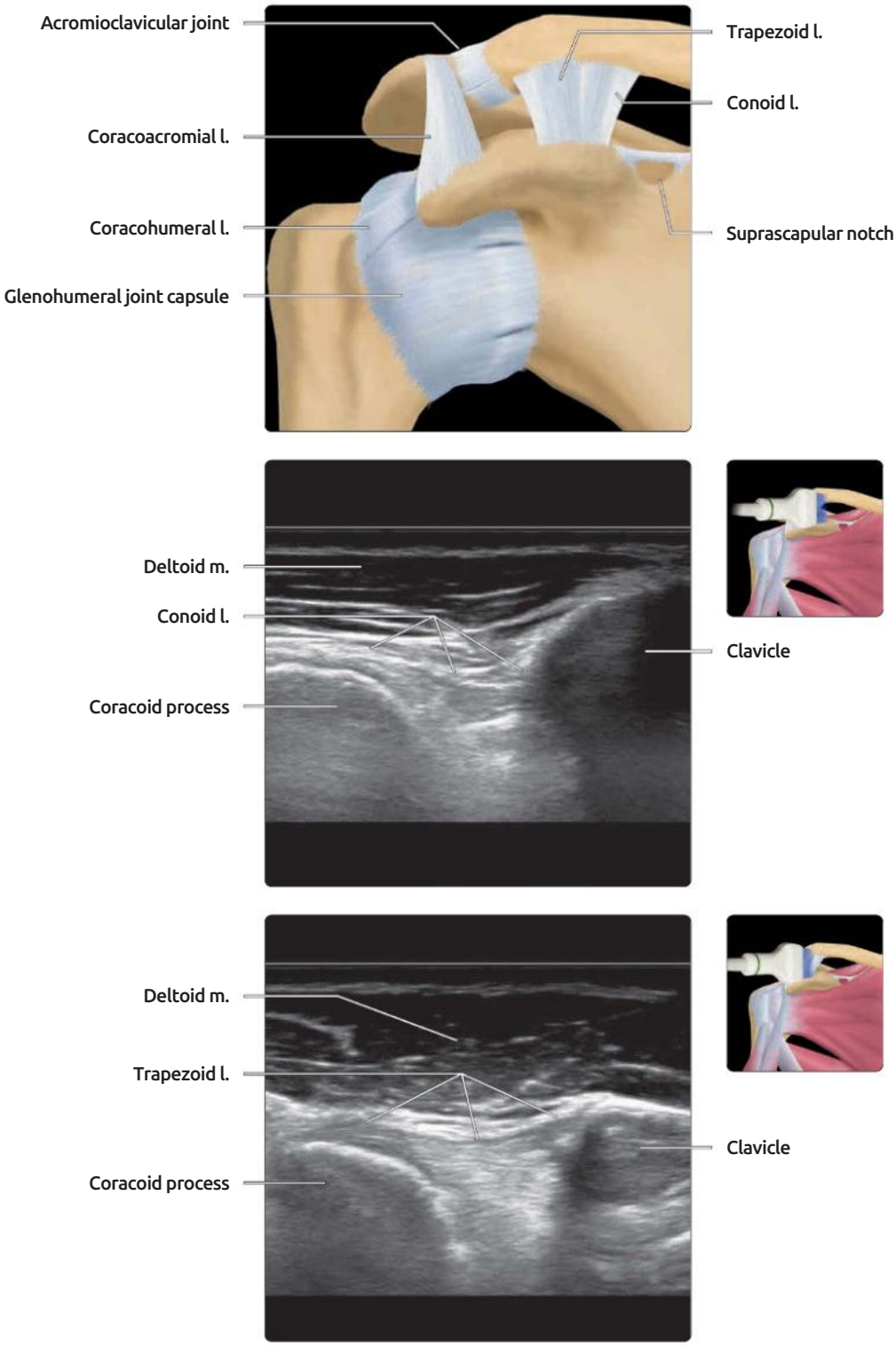

(Top) *Graphic shows the ligaments that support the acromioclavicular joint, all of which arise from the coracoid process. The coracoclavicular ligaments are the conoid and trapezoid ligaments. The conoid ligament lies more medial than the trapezoid ligament. The coracoacromial and coracohumeral ligaments provide additional support.* **(Middle)** *Longitudinal US shows conoid ligament extending between the coracoid process and the clavicle. This ligament is inserted into the conoid tubercle, which is located on the undersurface of the clavicle at the junction between the middle and lateral 1/3 of the clavicle.* **(Bottom)** *Longitudinal US shows the trapezoid ligament, which runs between the coracoid process and the trapezoid ridge. The trapezoid ridge extends along the inferior surface of the lateral 1/3 of the clavicle.*

IMAGING ANATOMY

Overview

- **Rotator cuff**
  - Comprises supraspinatus, infraspinatus, teres minor, subscapularis muscles & tendons
  - Posterior fibers supraspinatus interdigitate with anterior fibers infraspinatus at insertion
- **Supraspinatus muscle & tendon**
  - Origin: Supraspinatus fossa scapula
  - Insertion: Superior facet & anterior portion of middle facet greater tuberosity
    - Anterior 1/3 inserts into anterior 1/2 superior facet; middle 1/3 inserts into posterior 1/2 superior facet; posterior 1/3 inserts into anterior 1/2 middle facet
    - Overall insertional area ~ 23 mm anteroposterior x 7 mm mediolateral
    - ~ 6 mm thick 1 cm proximal to insertion
    - 5 layers from bursal to articular surface
    - (1) Coracohumeral ligament, (2) densely packed fibers, parallel orientation, (3) small fibers, random orientation, (4) loose connective tissue, (5) capsule
    - Layers cannot be separated on US or MR imaging
  - Nerve supply: Suprascapular nerve
  - Action: Abduction of humerus
  - Muscle composes 2 portions
    - Larger anterior portion with dominant tendon & smaller posterior portion
  - Most commonly torn rotator cuff tendon
  - **Aponeurotic expansion of supraspinatus tendon (AESST)**
    - Tendon-like structure originating from supraspinatus tendon, which passes alongside anterior aspect of long head of biceps tendon
      - Seen in 30% of normal patients
      - ↑ risk of supraspinatus tendon tear
- **Infraspinatus muscle & tendon**
  - Origin: Infraspinatus fossa scapula
  - Insertion: Middle facet greater tuberosity
  - Nerve supply: Suprascapular nerve
  - Action: External rotation of humerus
- **Teres minor muscle & tendon**
  - Origin: Lateral border of midscapula
  - Insertion: Inferior facet of greater tuberosity
    - More oblique tendon course than infraspinatus
  - Nerve supply: Axillary nerve
  - Action: External rotation of humerus
  - Least commonly torn rotator cuff tendon
- **Subscapularis muscle & tendon**
  - Origin: Subscapular fossa scapula
    - Multipennate structure ↑ strength
  - Insertion: Lesser tuberosity (tendinous attachment) & adjacent part of surgical neck (muscular attachment)
    - 4-6 tendon slips converge into main tendon
      - Superior fibers blend with coracohumeral ligament at rotator interval & anterior fibers of supraspinatus
  - Superficial fibers cross to lateral lip bicipital groove as transverse humeral ligament
    - Blends with expansion of pectoralis major tendon
  - Nerve supply: Subscapular nerve
  - Action: Mainly internal rotation & adduction of humerus
  - Largest rotator cuff muscle
- **Rotator cuff tendon blood supply**
  - Relatively hypovascular area termed critical zone ~ 1 cm proximal to insertion
    - Vulnerable to degeneration & calcific deposition
      - However, tears more frequent at insertional area than critical zone
- **Biceps tendon, long head tendon**
  - Origin: Supraglenoid tubercle, superior labrum ("biceps anchor")
    - Horizontal intraarticular segment leads to junctional segment ("genu"), which leads to vertical segment within bicipital groove
      - Myotendinous junction deep to pectoralis major tendon
  - Action: Stabilizes humeral head
  - Tendon sheath communicates with glenohumeral joint & often contains small amount of fluid
- **Rotator cuff interval**
  - Space between supraspinatus & subscapularis tendon through which biceps tendon passes
  - Borders of rotator cuff interval
    - Anterior border: Coracohumeral ligament
    - Posterior border: Humeral head
  - Reflections of coracohumeral ligament & superior glenohumeral ligament form biceps pulley, which stabilizes biceps tendon
- **Rotator cable**
  - Semicircular fibrous band on undersurface of supraspinatus & infraspinatus tendons
    - Localized thickening of parallel collagen fibers of joint capsule
  - Runs from coracohumeral ligament in rotator interval and inserts into posterior aspect of greater tuberosity
    - Located ~ 13 mm medial to tendon insertional area
    - Supraspinatus & infraspinatus tendon fibers lateral to cable known as rotator crescent
  - Cable is thicker ("cable dominant") in some patients (& in patients with tendinosis)
  - Helps prevent medial retraction of insertional tendon tears
- **Subacromial-subdeltoid bursa**
  - Large, synovial-lined bursa with predominantly fatty subintima
    - Roof attached to acromion, coracoacromial ligament, subdeltoid fascia
    - Floor fused with supraspinatus tendon & superior facet greater tuberosity
  - Normal bursa < 8 mm thick
- **Coracobrachial bursa**
  - Deep to conjoint tendon of coracobrachialis: Short head of biceps
- **Subcoracoid bursa**
  - Inconstant, deep to coracoid process
- **Subscapularis subtendinous bursa**
  - Deep to subscapularis tendon
- **Subscapularis recess**
  - Recess of joint capsule between superior & middle glenohumeral ligaments
    - Hangs like saddle bag over suprascapularis tendon

  - Inferior recess between middle & inferior glenohumeral ligaments less common
    - Lower margin subscapularis tendon
- **Coracoacromial ligament**
  - Forms coracoacromial arch extending from distal coracoid → subacromial area
    - Reinforces acromioclavicular joint
  - Thickest (normal < 2.5 mm) at subacromial insertional area
  - Also prone to insertional area plate-like hyperostosis osteophytic spurs
    - Contribute to subacromial impingement
    - Subacromial area cannot be seen on US
- **Pectoralis major muscle & tendon**
  - Origin: Clavicular & sternal heads
    - Clavicular head from medial 1/2 of clavicle
    - Sternal head as 6-7 segments from manubrium, sternum, & 2nd-6th costal cartilages
      - Constitutes 80% of muscle bulk; most prone to injury, especially inferior sternal segments
  - Insertion: Lateral lip bicipital groove > 7.5 cm long
  - Nerve supply: Lateral & medial pectoral nerves
  - Action: Adduction & internal rotation humerus, forward flexion
- **Glenoid labrum**
  - Triangular-shaped rim of fibrocartilage extending around glenoid periphery

ANATOMY IMAGING ISSUES

Imaging Approaches

- Supraspinatus tendon
  - Arm extended & internally rotated behind lumbar region ("Crass position")
    - Or hand behind hip with elbow close to body ("modified Crass position")
- Infraspinatus & teres minor tendons
  - Arm flexed & internally rotated with hand placed on contralateral shoulder
- Subscapularis tendon: Arm neutral & externally rotated
- Long head of biceps tendon
  - Arm neutral & externally rotated
  - Vary degree of external rotation for optimal view of biceps tendon
- Subacromial-subdeltoid bursa
  - Fluid collects preferentially just lateral to acromion & proximal humerus
- Acromioclavicular joint
  - Can pull down on arm to assess joint laxity
- Glenohumeral joint
  - Best seen from posterior aspect of joint
  - Passive movement of arm during scanning can help identify posterior glenoid labrum
- Spinoglenoid notch
  - Neutral position just medial to glenohumeral joint
- Supraspinatus, infraspinatus, & teres minor muscles
  - Neutral position with hands resting on thighs
  - Examine thickest part of muscle in retroscapular region
  - ↓ muscle bulk, ↑ echogenicity, ↓ visibility of central tendon are signs of atrophy with fatty replacement
    - Compare echogenicity to trapezius or deltoid muscles
- Pectoralis tendon & muscles
  - Supine position, abducted & externally rotated
  - Examine tendon in transverse
  - Turn transducer longitudinally & pan along length of tendon & clavicular/sternal muscle segments

Imaging Sweet Spots

- Look for tears, particularly at anterior leading edge of supraspinatus tendon
  - Unexplained bursal fluid is sensitive, indirect sign of bursal surface supraspinatus tendon tear
- Bursal fluid is often best seen with arm in neutral position or internal rotation
- As subclinical tendinosis & tears are common, do not rely on contralateral shoulder as internal reference standard

Imaging Pitfalls

- **Anisotropy**
  - Echoes are optimally reflected when transducer is parallel to tendon fibers
  - Rotator cuff tendons are prone to anisotropy due to curved course
  - If transducer is not at right angles to tendon, it will appear either isoechoic or hypoechoic to muscle
    - May mimic tendinosis or partial tear
- **Tendon edges**
  - Interfaces of tendons with adjacent structures may mimic tears
    - All pathology should be confirmed in 2 planes
- **Tendinous interspace at rotator cuff interval**
  - Interspace between leading (anterior) edge of supraspinatus & long head of biceps tendon may mimic tear
  - Overcome by recognizing ovoid or rounded shape of biceps tendon
- **Supraspinatus-infraspinatus junction**
  - Often relatively hypoechoic due to fiber interdigitation
    - May mimic partial-thickness tear
- **Fibrocartilaginous insertion**
  - Thin layer of fibrocartilage exists between tendon & bone at insertional area ("enthesis")
  - May mimic avulsive tear
- **Musculotendinous junction**
  - Supraspinatus tendon
    - Hypoechoic appearance can mimic subacromial-subdeltoid bursal distension or tendon tear
  - Subscapularis tendon
    - Tendon slips converging to main tendon may mimic tendinosis
- **Fluid in biceps tendon sheath**
  - Small amount of fluid is normal
    - Do not misinterpret as tenosynovitis
  - ↑ fluid in biceps tendon sheath reflects ↑ fluid in glenohumeral joint
- **Biceps tendon tear**
  - Collapsed tendon sheath following complete tear can mimic attenuated biceps tendon
    - Check distally to identify retracted torn tendon & muscle sagging
  - AESST may mimic split tear proximal biceps tendon

MUSCLES & LIGAMENTS

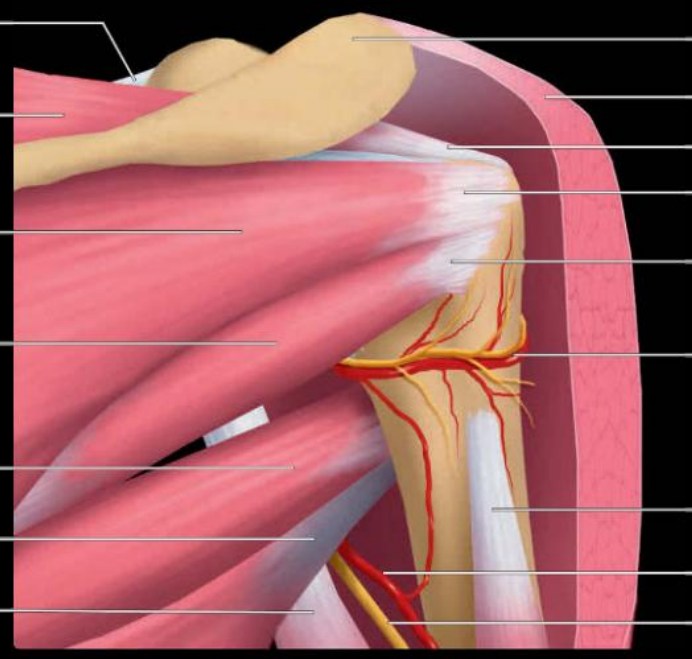

(Top) *Graphic of the anterior shoulder region shows the rotator cuff and adjacent structures. The rotator cuff composes the supraspinatus, infraspinatus, teres minor, and subscapularis muscles and tendons. The biceps tendon courses though the rotator interval between the supraspinatus and subscapularis tendons, then descends in the bicipital groove where it is covered by the transverse ligament.* **(Bottom)** *Graphic of the posterior shoulder region shows the rotator cuff and adjacent structures. The infraspinatus and teres muscles and tendons are located posteriorly. Inferior to the teres minor muscle and superior to the teres major muscle are the axillary nerve and posterior circumflex humeral vessels passing though the quadrilateral space.*

DEEP STRUCTURES

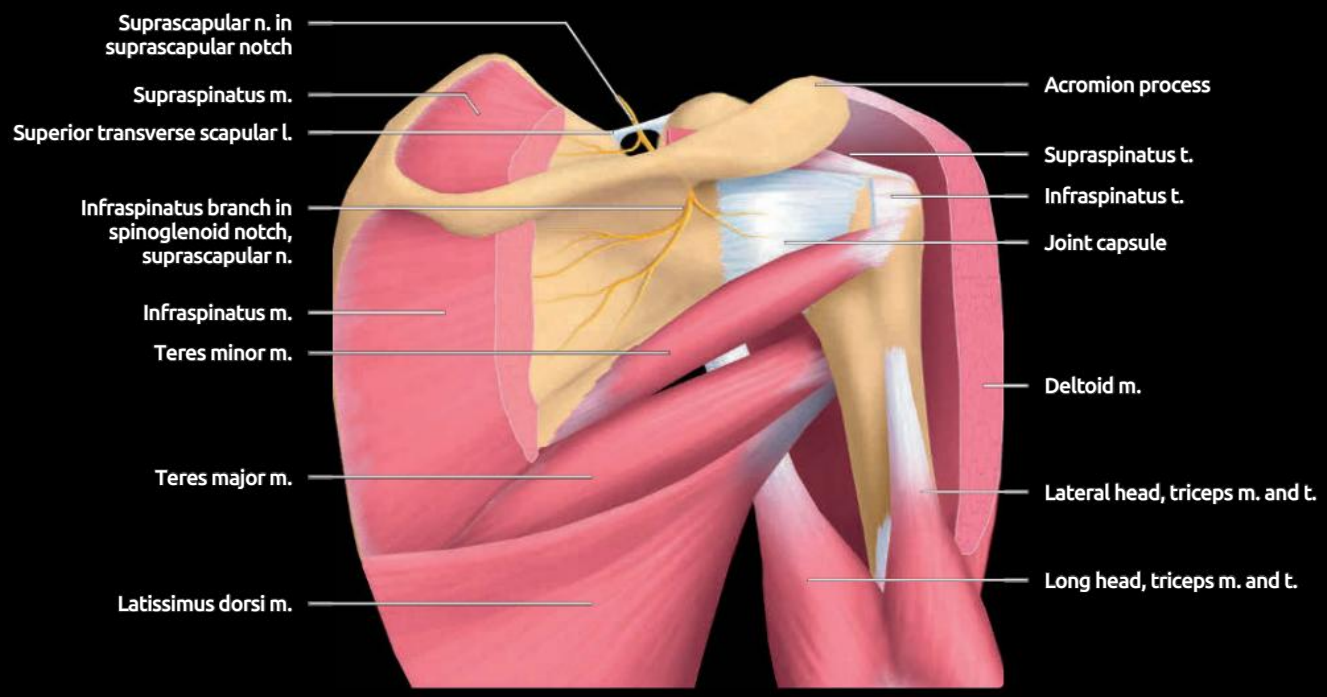

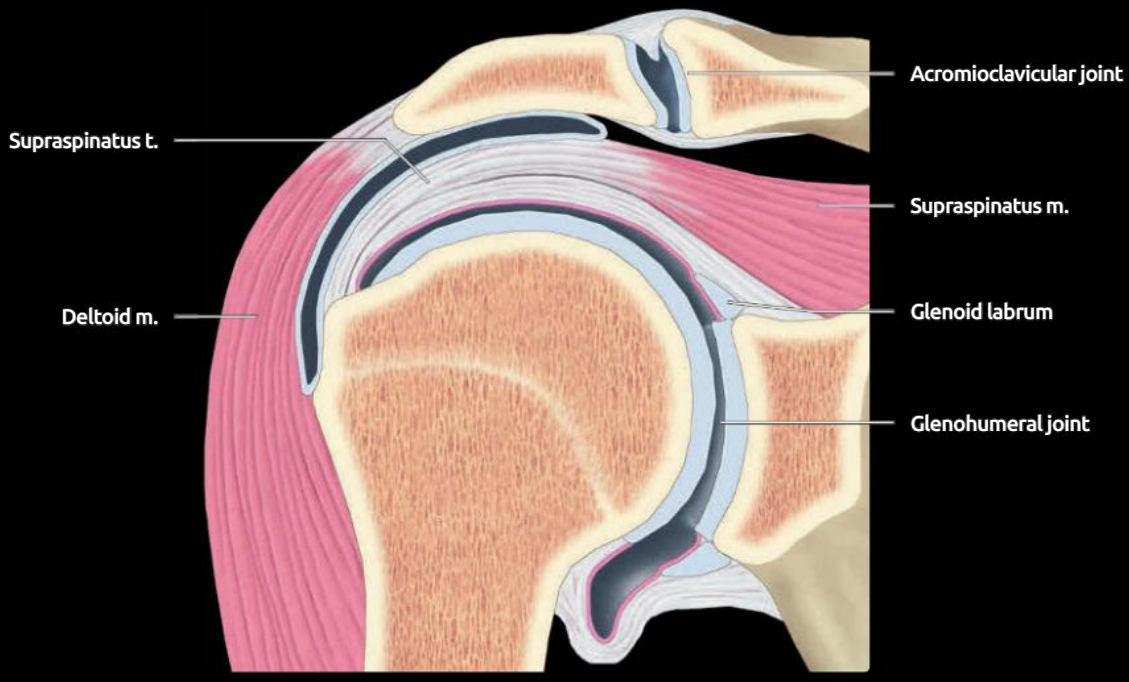

(Top) *Graphic shows the course of the suprascapular nerve. The nerve enters the supraspinous fossa through the suprascapular notch, deep to the superior transverse scapular ligament. The nerve then descends deep to the supraspinatus muscle and curves around the lateral border of the scapular spine to enter the infraspinous fossa. The suprascapular is a mixed sensory and motor nerve with sensory supply to the acromioclavicular and glenohumeral joints and motor supply to the supraspinatus and infraspinatus muscles.* **(Bottom)** *Graphic shows coronal section through the midportion of the shoulder joint. The subacromial-subdeltoid bursa is situated between the deltoid muscle, acromion, acromioclavicular joint, and distal clavicle superiorly and the supraspinatus tendon and muscle inferiorly. There is no communication normally between the bursa and the glenohumeral joint. Communication occurs with a full-thickness supraspinatus tendon tear. The bursa is one of the main pain generators of the shoulder. The wide expanse of the subacromial-subdeltoid bursa explains why shoulder symptoms are often poorly localized.*

SHOULDER CAPSULE & ROTATOR CUFF TENDON INSERTION

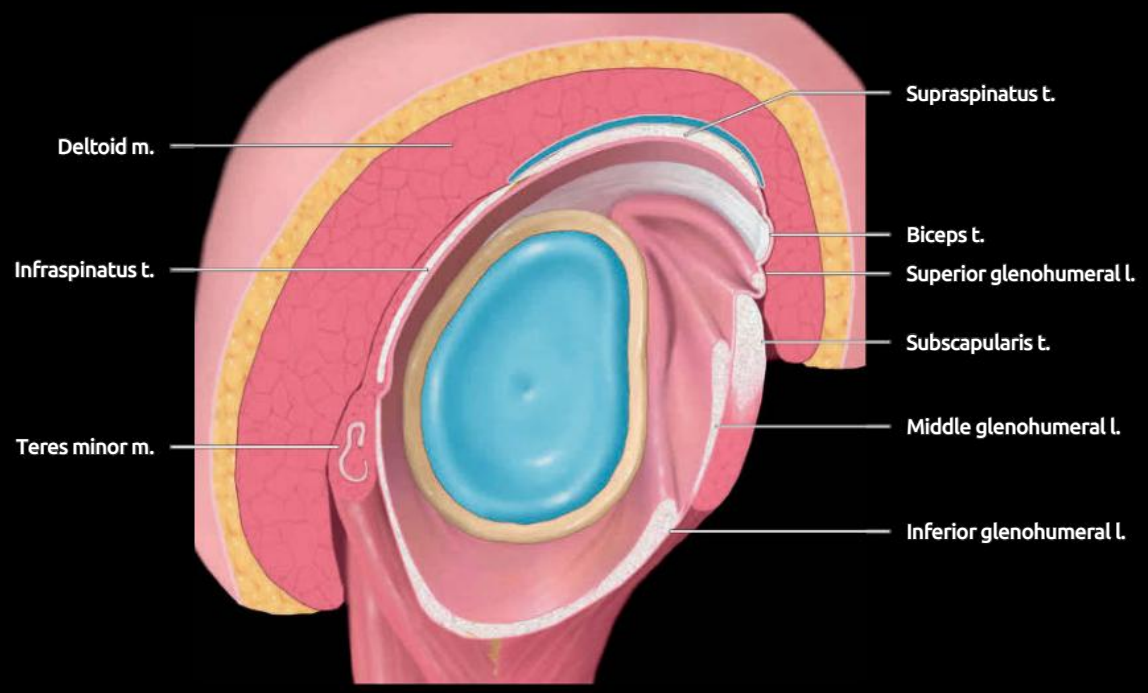

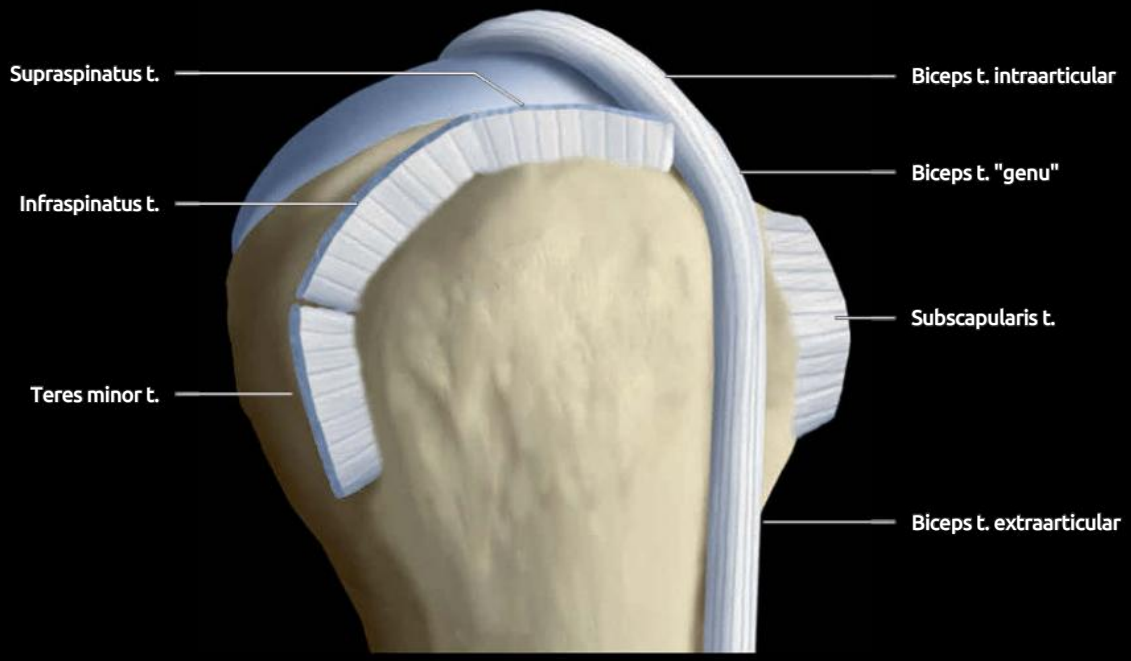

(Top) *Sagittal graphic shows the glenoid fossa. The labrum lines the glenoid edge, increasing the depth of and stabilizing the shoulder. Inferiorly, the labrum is barely discernible. The rotator interval surrounds the biceps tendon superiorly. The superior, middle, and inferior glenohumeral ligaments are distinctive thickenings of the anterior shoulder capsule, which cannot be resolved as separate structures on US examination. Adhesive capsulitis is associated with inflammation followed by fibrosis of the anterior shoulder structures and rotator interval. Clinically, this leads to painful, diminished external shoulder rotation.* **(Bottom)** *Sagittal graphic shows insertion of supraspinatus, infraspinatus, and teres minor tendons into the superior, middle, and inferior facets of the greater tuberosity, respectively. The opposing edges of supraspinatus and infraspinatus tendons merge. The biceps tendon moves from a more horizontal intraarticular portion to a more vertical extraarticular portion at the superior end of the bicipital groove, i.e., rotator interval area. This is known as the "genu" or "junctional zone" of the biceps tendon. The subscapularis is inserted mainly into the lesser tuberosity.*

SUPRASPINATUS INSERTIONAL AREA & ROTATOR CABLE

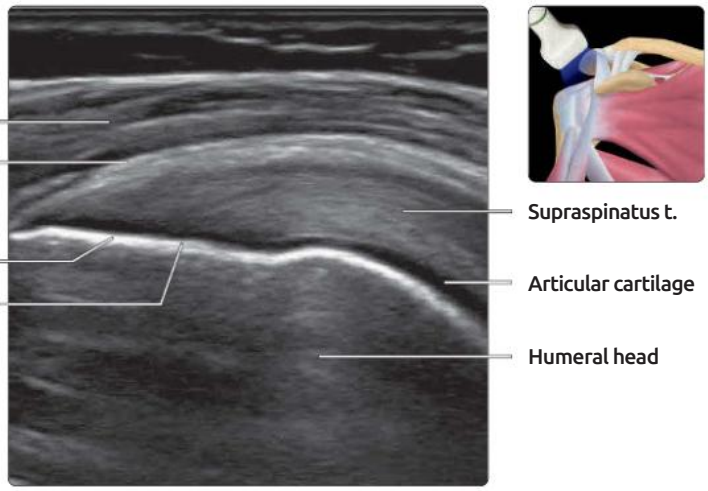

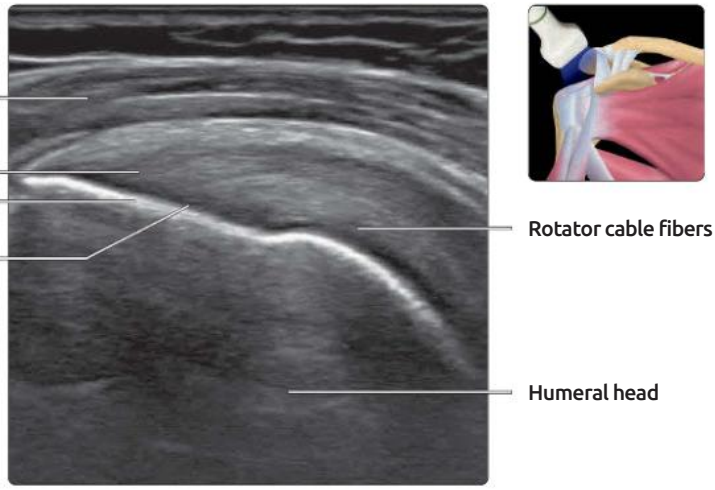

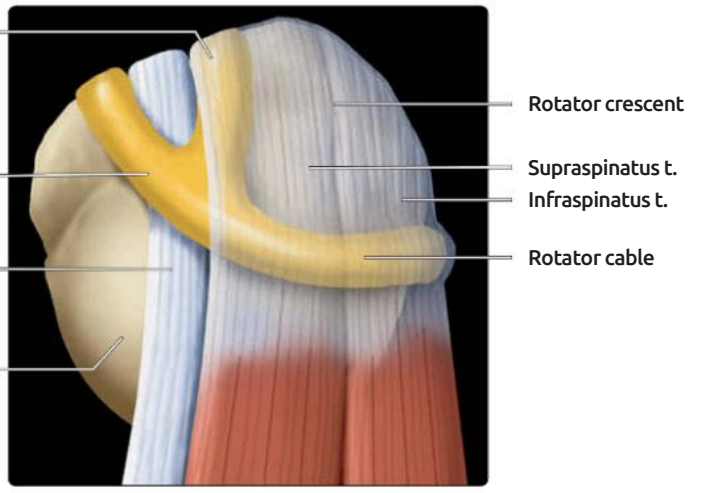

(Top) *Longitudinal US shows the anterior fibers of the supraspinatus tendon insertional area on the superior facet. The supraspinatus tendon inserts over a wide area ("footprint") on the superior facet and anterior parts of the middle facet of the greater tuberosity. Most supraspinatus tendon tears are avulsive-type tears from the insertional area. The normal subacromial-subdeltoid bursa is often not seen, per se. The peribursal fat around the bursa is readily appreciated.* **(Middle)** *Longitudinal US shows the supraspinatus tendon posterior fibers attached to anterior part of the middle facet. The slightly more echogenic transversely orientated rotator cable fibers can be appreciated.* **(Bottom)** *Graphic shows the rotator cable. Anteromedially, the cable merges with the medial and lateral bands of the coracohumeral ligament to surround and stabilize the biceps tendon in the rotator interval. The cable then travels posteriorly deep to the supraspinatus and infraspinatus tendons to attach to the posterior aspect of greater tuberosity immediately cranial to the teres minor insertion. The semicircular area of the supraspinatus and infraspinatus tendons lying lateral to the cable is the rotator crescent.*

SUPRASPINATUS INSERTIONAL AREA

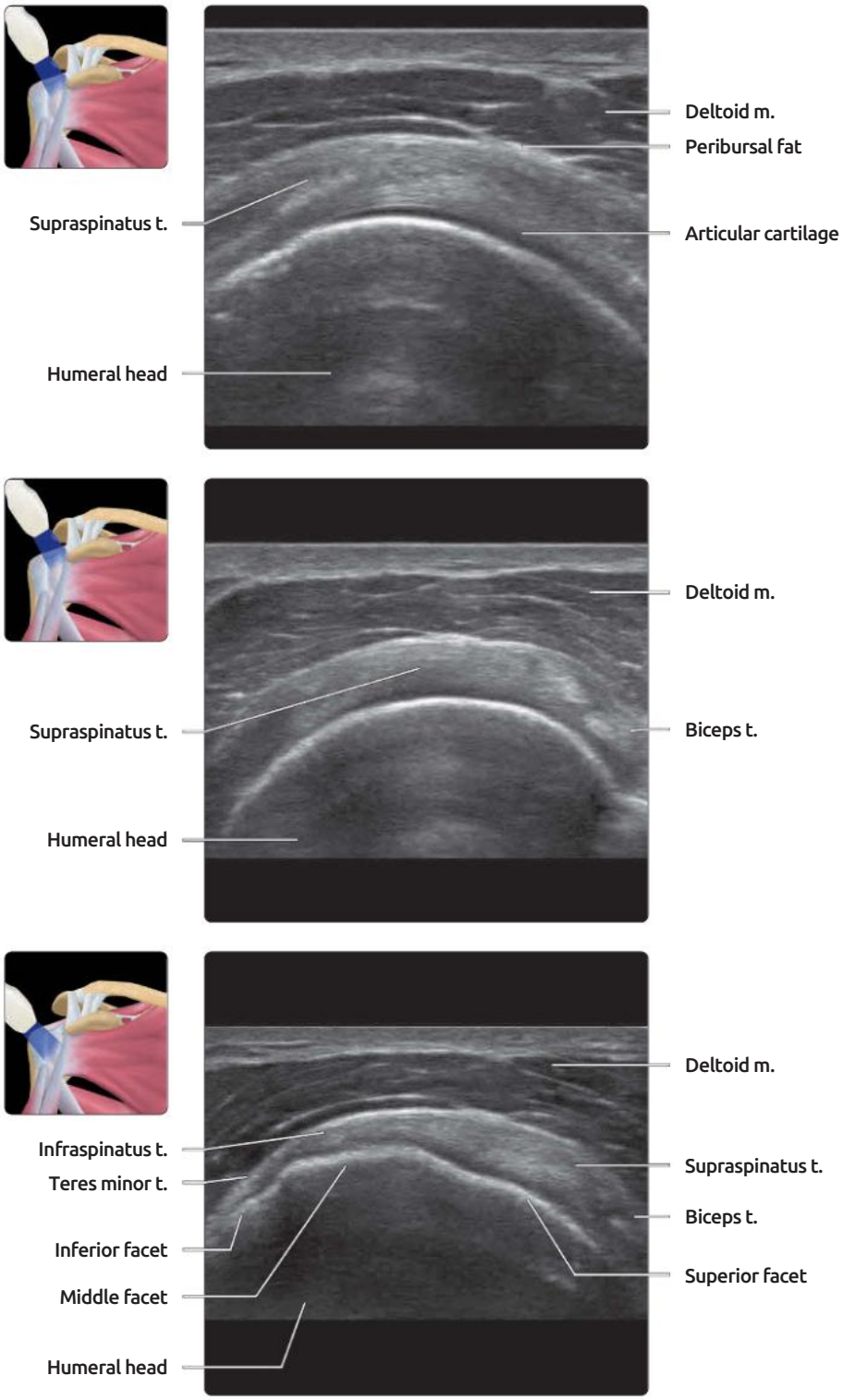

(Top) *Transverse US shows the supraspinatus tendon medial to the insertional area. Angulation and slight movement of the transducer will allow visualization of the lateral, middle, and medial fibers, respectively. The increased echogenicity of the more transversely orientated cable fibers can be appreciated.* **(Middle)** *Transverse US shows the supraspinatus tendon at the medial end of the insertional area. The biceps tendon at the leading edge of the anterior fibers supraspinatus can be appreciated.* **(Bottom)** *Transverse US at a more lateral aspect of greater tuberosity shows the superior, middle, and inferior facets for insertion of the supraspinatus, infraspinatus, and teres minor tendons, respectively. The orientation is not anatomic in this section, as the humeral is internally rotated. The biceps tendon in the rotator interval is also shown.*

CORACOACROMIAL & CORACOHUMERAL LIGAMENTS

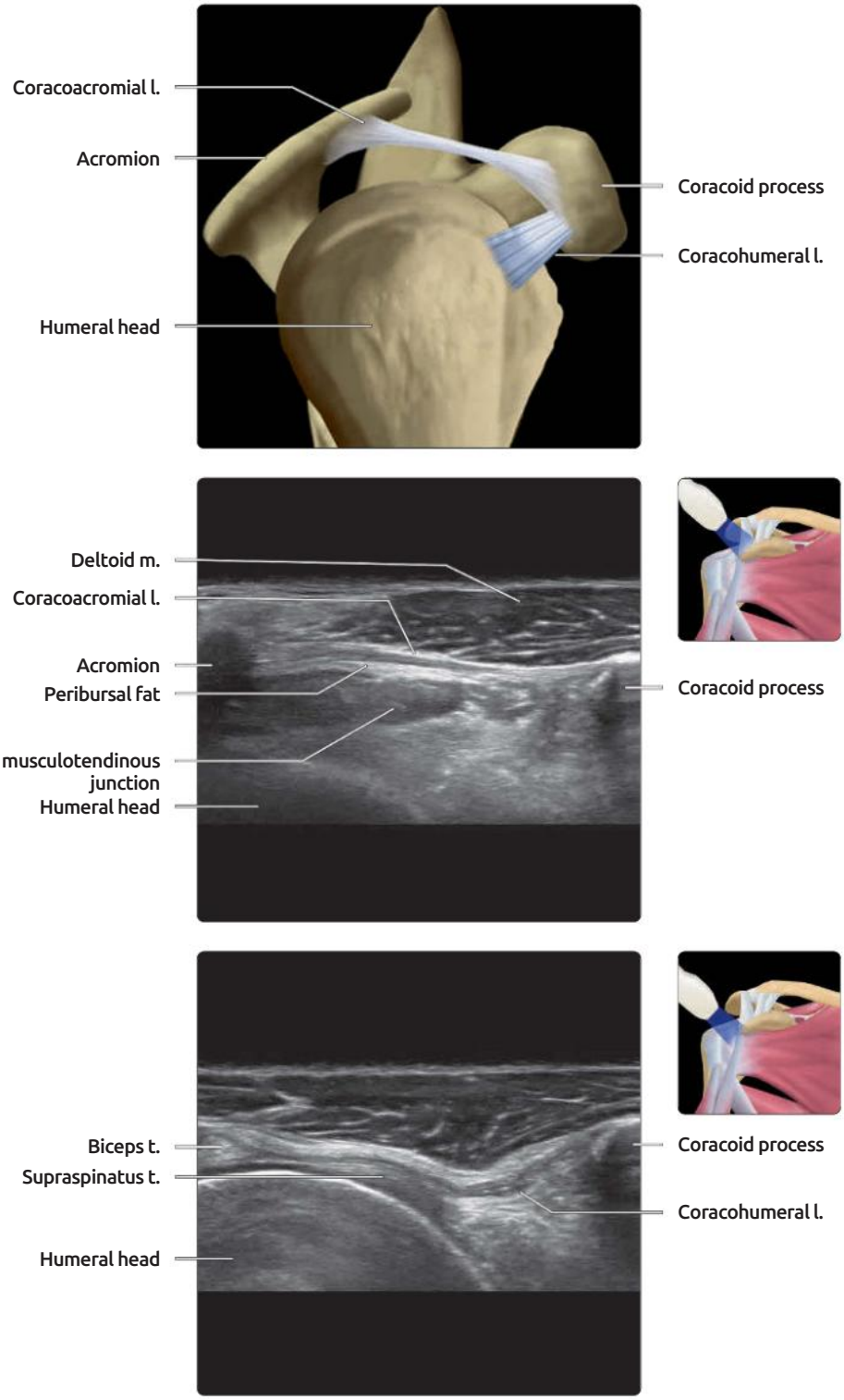

(Top) *Graphic shows the coracoacromial ligament (CAL) and CHL. The CAL runs from the undersurface of the coracoid process to the undersurface of the acromion and stabilizes the acromioclavicular joint. It may thicken, usually at the subacromial insertion, and encroach on the subacromial space. The CHL runs from the lateral aspect of the horizontal limb of the coracoid process to insert onto the greater and lesser tuberosities, covering the rotator interval. It helps stabilize the glenohumeral joint.* **(Middle)** *Transverse US shows CAL spanning the gap between the coracoid process and the acromion. The subacromial-subdeltoid bursa and supraspinatus musculotendinous junction tendon lie below the CAL at rest. With adduction, the supraspinatus tendon moves medially below the CAL.* **(Bottom)** *Transverse US shows the CHL extending between coracoid process and rotator interval in a neutral position. The CHL is tauter in external rotation and laxer in internal rotation. The CHL, with the superior glenohumeral ligament, stabilizes the biceps tendon in the rotator interval.*

ROTATOR INTERVAL

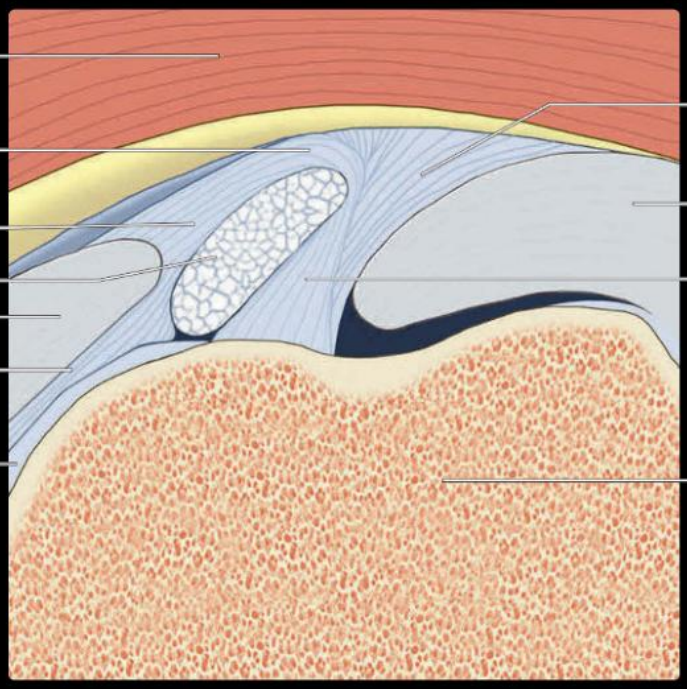

(Top) *Graphic shows the rotator interval and the high connectivity that exists between the rotator cable, the lateral and medial bands of the CHL, and the superior glenohumeral ligament, all interconnecting and serving to stabilize the biceps tendon at the rotator interval.* **(Bottom)** *Transverse US shows the rotator interval, which is the space between the anterior edge of supraspinatus tendon and the superior edge of subscapularis tendon. It contains the biceps tendon surrounded by the coracohumeral and superior glenohumeral ligaments. Patients with adhesive capsulitis may show increased thickening, hypoechogenicity, and, occasionally, hyperemia around the biceps tendon in the rotator interval due to inflammatory fibrovascular soft tissue overgrowth.*

BICEPS TENDON

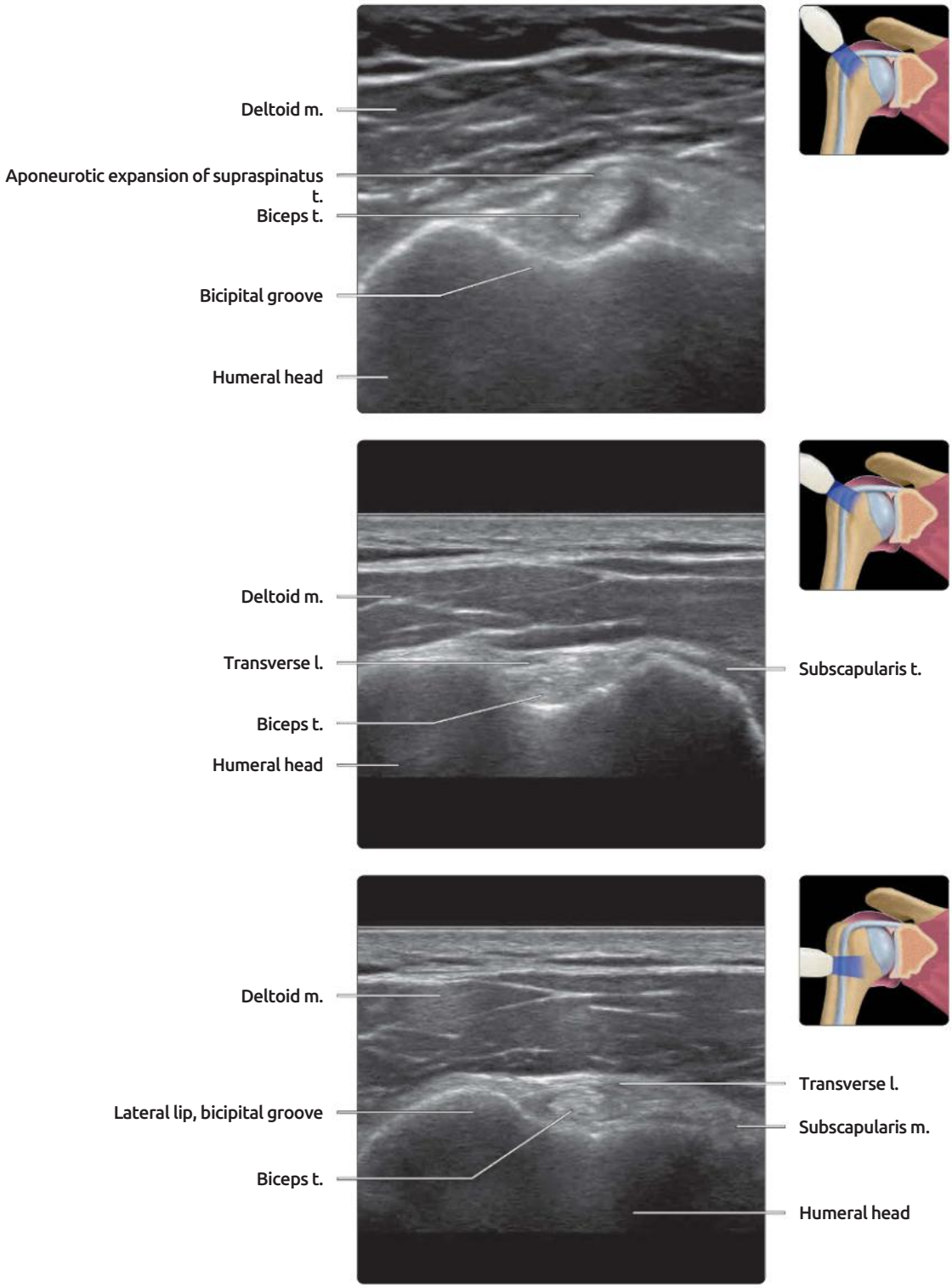

(Top) *Transverse US at the cephalad end of bicipital groove shows the normal oblong shape of the long head of the biceps tendon at this location. There is no tendinosis present. The small echogenic component superficially most likely represents the aponeurotic extension of the supraspinatus tendon (AESST) rather than a split biceps tendon tear.* **(Middle)** *Transverse US at the proximal aspect of the biceps tendon shows the normal smooth bicipital groove as a fibroosseous tunnel for the biceps tendon. The transverse ligament is formed by lateral expansion of the superficial subscapularis tendon fibers. The normal biceps tendon has an ovoid configuration.* **(Bottom)** *Transverse US shows the more distal end of the bicipital groove. The transverse ligament is still visible down to the level of pectoralis major tendon insertion. The lower part of the bicipital groove is shallower than the upper part.*

BICEPS & PECTORALIS MAJOR TENDONS

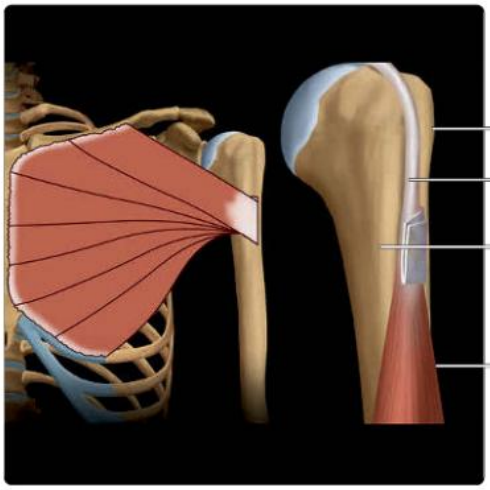

(Top) *Graphic shows the pectoralis major muscle and tendon. The pectoralis muscle has clavicular heads and several sternal heads. The common tendon passes anterior to the biceps tendon before attaching to the lateral lip of the bicipital groove. The tendon is U-shaped with anterior and posterior layers continuous inferiorly. The anterior layer receives clavicular and upper sternal fibers, while the posterior layer receives lower sternal fibers.* **(Middle)** *Longitudinal US shows the biceps tendon. There is often a small amount of fluid in the biceps tendon sheath, which is continuous with the glenohumeral joint. This is normal and should not be mistaken for tenosynovitis. No fluid is shown in this image.* **(Bottom)** *Transverse US shows the musculotendinous junction of the biceps tendon. It is located deep to the pectoralis major tendon close to the insertion of the pectoralis major tendon into the lateral lip of the bicipital groove. A completely torn long head of the biceps tendon will often retract to this level. One can appreciate the bilayered morphology of the pectoralis major tendon.*

SUBSCAPULARIS TENDON

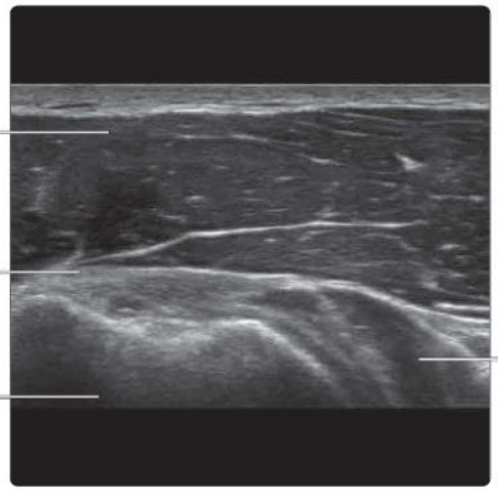

(Top) *Transverse US of the subscapularis tendon shows how the tendinous subscapularis muscle bands merge laterally into a flattened tendon. The superior 2/3 of the subscapularis has a tendinous insertion into the lesser tuberosity. The superior fibers of the subscapularis tendon interdigitate with the anterior fibers of supraspinatus tendon and contribute to the rotator interval.* **(Middle)** *Transverse US shows the midportion of the subscapularis insertional area.* **(Bottom)** *Transverse US shows the inferior part of the subscapularis tendon. The inferior 1/3 of the subscapularis muscle has a fleshier, more muscular attachment onto the more distal part of the lesser tuberosity and adjacent humeral shaft. The biomechanics of the inferior 1/3 of the subscapularis muscle and tendon are also somewhat different from that of the upper 2/3 of the muscle and tendon.*

SUBSCAPULARIS TENDON

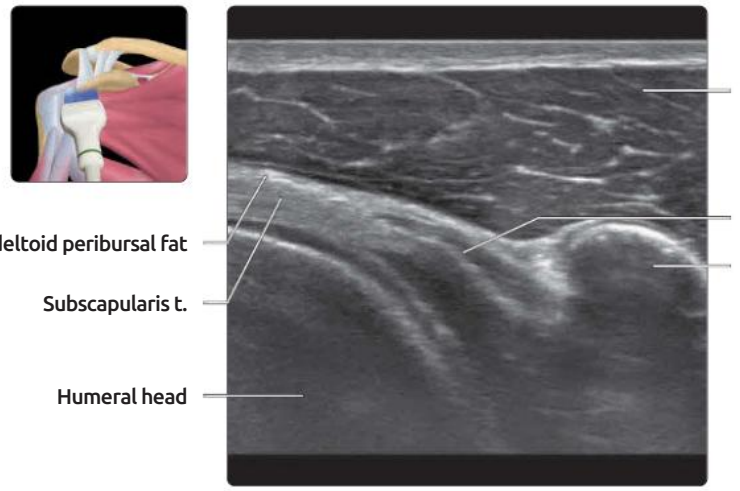

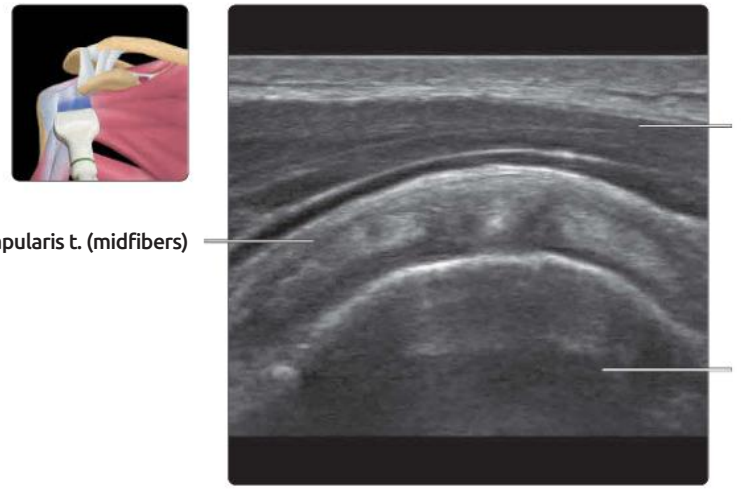

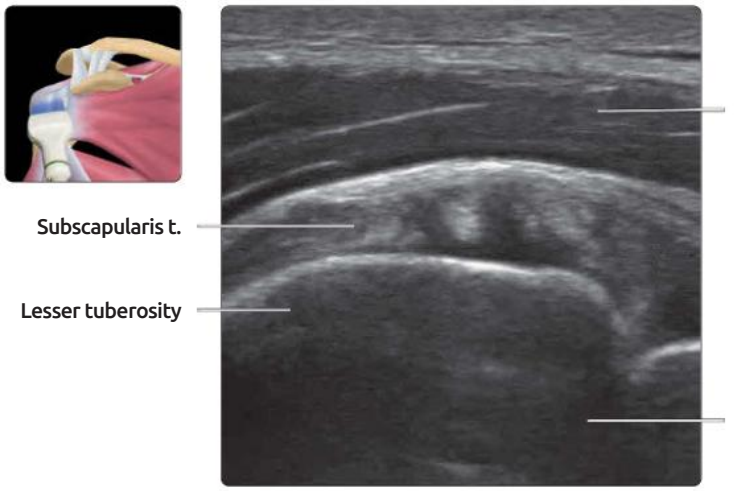

(Top) *Transverse US shows the subscapularis tendon musculotendinous junction deep to the coracoid process. The subscapularis tendon moves beneath the coracoid process on internal-external rotation. Narrowing of the coracohumeral distance to < 6 mm is associated with increased risk of subcoracoid impingement.* **(Middle)** *Transverse US shows the multipennate structure of the subscapularis tendon. 4-6 muscle tendons converge to a single tendon inserting onto the lesser tuberosity and the adjacent humeral shaft. This heterogeneous appearance should not be confused with tendinosis.* **(Bottom)** *Transverse US shows how the multipennate tendinous structure of the subscapularis tendon remains until the insertion into the lesser tuberosity. Tears of the subscapularis tendon usually occur just proximal to the insertional area. These tears may involve the tendinous expansion covering the biceps tendon (transverse ligament), resulting in medial dislocation of the long head of the biceps tendon.*

INFRASPINATUS TENDON & MUSCLE

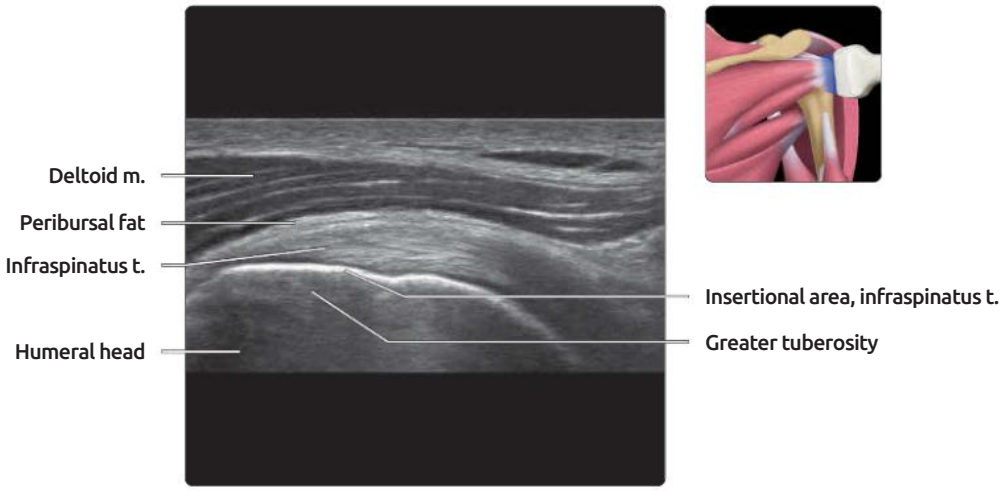

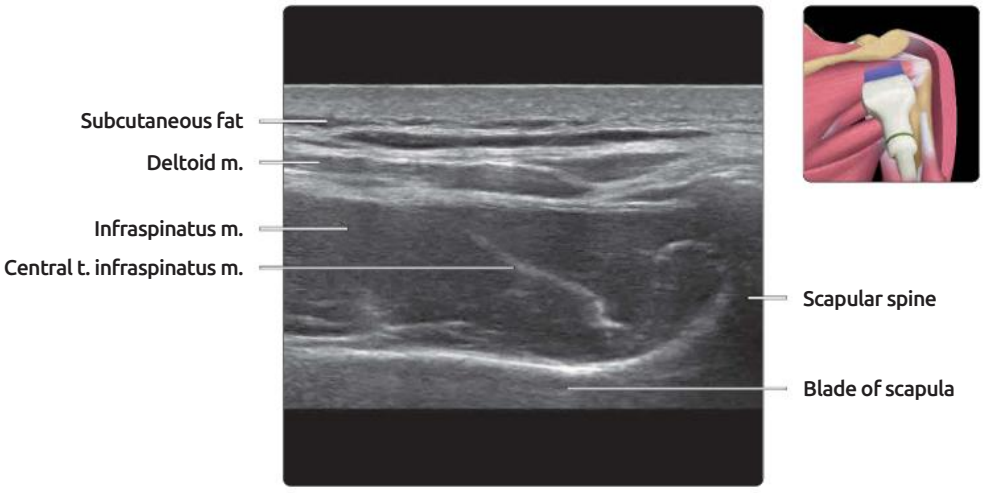

(Top) *Longitudinal US shows the infraspinatus tendon insertional area into the middle facet of the greater tuberosity. The infraspinatus tendon is less commonly torn than the supraspinatus tendon. Most infraspinatus tendon tears are avulsive-type tears involving the insertional area.* **(Middle)** *Longitudinal US at a more proximal level to the previous image shows the infraspinatus musculotendinous junction. The muscle fibers interdigitate with the tendon at the musculotendinous junction and should not be mistaken for tears or tendinosis.* **(Bottom)** *Transverse US shows the normal lean infraspinatus muscle. Muscle atrophy is seen as reduced muscle bulk and increased muscle echogenicity due to fat infiltration, leading to decreased conspicuity of the central tendon.*

TERES MINOR TENDON & MUSCLE

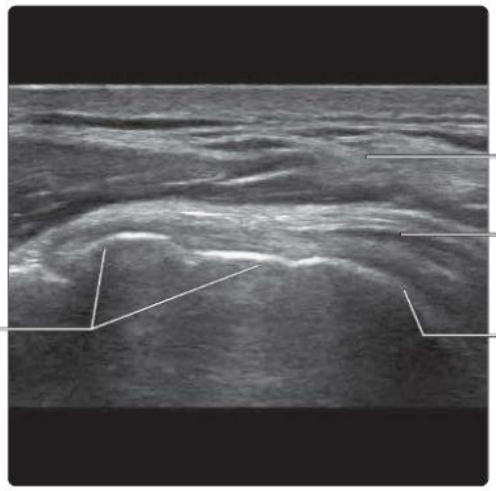

(Top) *Longitudinal US shows the teres minor muscle insertional area onto the inferior facet of the greater tuberosity. The teres minor muscle is usually not torn in isolation, though it may tear in massive rotator cuff tendon tears. The muscle and tendon are smaller than the infraspinatus muscle and have a more oblique vertical course. They are located posteroinferior to the infraspinatus muscle and tendon.* **(Middle)** *Longitudinal US shows the musculotendinous junction of the teres minor muscle.* **(Bottom)** *Transverse US shows the teres minor muscle. The teres minor muscle is best depicted on transverse imaging at the inferior aspect of the infraspinatus tendon. Isolated teres minor muscle atrophy can occur in quadrilateral space syndrome due to compression of the axillary nerve, which supplies the teres minor muscle. Part of the deltoid muscle may also be affected.*

SHOULDER CAPSULE & POSTERIOR ASPECT OF SHOULDER

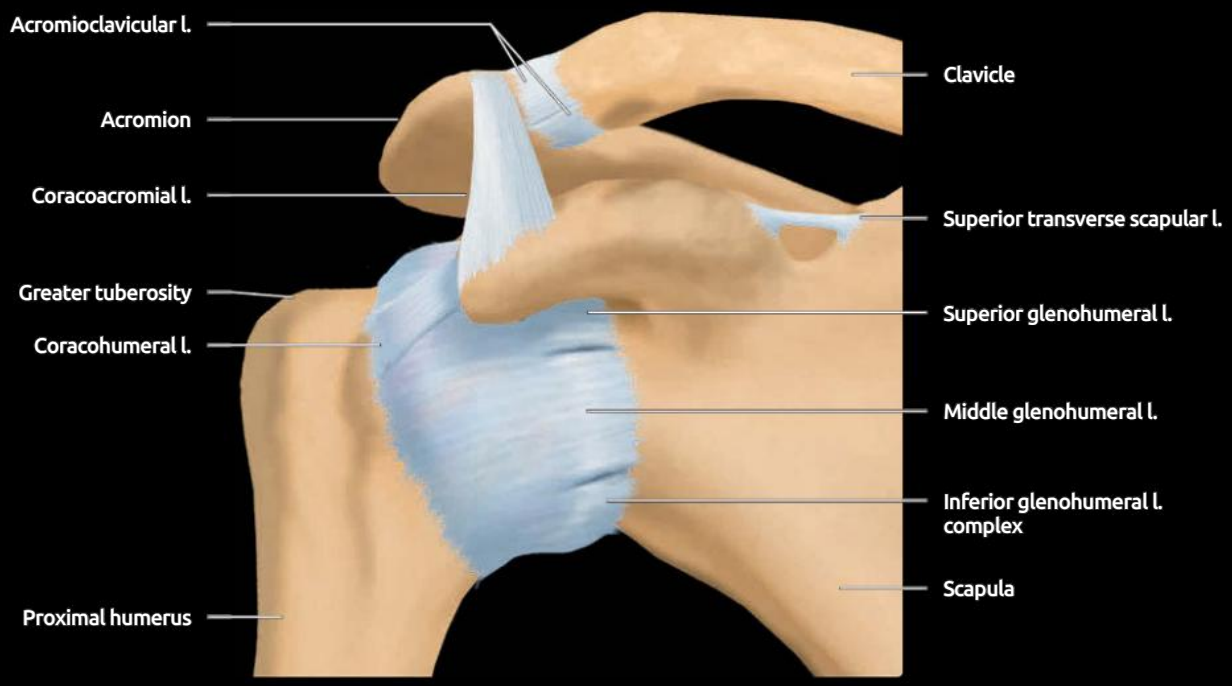

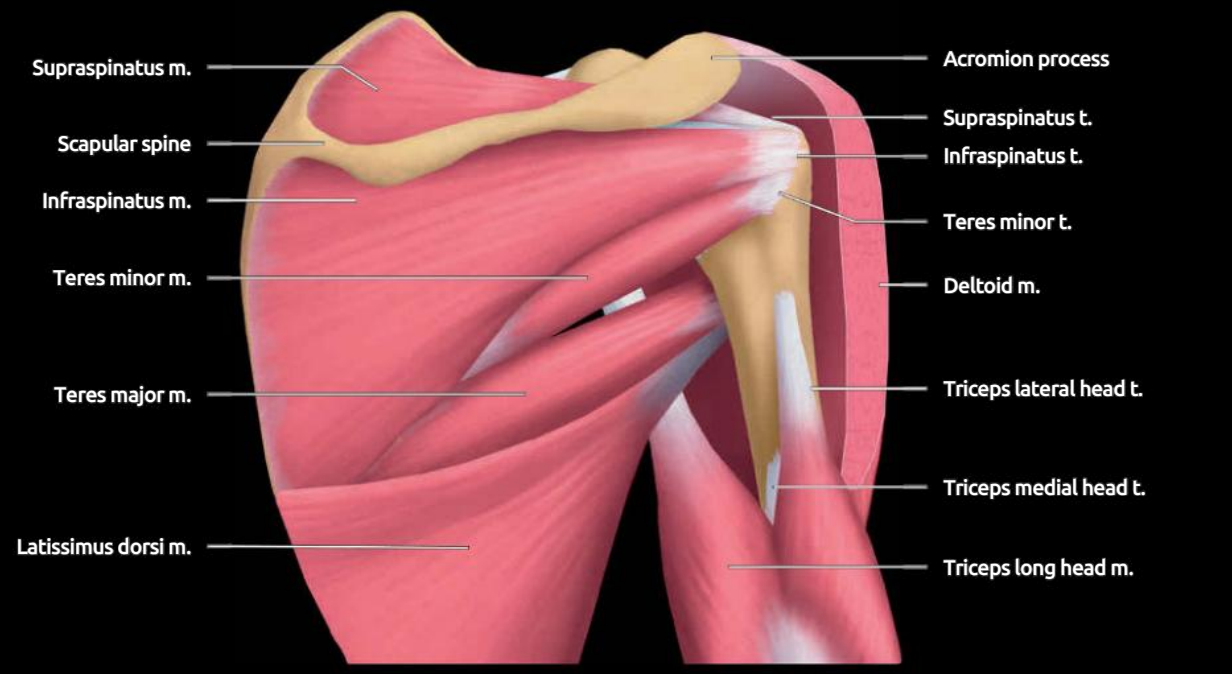

(Top) *Anterior graphic shows the capsular attachments of the shoulder joint as well as the glenohumeral ligaments. The glenohumeral ligaments are condensations of the anterior and inferior aspects of the shoulder capsule.* **(Bottom)** *Graphic illustrates the posterior shoulder muscles. The long head of the triceps arises from the infraglenoid tubercle. The lateral head arises from the posterior aspect of the humeral shaft just proximal to the traversing radial nerve. The medial head arises from the posterior aspect of the humeral shaft just distal to the traversing radial nerve. All 3 triceps muscles insert onto the olecranon process.*

PARASCAPULAR MUSCLES

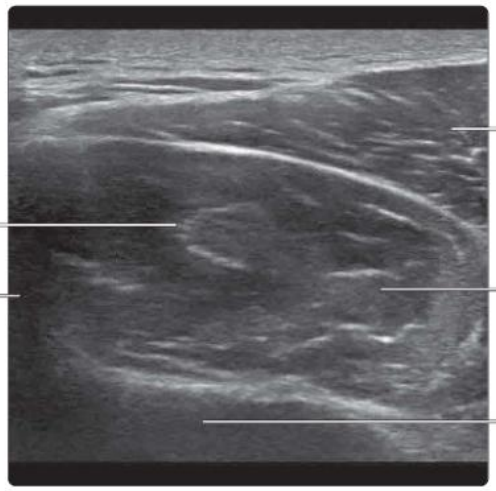

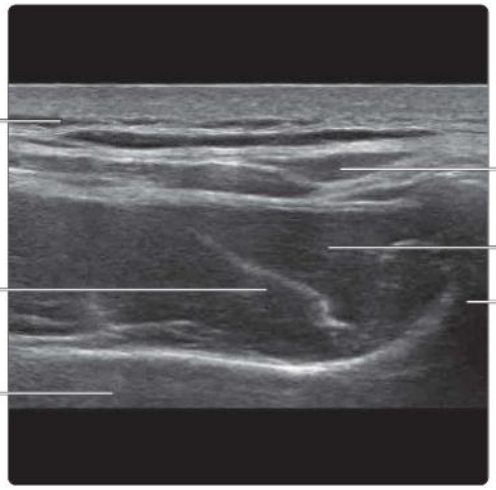

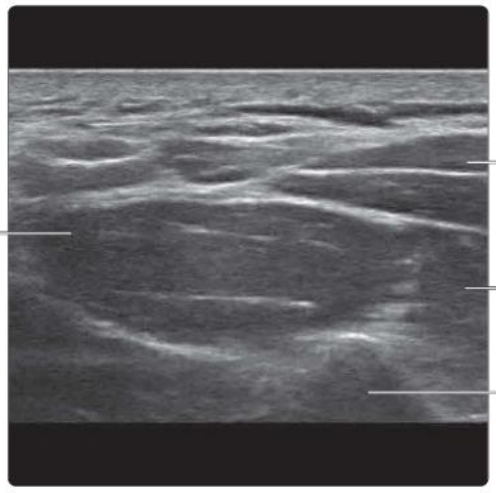

(Top) *Transverse US of the posterior scapular region shows the supraspinatus muscle. Muscle atrophy is common in rotator cuff pathology. US is almost as sensitive as MR in the depiction of muscle atrophy. Atrophy is seen as a reduction in muscle bulk with increase in muscle echogenicity. As a result, the central tendon is less readily seen. Muscle echogenicity can be compared to the overlying trapezius and deltoid muscles, bearing in mind that all muscles will atrophy with age-related sarcopenia.* **(Middle)** *Longitudinal US shows the infraspinatus muscle. Infraspinatus muscle atrophy often accompanies supraspinatus muscle atrophy, though to a lesser degree. Similar to the supraspinatus muscle, muscle bulk is reduced and becomes more echogenic with the central tendon becoming less easy to see. The degree of muscle atrophy is a good indication as to the chronicity and severity of tendon tear.* **(Bottom)** *Longitudinal US shows the teres minor muscle. The teres minor muscle lies inferolateral to the infraspinatus muscle at and beyond the inferolateral border of the scapula. It is the only rotator cuff muscle supplied by the axillary nerve.*

SCAPULAR NOTCHES & POSTERIOR GLENOHUMERAL JOINT

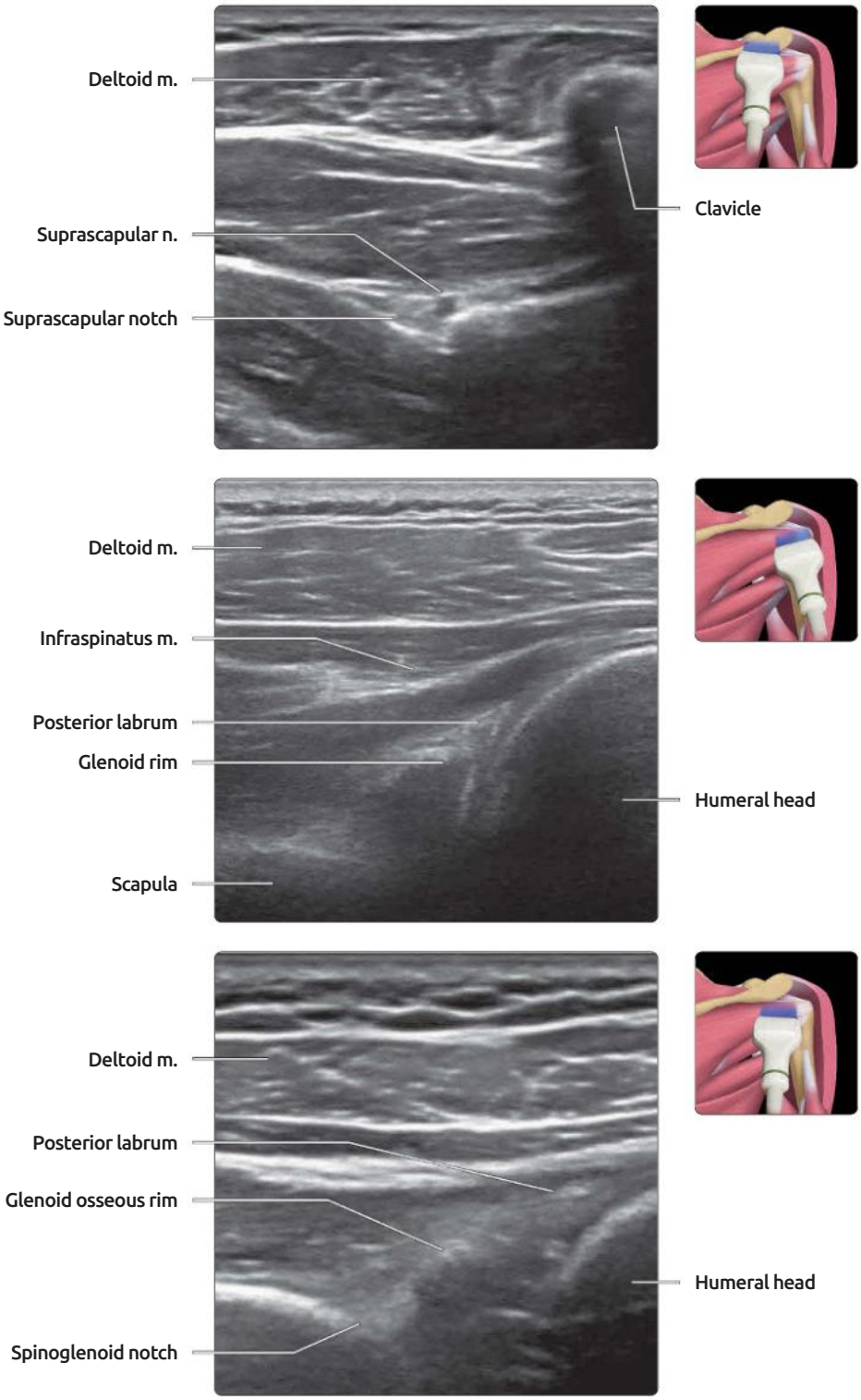

(Top) *Transverse US shows the suprascapular nerve at the suprascapular notch. The suprascapular notch is variable in appearance. It transmits the suprascapular nerve, which supplies the suprascapular muscle before entering the infraspinatus fossa to supply the infraspinatus muscle. It is a much less frequent site of neural compression than the spinoglenoid notch.* **(Middle)** *Transverse US of the posterior aspect of the glenohumeral joint shows the echogenic triangular posterior labrum attached to the glenoid rim. The rounded humeral head and overlying infraspinatus muscle are also shown. These landmarks should be identified during US-guided shoulder joint injection. The needle tip can be positioned deep to the labrum from a lateral to medial approach.* **(Bottom)** *Transverse US close to the previous image focuses on the spinoglenoid notch, which lies just medial to the glenohumeral joint at the medial aspect of the scapular spine. This transmits the suprascapular nerve and accompanying artery. Usually, the nerve is not visible. The nerve can be compressed at this location by paralabral ganglia arising, as a result of labral tear, from the posterior labrum or the superior labrum.*

TERMINOLOGY

Definitions

- Fat-filled space that acts as passageway between neck & arm

IMAGING ANATOMY

Extent

- Pyramid-shaped area composed of apex, base, & 4 walls
  - Apex
    - Between medial 1/3 of clavicle & 1st rib, akin to costoclavicular gap
  - Anterior wall
    - Pectoralis major & minor muscles
  - Posterior wall
    - Latissimus dorsi, subscapularis, & teres minor muscles
  - Lateral wall
    - Small area of bicipital groove of humerus lying between attachments of anterior & posterior axillary wall muscles
  - Medial wall
    - Serratus anterior muscle covering first 4 ribs
  - Base
    - Axillary fascia from lower border of pectoralis major anteriorly to lower border of latissimus dorsi posteriorly
- **Contents**
  - Cords & terminal branches of brachial plexus
  - Axillary artery & vein
    - 10% & 90% of subjects have accessory axillary artery & vein, respectively
  - Lymph nodes & lymphatic vessels
  - Fat, sometimes termed axillary fat pad
- Axillary artery
  - Subclavian artery termed axillary artery beyond lateral edge of 1st rib
  - Axillary artery termed brachial artery beyond lower border of teres major muscle
- Axillary vein
  - Continuation of brachial vein
- **Brachial plexus**
  - Cords & terminal branches pass through axilla
  - Lateral cord gives rise to
    - Median nerve
    - Musculocutaneous nerve: Pierces coracobrachialis to descend arm between biceps & brachialis muscles
    - Lateral pectoral nerve
  - Medial cord gives rise to
    - Ulnar nerve
    - Contributes to median nerve
    - Medial pectoral nerve
    - Medial cutaneous nerves of arm & forearm
  - Posterior cord gives rise to
    - Radial nerve
    - Axillary nerve passes inferior to glenohumeral joint & then incompletely wraps around surgical neck of humerus
      - Then, exits axilla posteriorly through quadrilateral space with posterior circumflex humeral artery
      - Supplies teres minor, deltoid, long head of triceps muscles, & skin of "regimental badge" area, i.e., inferior part of deltoid muscle
    - Subscapular nerve
    - Thoracodorsal nerve
  - Locations of terminal branches around axillary artery are reasonably consistent
    - Median nerve closest to coracobrachialis & biceps muscles
- **Lymph nodes**
  - 20-50 axillary lymph nodes, though most are not visible on US or other imaging
    - Lymph nodes typically follow vessels (axillary, lateral thoracic, & thoracodorsal arteries)
    - Also frequently occur in isolation in axillary fat & toward axillary tail of breast
  - Clustered into 5 groups: Mnemonic "SCALP"
    - **S**ubscapular (posterior) group in front of subscapularis muscle
    - **C**entral group in center of axilla
    - **A**pical group at lateral border of 1st rib
    - **L**ateral group at medial side of axillary vein
    - **P**ectoral (anterior) group along lower border of pectoralis minor muscle
- **Accessory breast tissue**
  - Failed regression of primitive mammary tissue
    - Normal variant & not pathologic
    - May be predominantly granular, fibrous, fibroglandular, or fatty
    - Looks similar to usual breast tissue on US
  - Can occur anywhere along "milk line" (i.e., anterior axilla to medial inguinal region), but axilla is most common site
    - Prevalence is 3%, more common in females, often bilateral
      - Higher prevalence in Japanese people
  - Not functionally connected to main breast duct as opposed to axillary "tail of Spence," which is normal extension of breast tissue to axilla

Anatomy Relationships

- **Quadrilateral space**
  - Posterolateral aspect of shoulder
  - Borders are teres minor superiorly, teres major inferiorly, long head of triceps medially, & surgical neck of humerus laterally
  - Contains axillary nerve & posterior circumflex humeral artery

ANATOMY IMAGING ISSUES

Key Concepts

- Quadrilateral space syndrome due to compression of axillary nerve or posterior humeral circumflex artery in quadrilateral space
  - Trauma, shoulder dislocation, paralabral cyst, muscle hypertrophy, or prolonged arm abduction during sleep
- Poorly localized shoulder pain ± paresthesia radiating to lateral arm
  - Aggravated by abduction & external rotation
  - Teres minor ± deltoid atrophy

AXILLA & BRACHIAL PLEXUS

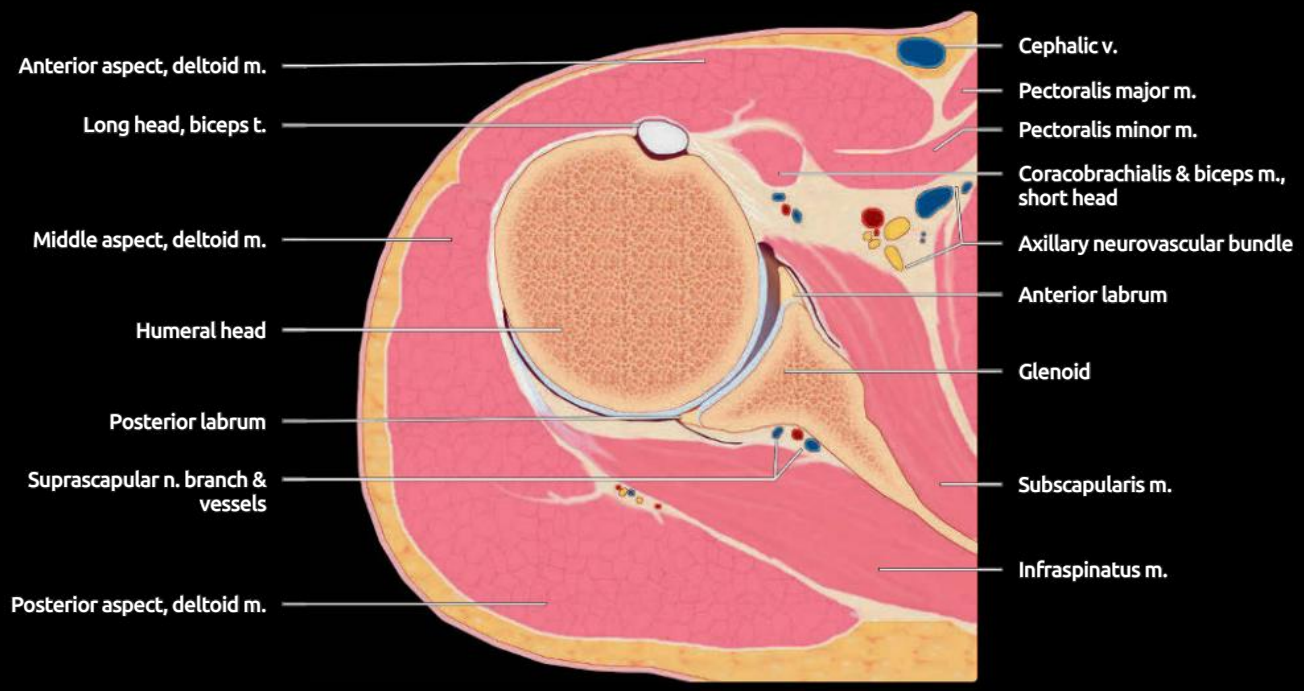

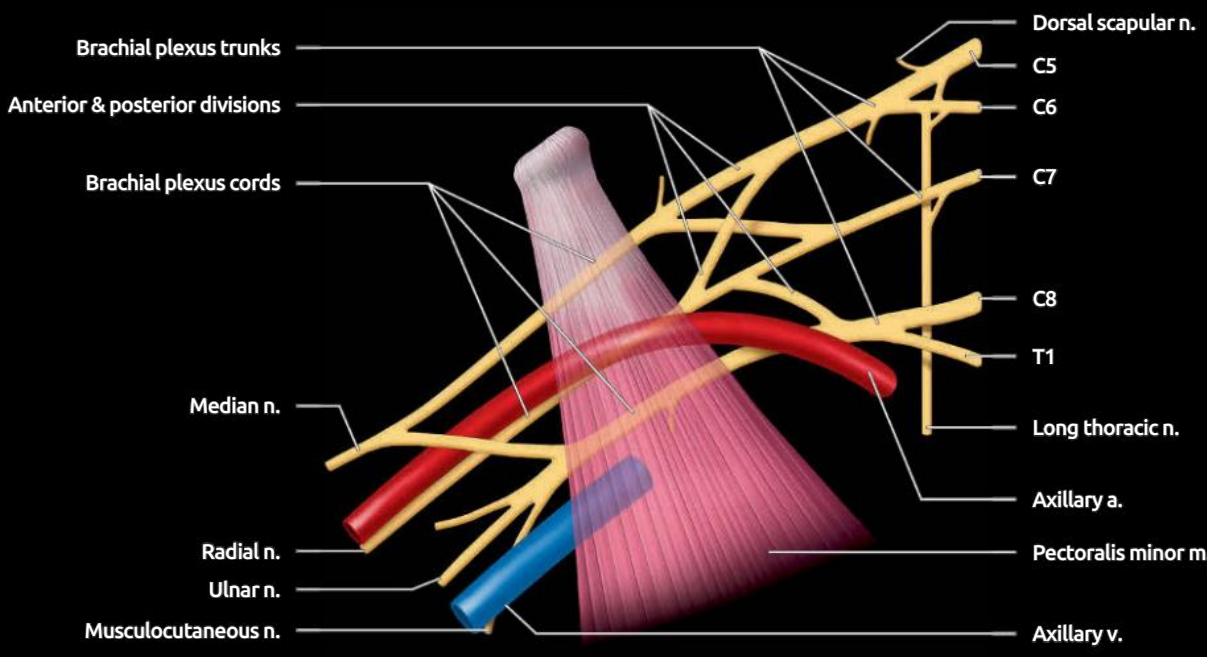

(Top) *Graphic shows the walls & content of the axilla as well as the location of the suprascapular neurovascular bundle, which passes from the suprascapular notch to the spinoglenoid notch.* **(Bottom)** *Graphic shows the neural network of the brachial plexus, which arises from the C5-T1 anterior rami. The rami first unite to form superior, middle, & inferior trunks. The trunks divide into the anterior & posterior divisions before uniting to form the lateral, posterior, & medial cords. The cords divide into 5 terminal branches, which are the axillary, musculocutaneous, radial, medial, & ulnar nerves.*

ARTERIES OF AXILLARY REGION

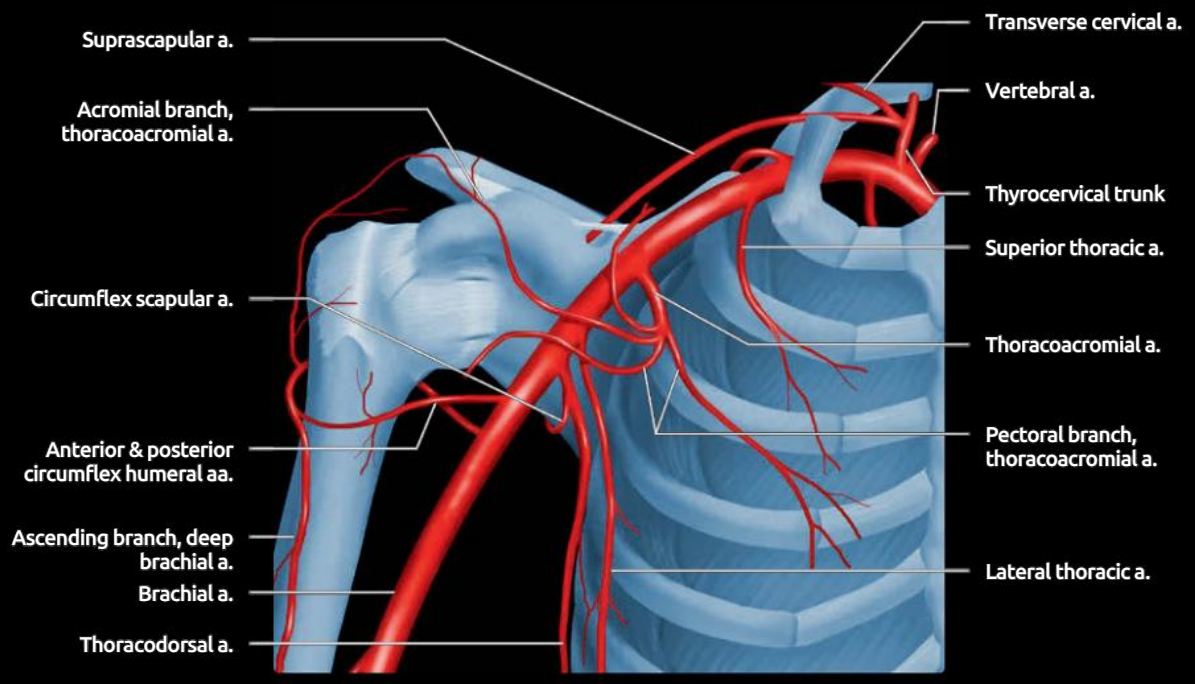

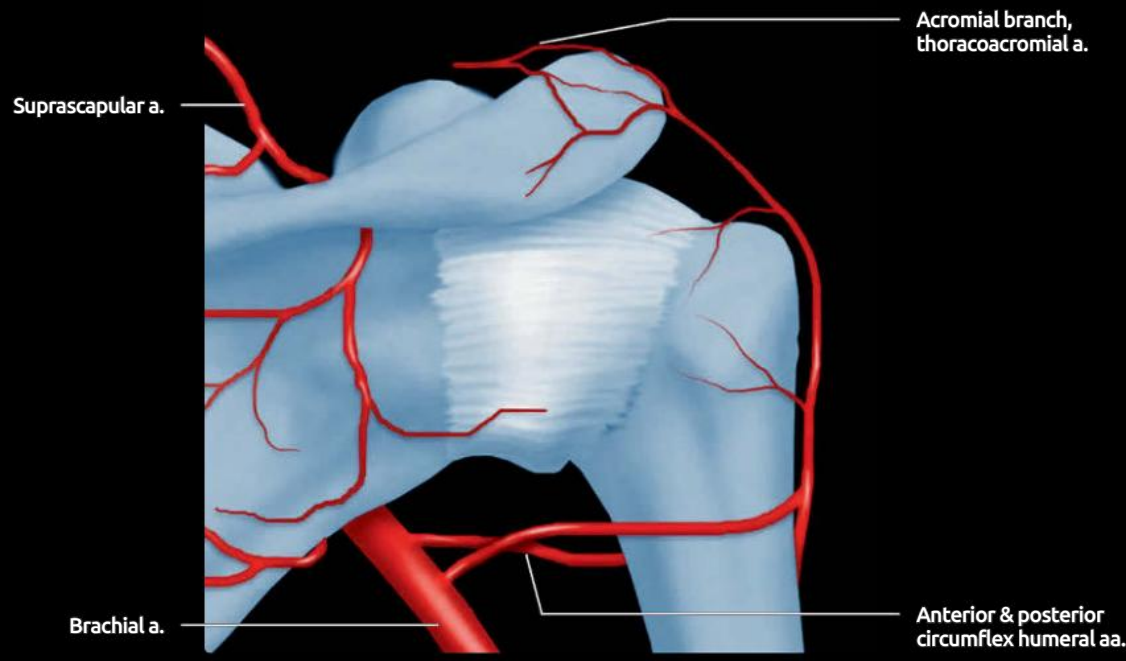

(Top) *Graphic shows how the shoulder & axillary regions are mainly supplied by the anterior & posterior circumflex humeral arteries, the suprascapular artery, & the circumflex scapular arteries.* **(Bottom)** *Graphic shows the extensive arterial collaterals that are present around the shoulder & axillary regions.*

QUADRILATERAL SPACE

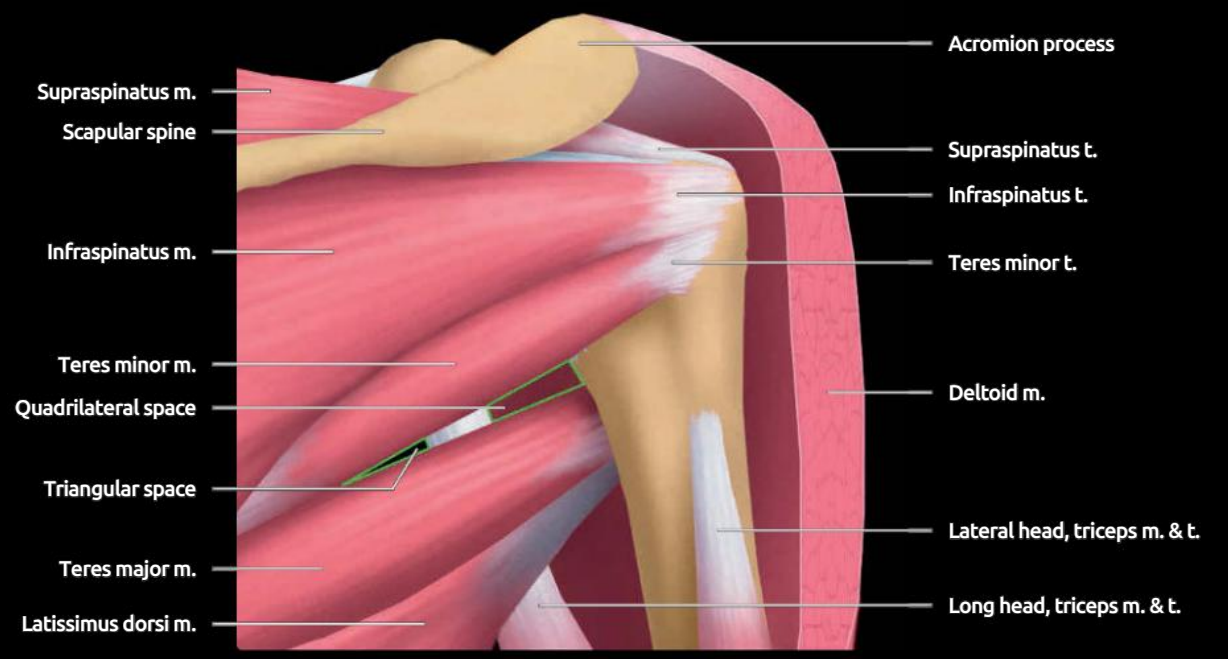

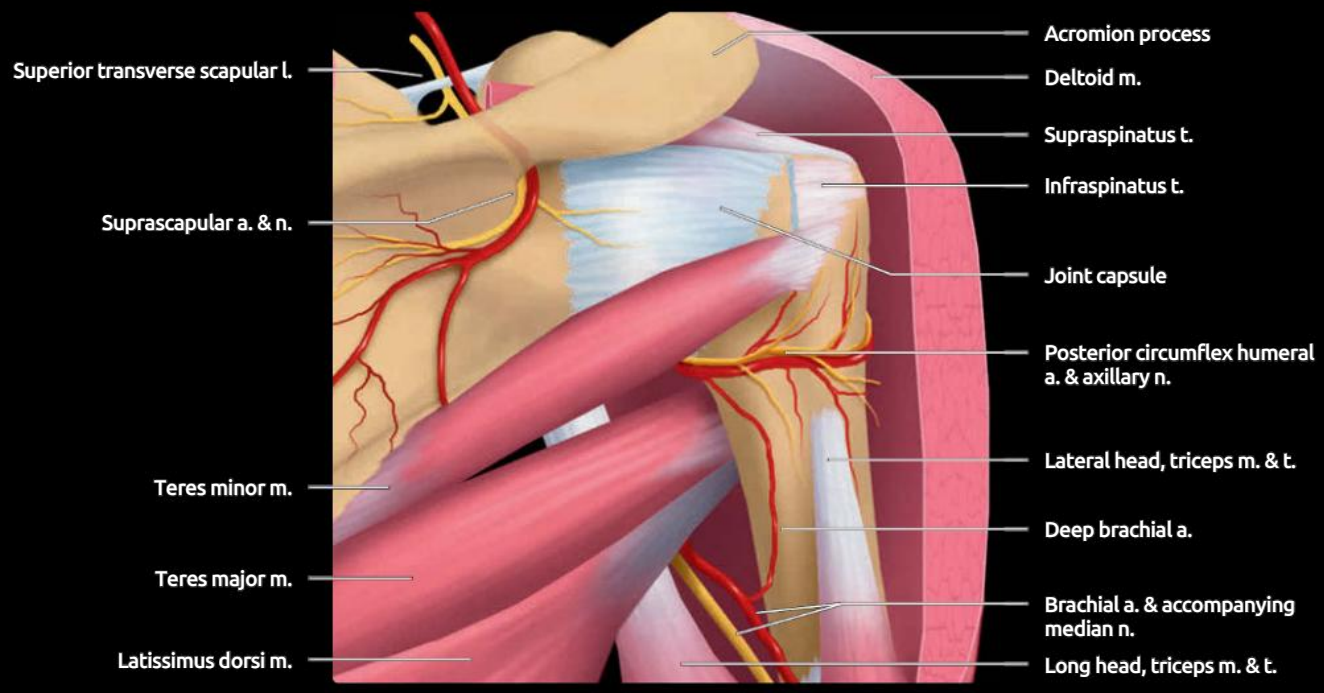

(Top) *Graphic of the posterior shoulder shows the location of the quadrilateral and triangular spaces (each outlined in green). The quadrilateral space transmits the axillary nerve & the posterior circumflex humeral artery, while the less important triangular space transmits the scapular circumflex vessels.* **(Bottom)** *Graphic shows the posterior circumflex humeral artery & axillary nerve emerging through the quadrilateral space.*

AXILLARY NERVES

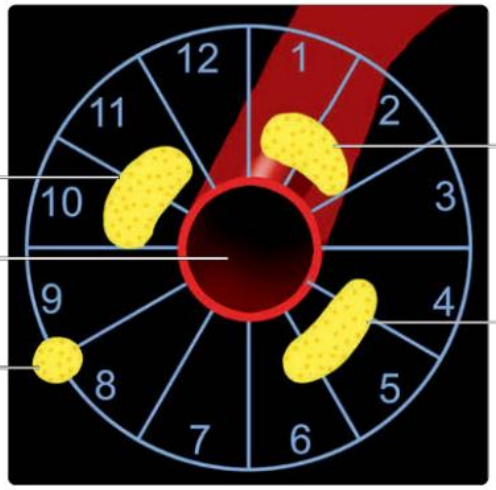

(Top) *Graphic shows the typical arrangement of nerves around the axillary artery on transverse US of the axilla with the arm abducted & externally rotated ("bathing beauty" position). The medial nerve is located superolateral, the ulnar nerve superomedial, & the radial nerve inferomedial to the artery. The musculocutaneous nerve is located inferolateral to the artery between the coracobrachialis & short head of biceps muscles.* **(Middle)** *Transverse US of the axilla shows the typical arrangement of the nerve around the axillary artery. Usually, there is just 1 axillary artery, but there are commonly 2-3 axillary veins. These veins are shown here with minimal transducer pressure. Normally, even mild transducer pressure will efface the axillary veins.* **(Bottom)** *Transverse US in another patient shows a more localized view of the main nerves surrounding the axillary artery. These positions are quite constant.*

QUADRILATERAL SPACE, AXILLARY NERVE, & LYMPH NODE

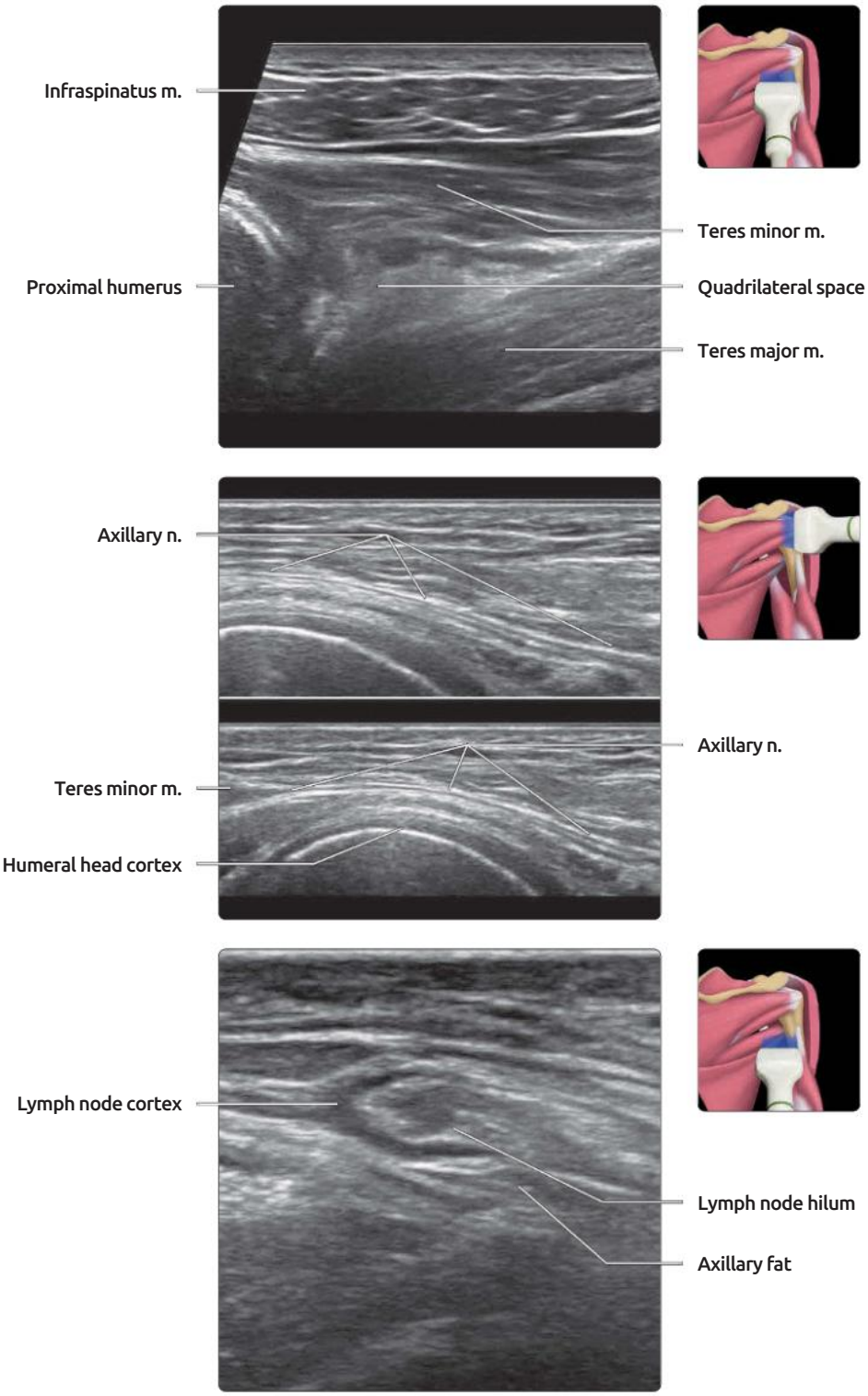

(Top) *Transverse US shows the quadrilateral space on the posterior aspect of the axilla. This space transmits the axillary nerve as well as the circumflex humeral artery & vein.* **(Middle)** *Longitudinal US shows the axillary nerve from the posterior cord of the brachial plexus (not shown) extending from anterior to posterior around the humeral head-neck junction with the arm in a fully extended & externally rotated position ("bathing beauty" position).* **(Bottom)** *Transverse US of the axilla shows a normal axillary lymph node with a thin, hypoechoic cortex & an echogenic hilum containing fat & vasculature. There are up to 50 axillary lymph nodes, but only a few of these are visible on imaging.*

IMAGING ANATOMY

Overview

- Muscles of arm are divided into anterior & posterior compartments

Anatomy Relationships

- **Anterior compartment of arm**
  - Coracobrachialis muscle
    - Origin: Coracoid process tip, in common with & medial to short head biceps tendon
    - Insertion: Medial aspect humeral midshaft, between brachialis & triceps muscle origins
    - Nerve supply: Musculocutaneous nerve, perforates muscle
    - Blood supply: Brachial artery
    - Action: Flexes & adducts shoulder, stabilizes humeral head
  - Biceps muscle, short head
    - Origin: Coracoid process tip, in common with & lateral to coracobrachialis tendon
    - Insertion: Radial tuberosity after joining long head
    - Nerve supply: Musculocutaneous nerve
    - Blood supply: Brachial artery
    - Action: Flexes elbow & shoulder, supinates forearm
  - Biceps muscle, long head
    - Origin: Predominantly supraglenoid tubercle, also superior glenoid labrum & coracoid base
    - Insertion: Radial tuberosity after joining short head
    - Tendon passes through & stabilized at rotator interval
    - Tendon runs along bicipital groove, covered by transverse ligament
    - Transverse ligament spans bicipital groove
      - Composed of deep layer from extension of subscapularis tendon fibers & superficial layer in continuity with supraspinatus tendon & coracohumeral ligament
    - Nerve supply: Musculocutaneous nerve
    - Blood supply: Brachial artery
    - Action: Flexes elbow, supinates forearm
    - Variants: 3rd head from upper medial aspect of brachialis muscle; 4th head from lateral humerus, bicipital groove, or greater tuberosity
  - Brachialis muscle
    - Origin: Distal 1/2 of anterior & lateral aspects of humeral shaft & lateral intermuscular septum
    - Insertion: Tuberosity of ulna & anterior surface of coronoid process
    - Nerve supply: Musculocutaneous nerve plus branch of radial nerve
    - Blood supply: Brachial artery & recurrent radial artery
    - Action: Flexes forearm
    - Covers anterior aspect of elbow joint
- **Posterior compartment of arm**
  - Triceps muscle, long head
    - Origin: Infraglenoid tubercle of scapula
    - Insertion: Proximal olecranon & deep fascia of arm after joining with lateral & medial heads
    - Nerve supply: Radial nerve
    - Blood supply: Brachial artery
    - Action: Elbow extension, adducts humerus when arm is extended
  - Triceps muscle, lateral head
    - Origin: Posterior & lateral aspects of humeral shaft, lateral intermuscular septum
    - Insertion: Proximal olecranon & deep fascia of arm after joining with long & medial heads
    - Nerve supply: Radial nerve
    - Blood supply: Brachial artery
    - Action: Elbow extension
  - Triceps muscle, medial head
    - Origin: Posterior humeral shaft from teres major insertion to near trochlea, medial intermuscular septum
    - Insertion: Proximal olecranon process, medial aspect of olecranon process & deep fascia of arm after joining with lateral & long heads
    - Nerve supply: Radial & branches of ulnar nerve
    - Blood supply: Brachial artery
    - Action: Elbow extension
  - Anconeus muscle
    - Origin: Posterior aspect lateral epicondyle of humerus
    - Insertion: Lateral aspect olecranon & posterior 1/4 of ulnar shaft
    - Nerve supply: Radial nerve
    - Blood supply: Brachial artery
    - Action: Assists elbow extension, abducts ulna
- **Fascia**
  - Brachial fascia (deep fascia of arm)
    - Continuous with fascia covering deltoid & pectoralis major
    - Varies in thickness: Thin over biceps & thick over triceps muscles
    - Continuous with lateral & medial intermuscular septa
    - Lateral intermuscular septum from lower aspect of greater tuberosity to lateral epicondyle
      - Perforated by radial nerve & deep branches brachial artery
    - Medial intermuscular septum from lower aspect of lesser tuberosity to medial epicondyle
      - Perforated by ulnar nerve & ulnar collateral arteries
    - Provides traction on deep fascia of forearm
  - Bicipital aponeurosis (lacertus fibrosus)
    - Arises from medial side of distal biceps tendon at level of elbow joint
    - Passes medially superficial to brachial artery & median nerve
    - Continuous with myofascia covering flexor-pronator muscle group

ANATOMY IMAGING ISSUES

Imaging Recommendations

- Examine with arm extended in supine & prone positions
- Transverse plane most helpful to delineate muscle borders & neurovascular structures

Imaging Pitfalls

- Muscle may appear echogenic, simulating fatty replacement or edema when beam not aligned parallel to muscle fibers

CORONAL AND AXIAL ARM

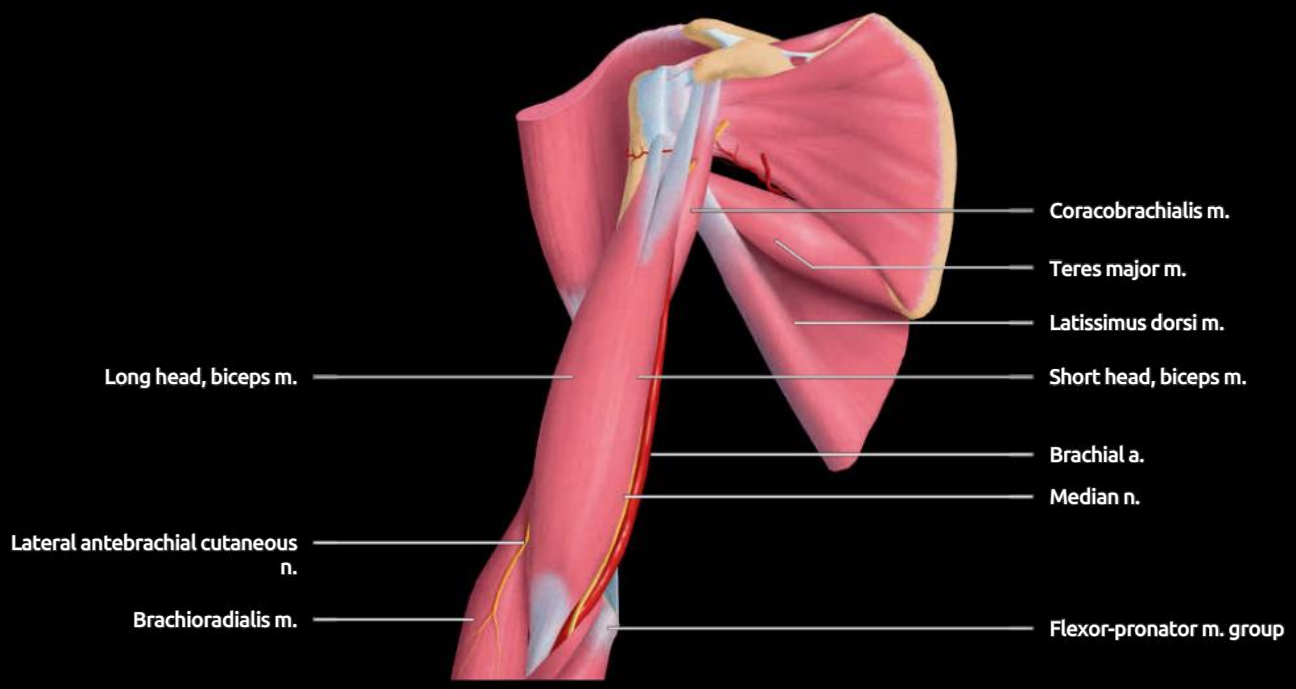

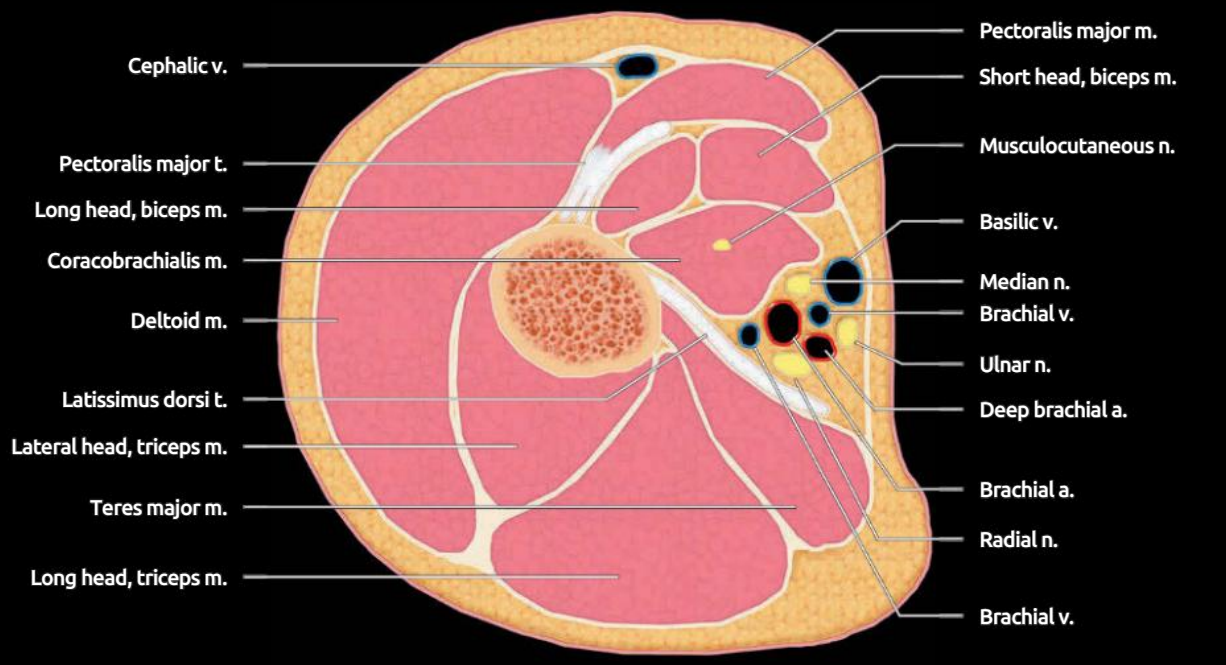

(Top) *Graphic of the anterior arm muscles shows the short head of the biceps and coracobrachialis arising from the coracoid process tip. The long head arises from the biceps labral complex at the supraglenoid tubercle and passes through the rotator interval and bicipital groove.* **(Bottom)** *Graphic shows cross-sectional anatomy of the proximal arm. The coracobrachialis muscle lies deep to the biceps muscle. Posteriorly, only the lateral head and long heads of triceps muscle are present at this level. All of the neurovascular bundles are positioned on the medial side of the upper arm. Paired brachial (and axillary) veins are common.*

AXIAL ARM

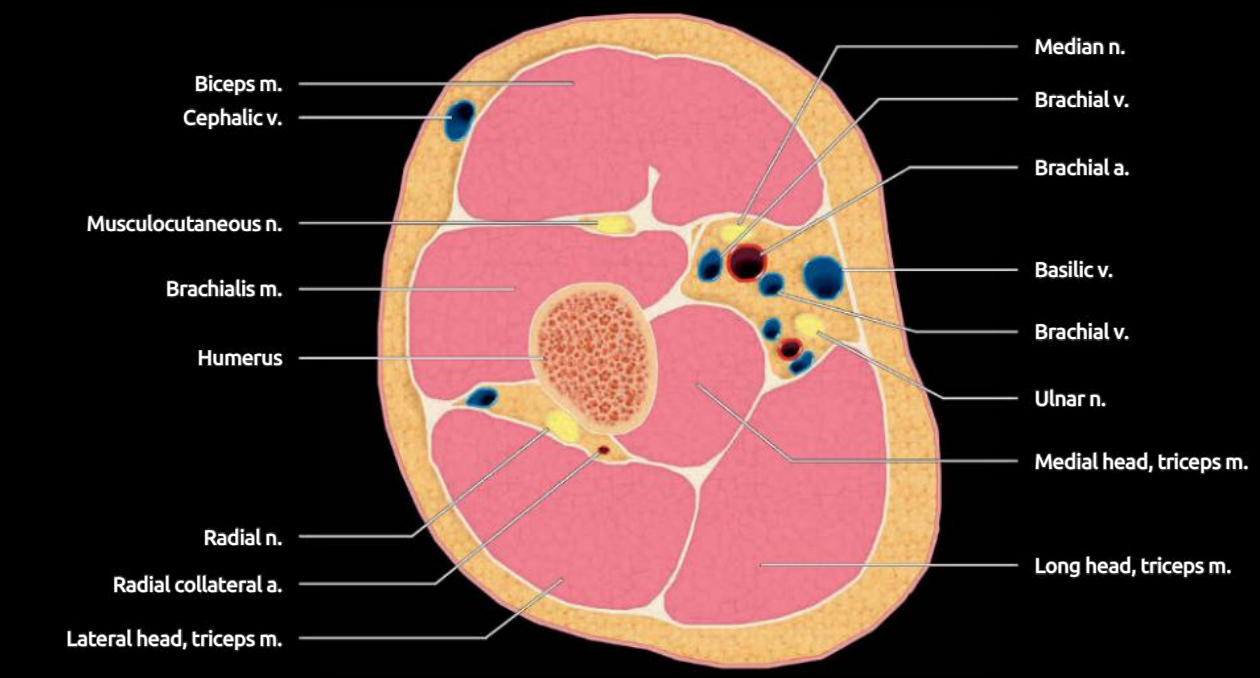

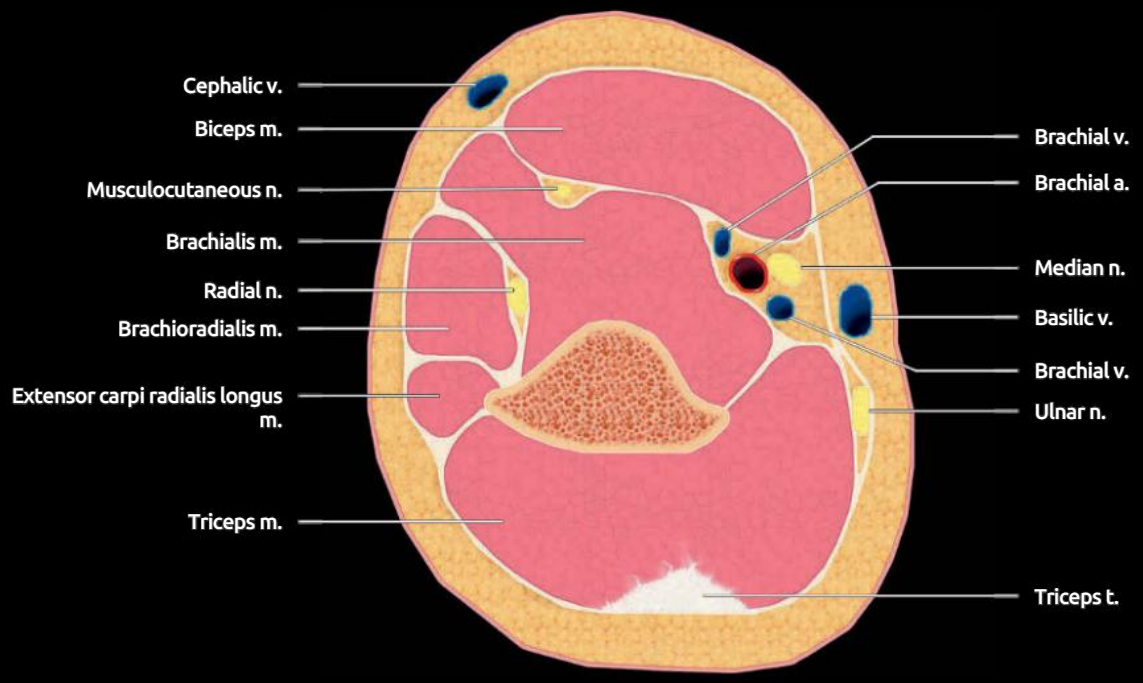

(Top) *Graphic shows cross-sectional anatomy of the midarm. The medial head of triceps is apparent at this level as it arises from the humeral shaft distal to the "spiral groove".* **(Bottom)** *Graphic shows cross-sectional anatomy of the distal arm. The triceps tendon is a bilayered structure with a tendinous superficial component from the long and lateral heads and a deep muscular component from the medial head.*

TRANSVERSE US, ANTEROMEDIAL ASPECT

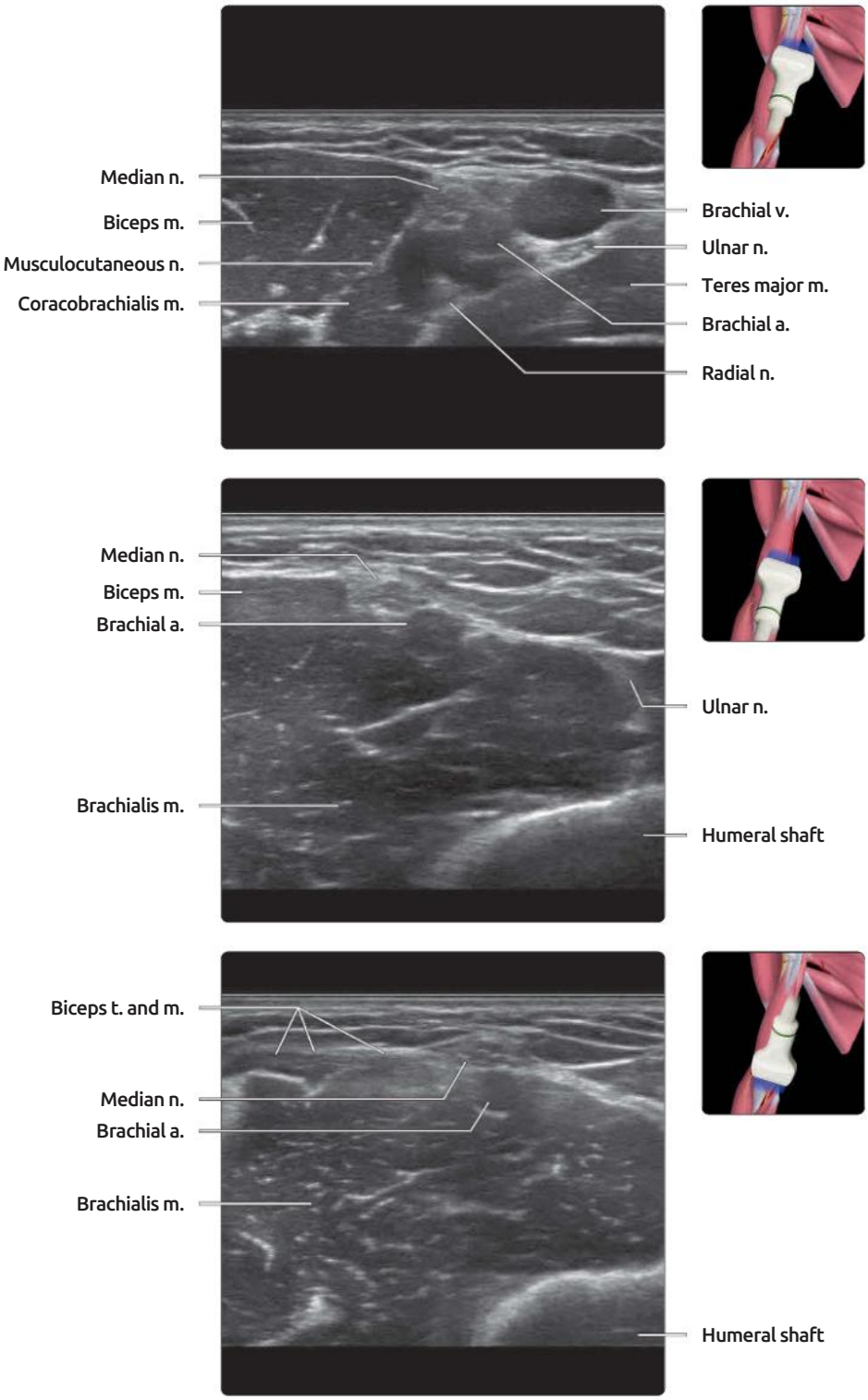

(Top) *Transverse US shows the anteromedial aspect of the proximal arm. The terminal branches (median nerve, ulnar nerve, and radial nerve) of the brachial plexus surround the brachial artery and vein. As they descend the arm, they move away from the classic positioning seen in the axilla. If necessary, neural identity can be confirmed by identifying the various nerves in their typical "target areas" in the distal arm and tracing the relevant nerve proximally in a transverse plane.* **(Middle)** *Transverse US shows the anteromedial aspect of the midarm. The median nerve-brachial artery neurovascular bundle helps demarcate the anterior and posterior compartments of the arm medially.* **(Bottom)** *Transverse US shows the anteromedial aspect of the distal arm where the median nerve alone is closely associated with the brachial neurovascular bundle. Most of the muscle bulk of the distal arm anteriorly is provided by the brachialis muscle.*

TRANSVERSE US, ANTERIOR ASPECT

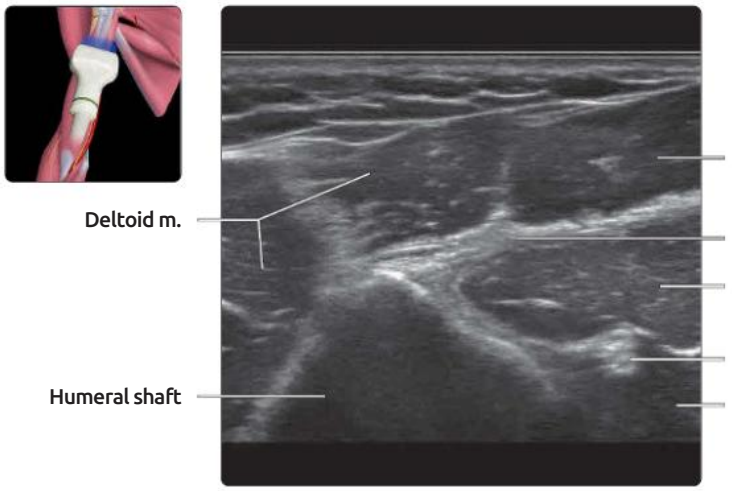

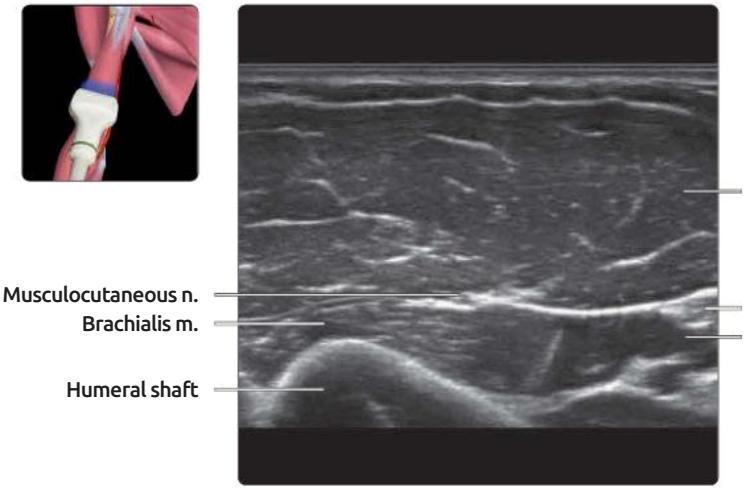

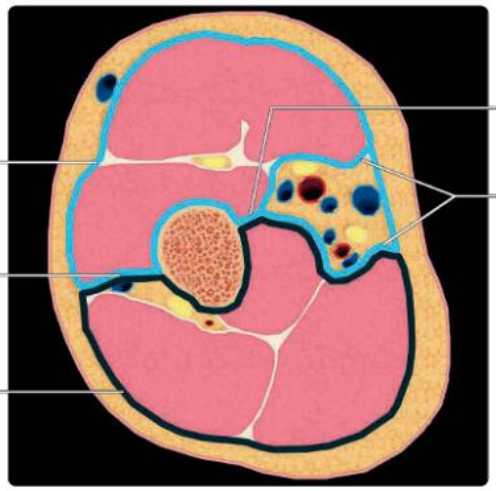

(Top) *Transverse US shows the proximal arm. The 3 muscles of the anterior compartment of the arm are the biceps, brachialis, and coracobrachialis muscles. The biceps muscle is midline, the brachialis muscle is midline and lateral, and the coracobrachialis muscle is midline and medial.* **(Middle)** *Transverse US shows the middle 1/3 of the anterior arm. Compared to the proximal arm, the short and long heads of biceps brachii in the midarm are not clearly delineated. The short head lies more anteriorly and medially, the long head more deeply and laterally. The musculocutaneous nerve supplies all 3 anterior arm compartment muscles and also provides cutaneous innervation for the lateral forearm via the lateral (antebrachial) cutaneous nerve.* **(Bottom)** *Graphic shows compartmental anatomy of the arm, which has anterior (blue outline) and posterior (black outline) compartments separated by the lateral and medial intermuscular septa. The thicker medial intermuscular septum divides into anterior and posterior layers to form a 3rd compartment, the neurovascular compartment, which lies between the anterior and posterior compartments medially.*

TRANSVERSE US, POSTEROLATERAL ASPECT

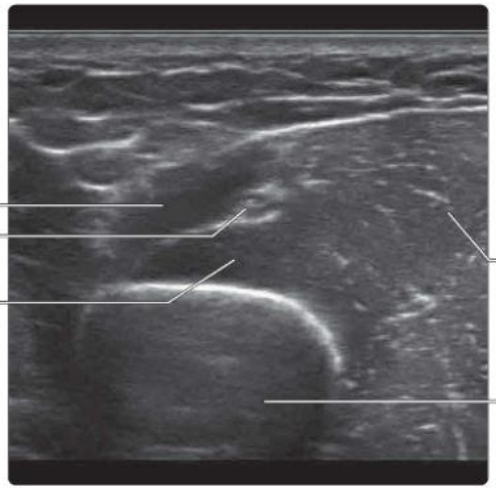

(Top) *Transverse US shows the anterolateral aspect of the midarm. After leaving the axilla, the radial nerve descends and winds around the posterolateral aspect of the humeral shaft, passing in the "spiral groove" between the long and the lateral heads of the triceps accompanied by the deep brachial artery and vein. There is no actual groove present, but, by proximity, the radial nerve is vulnerable at this location to injury in humeral shaft fractures.* **(Middle)** *Transverse US of the lateral aspect of the mid-to-distal arm shows the radial nerve positioned between the proximal end of the brachioradialis muscle and the medial head of the triceps muscle arising from the posterior aspect of the more distal humeral shaft.* **(Bottom)** *Transverse US of the lateral aspect of the distal arm shows where the radial nerve pierces the lateral intermuscular septum to enter the anterior compartment of the arm running initially deep to the brachioradialis and then between the brachioradialis and brachialis muscles.*

POSTERIOR ARM

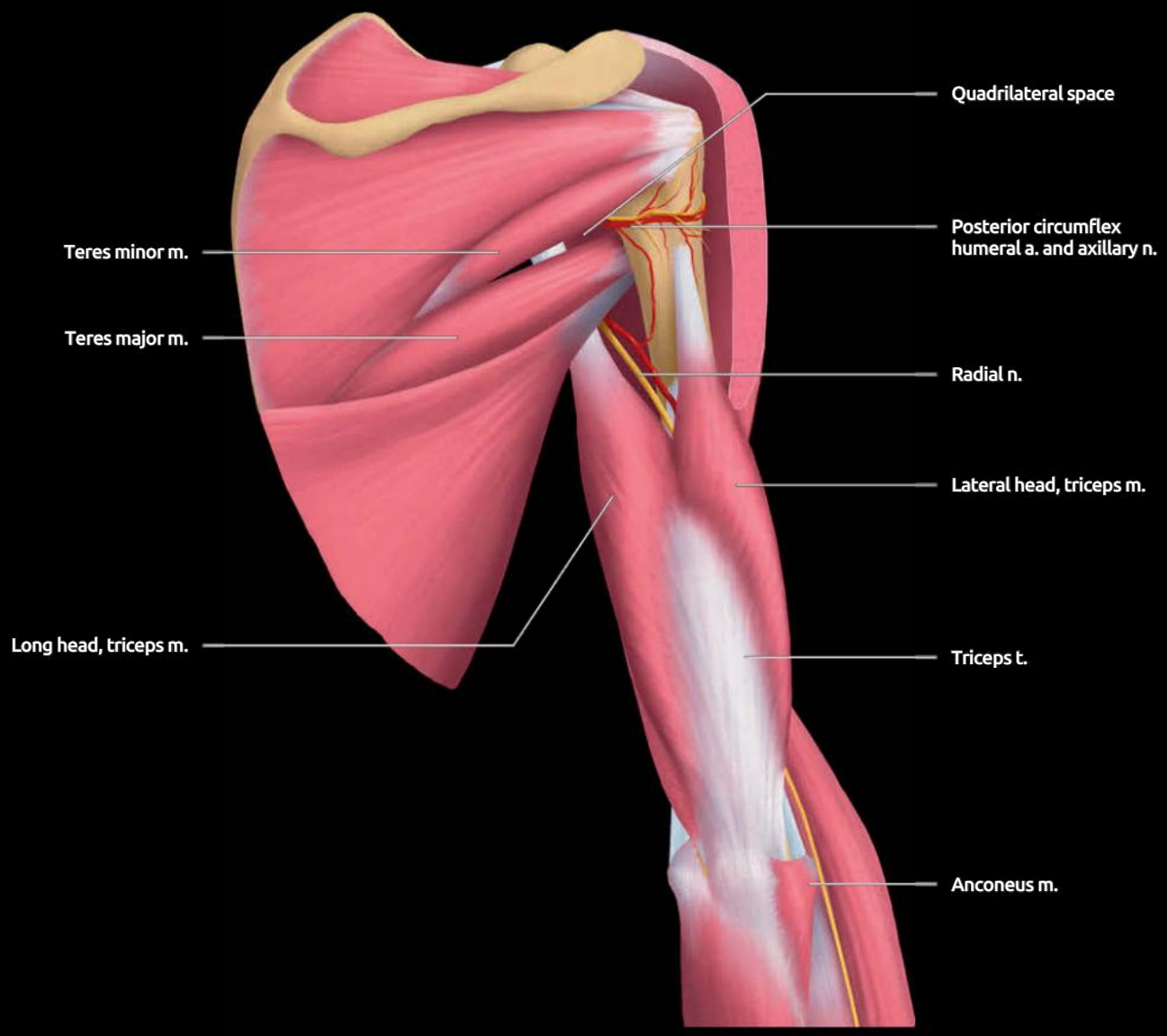

Graphic shows the muscles of the posterior arm. The quadrilateral space is an anatomic space bounded by the long head of triceps, teres minor muscle, teres major muscle, and humeral shaft. The 3 heads of triceps have a bilayered insertion into the olecranon with the medial head having a muscular insertion deep to the conjoint tendinous insertion of the lateral and long heads, which lie superficially.

TRANSVERSE AND LONGITUDINAL US, POSTERIOR ASPECT

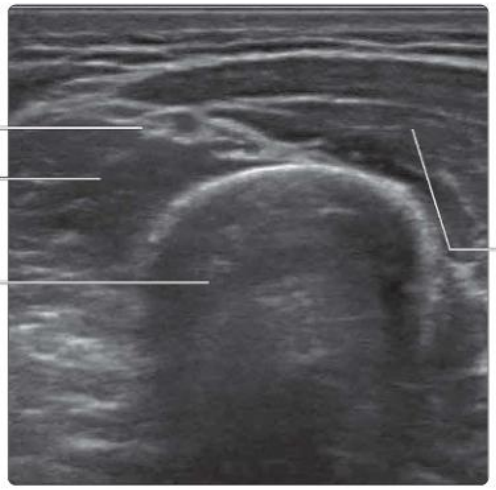

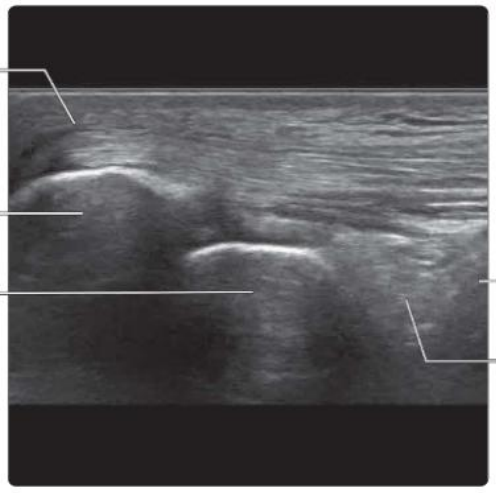

(Top) *Transverse US shows the posterior upper arm. The long head of triceps muscle is the main muscle of the posterior upper arm, and the radial nerve lies deep to this as it emerges from the axilla. As the radial passes over the posterior aspect of the humeral shaft from medial to lateral, it is mainly covered by the lateral belly of triceps muscle. The radial nerve has a slightly flattened appearance at the radial groove on the posterior aspect of the humeral shaft.* **(Middle)** *Transverse US shows the posterolateral midarm. The radial nerve is passing though the lateral intermuscular septum between the posterior and anterior compartments of the arm.* **(Bottom)** *Longitudinal US of the posterior aspect of the distal arm shows the triceps tendon inserting into the olecranon process. The layered appearance of the triceps tendon is not clearly visible on US examination. With a joint effusion, fluid often accumulates in the olecranon fossa displacing the posterior fat pad superficially.*

GROSS ANATOMY

Joint Capsule Attachments

- Anterior
  - Proximally attaches to humerus proximal to coronoid & radial fossae; distally attaches to coronoid process & annular ligament
- Posterior
  - Proximally attaches to humerus proximal to olecranon fossa & capitellum; distally attaches to proximal ulna
- Anterior & posterior elbow fat pads are intracapsular but extrasynovial
- Elbow is strengthened by collateral ligaments
- Main synovial recesses
  - Olecranon recesses
    - Largest; superior, medial, & lateral around olecranon process
  - Anterior humeral recess
    - Proximal to coronoid fossa

Ligaments

- **Ulnar collateral ligament**
  - Extends from distal aspect of medial epicondyle → coronoid & olecranon portions of ulna
    - Separated from overlying common flexor tendon by thin layer of fat
  - 3 bands: Anterior, posterior, & transverse
    - Anterior band: Most important; cord-like, 4-6 mm thick, taut in extension, extends from anterior aspect medial epicondyle → sublime tubercle of coronoid tubercle
    - Posterior band: Less important; fan-like & thinner, taut in flexion, extends from medial epicondyle → olecranon along base of cubital tunnel
    - Transverse band: Functionally unimportant; forms base of triangle between anterior & posterior bands
- **Radial collateral ligament**
  - Triangular in shape
  - Apex on lateral epicondyle → merges distally with annular ligament
    - Lies deep to common extensor tendons
    - Partially provides origin for supinator muscle
- **Annular ligament**
  - Attached to anterior & posterior aspects of radial notch of ulna forming collar around radial head
    - Anterior attachment taut in supination
    - Posterior attachment taut in extreme pronation
    - Partially provides origin for supinator muscle

Tendons

- **Triceps tendon**
  - 3 heads combine to insert onto olecranon process
  - Medial fibers insert on medial side of olecranon
  - Lateral fibers may fan out as lateral cubital retinaculum to connect with ulna & antebrachial fascia
- **Biceps tendon**
  - Flat tendon forms ~ 7 cm proximal to elbow joint
  - Twists 90° as it passes deeply so that anterior surface faces laterally
    - Long head lies deep to short head
    - Expands close to attachment into radial tuberosity; attachment area is ~ 3 cm²
    - Long head inserts onto apex of tuberosity, short head inserts more distally
  - Short & long heads have separate adjoined attachments
  - Bicipital aponeurosis
    - Arises from medial aspect distal biceps myotendinous junction
    - Merges with epimysium of flexor-pronator muscle mass
    - Reinforces biceps action, reduces stress concentration on biceps enthesis & limits retraction of torn distal biceps tendon
- **Common extensor tendon origin (CETO)**
  - Arises from lateral aspect lateral epicondyle
  - Superficial to radial collateral ligament
  - Composed of extensor-supinator group
    - Extensor carpi radialis brevis, extensor carpi radialis longus, extensor digiti minimi, extensor digitorum communis
    - Normal thickness at 1 cm distal to tip of lateral epicondyle is 4.5 ± 0.8 mm, > males, > dominant limb
    - Osteophytic spurs proximal aspect of asymptomatic CETO in 25% < 25 years & 75% > 75 years
    - 10% of asymptomatic CETO have intrinsic hyperemia
- **Common flexor tendon origin (CFTO)**
  - Arises from anterior aspect medial epicondyle
  - Superficial to ulnar collateral ligament
  - Composed of flexor-pronator group
    - Flexor carpi radialis, flexor carpi ulnaris, flexor digitorum superficialis, pronator teres, palmaris longus

Bursae

- **Subcutaneous olecranon bursa**
  - Between skin & olecranon process
- **Bicipitoradial bursa**
  - Between biceps tendon & radial tuberosity
- **Subtendinous olecranon bursa**
  - Between triceps tendon & olecranon process
- **Radioulnar bursa**
  - Between extensor digitorum & radiohumeral joint

ANATOMY IMAGING ISSUES

Imaging Recommendations

- Examine anterior aspect of elbow completely flat & supinated
- Dynamic evaluation particularly useful for many elbow entities
- Examination usually tailored to site of symptoms
- Lateral elbow best examined with elbow fully or slightly flexed
- Medial elbow best examined with elbow extended
- Distal biceps tendon best seen from medial approach
- Biceps insertional area also well seen from posterior part of elbow with forearm fully pronated & elbow flexed & transducer aligned transversely over radial tuberosity
- Effusion will displace fat pads away from bone

CORONAL ELBOW

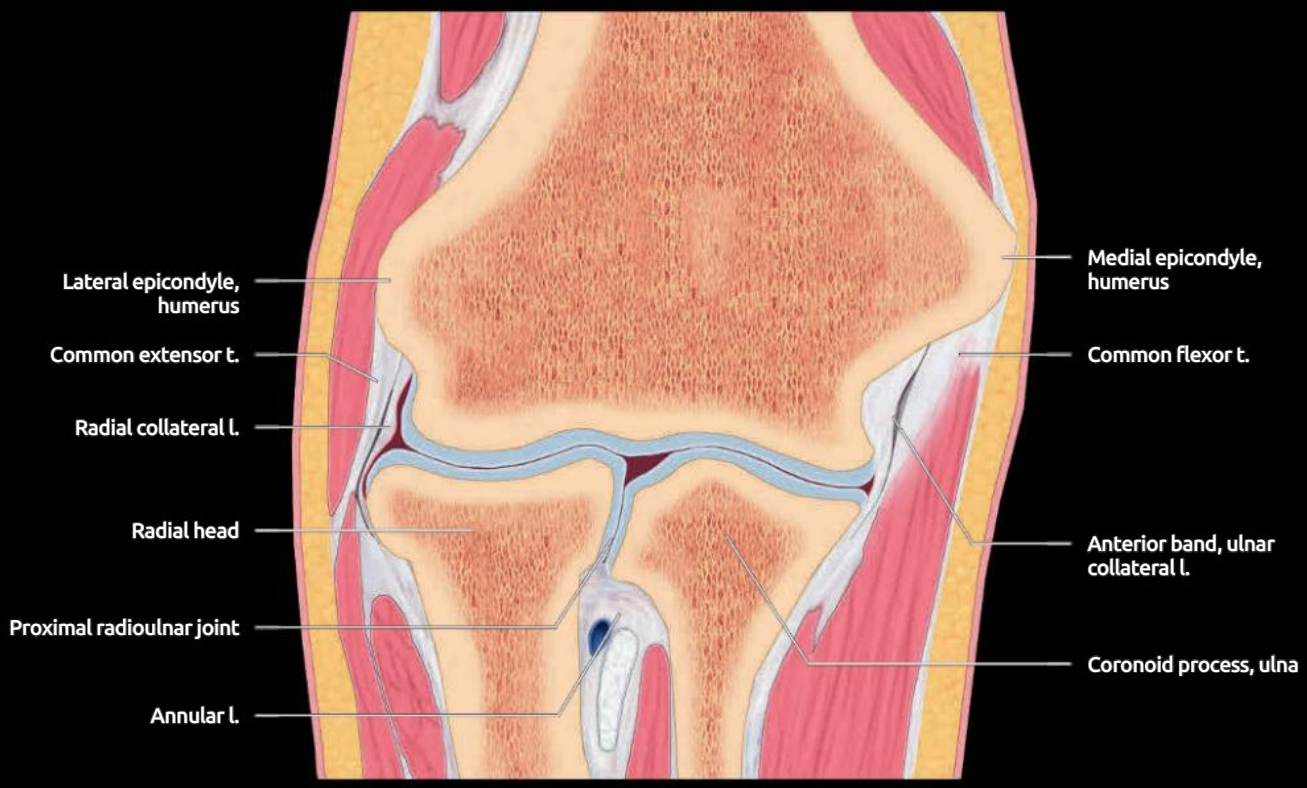

Coronal graphic through the epicondyles shows the collateral ligaments deep to the common tendon groups. Although the radial collateral ligament is shown, this section is too anterior to show most of the ulnar collateral ligament, which originates slightly posterior to the radial collateral ligament.

PROXIMAL ELBOW CROSS SECTION

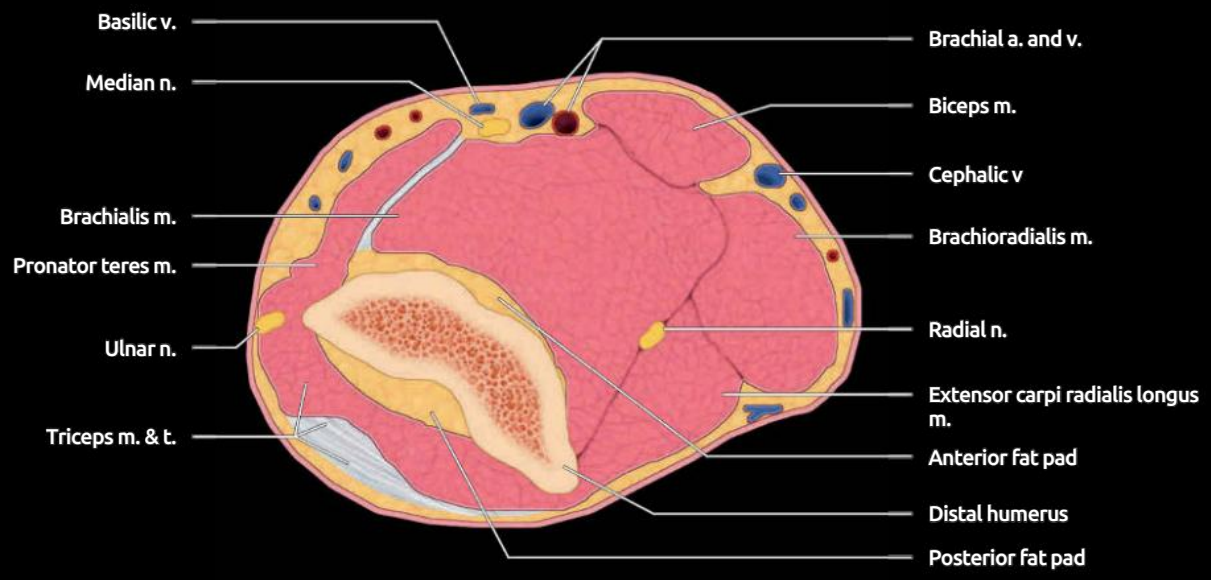

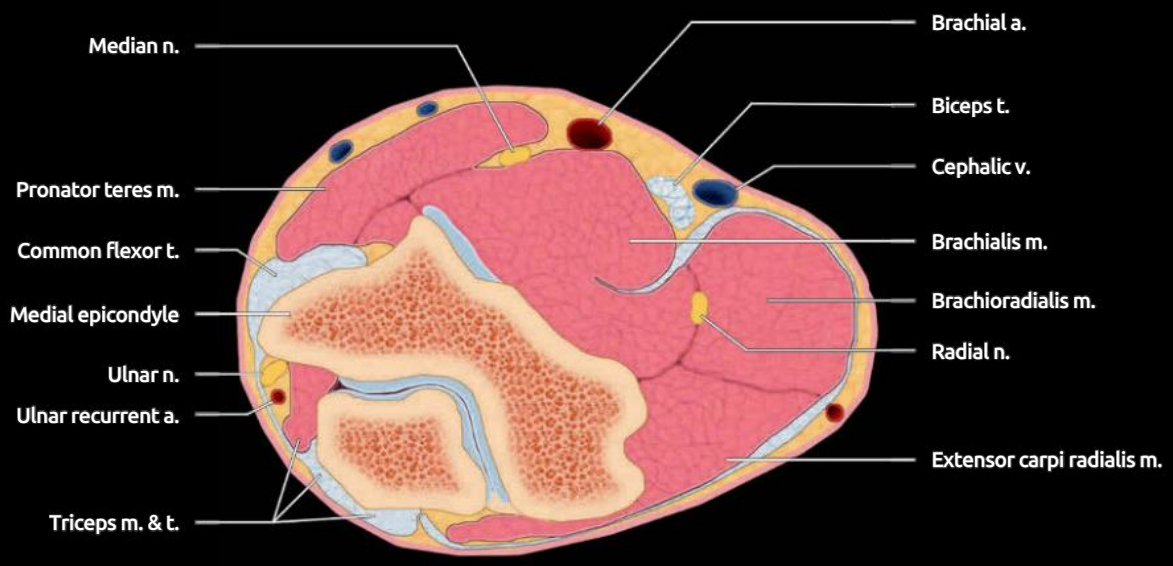

(Top) *Axial graphic shows the supracondylar region of humerus. The anterior & posterior fat pads are seen in the coronoid & olecranon fossae, respectively. The brachialis muscle accounts for most of the bulk of the anterior compartment of the distal arm.* **(Bottom)** *Axial graphic shows the epicondylar region of the distal humerus. The triceps muscle thins as its tendon attaches to the olecranon. The ulnar nerve & posterior ulnar recurrent artery are within the cubital tunnel covered by the cubital retinaculum, formed by the ligament of Osborne proximally & the fascia of flexor carpi ulnaris tendon (i.e., the arcuate ligament) distally.*

MID-ELBOW CROSS SECTION

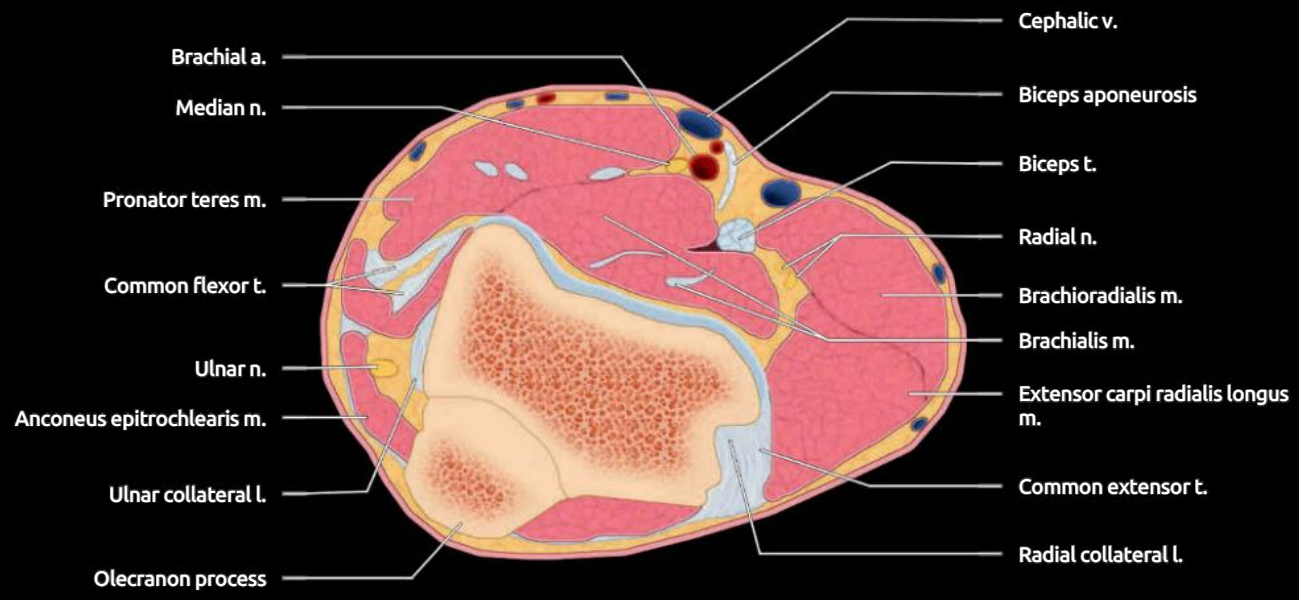

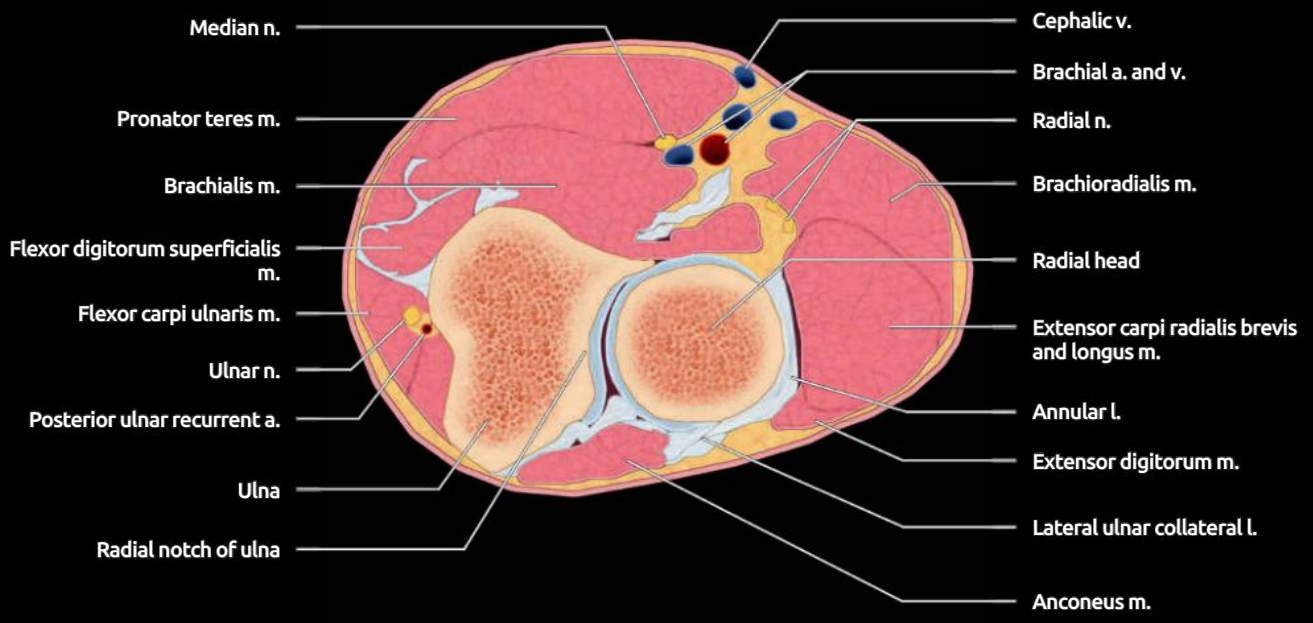

(Top) *Axial graphic immediately proximal to the elbow joint shows the difficulty in distinguishing the radial collateral ligament from the overlying common extensor tendon origin. The ulnar nerve has exited the cubital tunnel & lies deep to the flexor carpi ulnaris muscle.* **(Bottom)** *Axial graphic at the level of the proximal radioulnar joint is shown. The articulating surfaces of the proximal radioulnar joint are well seen with the radial head being held in the radial notch of the ulna by the annular ligament. The lateral ulnar collateral ligament (LUCL) blends with the posterior aspect of the annular ligament.*

DISTAL ELBOW CROSS SECTION

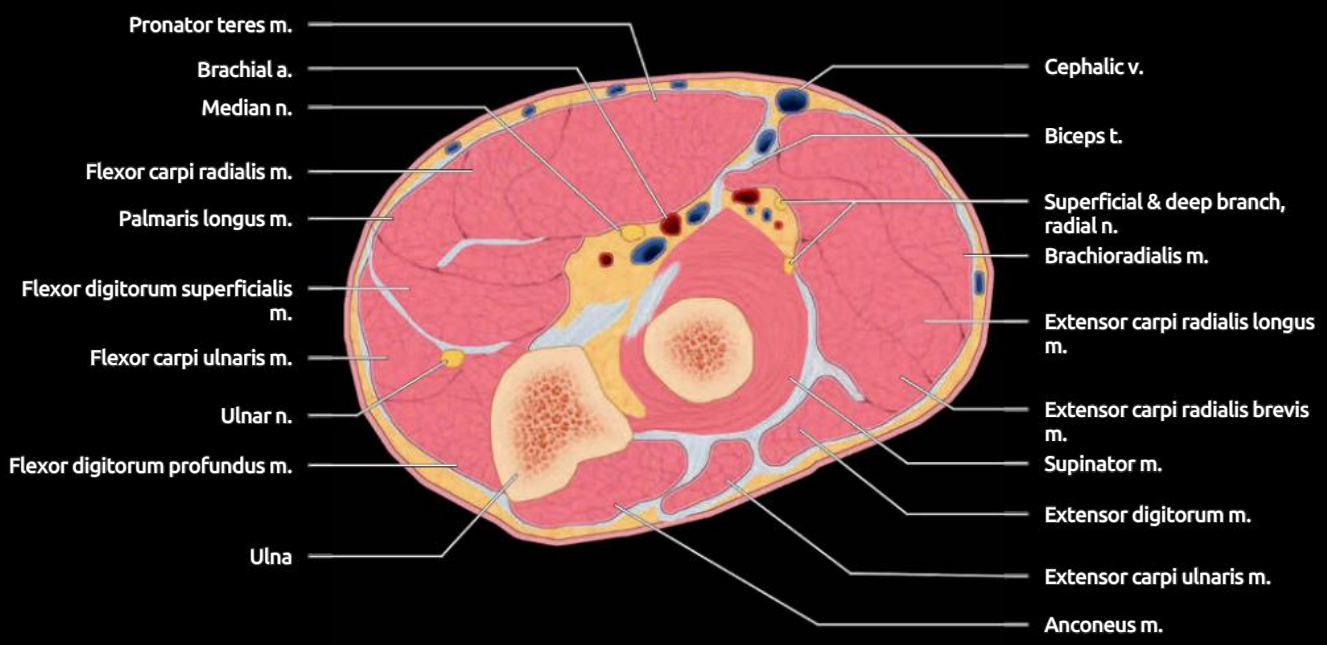

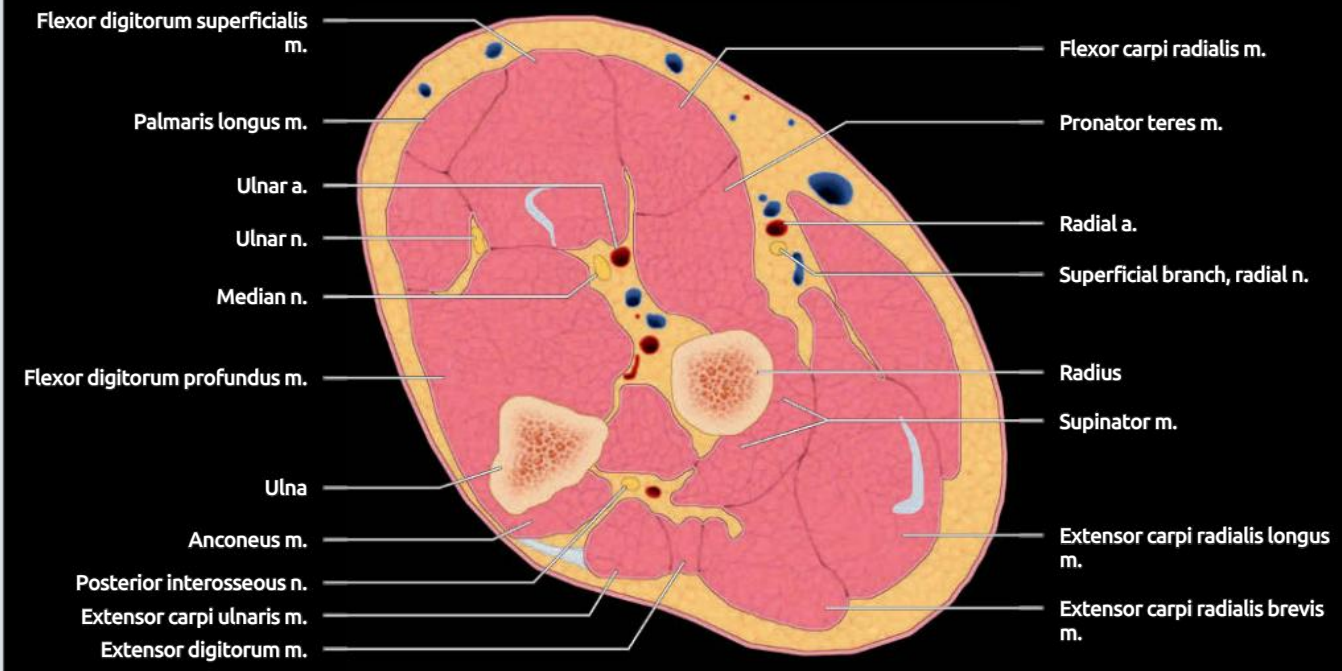

(Top) *Axial graphic shows the elbow immediately proximal to the radial tuberosity. The brachialis tendon inserts on the coronoid process of the ulna, & the biceps tendon approaches its insertion on the radial tuberosity, which is slightly more distal to the brachialis insertion.* **(Bottom)** *Axial graphic at the level of the proximal forearm is shown. The muscles align themselves into the anterior (flexor) & posterior (extensor) compartments.*

LONGITUDINAL US, ANTERIOR ELBOW

(Top) *Longitudinal US of the anteroradial aspect of the elbow joint shows the squared radial head articulating with the capitellum. A small joint recess lies posterior to the anterior fat pad proximal to the capitellum. This intraarticular, extrasynovial anterior fat pad is displaced anteriorly & becomes visible radiographically with a medium-sized or large elbow effusion. There is often a small amount of fluid deep to this anterior fat pad.* **(Middle)** *Longitudinal US of the midline anterior elbow shows the brachialis tendon insertion. The brachialis muscle inserts into the anterior aspect of the coronoid process & the adjacent ulnar shaft. One can appreciate that the proximal part of the brachialis insertion is fleshy while the distal part is more tendinous.* **(Bottom)** *Longitudinal US of the ulnar anterior aspect of elbow shows the coronoid process of the ulna articulating with the trochlear process of the humerus. The anterior fat pad is seen. An effusion will accumulate between the anterior recess ("coronoid notch") of the humerus & the anterior fat pad.*

TRANSVERSE US, ANTERIOR ELBOW

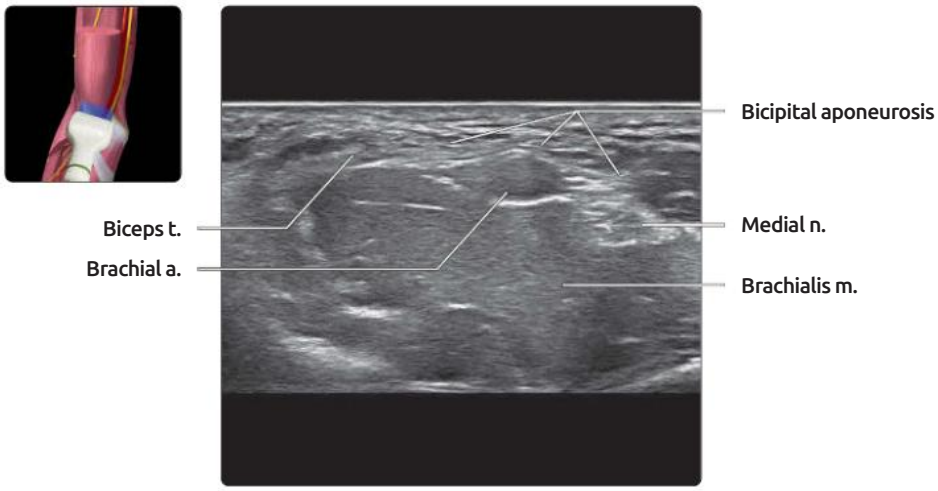

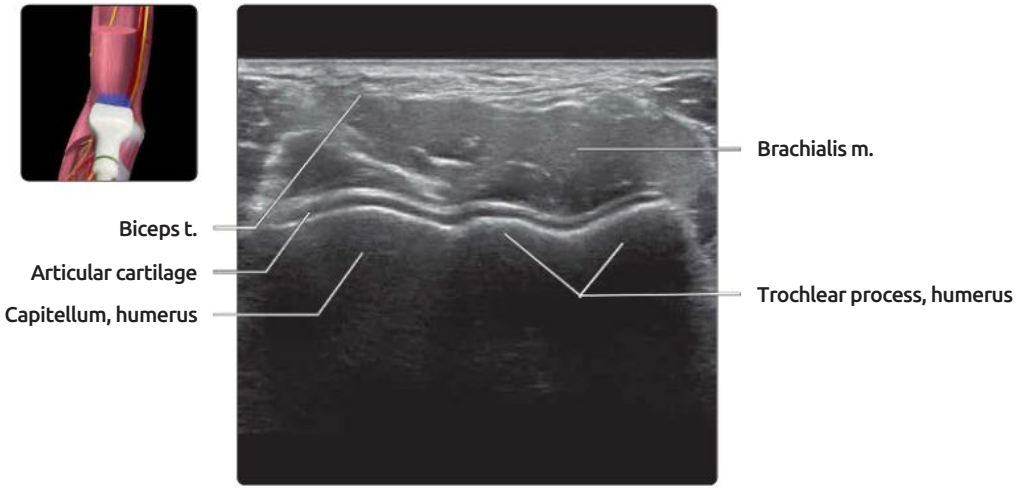

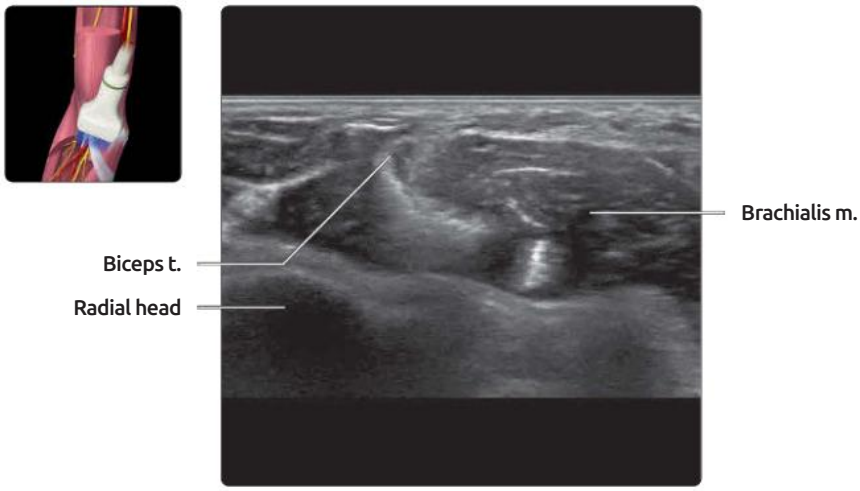

(Top) *Transverse US of the anterior elbow shows the proximal part of the antecubital fossa. The biceps tendon forms a few centimeters above the elbow. The bicipital aponeurosis arises from the medial side of the biceps tendon & extends laterally, superficial to the brachial artery & median nerve, to merge with the pronator teres myofascia.* **(Middle)** *Transverse US shows the anterior articulating surfaces of the distal humerus. The capitellum is rounded, while the trochlear process is more spool-shaped. These different shapes reflect the different movements of the proximal radius & ulna. During pronation & supination, the radius rotates freely around the more fixed ulna. The large brachialis muscle covers the anterior aspect of the distal humerus.* **(Bottom)** *Transverse US at the more distal aspect of elbow is shown. The biceps tendon rotates 90° as it descends steeply to insert into the radial tuberosity. This makes it difficult to delineate clearly on transverse US scanning. It is best seen on longitudinal scanning.*

LONGITUDINAL & TRANSVERSE US, BICEPS TENDON

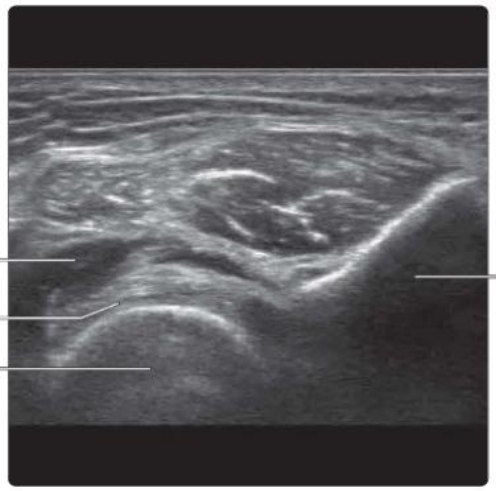

(Top) *Longitudinal oblique US of the anterior elbow flexed to 25° shows the biceps tendon insertion to radial tuberosity just distal to supinator muscle. The short & long head biceps tendons are continuous at the radial insertion, though the short head is inserted more distally than the long head.* **(Middle)** *Longitudinal US shows an alternative long-axis view of the biceps tendon. This view is obtained with the elbow flexed & the transducer almost parallel to, though anterior to, the humeral shaft.* **(Bottom)** *Transverse US shows the biceps tendon insertion. This view is obtained with the elbow fully flexed & the forearm pronated so that the hand faces the examiner. It provides a good view of the biceps insertional area. The insertional area will appear & disappear with pronation & supination of the forearm during real-time US scanning.*

TRANSVERSE US, BICEPS TENDON

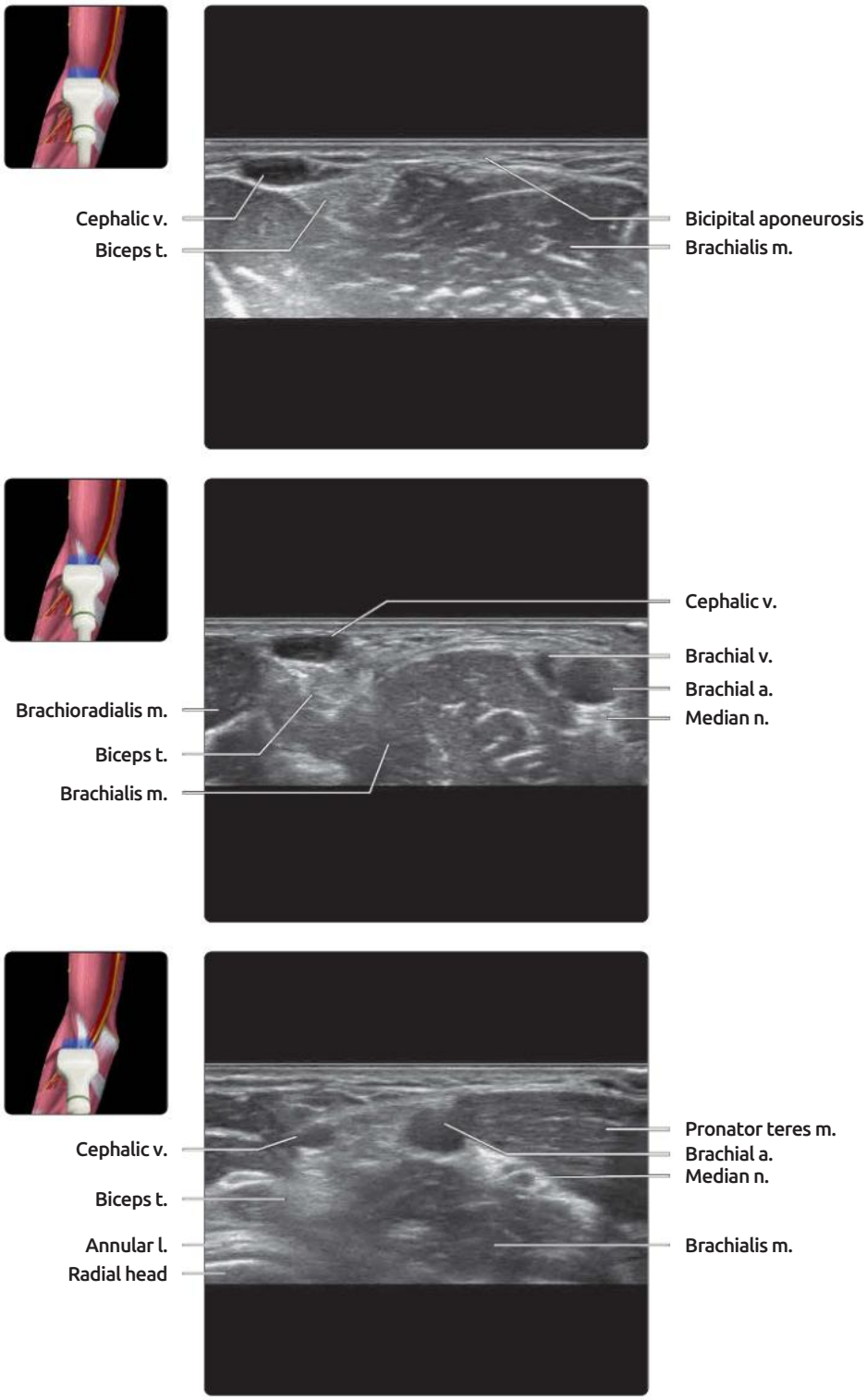

(Top) *Transverse US shows the biceps tendon at the proximal antecubital fossa. The biceps tendon forms a few centimeters proximal to the elbow joint. It lies deep to the cephalic vein.* **(Middle)** *Transverse US shows the biceps tendon at the midcubital fossa. The biceps tendon dips deeply indenting the brachialis muscle & rotates as it passes to its insertion. The cephalic vein provides an acoustic window to more clearly visualize the distal biceps tendon.* **(Bottom)** *Transverse US shows the distal biceps tendon insertional area. The distal end of the biceps tendon rotates 90° laterally as it descends to its insertion, making it difficult to see on transverse imaging & best seen on longitudinal imaging.*

TRANSVERSE & LONGITUDINAL US, ANTEROLATERAL ELBOW

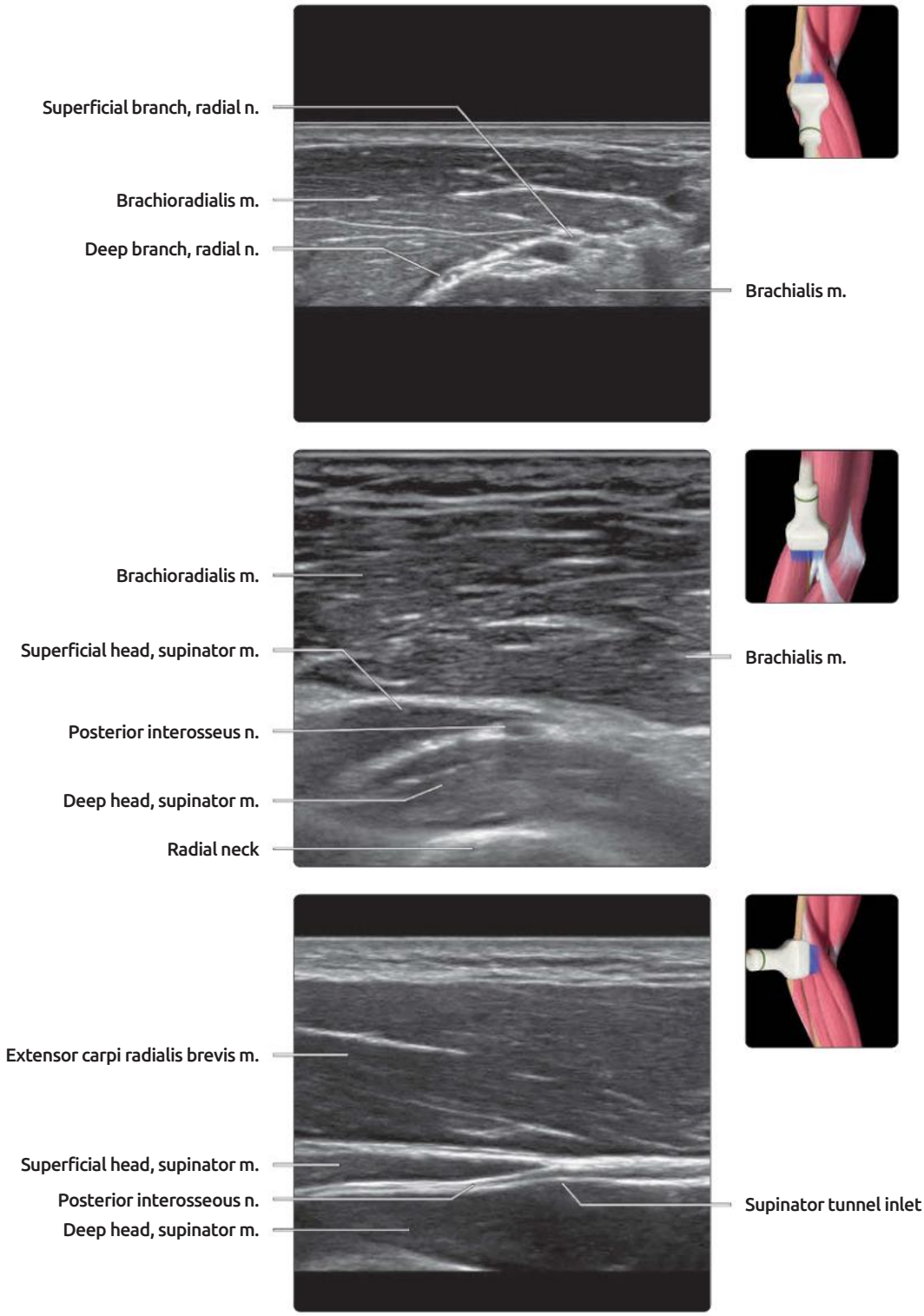

(Top) *Transverse US shows the radial tunnel at the anterolateral aspect of the elbow. The radial tunnel lies between the lateral intermuscular septum & the supinator muscle inlet. The radial nerve divides in the radial tunnel into a superficial sensory branch & a deep motor branch.* **(Middle)** *Transverse US shows the deep branch of the radial nerve entering the supinator tunnel. It is now known as the posterior interosseous nerve. The nerve often slightly swells just proximal to the tunnel. The tunnel inlet is the most common site of the posterior interosseous nerve entrapment due to a fibrous band (arcade of Fröhse).* **(Bottom)** *Longitudinal US shows the posterior interosseous nerve running between the superficial & deep bellies of the supinator muscle. Slight swelling of the nerve just proximal to the tunnel inlet is normal.*

COMMON EXTENSOR TENDON ORIGIN

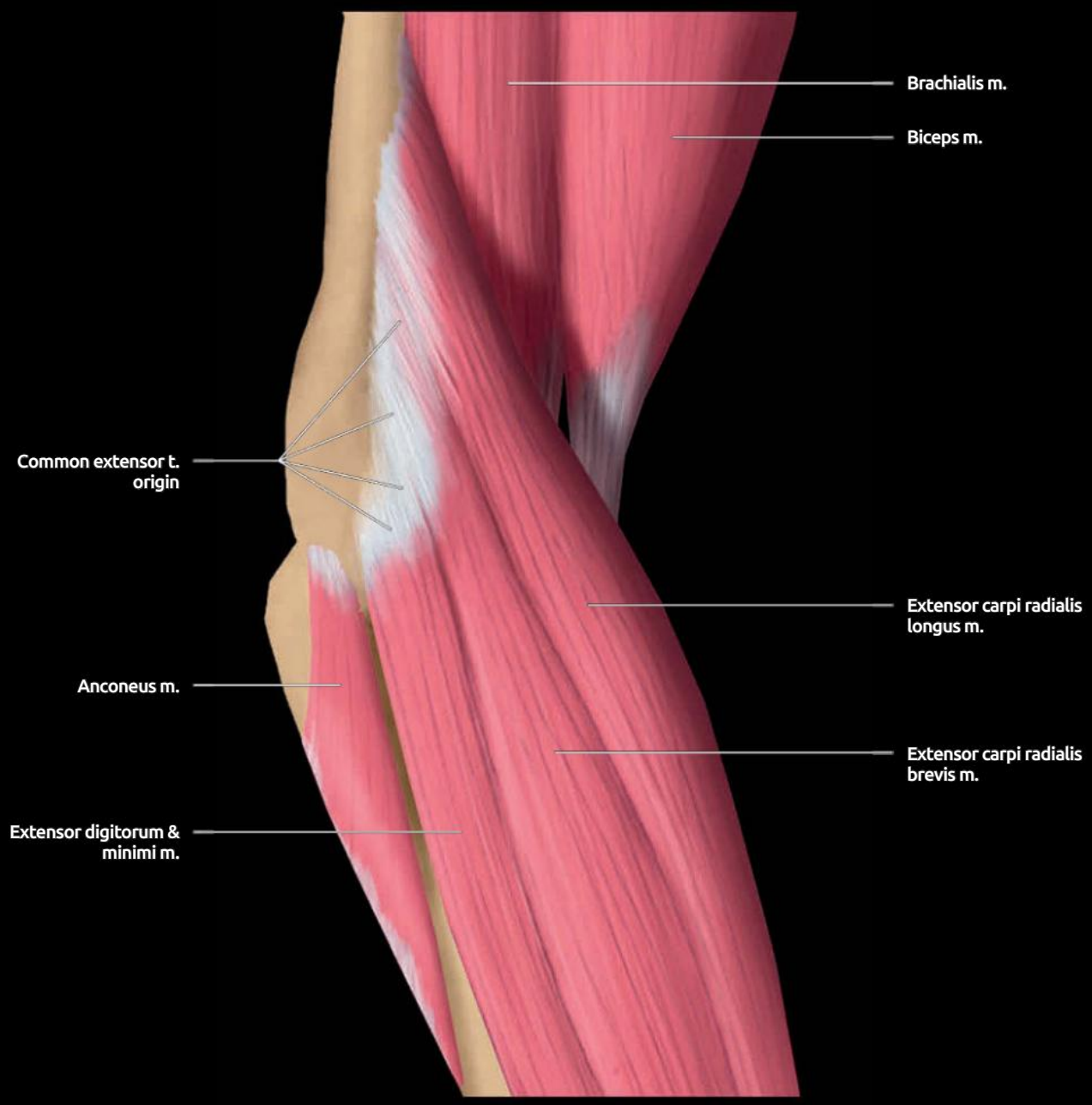

Side view of the lateral aspect of the elbow shows the extensor-supinator group & its common extensor tendon origin attaching to the lateral epicondyle & supracondylar aspect of the humerus. The common extensor tendon origin is composed of the extensor carpi radialis brevis, extensor digitorum, extensor digiti minimi, & extensor carpi ulnaris. The extensor digitorum origin & extensor carpi radialis brevis are very closely aligned.

LONGITUDINAL & TRANSVERSE US, COMMON EXTENSOR ORIGIN

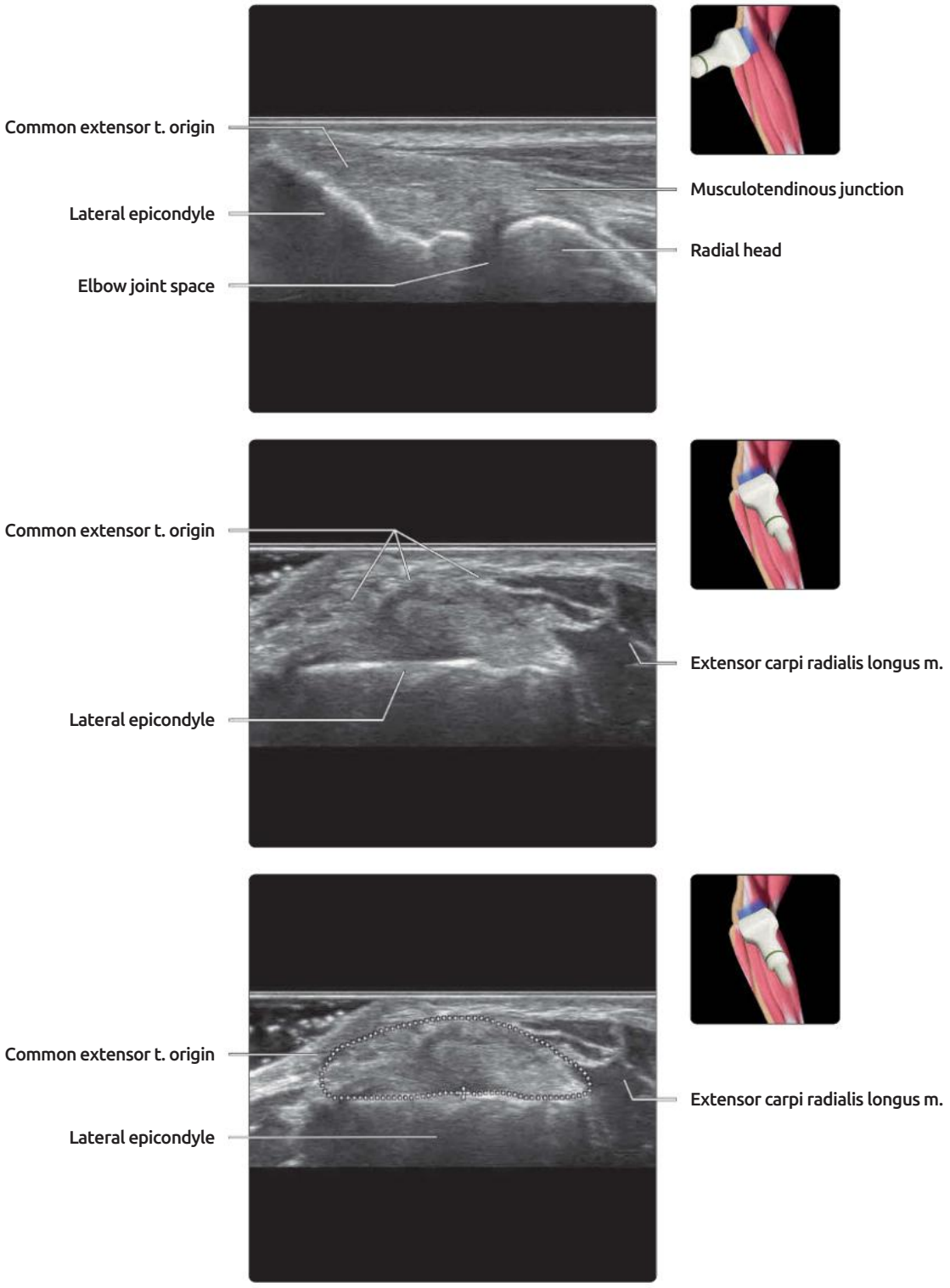

(Top) *Longitudinal US of the common extensor tendon origin shows its broad attachment on the posterolateral aspect of the lateral epicondyle. The fibers from the different tendons are inseparable at or near the insertion. Fibers from the extensor digitorum muscle make up most of the superficial portion, while fibers from extensor carpi radialis brevis muscle make up most of the deep fibers. The contribution from extensor carpi ulnaris & extensor digiti minimi muscles is relatively small.* **(Middle)** *Transverse US shows the common extensor tendon origin. The common extensor tendon gains broad insertion onto the lateral aspect of the lateral epicondyle.* **(Bottom)** *Transverse US shows an outline of the normal common extensor origin at its attachment on the lateral epicondyle. The cross-sectional area was 1.2 cm².*

LONGITUDINAL US, RADIAL COLLATERAL LIGAMENT

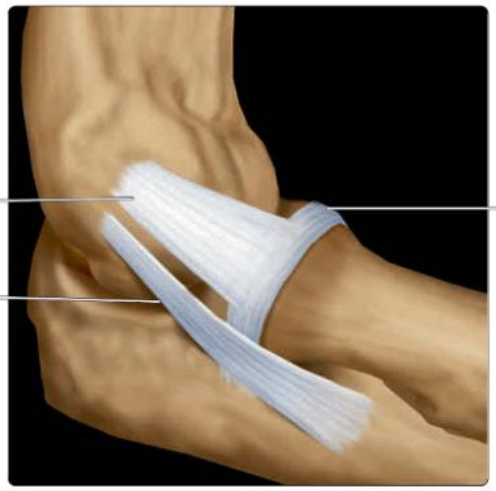

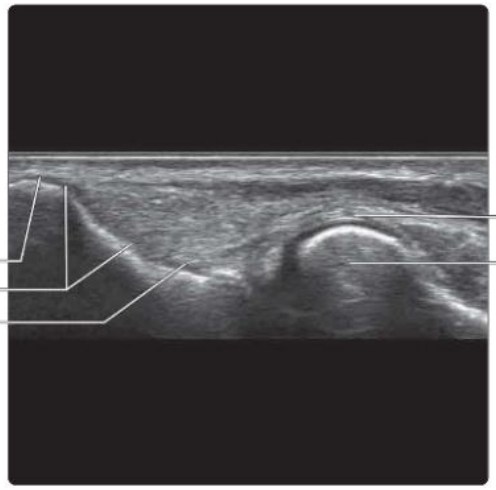

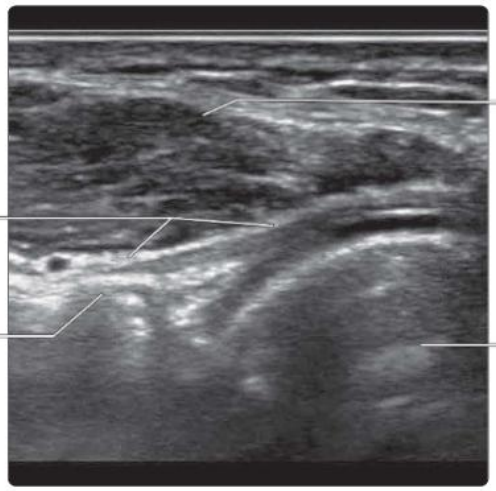

(Top) *Graphic shows the radial collateral ligament, comprising the radial collateral ligament proper, which is attached to the annular ligament. The lateral ulnar collateral ligament (LUCL) arises more posteriorly & runs obliquely distally & posteriorly, merging with the annular ligament posteriorly before inserting more distally along the ulnar supinator crest.* **(Middle)** *Longitudinal US shows the radial collateral ligament, which merges very closely with the common extensor tendon origin. Essentially, the deeper 1/3 of the common extensor tendon origin comprises fibers of the radial collateral ligament. Dynamic wrist flexion-extension can help separate movable tendons from the fixed radial collateral ligament.* **(Bottom)** *Transverse US of the posterolateral aspect of the elbow shows the mid to distal portion of the LUCL inserting into the supinator crest of the proximal ulna distal to the insertion of the annular ligament.*

TRANSVERSE ANTEROMEDIAL ELBOW

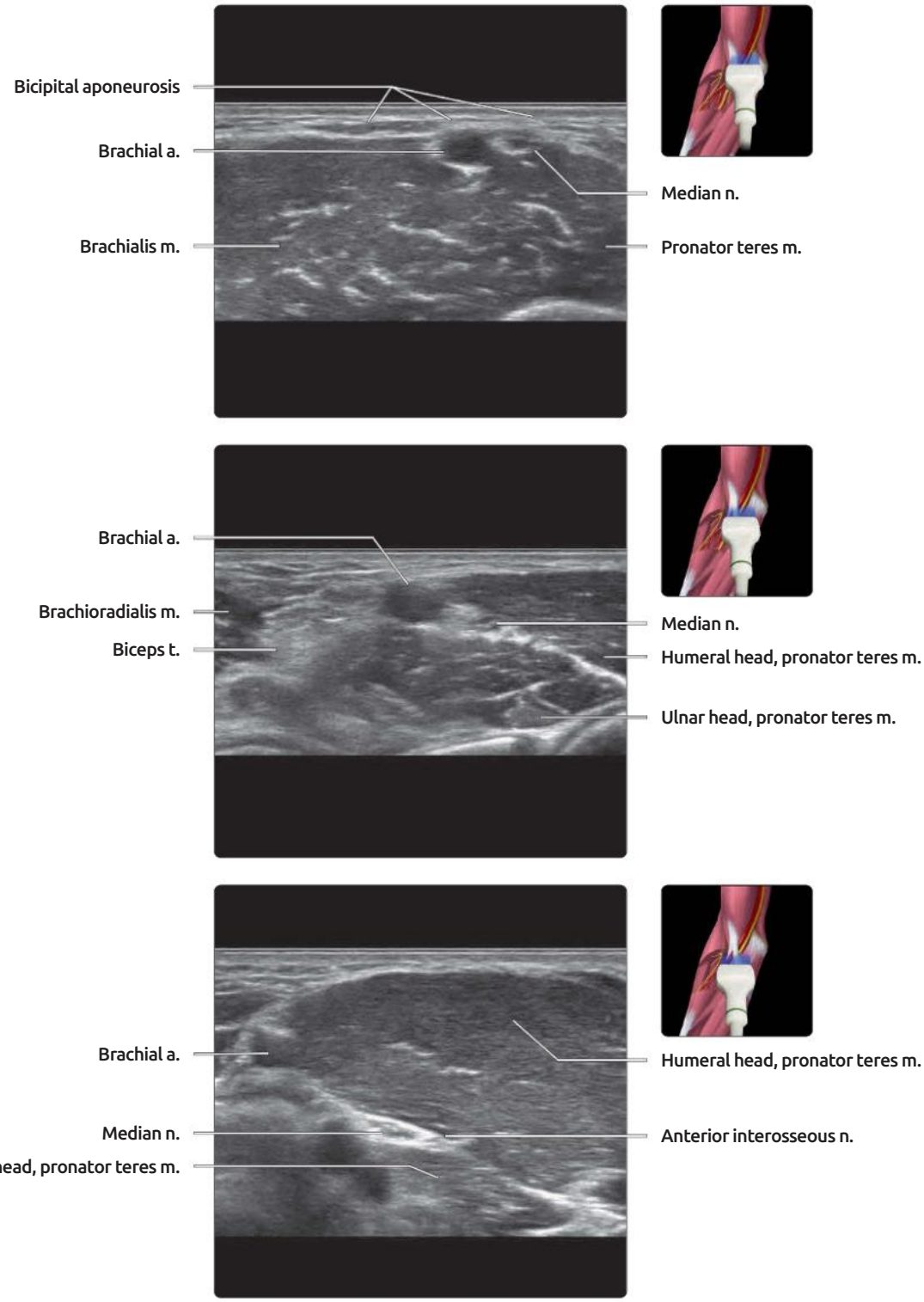

(Top) *Transverse US of the anteromedial aspect of the elbow shows the median nerve lying alongside the pronator teres muscle & medial to the brachial artery. The bicipital aponeurosis passes superficial to both the artery & the nerve as it extends medially & distally to merge with the myofascia of pronator teres muscle. The main muscle bulk centrally is brachialis.* **(Middle)** *Transverse US of the midportion of the antecubital fossa shows median nerve extending between 2 heads of pronator teres muscle. The larger head of pronator teres arises from common flexor tendon origin & the adjacent supracondylar ridge, while the smaller ulnar head arises from the medial aspect coronoid process of ulna. The median nerve can be compressed between both heads, giving rise to pronator teres syndrome.* **(Bottom)** *Transverse US shows median nerve extending deeply between 2 heads of pronator teres muscle. Here, the anterior interosseous nerve arises from median nerve & extends deeply to run on the volar aspect of the interosseous membrane with anterior interosseous artery. It supplies the flexor digitorum profundus (FDP) (radial half), flexor pollicis longus, & pronator quadratus muscles.*

LONGITUDINAL & TRANSVERSE US, COMMON FLEXOR TENDON ORIGIN

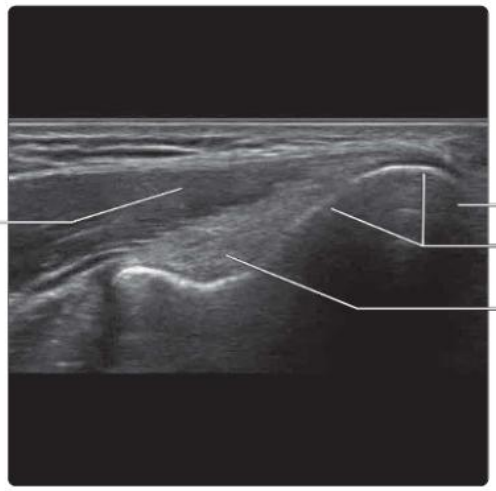

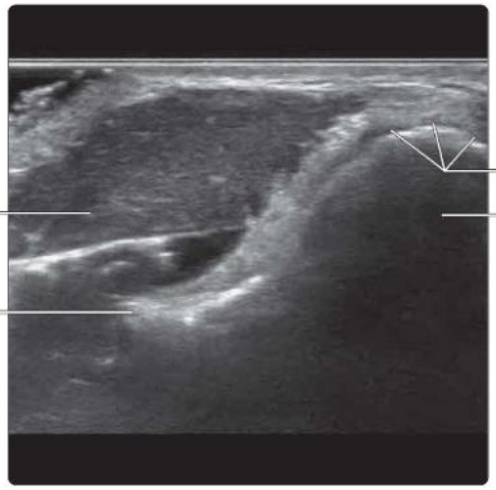

(Top) *Longitudinal US shows the common flexor tendon origin on the anterior aspect of the larger medial epicondyle, compared to the common extensor tendon origin, which is more on the lateral aspect of the smaller lateral epicondyle. The common flexor tendon origin is also shorter than the common extensor tendon origin.* **(Middle)** *Transverse US shows the common flexor tendon origin on the anterior & medial aspect of the medial epicondyle. The large pronator teres muscle lies anteriorly.* **(Bottom)** *Transverse US more distal to the medial epicondyle shows the muscles of the common flexor tendon origin diverging from the common tendon. The basilic vein is in the subcutaneous tissues on the anteromedial aspect of the elbow.*

COMMON FLEXOR TENDON ORIGIN

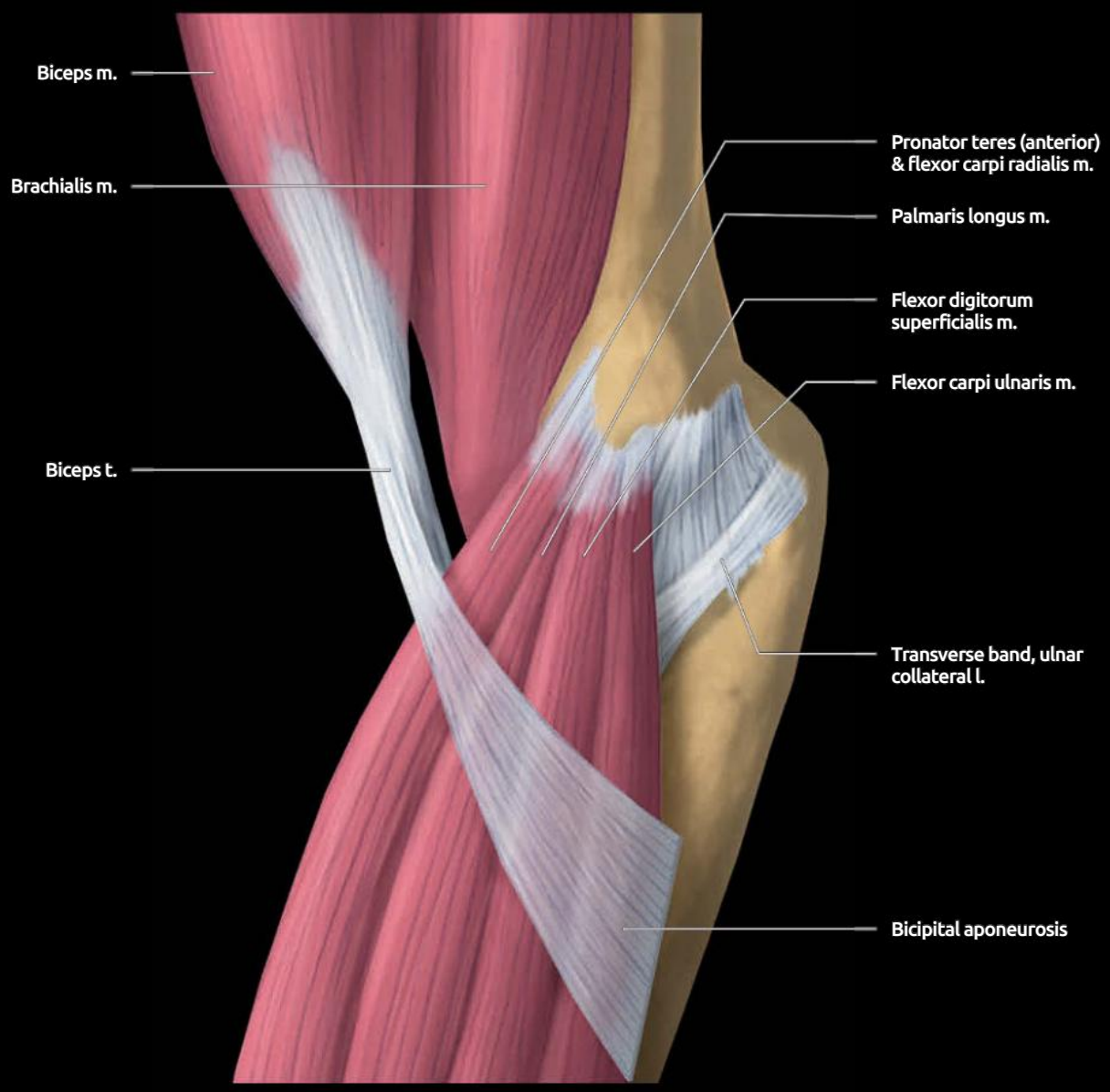

Graphic of the medial aspect of the elbow shows the flexor-pronator group & the common flexor tendons attaching to the medial epicondyle. The anterior band of the ulnar collateral ligament is deep to the common flexor tendons. The biceps aponeurosis blends with the myofascia of the flexor-pronator muscles, particularly the pronator teres. The FDP muscle (not shown) arises from the proximal & midparts of the ulnar shaft. It does not act on the elbow & is not part of the flexor-pronator muscle group.

ULNAR COLLATERAL LIGAMENT

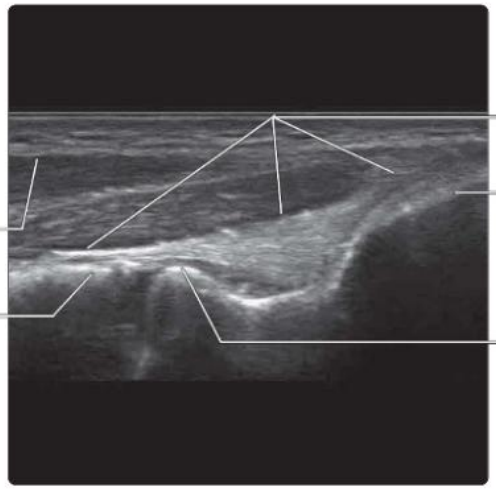

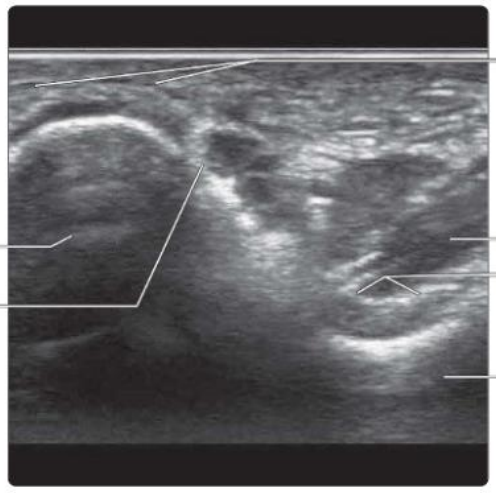

(Top) *Graphic shows the 3 components of the ulnar collateral ligament, namely, the anterior, posterior, & transverse bands. Structurally, the anterior band is the most important, while the transverse band is the least important. The anterior band restraints valgus stress on the elbow & is the most clinically relevant band.* **(Middle)** *Longitudinal US shows the anterior band of the ulnar collateral ligament, which is fan-shaped with a broad attachment on the medial epicondyle & a thin insertion onto the sublime tubercle on the medial aspect of the coronoid process of the ulna.* **(Bottom)** *Transverse US of the posteromedial aspect of the elbow shows the posterior band of the ulnar collateral ligament. The posterior band is a broad, thin ligament, which forms the floor of the cubital tunnel. This patient has a prominent medial belly of triceps muscle in the cubital tunnel.*

TRANSVERSE US, CUBITAL TUNNEL

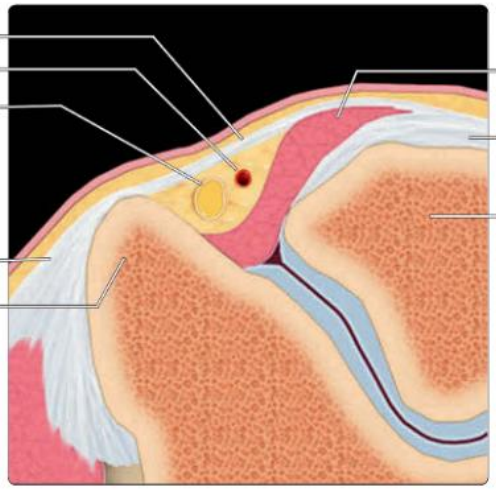

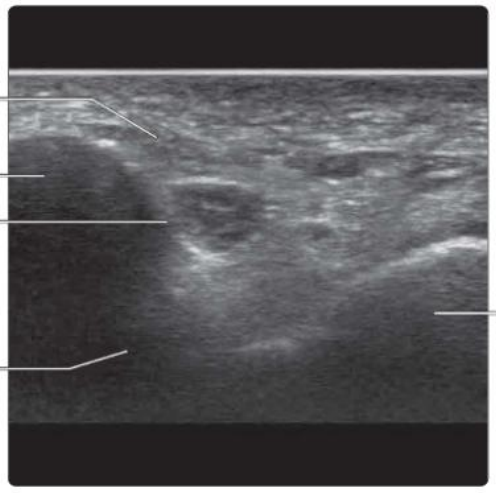

(Top) *Transverse US of the medial aspect of the distal arm shows the ulnar nerve located superficial to the medial belly triceps muscle.* **(Middle)** *Graphic shows cross section of cubital tunnel. The ulnar nerve may be accompanied by a small artery (superficial or inferior ulnar collateral artery). The cubital tunnel is covered by Osbornes ligament. There may be an accessory muscle (anconeus epitrochlearis muscle) attached to the deep margin of Osbornes ligament. A bulky medial belly of the triceps muscle may also be visible attaching along the medial border of the olecranon process. The close relationship between the common flexor tendon origin & the cubital tunnel is also shown.* **(Bottom)** *Transverse US shows the ulnar nerve within the cubital tunnel between the olecranon process & the medial epicondyle. The thin Osbornes ligament is barely visible. The elbow joint is located inferolaterally.*

TRANSVERSE & LONGITUDINAL US, CUBITAL TUNNEL

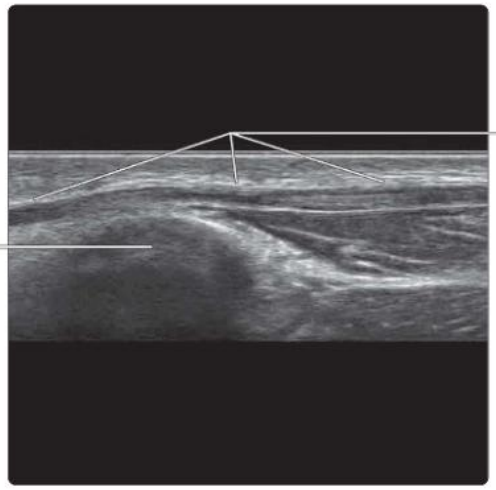

(Top) *Transverse US of the distal part of the cubital tunnel shows the ulnar nerve located between the ulnar & humeral heads of the flexor carpi ulnaris muscle. The ulnar head arises from the olecranon process, while the humeral head arises from the posterior aspect of medial epicondyle. The arcuate ligament covers the ulnar nerve at this location. The nerve may be compressed at this location.* **(Middle)** *Longitudinal US shows the ulnar nerve passing from the distal arm posterior to the medial epicondyle.* **(Bottom)** *Graphic shows how the ulnar nerve becomes relatively uncovered at the cubital tunnel during flexion, allowing subluxation over the medial epicondyle in some normal subjects. The humeral & ulnar heads of the flexor carpi ulnaris muscle with the intervening arcuate ligament (or fascia) are also shown. Repeated anterior subluxation of the ulnar nerve may give rise to friction neuritis.*

LONGITUDINAL & TRANSVERSE US, POSTERIOR ELBOW

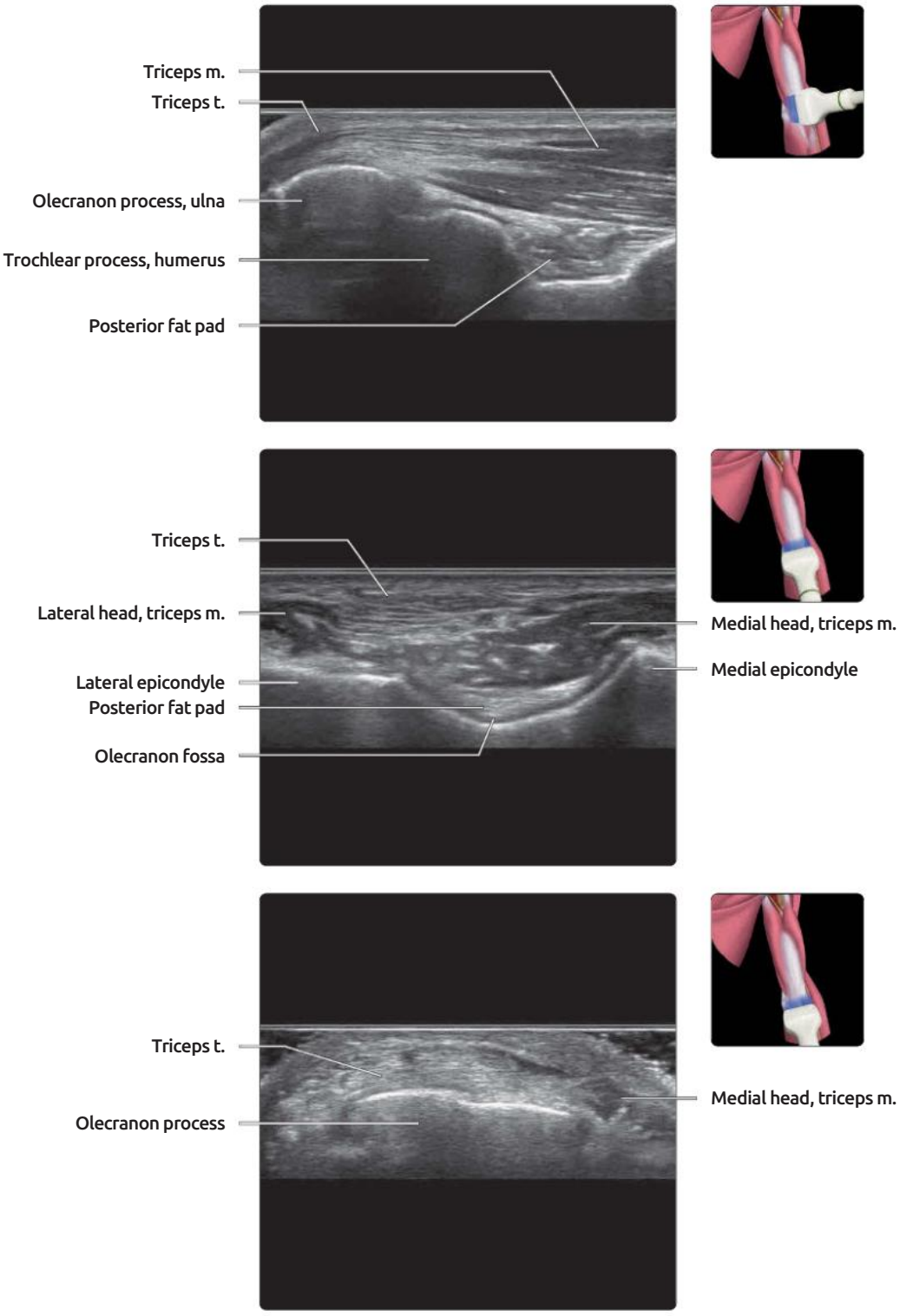

(Top) *Longitudinal US shows the triceps tendon attaching to the olecranon process. The posterior fat pad within the olecranon fossa of the distal ulna is intraarticular though extrasynovial. Fluid distension of the synovial cavity will elevate the fat pad.* **(Middle)** *Transverse US shows the posterior elbow just proximal to the olecranon process. A larger medial head of triceps muscle is attached to the triceps tendon with a small lateral head of triceps muscle laterally. The fat pad is present in the olecranon recess posteriorly.* **(Bottom)** *Transverse US shows triceps tendon attachment to the olecranon process. Some fibers of the medial head of triceps muscle are still visible. The olecranon bursa lies between the triceps tendon & the subcutaneous tissue. The normal olecranon bursa is not visible. The bursa only becomes visible when it is inflamed & distended.*

IMAGING ANATOMY

Volar Compartment

- **Superficial volar group**
  - Pronator teres (PT)
    - Origin: Humeral head from common flexor tendon; ulnar head arises from medial aspect coronoid process
    - Insertion: Lateral surface of middle 1/3 of radius
  - Flexor carpi radialis (FCR)
    - Origin: Medial epicondyle/common flexor tendon
    - Insertion: 2nd metacarpal (MC) base
  - Palmaris longus (PL)
    - Origin: Medial epicondyle/common flexor tendon
    - Insertion: Flexor retinaculum & palmar aponeurosis
  - Flexor carpi ulnaris (FCU)
    - Origin: Medial epicondyle (humeral head) & medial proximal ulna (ulnar head)
    - Insertion: Pisiform bone
  - Flexor digitorum superficialis (FDS)
    - Origin: Medial epicondyle & proximal ulna & radius
    - Insertion: Middle phalanges of index, middle, ring, & little fingers
- **Deep volar group**
  - Flexor digitorum profundus (FDP)
    - Origin: Proximal ulna
    - Insertion: Distal phalangeal bases of fingers
  - Flexor pollicis longus (FPL)
    - Origin: Radius, interosseous membrane, coronoid process
    - Insertion: Distal phalangeal base of thumb
  - Pronator quadratus (PQ)
    - Origin: Medial distal volar ulna
    - Insertion: Lateral aspect of distal radius dorsally

Dorsal Compartment

- **Superficial dorsal group**
  - Anconeus
    - Origin: Lateral epicondyle proximally
    - Insertion: Lateral aspect of olecranon & adjacent ulna
  - Supinator
    - Origin: Lateral epicondyle, supinator crest ulna, radial collateral ligament, annular ligament
    - Insertion: Lateral aspect of proximal radial shaft
  - Extensor digitorum (ED)
    - Origin: Lateral epicondyle/common extensor tendon
    - Insertion: Middle & distal phalanges of fingers
  - Extensor digiti minimi (EDM)
    - Origin: Lateral epicondyle/common extensor tendon
    - Insertion: Extensor hood of little finger with slip to ring finger
  - Extensor carpi ulnaris (ECU)
    - Origin: Common extensor tendon & dorsal ulna
    - Insertion: Ulnodorsal aspect of 5th MC base
- **Deep dorsal group**
  - Abductor pollicis longus (APL)
    - Origin: Dorsal lateral ulna, dorsal midradius
    - Insertion: 1st MC radial base
  - Extensor pollicis brevis (EPB)
    - Origin: Dorsal midradius
    - Insertion: Proximal phalangeal base of thumb
  - Extensor pollicis longus (EPL)
    - Origin: Dorsal midulna
    - Insertion: Base of distal phalanx of thumb
  - Extensor indicis
    - Origin: Dorsal mid-ulna & interosseous membrane
    - Insertion: Extensor hood of index finger

Lateral Compartment

- Brachioradialis (BR)
  - Origin: Lateral supracondylar ridge of humerus
  - Insertion: Radial styloid process
- Extensor carpi radialis longus (ECRL)
  - Origin: Lateral epicondyle/common extensor tendon
  - Insertion: Dorsoradial aspect of 2nd MC
- Extensor carpi radialis brevis (ECRBr)
  - Origin: Lateral epicondyle/common extensor tendon
  - Insertion: Dorsoradial aspect of 3rd MC

Innervation

- Volar compartment
  - Mainly by median nerve
    - Superficial group by median nerve directly, deep group by anterior interosseous nerve (AIN)
  - FCU by ulnar nerve
  - FDS medial part by ulnar nerve, lateral part by AIN
- Dorsal compartment
  - By deep branch of radial nerve & posterior interosseous nerve (PIN)
    - Exception is anconeus muscle, which is by radial nerve
- Lateral compartment
  - BR & ECRL by radial nerve
  - ECRBr by deep branch of radial nerve

ANATOMY IMAGING ISSUES

Imaging Pitfalls

- Many variations of muscles & tendons
  - PL absent in 20%; short tendon with extended muscle belly may compress median nerve
  - EPB may be absent or fused with EPL
  - Multiple tendon slips can mimic longitudinal tendon tears (e.g., APL)
  - Small amount of fluid is common in tendon sheaths

Imaging Issues

- APL & EPB cross over ECRB & ECRL just proximal to extensor retinaculum (proximal intersection syndrome)
- Sites of radial nerve entrapment in forearm
  - PIN within radial tunnel under arcade of Frohse
  - PIN between deep & superficial heads of supinator muscle
  - Superficial radial nerve between BR & ECRL in mid to distal forearm
- Sites of ulnar nerve entrapment in forearm
  - Cubital tunnel
  - Beyond cubital tunnel as it passes between humeral & ulnar origins of FCU muscle
- Sites of medial nerve entrapment in forearm
  - Between heads of PT

AXIAL ANATOMY OF FOREARM

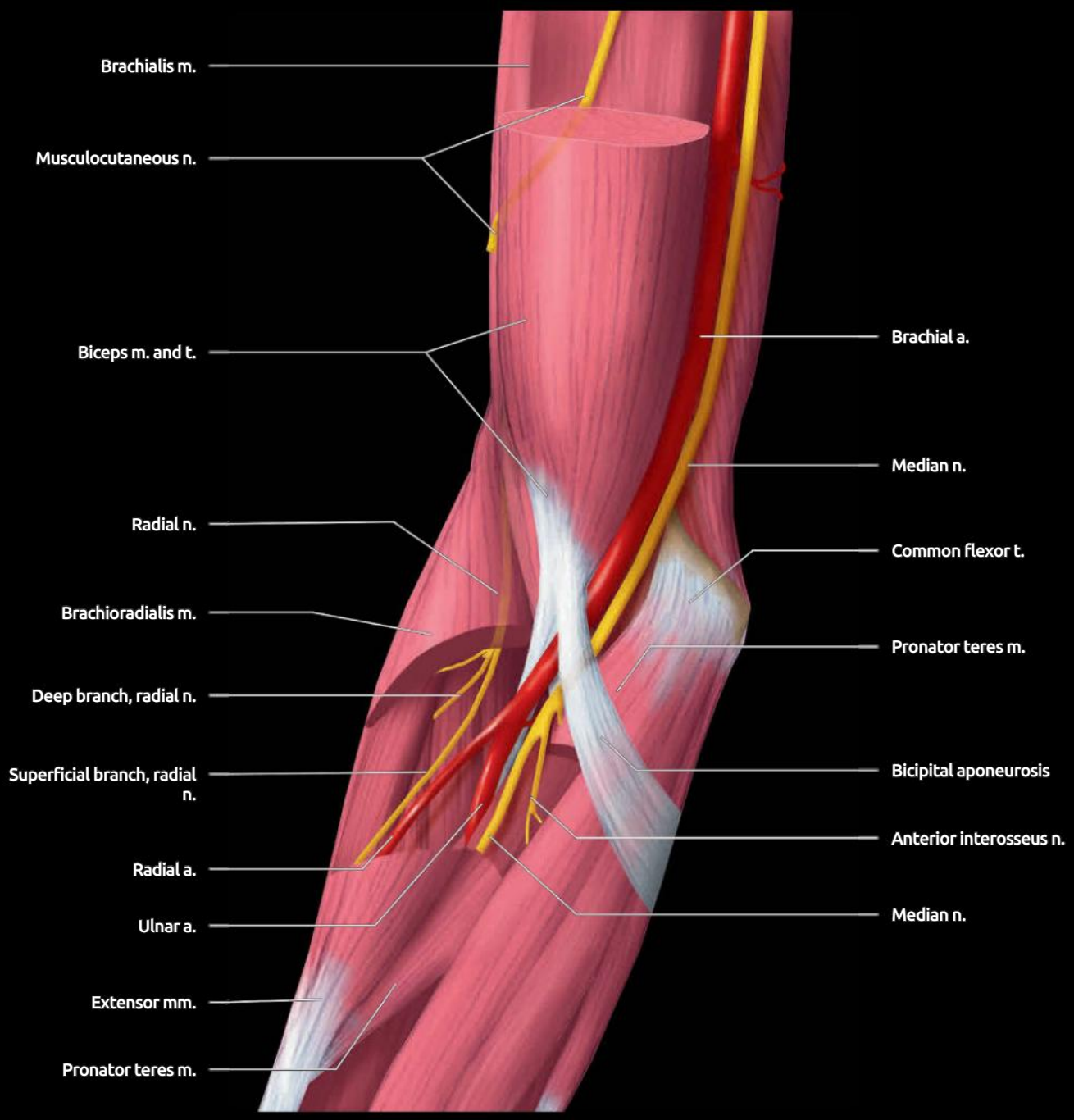

Graphic of the anterior aspect of the cubital fossa shows the median nerve and brachial artery passing underneath the bicipital aponeurosis. The anterior interosseus nerve arises from the median nerve as the median nerve passes between the 2 heads of the pronator teres muscle. The radial nerve, deep to the brachioradialis muscle, is seen dividing into the superficial and deep branches.

AXIAL ANATOMY OF FOREARM

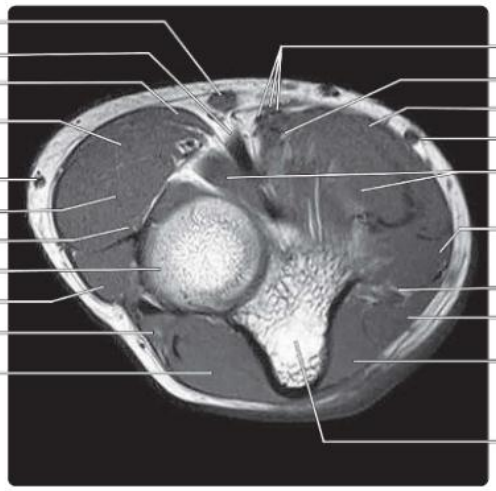

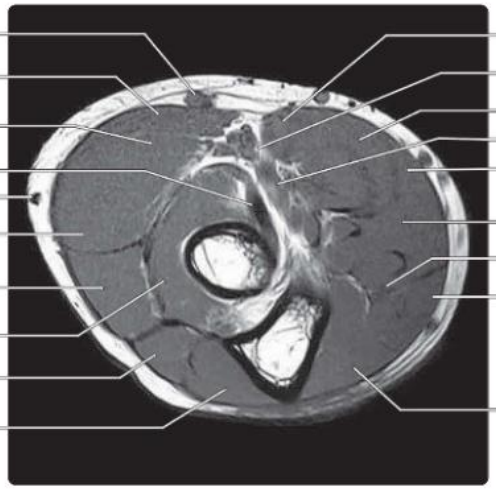

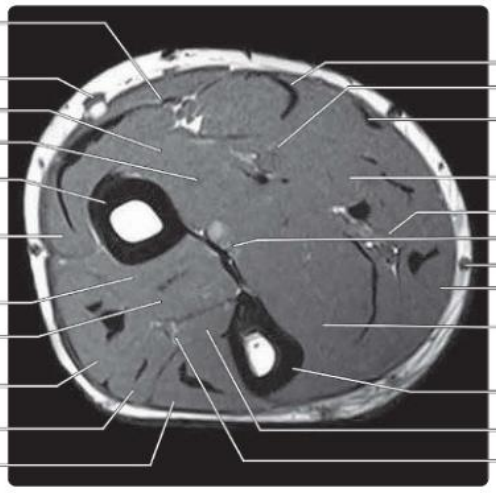

(Top) *Axial T1 MR of the forearm at the level of the proximal radioulnar joint is shown. The biceps tendon plunges down toward the radial tuberosity.* **(Middle)** *Axial T1 MR of the forearm just distal to the proximal radioulnar joint, at the radial tuberosity level, is shown. The medial nerve passes deeply to take up a position deep to the flexor digitorum superficialis muscle.* **(Bottom)** *Axial T1 MR of the proximal to midforearm is shown. The radius and ulna, as well as the intervening interosseous membrane, separate the flexor and extensor compartments.*

AXIAL ANATOMY OF FOREARM



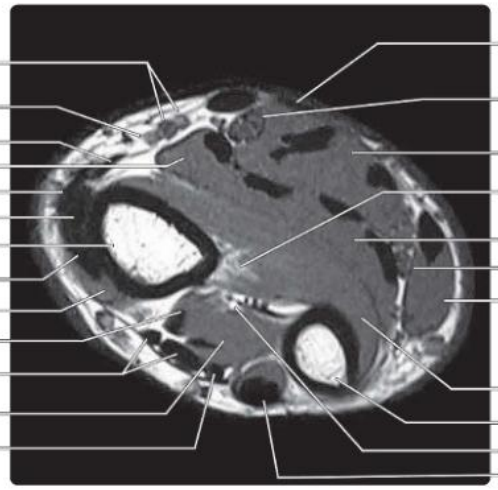

(Top) *Axial T1 MR of the mid to distal forearm shows the median nerve lies well protected between the flexor digitorum superficialis and flexor digitorum profundus muscles.* **(Middle)** *Axial T1 MR of the distal forearm just proximal to the ulnar notch of radius is shown. The median nerve passes superficially to lie deep to the palmaris longus tendon.* **(Bottom)** *Axial T1 MR of the midforearm shows the 4 forearm compartments. The superficial volar compartment is composed of the palmaris longus, flexor carpi radialis, flexor digitorum superficialis, and flexor carpi ulnaris muscles. The deep volar compartment is composed of the flexor digitorum profundus muscle. The dorsal compartment is composed of the extensor carpi ulnaris, extensor digiti minimi, and extensor digitorum muscles. The mobile wad compartment is composed of the brachioradialis and extensor carpi radialis longus muscles.*

ANTEROLATERAL ANATOMY OF FOREARM

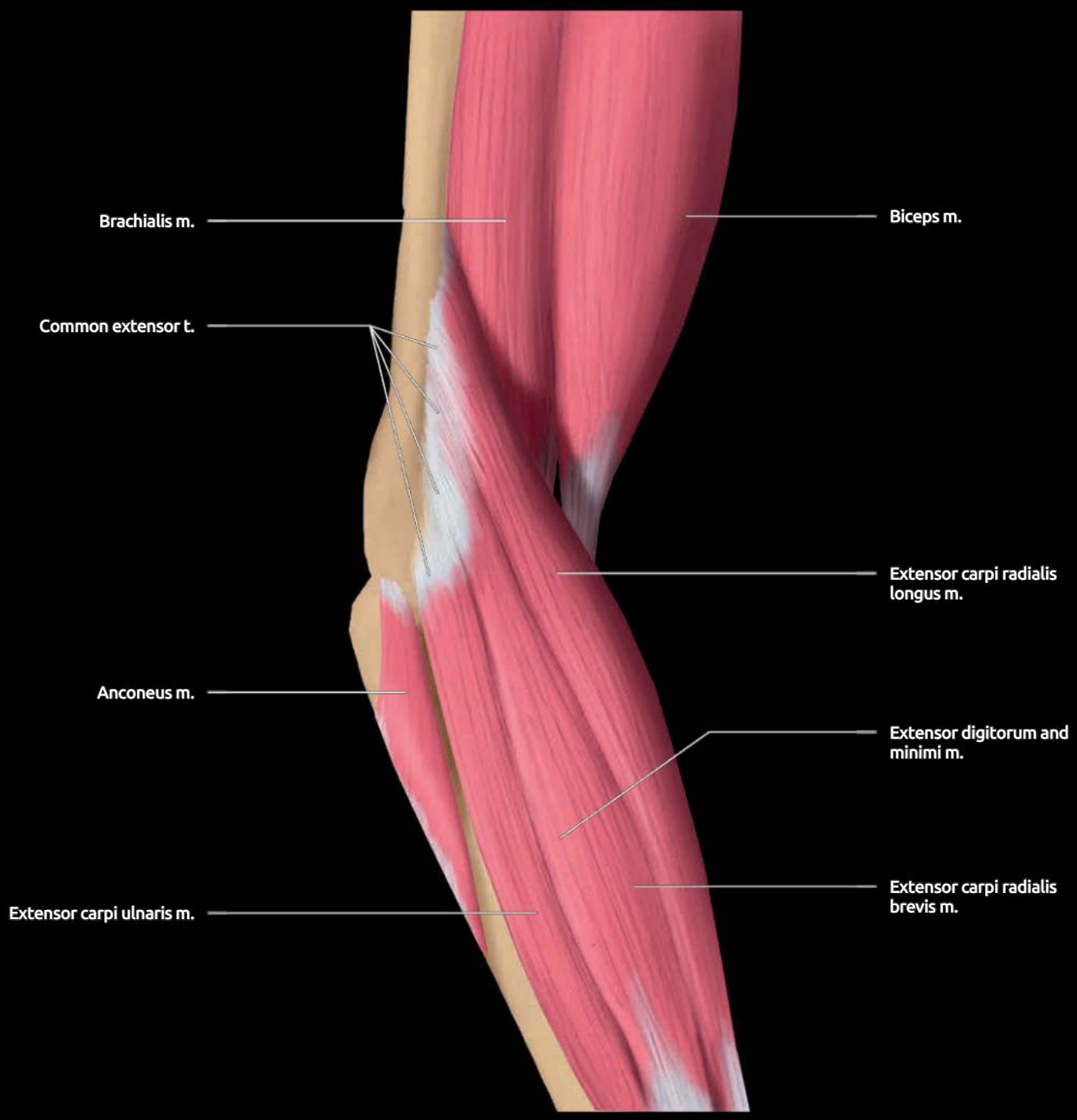

Graphic side view of lateral aspect of the elbow shows the extensor-supinator group and its common extensor tendon origin attached to the lateral epicondyle and supracondylar aspect of the humerus. The common extensor tendon origin is composed of the extensor carpi radialis brevis, extensor digitorum, extensor digiti minimi, and extensor carpi ulnaris tendons.

ANTEROLATERAL ANATOMY OF FOREARM

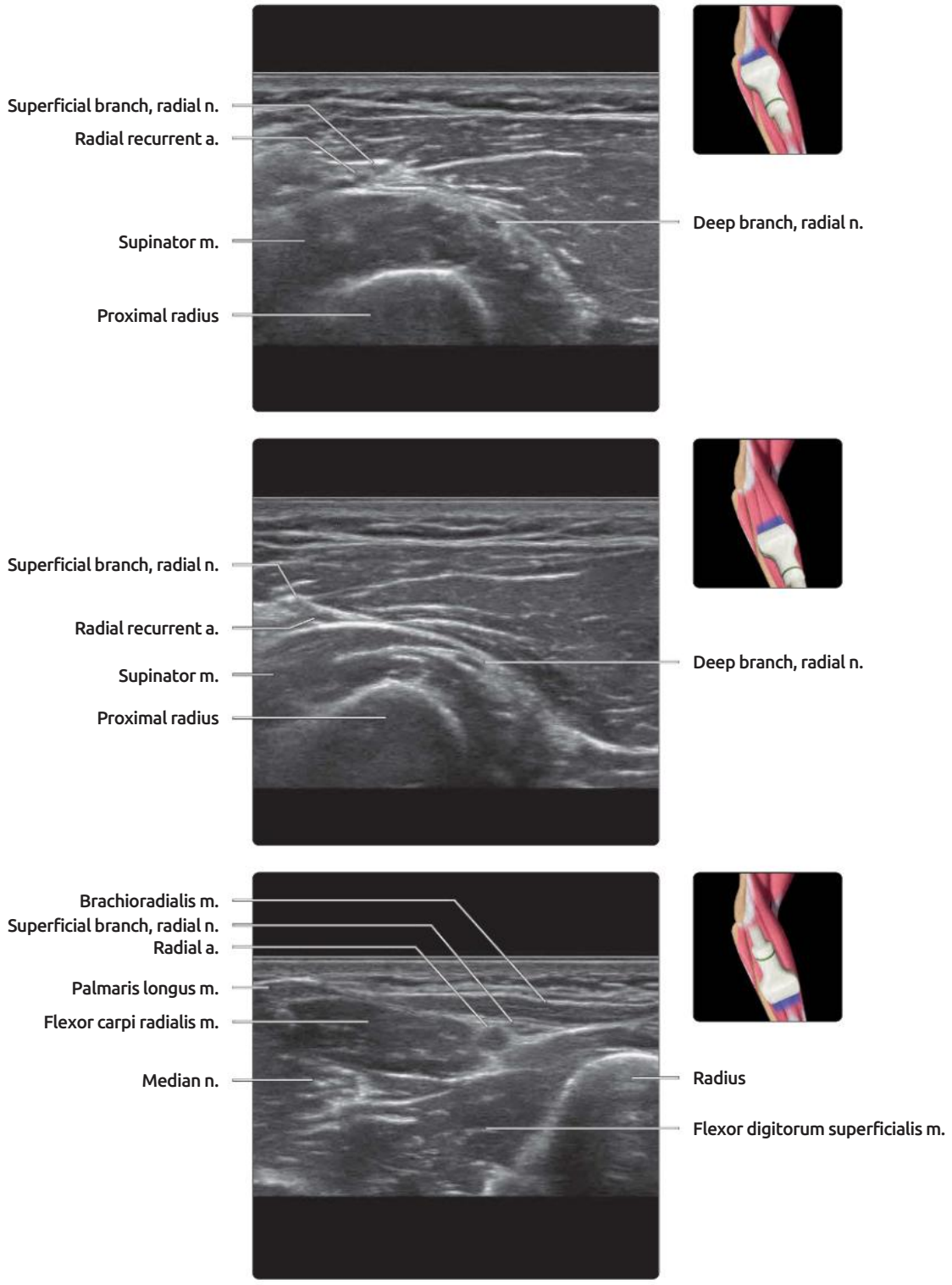

(Top) *Transverse US of the anterolateral aspect of the proximal forearm shows the superficial and deep branches of the radial nerve in the radial tunnel, which is between the lateral intermuscular septum of the arm and the supinator tunnel inlet.* **(Middle)** *Transverse US of the proximal anterolateral aspect of the forearm shows the deep branch of the radial nerve about to enter the supinator tunnel. The deep branch can normally slightly enlarge just before it enters the tunnel.* **(Bottom)** *Transverse US shows how the superficial branch of the radial nerve joins the radial artery in the midforearm, deep to the distal part of the brachioradialis muscle. More distally, the superficial branch of the radial nerve will run in the subcutaneous tissues and cross the 1st extensor compartment at its more terminal branches.*

COMMON FLEXOR TENDON

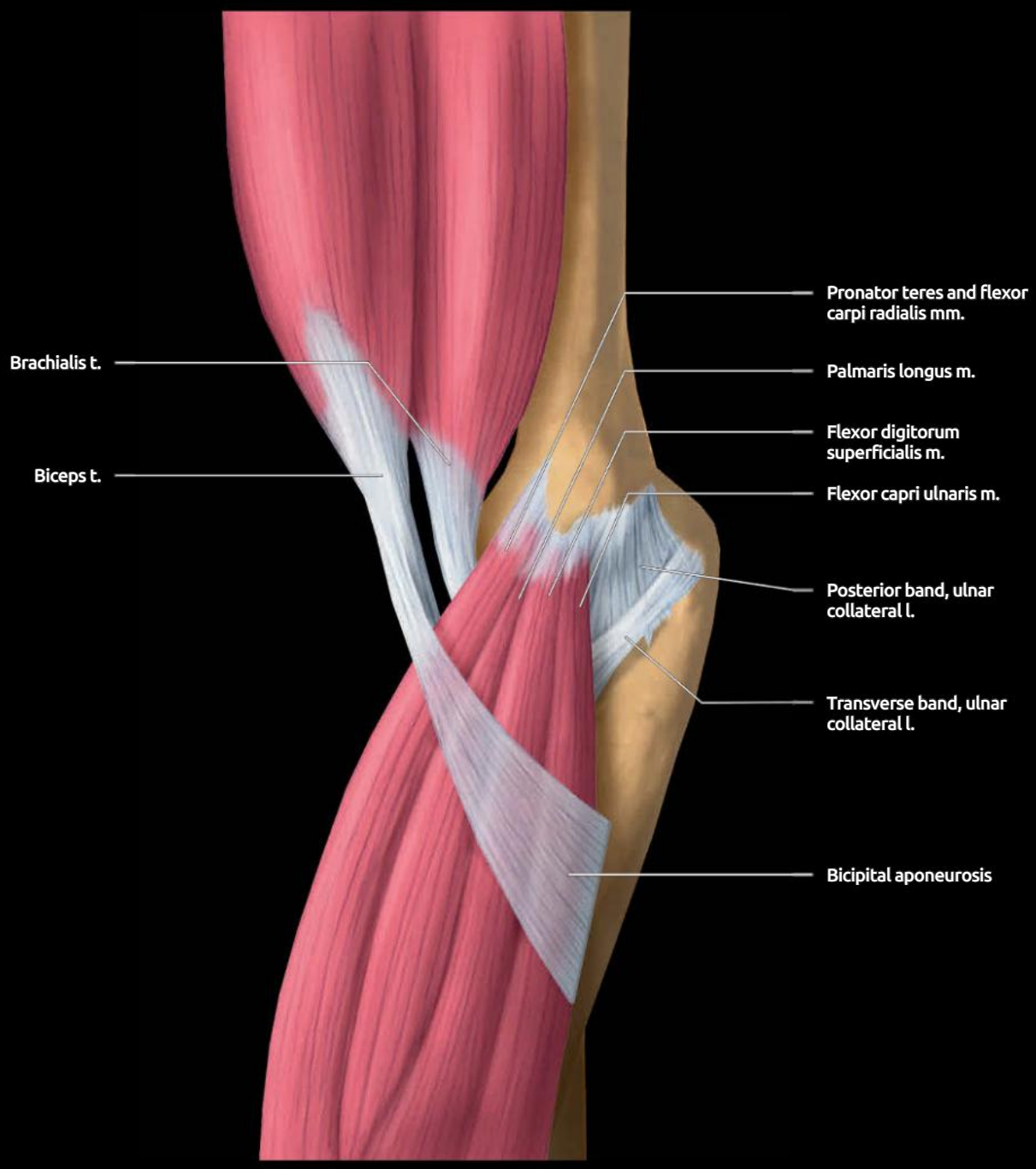

Graphic of the side view of the medial aspect of the elbow shows the flexor-pronator group and the common flexor tendon origin attaching to the medial epicondyle. The anterior band of the ulnar collateral ligament is deep to the common flexor tendon. The bicipital aponeurosis blends with the anterior aspect of the common flexor muscle mass. The flexor digitorum profundus arises from the proximal ulna, posterior and deep to the flexor carpi ulnaris. It does not act on the elbow and is not part of the flexor-pronator group.

ANTEROMEDIAL ANATOMY OF FOREARM

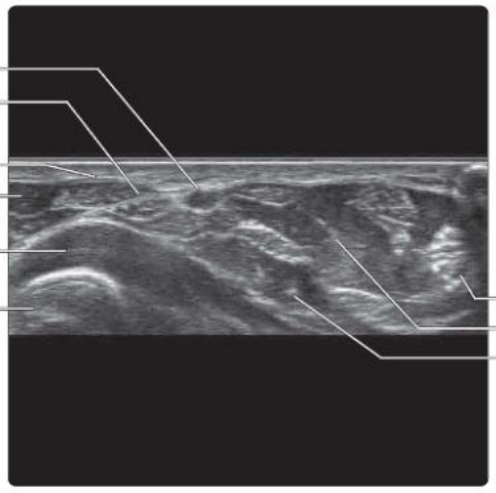

(Top) *Transverse US of the anteromedial aspect of the proximal forearm shows the ulnar nerve protected by the overlying flexor carpi ulnaris muscle. The ulnar nerve follows this muscle distally to Guyon canal.* **(Middle)** *Transverse US of the midforearm shows how the ulnar artery and the ulnar nerve align alongside each other in the midforearm region deep to the flexor carpi ulnaris muscle.* **(Bottom)** *Transverse US of the anteromedial aspect of the distal forearm shows the ulnar nerve alongside the ulnar artery just proximal to the wrist. The median nerve lies centrally in the forearm, mainly between the flexor digitorum superficialis and flexor digitorum profundus muscles.*

ANATOMY OF FOREARM

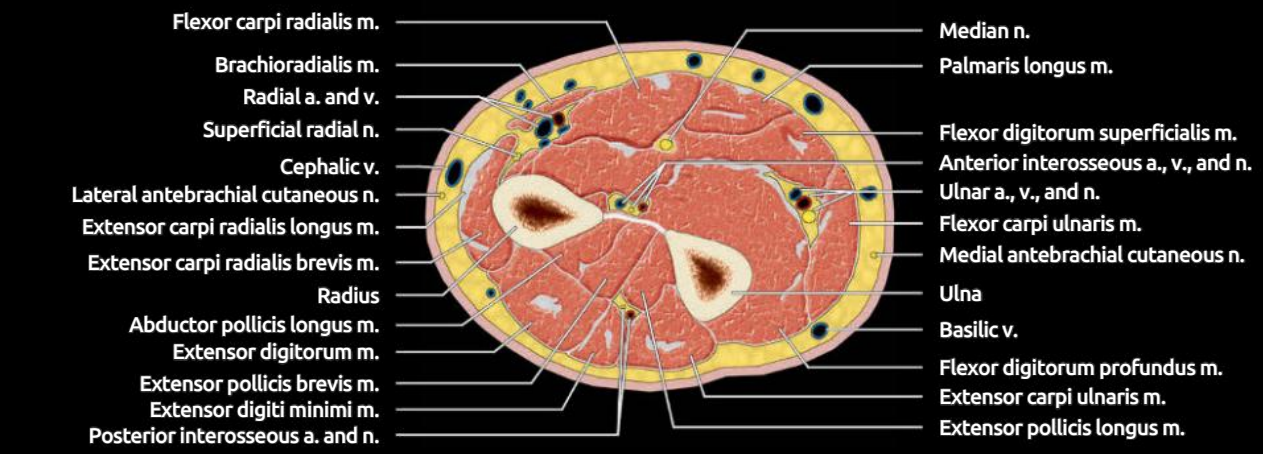

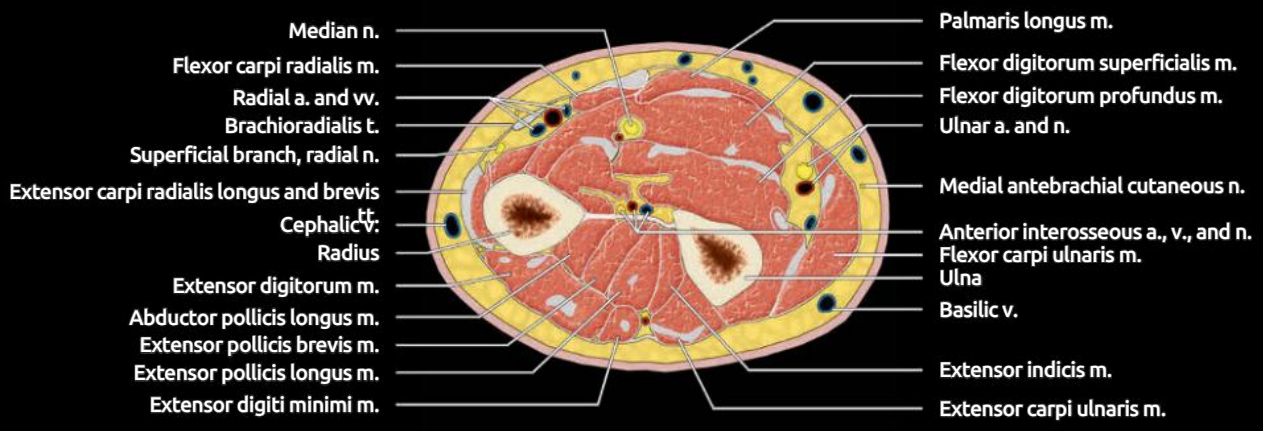

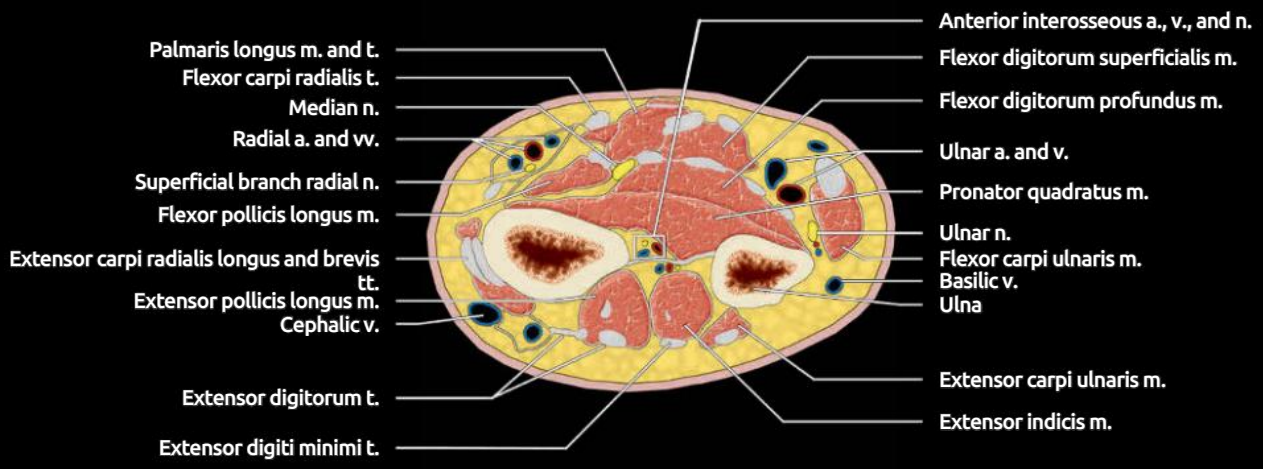

(Top) *Graphic shows transverse view of the proximal to midarm region. One can appreciate the relationship of the forearm nerves to the surrounding muscles.* **(Middle)** *Graphic shows transverse view of midforearm region. The intricate and quite constant arrangement of the muscles, nerves, and vessels of the midforearm is readily appreciated.* **(Bottom)** *Graphic provides transverse view at distal forearm level. One of the main muscles of the distal arm is the pronator quadratus muscle. This is 1 of the 2 muscles in the forearm that extend between the radius and ulna. When the pronator quadratus contracts, it pulls the lateral aspect of the radius volarly, helping to pronate the radius around the ulna at the distal radioulnar joint so that the palm faces downward. The counterpart of the pronator quadratus muscle is the supinator muscle, which lies in the proximal forearm.*

POSTERIOR ANATOMY OF FOREARM

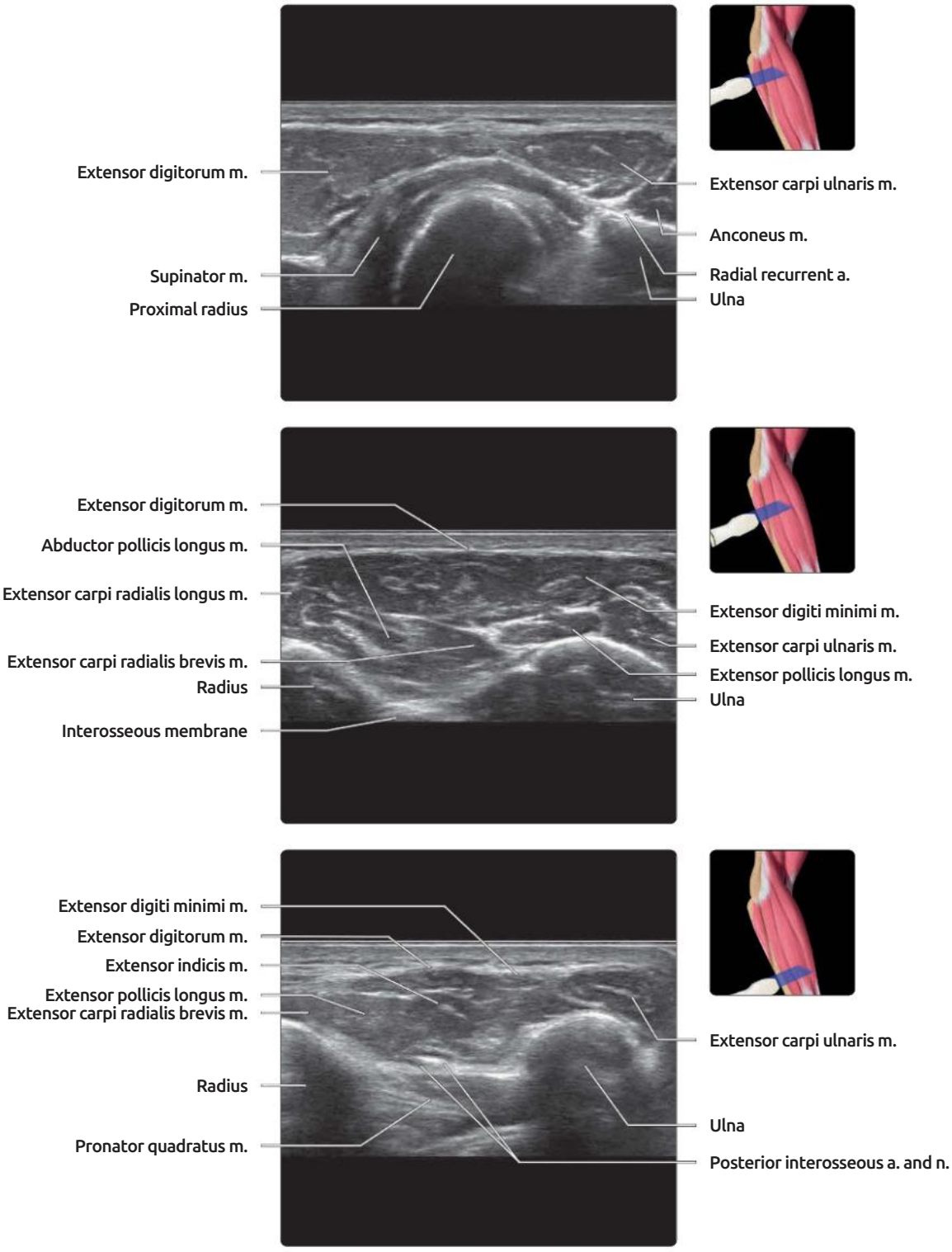

(Top) *Transverse US of the proximal forearm shows the supinator muscle originating from the ulna to extend around the neck and proximal shaft of the radius.* **(Middle)** *Transverse US shows the musculature of the posterior midforearm. Other than the posterior interosseous nerve, which runs with the posterior interosseous artery on the dorsal surface of the interosseous membrane, there are no main nerves on the extensor aspect of the forearm.* **(Bottom)** *Transverse US shows the musculature at the distal 1/3 of the forearm. The individual muscles can be identified, if necessary, by tracing, on transverse US scan, the tendon of any individual muscle proximally to the forearm from the wrist level.*

TERMINOLOGY

Abbreviations

- Triangular fibrocartilage complex (TFCC)
- Distal radioulnar joint (DRUJ)

Definitions

- Articulation is complex comprising distal radioulnar, radiocarpal, ulnocarpal, pisotriquetral, midcarpal, & carpometacarpal joints

IMAGING ANATOMY

Osseous Structures

- Distal radius: Lister tubercle on dorsal surface acts as fulcrum for action of extensor pollicis longus
- Distal ulna: Ulnar variance refers to length of ulnar head relative to distal radius
  - Ulnar negative (25%), ulnar positive (15%)
- Proximal carpal row: Scaphoid, lunate, triquetrum, pisiform
  - Scaphoid: Proximal & distal pole separated by waist
    - Tuberosity = volar prominence of distal pole
  - Lunate: 1/2 moon-shaped
  - Triquetrum: Triangular-shaped
  - Pisiform: Pea-shaped, sesamoid-type bone onto which flexor carpi ulnaris attaches, continuing distally as pisohamate & pisometacarpal ligaments
- Distal carpal row: Trapezium, trapezoid, capitate, hamate
  - Trapezium: Saddle-shaped bone linking carpus & thumb
  - Trapezoid: Wedge-shaped bone
  - Capitate: Head (proximal), neck (midportion), & body (bulky distal portion)
  - Hamate: Hook (hamulus) arises from palmar surface

Triangular Fibrocartilage Complex

- Between ulnar head & proximal carpal row
- Main components are fibrocartilage disc, styloid & foveal lamina, dorsal & styloid lamina
  - Also, meniscal homologue, ulnocarpal ligaments, & extensor carpi ulnaris subsheath
- Articular disc dissipates forces across ulnocarpal joint
  - Remaining components are main stabilizers of DRUJ

Ligaments

- Extrinsic (between radius or ulna & carpus or between nonopposing carpal bones); intrinsic (between carpal bones)
- Extrinsic ligaments: Volar is more structurally relevant than dorsal
- Intrinsic ligaments: Scapholunate & lunotriquetral are most important

Muscles & Tendons

- **Flexors, deep**
  - Flexor digitorum profundus: Ulnar shaft to index, middle, ring, & little finger distal phalangeal bases
  - Flexor pollicis longus: Radial shaft, interosseous membrane, & coronoid process ulna to distal phalangeal base of thumb
- **Flexors, superficial**
  - Flexor carpi radialis: Medial epicondyle to 2nd metacarpal base
  - Palmaris longus: Medial epicondyle to palmar aponeurosis
  - Flexor carpi ulnaris: Medial epicondyle & proximal ulna to pisiform
  - Flexor digitorum superficialis: Medial epicondyle, coronoid process ulna, & radius shaft to middle phalangeal bases of digits 2-5
- **Extensors, deep**
  - Abductor pollicis longus: Mid ulna to radial aspect of 1st metacarpal base
  - Extensor pollicis brevis: Mid radius to proximal phalangeal base of thumb
  - Extensor pollicis longus: Mid ulna to distal phalangeal base of thumb
  - Extensor indicis: Mid ulna to ulnar side of extensor digitorum tendon to 2nd digit of extensor hood
- **Extensors, superficial**
  - Extensor carpi radialis longus: Lateral supracondylar ridge humerus to 2nd metacarpal base
  - Extensor carpi radialis brevis: Lateral epicondyle to 3rd metacarpal base
  - Extensor digitorum: Lateral epicondyle to distal phalangeal bases of digits of 2-5
  - Extensor digiti minimi: Lateral epicondyle to extensor hood of little finger
  - Extensor carpi ulnaris: Lateral epicondyle to 5th metacarpal base

Retinacula

- **Flexor retinaculum (a.k.a. transverse carpal ligament)**
  - Attached to scaphoid & pisiform proximally; attached to trapezium & hook of hamate distally
- **Extensor retinaculum**
  - Attaches to ulnar styloid process, triquetrum medially; crosses obliquely to attach to Lister tubercle & radial styloid process laterally
    - Sends septa to radius, creating 6 separate compartments for extensor tendons
  - Extensor compartment contents
    - 1st: Abductor pollicis longus & extensor pollicis brevis
    - 2nd: Extensor carpi radialis longus & brevis
    - 3rd: Extensor pollicis longus
    - 4th: Extensor digitorum & extensor indicis
    - 5th: Extensor digiti minimi
    - 6th: Extensor carpi ulnaris

Anatomic Spaces

- **Carpal tunnel**
  - Margins: Carpal bones (deep margin), flexor retinaculum (superficial margin), pisiform & hook of hamate (ulnar margin), scaphoid & trapezium (radial margin), radiocarpal joint (proximal margin), & metacarpal base (distal margin)
    - Contents: Flexor digitorum superficialis (4 tendons), flexor digitorum profundus (4 tendons), flexor pollicis longus, median nerve
- **Guyon canal**
  - Margins: Fascial extension from flexor retinaculum, volar carpal ligament (volar margin), pisiform (ulnar margin), flexor retinaculum (radial & dorsal margins)
    - Contents: Ulnar artery & vein, ulnar nerve

CARPAL BONES & WRIST COMPARTMENTS

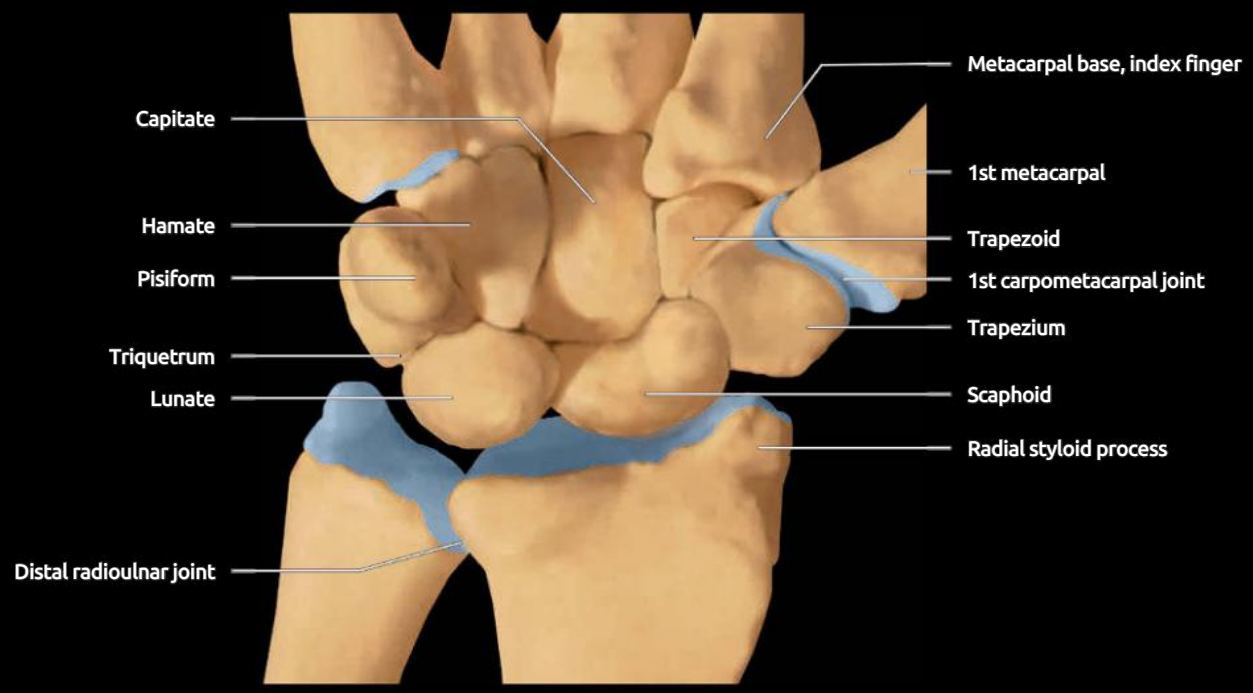

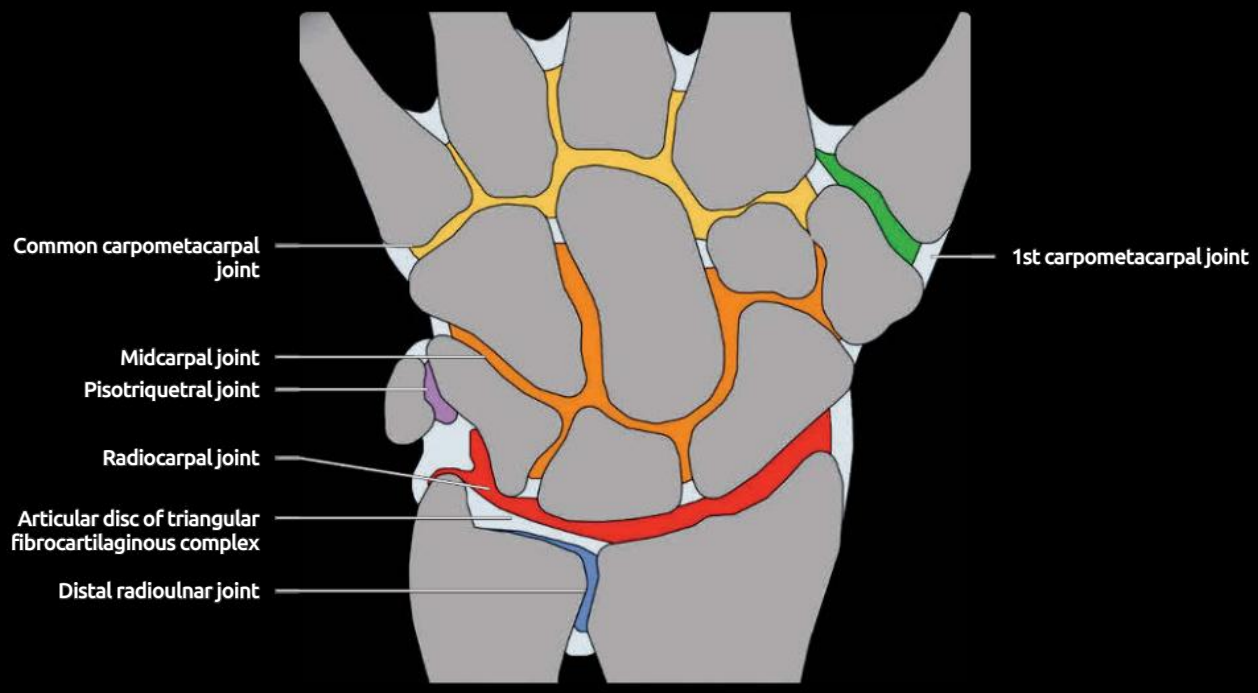

(Top) *Graphic shows the bones of the wrist joint. A useful mnemonic is "she looks too pretty, try to catch her" for the bones of the proximal & distal carpal rows, namely the scaphoid, lunate, triquetrum, pisiform, trapezium, trapezoid, capitate, & hamate bones.* **(Bottom)** *Graphic shows the 5 different wrist compartments. The distal radioulnar compartment (blue) is separated from the radiocarpal compartment (red) by the triangular fibrocartilage complex (TFCC). The pisotriquetral compartment (purple) is separated from the radiocarpal compartment in 20% of normal subjects. The midcarpal compartment (orange) is separated from the radiocarpal compartment by the scapholunate & lunotriquetral intrinsic ligaments & typically communicates with the carpometacarpal joints (yellow) of the fingers. The 1st carpometacarpal compartment (green) is separated from the common carpometacarpal compartment by the trapeziometacarpal ligament.*

DORSAL TENDONS & TENDON SHEATHS

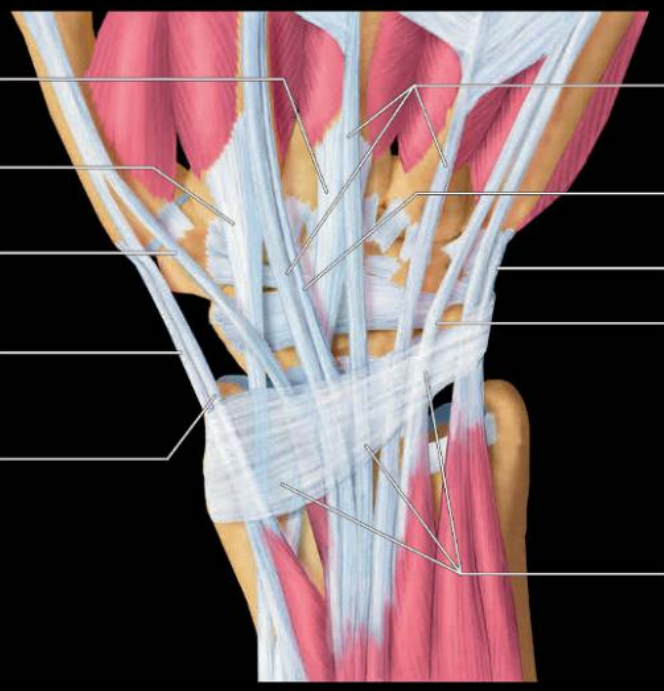

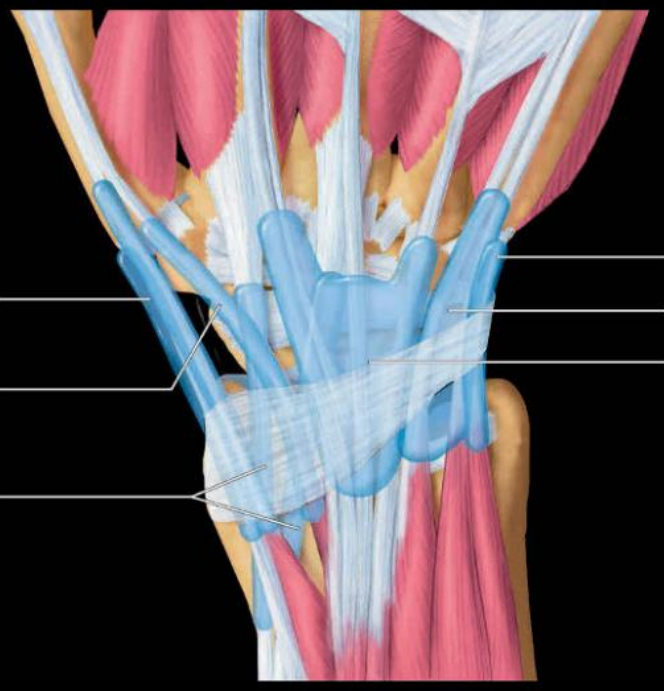

(Top) *The dorsal extensor tendons pass deep to the extensor retinaculum, which separates them into 6 compartments by fibrous attachments of the retinaculum to the underlying bones. One can appreciate how the 3rd extensor compartment with the extensor pollicis longus (EPL), passes dorsal to the 2nd compartment tendons, the extensor carpi radialis brevis & longus.* **(Bottom)** *Separate tendon sheaths individually enclose the dorsal extensor tendons in compartments 1-6. The tendon sheath of the 4th compartment, the extensor digitorum tendon, is easily the largest tendon sheath.*

TENDONS OF DORSAL & VOLAR WRIST

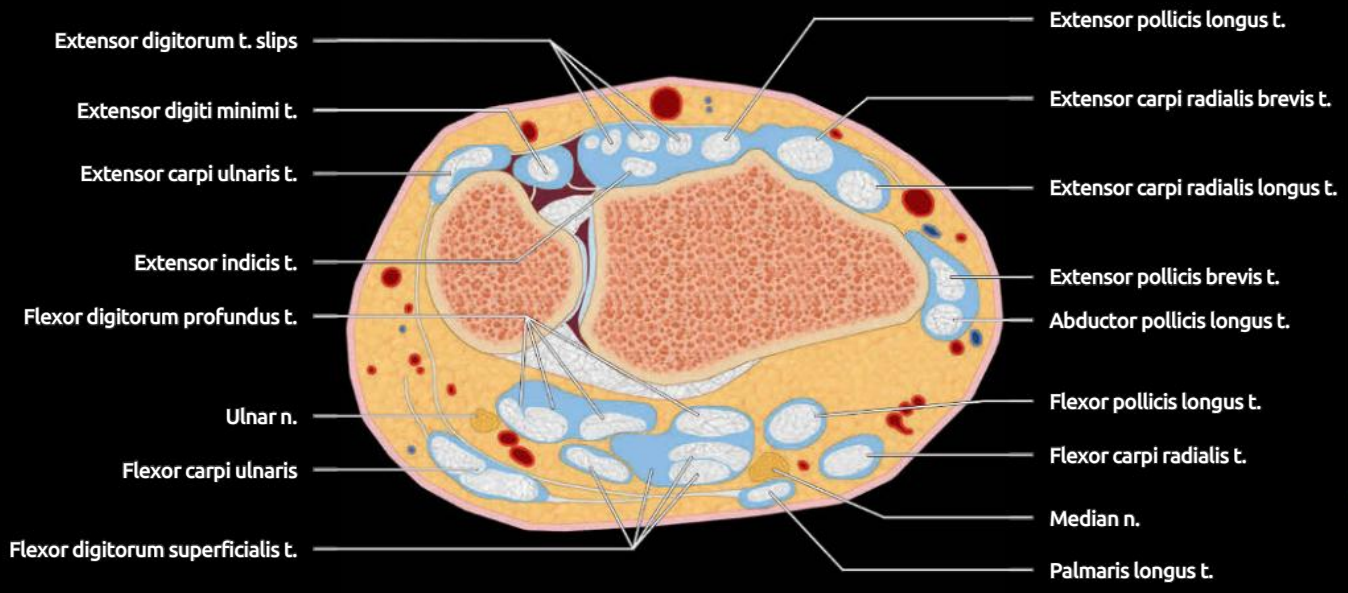

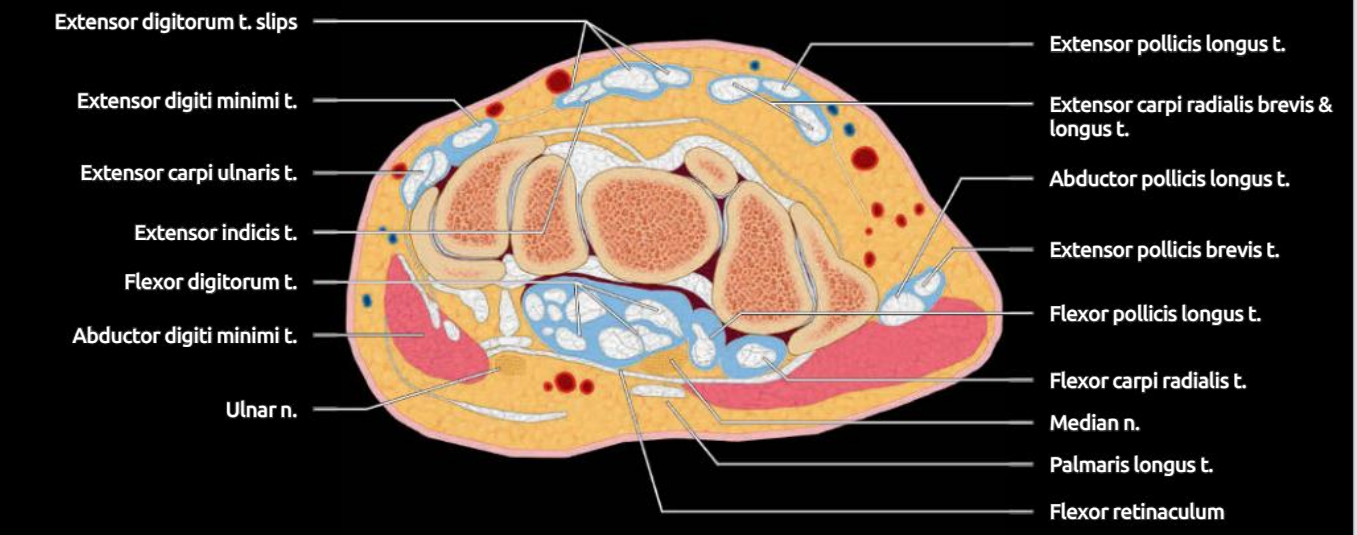

(Top) *Graphic shows the flexor & extensor tendons in the proximal wrist. Extensor tendons are deep to the extensor retinaculum, whereas the flexor tendons are proximal to the flexor retinaculum at this level in the wrist.* **(Bottom)** *Axial section though the level of the carpal tunnel is shown. The median nerve is slightly flattened as it passes deep to the flexor retinaculum & remains superficial to the flexor pollicis longus. The ulnar nerve, artery, & veins lie radial to the pisiform bone in Guyon canal where the ulnar nerve divides into deep & superficial branches.*

EXTENSOR COMPARTMENTS & CARPAL TUNNEL

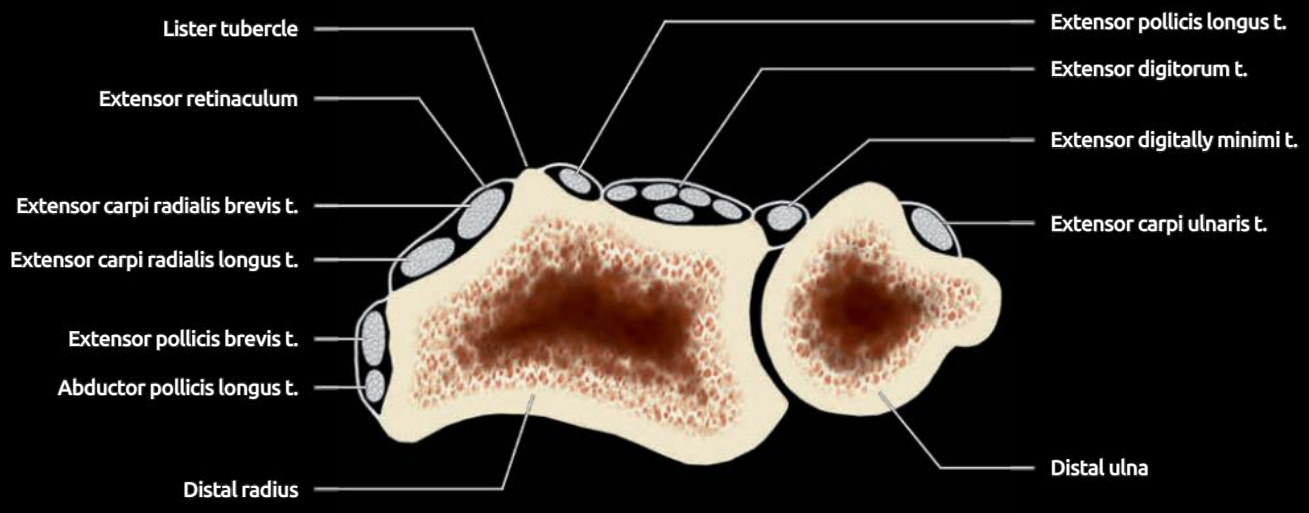

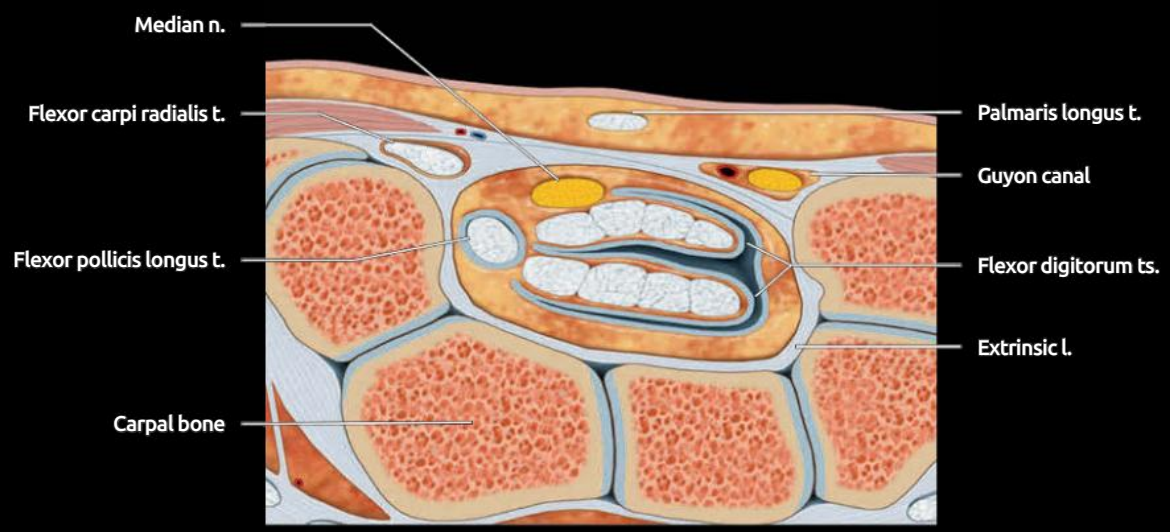

(Top) *Graphic shows the 6 extensor compartments on the dorsum of the wrist. Remember the position of the EPL tendon alongside Lister tubercle. This & the other tendons on the dorsoradial aspect of the wrist are conveniently arranged as longus-brevis-longus-brevis-longus.* **(Bottom)** *Graphic though the distal 1/2 of the carpal tunnel shows the median nerve immediately deep to the flexor retinaculum & superficial to the flexor pollicis longus & digitorum tendons. The flexor pollicis longus tendon is surrounded by the radial bursa. The digitorum tendons are surrounded by the ulnar bursa. The Guyon canal is outside the canal superficially on the ulnar side as is the flexor carpi radialis tendon on the radial side. The palmaris longus tendon lies outside the canal superficially. The flexor carpi ulnaris tendon, which is also outside the canal, is not shown. Neither the palmaris longus nor the flexor carpi ulnaris tendons have tendon sheaths.*

DORSUM WRIST

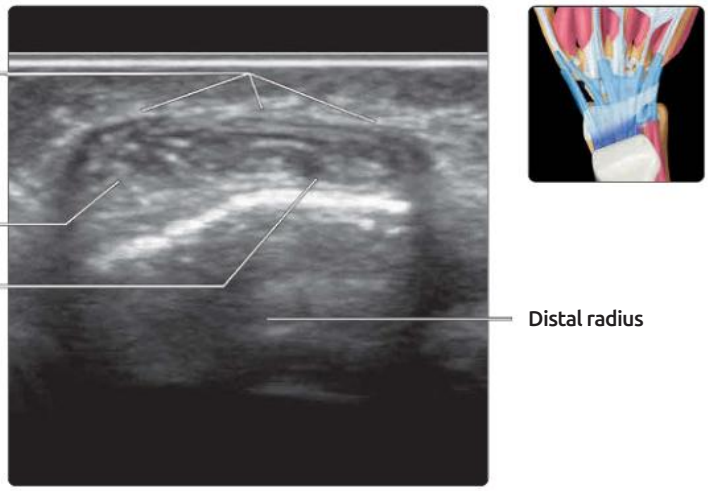

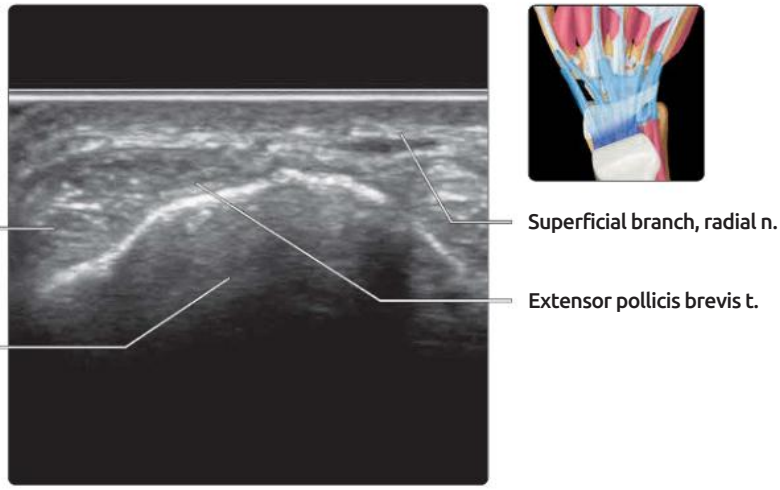

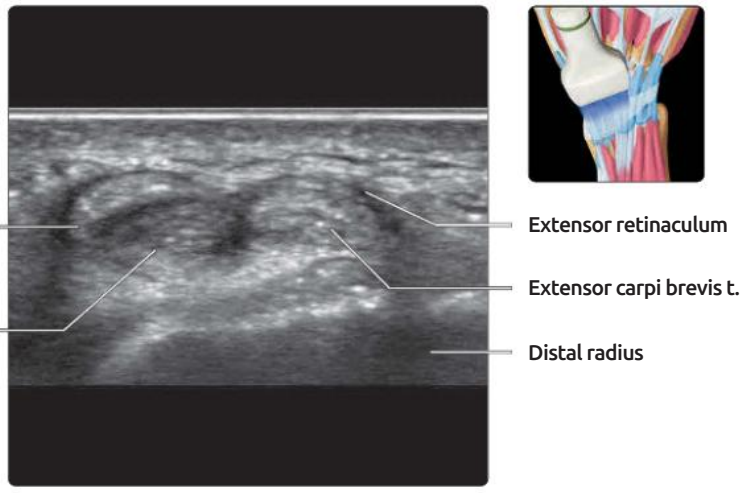

(Top) *Transverse US shows the 1st extensor compartment tendons on the radial aspect of the distal radius. These tendons are often closely applied, as shown here, though they can be separated by movement on real-time scanning. The thin extensor retinaculum can markedly thicken with de Quervain disease. A thin septum, not present here, separates both tendons in 30% of normal subjects & 70% of patients with de Quervain disease.* **(Middle)** *Transverse US shows the superficial branch of the radial nerve. More distally, branches of this nerve can transverse the 1st extensor compartment. This nerve is prone to iatrogenic injury from either injection around the 1st extensor compartment or cephalic vein cannulation.* **(Bottom)** *Transverse US of the radiodorsal aspect of the wrist shows the 2nd extensor compartment tendons, the extensor carpi radialis longus & brevis, being crossed by the 3rd extensor compartment tendon, the EPL tendon. The EPL passes superficial to the 2nd extensor compartment tendons from ulnar to radial. Uncommonly, this interplay may lead to tenosynovitis of these tendons, which is known as distal intersection syndrome.*

EXTENSOR COMPARTMENTS DORSUM OF WRIST

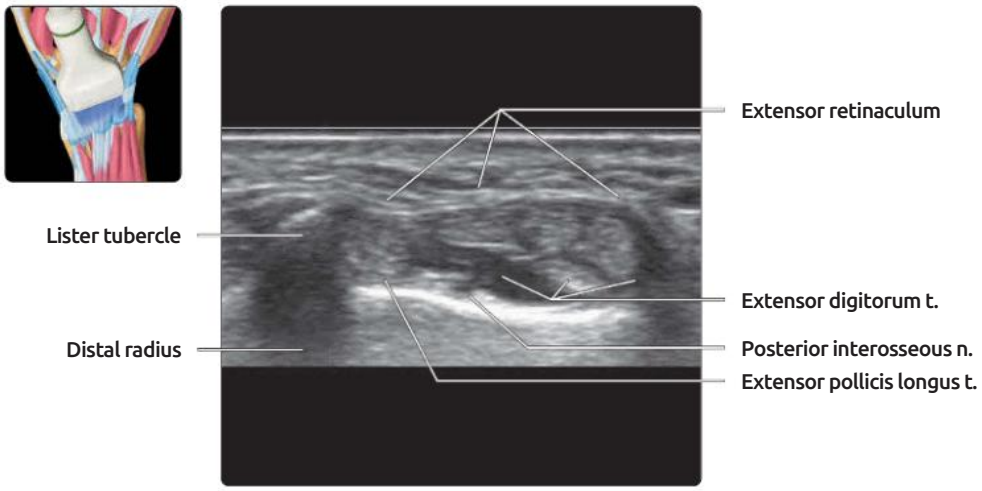

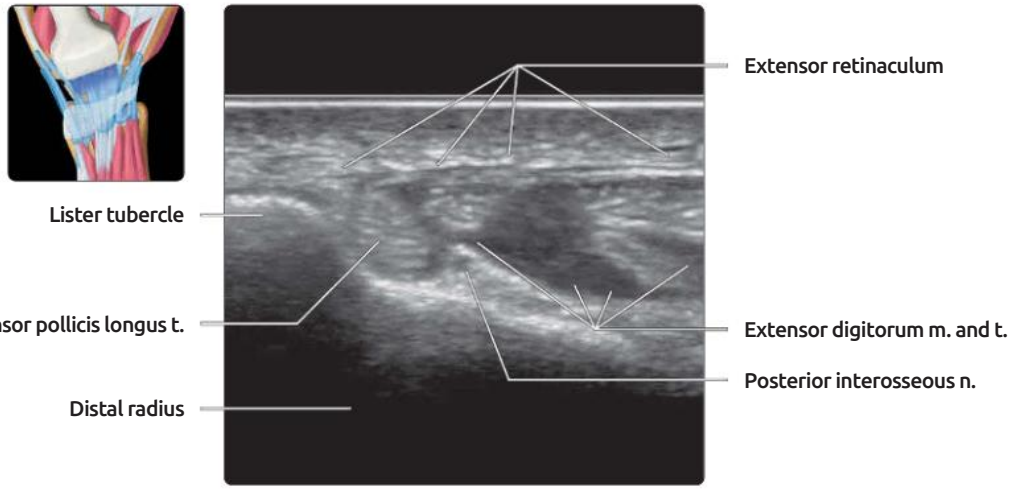

(Top) *Transverse US shows the 3rd & 4th extensor compartment at the level of the distal radius. The extensor digitorum muscle extends down to the wrist level. The Lister tubercle on the distal radius acts as a fulcrum for EPL tendon action to extend the thumb. The EPL is prone to spontaneous rupture as a result of this biomechanics & abrupt change in direction.* **(Middle)** *Transverse US of the interspace between the EPL tendon (3rd compartment) & extensor digitorum tendons (4th compartment) shows the posterior interosseous nerve located at the deeper part of this interspace. The posterior interosseous nerve enlarges slightly at this location before dividing into its terminal branches. This enlargement is sometimes referred to a pseudoganglion appearance.* **(Bottom)** *Transverse US shows the thick extensor retinaculum over the extensor digitorum tendons dorsal to the wrist joint. This should not be confused with tenosynovitis. The extensor retinaculum is a continuation of the deep investing fascia of the forearm. It is focally much thicker over the extensor digitorum tendons than the other extensor tendons.*

EXTENSOR COMPARTMENTS DORSOULNAR ASPECT WRIST

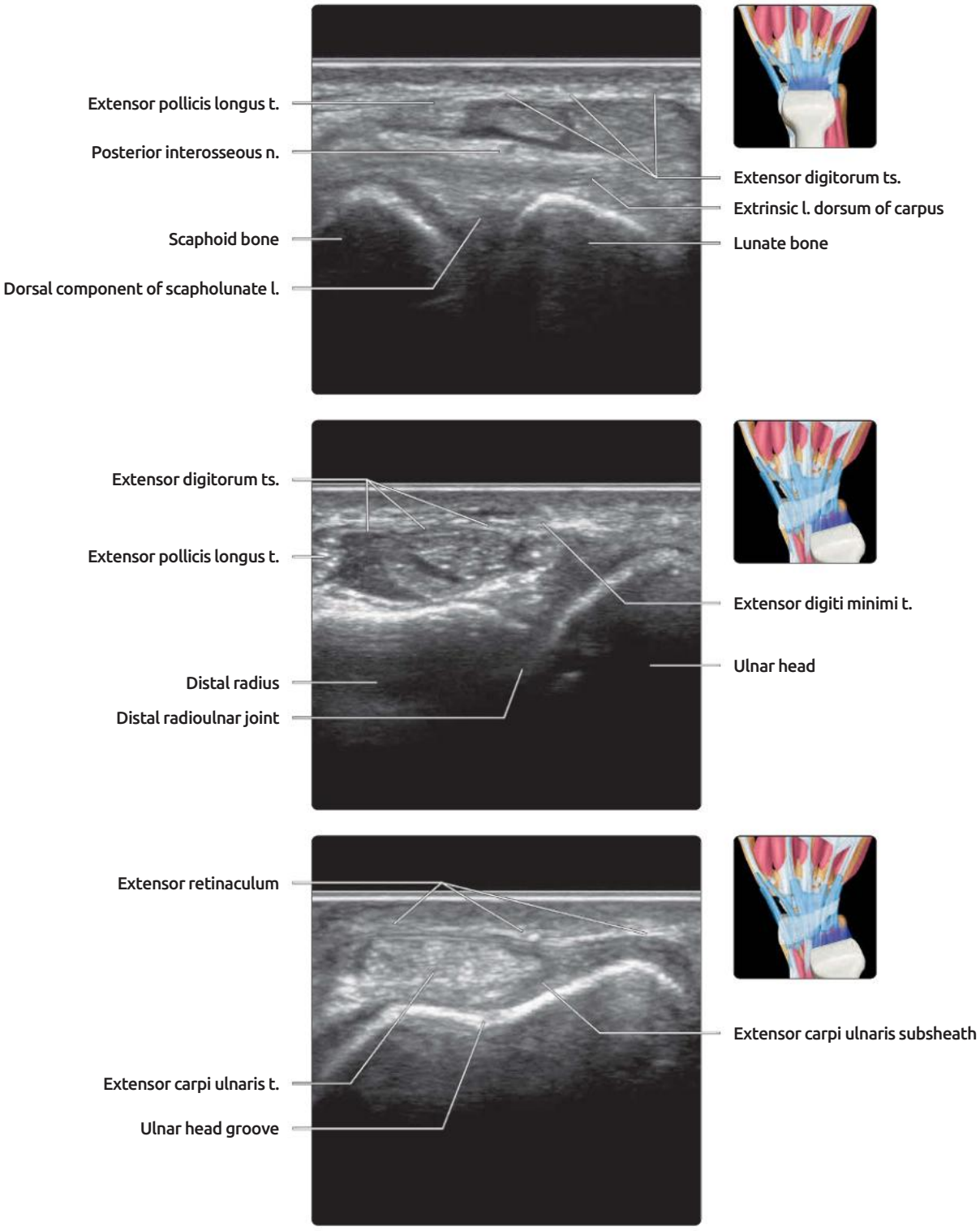

(Top) *Transverse US of dorsal aspect of the scapholunate interspace shows the close relationship between the scapholunate interval & the posterior interosseous nerve. Ganglia commonly arise through the dorsal aspect of the scapholunate interval & may impinge on the posterior interosseous nerve. The nerve should be avoided during needle puncture of the wrist joint.* **(Middle)** *Transverse US shows the 5th extensor compartment, which contains the extensor digiti minimi tendon, located dorsal to the distal radioulnar joint. This tendon joins the extensor digitorum tendon to the little finger just proximal to the metacarpophalangeal joint. As the radius rotates around the ulna during pronation & supination, stability & congruity of the distal radioulnar joint is critical to normal wrist rotation.* **(Bottom)** *Transverse US shows the 6th extensor compartment, which contains the extensor carpi ulnaris (ECU) tendon. The ECU tendon runs through a shallow groove on the ulnar head within the connective tissue sheath known as the ECU subsheath. The ECU tendon is constrained by the subsheath, but not by the extensor retinaculum, and it has a tendency to sublux & dislocate toward the ulnar side.*

DORSAL WRIST

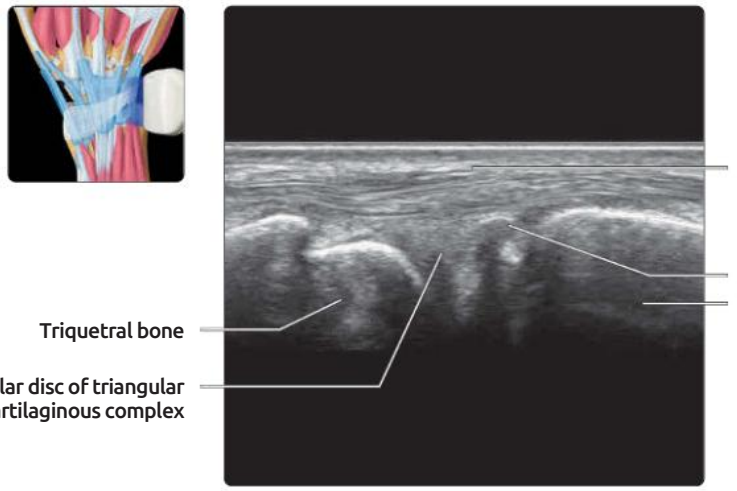

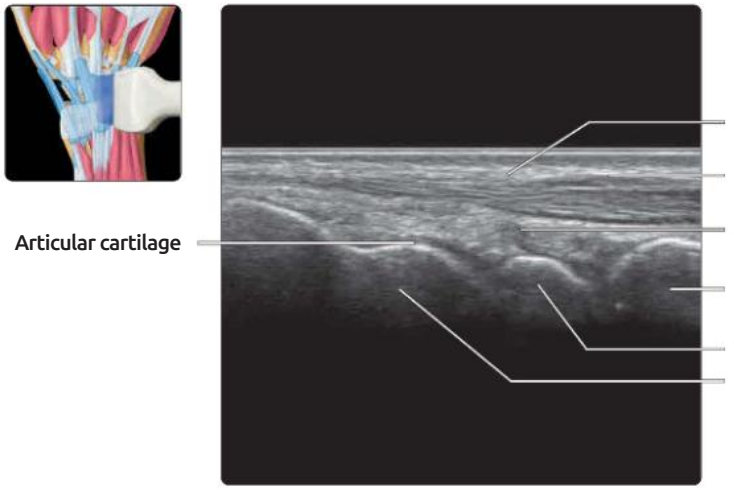

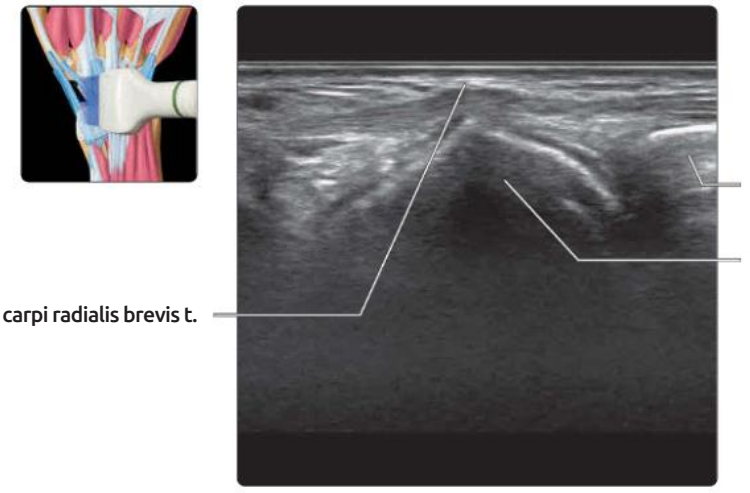

(Top) *Longitudinal US of the ulnar aspect of the wrist joint shows the ulnocarpal articulation. The TFCC area can be seen on US, though US is not accurate at identifying TFCC pathology, such as tears or degeneration.* **(Middle)** *Longitudinal US of the dorsum of the wrist shows the distal radius, lunate, & capitate bones aligned. The radiocarpal & intercarpal joint spaces extend distally & are barely discernible when no synovitis or joint fluid exists. The soft tissue on the dorsum of the carpus is composed of the extrinsic ligaments, the synovium & the periarticular fat. One should have a good awareness of the expected thickness of the soft tissues in this area. Swelling & hyperemia of the soft tissues in this area is a feature of synovitis. The thickened extensor retinaculum superficial to the extensor digitorum tendons is also shown.* **(Bottom)** *Longitudinal US of the radial aspect of the wrist shows the dorsal surface of the scaphoid bone. The close relationship between the extensor carpi radialis brevis tendon & the dorsal aspect of the scaphoid bone can be appreciated.*

VOLAR WRIST

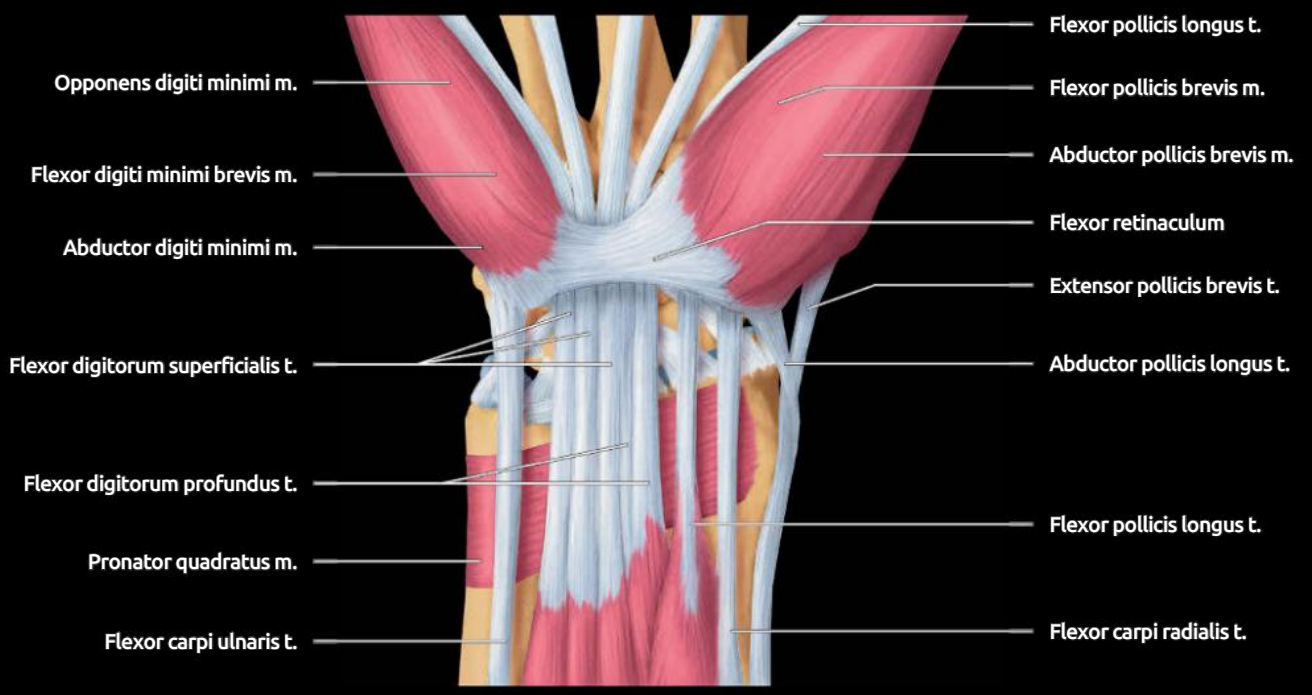

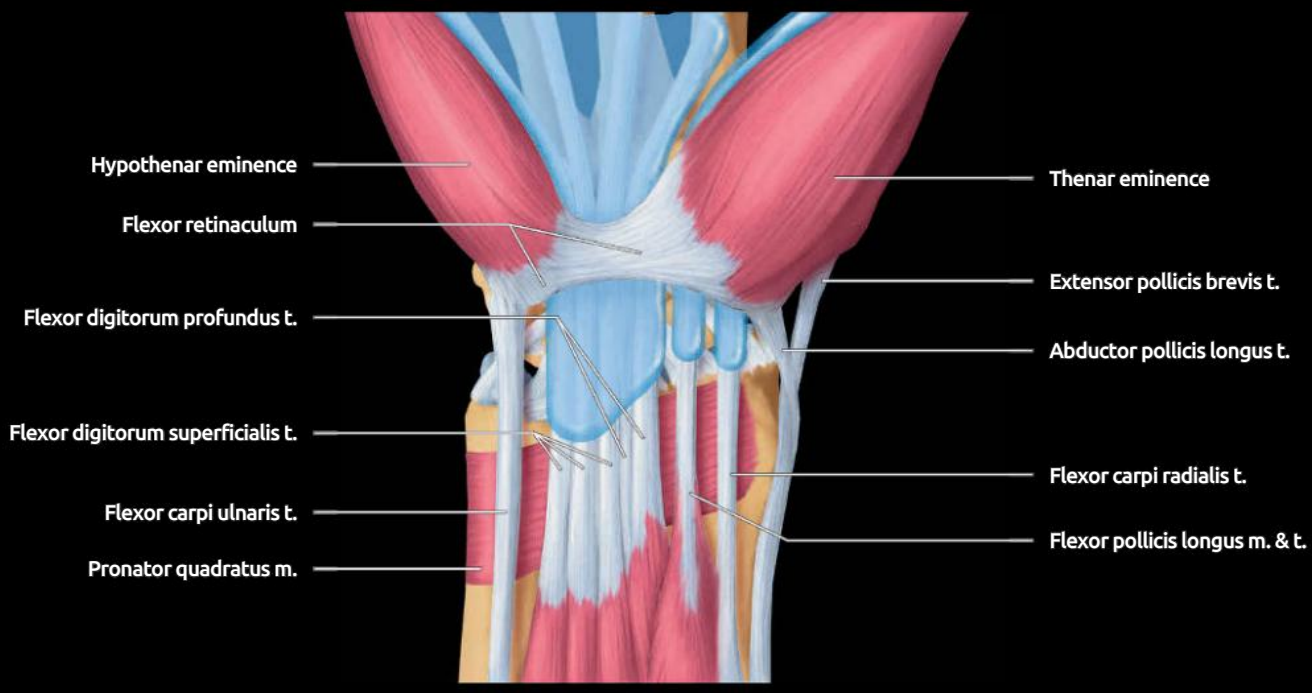

(Top) *Graphic shows the volar wrist muscles & tendons & the relationship to the flexor retinaculum. The thenar & hypothenar eminence muscles arise from the retinaculum. Flexor digitorum & flexor pollicis longus tendons pass deep to the retinaculum. On the radial side, the retinaculum splits to accommodate the flexor carpi radialis tendon.* **(Bottom)** *Graphic shows the volar wrist tendons & flexor retinaculum. The flexor retinaculum spans the palmar arch, attaching to the tubercle of the scaphoid, pisiform, hook of hamate, & ridge of the trapezium. The thenar eminence musculature includes the abductor pollicis brevis, opponens pollicis, flexor pollicis brevis, & adductor pollicis. The hypothenar eminence musculature includes the palmaris brevis, adductor digiti minimi, flexor digiti minimi brevis, & opponens digiti minimi.*

VOLAR WRIST

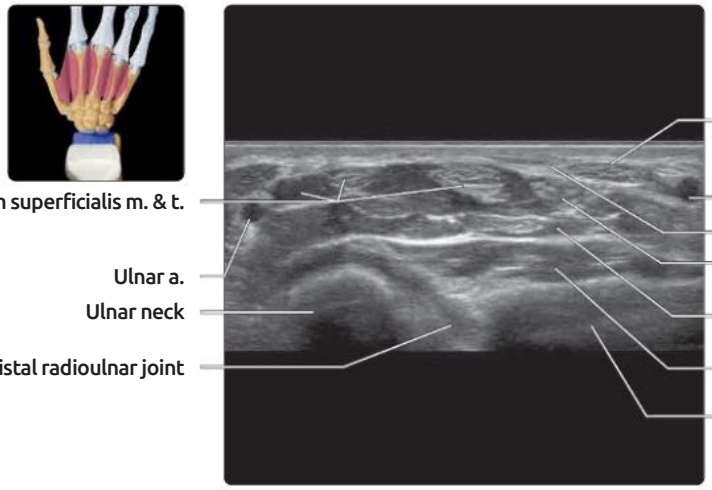

Extensor digitorum superficialis m. & t.
Ulnar a.
Ulnar neck
Distal radioulnar joint
Flexor carpi radialis t.
Radial a.
Palmaris longus t.
Median n.
Flexor digitorum profundus m.
Pronator quadratus m.
Distal radius

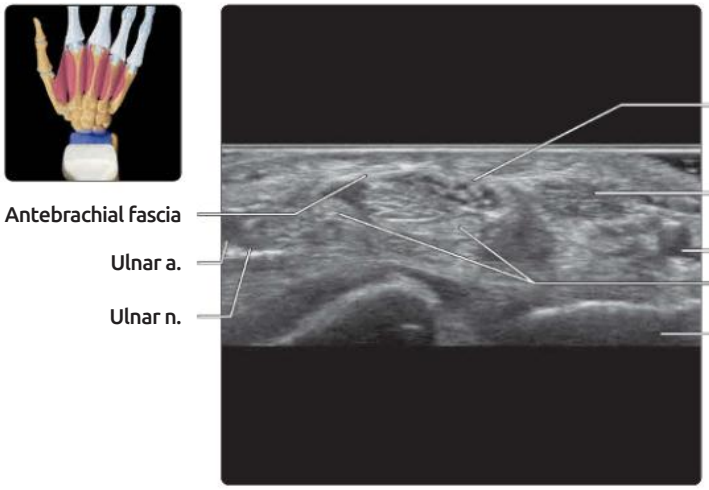

Antebrachial fascia
Ulnar a.
Ulnar n.
Median n.
Flexor carpi radialis t.
Radial a.
Flexor digitorum profundus t.
Distal radius

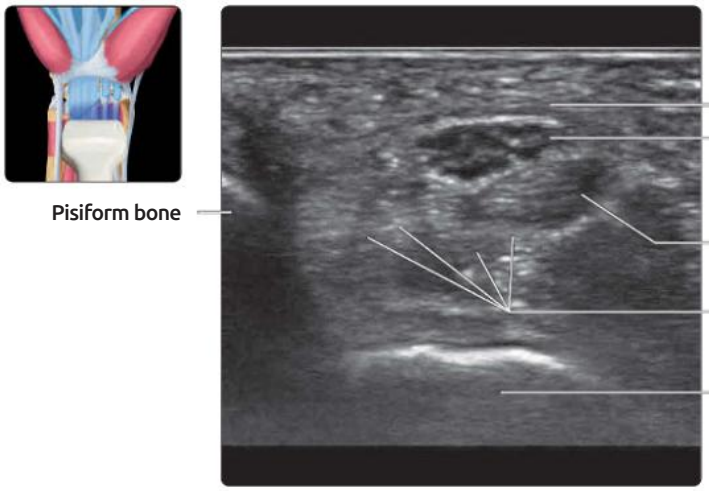

Pisiform bone
Antebrachial fascia
Median n.
Flexor pollicis longus t.
Long flexor tt.
Lunate bone

(Top) *Transverse US at the proximal end of the distal radioulnar joint is shown. The median nerve moves superficially from between the flexor digitorum superficialis & profundus muscles & tendons to lie deep to the investing fascia of the forearm, which is known as the antebrachial fascia.* **(Middle)** *Transverse US just proximal to the carpal tunnel is shown. The antebrachial fascia should not be mistaken for the thicker flexor retinaculum, which lies just distal to this level. The multifascicular configuration of the median nerve enables it to be distinguished from the surrounding flexor tendons.* **(Bottom)** *Transverse US shows a localized view of the median nerve at the distal end of the forearm just proximal to the carpal tunnel. The antebrachial fascia overlies the median nerve. The echogenic rim surrounding the nerve is the epineurium. This is not included in US measurements of nerve caliber. Only the hypoechoic nerve fascicles should be included.*

CARPAL TUNNEL

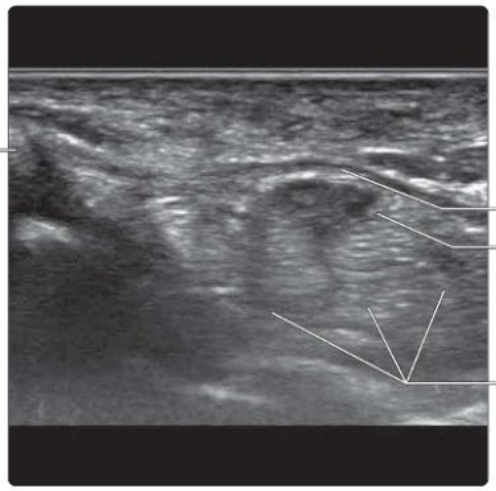

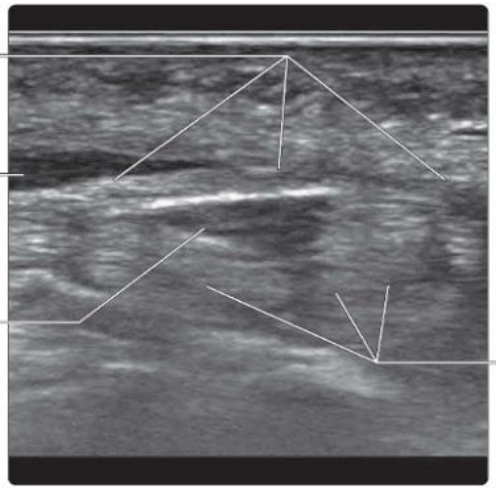

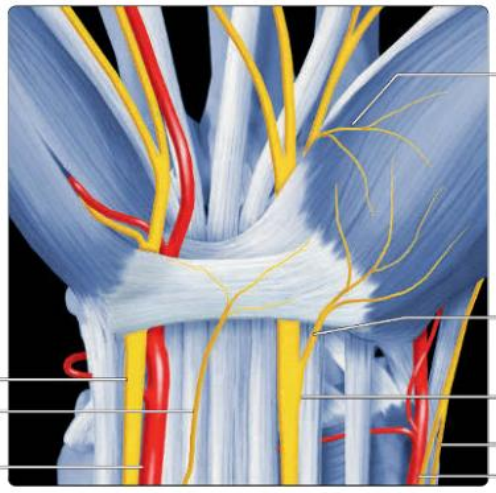

(Top) *Transverse US shows the carpal tunnel inlet. The proximal & distal borders of the carpal tunnel are accurately identified by recognizing the proximal & distal margins of the flexor retinaculum rather than by the bony attachments of the retinaculum to the carpus. The median nerve dips down to pass under the relatively thick flexor retinaculum. All of the long flexor tendons are closely applied within the carpal tunnel. Individual tendons can be identified by flexing & extending the respective fingers. The fascicular structure of the median nerve is often not seen within the carpal tunnel.* **(Middle)** *Transverse US at the tunnel outlet shows the median nerve deep to the flexor retinaculum. This is the narrowest part of the carpal tunnel. Compression of the median nerve usually occurs at the outlet or inlet rather than in the midportion of the tunnel. Anisotropy is used to identify the closely packed median nerve from the flexor tendons.* **(Bottom)** *Graphic shows the median & ulnar nerves as well as the small branches of these nerves in the distal forearm & wrist. The dorsal cutaneous branch of the ulnar nerve is not shown.*

TRIANGULAR FIBROCARTILAGE

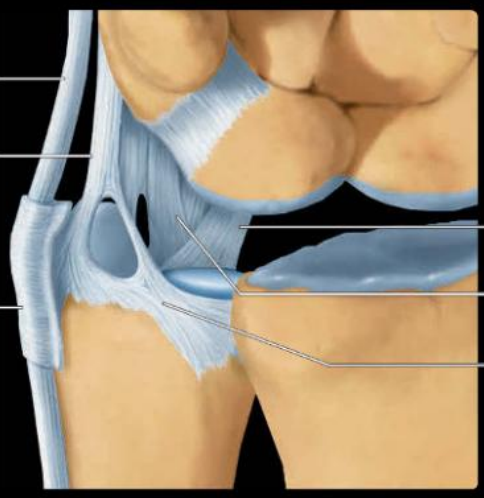

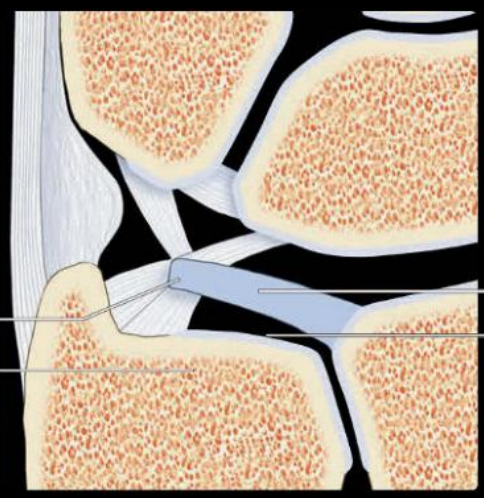

(Top) *Graphic shows supporting structures of the TFCC with the articular disc removed. These supporting structures are the volar ulnocarpal ligaments, volar & dorsal radioulnar ligaments, the ulnar collateral ligament, and the ECU tendon & its subsheath.* **(Middle)** *Graphic shows the articular disc of the TFCC. The triangular fibrocartilage or articular disc is a central component of the TFCC. The articular disc attaches to the ulna by the styloid & foveal lamina. It also attaches to the radial articular cartilage &, on the volar aspect, the lunate, & the triquetrum via the ulnotriquetral & ulnolunate ligaments.* **(Bottom)** *Longitudinal US of the TFCC during radial deviation of the wrist is shown. The individual components of the TFCC cannot be clearly delineated with US examination, though the general outline of the TFCC can be appreciated. The individual components of the TFCC are best identified on MR imaging.*

VOLAR & DORSAL LIGAMENTS

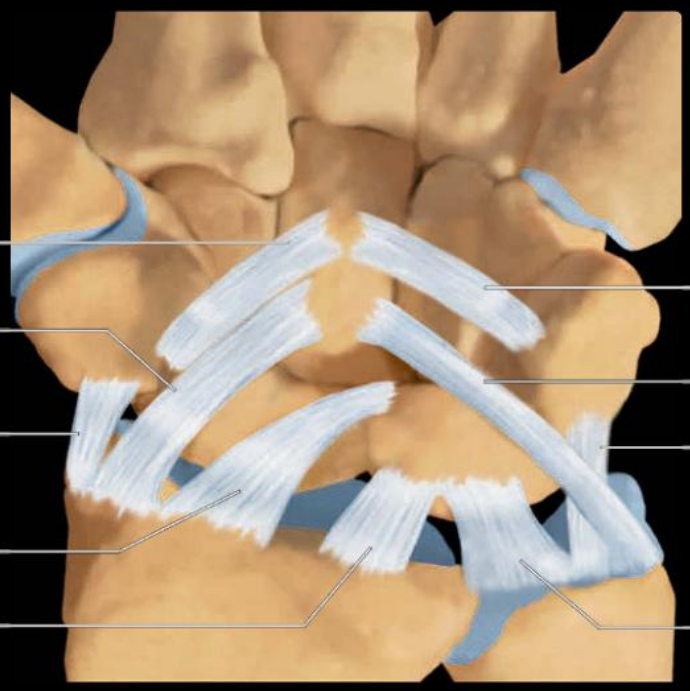

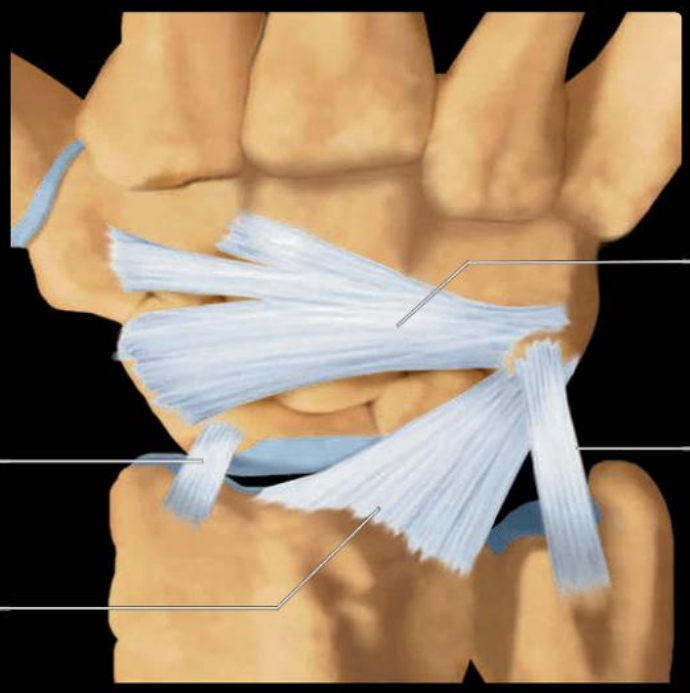

(Top) *Graphic shows the volar extrinsic wrist ligaments. The scaphocapitate ligament & triquetral-hamate-capitate make up the radial & volar components of the arcuate ligament, respectively.* **(Bottom)** *Graphic shows the dorsal extrinsic wrist ligaments.*

VOLAR WRIST

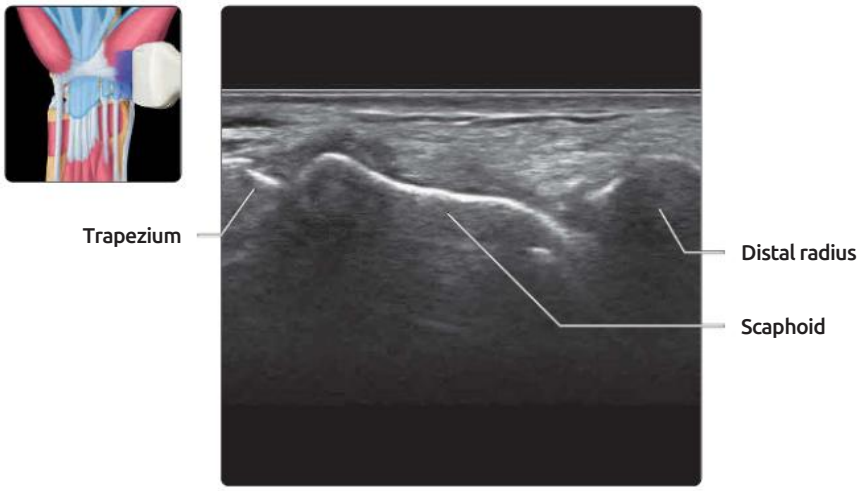

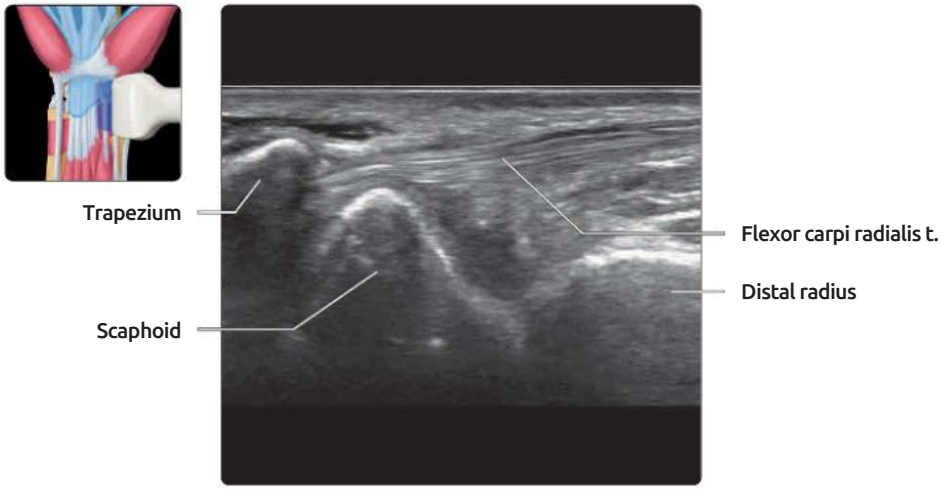

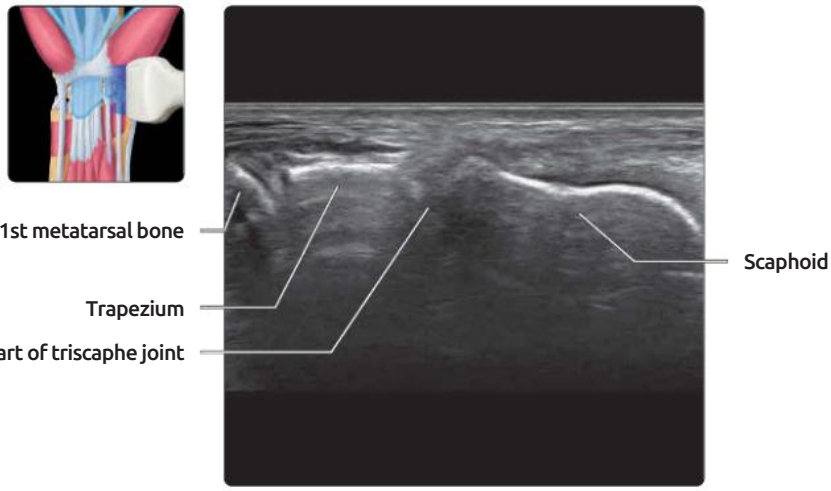

(Top) *Longitudinal US shows the long dorsal aspect of the scaphoid bone. US is a reasonably accurate means of detecting scaphoid bone fractures.* **(Middle)** *Longitudinal US shows the flexor carpi radialis tendon, which dips down over the distal pole of the scaphoid to be inserted into the base of the 2nd metatarsal bone. The distal part of the tendon is best seen with the wrist flexed, as shown here.* **(Bottom)** *Longitudinal US shows part of the triscaphe joint. The triscaphe joint is the articulation between the distal pole of the scaphoid, the trapezium, & the trapezoid. It is quite frequently affected by osteoarthritis & inflammatory arthritis.*

GUYON CANAL

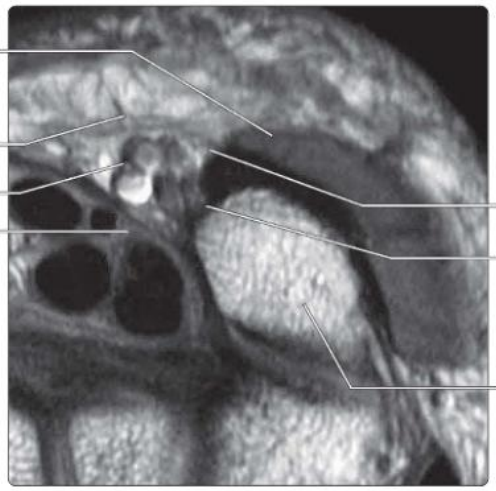

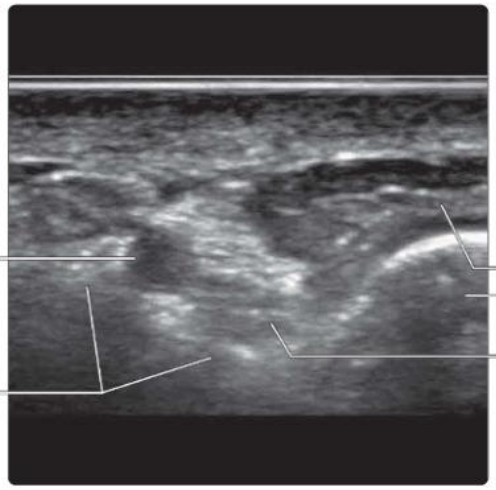

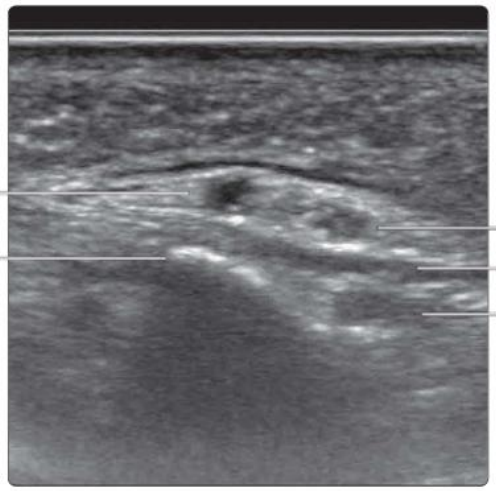

(Top) *Transverse proton density-weighted MR shows the Guyon canal. The relationship between the Guyon canal & the flexor retinaculum & carpal tunnel can be appreciated. The flexor carpi ulnaris tendon inserts into, while the abductor digiti minimi tendon arises from, the pisiform bone.* **(Middle)** *Transverse US shows the ulnar nerve within the Guyon canal bounded by the pisiform bone on the ulnar side & the flexor retinaculum on the radial side.* **(Bottom)** *Transverse US shows the superficial & deep branches of the ulnar nerve at the distal margin of the Guyon canal. The ulnar artery, as it passes superficial to the hook of hamate, can be injured by repetitive compressive trauma leading to arterial thrombosis or aneurysm (hypothenar hammer syndrome).*

MNEMONIC FOR MUSCLES OF THENAR & HYPOTHENAR EMINENCES

"All For One And"

- **A**bductor pollicis brevis (APB), **f**lexor pollicis brevis (FPB), **o**pponens pollicis (OP), **a**dductor pollicis
  - For thenar muscles, from superficial to deep

"One For All"

- **O**pponens digiti minimi (ODM), **f**lexor digiti minimi (FDM), **a**bductor digiti minimi (ADM)
  - For hypothenar muscles, from deep to superficial

THENAR EMINENCE

Abductor Pollicis Brevis, Flexor Pollicis Brevis, Opponens Pollicis

- Origin: Flexor retinaculum & tubercle of trapezium
- Insertion: APB & FPB have conjoint insertion of radial aspect of proximal phalangeal base embedding radial sesamoid bone
  - OP inserts onto volar aspect of 1st metacarpal shaft
- All innervated by median nerve except for deep belly of FPB, which is supplied by ulnar nerve

Adductor Pollicis Muscle

- Oblique (proximal) & transverse (distal) heads
- Origin: Capitate, trapezoid, 2nd & 3rd metacarpals
- Insertion: Ulnar aspect of base of proximal phalanx of thumb embedding lateral sesamoid bone
  - Also contributes fibers to extensor hood of thumb, which forms adductor aponeurosis
- Innervation: Ulnar nerve
- Actions: Adducts thumb toward 3rd digit & aids extension of interphalangeal (IP) joint
- Separated from thenar muscles by fascial plane & innervated by ulnar rather than median nerve

Scanning Technique

- Transducer at right angles to long axis of 1st metacarpal
  - Thenar muscles seen as 3 distinct layers around flexor pollicis longus (FPL) tendon
    - Superficial: APB on radial side & superficial belly of FPB on ulnar side
    - Intermediate: OP in same plane as FPL tendon
    - Deep: Deep belly of FPB & adductor pollicis muscle (AddP)

HYPOTHENAR EMINENCE

Opponens Digiti Minimi, Flexor Digiti Minimi, Abductor Digiti Minimi

- Origin: ADM from pisiform; FDM & ODM from flexor retinaculum & hook of hamate
- Insertion: ADM & FDM as conjoint insertion on ulnar aspect of base of proximal phalanx of little finger
  - ODM to proximal 2/3 of metacarpal shaft of little finger
- All innervated by ulnar nerve

Scanning Technique

- Transducer at right angles to long axis of 5th metacarpal
  - Superficial: ADM on ulnar side, FDM on radial side
  - Deep: ODM

OTHER INTRINSIC MUSCLES

Lumbricals

- Numbered 1-4 from radial to ulnar
- Origin: Flexor digitorum profundus tendons index to little fingers
- Insertion: Radial lateral bands of digits 2-5
  - Flex metacarpophalangeal (MCP) joints & extend IP joints
- Innervation: Most radial 2 lumbricals by median nerve, most ulnar 2 lumbricals by ulnar nerve

Palmar Interossei

- Numbered 1-3 from radial to ulnar
- Origin: Diaphysis of 2nd, 4th, & 5th metacarpals
  - Originate from side of metacarpal facing midline
- Insertion: Radial lateral bands & proximal phalangeal bases of digits 2,4, & 5
- Innervation: Ulnar nerve
- Actions: Adducts digits 2,4, & 5
  - Flexes MCP joints & extends IP joints

Palmaris Brevis

- Small trapezoidal muscle within subcutaneous tissue over hypothenar eminence
  - Extends from flexor retinaculum to hypothenar skin
  - Deepens hollow of palm by accentuating hypothenar eminence

Dorsal Interossei

- Numbered 1-4 from radial to ulnar
- Origin: Diaphysis of 2nd, 4th, & 5th metacarpals
- Insertion: Lateral bands & proximal phalangeal bases 2-4
- Innervation: Ulnar nerve
- Actions: Abducts digits 2-4
  - Flexes MCP joints & extends IP joints

TENDONS

Tendon Sheaths

- Common flexor sheath (a.k.a. ulnar bursa)
  - Contains flexor digitorum superficialis & profundus tendons
  - Begins just proximal to carpal tunnel
  - Ends just beyond carpal tunnel for digits 2-4
  - Encloses 5th digit flexor tendons over entire course to distal IP joint
- FPL tendon sheath (a.k.a. radial bursa)
  - Encloses FPL tendon from just proximal to carpal tunnel to tendon insertion at base of distal phalanx thumb
  - ± communication with ulnar bursa at level of carpal tunnel in 50% of normal population
    - Potential route for spread of infection
- Individual flexor digital sheaths (digits 2-4)
  - Encloses flexor tendons from level of metacarpal necks to bases of distal phalanges

Extensor Expansion (or Extensor Hood)

- Expansions of extensor tendons on dorsum of fingers
  - Help prevent lateral translation of tendons
  - Lumbricals, palmar & dorsal interossei insert into lateral bands

PALMAR ASPECT OF HAND

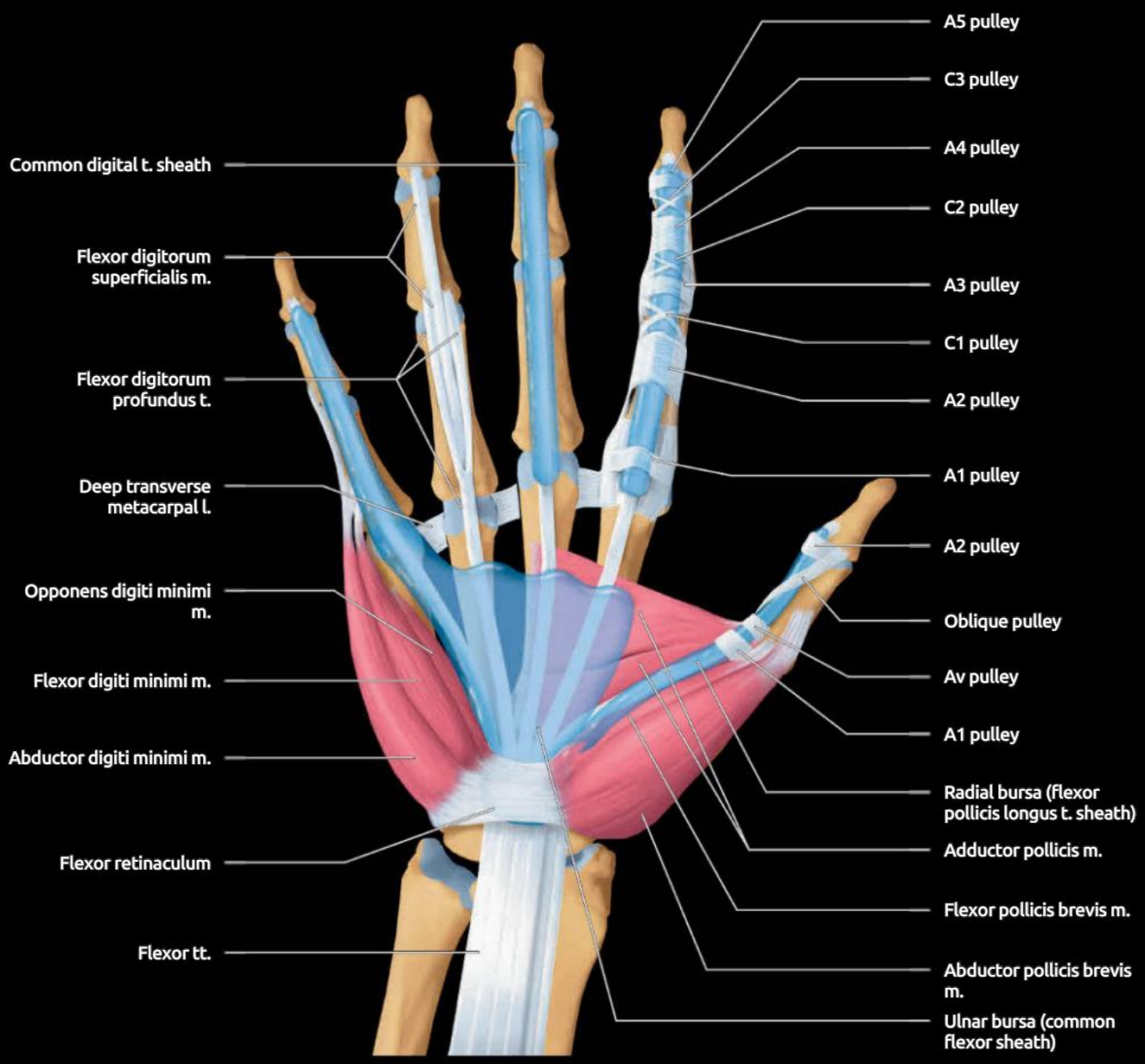

The pulley system for the 3rd-5th digits is identical to that demonstrated for the 2nd digit. The common digital sheath of the 4th digit is removed in this graphic to show the relationship of the flexor digitorum superficialis (FDS) and the flexor digitorum profundus (FDP) tendons. Deep transverse metacarpal ligaments connect the volar plates (not shown) of digits 2-5. Although there is overlap of the radial and ulnar bursae in this image, these structures normally do not invariably communicate. The radial and ulnar bursae may communicate as a normal variation in ~ 50% of the population. Similarly, any 1 or more of the common digital sheaths may communicate with the ulnar bursa in up to 10% of the normal population. These different bursal communications are important as they provide routes for more extensive spread of infection.

DORSAL ASPECT OF HAND

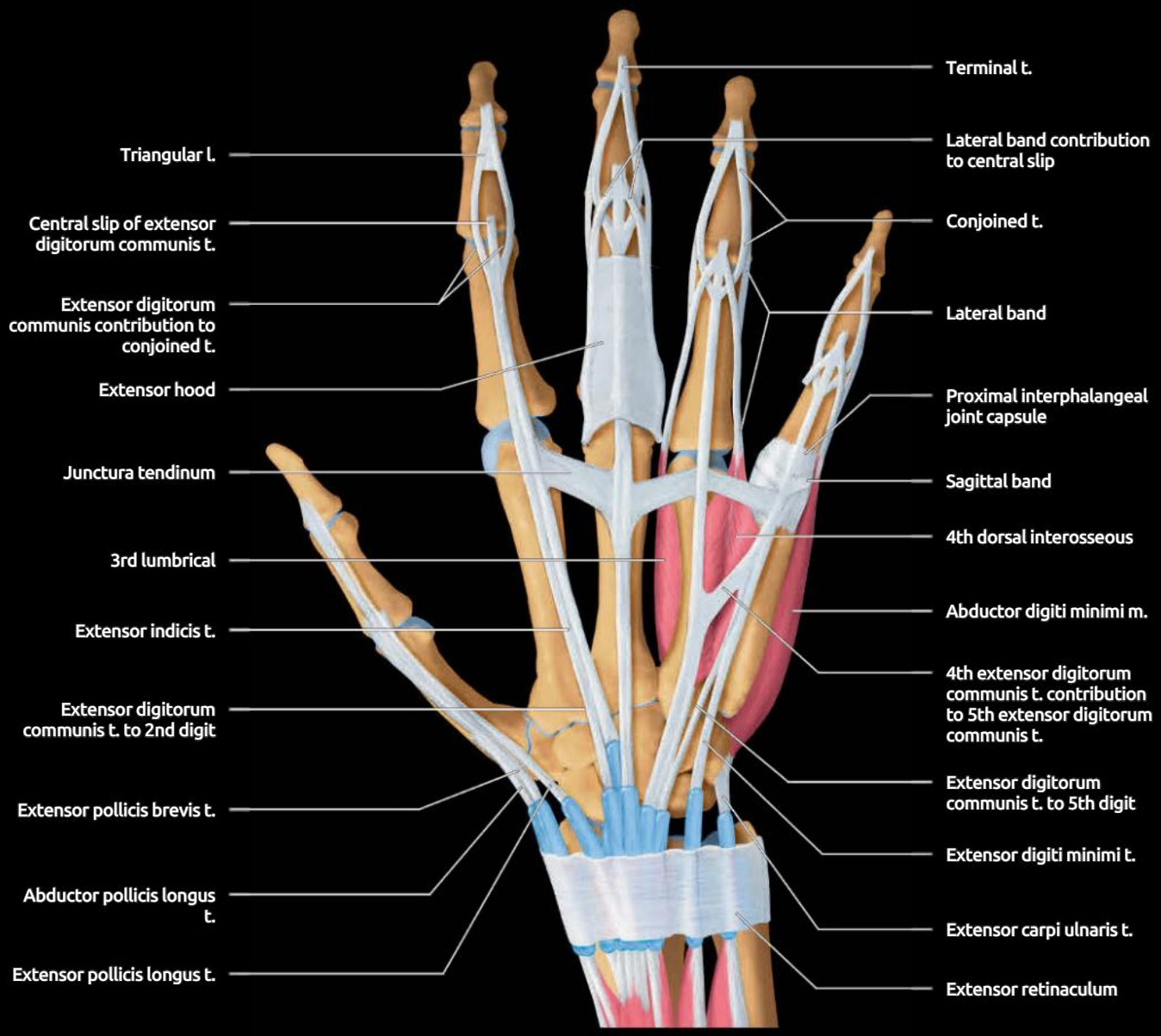

The extensor mechanism composite shows different components of the extensor mechanism on different digits. With the exception of the extensor indicis, extensor digiti minimi, abductor digiti minimi (ADM), and 4th extensor digitorum communis (EDC) tendon contribution to the 5th EDC tendon, any structure on any of the 2nd-5th digits can be extrapolated to any and all of the other 2nd-5th digits. Note that the 2nd extensor retinaculum compartment and its contents (extensor carpi radialis longus and brevis tendons) are not included in this graphic. Although the abductor pollicis longus tendon travels in the 1st compartment of the extensor retinaculum, its insertion (not shown) is actually on the radial aspect of the volar surface of the base of the 1st metacarpal.

PALM

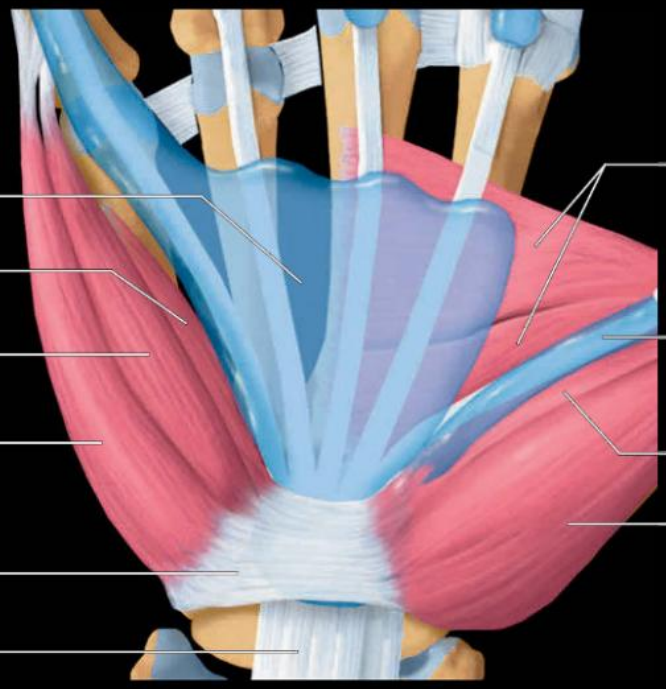

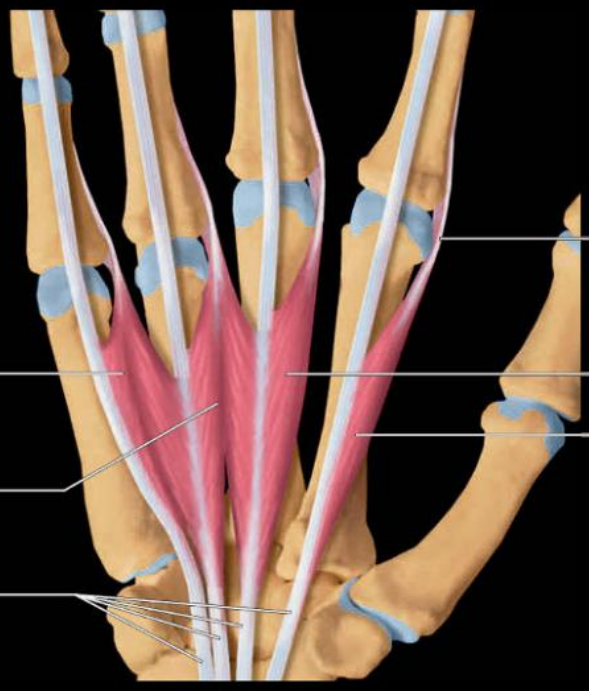

(Top) *Graphic shows the radial and ulnar bursae, which may communicate normally in 50% of the population. Any 1 or more of the common digital sheaths may communicate with the ulnar bursa in 10% of the population. Bursal communication is relevant as it provides a route for a more extensive spread of a tenosynovial infection.* **(Bottom)** *Graphic shows the lumbrical muscles that originate from the FDP tendons. The 1st and 2nd lumbricals are unipennate, whereas the 3rd and 4th lumbricals are bipennate. All of the lumbrical tendons insert on the radial aspect of their respective phalangeal bases.*

PALM MUSCLES

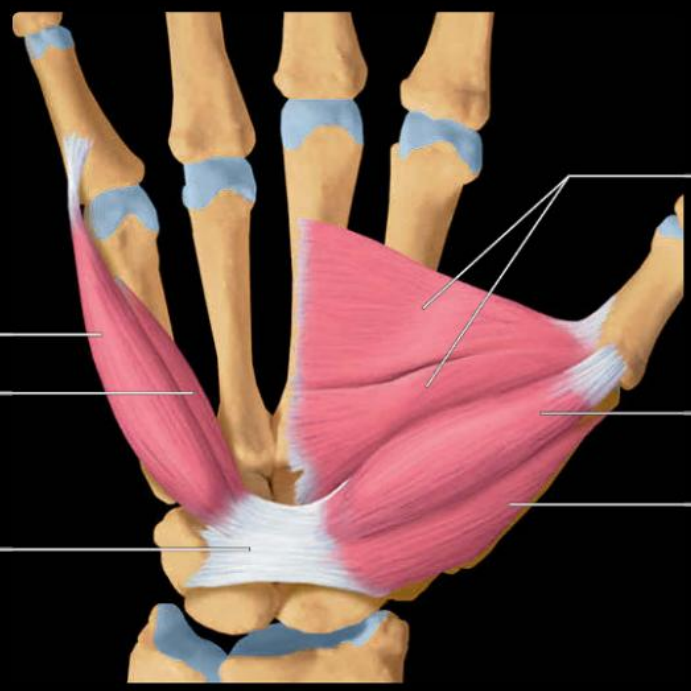

(Top) *Graphic shows the palmar interossei muscles. The palmar interossei adduct (PAD) the fingers, as well as flex the metacarpophalangeal (MCP) joints, and, by virtue of their attachment to the lateral bands, extend the proximal and distal interphalangeal joints. There is no palmar interosseus muscle attached to, or acting on, the middle finger.* **(Bottom)** *Graphic shows the superficial muscles of the thenar and hypothenar eminences as well as the abductor pollicis muscle, which is deeply located.*

PALM

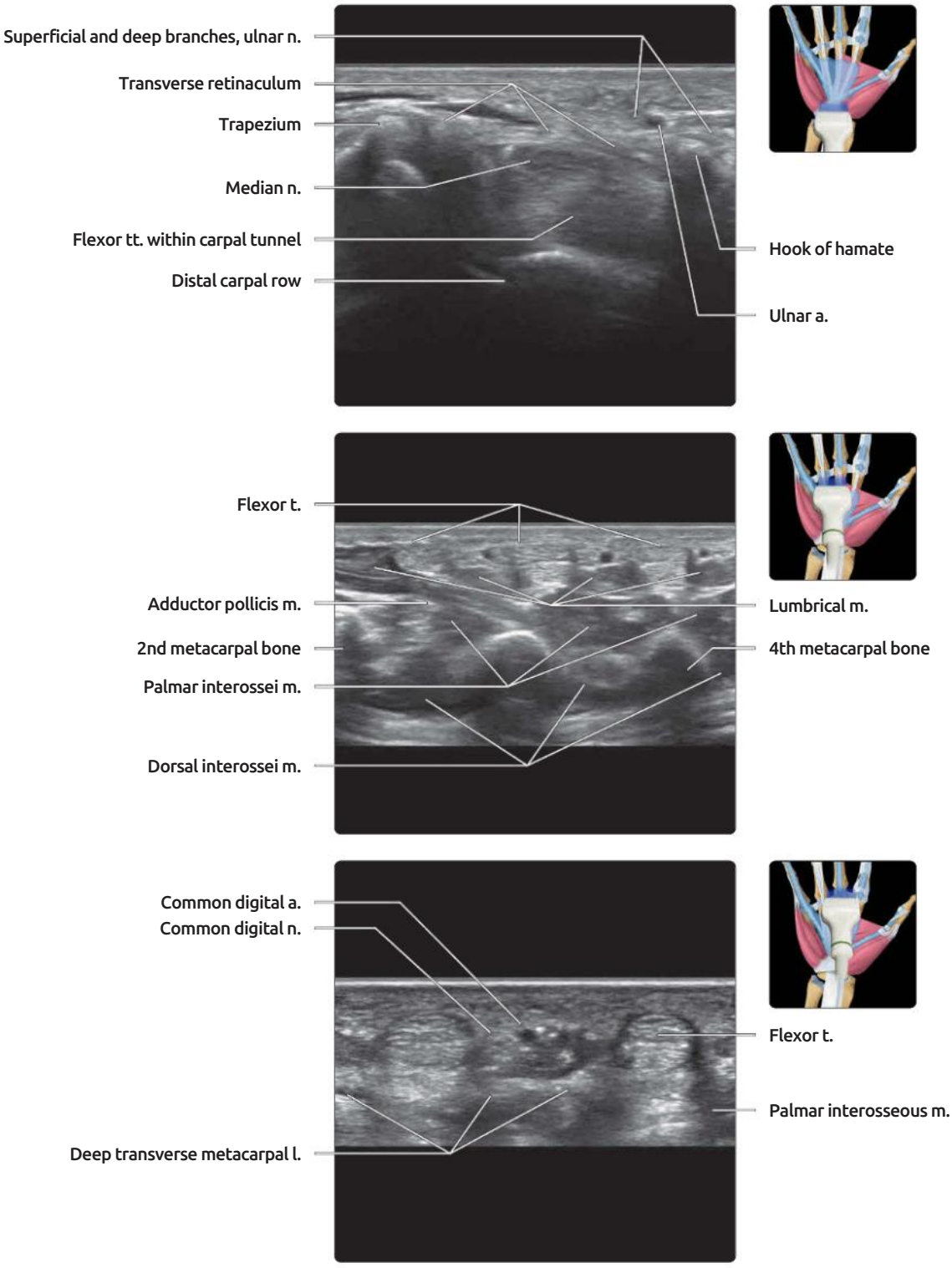

(Top) *Transverse US shows the carpal tunnel outlet. The narrowest part of the carpal tunnel is the tunnel outlet. Constriction of the median nerve at this level is usually seen as undue swelling of the median nerve immediately distal to the carpal tunnel outlet.* **(Middle)** *Transverse US of the midpalm shows the lumbrical muscles attach to the radial sides of the flexor tendons. The palmar interossei between the 3rd and 4th metacarpal bones and the 4th and 5th metacarpal bones are more prominent than the other palmar interossei. The adductor pollicis muscle intervenes between the lumbrical and palmar interosseous muscles.* **(Bottom)** *Transverse US at distal aspect of palm shows the deep transverse metacarpal ligament connecting the volar plates of the MCP joints. The lumbrical muscles are superficial to, and the palmar interossei muscles are deep to, the deep transverse metacarpal ligament.*

THENAR EMINENCE

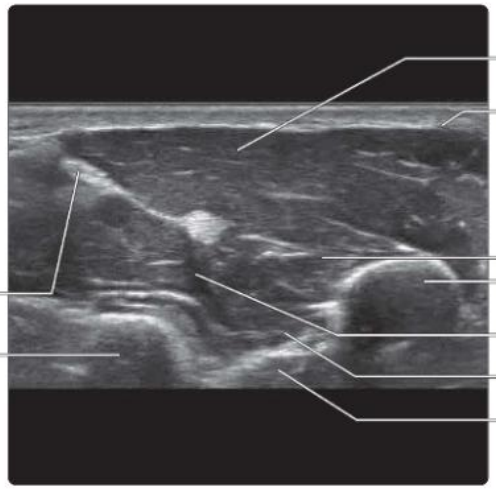

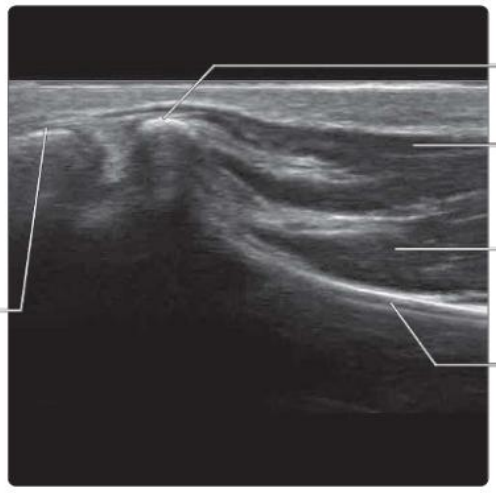

(Top) *Transverse US of the radial aspect of the palm shows the transverse head of the abductor pollicis muscle. The transverse and oblique heads of the abductor pollicis muscle converge to insert onto the ulnar aspect of the proximal phalangeal base of the thumb, embedding the medial sesamoid bone. Some fibers from the oblique head also insert into the extensor hood of the thumb.* **(Middle)** *Transverse US shows the thenar muscles. The abductor pollicis brevis (APB) is a small, flat muscle located superficially and radially. The flexor pollicis brevis (FPB) muscle is also superficial and located on the ulnar side of the APB. The opponens pollicis (OP) is a small, triangular muscle lying deep to the APB at the same level as the flexor pollicis longus (FPL) tendon. The deep belly of the FPB lies below the FPL tendon on a fairly similar level to the adductor pollicis (AddP) muscle.* **(Bottom)** *Longitudinal US shows the superficial and deep bellies of the FPB inserting into the radial of the proximal phalangeal base and embedding the radial sesamoid bone.*

HYPOTHENAR EMINENCE

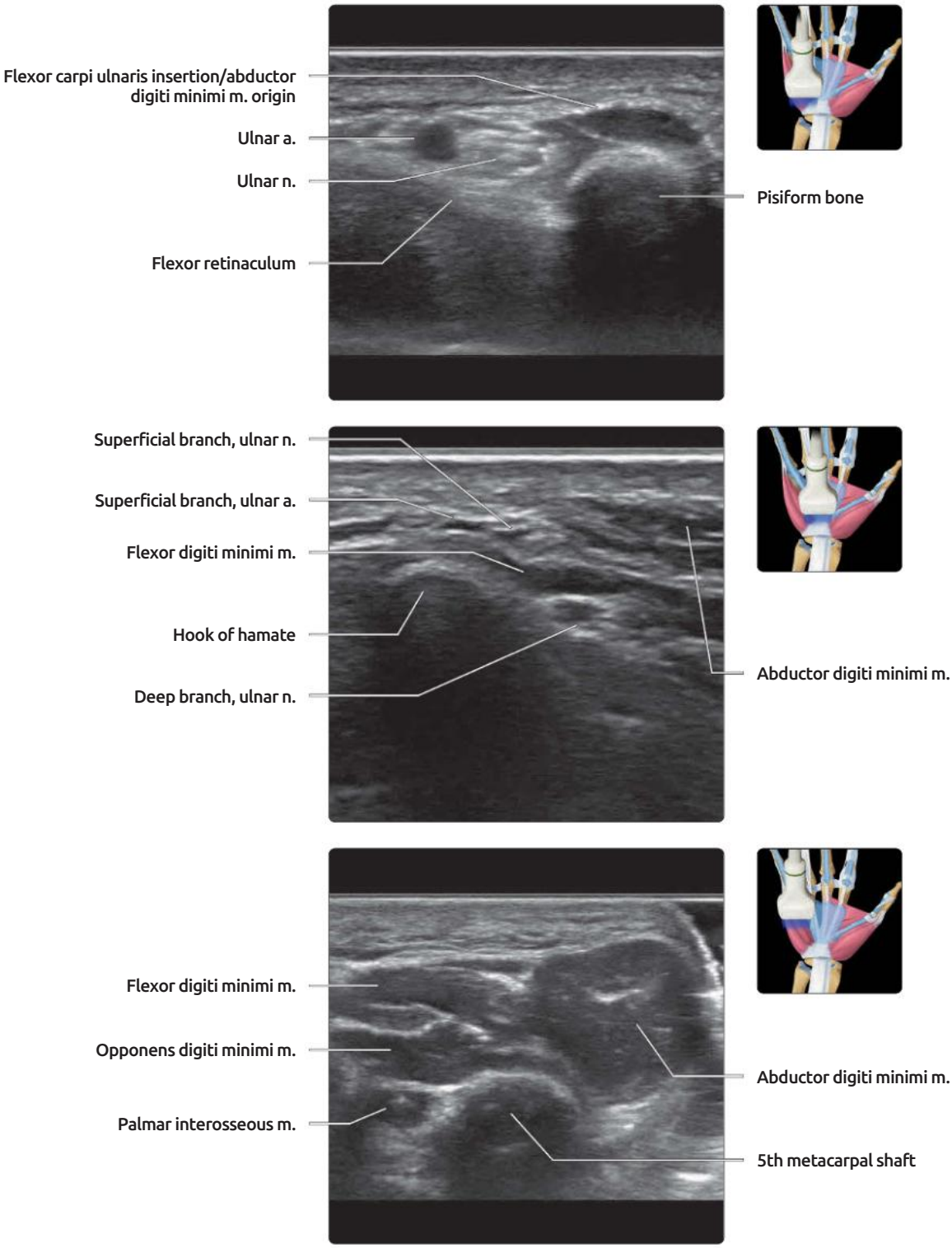

(Top) *Transverse US shows the pisiform bone and Guyon canal. The flexor carpi ulnaris tendon inserts into the pisiform bone, which also provides the origin for the ADM muscle of the hypothenar eminence.* **(Middle)** *Transverse US at the hook of hamate shows the flexor digiti minimi (FDM) muscle interposed between the superficial and deep branches of the ulnar nerve. The FDM muscle originates from the hook of hamate. Both the superficial branch of the ulnar artery and nerve pass over the hook of hamate and can be injured in hypothenar hammer syndrome.* **(Bottom)** *Transverse US shows the 3 muscles of the hypothenar eminence, namely the ADM muscle on the ulnar border, the FDM muscle on the radial aspect of the ADM, and the opponens digiti minimi (ODM) muscle deep to the ADM and FDM.*

DORSUM HAND

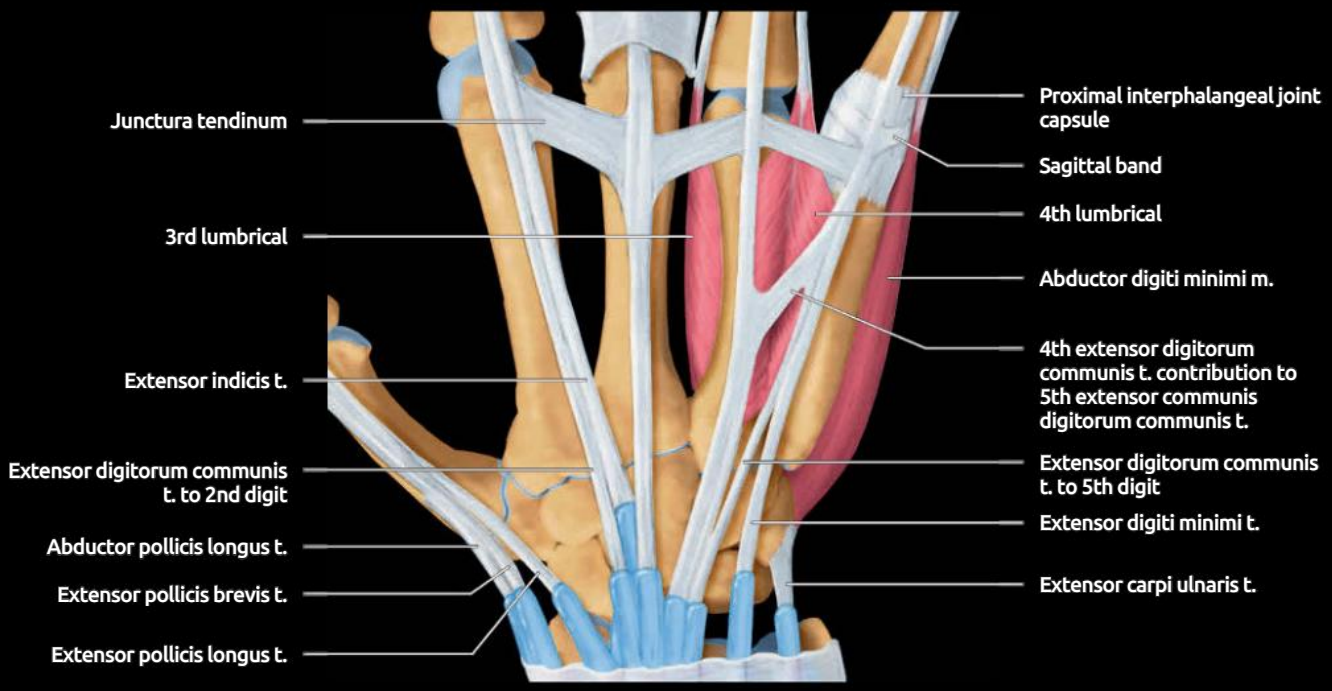

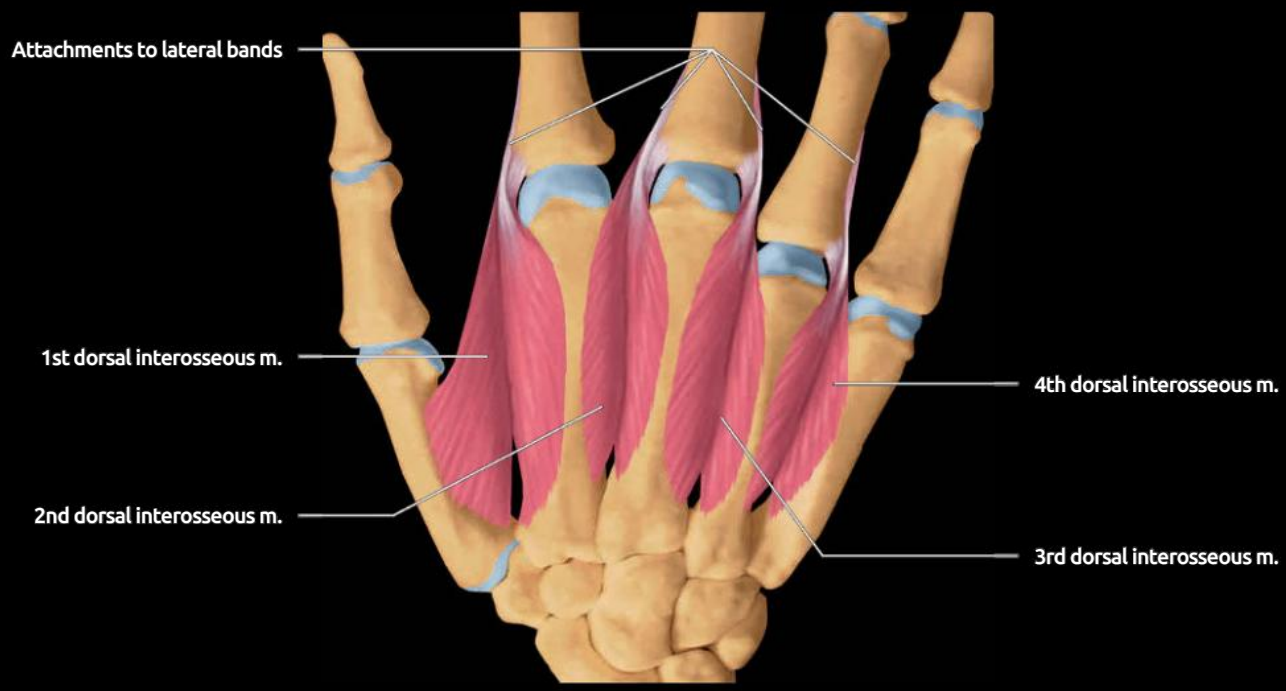

(Top) *Graphic shows the extensor tendons on the dorsum of the hand. The juncturae tendinum are connective tissue bands that extend transversely and obliquely between the EDC tendons. They assist the sagittal bands more distally in helping to maintain the positions of the extensor tendons. The sagittal bands arise from the volar plates and the deep transverse metacarpal ligaments.* **(Bottom)** *Graphic shows the dorsal interossei muscles. These muscles abduct the digits in addition to assisting flexion at the MCP joint and, by virtue of their attachment to the lateral bands, assist with extension of the proximal and distal interphalangeal joints. Each dorsal interosseous muscle only contributes fibers to that corresponding lateral band closest to the midline of the hand. The dorsal interossei do not contribute to the 1st or 5th digits.*

DORSUM HAND

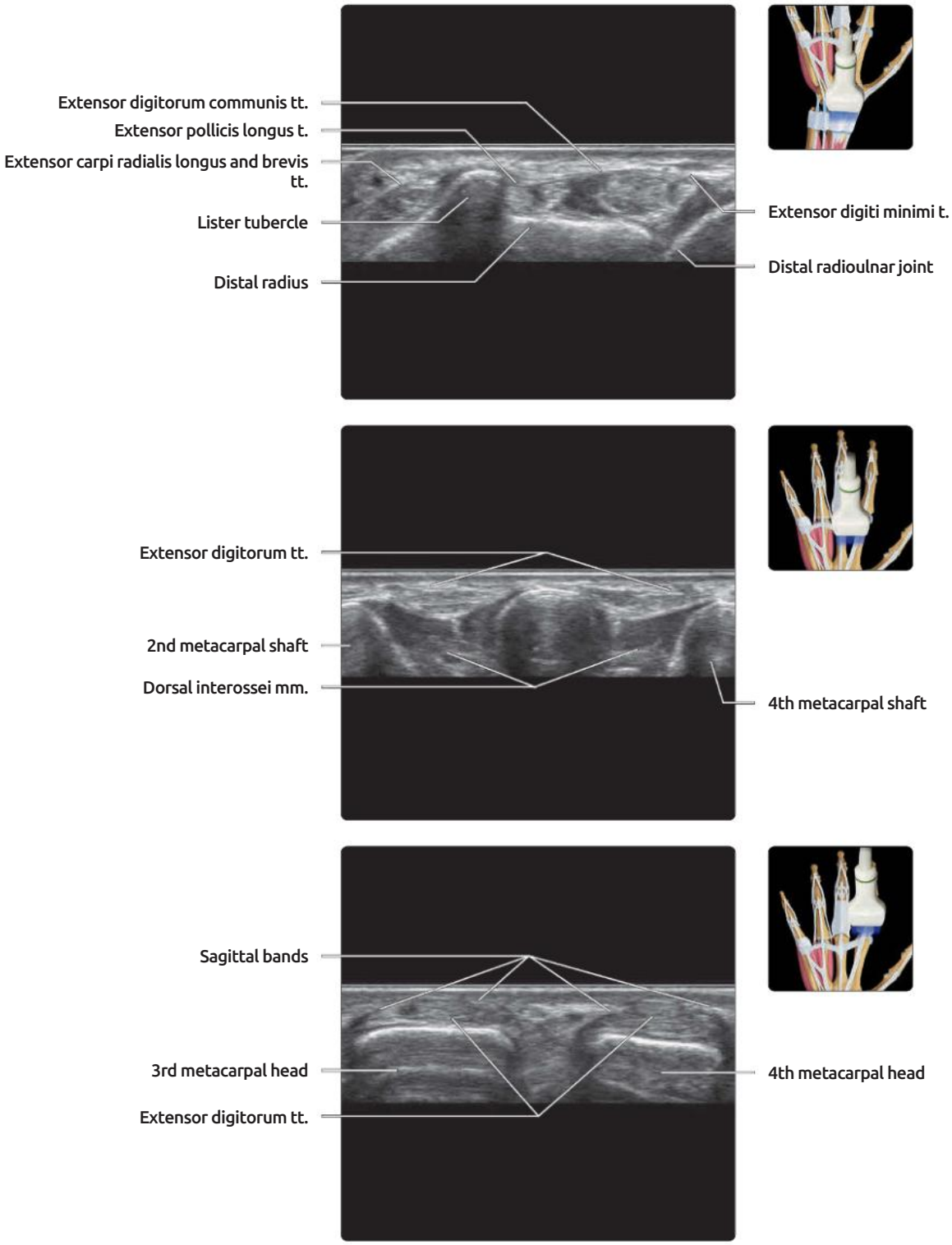

(Top) *Transverse US of the dorsal aspect of wrist shows the Lister tubercle with the extensor tendons of the 2nd (extensor carpi radialis longus and brevis), 3rd (extensor pollicis longus), 4th (EDC), and 5th (extensor digital minimi) extensor compartments.* **(Middle)** *Transverse US of the mid to distal aspect of the hand dorsally shows the extensor digitorum tendons overlying the dorsal interosseous muscles, located between the 2nd and 3rd and 3rd and 4th metacarpal shafts.* **(Bottom)** *Transverse US of the dorsum of the MCP joints shows the sagittal bands on the sides of the extensor digitorum tendons. The sagittal bands, in addition to the juncturae tendinum, help to maintain the extensor tendons in their correct positions.*

GROSS ANATOMY

Thenar Muscles

- 4 thenar muscles; mnemonic: "**A**ll **f**or **o**ne **a**nd..."
  - **Ab**ductor pollicis brevis (APB)
  - **F**lexor pollicis brevis (FPB)
  - **O**pponens pollicis (OP)
  - Origin: All originate from flexor retinaculum
  - Insertion
    - APB inserts to proximal phalanx base
    - FPB (superficial and deep bellies) inserts to radial sesamoid & proximal phalanx base
    - OP inserts along 1st metacarpal shaft
  - **A**dductor pollicis (AP)
    - Largest thenar muscle, deep to thenar eminence
  - AP considered with thenar muscles but anatomically distinct from them
    - Oblique & transverse heads
    - Origin: 2nd & 3rd metacarpal bases, capitate bone
      - Converge into single entity as it moves toward thumb
    - Insertion: Ulnar sesamoid as well as base of proximal phalanx, oblique & annular variable pulleys, & extensor expansion, via aponeurosis
    - Innervated by ulnar nerve rather than median nerve
- **Extrinsic Muscles**
  - Extensor pollicis longus (EPL)
    - Inserts at dorsal aspect base of distal phalanx
  - Extensor pollicis brevis (EPBr)
    - Inserts at dorsal aspect base of proximal phalanx
  - Abductor pollicis longus (APL)
    - Inserts at base of 1st metacarpal bone
  - Flexor pollicis longus (FPL)
    - Inserts at base of distal phalanx

Extensor Apparatus

- Thin fibrous band covering the extensor tendon
  - Sagittal band at MCP joint level
    - Triangular expansion is direct extension of extensor hood beyond sagittal bands
  - AP aponeurosis connects with ulnar aspect of extensor expansion
  - APB & FPB connect with radial aspect of extensor expansion

Flexor Pulley System

- Different from pulley system of fingers
  - Thumb has only annular pulleys & no cruciform pulleys
- A1 pulley: MCP joint level
- A2 pulley: Interphalangeal joint level
- Oblique annular pulley
  - Located at middle to distal aspect of proximal phalanx
- Variable annular pulley present in ~ 90% of subjects
  - Located between 1st annular & oblique annular pulleys

Ulnar Collateral Ligament

- Ulnar aspect of MCP joint
  - Lies deep to adductor aponeurosis

1st Carpometacarpal Joint

- Trapeziometacarpal joint
- Provides high level of dexterity & functionality to thumb
  - Due to saddle-shape, ligaments, & muscle action
  - Predisposes 1st carpometacarpal joint (CMC) to early osteoarthritis
- Dorsal ligaments
  - Dorsal radial ligament, thickest
  - Posterior oblique ligament
  - Intermetacarpal ligament, thinnest
- Volar ligaments
  - Superficial anterior oblique ligament (AOL)
  - Deep AOL, "beak ligament"
- CMC ligaments lax at rest

IMAGING ANATOMY

Overview

- On dorsal transverse imaging, extensor expansions are seen as thin, regular, hypoechoic bands arising from edges of extensor tendon
- On palmar transverse imaging, annular pulleys are seen as thin, ring-shaped structures covering flexor tendons & inserting in palmar plate

ANATOMY IMAGING ISSUES

Imaging Recommendations

- Thenar muscles can be identified reliably on US
- For suspected ulnar collateral ligament (UCL) injury of thumb, first assess contralateral unaffected side to appreciate normal thickness of UCL
  - Check for avulsion fracture from base of proximal phalanx (uncommon)
  - Hyperabduction of thumb during US examination is usually not necessary
  - Best to perform US soon after injury, as scar tissue may blur anatomic delineation in later stages

CLINICAL IMPLICATIONS

Clinical Importance

- UCL of MCP joint of thumb is especially prone to tearing in forced abduction & extension
  - Referred to as gamekeeper thumb or skier thumb
  - Nearly all tears occur at base of proximal phalanx
  - If UCL is torn, position of proximal retracted end with respect to adductor aponeurosis is of importance
    - If proximal portion is displaced superficial to adductor aponeurosis, it is referred to as Stener lesion
      - 75% of complete UCL tears are Stener lesions
    - This interposition of adductor aponeurosis prevents UCL from reuniting with proximal phalanx
      - Surgical repair is usually required
    - If proximal portion remains deep to adductor aponeurosis, conservative management may suffice
- A1 pulley most commonly implicated in pathogenesis of trigger thumb
  - Normal thickness of A1 pulley < 0.5 mm
  - In trigger thumb, A1 pulley is thickened to ~ 1 mm or greater
  - ± restricted FPL tendon motion or lifting up of A1 pulley on real-time US imaging during passive finger flexion
  - Other pulleys less commonly affected

FLEXOR TENDON SHEATHS AND THENAR EMINENCE

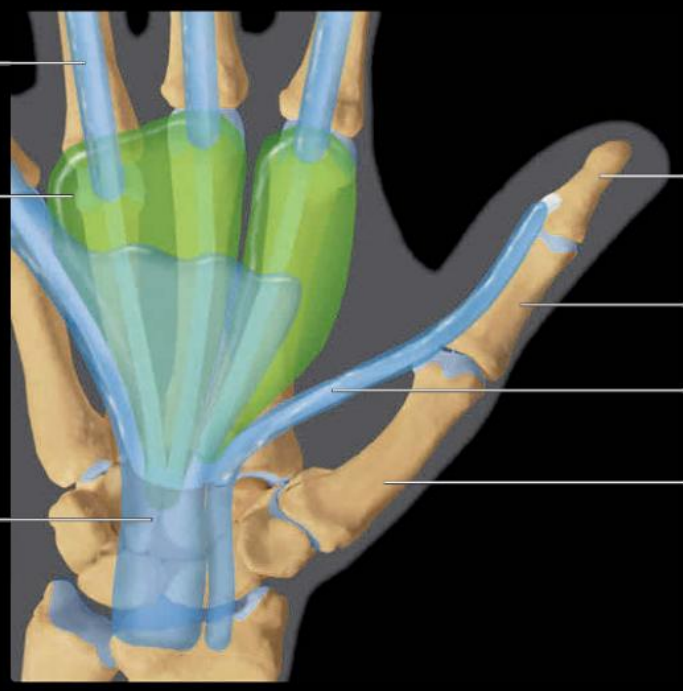

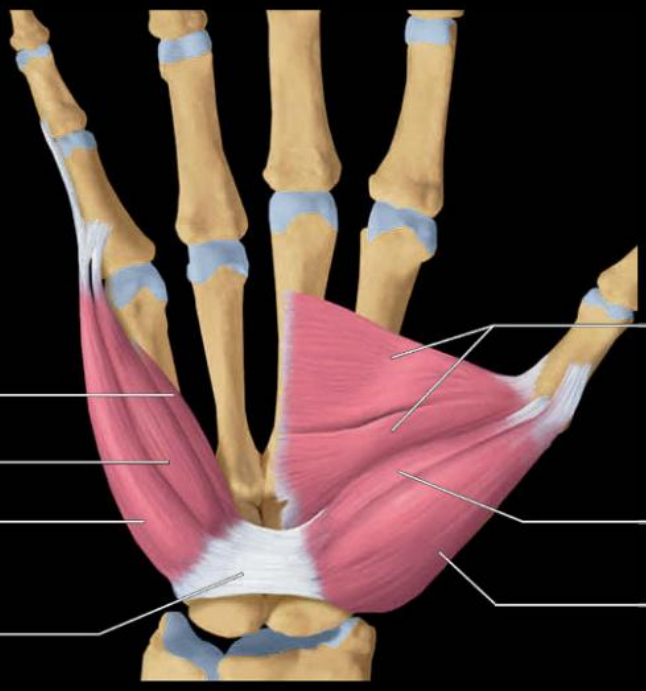

(Top) *Graphic shows the radial and ulnar bursa tendon sheaths. The radial bursa [a.k.a. flexor pollicis longus (FPL) tendon sheath] connects with the ulnar bursa in 50% of normal subjects. The ulnar bursa connects with 1 or other of the digital tendon sheaths in 10% of normal subjects.* **(Bottom)** *Graphic shows the thenar and hypothenar muscles. The thenar muscles enable fine movements of the thumb. The thenar muscles are innervated by the recurrent motor branch of the median nerve except for the deep belly of flexor pollicis brevis (FPB) and both heads of the adductor pollicis muscle, which are innervated by the ulnar nerve.*

THENAR MUSCLES

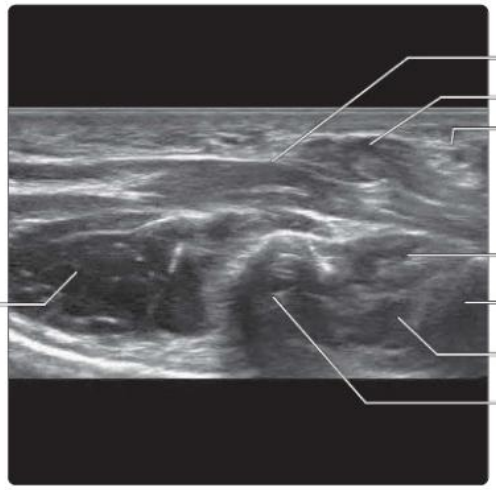

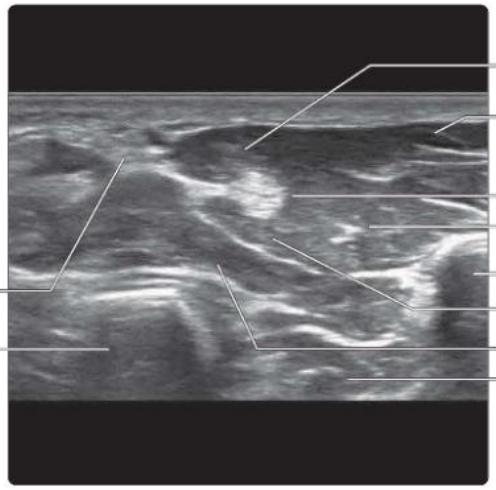

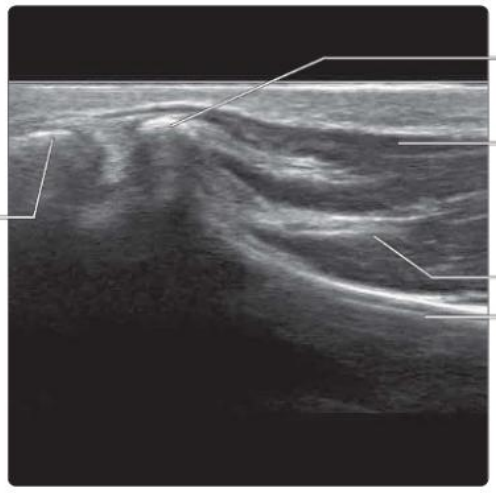

(Top) *Transverse US, radial aspect of the palm, shows the transverse head of the adductor pollicis (AP) muscle. The transverse and oblique heads of the AP muscle converge to insert onto the ulnar aspect of the proximal phalangeal base of the thumb, embedding the medial sesamoid bone. Some fibers from the oblique head also insert into the extensor hood of the thumb.* **(Middle)** *Transverse US shows the thenar muscles. The abductor pollicis brevis (APB) is a small, flat muscle located superficially and radially. The superficial belly of the FPB muscle is also superficially located, on the ulnar side of the APB. The opponens pollicis (OP) is a small, triangular muscle lying deep to the APB at the same level as the FPL tendon. The deep belly of the FPB lies below the FPL tendon on the same level as the AP muscle.* **(Bottom)** *Longitudinal US shows the superficial and deep bellies of the FPB inserting into the radial aspect of the proximal phalangeal base and embedding the radial sesamoid bone.*

FLEXOR TENDONS, THUMB

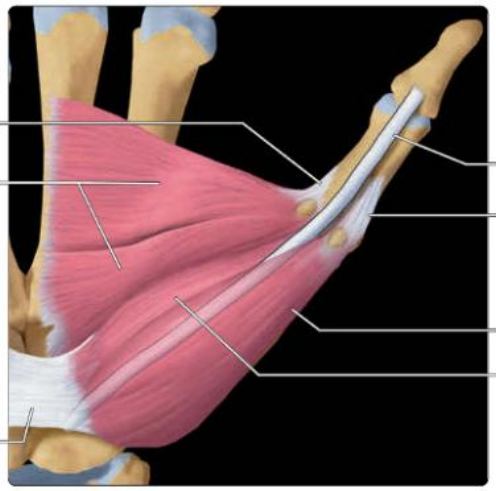

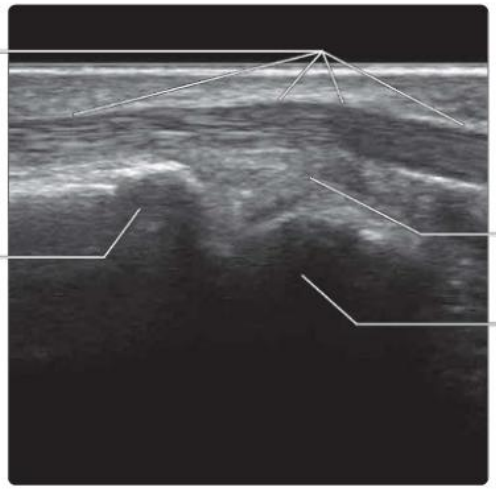

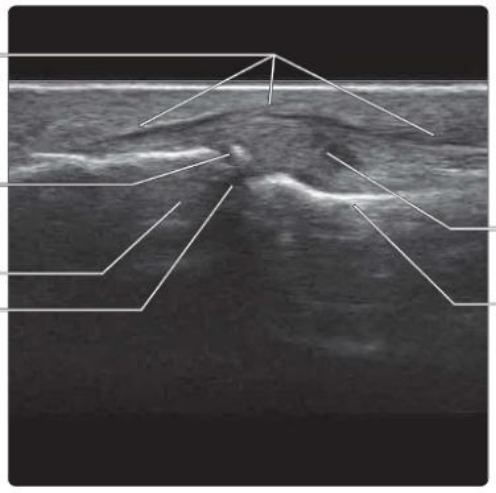

(Top) *Graphic shows the FPL tendon, which flexes the interphalangeal (IP) joint and, to a lesser degree, the 1st MCP joint of the thumb. The FPL tendon first passes through the thenar eminence and then between the 2 sesamoid bones of the MCP joint on the surface of the volar plate (not shown) before inserting into the base of the distal phalanx. The FPB tendon inserts onto the radial aspect of the proximal phalangeal base. As such, the FPB muscle primarily flexes the MCP joint and does not flex the IP joint.* **(Middle)** *Longitudinal US shows the FPL tendon passing over the volar plate of the MCP joint. As there is only one long flexor tendon to the thumb, no splitting of this tendon occurs as in the other digits.* **(Bottom)** *Longitudinal US shows the FPL tendon inserting into the base of the distal phalanx of the thumb. The small ossicle is a normal variation. It is termed an ossicle rather than a sesamoid bone, as it is not embedded within the tendon.*

FLEXOR PULLEYS, THUMB

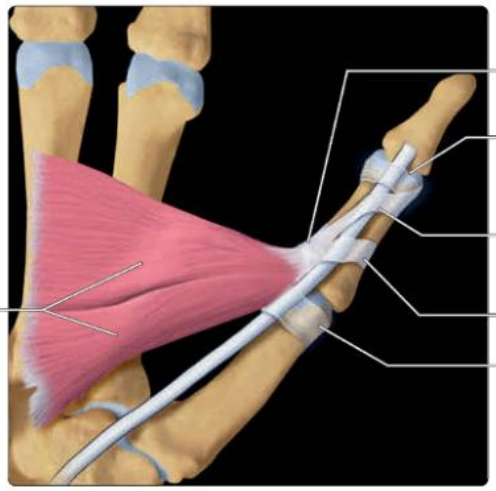

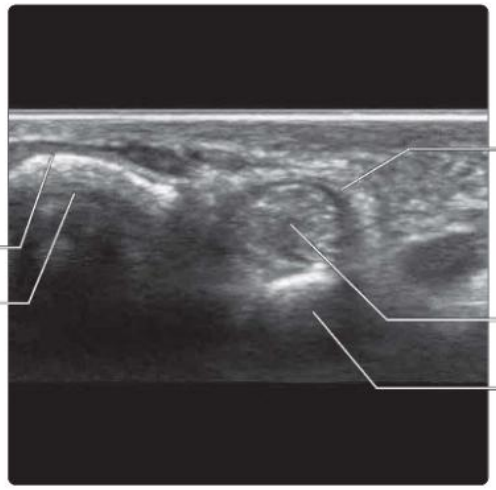

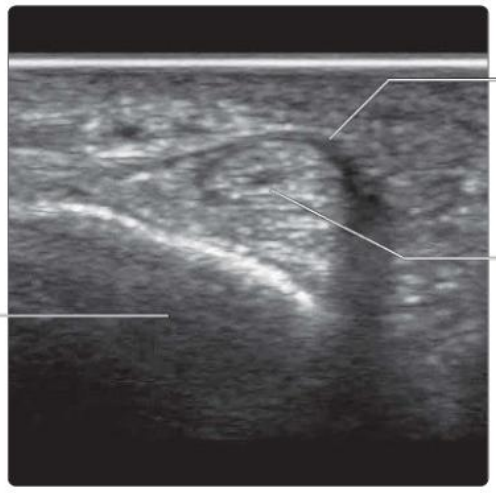

(Top) *Graphic shows the flexor pulley system of the thumb which is different to that seen in the other digits. The pulley system helps to prevent bowstringing of the FPL tendon. The A1 and A2 pulleys are located at the MCP and IP joints, respectively. The oblique pulley is attached proximally to the adductor aponeurosis. The variable pulley is seen in 90% of normal subjects.* **(Middle)** *Transverse US shows the thin A1 pulley encasing the FPL tendon at the MCP joint. The A1 pulley is attached to the sesamoid bones. The radial sesamoid bone is embedded in the FPB tendon.* **(Bottom)** *Transverse US shows the thin variable pulley of the thumb covering the FPL tendon at the proximal end of the proximal phalanx.*

EXTENSOR APPARATUS, THUMB

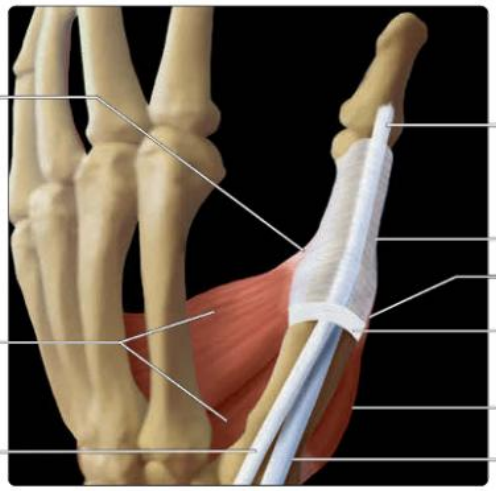

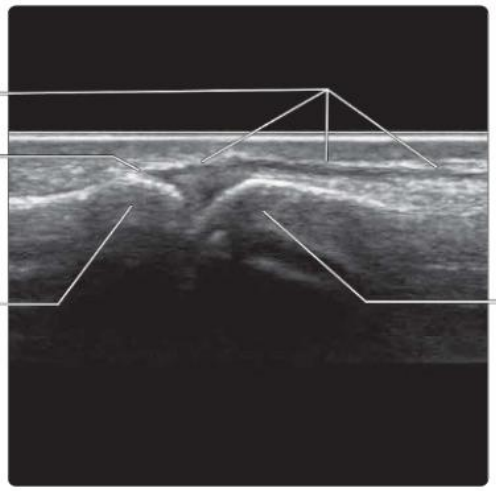

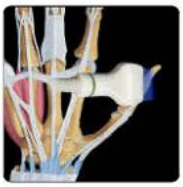

(Top) *Graphic shows the extensor tendons of the thumb, which have a simpler arrangement than the other digits. The extensor pollicis brevis (EPBr) tendon inserts onto the base of the proximal phalanx while the extensor pollicis longus (EPL) tendon inserts at the base of the distal phalanx. The extensor hood covers the extensor tendons. It comprises a sagittal band (not shown) at the MCP joint level. The adductor aponeurosis merges with the extensor hood on the ulnar side while the APB and FPB tendons merge with the hood on the radial side.* **(Middle)** *Longitudinal US shows the EPL tendon on the dorsum of the MCP joint. The EPL inserts into the base of the distal phalanx. The EPBr tendon (not shown) blends with the dorsal plate of the MCP joint before it inserts onto the base of the proximal phalanx. The dorsal plate does not have a bony attachment with synovial recesses deep to the plate.* **(Bottom)** *Longitudinal US shows the EPL tendon inserting into the base of the distal phalanx.*

EXTENSOR ASPECT, THUMB

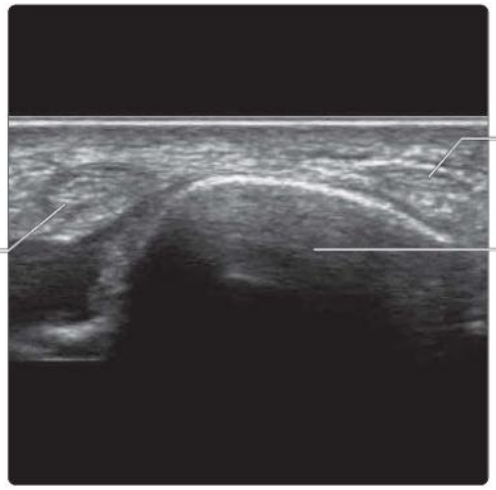

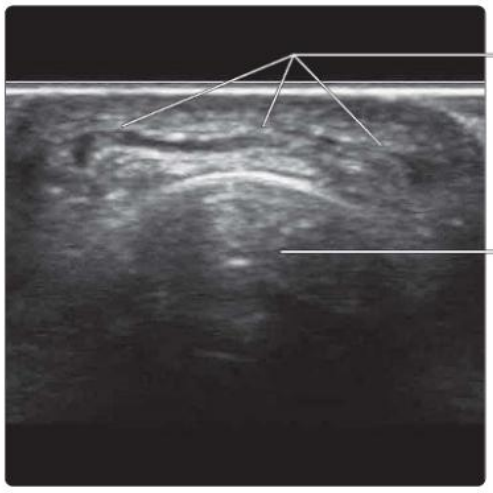

(Top) *Transverse US, dorsal aspect of trapezium, shows the EPL tendon lying radial to the EPBr tendon, which, in turn, lies radial to the abductor pollicis longus (APL) tendon. Normally, the APL tendon has a split appearance proximal to its insertion into the 1st metacarpal base and adjacent trapezium. This normal splitting should not be mistaken for a tear.* **(Middle)** *Transverse US at the metacarpal head level shows the EPL and EPBr tendons converging toward the thumb.* **(Bottom)** *Transverse US shows the thin extensor hood on the dorsal aspect of the proximal phalanx.*

ULNAR COLLATERAL LIGAMENT, THUMB

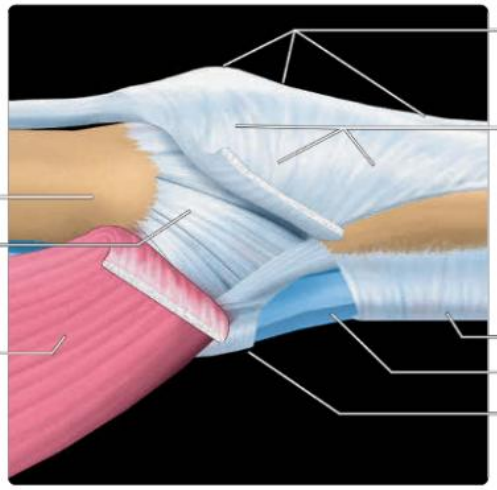

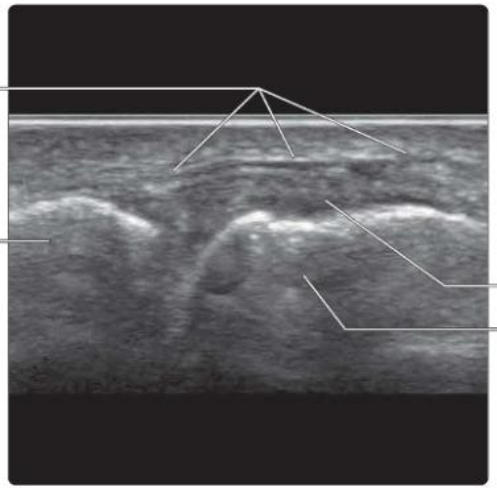

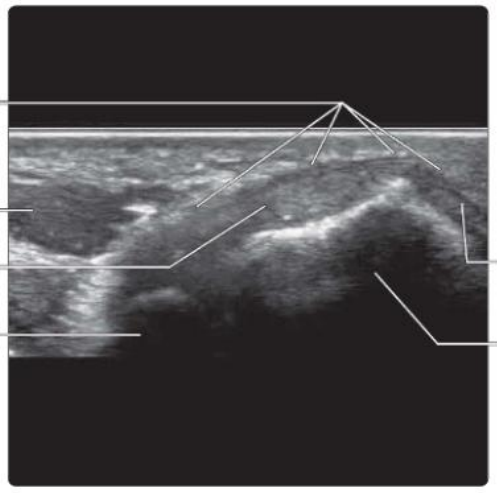

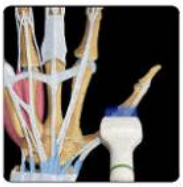

(Top) *Graphic shows the AP aponeurosis covering the ulnar collateral ligament of the MCP joint of the thumb. The adductor aponeurosis is attached to the ulnar aspect of the proximal phalangeal base as well as the ulnar sesamoid bone. It also attaches to the extensor hood and to the oblique annular pulley (not shown).* **(Middle)** *Longitudinal US shows the thin adductor aponeurosis overlying the thick ulnar collateral ligament on the ulnar aspect of the MCP joint of the thumb.* **(Bottom)** *Transverse US shows the ulnar collateral ligament with the overlying adductor aponeurosis. The adductor aponeurosis merges with the extensor hood on the dorsum of the metacarpal head and proximal phalanx.*

DORSAL LIGAMENTS, 1ST CARPOMETACARPAL JOINT

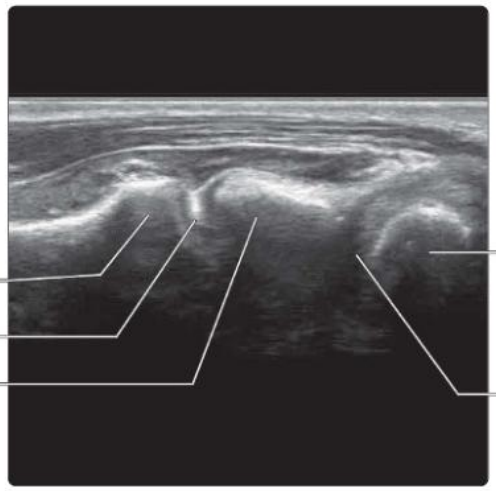

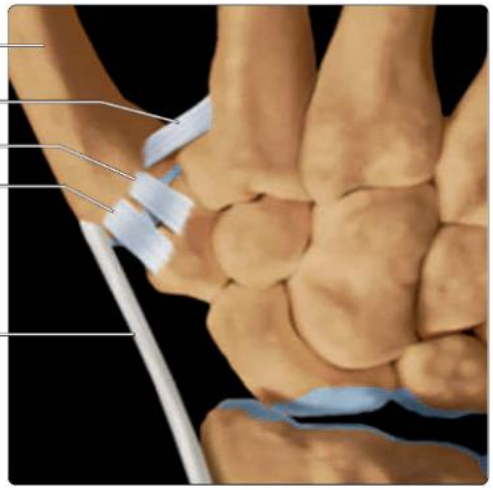

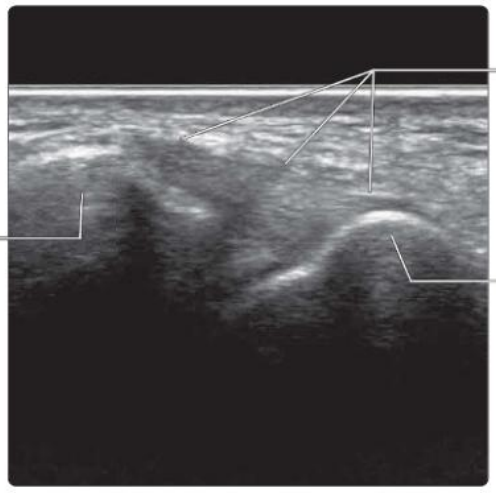

(Top) *Longitudinal US shows the palmar aspect of the 1st carpometacarpal joint. The 1st carpometacarpal joint is a very mobile joint, which makes it prone to osteoarthritis in later years.* **(Middle)** *Graphic shows the dorsal radial ligament and the adjacent posterior oblique ligament on the dorsum of the 1st carpometacarpal joint as well as the thin intermetacarpal ligament that connects the bases of the 1st and 2nd metacarpal bones. The stronger dorsal radial ligament lies close to the insertion of the APL tendon.* **(Bottom)** *Longitudinal US shows the thick, fan-shaped dorsal radial ligament on the dorsal aspect of the 1st carpometacarpal joint extending between the radial tubercle of the trapezium and the dorsal edge of the 1st metacarpal base. The dorsal radial ligament is a thicker ligament, and therefore more easily seen, than the adjacent posterior oblique ligament.*

VOLAR LIGAMENTS, 1ST CARPOMETACARPAL JOINT

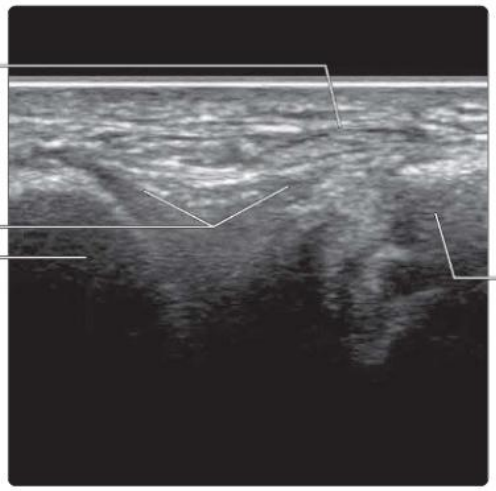

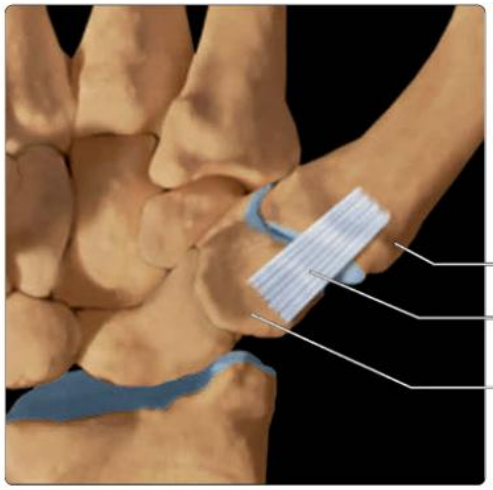

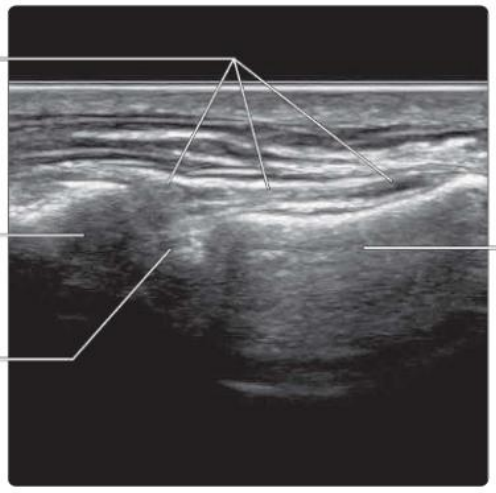

(Top) *Transverse US shows the thin intermetacarpal ligament extending between the dorsal aspects of the 1st and 2nd metacarpal bases. This thin ligament is an important retraining structure of the 1st MCP joint. It lies deep to the EPL tendon.* **(Middle)** *Graphic shows the anterior oblique ligament (AOL) on the volar aspect of the carpometacarpal joint. The AOL has a longer superficial component and a shorter (not shown), stronger, deep component.* **(Bottom)** *Longitudinal US, volar aspect of carpometacarpal joint, shows the superficial component of the AOL. The deep component (sometimes known as the beak ligament) of the AOL is intraarticular, attaching to the articular margin of the trapezium and the beaked volar base of the 1st metacarpal bone. This intraarticular component is more difficult to visualize.*

TERMINOLOGY

Abbreviations

- Extensor digitorum communis (EDC)
- Extensor digiti minimi (EDM)
- Interphalangeal (IP) joint
- Metacarpophalangeal (MCP) joint

GROSS ANATOMY

Muscles

- **Flexor aspect**
  - **Flexor digitorum superficialis (FDS)**
    - Origin: Common flexor tendon origin & midradius
    - Insertion: Volar plates of proximal IP joints & bases of middle phalanges, digits 2-5
    - Superficialis tendon superficial to profundus tendon until it divides at proximal 1/3 of proximal phalanx
    - 2 slips of superficialis tendon pass around profundus tendon & reunite deep to profundus tendon prior to insertion
    - Flexes MCP & proximal IP joints of digits 2-5, aided by lumbricals & interossei
  - **Flexor digitorum profundus (FDP)**
    - Origin: Proximal radius, midradius, & interosseus membrane
    - Profundus tendon passes through divided superficialis tendon to insert at base of distal phalanx
    - Insertion: Volar plates of distal IP joints & bases of distal phalanges, digits 2-5
    - Flexes MCP & proximal, distal IP of digits 2-5, aided by lumbricals & interossei
- **Lumbricals**
  - Numbered 1-4 from radial to ulnar
  - Origin: FDP tendons, just distal to carpal tunnel
  - Insertion: Radial lateral bands of digits 2-5
    - Flex MCP & extend IP joints of digits 2-5
- **Palmar interossei (adduct)**
  - Numbered 1-3 from radial to ulnar
  - Origin: Diaphyses of 2nd, 4th, & 5th metacarpals
    - Originate from side of metacarpal facing midline
  - Insertion: Radial lateral bands & proximal phalangeal bases of digits 2, 4, & 5
  - Adduct digits 2, 4, & 5
    - Assist lumbricals with flexion of MCP & extension of IP joints
- **Extensor aspect**
  - **EDC**
    - Origin: Common extensor tendon origin (lateral humeral epicondyle)
    - Insertion: As central slip at bases of middle phalanges & proximal IP joint capsule
    - Separate EDC tendon to 5th digit tendon is present in 50% of general population
  - **Extensor indicis**
    - Origin: Posterior ulna, distal ulna, & interosseus membrane
    - Insertion: Blends with 2nd digit EDC tendon & extensor hood
  - **EDM**
    - Origin: Common extensor tendon origin (lateral humeral epicondyle)
    - Insertion: 2 tendons of EDM fuse with one another & with 5th digit EDC tendon prior to insertion at base of proximal phalanx of 5th digit
- **Dorsal interossei (abduct)**
  - Numbered 1-4 from radial to ulnar
  - Origin: Metacarpal diaphyses
  - Insertion: Lateral bands & proximal phalangeal bases of digits 2-4
  - Abduct digits 2-4
    - Assist with flexion of MCP & extension of IP joints

Tendon Pulley System

- **Annular pulley**
  - Retinacula that retain flexor tendons at 5 points known as annular pulleys
  - Prevent tendon bowstringing during finger flexion
  - A1 pulley thickest (normal < 0.5 mm) with A2-5 pulleys becoming progressively thinner
  - Functionally, A2 & A4 pulleys are most important to prevent bowstringing
    - A1: MCP joint & base of proximal phalanx
    - A2: Midshaft proximal phalanx
    - A3: Proximal IP joint
    - A4: Midshaft of middle phalanx
    - A5: Distal IP joint
  - Also cruciform pulleys, C1-C3
- **Extensor expansion**
  - Begins just proximal to MCP joints & terminates just proximal to proximal IP joint
  - Dorsal expansion of fibers oriented perpendicular to long axis of extensor tendons
  - Fibers of extensor expansion interdigitate with EDC tendons to prevent lateral translation

Tendon Sheaths

- 2nd-4th digit flexor synovial sheaths extend from metacarpal neck to distal phalangeal bases
- 5th digit flexor tendon sheath extends from wrist to distal phalangeal base

ANATOMY IMAGING ISSUES

Imaging Approaches

- Pulley thickness should be measured at 11 or 1 o'clock positions as pulleys widen at base
  - Thickened in trigger finger (usually > 1 mm)
    - Most commonly affects A1 pulley
    - Check for restriction of tendon motion or uplifting of A1 pulley on passive finger movement
  - Pulley tear inferred by bowstringing of flexor tendons
    - Compare with normal fingers

CLINICAL IMPLICATIONS

Clinical Importance

- Digital tendon sheaths may connect to ulnar bursa in 10% of population, providing route for spread of infection from digits 2-4 to common flexor sheath & vice versa
- Cannot get tenosynovitis on dorsum of finger as no tendon sheath

TENDON SHEATHS AND TENDON OF FINGERS

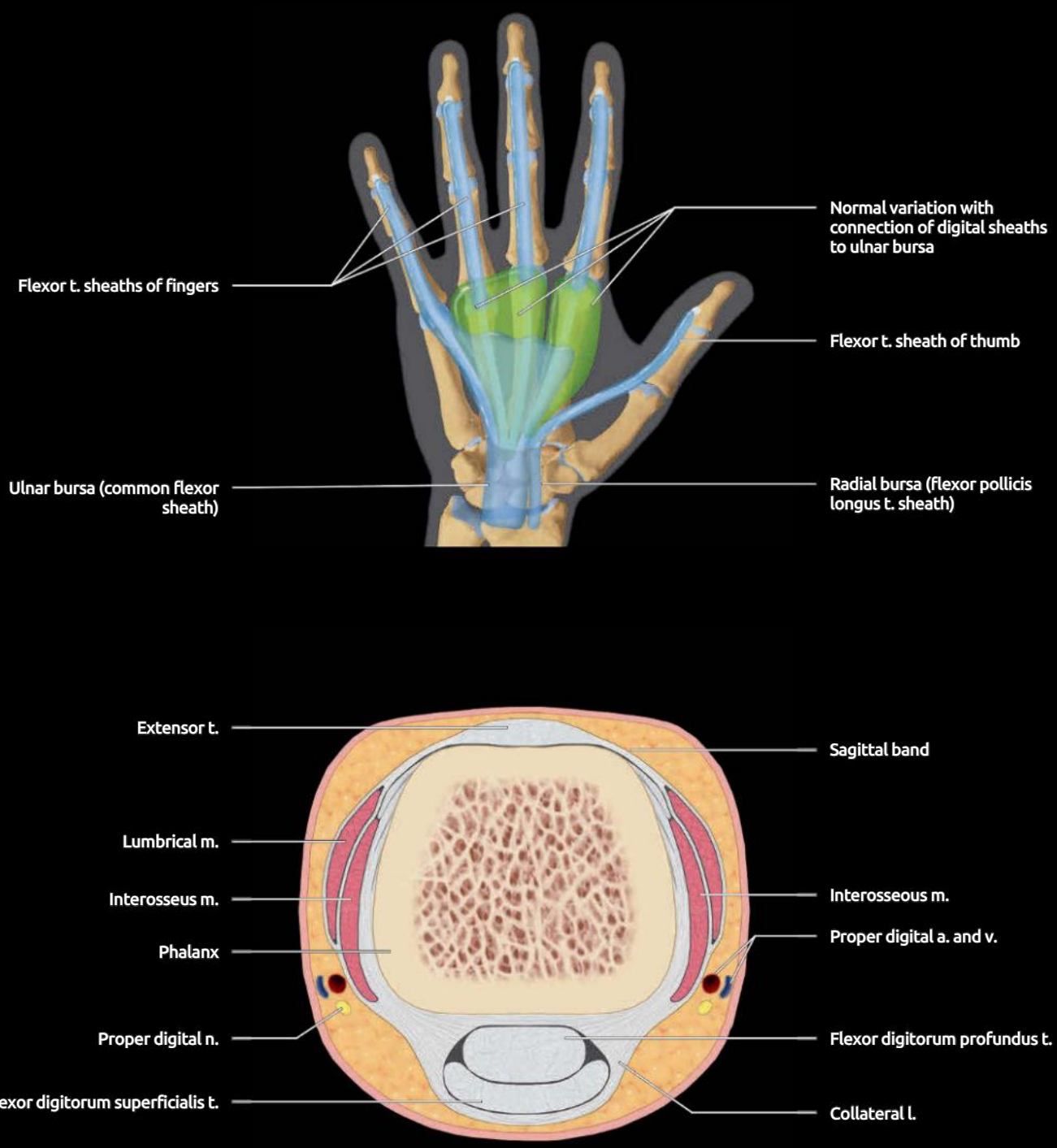

(Top) *Graphic shows tendon sheaths of the fingers (blue). Digital tendon sheaths connect to the ulnar bursa (green) in 10% of population, providing route for spread of infection from digits 2-4 to the common flexor tendon sheath (ulnar bursa) and vice versa. The ulnar and radial bursae communicate in 50% of subjects.* **(Bottom)** *Graphic shows the transverse section of a proximal phalanx depicting the relationships of the digital nerves, vessels, and tendons to the phalanx. On the dorsal aspect, the extensor expansion interdigitates with the extensor digitorum communis tendons to prevent lateral translation. On the palmar side, the collateral ligaments extend from the palmar aponeurosis in the palm to fuse with the fibrous digital sheaths. The proper digital artery and accompanying nerve are located between the intrinsic muscles and the flexor tendons.*

FLEXOR TENDONS, TENDON SHEATHS, AND PULLEYS

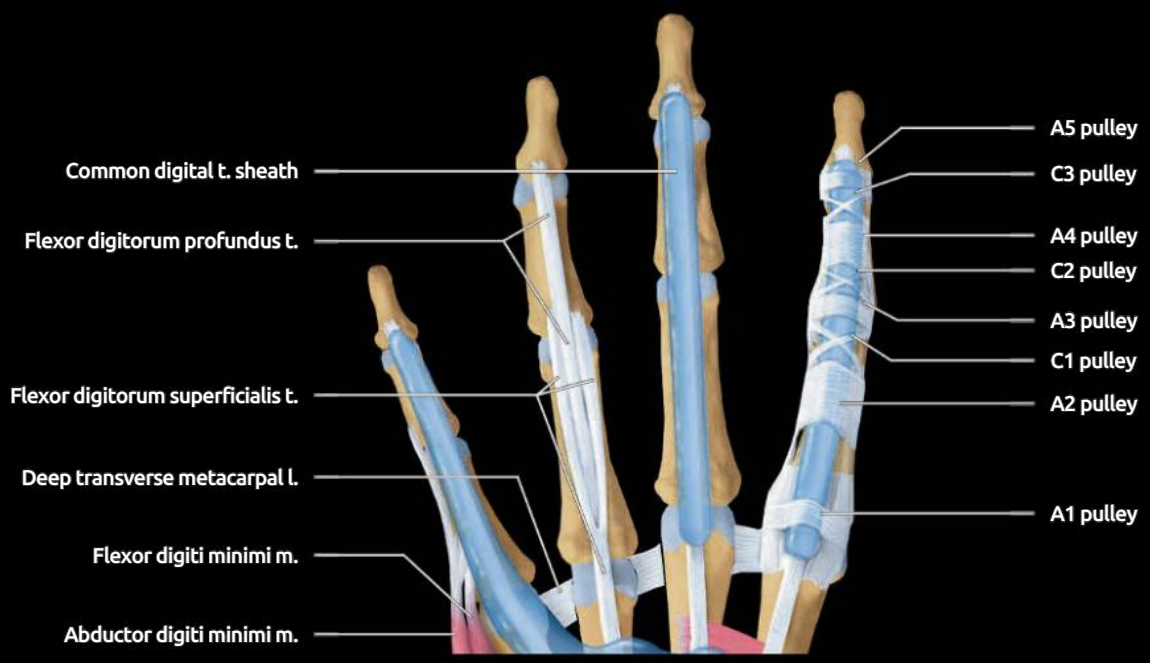

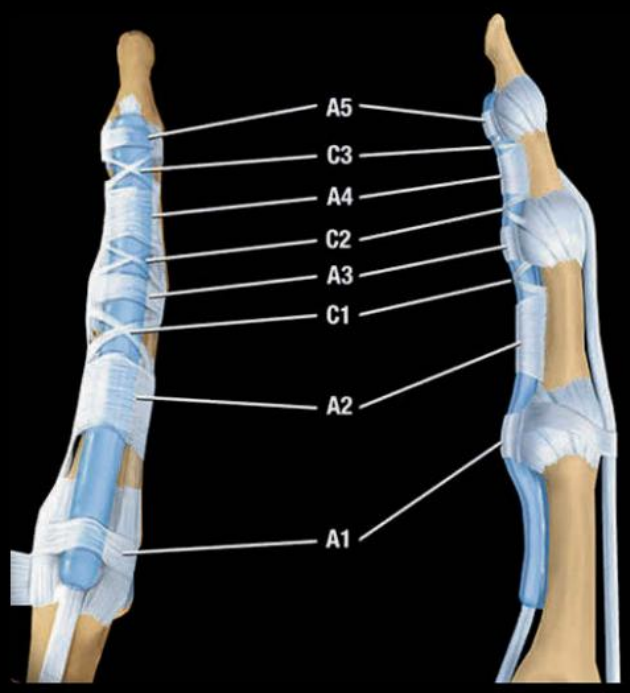

(Top) *Graphic shows tendon sheaths for the 5th and 3rd digits. The common tendon sheath of the 4th digit has been removed to show the flexor digitorum superficialis (FDS) and flexor digitorum profundus (FDP) tendons. The deep transverse metacarpal ligaments connect the volar plates (not shown) of digits 2-5. The flexor pulley system of the 2nd digit is shown.* **(Bottom)** *Graphic shows the flexor pulley system of the fingers. This comprises the annular (A1-5) and cruciate (C1-C3) pulleys. The most important pulleys clinically are the A1 pulley (most frequently affected in trigger finger) and the A2 and A4 pulleys (which prevent bowstringing). The pulleys get progressively thinner as one proceeds from A1 to A5. The annular pulleys are more easily seen on US than the cruciate pulleys.*

FLEXOR PULLEYS

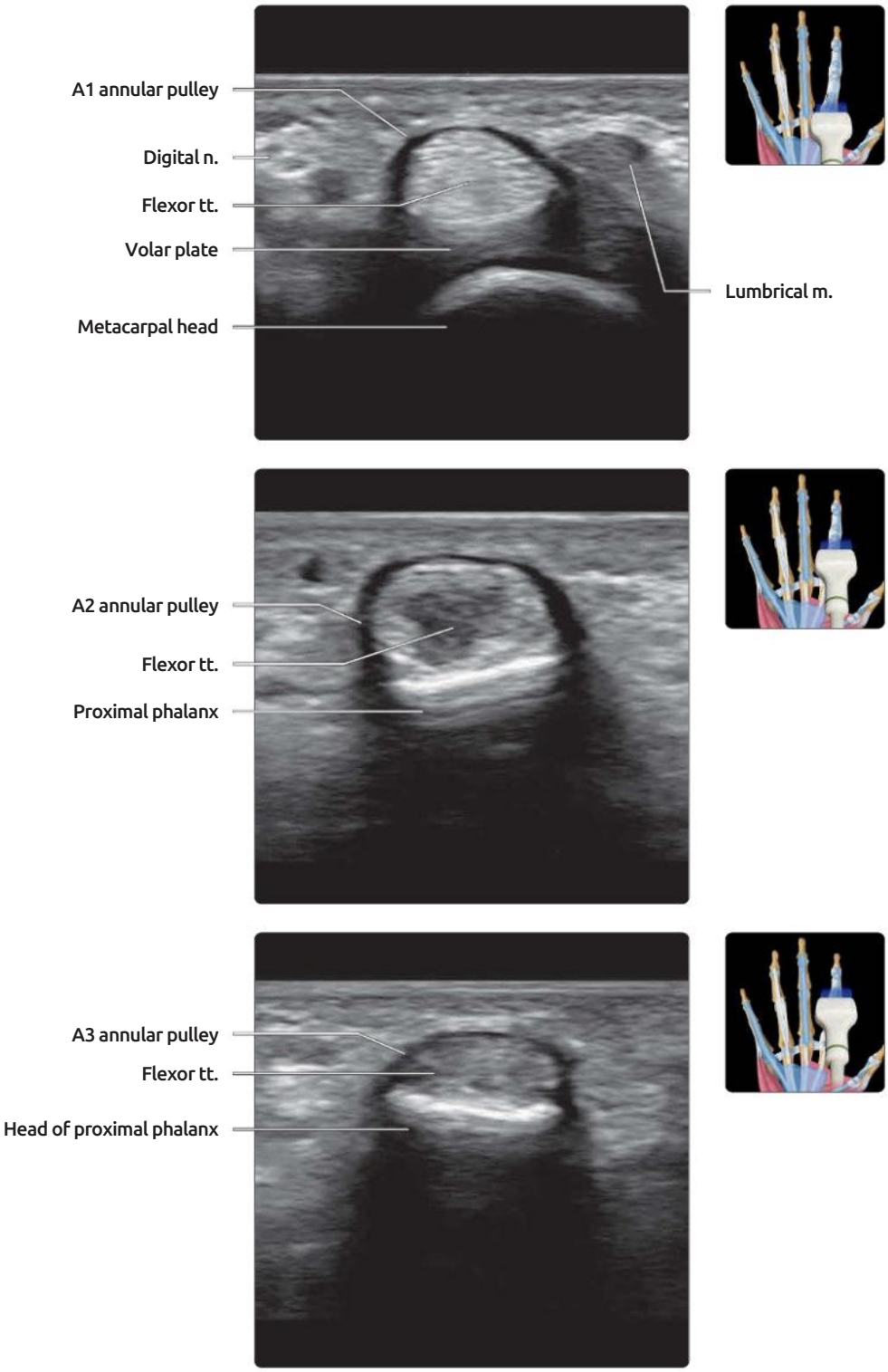

(Top) *Transverse US at the metacarpophalangeal (MCP) joint level shows the thin hypoechoic A1 annular pulley surrounding the flexor tendons. Annular pulley thickness should be measured at the 11 o'clock or 1 o'clock positions as the pulley widens out toward its base. The normal pulley is < 0.5 mm thick.* **(Middle)** *Transverse US at the level of the proximal phalanx shows the hypoechoic A2 pulley. This, and the A4 pulley, are the critical pulleys to prevent flexor tendon bowstringing. The A2 pulley can also be thickened in the trigger finger.* **(Bottom)** *Transverse US at the level of the proximal interphalangeal (IP) joint shows the slightly thinner A3 pulley.*

FLEXOR TENDONS, TRANSVERSE

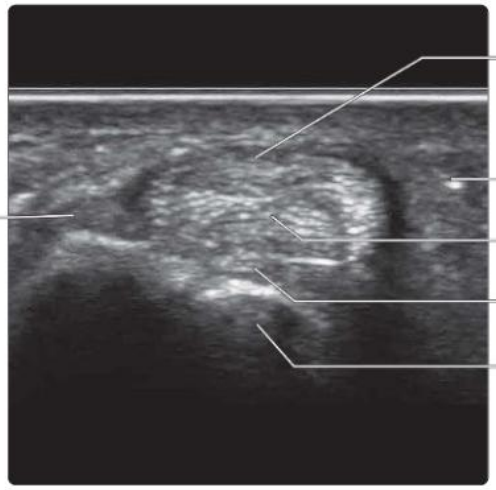

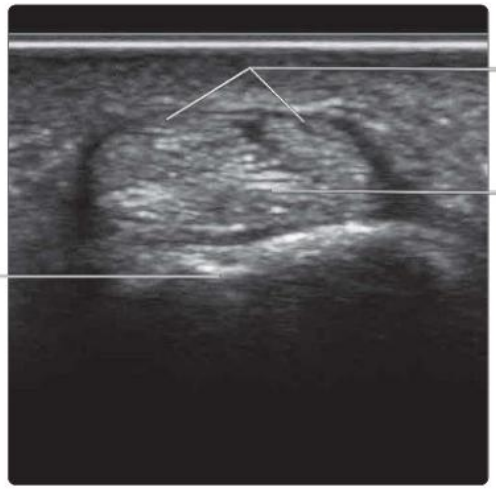

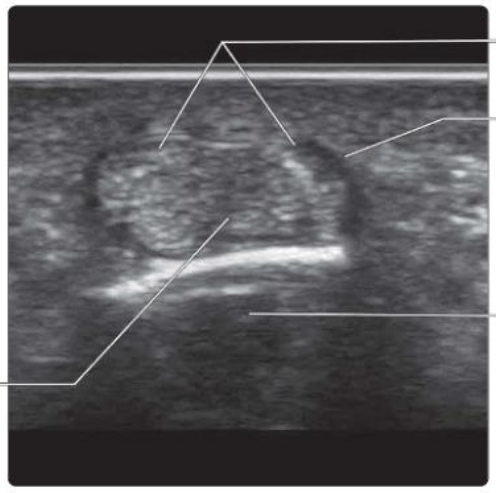

(Top) *Transverse US just proximal to the MCP joint shows the FDS tendon lying superficial to the FDP tendon. The deep transverse metacarpal ligament, which connects the palmar surfaces of the MCP joints and volar plates, is at the deep lateral margin of the flexor tendons.* **(Middle)** *Transverse US of the proximal end of the proximal phalanx shows the FDS and FDP tendons deep to the proximal end of the A2 pulley.* **(Bottom)** *Transverse US shows the flexor tendons, deep to the A2 pulley, at the midportion of the proximal phalanx. The FDS tendon is splitting and extending around the sides of the centrally located FDP tendon. The FDS tendon slips will reunite deep to the FDP tendon before inserting onto the base of the middle phalanx.*

FLEXOR TENDONS, LONGITUDINAL

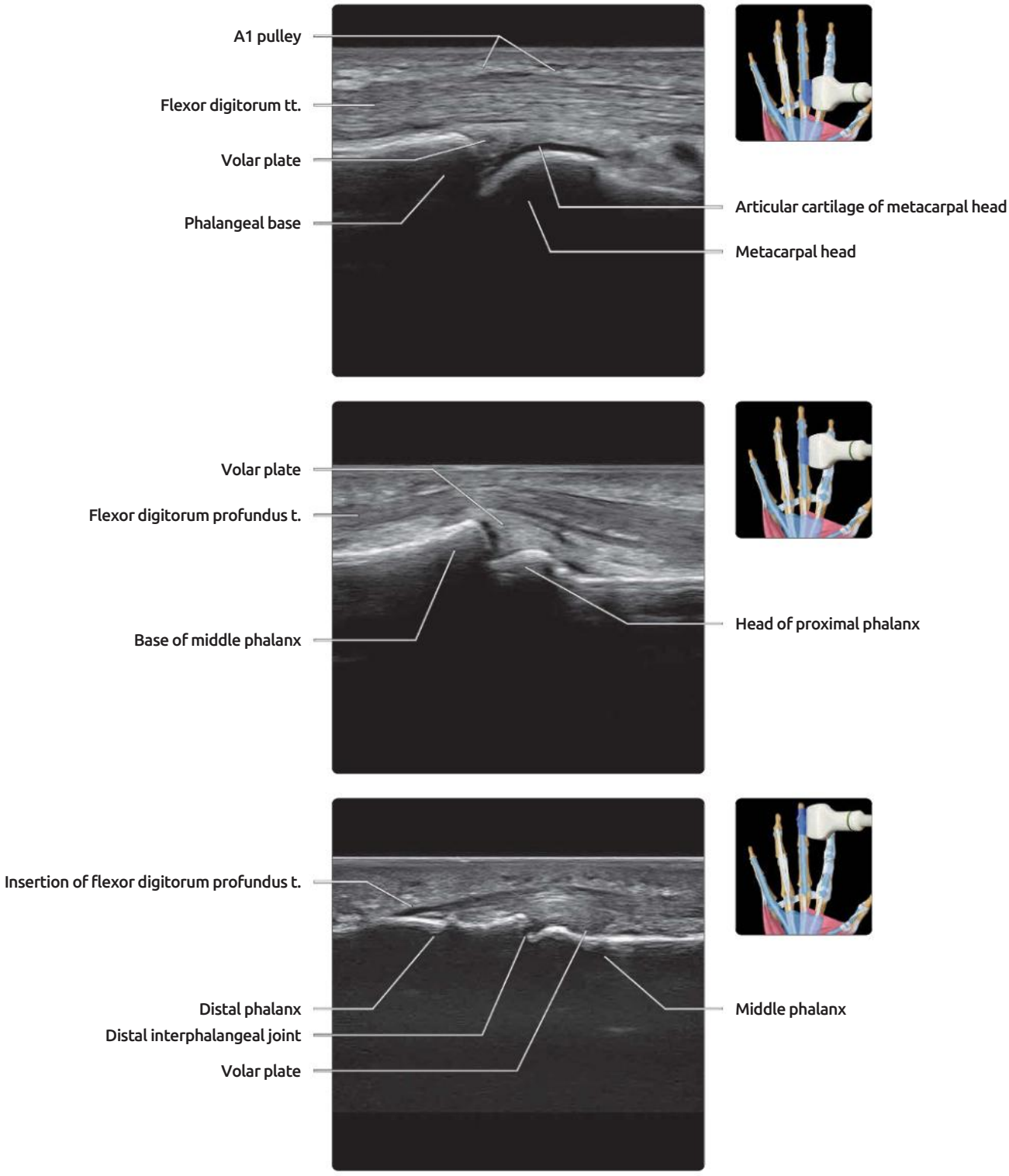

(Top) *Longitudinal US shows the flexor tendons overlying the middle finger MCP joint. The A1 pulley is a thin linear structure just superficial to the flexor tendon at the MCP joint level. The fibrocartilaginous volar plate lies deep to the flexor tendon. The volar plate is strongly attached to the phalangeal base distally. It is also attached to the accessory collateral ligaments laterally (not shown) and the metacarpal shaft via the paired checkrein ligaments proximally (not shown).* **(Middle)** *Longitudinal US shows the volar aspect of the proximal IP joint. The step-off between the base of the middle phalanx and the head of the proximal phalanx is a normal feature. The flexor tendon caliber lessens beyond the proximal IP joint as the flexor superficialis tendon has inserted to the base of the middle phalanx.* **(Bottom)** *Longitudinal US shows the volar aspect of the distal IP joint. The fibrocartilaginous volar plate deep to the distal end of the flexor to the FDP tendon is shown. The FDP tendon inserts into the base of the distal phalanx.*

METACARPOPHALANGEAL JOINT, FLEXOR AND EXTENSOR TENDONS

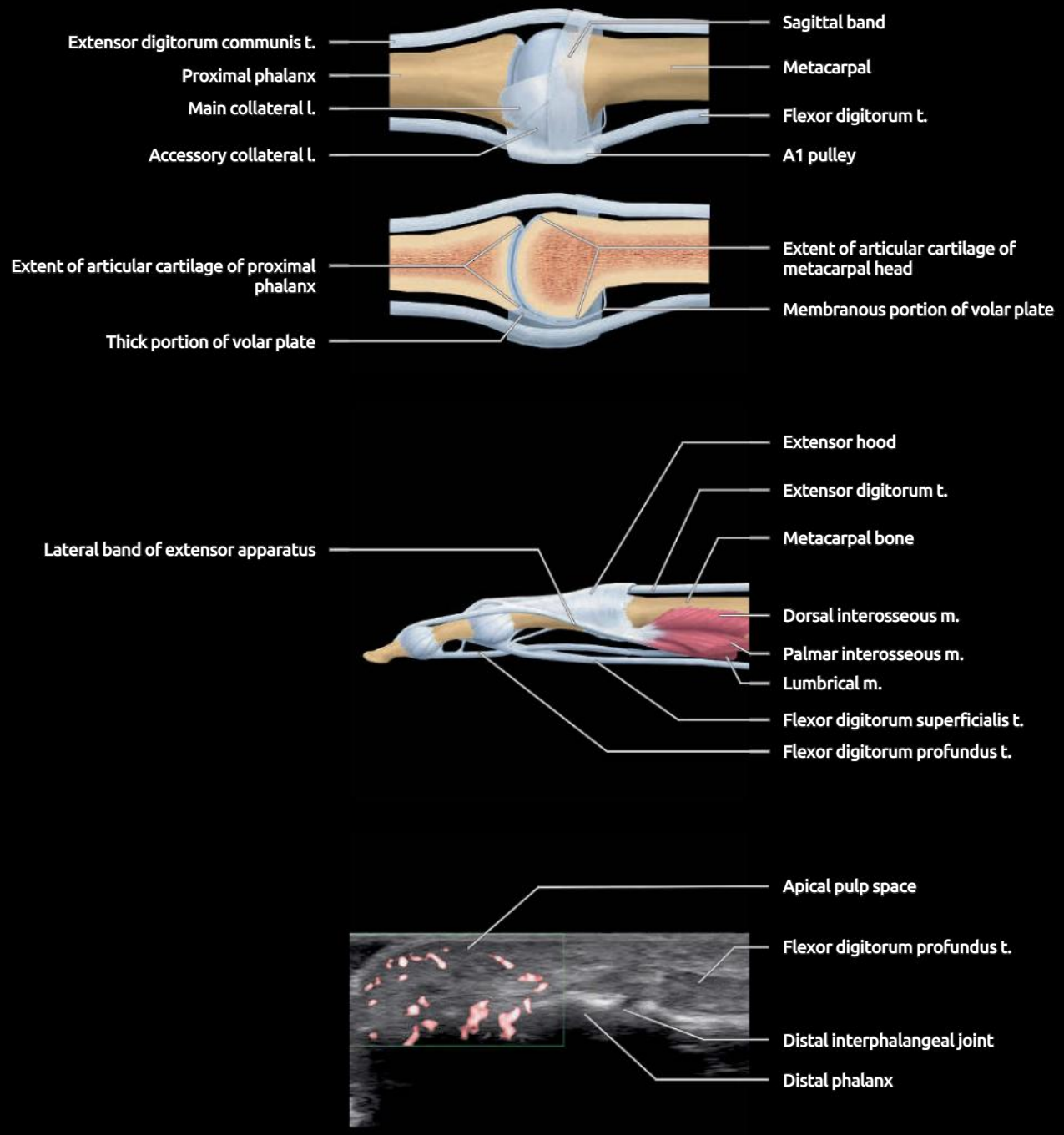

(Top) *Graphics show the MCP joint. The collateral ligament complex comprises the main collateral ligament attached to the phalangeal base and the accessory collateral ligament attached to the volar plate. The volar plate of the proximal IP joint is further stabilized by the paired checkrein ligaments (not shown) that attach the volar plate to the metacarpal shaft. With the exception of the sagittal bands and checkrein ligaments, this anatomy is similar for all MCP and IP joints.* **(Middle)** *Graphic shows the arrangement of the flexor tendons and the extensor expansion of the extensor tendons. The dorsal and palmar interossei as well as the lumbrical tendons all insert into the lateral bands. All these tendons flex the MCP joint and, by virtue of their connectivity to the lateral bands, extend the IP and distal IP joints.* **(Bottom)** *Longitudinal color Doppler US, with superb microvascular imaging, shows normal hyperemia of the apical pulp space of the finger. Proximally, the FDS tendon insertion into the base of the proximal phalanx is shown.*

EXTENSOR APPARATUS

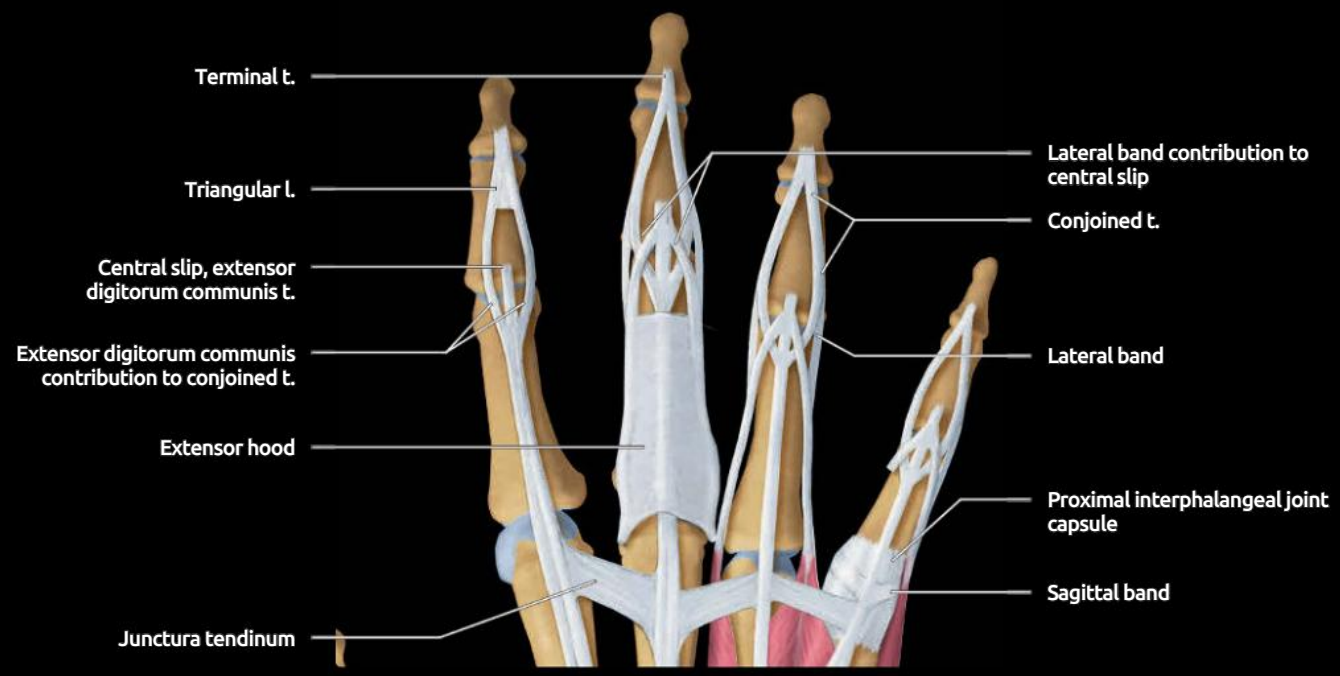

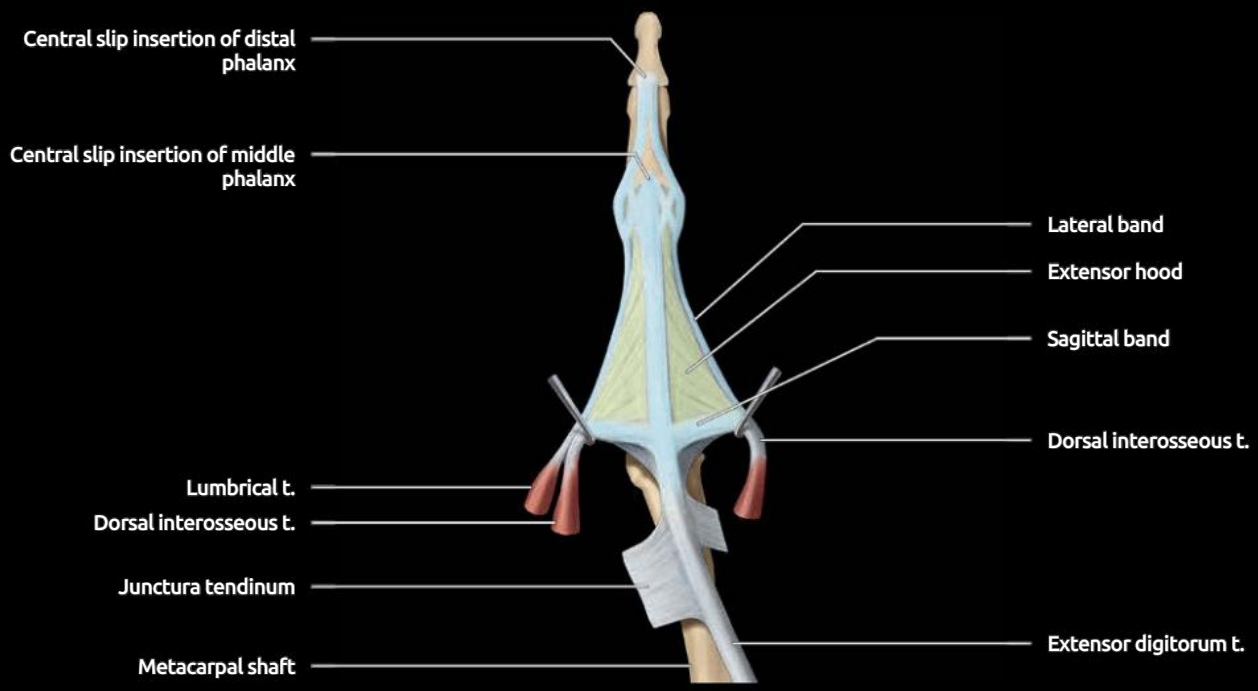

(Top) *Graphic shows the arrangement of the extensor tendon apparatus. The proximal central slip inserts at the middle phalangeal base. The extensor expansion (or hood) covers the proximal phalanx. The juncturae tendinum are thin fibrous bands that connect the tendons of extensor digitorum communis just proximal to the MCP joints. Note that, for the most part, no extensor tendon will be visible on the dorsal central aspect of the middle phalangeal shaft.* **(Bottom)** *Graphic shows extensor expansion, sagittal bands, and lateral slips of the middle finger. The dorsal interossei are inserted into the lateral bands on both sides of the middle finger. The lumbrical tendon is inserted into the radial lateral band. The palmar interossei do not insert into the middle finger. The sagittal bands are at the proximal end of the extensor hood. The sagittal bands and the juncturae tendinum serve to maintain the correct position of the extensor digitorum communis tendons.*

EXTENSOR APPARATUS, TRANSVERSE

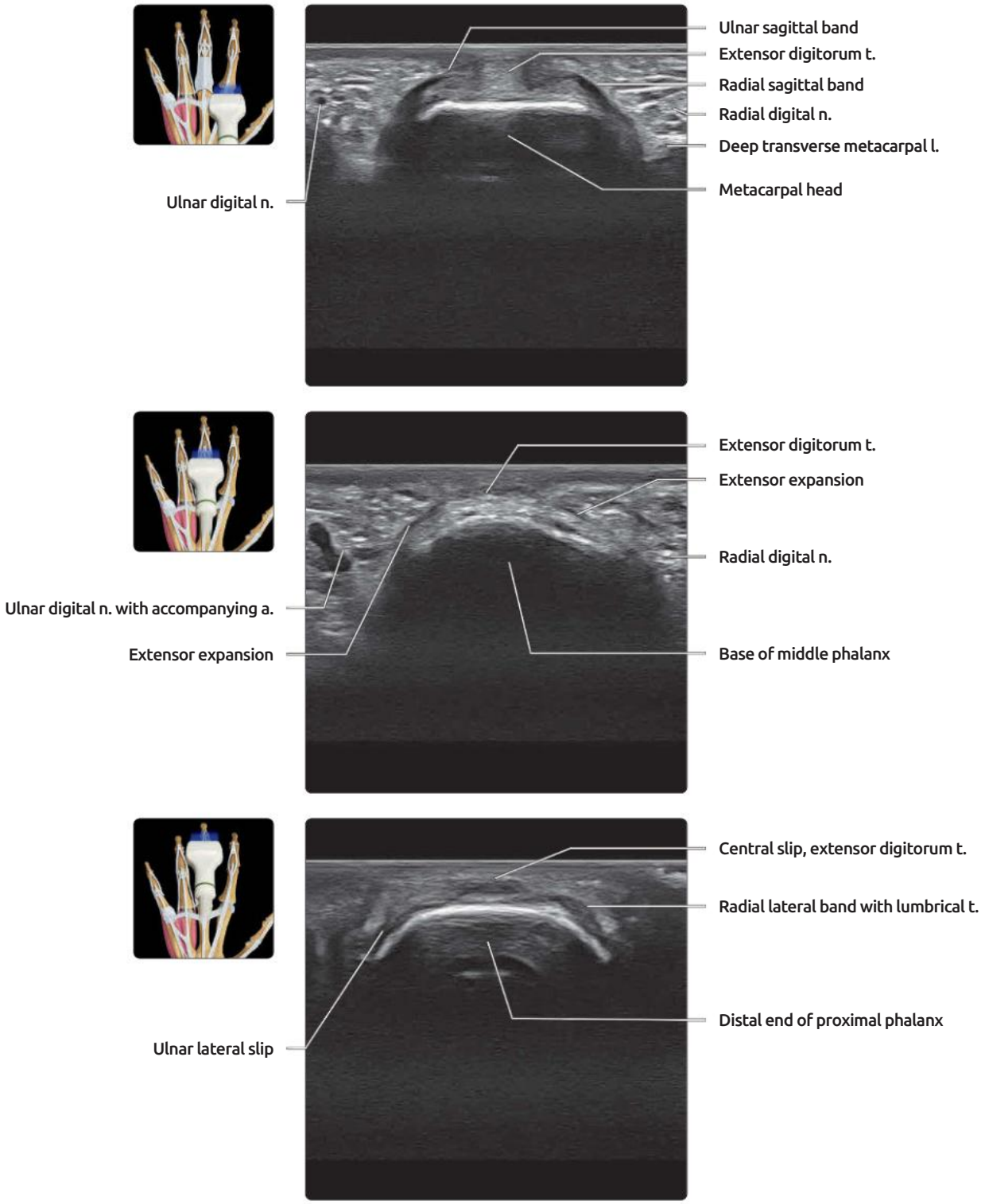

(Top) *Transverse US shows the extensor tendon with the sagittal bands laterally on the dorsum of the MCP joint. The sagittal bands prevent subluxation of the extensor tendons during MCP joint flexion.* **(Middle)** *Transverse US at the proximal end of the middle phalanx shows the thin extensor digitorum tendon with the extensor expansion bilaterally.* **(Bottom)** *Transverse US of the distal end of the proximal phalanx shows the central slip of the extensor digitorum tendon, which will insert more distally onto the middle phalangeal base. The radial and ulnar lateral bands are visible laterally. The radial lateral band is larger due to the attachment of the lumbrical tendon. The extensor digitorum tendon is not visible centrally on the dorsum of the middle phalanx as the extensor expansion comprises 2 lateral bands at this location. Such absence should not be mistaken for a tendon tear.*

EXTENSOR DIGITORUM TENDON, LONGITUDINAL

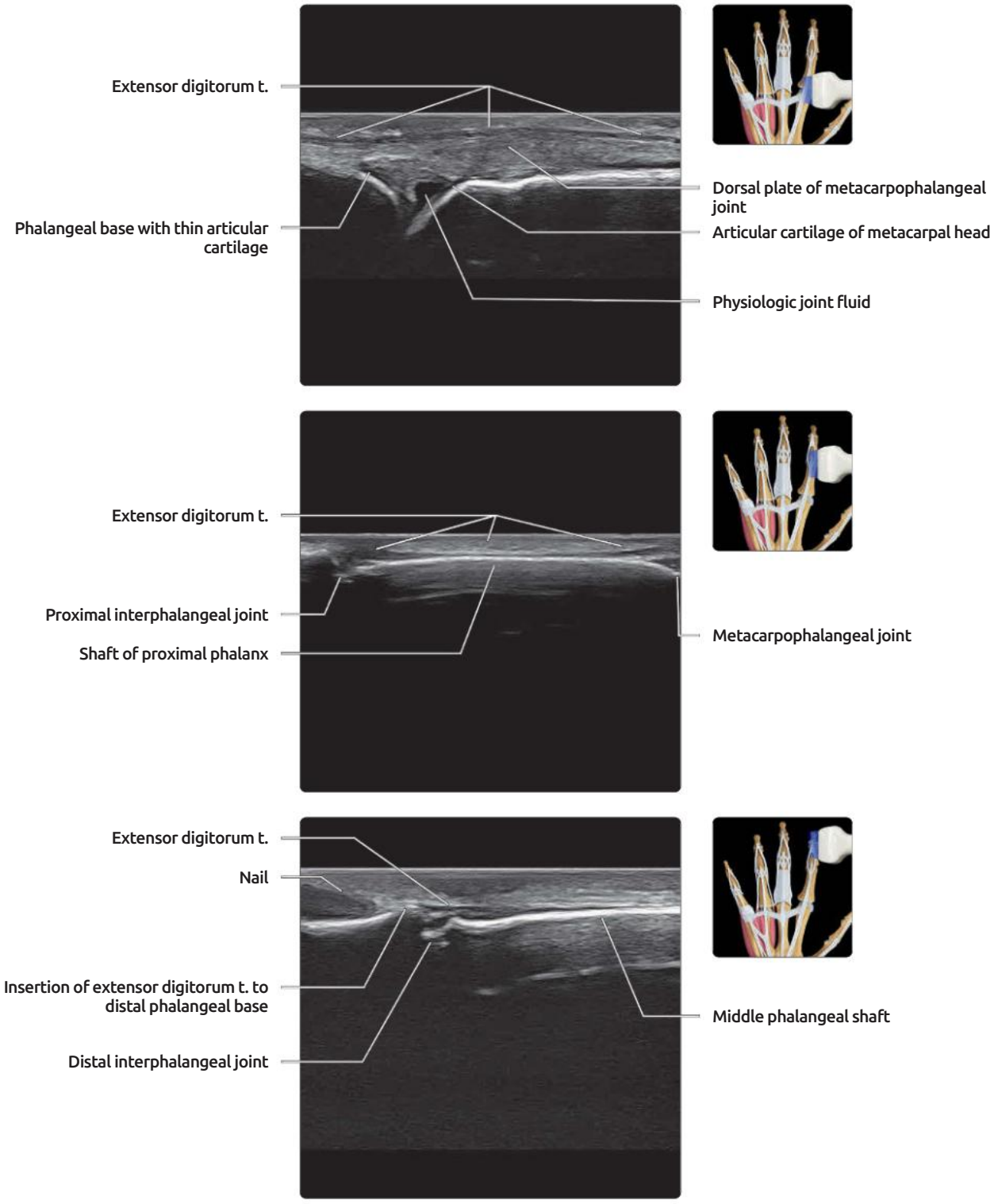

(Top) *Longitudinal US of the dorsal aspect of the MCP joint shows the thin extensor digitorum tendon overlying the dorsal aspect of the dorsal plate of the MCP joint. The dorsal plate is attached to the MCP joint capsule but not to the bone. It protects against hyperextension of the MCP joint.* **(Middle)** *Longitudinal US shows the thin extensor digitorum tendon on the dorsum of the proximal phalanx. This thin extensor digitorum tendon will not be visible on the dorsum of the middle phalanx as it comprises 2 lateral slips more distally.* **(Bottom)** *Longitudinal US shows the extensor digitorum tendon, which becomes visible again at the distal end of the middle phalanx due to convergence of the 2 lateral slips. The tendon inserts into the base of the distal phalanx just proximal to the nail bed.*

GROSS ANATOMY

ARTERIES OF UPPER LIMB

- **Brachial artery**
  - Continuation of axillary artery
  - Extends from lower border of teres major to neck of radius
    - Brachial artery lies superficial in its course in arm
  - Accompanies median nerve
- Profunda brachii: Main branch of brachial artery
  - Arises just distal to teres major, accompanies radial nerve, & passes backward in spiral groove on posterior surface of humerus
- Brachial artery covered by bicipital aponeurosis at elbow, where it may be compressed
- High takeoff of radial artery from brachial artery is common anatomical variant
- Brachial artery divides at neck of radius into radial & ulnar arteries
  - Ulnar artery is typically larger of 2 branches
- **Ulnar artery**
  - Ulnar artery initially passes inferiorly & medially, deep to ulnar head of pronator teres muscle
    - At this location, it is separated from median nerve, which lies above ulnar head of pronator teres muscle
    - Both ulnar artery & median nerve may be compressed by ulnar head of pronator teres giving rise to pronator teres syndrome
  - Ulnar artery gives rise to common interosseous artery, which divides into anterior & posterior interosseous arteries, which follow anterior & posterior interosseous nerves, respectively
  - More distally runs between flexor digitorum profundus muscle & superficialis muscles to meet ulnar nerve in midforearm
    - In proximal forearm & cubital tunnel, posterior ulnar recurrent artery is close to ulnar nerve
  - Terminates in superficial palmar arch of hand
    - 1 cm distal to deep palmar arch
    - Metacarpal shaft level, extending across palm from thumb web space
    - Lies deep to palmar aponeurosis but superficial to long flexor tendons & digital nerves
- **Radial artery**
  - Radial artery initially passes inferiorly & laterally from bifurcation at neck of radius, lying medial to biceps tendon
  - Covered proximally by brachioradialis muscle
    - In radial tunnel, recurrent branch of radial artery may, together with venae comitantes, compress superficial & deep branches of radial nerve as "leash of Henry"
  - Radial artery lies close to superficial branch of radial nerve in middle 1/3 of forearm, separating more distally as nerve moves dorsally
  - Distally at wrist, moves dorsally crossing floor of anatomical snuff box
  - Terminates in deep palmar arch of hand
    - 1 cm proximal to deep palmar arch
    - Carpometacarpal joint level
    - Lies deep to long flexor tendons & superficial to interossei muscles
- **Persistent median artery**
  - Persistent in 30% of subjects following course of median nerve
    - May terminate in forearm or continue to wrist
- **Digital arteries**
  - Common palmar digital arteries arise from superficial palmar arch
    - Run distally on surface of 2nd, 3rd, & 4th lumbrical muscles
    - Near metacarpophalangeal joint, each common digital artery divides into 2 proper digital arteries
    - Run distally in subcutaneous fat on sides of phalanges

VEINS OF UPPER LIMB

- **Superficial vein**
  - Dorsal venous network of hand formed on dorsum of hand by digital veins & dorsal metacarpal veins
  - Unites to form cephalic vein on radial side of wrist & basilic vein on ulnar side of wrist
    - Cephalic & basilic veins ascend proximally in subcutaneous tissues
- **Cephalic vein**
  - Ascends anterolaterally to antecubital fossa where is gives off medial cubital vein, which joins basilic vein
  - Continues ascent along arm to deltopectoral groove where it pierces clavipectoral fascia to drain into axillary vein
- **Basilic vein**
  - Ascends on medial side of forearm to anteromedial aspect of elbow where it receives medial cubital vein
  - Continues on medial aspect of arm until it pierces deep fascia to run cranially medial to brachial artery
  - Joins brachial vein & becomes axillary vein at lower border of teres major muscle
- **Deep veins**
  - Ascend Proximally in deep tissues
- **Brachial vein**
  - Forms deep venous system
  - Singular or paired veins, which continue to axilla
    - Brachial vein duplication is common
  - Accompanied by brachial artery & medial nerve

ANATOMY IMAGING ISSUES

Imaging Recommendations

- Arterial examination
  - In suspected thoracic outlet vascular compression syndromes, arteries are examined in various positions of shoulder abduction so that vascular compression may be accentuated
  - Angle of insonation should not be > 60°, as this will reduce sensitivity of Doppler & color flow signals
  - Color signal scale should match flow velocity
  - Doppler gate should be located at center of artery (or vein), as this is site of peak flow velocity
- Venous examination
  - Examination of upper limb veins is normally performed with patient supine & arm abducted to ~ 90°
    - Determine compressibility
    - Venous flow can be augmented by compressing muscles distally, clenching fist, or deep inspiration

ARTERIES OF SHOULDER AND PROXIMAL ARM

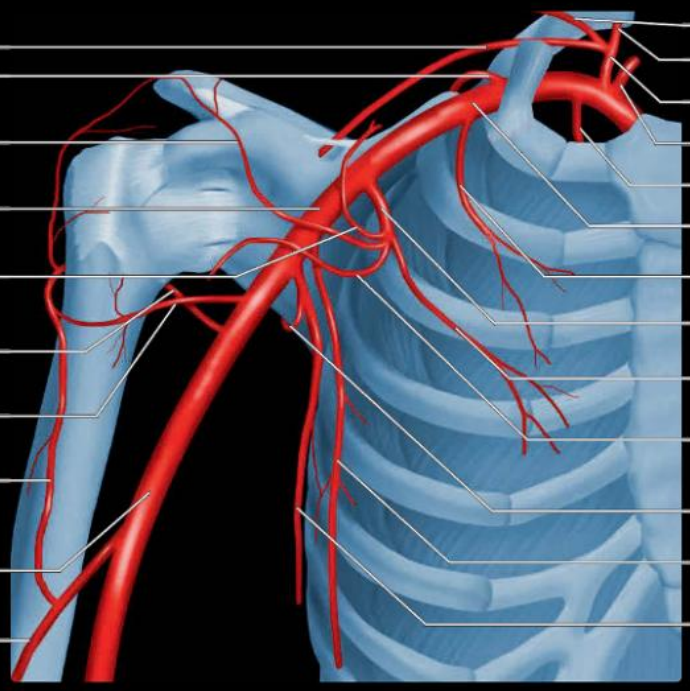

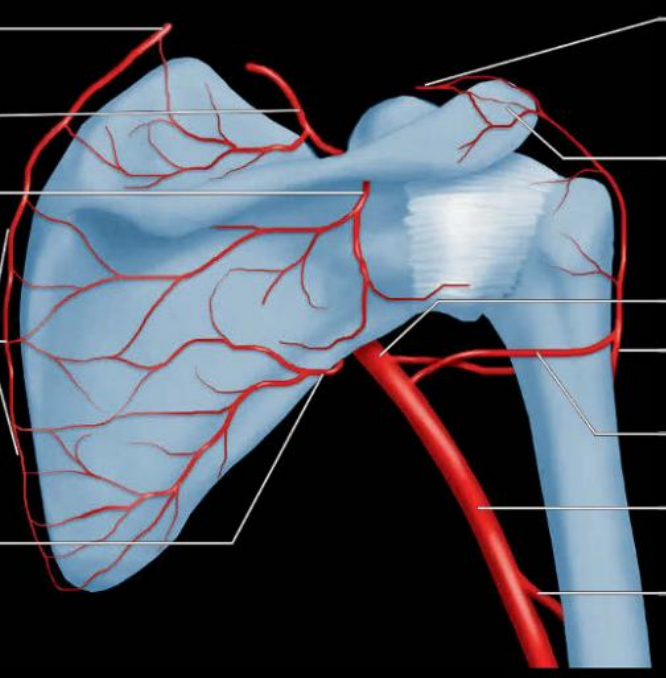

(Top) *Graphic shows arterial supply to the shoulder girdle region. The shoulder is predominantly supplied by the anterior and posterior circumflex humeral, suprascapular, and circumflex scapular arteries.* **(Bottom)** *Graphic shows arterial supply to the parascapular region. Extensive collateral blood vessels include anastomoses with intercostal arteries.*

SUBCLAVIAN AND AXILLARY ARTERIES

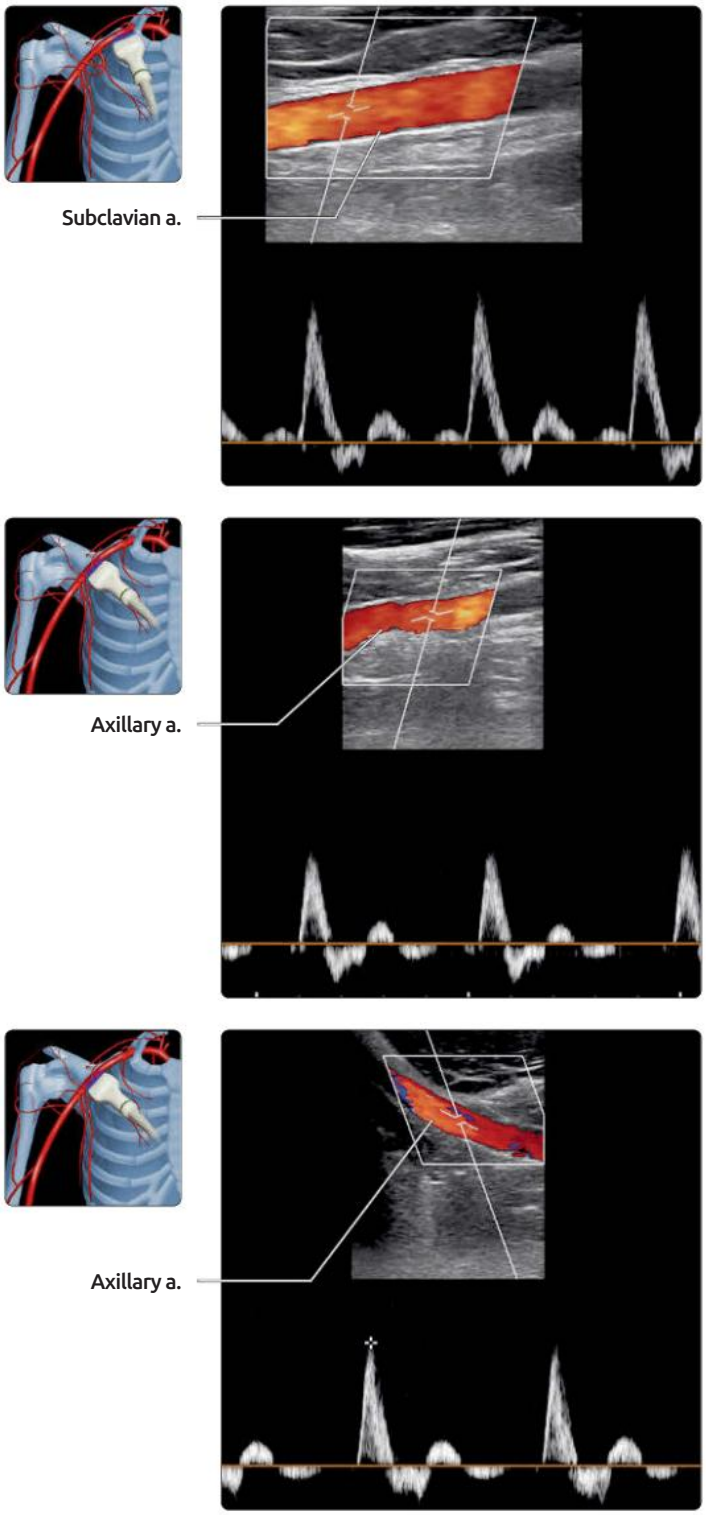

(Top) *Doppler spectral analysis of the subclavian artery in an arm neutral position is shown. The systolic velocity is 117 cm/s. Normal arterial waveform is shown.* **(Middle)** *Spectral Doppler US of the axillary artery in a neutral position is shown. These subclavicular portion of the axillary artery just beyond the 1st rib has been examined. The maximum systolic velocity is 120 cm/s* **(Bottom)** *Spectral Doppler analysis of the axillary artery in an arm abducted position is shown. Maximum systolic velocity is 107 cm/s. Normal arterial waveform is maintained. There is no evidence of arterial stenosis.*

AXILLARY AND SUBCLAVIAN VEINS

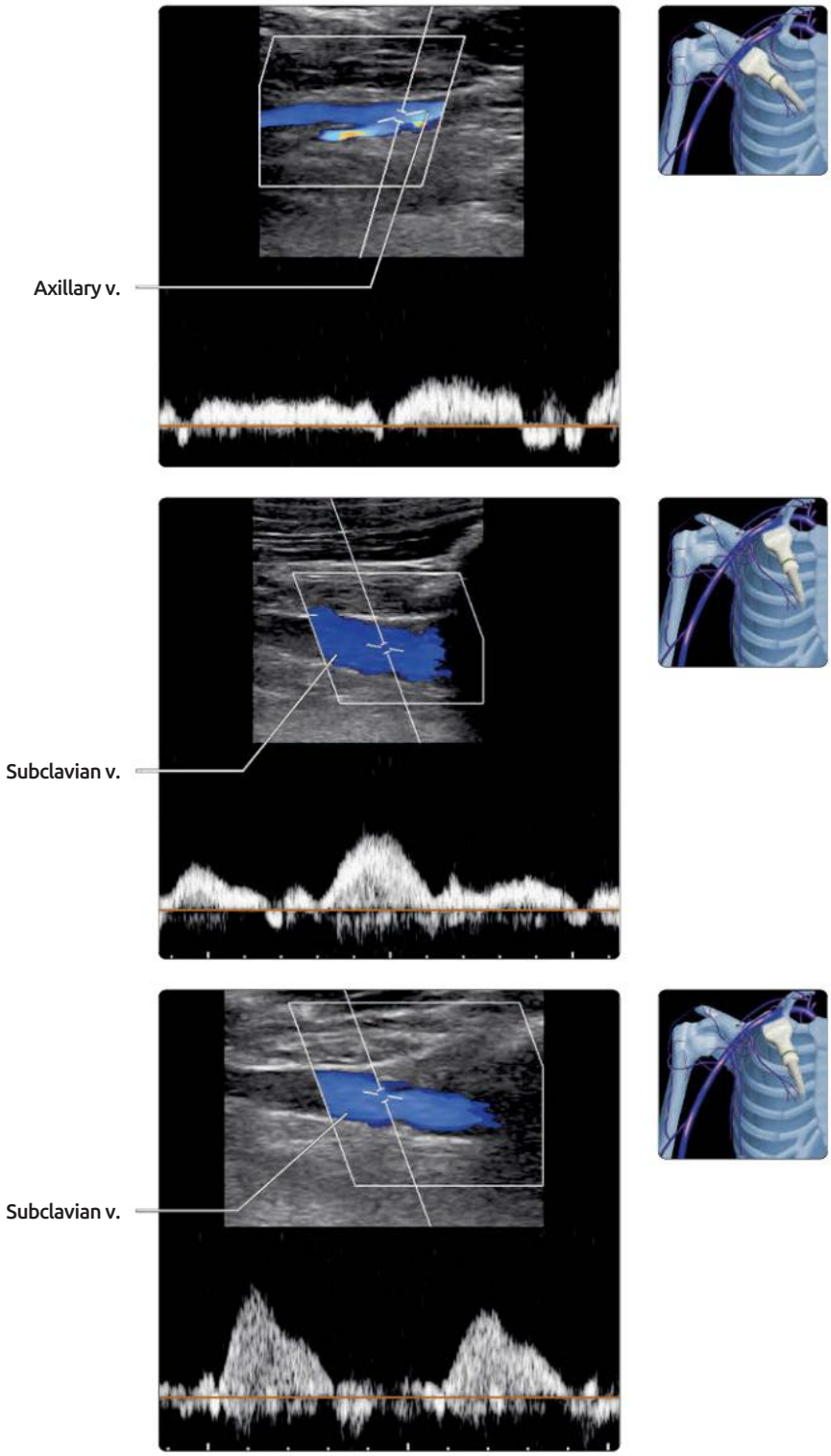

(Top) *Longitudinal spectral Doppler analysis of the axillary vein in a neutral position is shown. The maximum velocity is 36.3 cm/s. Normal phasic venous waveform is shown.* **(Middle)** *Spectral Doppler analysis of the subclavian vein with the arm in a neutral position is shown. Normal phasic venous waveform is also shown.* **(Bottom)** *Spectral Doppler analysis of the subclavian vein with the arm in an abducted position is shown. Maximum velocity is 41 cm/s. There is no dampening of the normal venous waveform. There is no evidence of venous obstruction.*

ARM ARTERIES AND VEINS

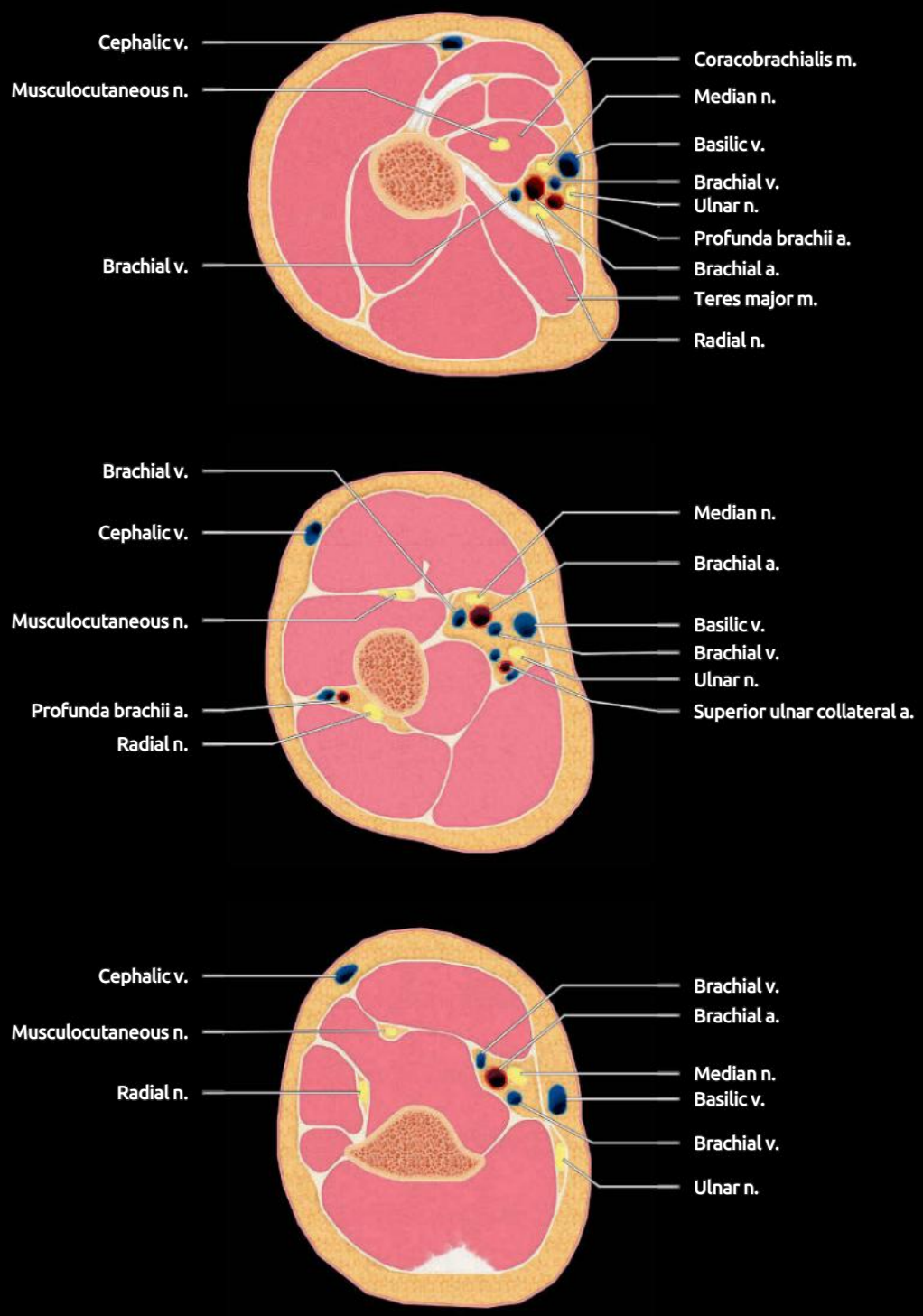

(Top) *Axial graphic of the proximal arm shows how the brachial artery accompanies the median nerve. The deep brachial artery (profunda brachii artery) is the main branch of the brachial artery and accompanies the radial nerve. The basilic vein lies medially and the cephalic vein anterolaterally.* **(Middle)** *Axial graphic of the midarm shows how the profunda brachii artery accompanies the radial nerve and passes backward in the spiral groove of the humeral shaft before dividing into medial and radial collateral arteries. The superior ulnar collateral artery arises from the brachial artery and descends with the ulnar nerve.* **(Bottom)** *Axial graphic shows the arm at the distal humeral level. The median nerve is on the medial side of the brachial artery at this level.*

BRACHIAL ARTERY BIFURCATION

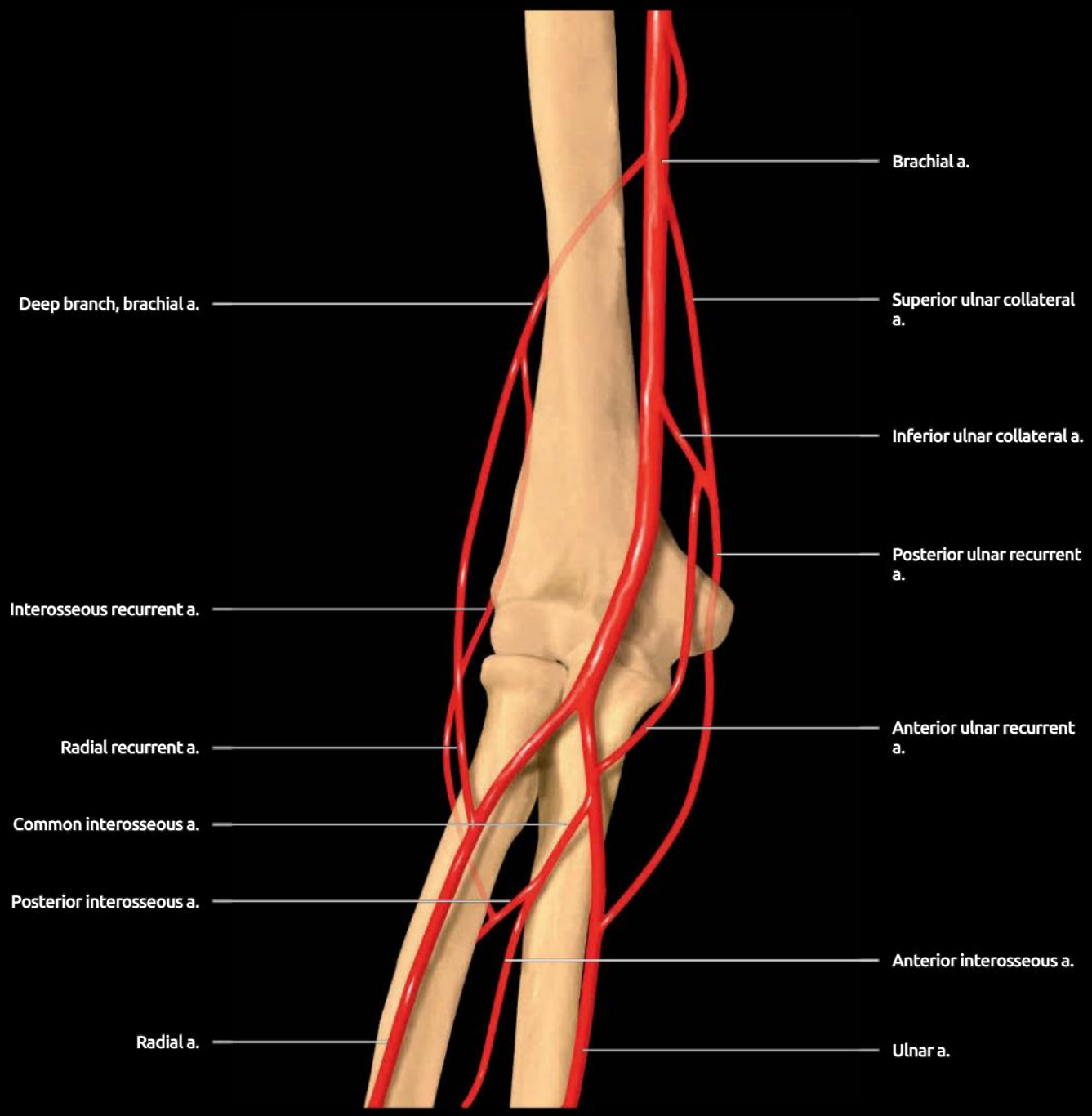

The brachial artery divides into a slightly larger ulnar and slightly smaller radial artery. A brachial artery bifurcation proximal to the antecubital fossa is known as a high brachial bifurcation. This variation is seen in 20% of upper extremity vascular mapping in US examinations. It may lead to errors in blood pressure measurement. It is not invariably bilateral.

BRACHIAL ARTERY

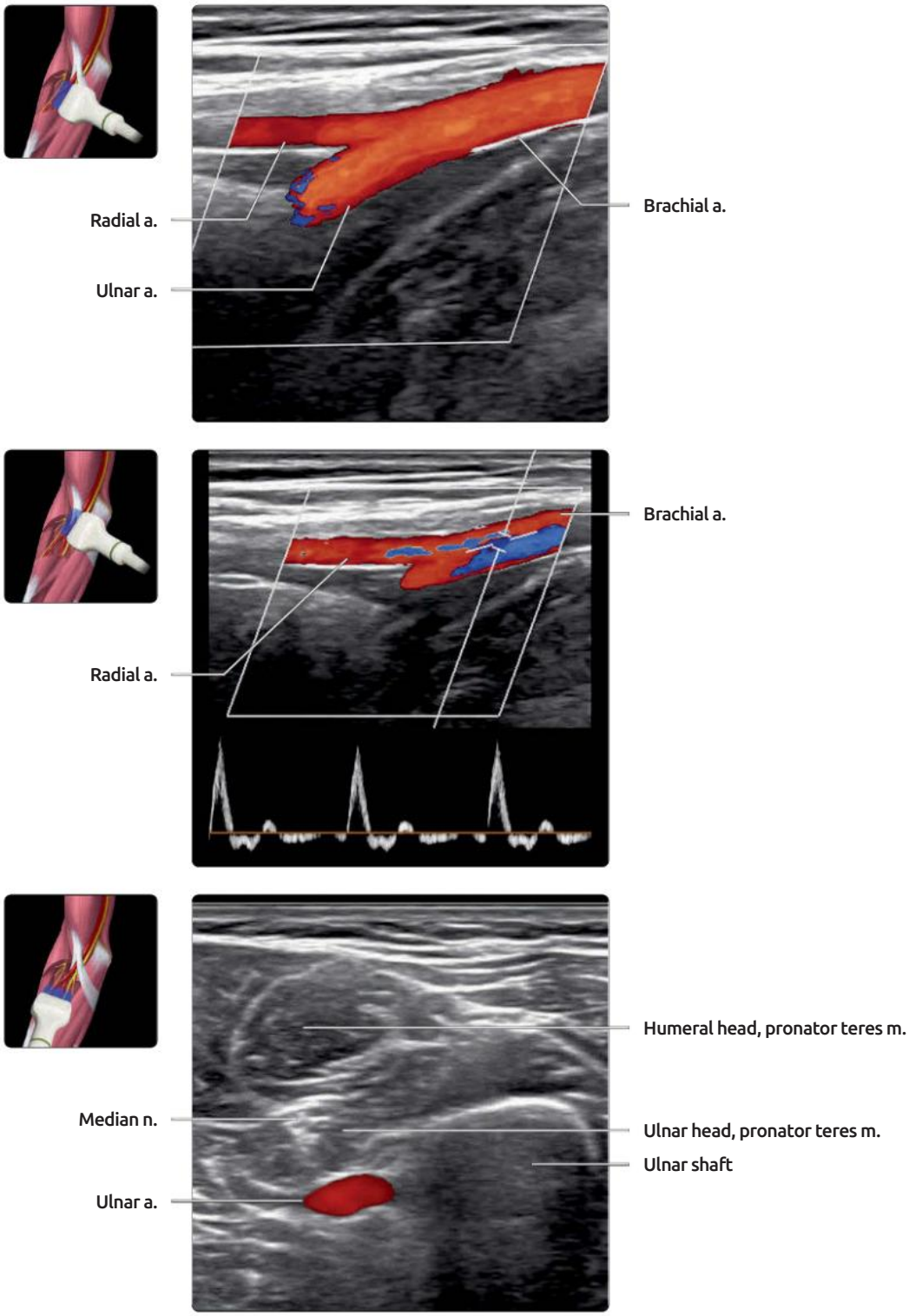

(Top) *Longitudinal color Doppler US shows the brachial artery dividing into a smaller radial and larger ulnar artery. This is the normal arrangement.* **(Middle)** *Longitudinal spectral Doppler analysis shows a normal spectral arterial waveform of the brachial artery just proximal to the bifurcation.* **(Bottom)** *Transverse color Doppler US just distal to the elbow shows how the median nerve is separated from the underlying ulnar artery by the ulnar head of the pronator teres muscle. The ulnar artery may be compressed by a hypertrophied ulnar head of the pronator teres muscle at this location. This is one cause of pronator teres syndrome.*

FOREARM ARTERIES AND ACCOMPANYING NERVES

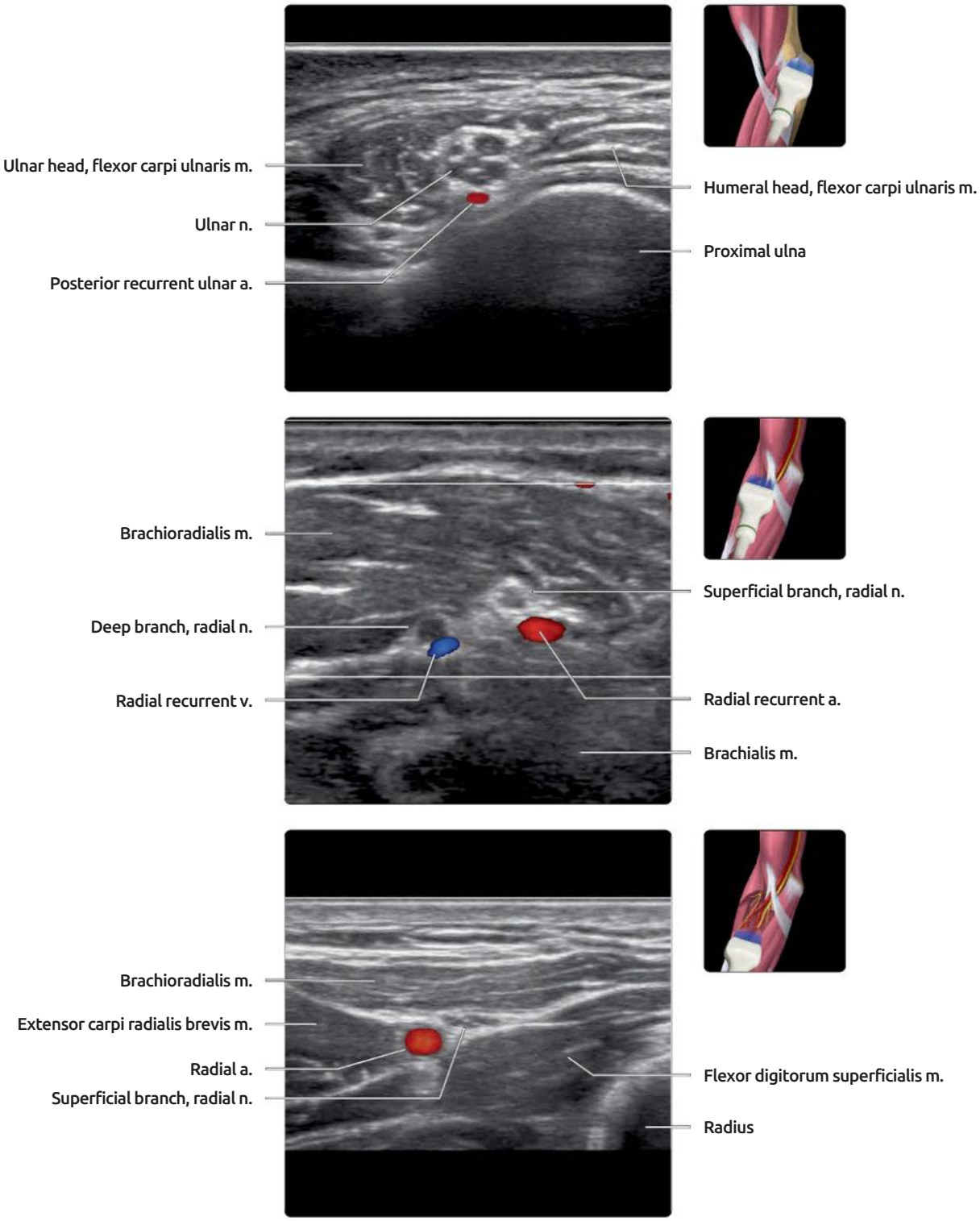

(Top) *Transverse color Doppler US at the outlet of the cubital tunnel shows the posterior recurrent ulnar artery (PURA) just deep to the ulnar nerve between the ulnar and humeral heads of the flexor carpi ulnaris muscle. The arcuate ligament passes over the ulnar nerve at this location. This is the 2nd most common site of ulnar nerve compression at the elbow region.* **(Middle)** *Transverse color Doppler US of the radial tunnel is shown. The radial tunnel is between the lateral intermuscular septum of the distal arm and the proximal end of the supinator tunnel. The radial nerve has divided into superficial and deep branches. Occasionally, an abundance of vessels from the transverse muscle branches of the radial recurrent artery and accompanying vein can occur in this area known as the "leash of Henry". Such vessels may lead to kinking or compression of the radial nerve branches.* **(Bottom)** *Transverse US of the midforearm shows the superficial branch of the radial nerve closely applied to the radial artery.*

HAND ARTERIES

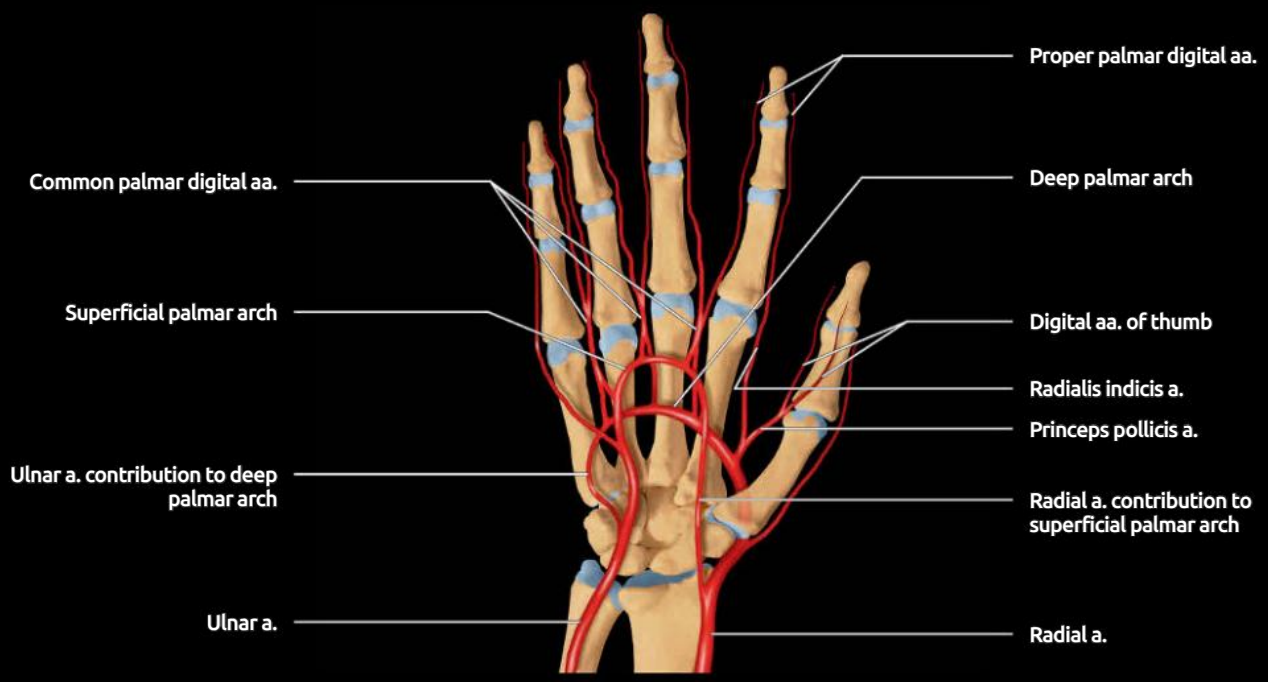

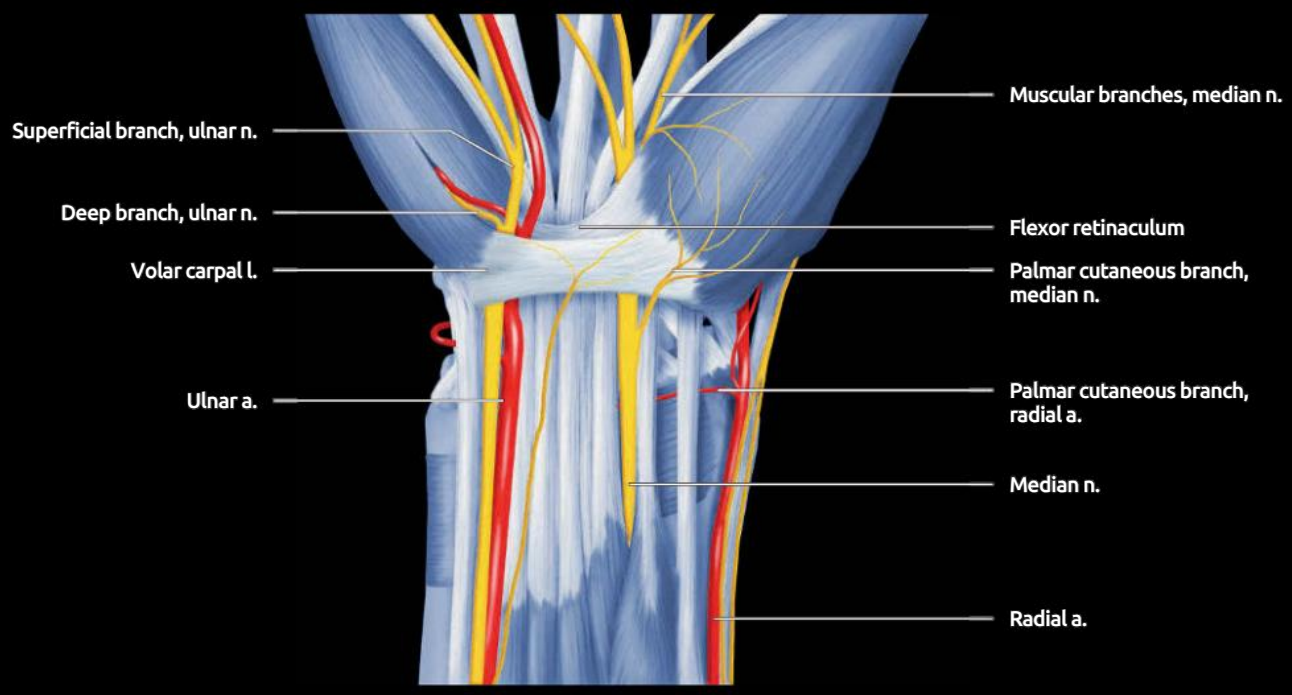

(Top) *Graphic of hand arteries shows how, after contributing to the superficial palmar arch at the level of the radial styloid, the radial artery travels around the radial aspect of the wrist deep in the anatomical snuffbox. On the dorsal aspect of the wrist, it passes into the 1st web space between the heads of the 1st dorsal interosseous muscle and between the transverse and oblique heads of the adductor pollicis muscle to form the deep palmar arch. The superficial palmar arch is located at the middle skin crease of the palm ("Kaplan cardinal line"). The deep palmar arch is just proximal to this location.* **(Bottom)** *Graphic shows the relationship of the nerves and arteries to the "volar carpal ligament," i.e., the superficial fibers of the flexor retinaculum that form the roof of Guyon canal. The ulnar artery passes deep to the volar carpal ligament along with the ulnar nerve before branching into superficial and deep branches that contribute to the superficial and deep palmar arches.*

PERSISTENT MEDIAN ARTERY, MR ANGIOGRAPHY

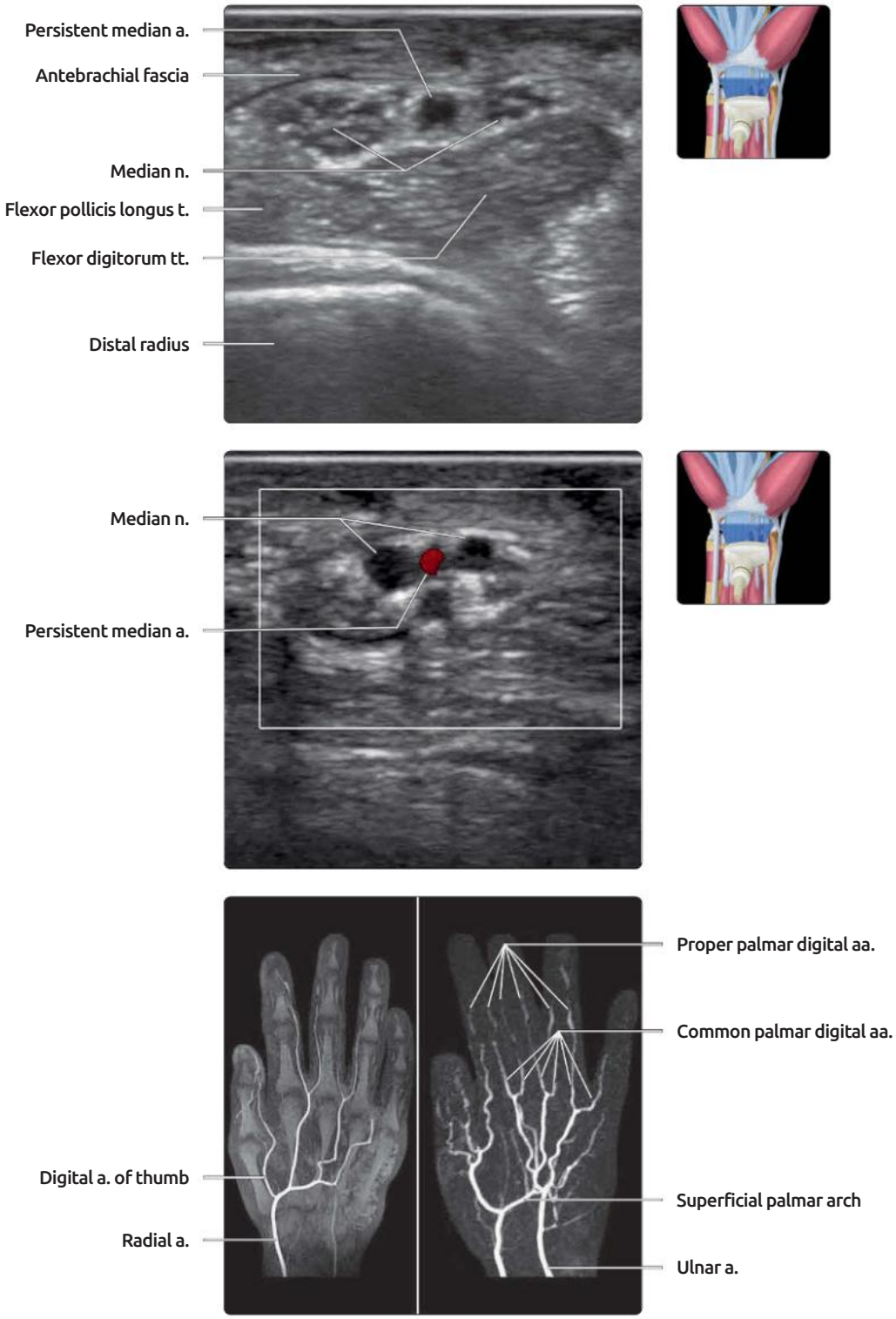

(Top) *Transverse US just proximal to the carpal tunnel shows a bifid median nerve with an intervening persistent median artery. These all lie deep to the antebrachial fascia. The prevalence of bifid median nerve in the normal population is ~ 15%. The prevalence of a persistent median artery is 30%.* **(Middle)** *Transverse color Doppler US shows normal flow within the median artery. Rarely, thrombosis of the persistent median artery may occur due to repetitive compression or trauma. This is an uncommon secondary cause of carpal tunnel syndrome.* **(Bottom)** *Coronal MR angiograms of 2 different hands is shown. The deep palmar arch is not seen on either image. MR angiography will not always show all arteries depending on relative flow. Generally, CT angiography is best at showing the morphology and providing a roadmap of the large or medium-sized upper limb arteries, while MR angiography is best for the hand arteries. US is best for assessing flow dynamics or assessing specific arterial areas.*

SUPERFICIAL VEINS FOREARM

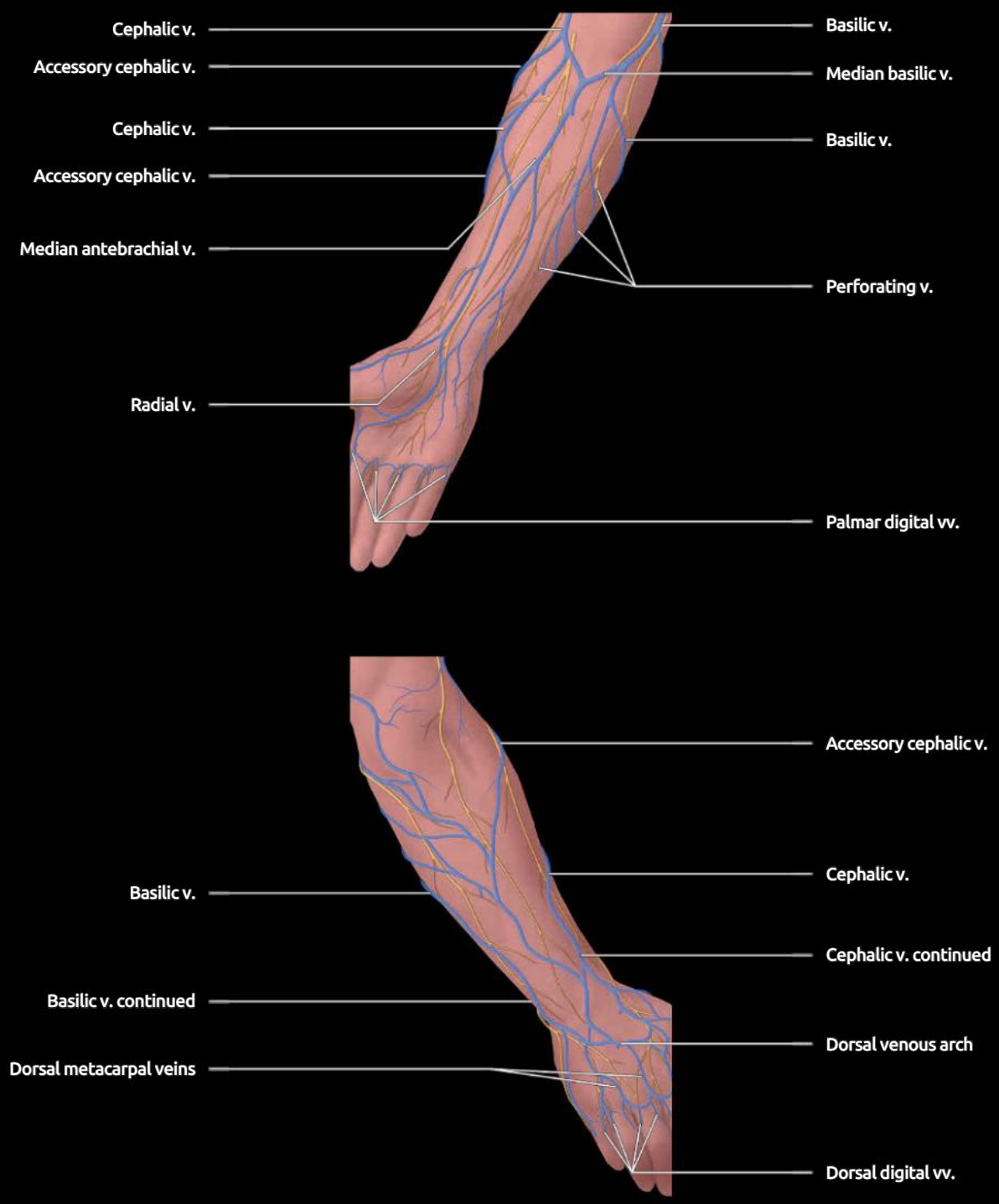

(Top) *Graphic shows the superficial venous system of the forearm. The most important superficial vein of the forearm and arm is the cephalic vein, which drains the radial aspect of the dorsal venous network of the hand. The cephalic vein extends from the dorsoradial aspect of the wrist to the anteromedial aspect of the elbow. It continues to ascend on the lateral aspect of the arm, moving anteromedially in the upper arm to enter the axillary vein just below the clavicle. The deep ulnar and radial veins drain the deep palmar arch and run in in pairs with the corresponding arteries. Perforating veins unite the superficial and deep venous systems.* **(Bottom)** *Graphic shows superficial venous system on the posterior aspect of the forearm. The basilic vein drains the ulnar margin of the dorsal venous plexus. At the elbow, it communicates with the cephalic vein.*

BRACHIAL AND CEPHALIC VEINS

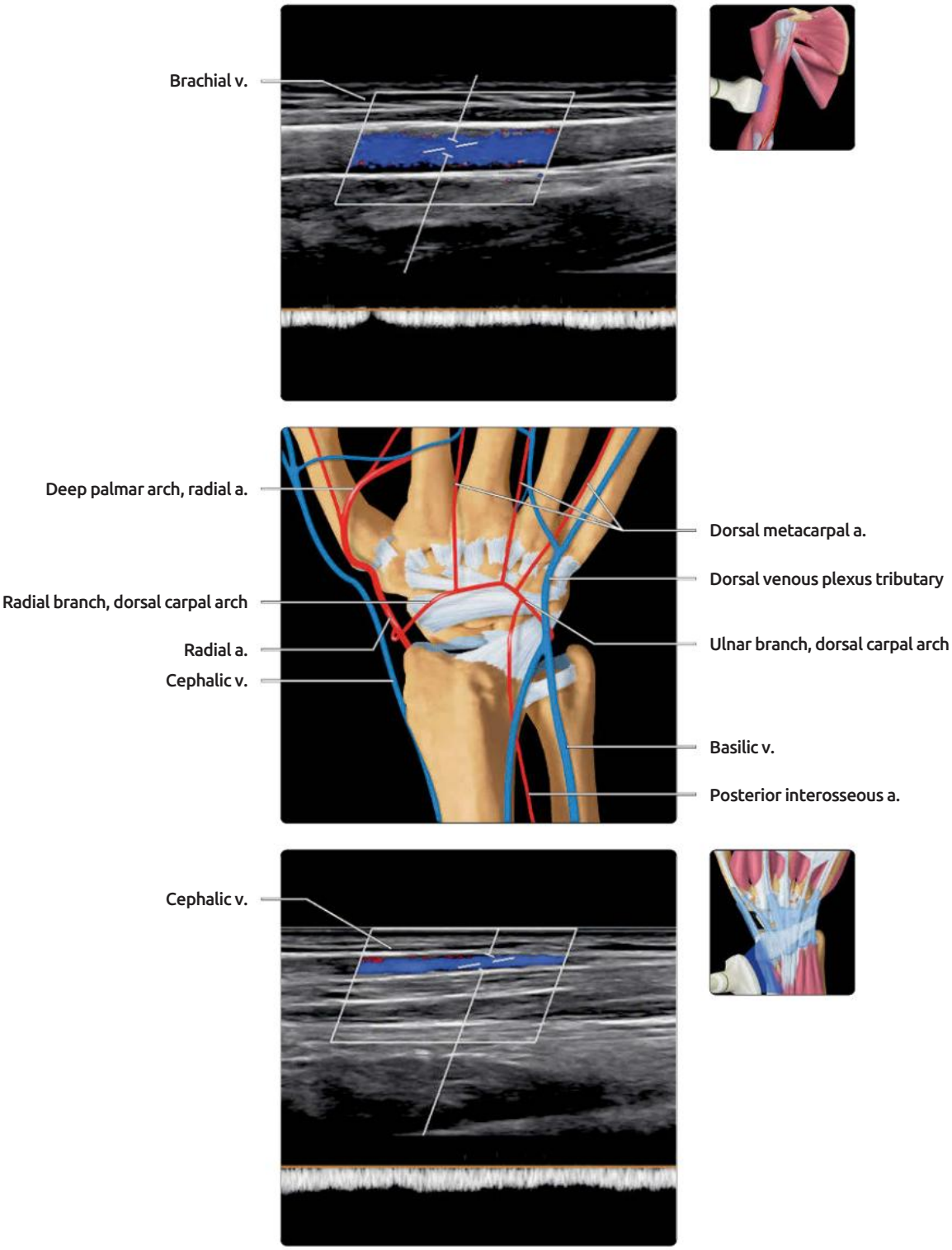

(Top) *Longitudinal color Doppler US of the brachial vein shows normal monophasic venous flow. The velocity is 10m/s. The normal width of the brachial vein is <2.7mm. The brachial vein is part of the deep venous system and may be paired or singular.* **(Middle)** *Graphic shows the dorsal carpal arch, which is formed from the dorsal carpal ulnar and radial arteries. The deep venous drainage of the hands is via the radial and ulnar veins with travel in pairs along with the radial and ulnar arteries in the deep tissues. The superficial drainage is via the cephalic and basilic veins, which travel in the subcutaneous tissues with no corresponding arteries.* **(Bottom)** *Longitudinal color Doppler US of the distal forearm shows normal monophasic venous flow in the cephalic vein. The velocity is 10m/s.*

GROSS ANATOMY

Overview

- Brachial plexus is neural highway to upper limbs
  - Formed from C5-T1 ventral rami combining to form 3 trunks, 6 divisions, 3 cords, & 5 terminal branches (classic pattern)
    - 5 terminal branches are ulnar, median, musculocutaneous, axillary, & radial nerves
  - Many variations in this classic anatomy exist
    - Cannot rely on having definite number of trunks, divisions, or cords at any particular location
  - Roots, trunks, & divisions are monofascicular & hypoechoic, while cords & terminal branches are polyfascicular & hyperechoic

US Anatomy

- 5 specific areas should be assessed to ensure complete evaluation
  - Extraforaminal, interscalene, supraclavicular, infraclavicular, & axillary areas
- **Extraforaminal area (5 roots)**
  - Single large anterior ramus emerging from spinal root levels C5-T1
    - C5 & C5 roots seen between anterior & posterior tubercles of C5 & C6 vertebrae
    - Anterior tubercle of C7 transverse process is small; so C7 root is seen lying anterior to large posterior tubercle
    - C8 & T1 roots are more difficult to see due to their deep location
    - Cross-sectional area (CSA) of C7 & C8 roots (~ 11 mm²) > C6 (~ 9 mm²) > C5 root (~ 6 mm²)
- **Interscalene area (5 roots form 3 trunks)**
  - Between scalenus anterior muscle anteromedially & scalenus medius muscle posterolaterally
  - Roots unite to form trunks in more distal interscalene area
    - **Upper (C5-C6), middle (C7), lower (C8, T1) trunks**
    - CSA of upper trunk (~ 17 mm²) > middle & lower trunks (~ 14 mm²)
    - Upper trunk or C5, C6 roots may pass through or anterior to anterior scalene muscle
    - Dorsal scapular artery frequently runs posteriorly between upper & middle trunks
  - Upper trunk gives rise to suprascapular nerve
    - Normal suprascapular nerve CSA is 2.8 ± 0.8 mm²
  - Interscalene triangle is common site for nerve block
- **Supraclavicular area (6 divisions)**
  - Trunks divide into anterior & posterior divisions in supraclavicular fossa; 3 trunks form 6 divisions
  - Lie posterior & superoposterior to subclavian artery
  - Anterior divisions innervate anterior (flexor) muscles
  - Posterior divisions innervate posterior (extensor) muscles
  - Transverse cervical artery often loops over divisions
  - Costoclavicular gap is between clavicle & 1st rib
    - Narrowest passageway for brachial plexus
    - Can be narrowed with fracture of clavicle or 1st rib
    - Not possible to see costoclavicular gap with US
- **Infraclavicular area (3 cords)**
  - Passageway between supraclavicular fossa & apex of axilla
  - Also called retropectoralis minor space or subcoracoid space
  - 6 divisions form 3 cords, located lateral, medial, & posterior to axillary artery
    - Lateral & medial cords innervate flexor muscles
    - Posterior cord innervates extensor muscles
  - Cords tend to be more hyperechoic than hypoechoic trunks or divisions
    - Brachial plexus components become more fascicular & contain more connective tissue distally
      - Roots are monofascicular & hypoechoic, while terminal branches are polyfascicular & hyperechoic
  - Pectoralis major muscle overlies cords medially, pectoralis minor muscle overlies cords laterally
- **Axillary area (5 terminal branches)**
  - Pyramidal space with apex superomedially
  - **Lateral cord** gives rise to median nerve & musculocutaneous nerve (C5-C6)
  - **Medial cord** gives rise to median nerve & ulnar nerve (C8-T1)
  - **Posterior cord** gives rise to axillary nerve (C5-C6), radial nerve (C5-T1), thoracodorsal nerve (C6-C8) as well as upper (C6-C7) & lower (C5-C6) subscapular nerves
  - Both lateral & medial cords contribute to median nerve
  - **Nerves are arranged around axillary artery** with median nerve at 10-11 o'clock, ulnar nerve at 1-2 o'clock, & radial nerve at 4-6 o'clock
    - Median nerve lies closest to biceps & coracobrachialis muscles
    - This neural arrangement is quite constant, seen in ~ 80% of patients
  - In most cases, musculocutaneous nerve branches early from lateral cord
    - Continues distally with median nerve in 30% of patients
    - Musculocutaneous nerve runs between coracobrachialis & biceps muscles before piercing coracobrachialis muscle

ANATOMY IMAGING ISSUES

Imaging Approaches

- US is efficient way of assessing brachial plexus
  - Excellent 1st-line investigation for most pathologies
- Always start with examining contralateral asymptomatic or less symptomatic side
  - Good side-to-side symmetry of brachial plexus appearances in normal subjects
- Routinely evaluate extraforaminal (roots), interscalene (trunks), supraclavicular (divisions), infraclavicular (cords), & axillary (terminal branches) areas
- Understand that considerable variation exists in normal neural anatomy of brachial plexus
- Remember that brachial plexus is not isolated group of nerves
  - Many neural pathologies (inflammatory polyneuropathy, neuralgic amyotrophy) may also affect nerves beyond brachial plexus (extraplexal nerves)

BRACHIAL PLEXUS

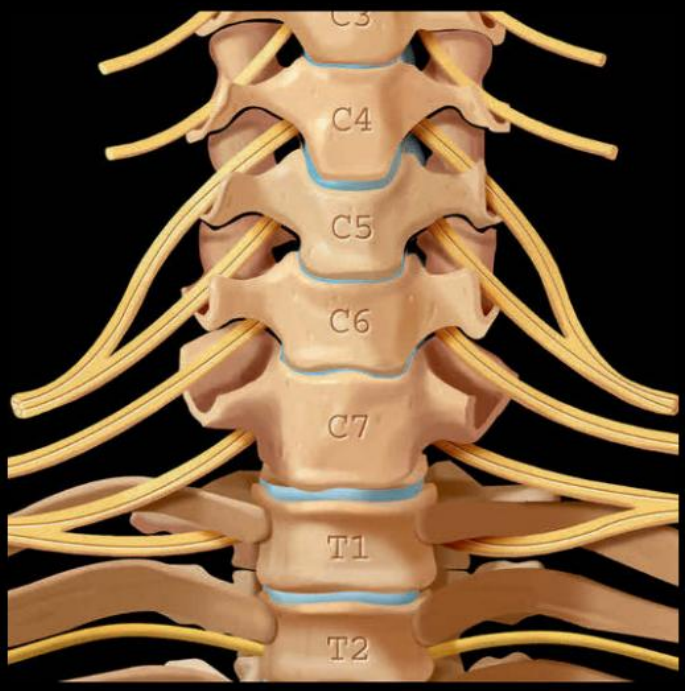

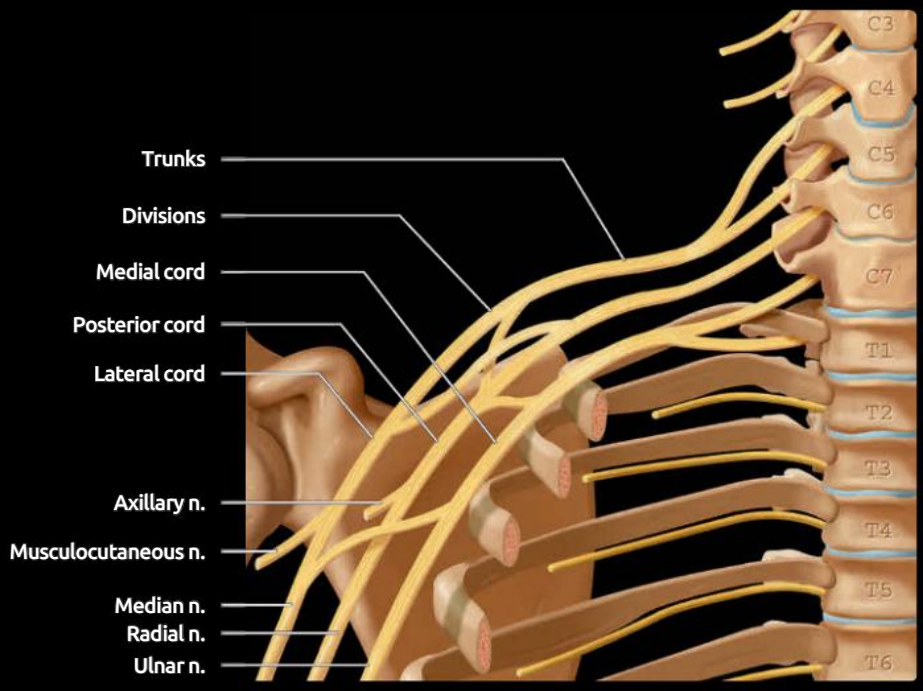

(Top) *Graphic of cervical spine and supraclavicular brachial plexus shows the C5-T1 ventral rami combining to form the brachial plexus. C5 nerve root exits out through the C4/5 neural foramen. C5-C6 ventral rami form the upper trunk, C7 the middle trunk, and C8-T1 the lower trunk.* **(Bottom)** *Graphic of the brachial plexus demonstrates the more distal plexus elements extending to the axilla. The trunks divide into posterior and anterior divisions. The divisions combine to form the cords. The posterior cord forms the radial and axillary nerves. The medial cord forms the ulnar nerve, and the lateral cord forms the musculocutaneous nerve. The median nerve is formed from contributions of both the medial and lateral cords.*

BRACHIAL PLEXUS AND TERMINAL BRANCHES

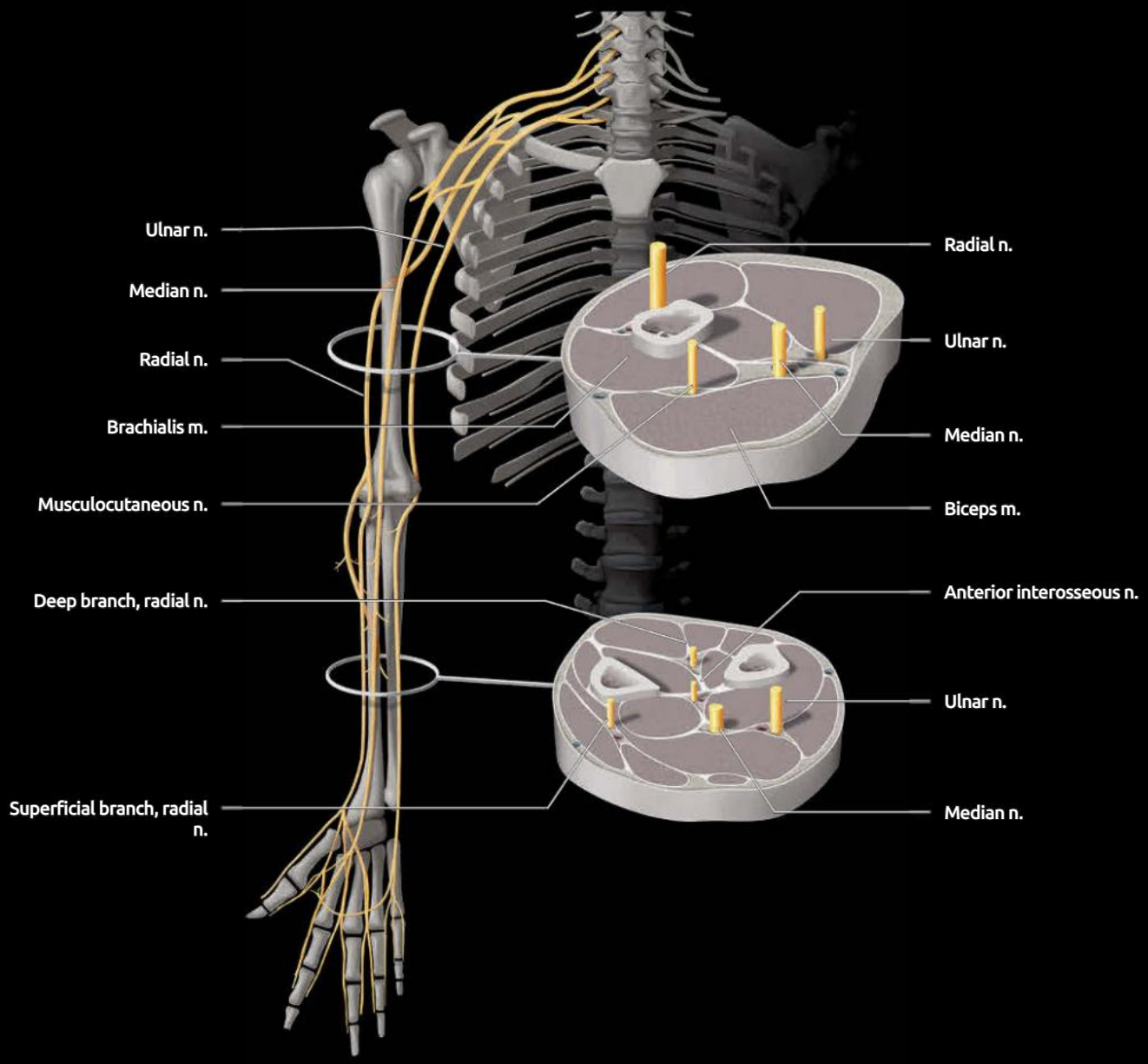

Graphic shows 3 of the 5 terminal branches of the brachial plexus (median, radial, and ulnar nerves) as they course down the arm. The other 2 terminal branches are the musculocutaneous and axillary nerves. The axillary nerve innervates the teres minor and deltoid muscles, while the musculocutaneous nerve innervates the 3 muscles of the anterior compartment of the arm, namely the coracobrachialis, biceps, and brachialis muscles.

BRACHIAL PLEXUS OVERVIEW

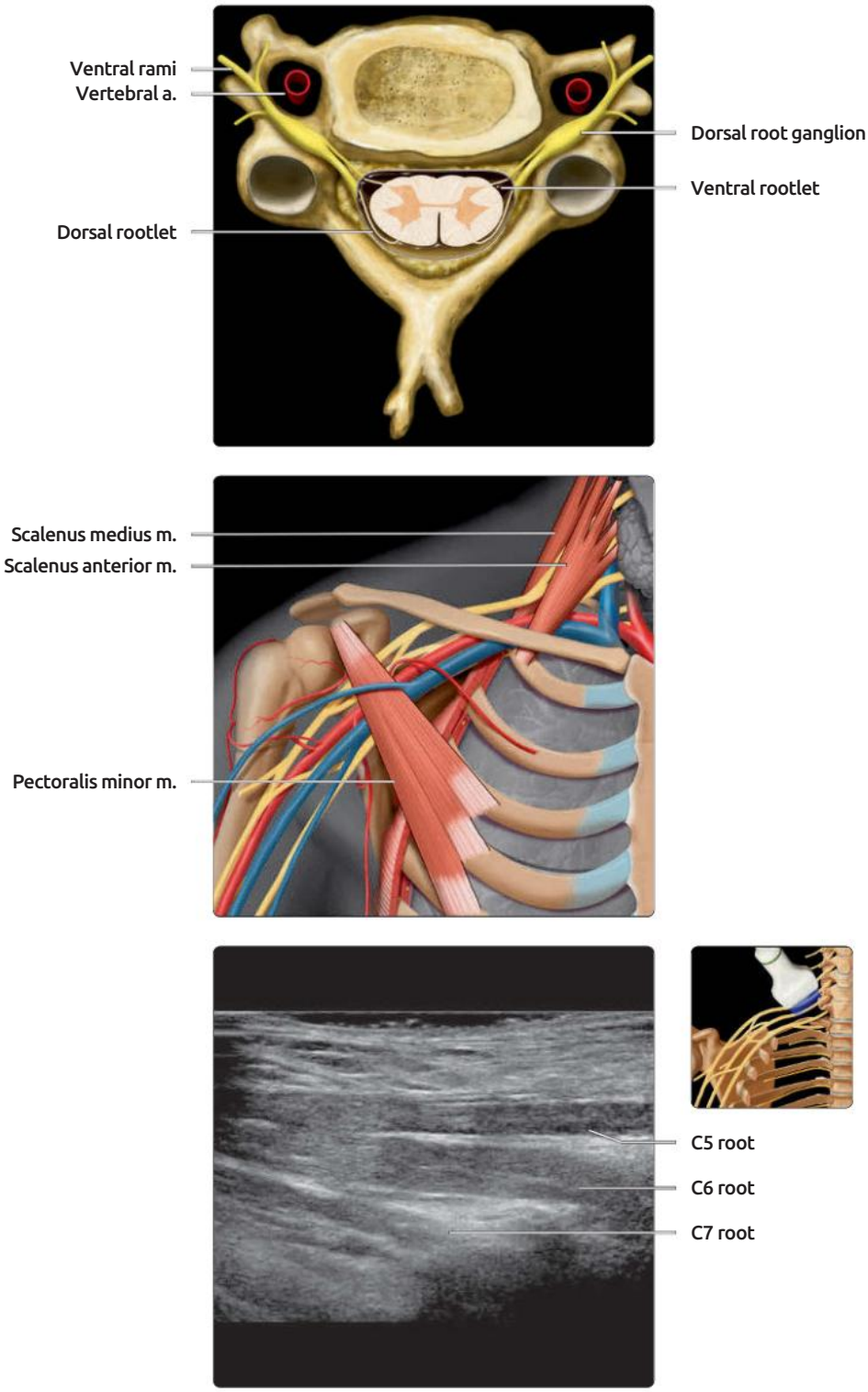

(Top) *Graphic shows the anterior and posterior rootlets emerging from the spinal cord. The roots unite within the spinal ganglia from which emerge the larger ventral and smaller dorsal rami. The brachial plexus is formed from the ventral rami of the C5-T1 roots. The ganglia and nerve rootlets are not part of the brachial plexus. The vertebral arteries within the transverse foramina of the transverse processes are also depicted.* **(Middle)** *Graphic shows the relationship of the brachial plexus to the arteries, veins, muscles, skeleton of the thoracic outlet, supraclavicular fossa, and axillary regions.* **(Bottom)** *Longitudinal US shows the C5, C6, and C7 roots arising from the neural foramina. The brachial plexus extends from beyond the spinal ganglia where the ventral rami become known as the roots. The brachial plexus is generally scanned in a transverse rather than a longitudinal section. Longitudinal scanning of the roots is most helpful when looking for a root avulsion or assessing the location of nerve sheath tumors.*

TRANSVERSE US ROOTS

(Top) *Transverse US of the C7 root is shown. The C7 root passes anterior to the large posterior tubercle (outlined) of the C7 transverse process (thumbs-up sign). The C7 anterior tubercle is absent or rudimentary. The vertebral artery is located anterior to the C7 root. At C6 and C5, the vertebral artery is within the foramen transversarium of the transverse process.* **(Middle)** *Transverse US shows the C6 root passing between the anterior and posterior tubercles of the C6 transverse process (V-sign, outlined).* **(Bottom)** *Transverse US shows the C5 root passing between the anterior and posterior tubercles of the C5 transverse process (outlined). The tubercles of the transverse processes become smaller and more closely aligned from C6 to C5 to C4.*

TRANSVERSE US TRUNKS

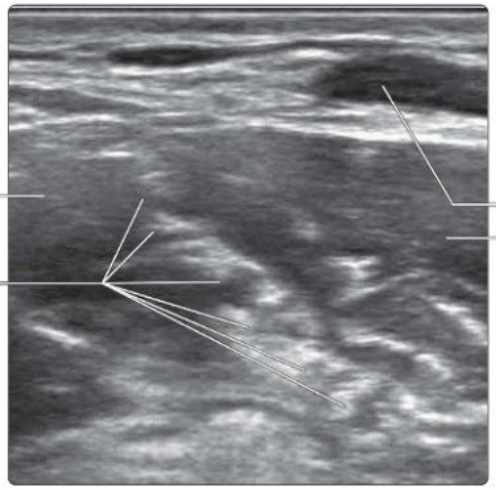

(Top) *Transverse US at interscalene level shows the upper, middle, and lower trunks ("traffic light sign") of the brachial plexus between the anterior and middle scalene muscles. Note the hypoechoic appearance of the monofascicular trunks. The suprascapular nerve, which arises from either the C5 root or the upper trunk, is also shown.* **(Middle)** *Transverse US shows roots and trunks of the brachial plexus between the scalenus medius and anterior muscles. Often, 3 distinct trunks are not visible with the trunks being rudimentary and the roots passing almost directly to divisions. Such variability in the brachial plexus morphology limits the use of objective size measurements to define normality. It is best to compare with the contralateral normal or less symptomatic side, as good side-to-side symmetry in brachial plexus morphology normally exists.* **(Bottom)** *Transverse US of the interscalene triangle outlet shows the dorsal scapular artery running between the upper and middle trunks. This is a fairly common finding. The suprascapular nerve is also shown. This nerve is the 1st branch of either the upper trunk or C5 root.*

TRANSVERSE US DIVISIONS

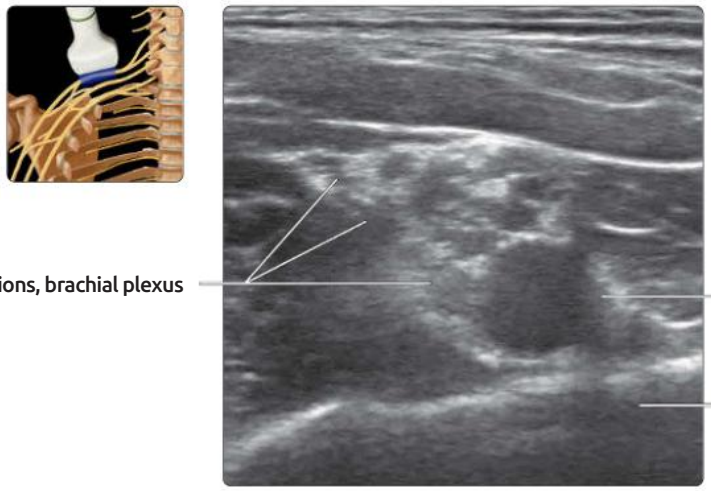

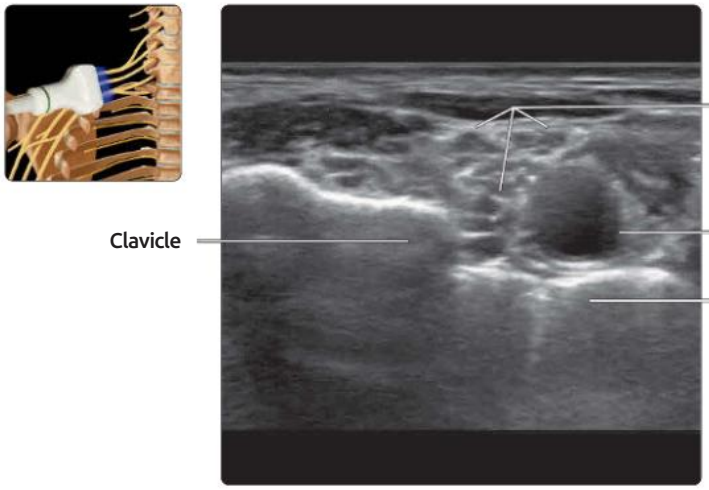

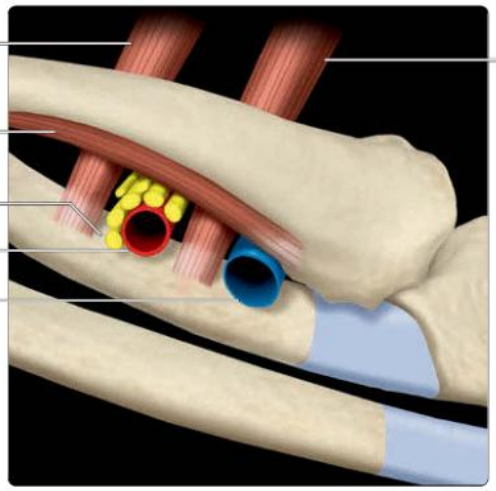

(Top) *Transverse US of the extrascalenus supraclavicular portion of the brachial plexus shows the divisions of the brachial plexus. These resemble a bunch of grapes and line up lateral or superolateral to the subclavian artery. The upper, middle, and lower trunks divide into 6 divisions. Note the normal hyperechoic fat between the divisions.* **(Middle)** *Transverse US just slightly more distal to the previous image in the immediate retroclavicular area shows the divisions arranged lateral and superolateral to the subclavian artery. The divisions, similar to the other components of the brachial plexus, are variable in size across the population, though good individual side-to-side symmetry exists in normal subjects.* **(Bottom)** *Graphic shows the costoclavicular gap, which is the narrowest area through which the brachial plexus passes. This gap can be compressed by deformity of the 1st rib or the clavicle. This small segment of the brachial plexus is not visible on US, though one can still appreciate the brachial plexus immediately proximal and distal to the costoclavicular gap. The subclavian artery becomes the axillary artery after it passes over the 1st rib.*

TRANSVERSE US CORDS AND TERMINAL BRANCHES

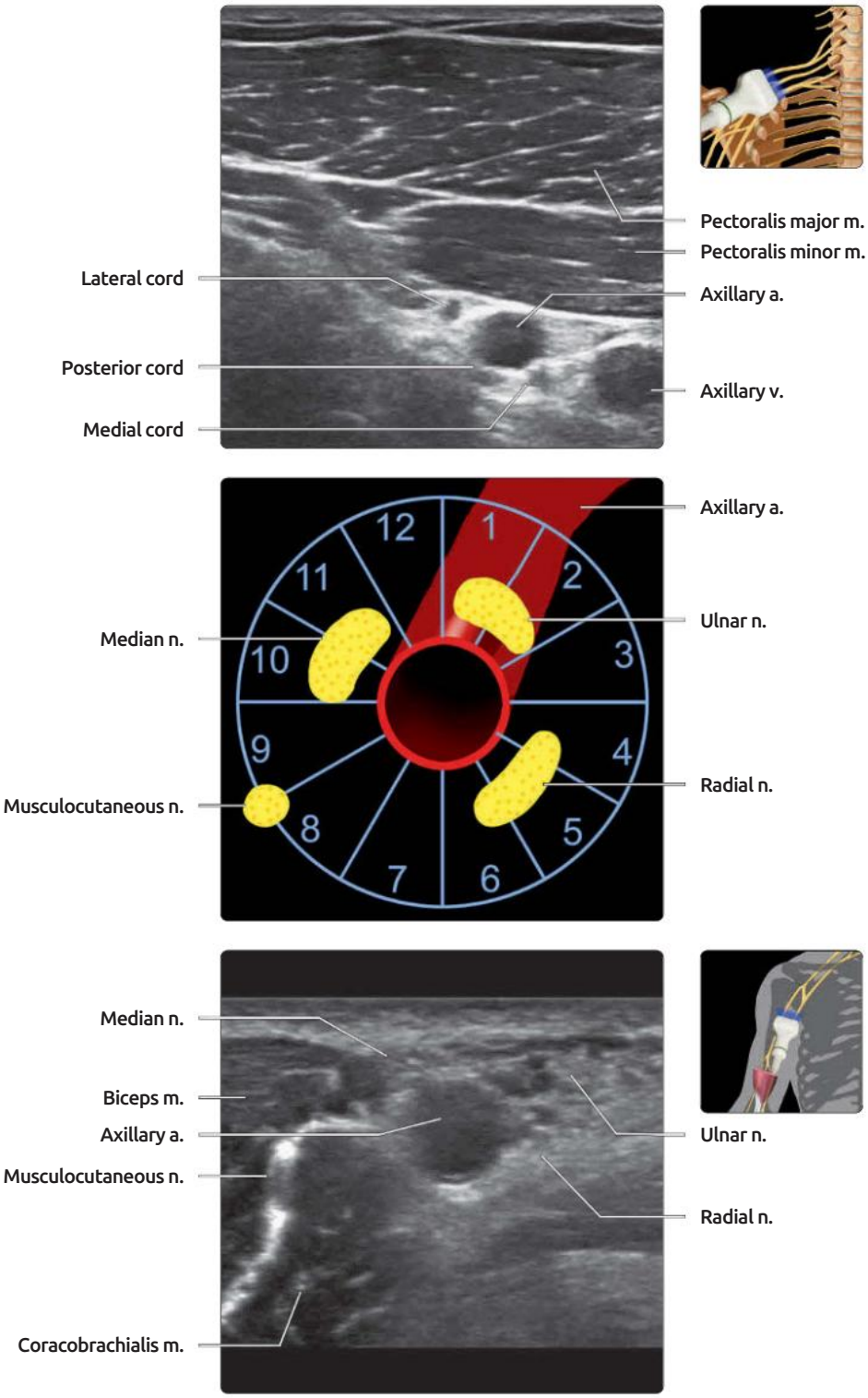

(Top) *Transverse US of the infraclavicular area, also known as the subpectoralis minor space or the subcoracoid space, shows the 3 cords of the brachial plexus positioned alongside the axillary artery. This area is examined with the arm abducted to 90°. The cords are not always readily clearly visible on US, though one can still appreciate normality of the tissues around the axillary artery.* **(Middle)** *Graphic shows clock face relationship of the nerves around the axillary artery in the axilla with the arm fully abducted. The median nerve lies superolateral, the ulnar nerve lies superomedial, and the radial nerve lies posteromedial or posterior to the axillary artery. The musculocutaneous nerve lies posterolateral to the axillary artery between the coracobrachialis and biceps muscles.* **(Bottom)** *Transverse US of the axilla with the arm fully abducted shows nerves surrounding the axillary artery. The 2-3 axillary veins have been effaced by transducer pressure. The musculocutaneous nerve lies between the coracobrachialis and biceps brachii muscles. The terminal branches in the axilla can be traced distally to the arm region to confirm their identify.*

GROSS ANATOMY

Arm

- Radial nerve arises from posterior cord of brachial plexus
  - Receives contributions from cervical roots C5-C8
  - Contains motor & sensory components, which supply extensor muscles of arm & forearm
  - Lies posterior & deep to axillary artery in axilla
- Lies between coracobrachialis & teres major muscles & then between bellies of medial & lateral head of triceps
- Runs deep to triceps in spiral groove & then deep to brachioradialis muscle
  - No actual osseous groove present; nerve runs from medial to lateral along side shaft of humerus
- 10 cm proximal to lateral epicondyle of humerus, radial nerve penetrates lateral intermuscular septum to enter anterior compartment of arm
- Area between lateral intermuscular septum & supinator inlet known as radial tunnel
- Just anterior to lateral epicondyle, nerve bifurcates into sensory (superficial) & motor (deep) branches

Forearm

- Branches of radial nerve
  - Superficial branch of radial nerve (purely sensory)
    - Courses distally, deep to brachioradialis, to extensor compartment of distal forearm & then to dorsal wrist
    - Cephalic vein crosses over superficial branch in distal forearm
      - Nerve may be injured during venous cannulation
    - Divides into lateral & medial branches 5 cm proximal to radial styloid
    - Lateral branch supplies radial wrist & thumb skin; medial branch (supplies mid- & ulnar wrist skin)
      - Dorsal digital nerves supply ulnar thumb, index, middle, & radial ring fingers
  - Deep branch of radial nerve (purely motor)
    - Deep branch of radial nerve becomes posterior interosseous nerve (PIN) at entry into supinator muscle (supinator arch or arcade of Fröhse)
    - PIN passes between superficial & deep heads of supinator muscle (supinator canal)
      - Then exits distally & runs posteriorly as PIN
    - Supplies extensor compartment muscles of forearm
    - 5 potential anatomical causes of PIN compression near elbow
      - Fibrous band of radial head, which is continuous with extensor carpi radialis brevis (ECRBr) & superficial head of supinator muscle
      - Radial recurrent vessels ("leash of Henry") at level of radial head
      - Tendinous margin of ECRBr
      - Aponeurotic proximal margin of supinator (arcade of Fröhse) = most common site of compression
      - Distal margin of supinator muscle
    - After exiting from supinator canal, PIN travels between superficial & deep extensor muscles until it reaches interosseous membrane distally
      - Travels first with posterior interosseous artery & then anterior interosseous artery
    - At wrist, PIN lies deep to radial side of 4th extensor compartments where it can be focally enlarged (pseudoganglion)
      - Thereafter, PIN divides into 2-4 terminal branches

Hand: Branches of Radial Nerve

- Not usually seen on routine imaging
- No motor innervation in hand
- Sensory to back of hand & dorsal aspect of radial 3.5 digits

ANATOMY IMAGING ISSUES

Imaging Recommendations

- Radial nerve is best identified at lateral aspect of distal arm deep to brachioradialis muscle
  - Alternatively, identify nerve deep to triceps in spiral groove midhumeral level
  - Or in proximal aspect of arm medially lying just deep to axillary & brachial arteries
- Trace medium-sized branches by following their course as they branch from parent nerve
- Examining nerves in transverse plane is preferable to longitudinal plane as it allows easier, continuous tracing of nerves
  - If one loses sight of small nerve, continue moving transducer slowly along expected path of nerve, & it will usually be reseen after few cm

Imaging Approaches

- Most common site of entrapment of PIN is at supinator arch (arcade of Fröhse)
  - Nerve will be focally thickened to > 2 mm thick (normal = 1 mm thick)

Imaging Pitfalls

- Smaller nerves & their branches (measuring ~ 1 mm wide) can be difficult to identify & separate from vessels
  - Color Doppler US helps
  - Identify nerves at target areas & follow distally or proximally
- Functional compression is not as readily appreciated as structural compression

CLINICAL IMPLICATIONS

Clinical Importance

- More common sites of radial nerve entrapment or injury
  - Lateral to long head of triceps due to fibrous arch
  - Spiral groove between medial & lateral heads of triceps muscle due to fibrous arch, fractures, tourniquet
  - Between brachialis & brachioradialis muscles at antecubital fossa due to muscle hypertrophy (body builders)
  - Recurrent radial artery ("leash of Henry") proximal to supinator muscle
  - Arcade of Fröhse at supinator inlet compressing PIN
  - Between deep & superficial heads of supinator muscle compressing PIN
  - Superficial branch of radial nerve in mid- to distal forearm (Wartenberg syndrome)
  - PIN deep to 4th extensor compartment at wrist by ganglion, during wrist injection, arthroscopy, or radial bone fixation

RADIAL NERVE

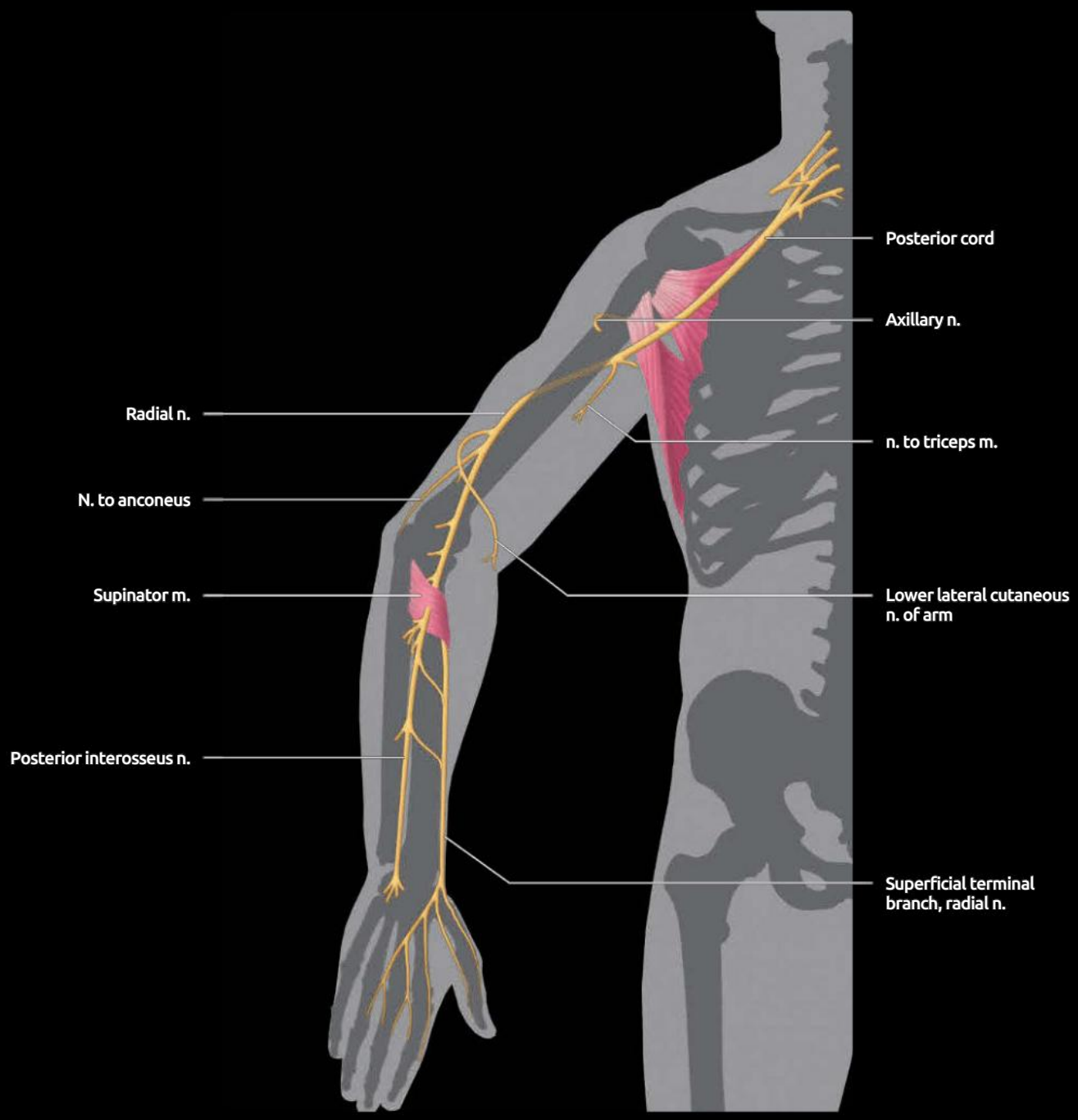

Graphic shows the course and distribution of the radial nerve. The radial nerve arises from the posterior cord of the brachial plexus (C5-C8, T1). It spirals posterolaterally around the humerus with the deep brachial artery located anterolateral between the brachialis and the brachioradialis. It gives off the posterior cutaneous nerve of the forearm, which passes posterior to the lateral condyle and supplies the posterior forearm. It divides into deep and superficial branches at the lateral epicondyle. The deep branch is purely motor and pierces the supinator muscle and winds around the lateral aspect of the radial neck. The superficial branch is purely sensory and is located in the anterolateral aspect of the forearm, superficial to the supinator and pronator teres muscles.

POSTERIOR ARM

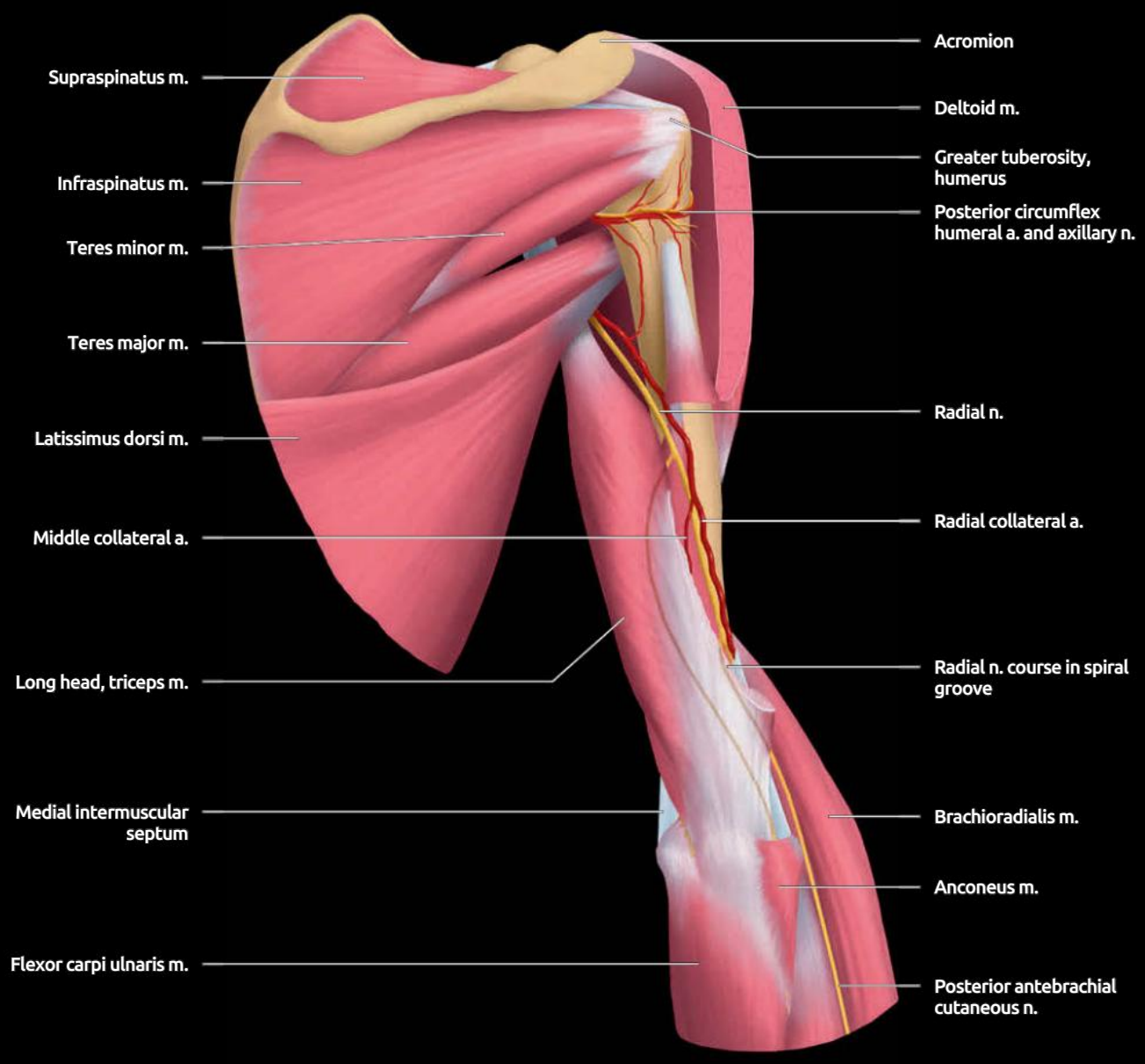

Graphic shows the course of the radial nerve in the posterior aspect of the arm. The radial nerve spirals posterolaterally around the humerus with the deep brachial artery. It gives off the posterior cutaneous nerve of the forearm, which passes posterior to the lateral condyle and supplies the posterior forearm. It is located anterolaterally, between the brachialis and brachioradialis, where it supplies the triceps, anconeus, brachioradialis, and the lateral portion of the brachialis.

TRANSVERSE US: ARM

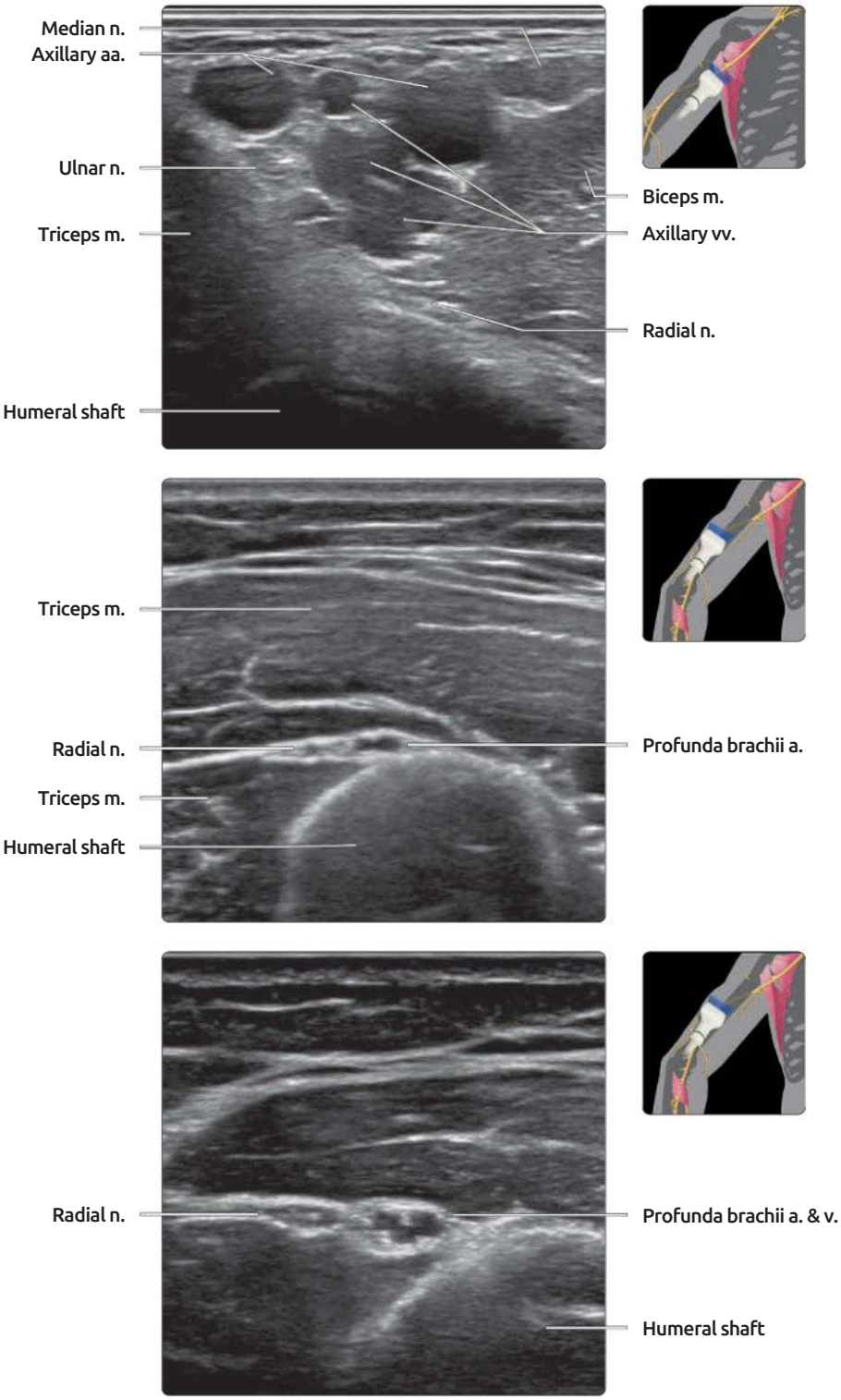

(Top) *Transverse US shows the radial nerve in the axilla. The radial nerve is a continuation of the posterior cord of the brachial plexus. It supplies the triceps and the supinator. In the proximal arm, it lies deep to the axillary artery and vein. There is commonly at least 2 axillary arteries and 3 axillary veins.* **(Middle)** *Transverse US shows the radial nerve at the mid 1/3 of the arm. The radial nerve may be injured as it passes around the posterior aspect of the mid to distal 1/3 of the humeral shaft. This injury may occur at the time of fracture, during fracture manipulation or fixation, or due to postoperative fibrosis.* **(Bottom)** *More localized view of the radial nerve and profunda brachii artery and veins are seen close to the posterior aspect of the humeral shaft in the midarm region.*

TRANSVERSE US: RADIAL TUNNEL

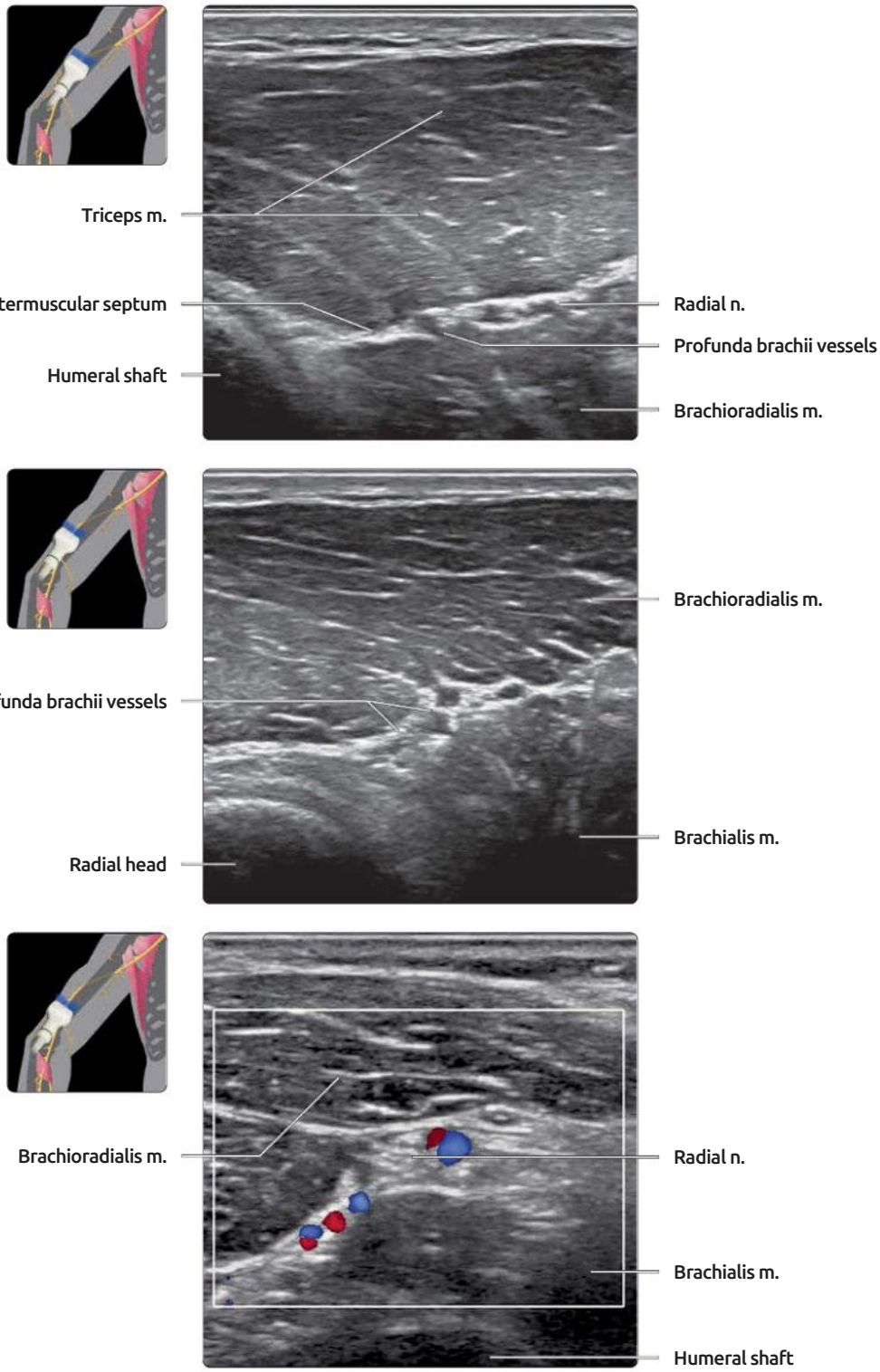

(Top) *Transverse US shows the radial nerve on the volar aspect of the distal 1/3 of the arm. The radial nerve passes from the posterior to the anterior compartment of the arm by piercing the lateral intermuscular septum at the lateral end of the distal humerus. Compression of the radial nerve at the lateral intermuscular septum may occur.* **(Middle)** *Transverse US shows the radial nerve in the radial tunnel. The radial tunnel is the area between the lateral intermuscular septum and the supinator muscle inlet, deep to the brachioradialis muscle. The radial nerve can be readily identified in this area. The radial nerve divides into superficial and deep branches in the radial tunnel area.* **(Bottom)** *Transverse color Doppler US can help identify the radial nerve from adjacent vessels in the radial canal. Rarely, vascular compression of the radial nerve can occur in the radial tunnel area from a mesh of profunda brachii vessels ("leash of Henry"), leading to radial tunnel syndrome.*

TRANSVERSE US: SUPINATOR TUNNEL

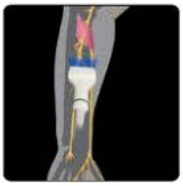

(Top) *Transverse US of the proximal forearm shows the deep branch of the radial nerve entering the supinator canal course in the proximal forearm. The inlet of the supinator tunnel, known as the arcade of Fröhse, is the most common site of radial nerve compression. Compression of the posterior interosseous nerve at this location leads to supinator syndrome.* **(Middle)** *Longitudinal US of the proximal forearm shows the deep branch of the radial nerve in the radial tunnel. Once the deep branch of the radial nerve passes into the supinator inlet (arcade of Fröhse), it is known as the posterior interosseous nerve. The supinator canal lies between the superficial and deep heads of the supinator muscle. The deep branch of the radial nerve normally slightly thickens just before entering the supinator canal. More pronounced thickening (> 2-mm width) just proximal to the supinator inlet would suggest compression. This compression can lead to supinator syndrome.* **(Bottom)** *Longitudinal US of the proximal forearm shows the posterior interosseus nerve within and exiting the supinator tunnel. This tunnel lies between the superficial and deep heads of the supinator muscle.*

TRANSVERSE US: FOREARM

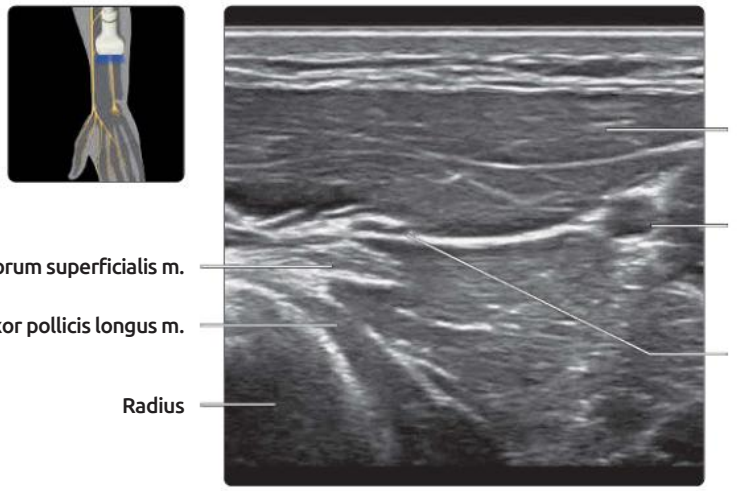

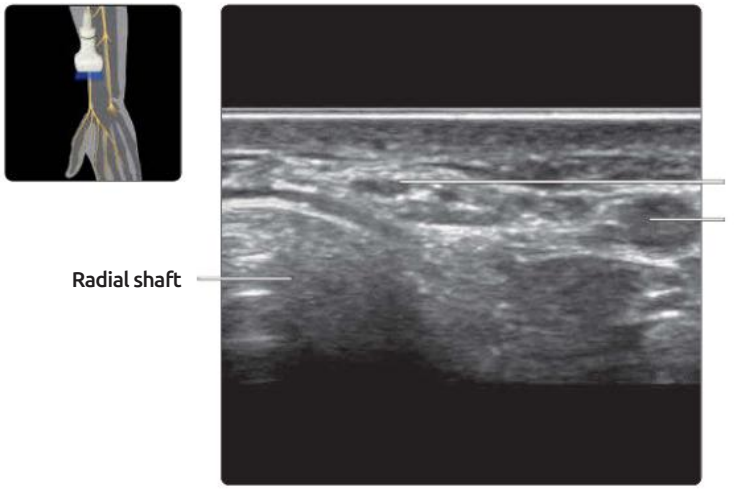

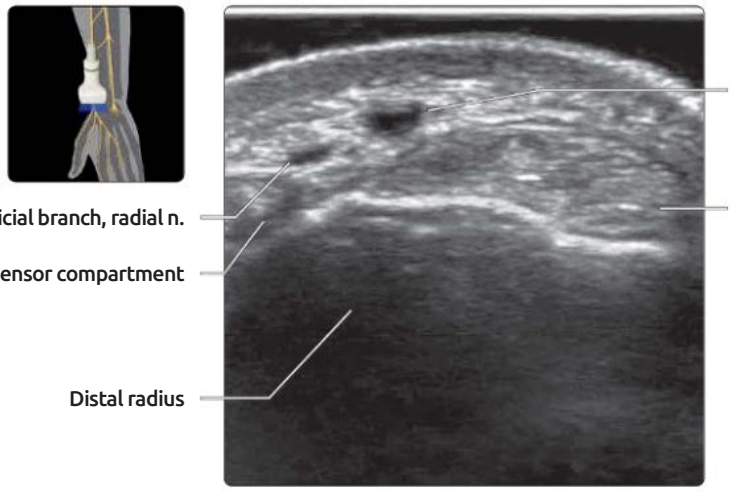

(Top) *Transverse US shows the superficial branch of the radial nerve on the volar aspect of the midforearm. The superficial branch of the radial nerve moves from the deep to the superficial tissues.* **(Middle)** *Transverse US shows the superficial branch of the radial nerve on the volar aspect of the distal forearm. About 8 cm proximal to the radial styloid, the superficial branch of the radial nerve emerges from underneath the brachioradialis muscle to lie superficially. Entrapment or injury to the superficial branch of the radial nerve is called Wartenberg syndrome and can be due to a tight wristwatch, plaster of Paris cast, internal fixation of the radius, or cephalic vein cannulation.* **(Bottom)** *Transverse US shows the superficial branch of the radial nerve on the radial side of the distal forearm traversing the 2nd and 1st extensor tendon compartments. The superficial branch of the radial nerve can be injured during cephalic vein cannulation or percutaneous injection of these extensor compartments.*

ELBOW AND WRIST

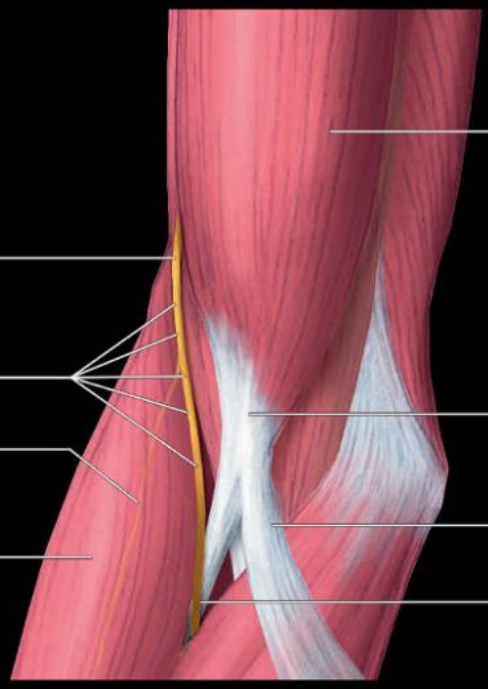

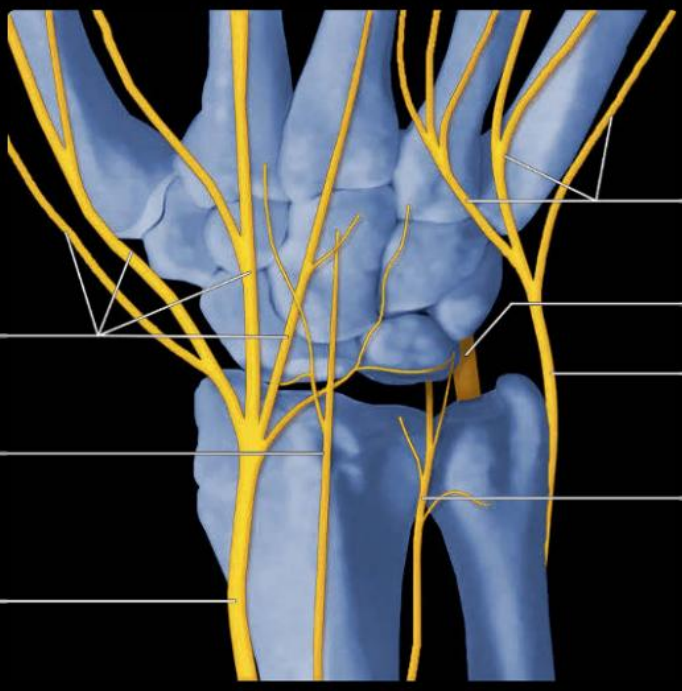

(Top) *Graphic shows the radial nerve course at the anterolateral aspect of the elbow. The deep branch of the radial nerve is potentially prone to impingement at the superficial proximal margin of the supinator muscle (arcade of Fröhse), resulting in posterior interosseus nerve syndrome.* **(Bottom)** *Graphic shows the nerves of the dorsal wrist. The radial nerve branches in the forearm with the superficial, posterior cutaneous, and posterior interosseus branches supplying the wrist and hand. The ulnar nerve provides branches to both the dorsal and volar wrist.*

TERMINOLOGY

Abbreviations

- Flexor digitorum profundus (FDP)
- Flexor digitorum superficialis (FDS)
- Flexor carpi ulnaris (FCU)
- Flexor pollicis longus (FPL)
- Pronator quadratus (PQ)
- Palmaris longus (PL)

GROSS ANATOMY

Arm: Median Nerve

- Arises from medial & lateral cords of brachial plexus (C6-C8, T1)
- In axilla, lies superolateral to artery close to short head of biceps muscle
- Lies medial to brachial artery & vein
- Located deep to bicipital aponeurosis in cubital fossa
- Supplies pronator teres, PQ, & flexors of anterior compartment forearm (except FCU & medial 1/2 of FDP, which are supplied by ulnar nerve)

Forearm: Median Nerve & Branches

- Enters forearm by passing between humeral & ulnar heads of pronator teres; located in forearm between FDP & FDS
  - Courses distally & attached to deep surface of FDS by fascial sheath
  - Anterior interosseous nerve
    - Purely motor nerve
    - Arises from median nerve at level of pronator teres
    - Located in forearm anterior to interosseous membrane, between FPL & FDP, alongside anterior interosseous artery
- At wrist, median nerve emerges from lateral side of FDS, becomes more superficial, & runs deep to PL tendon toward carpal tunnel
  - Supplies FPL, PQ, & lateral 1/2 of FDP

Wrist & Hand: Median Nerve & Branches

- Median nerve lies along axis of ring finger, i.e., to ulnar side of midline
- Lies deep to antebrachial fascia & PL before dipping deeply to enter carpal tunnel
- At distal radioulnar joint: Nerve is rounded, deep to PL, medial & superficial to FCR & FPL, & lateral & superficial to FDS
- Carpal tunnel is fibroosseous tunnel located immediately distal to volar wrist crease
  - Formed by carpal bones & flexor retinaculum (transverse carpal ligament)
  - Flexor retinaculum attaches to pisiform, hook of hamate, scaphoid, & trapezium
  - 9 structures pass through carpal tunnel
    - 4 FDS tendons, 4 FDP tendons, FPL tendon, & median nerve
    - Median nerve is located superficially in carpal tunnel just deep to retinaculum
  - Tunnel outlet is narrowest part of carpal tunnel
- Branches
  - Motor to thenar & 1st & 2nd lumbrical muscles
  - Sensory to radial 1/2 of palm, radial 3.5 digits
    - Palmar cutaneous branch typically arises proximal to carpal tunnel
  - Median nerve divides just distal to carpal tunnel

ANATOMY IMAGING ISSUES

Imaging Recommendations

- Examination of nerve in transverse plane is preferable to longitudinal scanning since it allows nerve to be followed continuously throughout limb
- Use proximal & distal borders of retinaculum as markers of carpal tunnel

Imaging Approaches

- Use high-frequency, 12- to 17-MHz transducer

Imaging Pitfalls

- Median nerve may be bifid
  - If measuring neural caliber, both components should be measured & summated
- Keep transducer at right angles to nerve, as angulation will increase nerve caliber
  - May need to make use of anisotropy to best differentiate nerve from tendons in carpal tunnel
- Avoid too much transducer pressure, as this will reduce nerve caliber & increase flattening

CLINICAL IMPLICATIONS

Clinical Importance

- Normal cross-sectional area (CSA) of median nerve ranges from < 10 mm^2
  - Nerve swelling is considered if CSA > 10 mm^2
    - Between 10-14 mm^2 is questionable swelling
    - > 14 mm^2 nearly always abnormal
  - Larger median nerve, greater likelihood of carpal tunnel syndrome (CTS)
    - Just proximal or distal to tunnel are most common sites of median nerve swelling in CTS
  - US median nerve CSA measurements 20% smaller than on MR, as US CSA measurements do not usually include echogenic epineurium
- Potential sites of median nerve compression
  - Deep to ligament of Struthers
    - Ligament between medial epicondyle & anomalous bony spur arising from distal humeral diaphysis (present in 1% of population)
    - May compress median nerve, brachial artery, or both
  - Between brachialis & bicipital aponeurosis
    - Bicipital aponeurosis = medial fascial expansion of biceps tendon that extends superficial to brachial artery & median nerve & merges with investing fascia of forearm
  - Between heads of pronator teres
    - Either median nerve or anterior interosseus nerve may be compressed
  - CTS
    - Most common compressive neuropathy
    - Do not use opposite side as comparative standard, as subclinical compression common
    - Median nerve will remain unduly swollen even after clinically successful carpal tunnel release

MEDIAN NERVE

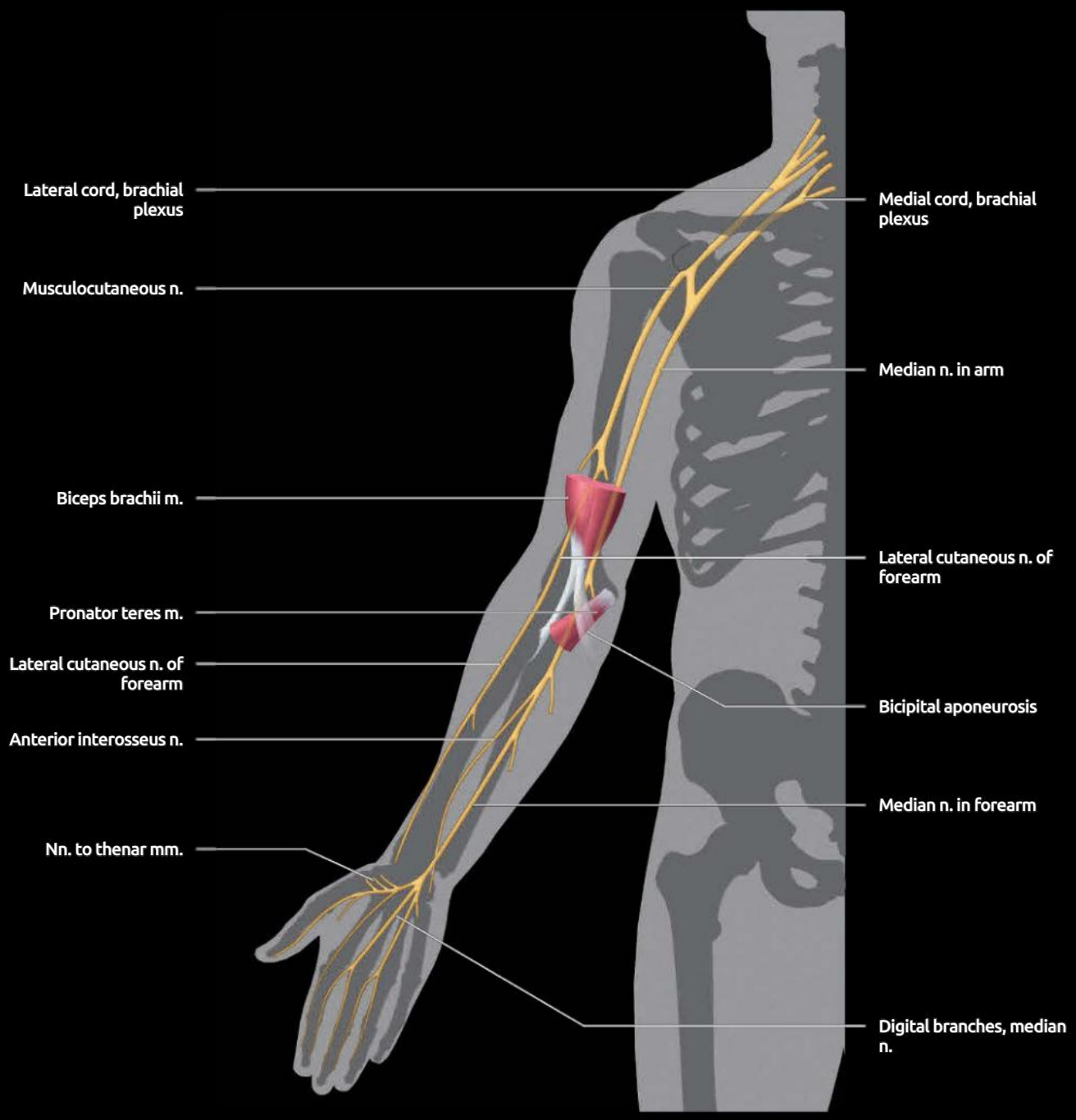

Graphic shows the course and distribution of the median and musculocutaneous nerves. The median nerve arises from the medial and lateral cords of the brachial plexus (C6-C8, T1). It travels together with other nerves of the arm. In the elbow, it is located deep to the biceps aponeurosis, enters the forearm by passing between the heads of the pronator teres, and is located in the forearm between the flexor digitorum superficialis and profundus muscles. The musculocutaneous nerve arises from the lateral cord of the brachial plexus (C5-C7). It lies between the brachialis and biceps brachii muscles and supplies both of them. It then becomes superficial at the elbow and continues laterally as the lateral cutaneous nerve of the forearm, which innervates the skin of the lateral side of the forearm.

CUBITAL FOSSA

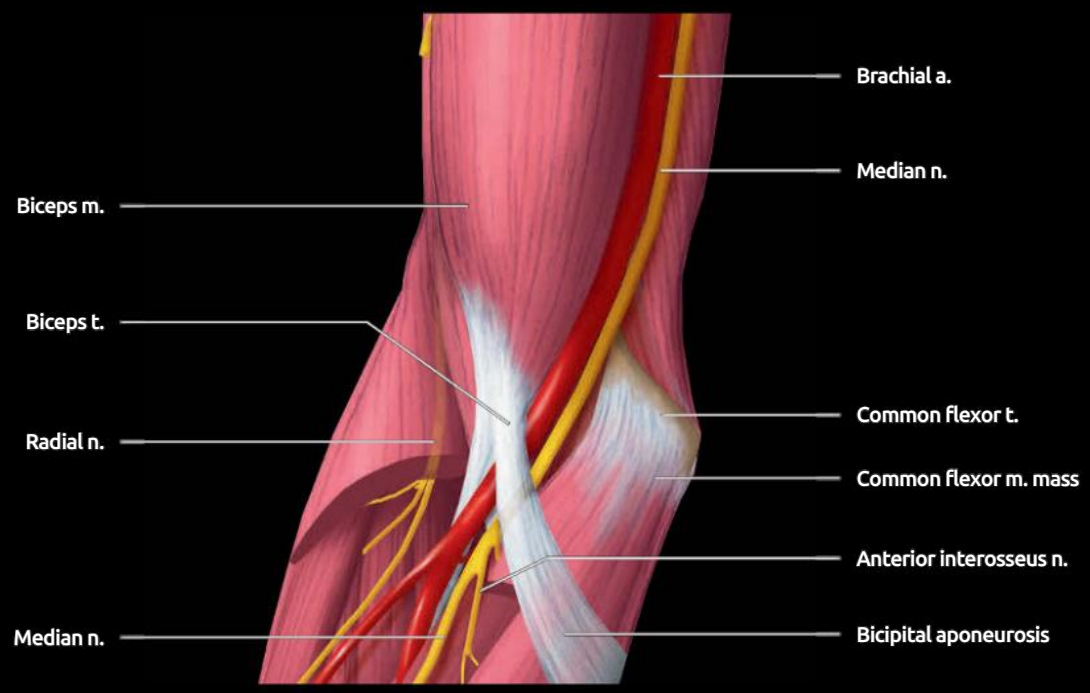

(Top) *Graphic of the anterior view of the cubital fossa shows the median nerve and brachial artery passing underneath the biceps aponeurosis. The anterior interosseus nerve arises from the median nerve as the median nerve passes between 2 heads of the pronator teres muscle.* **(Bottom)** *The median nerve may be entrapped between 2 heads of the pronator teres muscle or by the overlying bicipital aponeurosis. The median nerve gives rise to the articular branches to the elbow joint. It supplies the pronator teres, pronator quadratus, and flexors of the anterior compartment of the forearm (except the flexor carpi ulnaris and medial 1/2 of the flexor digitorum profundus, which are supplied by the ulnar nerve).*

TRANSVERSE US ARM

(Top) *Transverse US shows the median nerve at the proximal arm. The median nerve arises from the lateral and medial cords of the brachial plexus. In the proximal arm, it lies between the biceps muscle and the brachial artery/vein.* **(Middle)** *Transverse grayscale US shows the median nerve at the midarm. Little happens to the median nerve in the upper to midarm. It gives off no branches and is not prone to compression by normal structures.* **(Bottom)** *Transverse US shows the median nerve of the distal arm. The median nerve passes over the brachial artery and vein from lateral to medial. Occasionally, there is a ligament (of Struthers) in the distal arm with a bony spur attached to the humerus ~ 5 cm proximal to the medial epicondyle. The pronator teres gains additional attachment from this ligament. The median nerve may be compressed deep to this ligament.*

TRANSVERSE US ELBOW

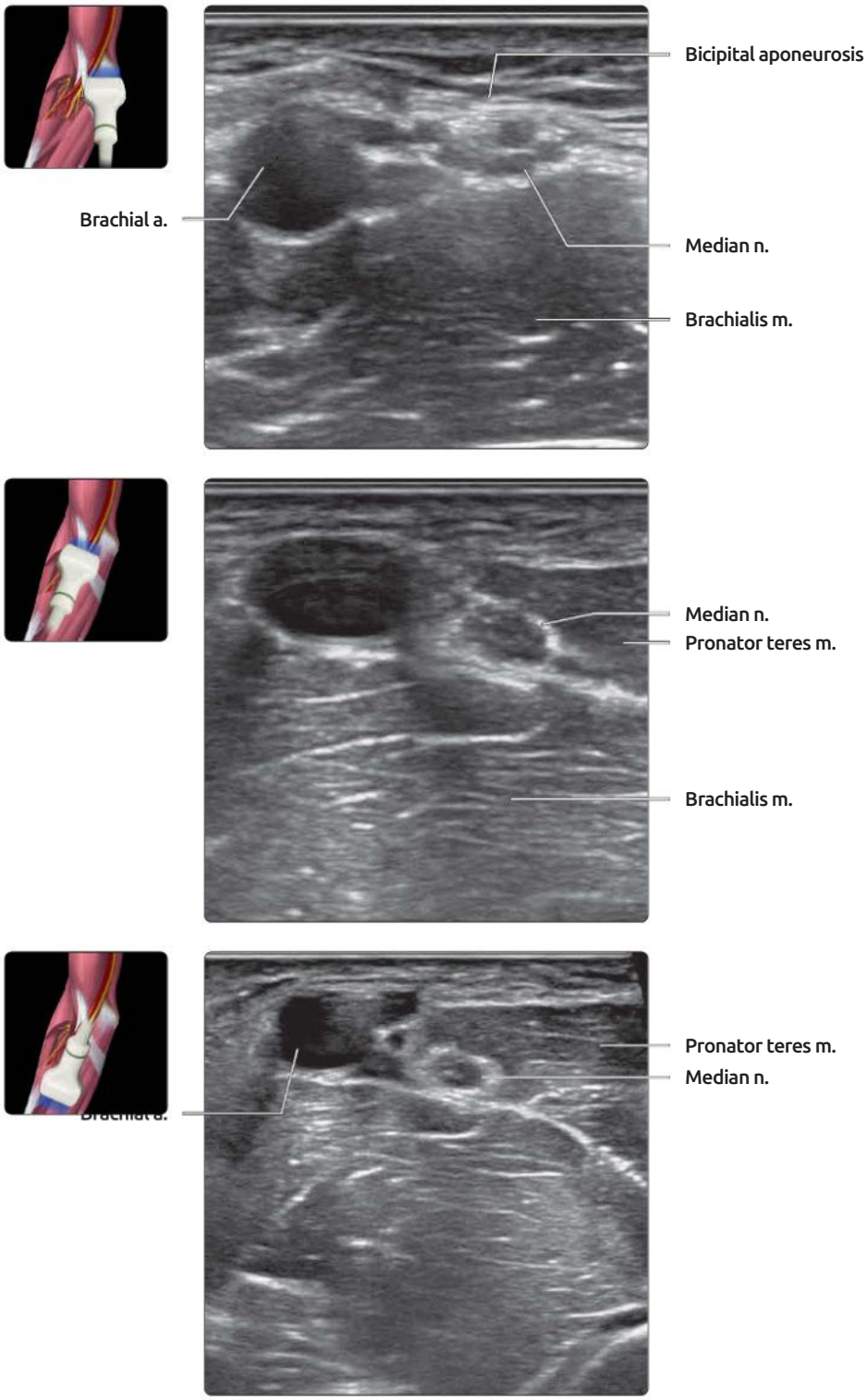

(Top) *Transverse US shows the median nerve at the distal arm. The median nerve travels deep to the bicipital aponeurosis. A fascial aponeurosis (a.k.a. lacertus fibrosis) arises from the biceps musculotendinous junction and inserts into the antebrachial fascia. The median nerve may be compressed deep to this fascia.* **(Middle)** *Transverse US shows the median nerve at the elbow region.* **(Bottom)** *Transverse US shows the median nerve at the proximal forearm. The median nerve is also prone to compression between the 2 heads of the pronator teres muscle (i.e., common flexor origin head and coronoid process head). The median nerve branches as it passes through these heads, giving rise to the anterior interosseus nerve, and may be compressed at this location. Pronator teres syndrome is characterized by pain in the forearm or hand with either prolonged forearm pronation or recurrent pronation/supination of the forearm.*

TRANSVERSE US FOREARM

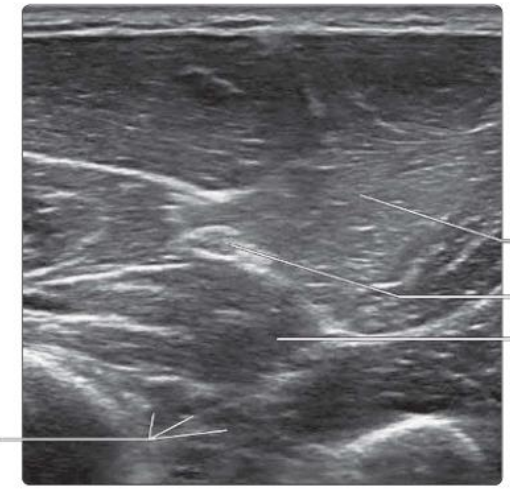

(Top) *Transverse US shows the median nerve at the proximal forearm. The anterior interosseus nerve supplies all the muscles of the anterior compartment of the forearm except the ulnar 1/2 of the flexor digitorum profundus muscle. It may be injured with fracture of the radial shaft.* **(Middle)** *Transverse US shows the median nerve at the midforearm. The median nerve is clearly identified in the mid to distal forearm as it travels between the flexor digitorum superficialis and profundus muscles. The anterior interosseous nerve is more difficult to see clearly, though its location can be inferred through identification of the adjacent anterior interosseous artery and veins.* **(Bottom)** *Transverse US shows the median nerve at the distal forearm.*

TRANSVERSE US WRIST

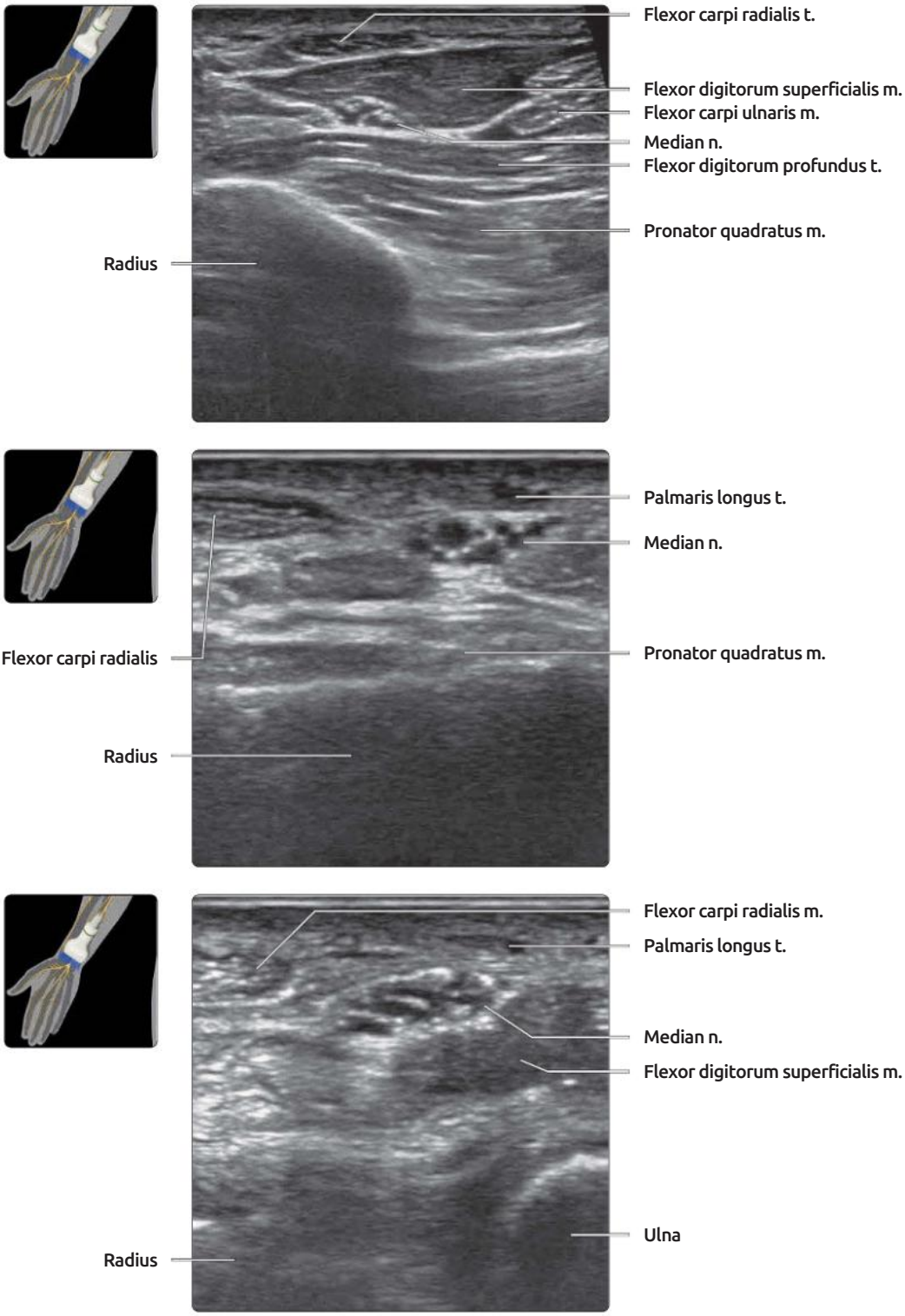

(Top) *Transverse US shows the median nerve in the distal forearm.* **(Middle)** *Transverse US shows the median nerve just proximal to the wrist. The median nerve gives off the palmar cutaneous branch in the distal forearm. This branch innervates the skin on the palm of the hand.* **(Bottom)** *Transverse US shows the median nerve just proximal to the carpal tunnel; the median nerve ascends from a deeper position (between the flexor digitorum profundus and superficialis) to lie just deep to palmaris longus tendon. Enlargement of the median nerve in patients with carpal tunnel syndrome may present clinically as a mass-like lesion in this area. In suspected carpal tunnel syndrome, the caliber of the nerve should be measured at this location.*

TRANSVERSE US CARPAL TUNNEL

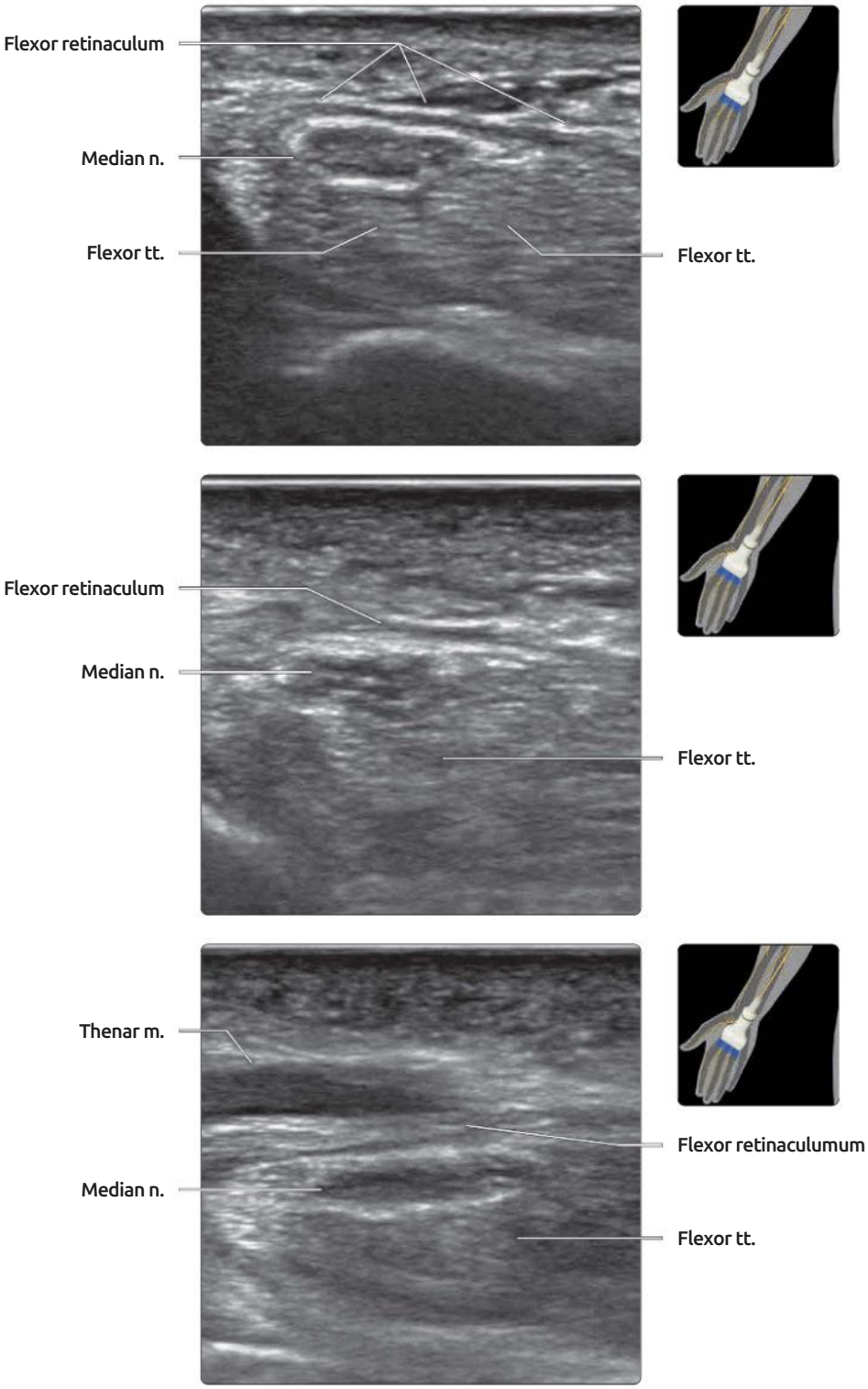

(Top) *Transverse US shows the median nerve at the carpal tunnel inlet. The best way to identify the carpal tunnel is to identify the leading and trailing edges of the flexor retinaculum. The median nerve dips deep to the retinaculum. The cross-sectional area should be measured at this location in suspected carpal tunnel syndrome. The echogenic epineurium around the nerve is not included in US cross-sectional area measurements.* **(Middle)** *Transverse US shows the median nerve at the midcarpal tunnel. The median nerve lies just deep to the retinaculum. It is variable in shape and changes with flexor tendon movement.* **(Bottom)** *Transverse US shows the median nerve at the carpal tunnel outlet. The cross-sectional area of the median nerve should also be measured at this location in patients with suspected carpal tunnel syndrome. This is the narrowest part of the carpal tunnel.*

TRANSVERSE AND LONGITUDINAL US HAND AND FOREARM

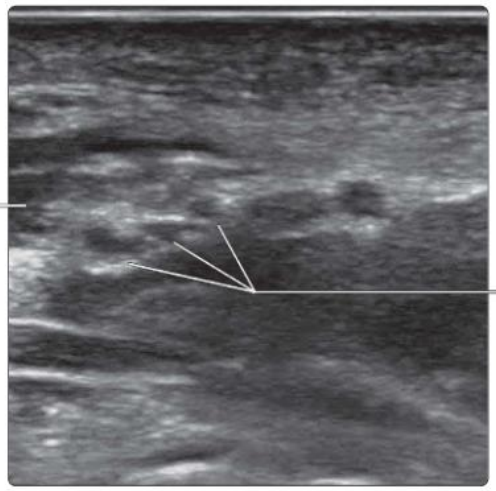

(Top) *Transverse US shows the median nerve just beyond the carpal tunnel outlet. The median nerve fairly consistently divides into its digital branches just beyond the tunnel outlet. If measured beyond the outlet, the median nerve cross-sectional area should be measured before the nerve divides into its digital branches.* **(Middle)** *Longitudinal US shows the median nerve in the carpal tunnel.* **(Bottom)** *Longitudinal US shows the median nerve in the distal forearm.*

PALMAR NERVES

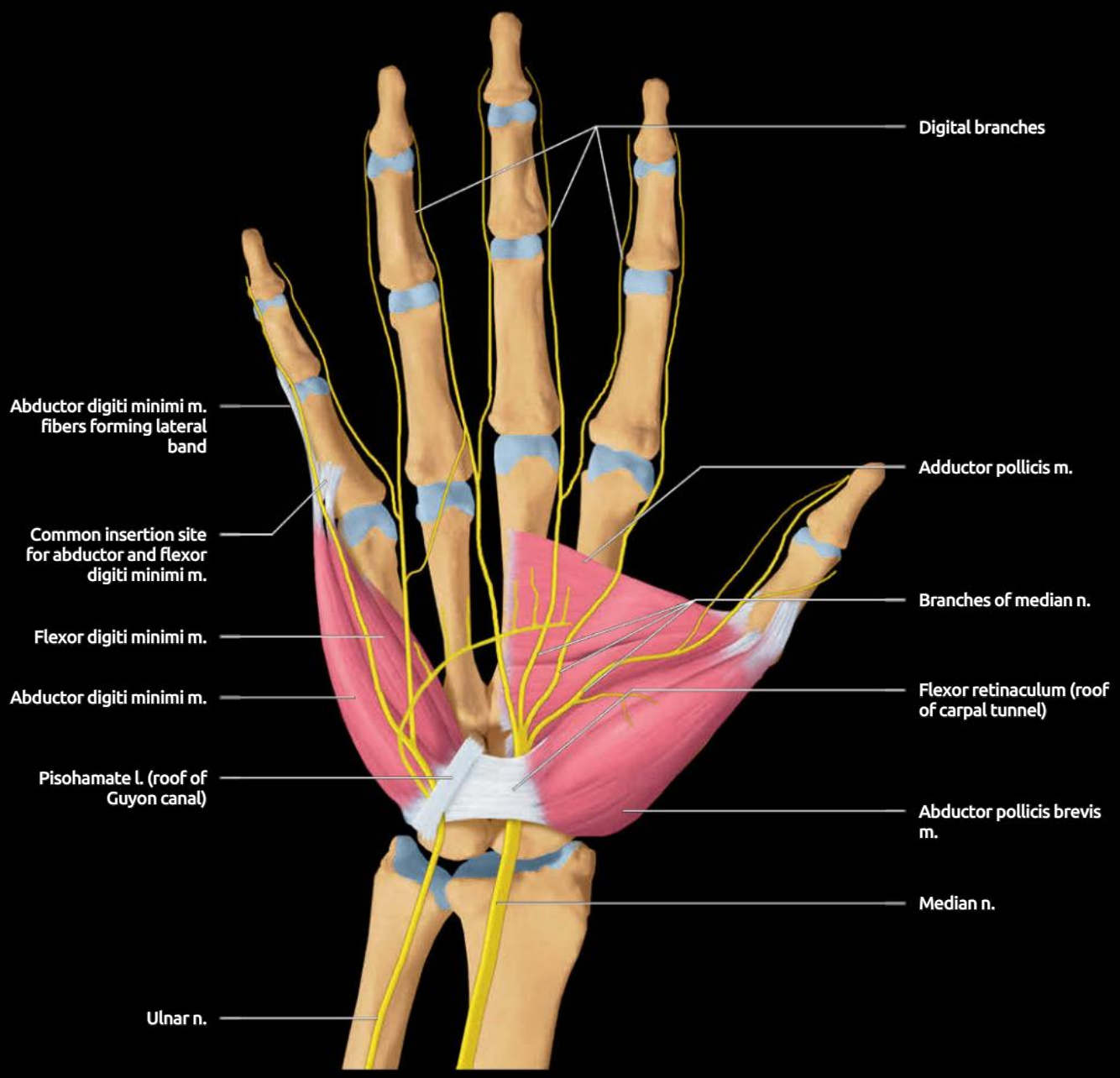

The median nerve travels deep to the flexor retinaculum (within the carpal tunnel). The ulnar nerve travels superficial to the flexor retinaculum and deep to the pisohamate ligament (within the Guyon canal). Both are prone to compression syndromes within these fibroosseous tunnels. Motor supply of the median nerve is to the thenar muscles (via the recurrent branch) and the 1st and 2nd lumbricals. The ulnar nerve motor supply is to all intrinsic muscles of the hand, which are not supplied by the median nerve. Muscle atrophy should prompt an evaluation of the innervating nerve.

GROSS ANATOMY

Arm: Ulnar Nerve

- Arises from medial cord of brachial plexus (C8, T1)
- In axilla, located superficial & medial to axillary artery
- In arm, located medial to brachial artery on coracobrachialis muscle in anterior compartment
  - Enters posterior compartment by piercing medial intermuscular septum before running distally with superior ulnar collateral artery
  - Courses posterior to medial humeral epicondyle in condylar groove (cubital tunnel)
- Cubital tunnel: Fibroosseous tunnel formed by medial epicondyle, olecranon, & Osborne fascia
  - Cubital tunnel syndrome (CUTS)
- Ulnar nerve may sublux over medial epicondyle in 20% of normal patients during flexion
  - Recurrent subluxation can lead to friction neuritis
- Anconeus epitrochlearis is accessory muscle extending from medial part of olecranon to medial epicondyle deep to Osborne ligament
  - Present in 10% normal patients; bilateral in 25%
  - Osborne ligament may be vestigial remnant of anconeus epitrochlearis muscle

Forearm: Ulnar Nerve & Branches

- On exiting cubital tunnel, enters forearm by passing deep to arcuate ligament between humeral & ulnar heads of flexor carpi ulnaris (FCU)
- Courses distally between FCU & flexor digitorum profundus (FDP)
  - Supplies FCU, medial 1/2 of FDP
- Palmar cutaneous branch
  - Arises in midforearm & supplies skin on ulnar 1/2 of palm
- Dorsal cutaneous branch
  - Arises in distal forearm & supplies skin on ulnar side of dorsum hand
- Distally, becomes superficial, comes closer to ulnar artery & passes into wrist superficial to flexor retinaculum

Hand: Ulnar Nerve & Branches

- Enters Guyon canal; small, triangular-shaped fibroosseous tunnel
  - Floor = flexor retinaculum; ulnar wall = pisiform & hook of hamate; roof = fascia continuous with flexor retinaculum (superficial palmar ligament)
  - Contains ulnar artery & ulnar nerve
  - Ulnar nerve lies between ulnar artery & pisiform or hook of hamate
  - Within tunnel, proximal to hook of hamate, it divides into superficial sensory & deep motor branches
    - Superficial branch passes over hook of hamate before bifurcating into digital nerves
      - Provides sensory innervation to skin of hypothenar eminence, little finger, & ulnar 1/2 of ring finger
    - Deep branch passes ulnar to hook of hamate
      - Provides motor innervation to hypothenar muscles, all interossei, 3rd & 4th lumbricals, & adductor pollicis muscle

ANATOMY IMAGING ISSUES

Imaging Recommendations

- Knowledge of nerve location & anatomic relationships is essential for US identification
- Examination of nerves in transverse plane is preferable to longitudinal plane, as it allows nerves to be followed continuously throughout limb
- Identify nerves at target area & follow proximally & distally
- Target areas for ulnar nerve = cubital tunnel, distal forearm alongside ulnar artery, & Guyon canal

Imaging Approaches

- Ulnar nerve prone to compression in cubital tunnel, between humeral & ulnar origins of FCU, & in Guyon canal
- CUTS = pain, weakness, & numbness in ulnar nerve distribution due to compression of ulnar nerve in cubital tunnel
  - Due to secondary compression much more frequently than primary compression
  - Common causes of secondary cubital tunnel compression
    - Bone (osteophytosis)
    - Capsule (synovitis, capsular thickening)
    - Muscle (anconeus epitrochlearis, medial belly triceps)
    - Tumor (ganglion, nerve sheath tumor)
  - If cross-sectional area (CSA) ulnar nerve at cubital tunnel > 10 mm², sensitivity 76%, specificity 61% for CUTS
  - Alternatively, nerve CSA within tunnel should not be > 1.5x CSA of nerve in distal arm
  - The more swollen the ulnar nerve in cubital tunnel, the greater the likelihood of CUTS
    - Only be definitive about CUTS when ulnar nerve CSA > ~ 18 mm²
- Recurrent subluxation of ulnar nerve can lead to friction neuritis & symptoms of CUTS
- Guyon canal compression is more often structural
  - Ganglion cyst, fracture hook of hamate, nerve sheath tumor, or other tumor
  - Repetitive microtrauma ("handlebar palsy")

Imaging Pitfalls

- Smaller nerves (< 1 mm) are difficult to identify, though their location can be inferred by adjacent anatomy
  - Color Doppler US helpful to differentiate from vessels
- Fixed structural causes of nerve compression are more easy to identify than functional compression
- Ulnar nerve normally enlarges slightly in cubital tunnel, though not to same degree as seen in CUTS

CLINICAL IMPLICATIONS

Clinical Importance

- Identification of cause of ulnar neuropathy is key to successful treatment
- Cubital tunnel compression & cubital tunnel neuritis can give similar symptoms
- Compression at Guyon canal spares palmar & dorsal cutaneous branches, which arise in distal forearm
  - Should have less pronounced sensory denervation than CUTS

ULNAR NERVE

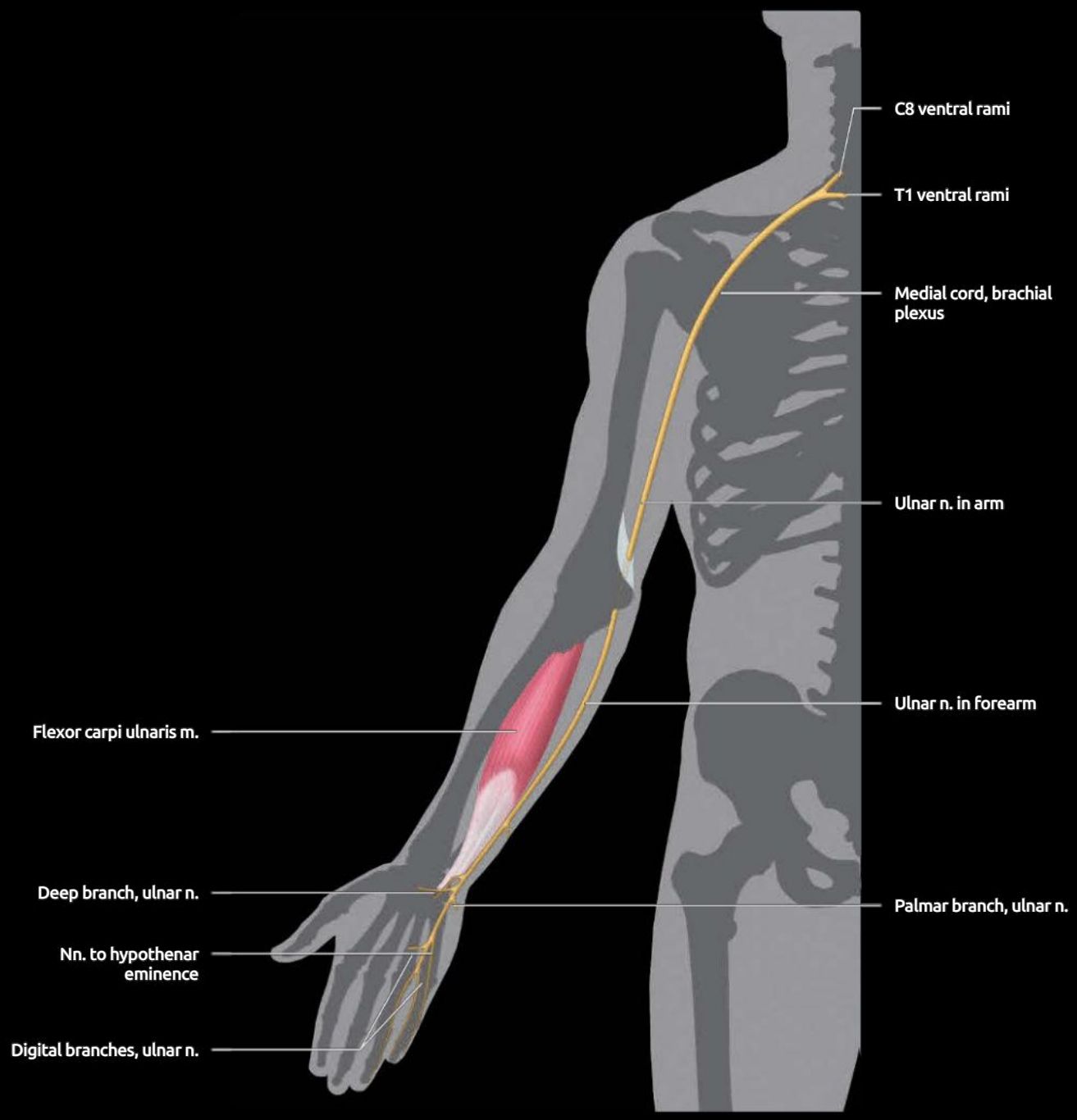

Graphic shows the course of the ulnar nerve. The ulnar nerve arises from the medial cord of the brachial plexus (C8, T1). It is located posteromedially, deep to the triceps muscles in the distal arm, where it passes posterior to medial epicondyle in the cubital tunnel (cubital syndrome due to compression of ulnar nerve in cubital tunnel). The ulnar nerve may sublux anterior to the medial epicondyle in ~ 15% of normal people, usually during flexion. The ulnar nerve passes behind the medial epicondyle, entering the forearm between the humeral and ulnar heads of flexor carpi ulnaris. The ulnar nerve then courses distally between flexor carpi ulnaris and the flexor digitorum profundus muscles, supplying the flexor carpi ulnaris muscle and medial 1/2 of the flexor digitorum profundus muscle.

CUBITAL TUNNEL

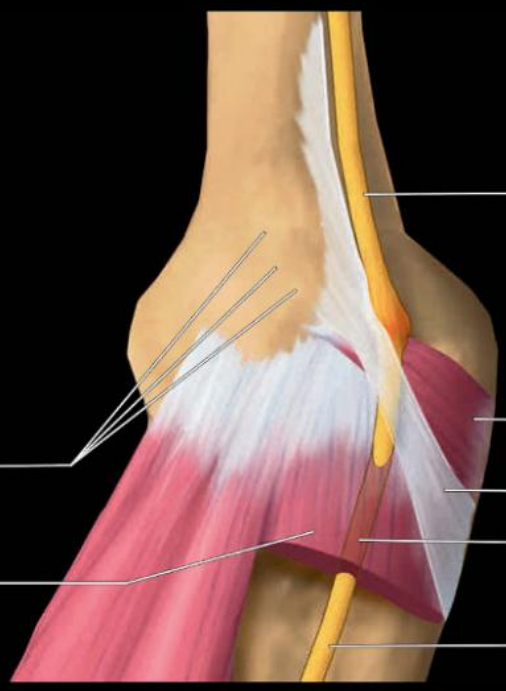

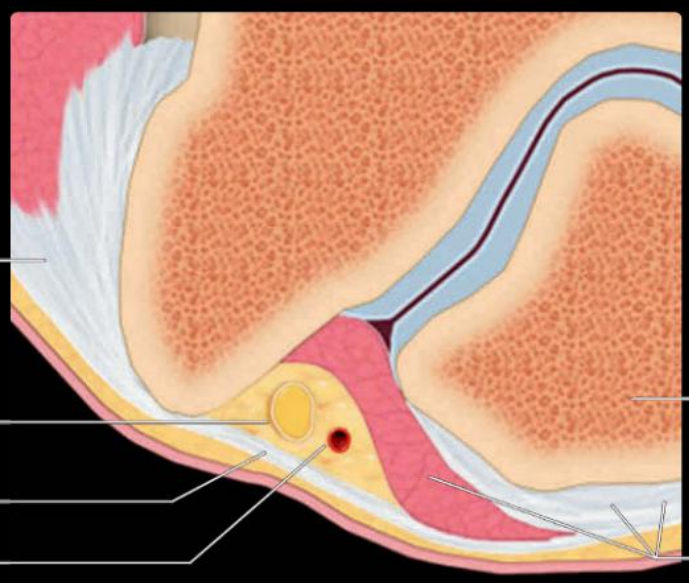

(Top) *Medial graphic shows the cubital tunnel. The anconeus epitrochlearis is an inconstant accessory muscle that lies superficial to the ulnar nerve and may compress the nerve against the medial epicondyle. The Osborne ligament is a continuation of the deep fascia covering the ulnar and humeral heads of the flexor carpi ulnaris. It extends from the medial epicondyle to the olecranon and is about 1.5mm thick. The Osborne ligament is continuous with the antebrachial fascia and is most taut at 90% flexion.* **(Bottom)** *Axial graphic shows the cubital tunnel. The ulnar nerve may be compressed within the cubital tunnel (cubital tunnel syndrome) by a mass, synovitis, posttraumatic osseous deformity, or aneurysm of the recurrent ulnar artery. The ulnar nerve may sublux out of the cubital tunnel aided by the adjacent medial head of the triceps. Recurrent subluxation, which can be found in ~ 15% of asymptomatic subjects, can lead to ulnar neuritis, which can produce similar symptoms to ulnar nerve compression.*

ARM

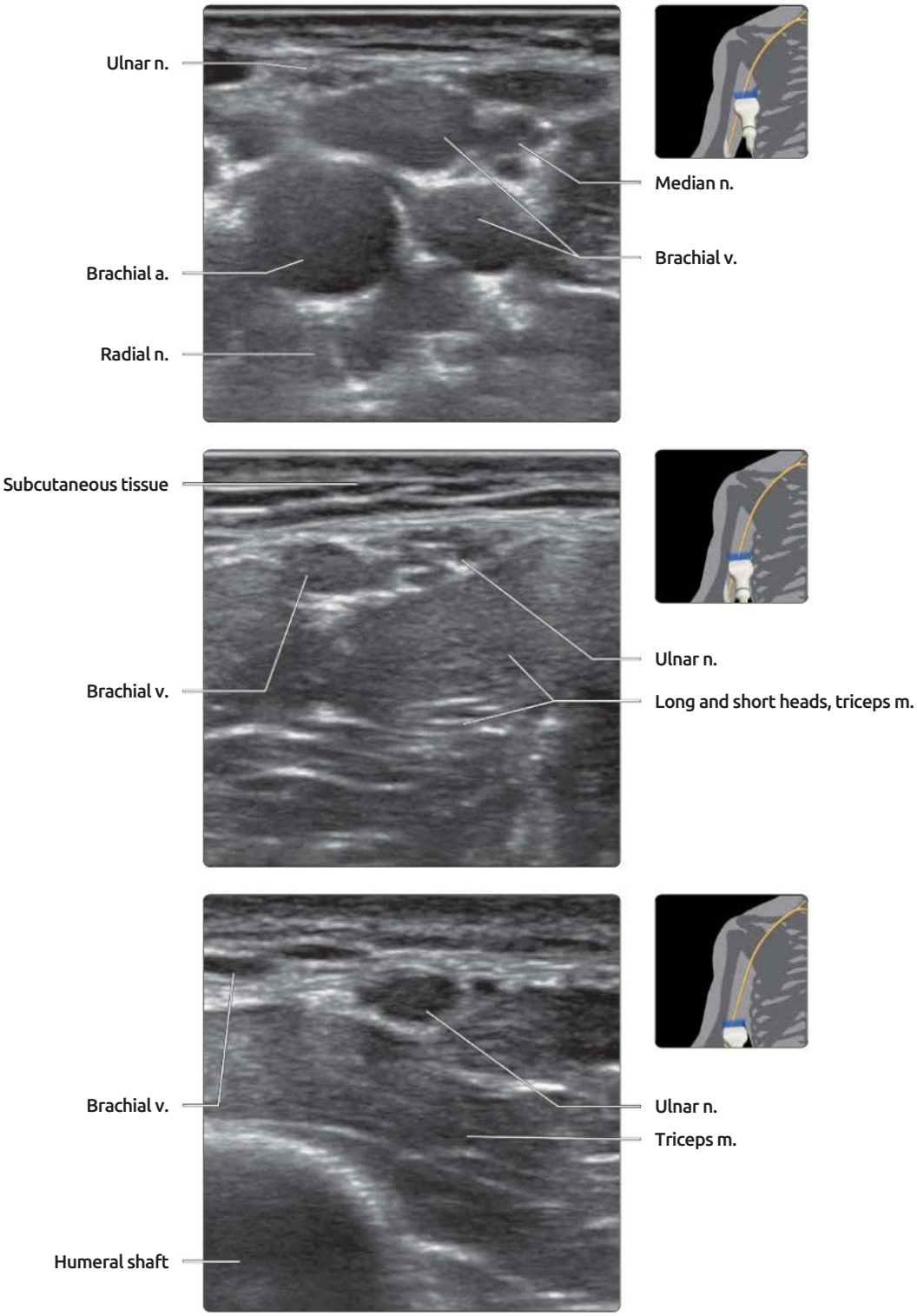

(Top) *Transverse US shows the ulnar nerve at the proximal arm. The ulnar nerve arises from the medial cord of the brachial plexus and lies just medial to the brachial vein.* **(Middle)** *Transverse US shows the ulnar nerve at the midarm. The ulnar nerve pierces the medial intermuscular septum in the midarm where it may be potentially compressed. The ulnar nerve gives off no branch in the arm.* **(Bottom)** *Transverse US shows the ulnar nerve in the distal arm. The ulnar nerve runs distally on the surface of the triceps muscle to reach the area between the olecranon and the medial epicondyle, i.e., the cubital tunnel.*

CUBITAL TUNNEL

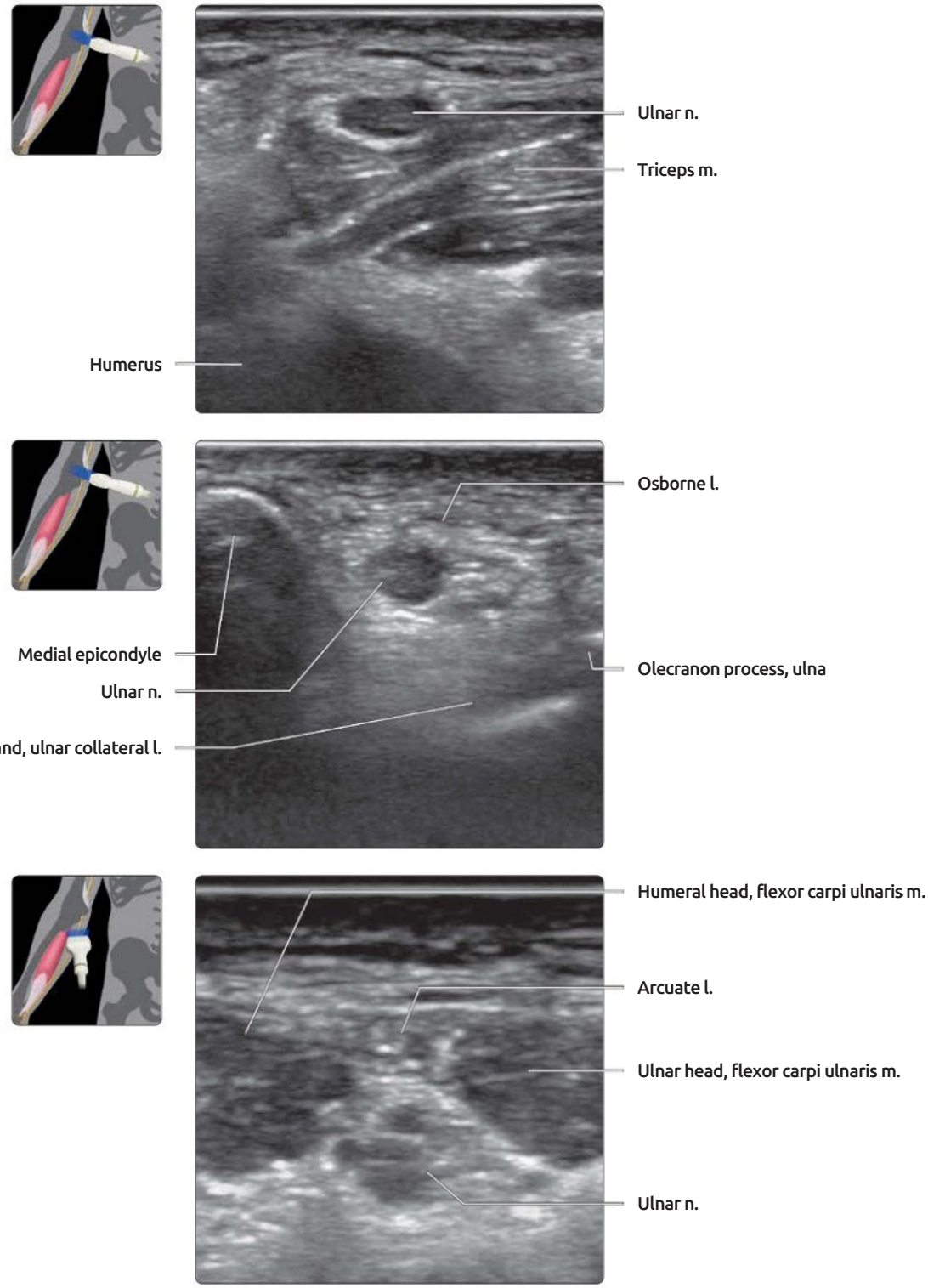

(Top) *Transverse US shows the ulnar nerve just proximal to the cubital tunnel. The cubital tunnel is the most common site of ulnar neuropathy. Neuropathy may take the form of idiopathic compression, bony impingement, synovial or muscular encroachment, recurrent subluxation of the ulnar nerve over the medial epicondyle, or direct injury.* **(Middle)** *Transverse US shows the ulnar nerve at the cubital tunnel. The cubital tunnel retinaculum (formed from an extension of investing fascia of the flexor carpi ulnaris and ligament of Osborne) forms the roof of the cubital tunnel. The retinaculum is 4 mm wide and difficult to depict on US. The floor and wall of cubital tunnel are formed by containing bones, elbow capsule, and medial collateral ligament. The ulnar nerve normally enlarges slightly within the cubital tunnel.* **(Bottom)** *Transverse US shows the ulnar nerve at the distal end of the cubital tunnel where the ulnar nerve runs deep to the arcuate ligament traversing between the humeral and ulnar heads of the flexor carpi ulnaris muscle. Less frequently, the ulnar nerve may be compressed at this location. This area is sometimes referred to as the carpal tunnel proper.*

FOREARM

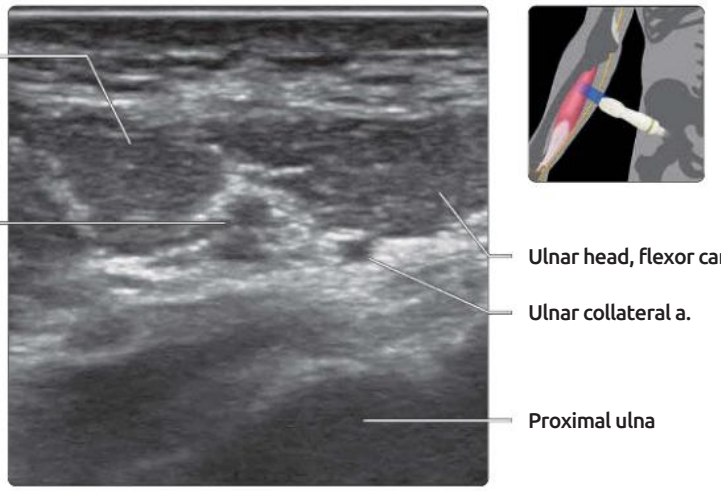

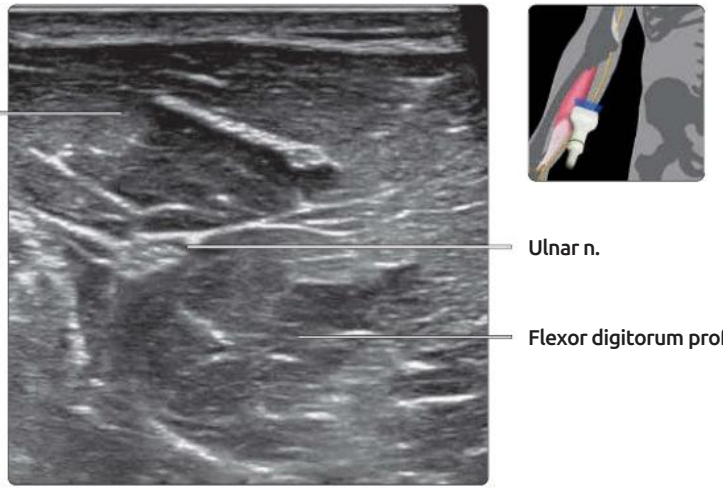

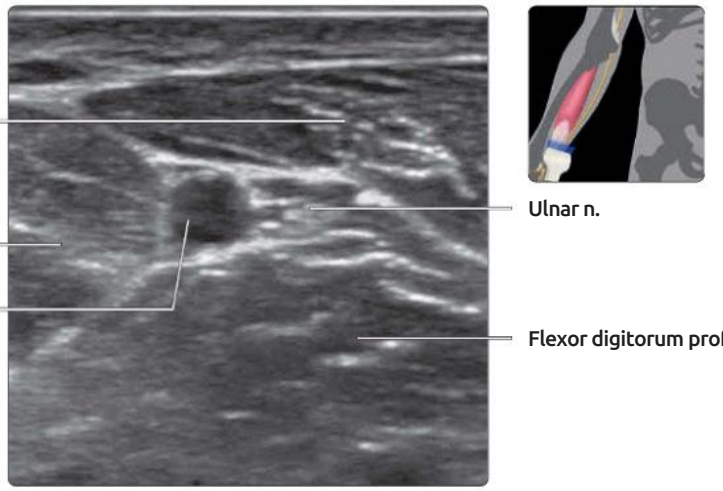

(Top) *Transverse US shows the ulnar nerve just beyond the cubital tunnel, where the ulnar nerve passes between the 2 heads (humeral and ulnar) of the flexor carpi ulnaris tendon. This is another potential site of compression. The ulnar head arises from the olecranon, the humeral head arises from the medial humeral epicondyle.* **(Middle)** *Transverse US shows the ulnar nerve in the midforearm. The ulnar nerve pierces the intermuscular septum, dividing the flexor and extensor compartments of the forearm to descend in the flexor compartment between the flexor carpi ulnaris and flexor digitorum profundus muscles.* **(Bottom)** *Transverse US shows the ulnar nerve in the distal forearm. The ulnar nerve is joined on its radial side by the ulnar artery in the distal forearm, and the 2 structures travel to the wrist, deep to the flexor carpi ulnaris muscle.*

WRIST AND FOREARM

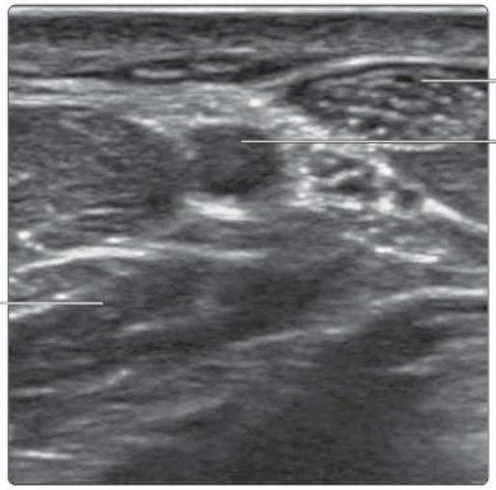

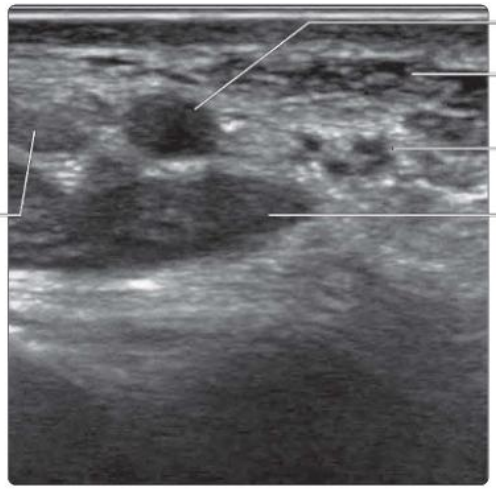

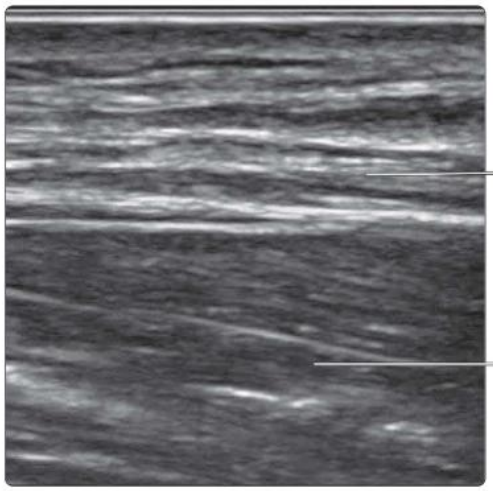

(Top) *Transverse US shows the ulnar nerve at the distal forearm. The ulnar nerve can be identified by first visualizing the ulnar artery and then identifying the nerve just ulnar to the artery.* **(Middle)** *Transverse US shows the ulnar nerve just proximal to the wrist. At this location, the ulnar nerve is prone to injury from trauma, such as dog bites, other penetrating injuries, and nonaccidental self-injuries.* **(Bottom)** *Longitudinal US shows the ulnar nerve at the distal 1/3 of the forearm. Note the fibrillar pattern of the nerve with a mixed hypoechoic and hyperechoic pattern due to hypoechoic nerve fascicles separated by hyperechoic perineurium.*

GUYON CANAL

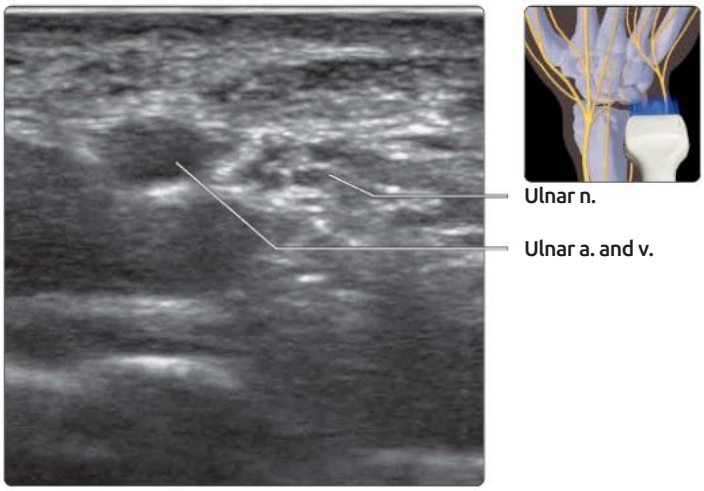

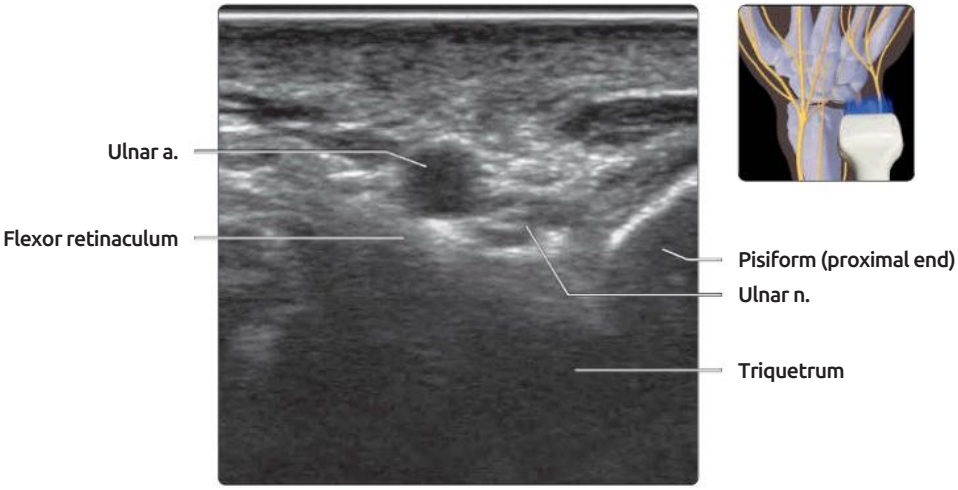

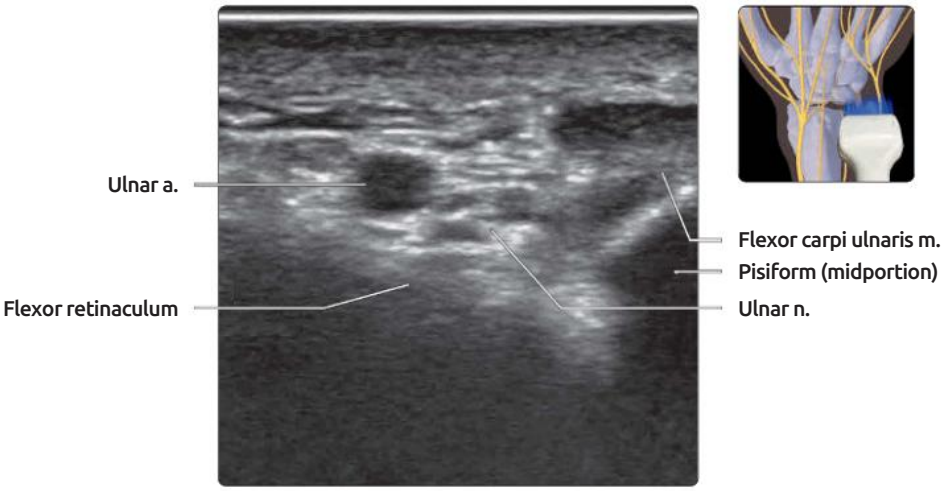

(Top) *Transverse US shows the ulnar nerve just proximal to the Guyon canal.* **(Middle)** *Transverse US shows the ulnar nerve at the proximal end of the Guyon canal. The Guyon canal is the 2nd most common site of ulnar neuropathy.* **(Bottom)** *Transverse US shows the ulnar nerve at the distal end of the Guyon canal. Ganglia arising from the pisiform-triquetral articulation are the most common cause of ulnar nerve compression in Guyon canal.*

DISTAL TO GUYON CANAL

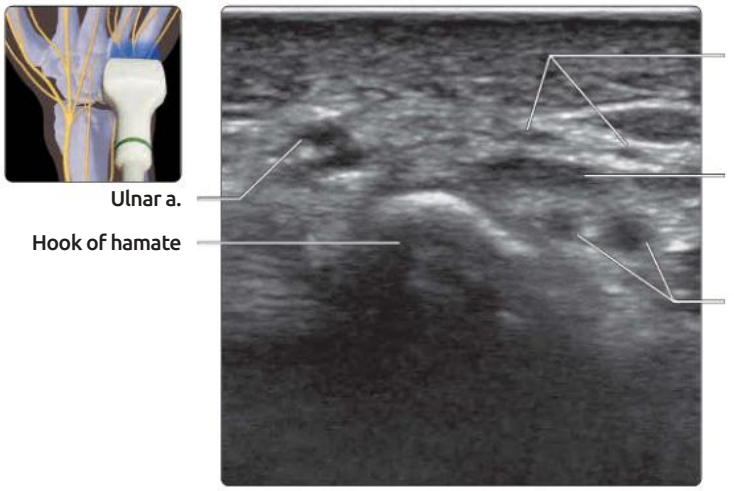

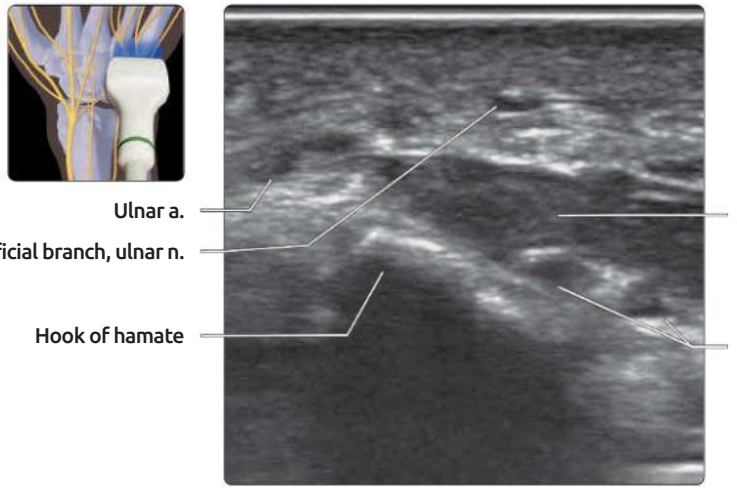

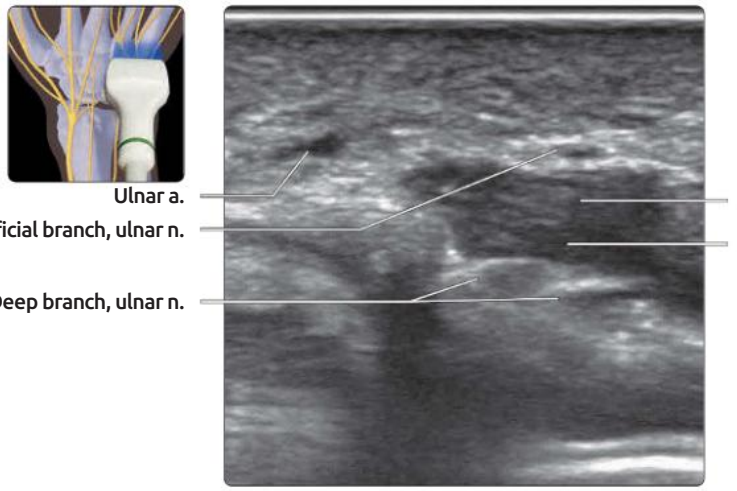

(Top) *Transverse US shows the ulnar nerve at the distal end of the Guyon canal where the ulnar nerve divides into superficial and deep branches. These pass close to the top of (superficial branch) and outer side of (deep branch) the hook of hamate.* **(Middle)** *Transverse US shows the ulnar nerve at the distal end of the hook of hamate level. Hook of hamate fractures (common in golfers and baseball players) and repeated blunt trauma ("handlebar palsy") may injure the ulnar nerve as it passes alongside the hook of hamate. The ulnar artery can be injured at this location as well (hypothenar hammer syndrome).* **(Bottom)** *Transverse US shows the ulnar nerve at the base of the hypothenar muscles. The superficial branch of the ulnar nerve stays superficial to supply the skin, whereas the deep branch stays deep to supply the hypothenar muscles and the 3rd and 4th lumbrical muscles.*

PROXIMAL AND DISTAL ULNAR NERVE

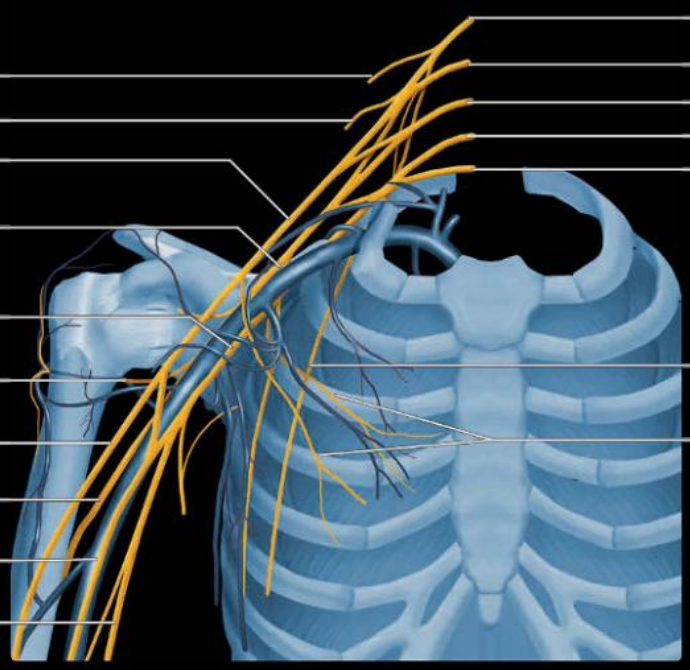

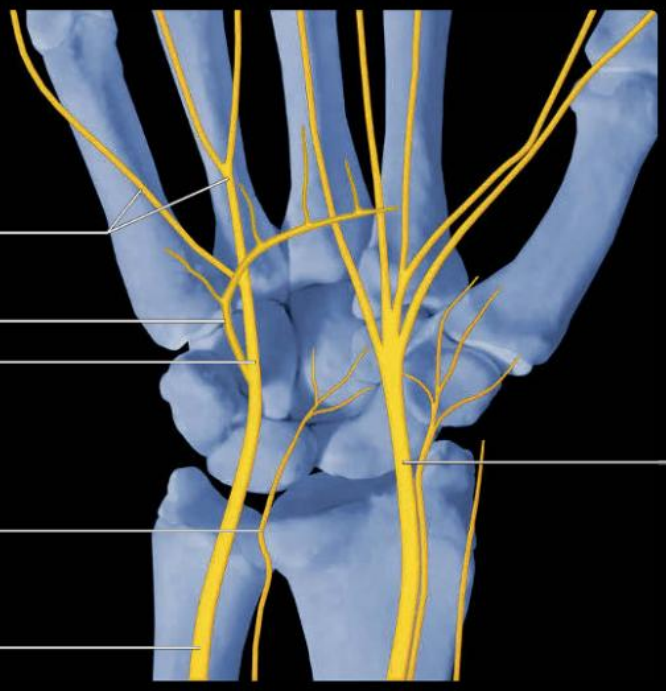

(Top) *Anterior graphic shows the ulnar nerve arising from the medial cord of the brachial plexus.* **(Bottom)** *The ulnar nerve supplies the ulnar aspect of the wrist and hand. In addition to the ulnar nerve branches shown, these is also a dorsal branch of the ulnar nerve which passes between the flexor carpi ulnaris and the ulna. The dorsal branch emerges from the ulnar nerve 5 cm proximal to the wrist to supply the dorsal ulnar wrist and the little finger. Deep and superficial branches supply motor and sensory branches to the hypothenar eminence.*

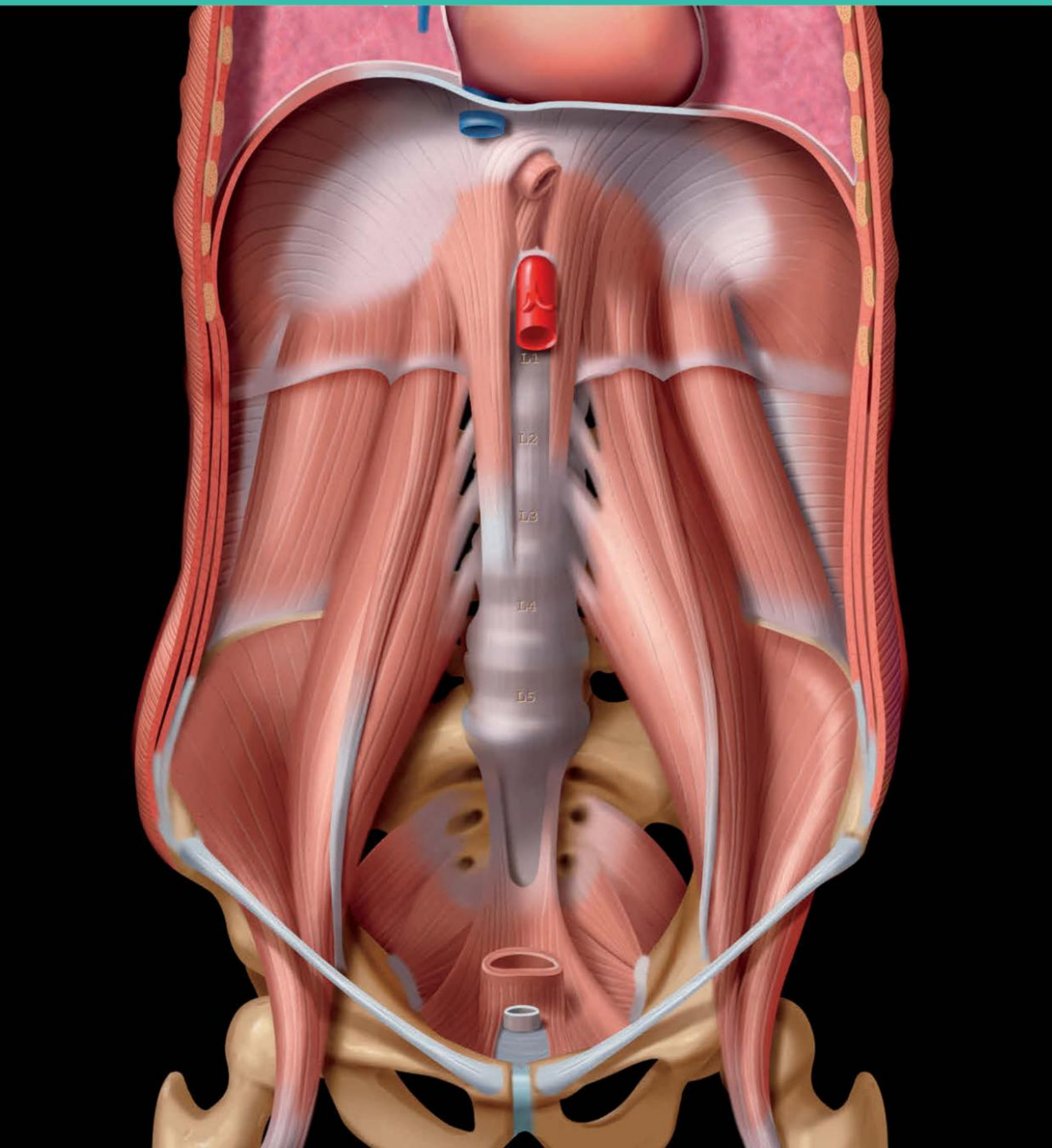
L1
L2
L3
L4
L5

PART I
SECTION 2

Trunk

Chest Wall	168
Abdominal Wall	174
Paraspinal Structures	182
Groin	190
Pelvic and Thigh Nerves	200

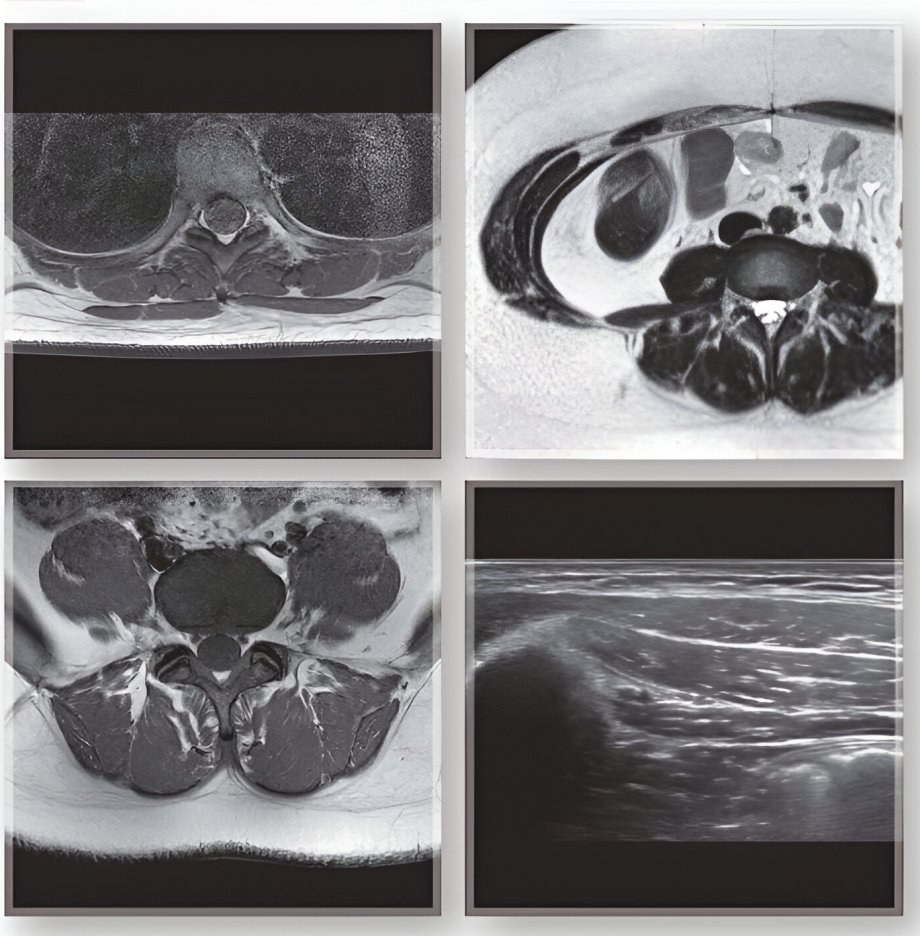

GENERAL ANATOMY & FUNCTION

Chest Wall Anatomy

- Main function is to protect lungs & mediastinum
  - Assists respiration

Surface Landmarks

- Suprasternal (jugular) notch: At superior manubrium of sternum; between sternal ends of clavicles
- Sternal angle (angle of Louis): Angle formed between manubrium & body of sternum at manubriosternal joint
- Costal margin: Inferior margins of lowest ribs & costal cartilages

SKELETAL STRUCTURES

Sternum

- Flat, broad bone that forms anterior thoracic wall; 3 parts
  - Manubrium forms superior part of sternum
  - Body articulates with manubrium superiorly, xiphoid process inferiorly, costal cartilages of 2nd-7th ribs bilaterally
  - Xiphoid process variable in size, shape, ossification, and degree of fusion with body of sternum

Ribs

- 12 pairs, symmetrically arrayed; numbered according to attached vertebral body
- True ribs (1-7) attach to sternum by costal cartilages
- False ribs (8-10) articulate by costal cartilages with costal cartilage of 7th rib
- Floating ribs (11-12) do not articulate with sternum or rib costal cartilages; short costal cartilages terminate in abdominal wall muscle
- Head of rib articulates with hemifacets of 2 adjacent vertebral bodies; neck located between head & tubercle; tubercle articulates with transverse process
- Body: Longest part of each rib
- Angle: Most posterior part
- Rib location can be broadly categorized as midclavicular, anterior axillary, midaxillary, posterior axillary, & dorsal sections
- Costal groove on inner surface of inferior border, accommodates intercostal neurovascular bundle
- Costal cartilage can normally calcify, usually parallel to surface ± punctuate internal calcification
  - No known association, though may mimic rib fracture on US

MUSCLES

Pectoral

- Pectoralis major: Largest muscle in pectoral region; extends from anterior chest wall, sternum, & clavicle to lateral lip of bicipital groove
  - Adducts, flexes, & medially rotates arm
  - Prone to hypoplasia or aplasia: Sternocostal > clavicle portion > whole muscle
- Pectoralis minor: Deep to pectoralis major; extends from chest wall to coracoid process of scapula
  - Stabilizes scapula
- Sternalis: Anatomic variant (in 5% of cadavers), runs parallel to sternum & connects sternocleidomastoid muscle to rectus abdominis muscle

Intercostal

- External: Contained within 11 intercostal spaces; extends from tubercle of ribs to costochondral junction
- Internal: Middle layer; occupies 11 intercostal spaces; extends from border of sternum to angle of ribs
- Innermost: Forms inner layer of chest wall muscles with subcostales & transversus thoracis muscles

Transversus Thoracis

- Extends from posterior surface of lower 1/3 of sternal body & xiphisternum to posterior surface of 2nd-6th costal cartilages
  - Lower fibers run horizontally; intermediate fibers run obliquely; higher fibers run vertically
  - Assists with respiration; hypertrophied in performance athletes

Serratus Anterior

- Thin muscular sheet; overlies lateral thoracic cage & intercostal muscles; arises from upper 8 ribs; wraps around rib cage; inserts along medial anterior surface of scapula

VESSELS & NERVES

Arteries

- Internal thoracic (internal mammary): Branch of subclavian artery; descends posterior to first 6 costal cartilages; supplies upper anterior chest wall
  - Supplies anterior intercostal arteries to first 6 intercostal spaces

Veins

- Azygos vein receives drainage from posterior intercostal veins, hemiazygos, & accessory hemiazygos veins

Nerves

- Anterior rami of thoracic spinal nerves (T1-T11) form intercostal nerves
- Intercostal nerves run in costal groove between internal & innermost intercostal muscles
- T1-T2 supplies upper limb, T3-T6 supplies chest wall, T7-T11 supplies chest & abdominal wall, T12 supplies abdomen & groin

IMAGING

Radiography

- Poor at detecting rib fractures

US

- Allows detailed examination of intercostal spaces, ribs, & costal cartilages
  - Intercostal muscles are seen as hypoechoic structures
- Only anterior cortex of ribs evaluated

Computed Tomography

- Excellent visualization of chest wall lesions

RIBS AND INTERCOSTAL SPACES

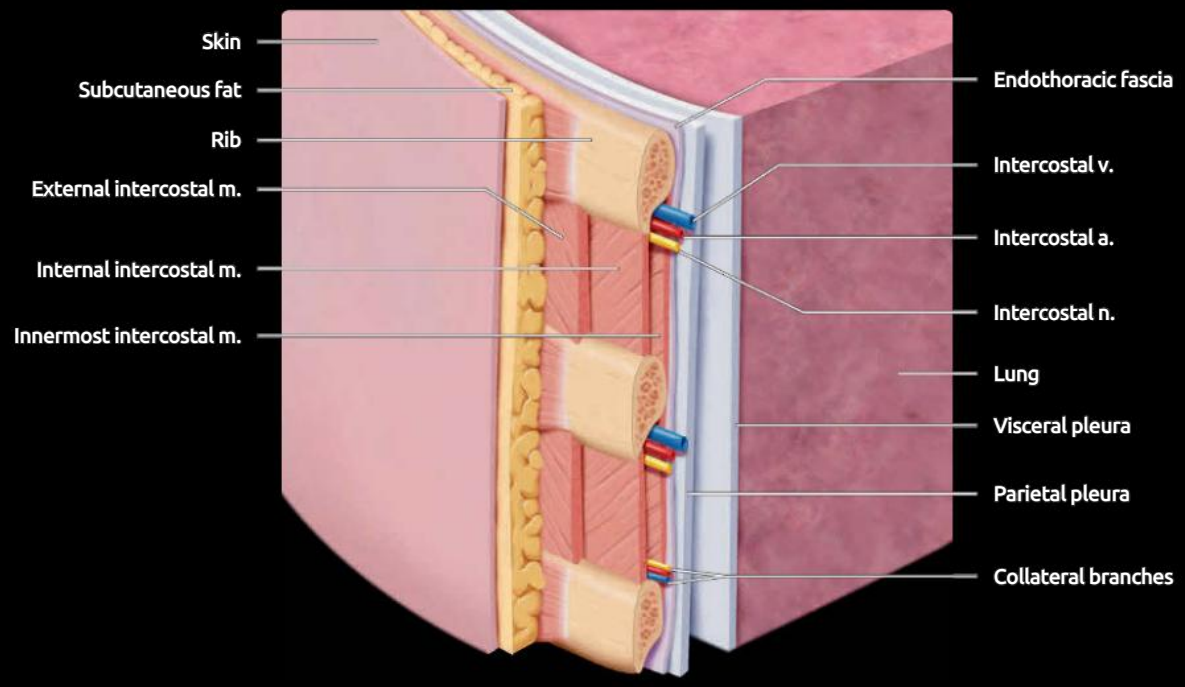

(Top) *Graphic shows the chest wall layers and vessels.* **(Bottom)** *Graphic shows the intercostal region with 3 layers of intercostal muscles (external, internal, and innermost) between the ribs. The costal groove along the inferomedial aspect of each rib accommodates the intercostal neurovascular bundle (vein, artery, and nerve). Small collateral branches of the major intercostal vessels and nerves may be present above the body of the subjacent rib. The endothoracic fascia forms a connective tissue layer between the inner aspect of the chest wall and the costal parietal pleura.*

STERNUM

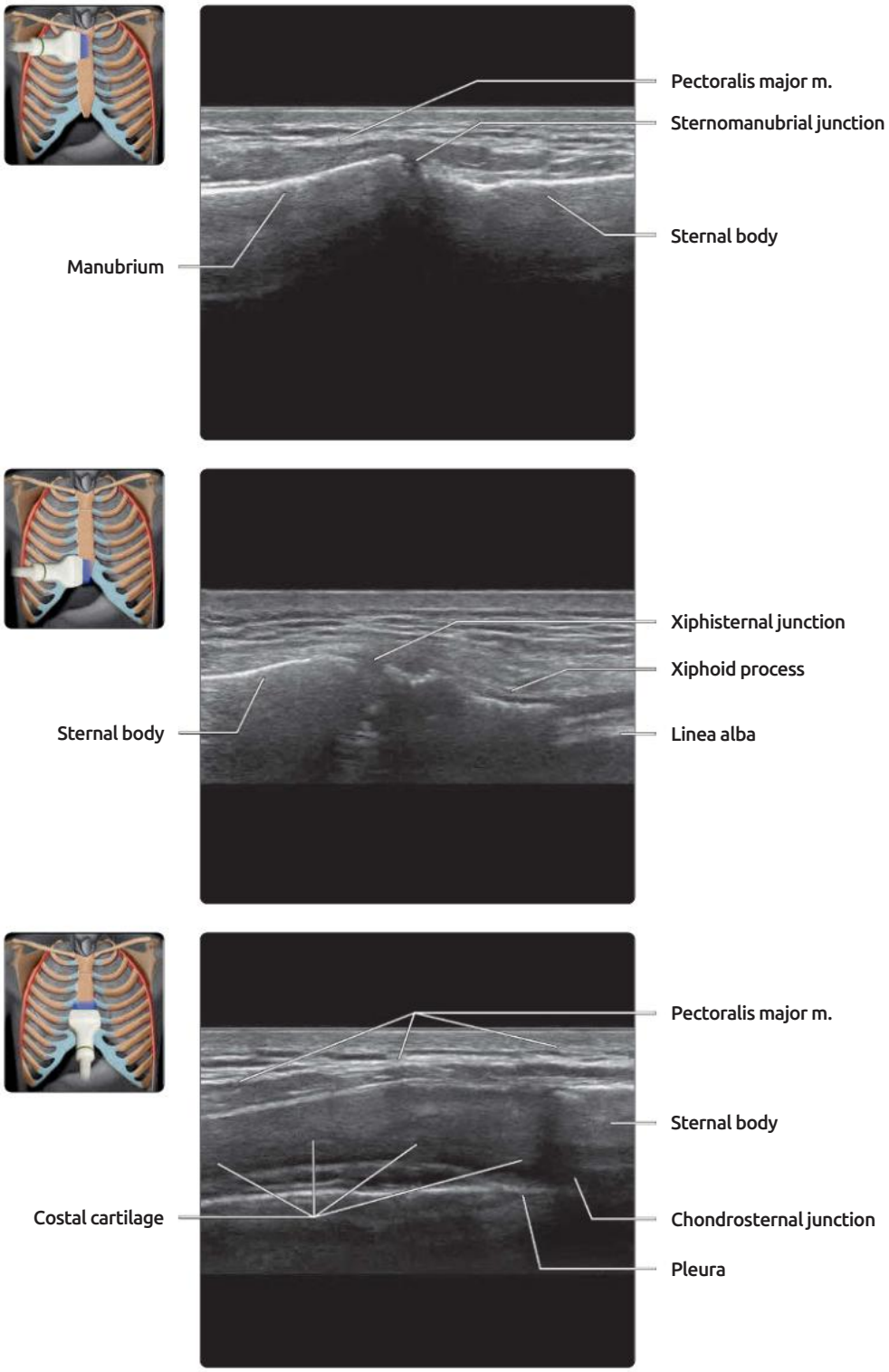

(Top) *Longitudinal US shows the sternomanubrial joint at the upper end of the sternal body. The sternomanubrial joint is classified as a symphysis rather than synchondrosis. Both synchondrosis and symphysis are cartilaginous joints. With synchondrosis, the bones are joined by hyaline cartilage. With symphysis, the bones are joined by fibrocartilage.* **(Middle)** *Longitudinal US shows the xiphisternum at the lower margin of the sternal body. This xiphisternal junction should not be mistaken for a fracture. The xiphisternum is occasionally more cartilaginous and also more fixed to the sternal body. The xiphisternal joint is a synchondrosis.* **(Bottom)** *Transverse US of the midsternal region shows the pectoralis major muscle attached to the anterior aspect of the sternal body and spreading out over the costal cartilages and ribs.*

RIBS

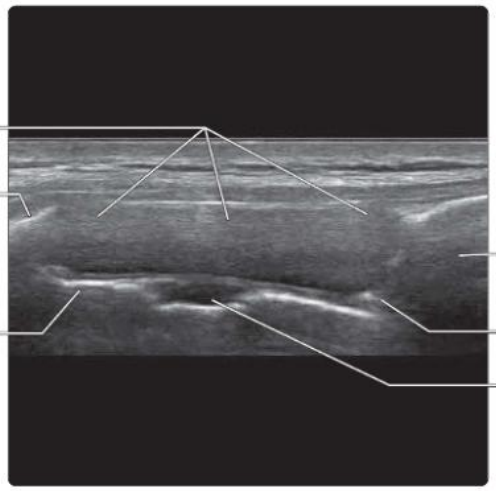

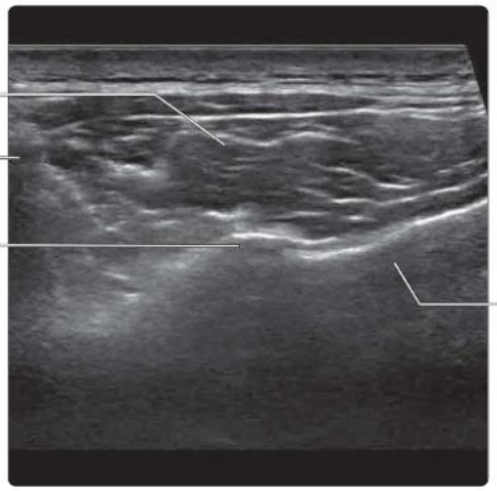

(Top) *Transverse US shows 2nd costal cartilage with costochondral and chondrosternal junctions. The 1st chondrosternal junction is a synchondrosis. The remaining chondrosternal joints are classified as synovial joints and may become inflamed in inflammatory arthropathies. Internal mammary vessels run deep to the costal cartilages. One can also appreciate the pectoralis major muscle attached to the superficial surface of the sternal body.* **(Middle)** *Transverse US shows the transition between the hypoechoic costal cartilage and the hyperechoic anterior cortex of the ossified portion of the rib. The pleura is visible deep to the costal cartilage, though it is not visible deep to the rib.* **(Bottom)** *Transverse US of the posterior aspect of rib shows the junction between the rib tubercle of the rib and the transverse process of a thoracic vertebrae.*

INTERCOSTAL SPACES

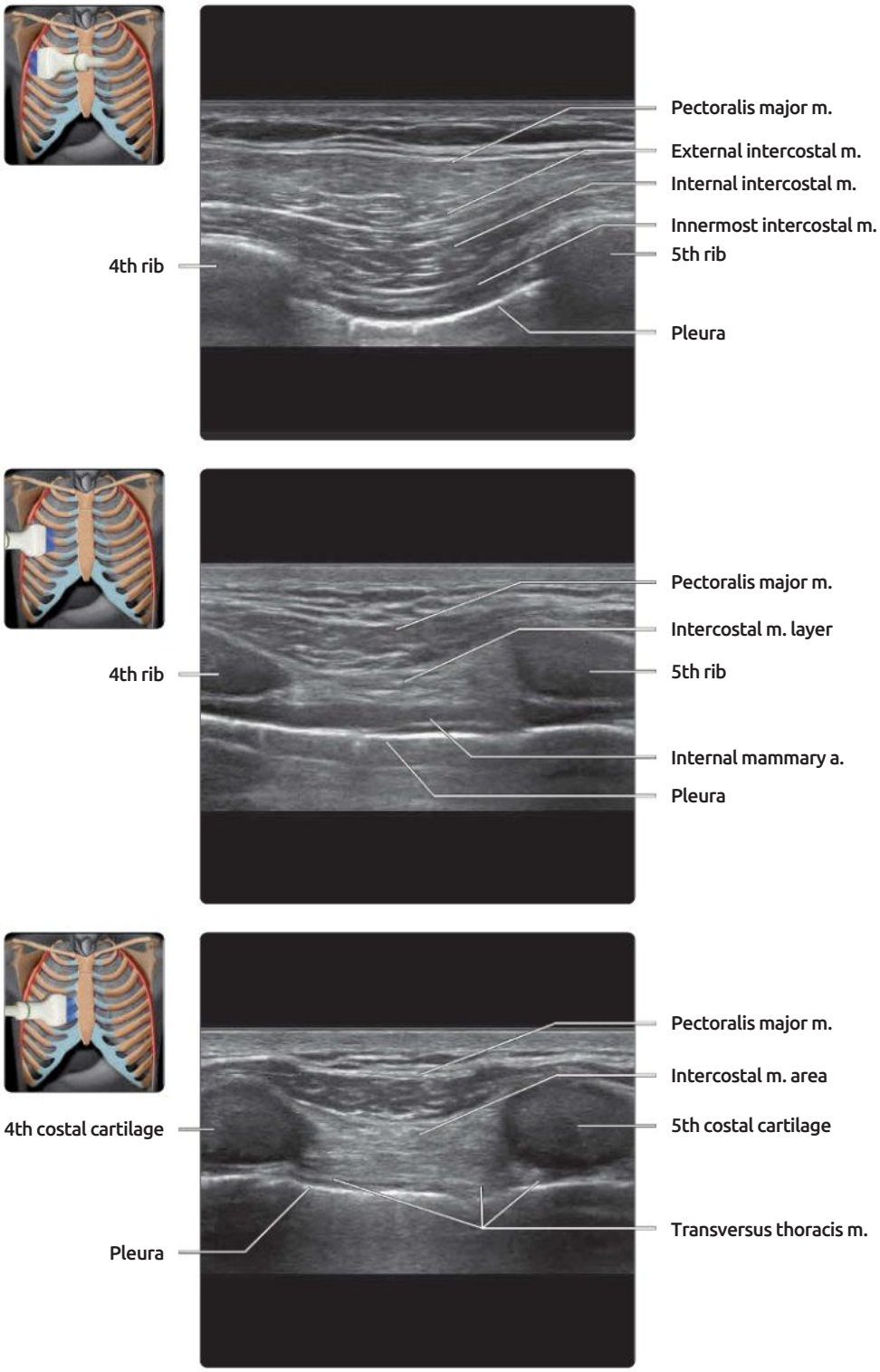

(Top) *Longitudinal US shows the 3 layers of the intercostal muscle (external, internal, and innermost) between opposing ribs at the anterior axillary. The pectoralis major muscle overlies these intercostal muscles. The pleura lies deep to the intercostal muscles.* **(Middle)** *Longitudinal US just medial to the midclavicular line shows the internal mammary artery running between the pleura and the costal cartilages.* **(Bottom)** *Longitudinal US of the parasternal area between the 4th and 5th costal cartilages shows the transversus thoracis muscle deep to the intercostal muscles. This small muscle assists with respiration and can hypertrophy in performance athletes, though it is largely supernumerary. It is not visible lateral to the internal mammary artery.*

PECTORALIS MAJOR MUSCLE

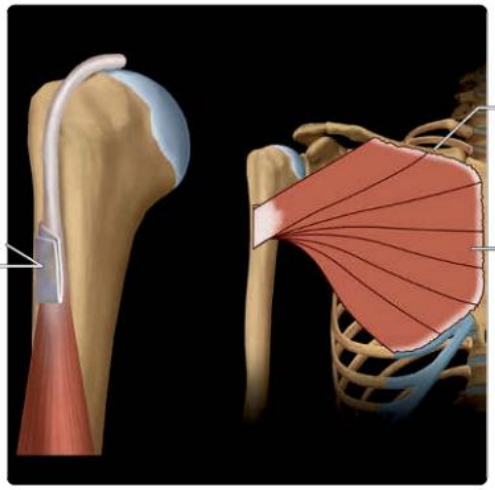

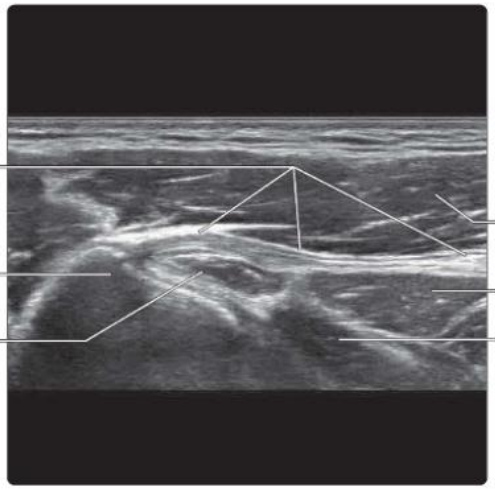

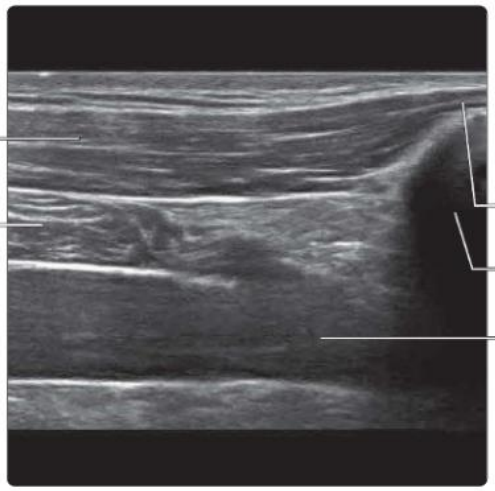

(Top) *Graphic shows the clavicular and sternal heads of the pectoralis major muscle converging to insert on the lateral lip of the lowermost part of the bicipital groove. The pectoralis major tendon is U-shaped. The anterior tendon layer is formed from the clavicular head and upper sternal head fibers. The posterior tendon layer is formed from the lower sternal head fibers.* **(Middle)** *Transverse US of the proximal arm shows the pectoralis major tendon insertion into the lateral lip of the bicipital groove. The musculotendinous junction of the long head of biceps lies just deep to this pectoralis major tendon. The anterior and posterior layers of the pectoralis tendon cannot be readily appreciated on US examination.* **(Bottom)** *Longitudinal US shows part of the clavicular head of the pectoralis major muscle originating from the superior margin of the clavicle. The pectoralis minor runs deeply to insert usually into the coracoid process. Not infrequently, the pectoralis minor insertion bypasses the coracoid process either partially or entirely to insert into the supraspinatus tendon, coracoacromial ligament, proximal humerus, or coracohumeral ligament.*

TERMINOLOGY

Definitions

- Abdomen: Region between diaphragm & pelvis

GROSS ANATOMY

Anatomic Boundaries of Anterior Abdominal Wall

- Superiorly: Xiphoid process & costal cartilages of 7th-10th ribs
- Inferiorly: Iliac crest, iliac spine, inguinal ligament, & pubis
- Inguinal ligament is inferior edge of external oblique aponeurosis

Muscles of Anterior Abdominal Wall

- Consists of 3 flat muscles (external oblique, internal oblique, & transversus abdominis) & 1 strap-like muscle (rectus)
- Combination of muscles & aponeuroses (sheet-like tendons) act as corset to confine & protect abdominal viscera
- Linea alba is fibrous raphe stretching from xiphoid to pubis
  - Forms central anterior attachment for abdominal wall muscles
  - Formed by interlacing fibers of aponeuroses of oblique & transverse abdominal muscles
  - Rectus sheath also formed by these aponeuroses as they surround the rectus muscle
- Linea semilunaris is vertical fibrous band at lateral edge of rectus sheath bilaterally
  - Aponeuroses of internal & transversus abdominis join in linea semilunaris before forming rectus sheath
- External oblique muscle
  - Largest & most superficial of 3 flat abdominal muscles
  - Origin: External surfaces of ribs 5-12
  - Insertion: Linea alba, iliac crest, pubis via broad aponeurosis
- Internal oblique muscle
  - Middle of 3 flat abdominal muscles
  - Runs at right angles to external oblique
  - Origin: Posterior layer of thoracolumbar fascia, iliac crest, & inguinal ligament
  - Insertion: Ribs 10-12 posteriorly, linea alba via broad aponeurosis, pubis
- Transversus abdominis muscle
  - Innermost of 3 flat abdominal muscles
  - Origin: Lowest 6 costal cartilages, thoracolumbar fascia, iliac crest, inguinal ligament
  - Insertion: Linea alba via broad aponeurosis, pubis
- Rectus abdominis muscle
  - Origin: Pubic symphysis & pubic crest
  - Insertion: Xiphoid process & costal cartilages 5-7
  - Rectus sheath: Strong, fibrous compartment that envelops each rectus muscle
    - Contains superior & inferior epigastric vessels
- Actions of anterior abdominal wall muscles
  - Support & protect abdominal viscera
  - Help flex & twist trunk, maintain posture
  - Increase intraabdominal pressure for defecation, micturition, & childbirth
  - Stabilize pelvis during walking, sitting up
- Transversalis fascia
  - Lies deep to abdominal wall muscles & lines entire abdominal wall
  - Separated from parietal peritoneum by layer of extraperitoneal fat

Muscles of Posterior Abdominal Wall

- Consist of psoas (major & minor), iliacus, & quadratus lumborum
- Psoas: Long, thick, fusiform muscle lying lateral to vertebral column
  - Origin: Transverse processes & bodies of vertebrae T12-L5
  - Insertion: Lesser trochanter of femur (passing behind inguinal ligament)
  - Action: Flexes thigh at hip joint; bends vertebral column laterally
- Iliacus: Large, triangular sheet of muscle lying along lateral side of psoas
  - Origin: Superior part of iliac fossa
  - Insertion: Lesser trochanter of femur (after joining with psoas tendon)
  - Action: Iliopsoas muscle flexes thigh
- Quadratus lumborum: Thick sheet of muscle lying adjacent to transverse processes of lumbar vertebrae
  - Invested by lumbodorsal fascia
  - Origin: Iliac crest & transverse processes of lumbar vertebrae
  - Insertion: 12th rib
  - Actions: Stabilizes position of thorax & pelvis during respiration, walking; bends trunk to side

Paraspinal Muscles

- Also called erector spinae muscles
  - Invested by lumbodorsal fascia
- Composed of 3 columns
  - Iliocostalis: Lateral
  - Longissimus: Intermediate
  - Spinalis: Medial
- Origins: Sacrum, ilium, & spines of lumbar & 11th-12th thoracic vertebrae
- Insertions: Ribs & vertebrae with additional muscle slips joining columns at successively higher levels
- Action: Extends vertebral column

ANATOMY IMAGING ISSUES

Imaging Recommendations

- Compare with contralateral side to check for symmetry
- Routine image during Valsalva maneuver if suspected hernia
  - Particularly if symptoms are aggravated by weight bearing, also examine in standing position if supine examination is negative for hernia
- Pay particular attention to deep margin of any mass
  - Critical to ensure that any mass is not emerging from abdominal cavity
- Perform color Doppler imaging during breath hold
  - Even movement from quiet respiration can artifactually simulate color flow

ANTERIOR ABDOMINAL WALL

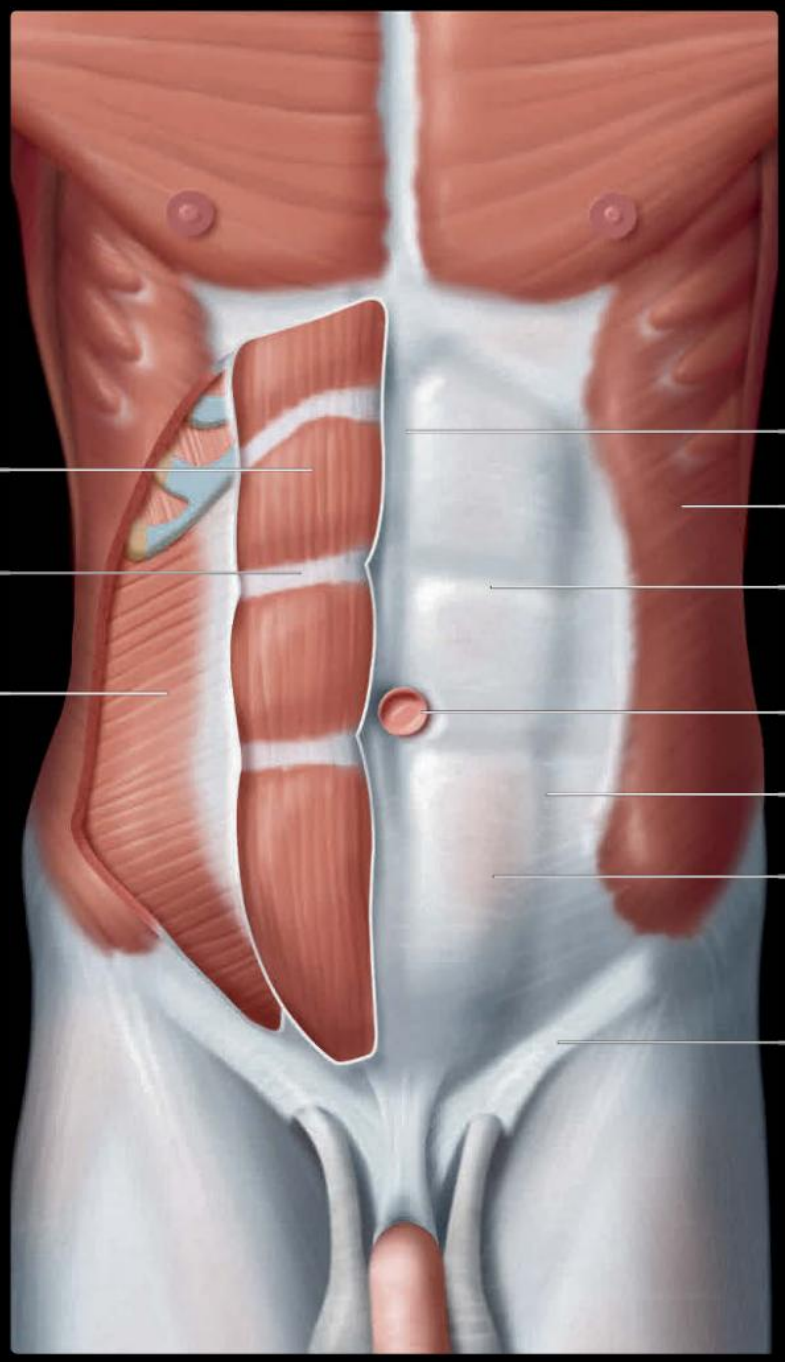

Graphic shows the aponeuroses of the anterior abdominal wall. At the lateral border of the rectus muscle ("linea semilunaris"), the internal oblique aponeurosis splits into 2 layers. The anterior layer and the external oblique aponeurosis form the anterior layer of the rectus sheath. The posterior layer and the transversus abdominus aponeurosis form the posterior layer. Midway between the umbilicus and symphysis, at the arcuate line, the posterior rectus sheath ends. Below this, the transversalis fascia is the only structure between the rectus muscle and parietal peritoneum.

POSTERIOR ABDOMINAL WALL

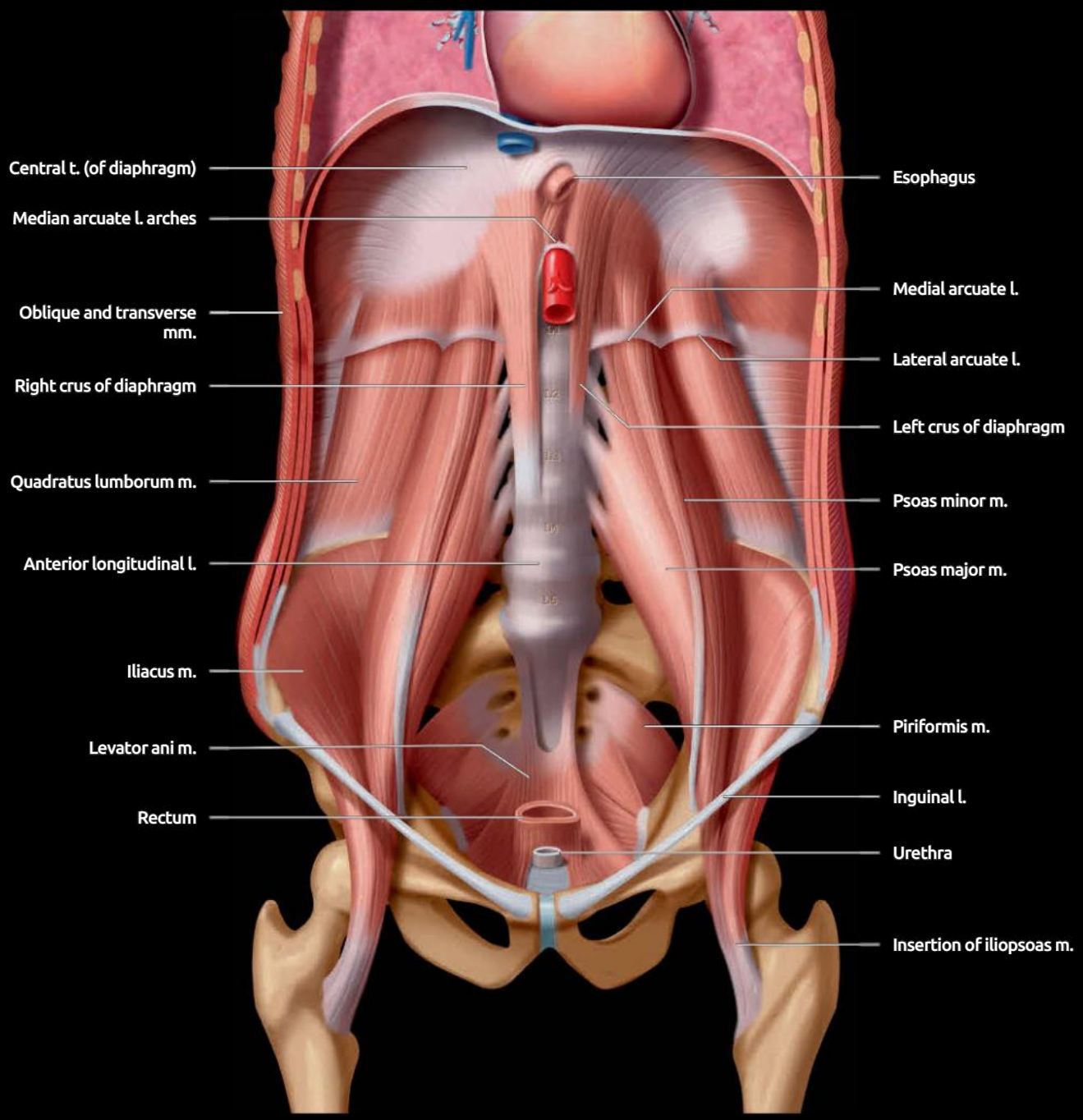

Graphic shows the lumbar vertebrae covered by the anterior longitudinal ligament and the diaphragmatic crura closely attached to it, as are the origins of the psoas muscles, which also arise from the transverse processes. The iliacus muscle arises from the iliac fossa of the pelvis and inserts into the tendon of the psoas major, constituting the iliopsoas tendon, which inserts onto the lesser trochanter. The quadratus lumborum arises from the iliac crest and inserts onto the 12th rib and transverse processes of the lumbar vertebrae. The psoas and quadratus lumborum pass behind the diaphragm under the medial and lateral arcuate ligaments.

MUSCLES OF BACK IN SITU

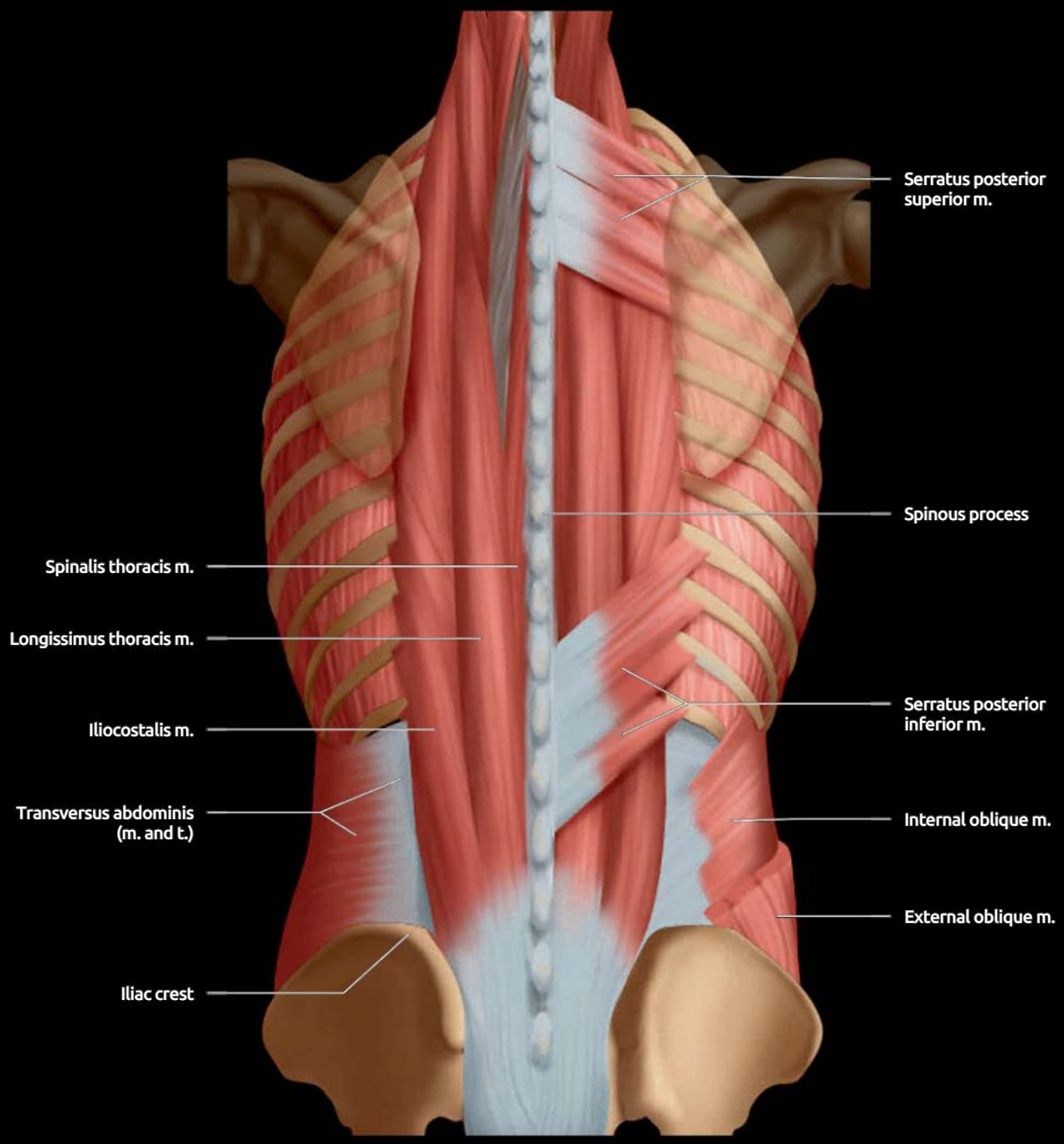

Graphic shows the paraspinal and back muscles. Latissimus dorsi muscles are not included. The erector spinae have thick, tendinous origins from the sacral and iliac crests, and the lumbar and 11th-12th thoracic spinous processes. Superiorly, the muscle becomes fleshy and in the upper lumbar region subdivides to become the iliocostalis, longissimus, and spinalis muscles (from lateral to medial), tapering as they insert into the vertebrae and ribs. The erector muscles flank the spinous processes and span the length of the posterior thorax and abdomen. They are responsible for extension of the vertebral column.

ANTERIOR ABDOMINAL WALL

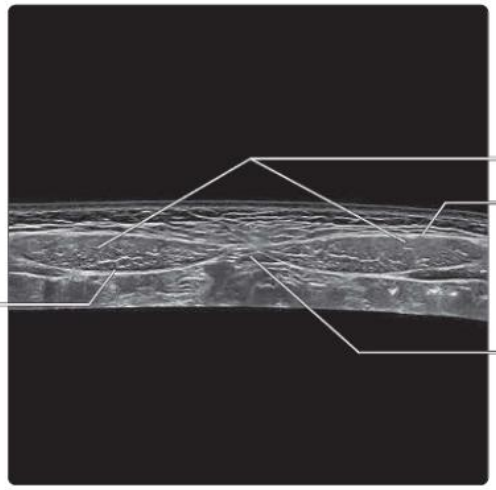

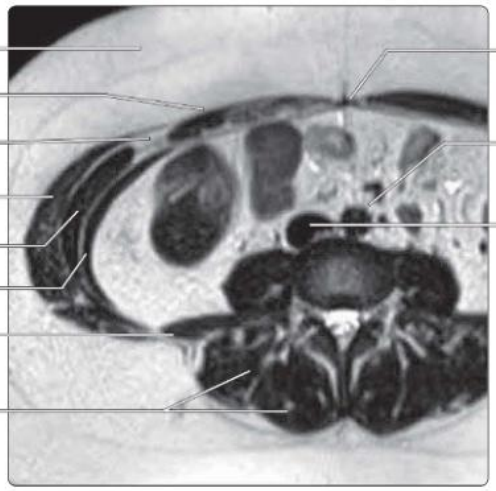

(Top) *Extended field-of-view transverse US shows the paired rectus abdominis muscles separated by the linea alba. The rectus sheath is seen as a thin echogenic structure surrounding the rectus abdominis muscles.* **(Middle)** *Transverse US shows the aponeurotic component of the external and internal oblique muscles anteriorly. This aponeurosis of the internal oblique muscle splits into 2 layers at the lateral margin of the rectus abdominis muscle to form the rectus sheath.* **(Bottom)** *Axial T2 HASTE MR in an older patient with muscle atrophy shows fat in between the individual muscles of the anterior and posterior abdominal wall.*

ANTEROLATERAL ABDOMINAL WALL

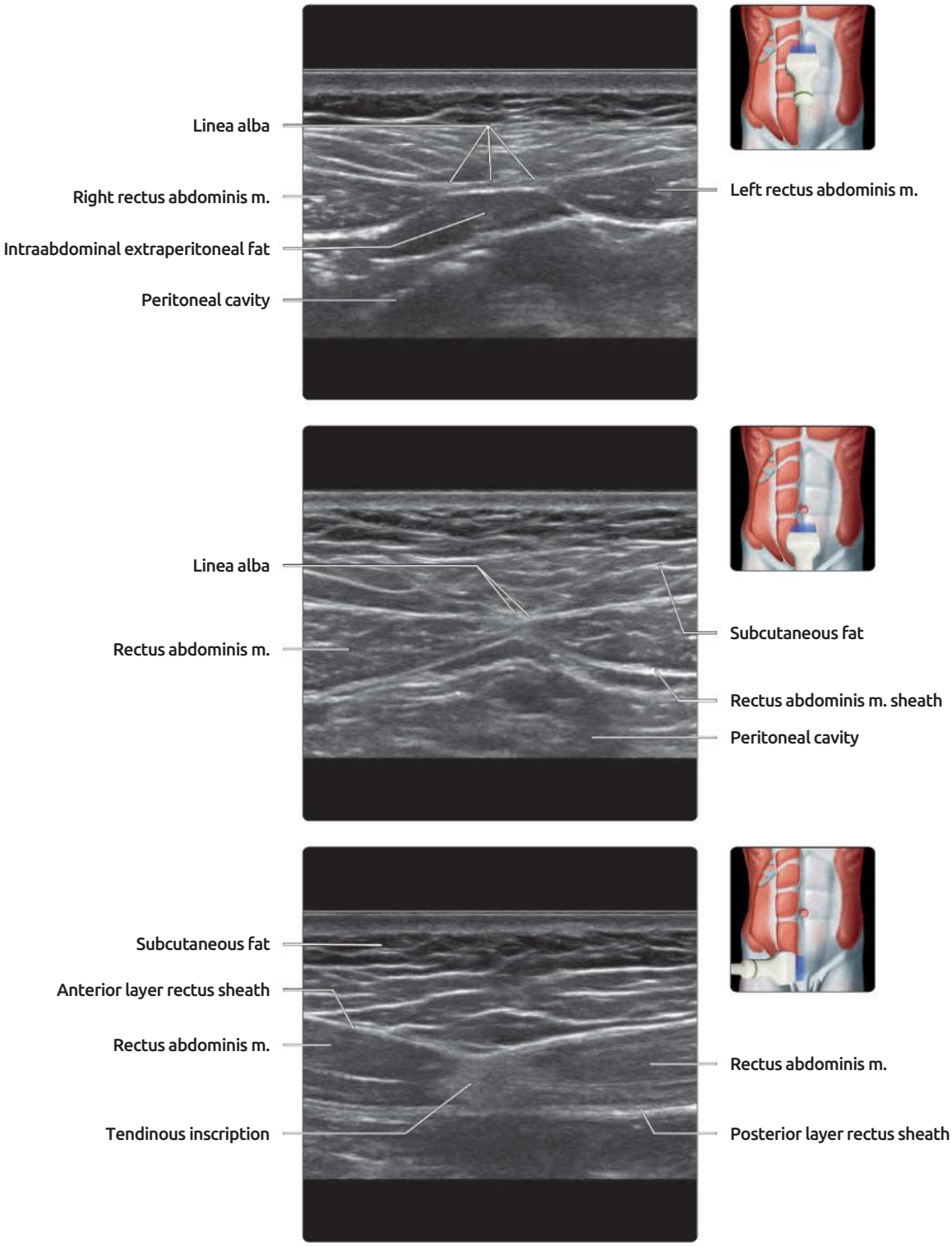

(Top) *Transverse US of the upper abdomen shows how the linea alba is considerably wider above the umbilicus compared to below the umbilicus. This is one of the reasons why fatty hernias of the linea alba nearly always occur.* **(Middle)** *Transverse US of the abdominal wall shows how the lineal alba becomes narrower below the umbilicus.* **(Bottom)** *Longitudinal US shows an echogenic fibrinous tendon inscription of a rectus abdominis muscle. There are at least 3 of these fibrinous inscriptions along the length of the rectus abdominis muscle. Muscle bulging between these inscriptions gives rise to the 6-pack appearance of the anterior abdominal wall.*

INFERIOR EPIGASTRIC ARTERY

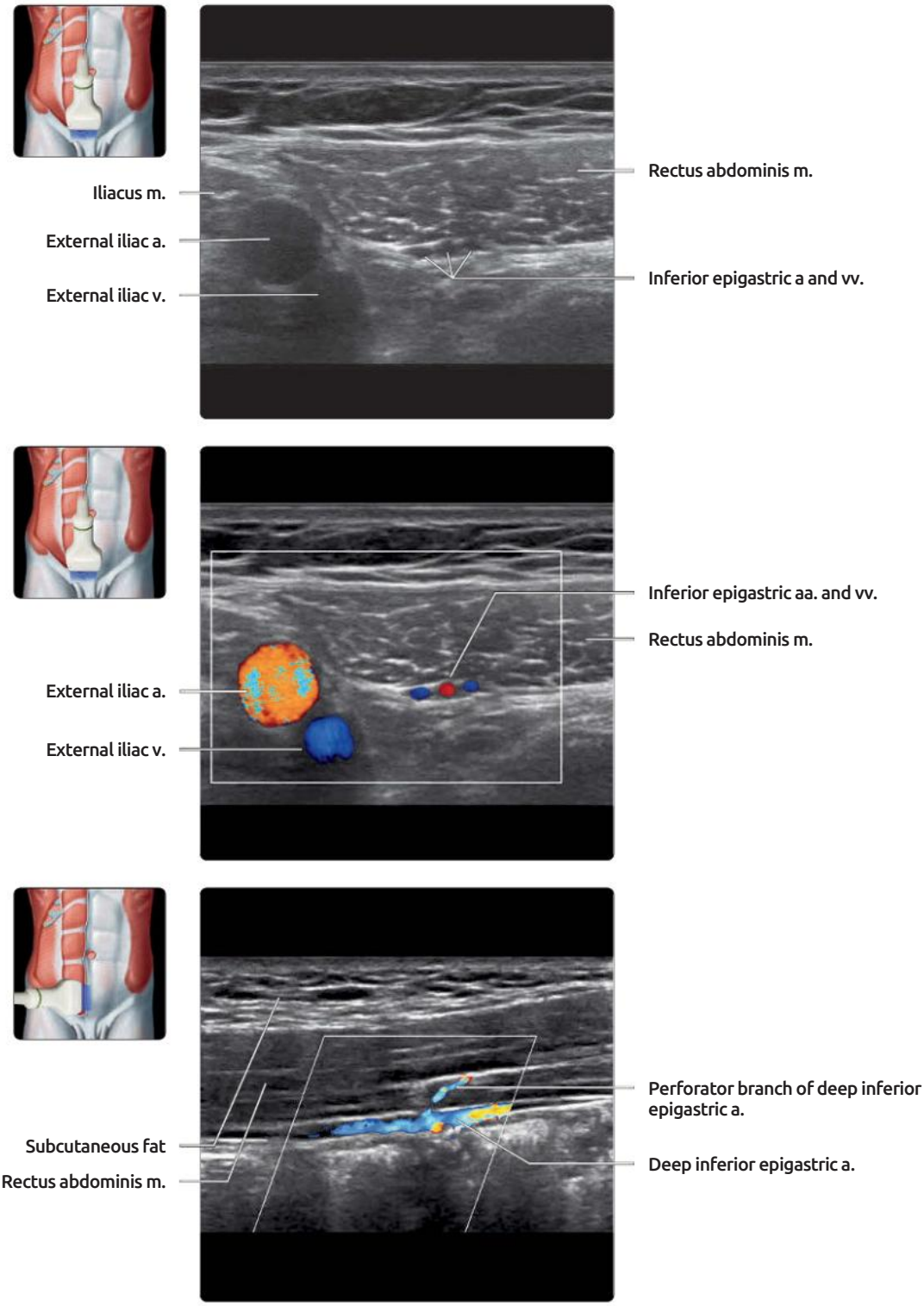

(Top) *Transverse US of the more distal part of the rectus abdominis muscle shows the inferior epigastric vessels, which usually comprises a central artery and 2 accompanying veins.* **(Middle)** *Transverse color Doppler US increases visibility of the interior epigastric arteries and veins.* **(Bottom)** *Longitudinal color Doppler US shows a perforating branch of the deep inferior epigastric artery extending into the rectus muscle. These perforators are important for breast reconstruction with abdominal wall flaps.*

OBLIQUE MUSCULATURE

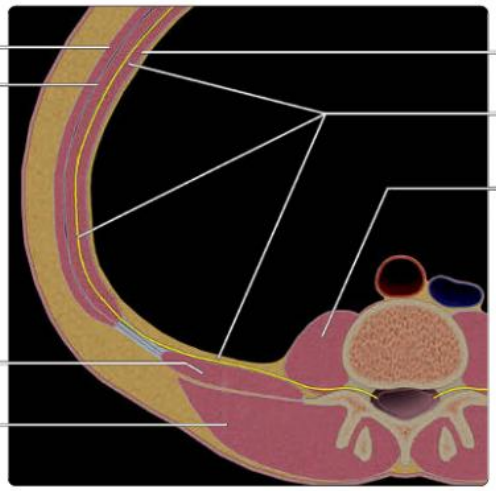

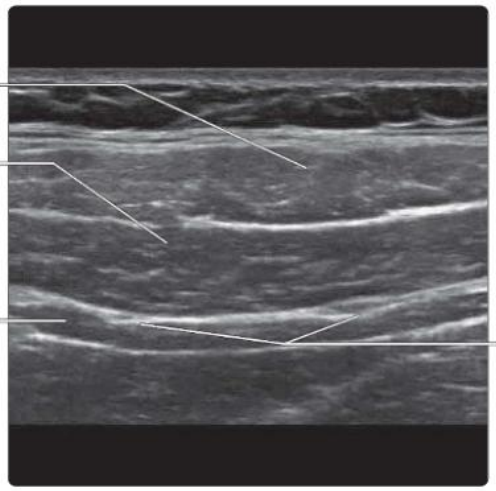

(Top) *Graphic shows the location of the iliohypogastric and ilioinguinal nerves. Both nerves run between the internal oblique and the transversus abdominis muscles with the iliohypogastric nerve being more medially located (only 1 nerve is depicted in the graphic). The iliohypogastric nerve provides sensory innervation to the gluteal and hypogastric regions. The ilioinguinal nerve provides sensory innervation to the groin, inner thigh, and labia majora.* **(Middle)** *Transverse US of the anterolateral abdominal wall shows the 3 layers of the abdominal wall, namely, the external oblique, internal oblique, and transversus abdominis muscles. Both the Ilioinguinal and the iliohypogastric nerves run between the internal oblique and the transversus abdominis muscles. The iliohypogastric nerve lies more medial than the ilioinguinal nerve. This can be remembered by recalling that "hypogastric" means "below the stomach."* **(Bottom)** *Transverse US of a more medial distal section than the previous image shows the 3 muscle layers of the abdominal wall with the ilioinguinal and iliohypogastric nerves between the internal oblique and the transversus abdominis muscles.*

GROSS ANATOMY

Paraspinal Muscles: General Considerations

- Paraspinal muscles can be divided into 3 groups
  - Superficial extrinsic back muscles (assist upper limb movement) include trapezius, levator scapulae, latissimus dorsi, rhomboid major & minor
  - Intermediate extrinsic back muscles (assist respiration): Serratus posterior superior, serratus posterior inferior
  - Intrinsic back muscles (assist spinal movement, mainly extension), which can be further divided into 3 layers
    - Superficial layer, including splenius muscles located in lateral & posterior neck region
    - Intermediate layer (erector spinae) spans cervical, thoracic, & lumbar spine & contains iliocostalis, longissimus, & spinalis muscles
      - Spinalis muscle difficult to separate from adjacent muscles on US
    - Deep layer, located between spinous process & transverse processes, is composed of semispinalis, multifidus, & rotatores muscles
      - Rotatores muscle is difficult to differentiate from adjacent muscles on US

Paraspinal Muscles of Thoracolumbar Region

- Also referred to as erector spinae muscles
  - Invested by lumbodorsal fascia
- Iliocostalis thoracis
  - Origin: Angles of lower 6 ribs
  - Insertion: Transverse process of C7 & angles of upper 6 ribs
- Longissimus thoracis (thoracic part)
  - Longest component of erector spinae, consisting of thoracic & lumbar parts
  - Origin: Lumbar spinous processes, supraspinous ligament, median sacral crest, posterior surface of sacrum, dorsal segment of iliac crest
  - Insertion: Thoracic transverse processes & adjacent ribs
- Semispinalis thoracis
  - Lies deep to spinalis thoracis & superficial to multifidus muscle
  - Origin: Transverse processes of 6th-10th thoracic vertebrae
  - Insertion: Spinous processes of lower 2 cervical & upper 4 thoracic vertebrae
- Thoracic multifidus
  - Origin: Transverse processes of thoracic vertebrae near their bases
  - Insertion: Spinous processes at 2-5 levels cephalad to their origin
  - In thoracic spine, multifidus hugs spinous processes, semispinalis thoracis lies just lateral to the multifidus on surface of lamina
    - Longissimus thoracis (largest among thoracic erector spinae) lies on transverse process with iliocostalis thoracis muscle lying more laterally
- Iliocostalis thoracis (lumbar part)
  - Origin: Iliac crest, sacrum, spinous processes T11 to L5
  - Insertion: Angles of lower 6-9 ribs
- Longissimus thoracis
  - Separated from lumbar multifidus muscle by wide cleavage plane filled with fat & veins
  - Origin: Lumbar intermuscular aponeurosis attaching to medium ilium & dorsal sacroiliac ligament
  - Insertion: Transverse process of lumbar vertebrae
- Lumbar multifidus
  - Covers lamina at upper lumbar levels, progressively expanding to cover sacral bone more caudally
  - Origin: Mammillary processes of lumbar vertebrae & posterior surface sacrum
    - Mammillary bodies are small, rough prominences on posterior aspects of superior articular processes of lumbar vertebrae
  - Insertion: Spinous processes at 2-5 levels cephalad to their origin

Muscles of Posterior Abdominal Wall

- Comprises psoas, iliacus, & quadratus lumborum
- Psoas: Long, thick, fusiform muscle lying lateral to vertebral column
  - Origin: Transverse processes & bodies of vertebrae T12-L5
  - Insertion: Lesser trochanter of femur
    - Joins iliacus muscle distally to form iliopsoas muscle
    - Can be examined from anterior, decubitus, & posterior positions
- Iliacus: Large, triangular sheet of muscle lying along lateral side of psoas
  - Origin: Superior part of iliac fossa
  - Insertion: Lesser trochanter of femur (after joining with psoas tendon)
- Quadratus lumborum: Thick sheet of muscle lying adjacent to transverse processes of lumbar vertebrae
  - Origin: Iliac crest & iliolumbar ligament
  - Insertion: 12th rib & transverse processes of L1-L4

Muscles of Anterior Abdominal Wall

- 3 flat muscles (external oblique, internal oblique, & transverse abdominal) & 1 strap-like muscle (rectus)
- External oblique muscle
  - Largest of 3 flat abdominal muscles
- Internal oblique muscle
  - Runs at right angles to external oblique muscle
- Transverse abdominal muscle
  - Innermost of 3 flat abdominal muscles
- Rectus abdominis muscle
  - Rectus sheath: Strong fibrous compartment that envelops each rectus muscle
  - 3 tendinous intersections divide rectus sheath into distinct muscle bellies
- Transversalis fascia
  - Lies deep to abdominal wall muscles & lines entire abdominal wall
  - Separated from parietal peritoneum by layer of extraperitoneal fat

ANATOMY IMAGING ISSUES

Imaging Recommendations

- US of paraspinal region is helpful for myofascial pain, guiding therapeutic infiltration, & localizing masses
- Compare with contralateral side to check for symmetry

ANTERIOR ABDOMINAL WALL

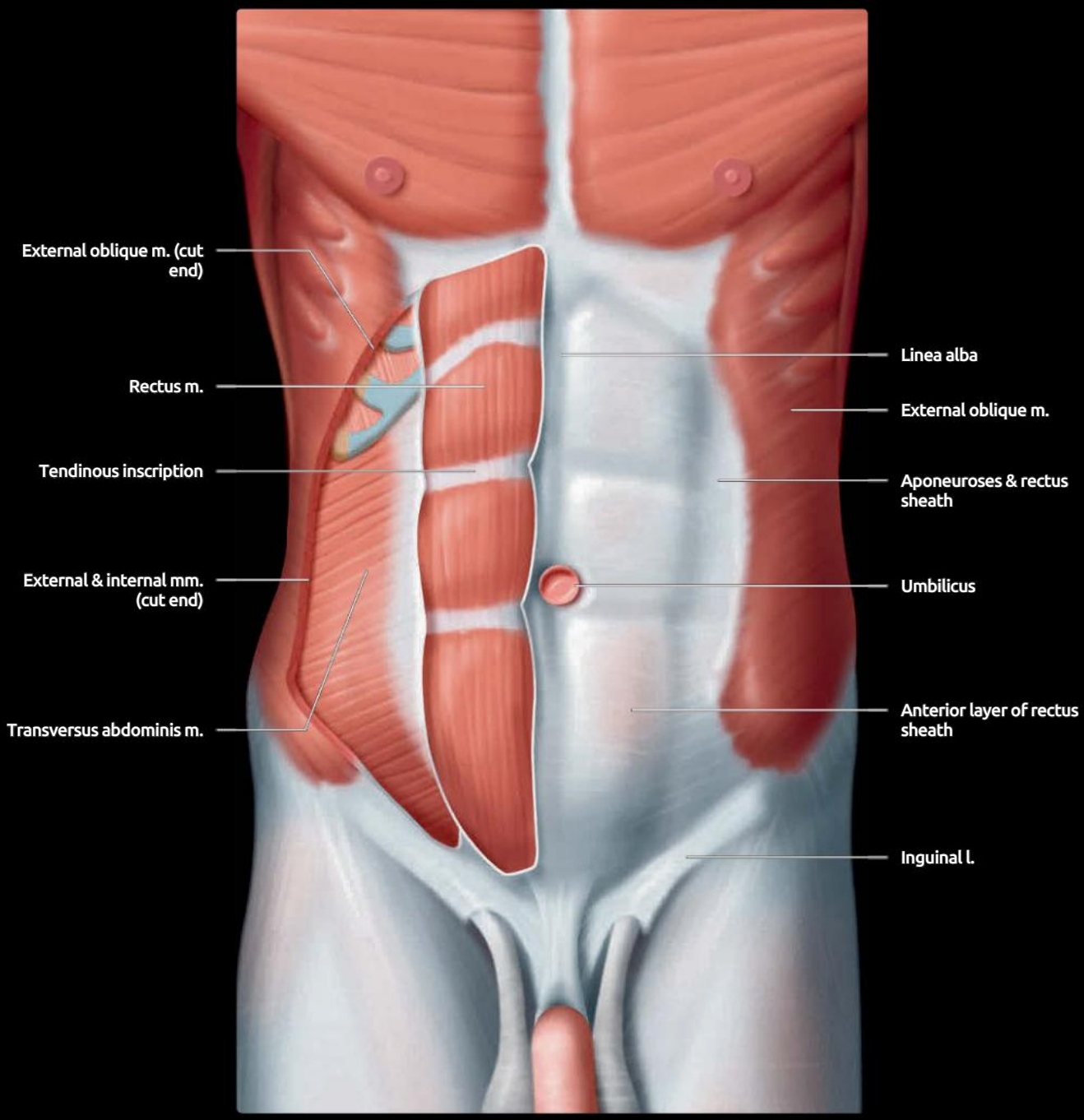

Graphic shows the aponeuroses of the external, internal oblique, & transversus abdominus muscles which interweave with each other, forming the rectus sheath & linea alba. About midway between the umbilicus & symphysis, at the arcuate line, the posterior rectus sheath ends. The transversalis fascia is the only structure between the rectus muscle & parietal peritoneum below the arcuate line. The arcuate line is also the location where the inferior epigastric artery enters the rectus sheath.

POSTERIOR ABDOMINAL WALL

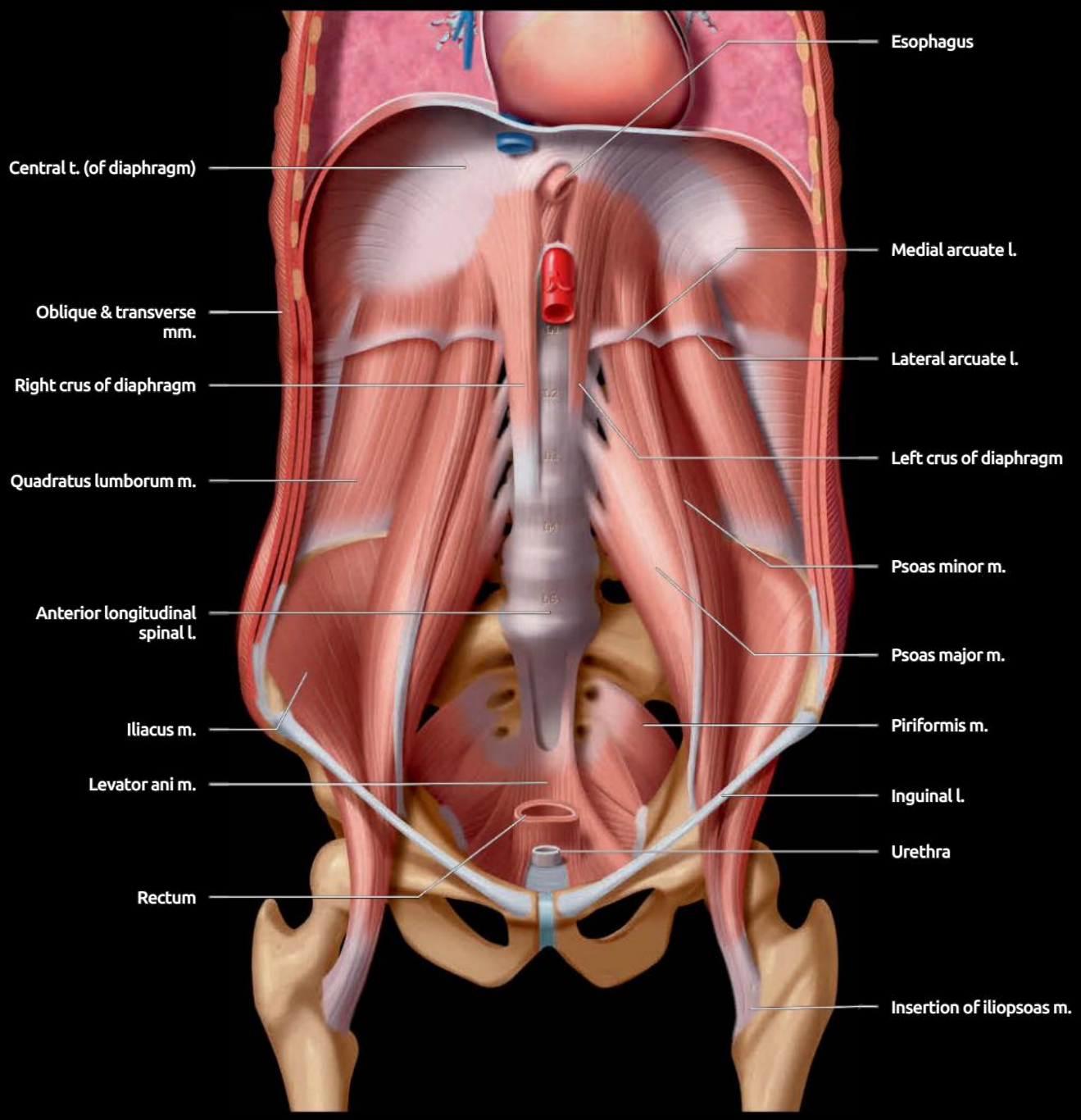

Graphic shows the lumbar vertebrae are covered & attached by the anterior longitudinal ligament, & the diaphragmatic crura are closely attached to it, as are the origins of the psoas muscles, which also arise from the transverse processes. The iliacus muscle arises from the iliac fossa of the pelvis & inserts into the tendon of the psoas major, constituting the iliopsoas tendon, which inserts into the lesser trochanter. The quadratus lumborum arises from the iliac crest & inserts into the 12th rib & transverse processes of the lumbar vertebrae. Diaphragmatic & transverse abdominal fibers interlace. The psoas & quadratus lumborum pass behind the diaphragm under the medial & lateral arcuate ligaments.

PARASPINAL MUSCLES

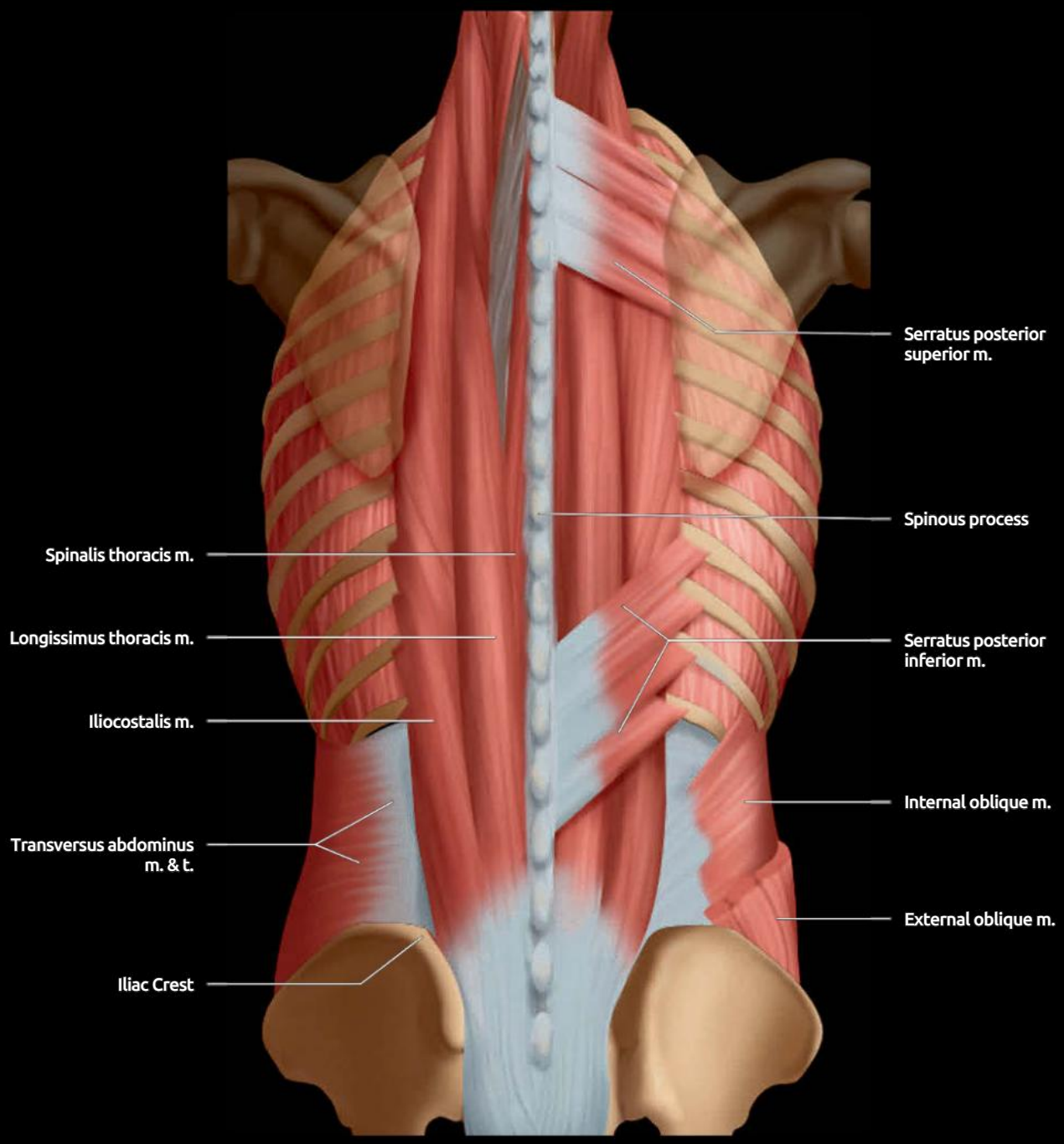

Graphic shows the paraspinal muscles & muscles of the back. The latissimus dorsi muscles are not included. The erector spinae have thick, tendinous origins from the sacral & iliac crests & the lumbar & 11th-12th thoracic spinous processes. Superiorly, the muscle becomes fleshy & subdivides in the upper lumbar region to become the iliocostalis, longissimus, & spinalis muscles (from lateral to medial), tapering as they insert into the vertebrae & ribs. The erector muscles flank the spinous processes & span the length of the posterior thorax & abdomen. They are responsible for extension of the vertebral column.

PARASPINAL MUSCULATURE, THORACIC

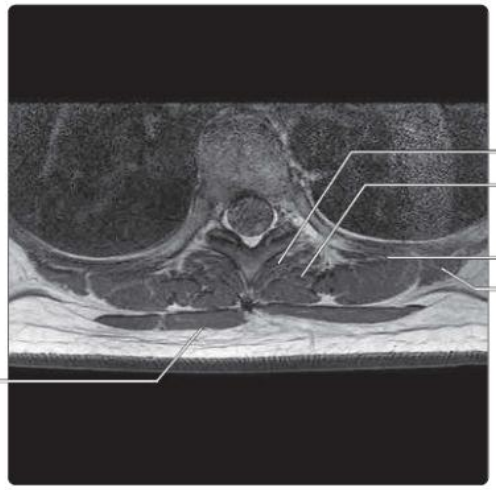

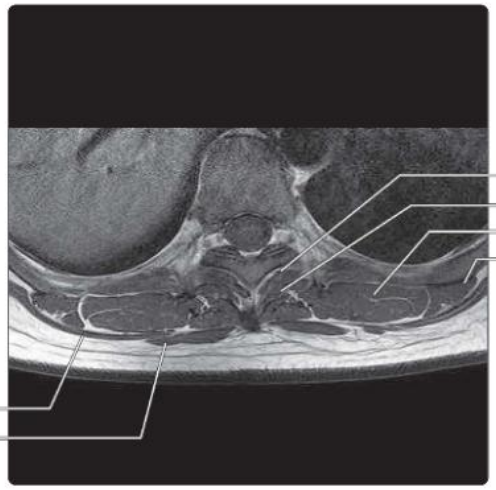

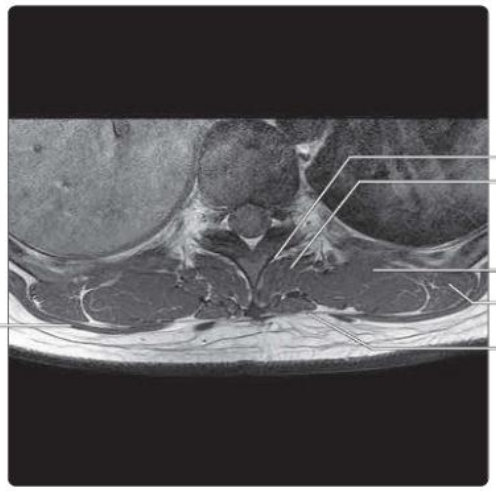

(Top) *Axial T1 MR at the T3 level shows the paraspinal musculature.* **(Middle)** *Axial T1 MR at the T7 level shows the paraspinal musculature.* **(Bottom)** *Axial T1 MR at the T12 level shows the paraspinal musculature.*

PARASPINAL MUSCULATURE, THORACIC

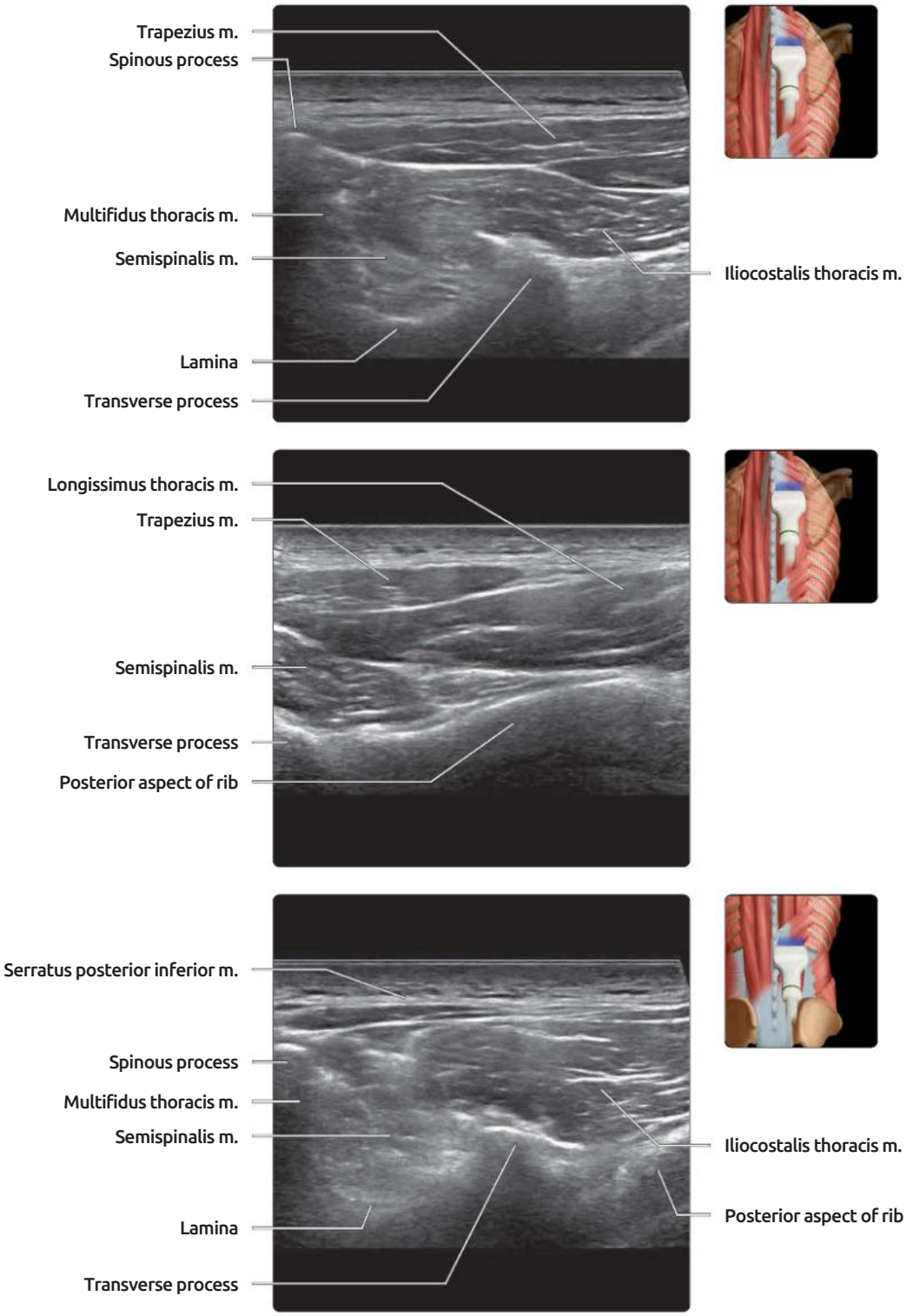

(Top) *Transverse US shows the paraspinal musculature at the midthoracic level.* **(Middle)** *Transverse US, more lateral to the previous image, shows the paraspinal musculature at a midthoracic level.* **(Bottom)** *Transverse US shows the paraspinal musculature at the lower thoracic level.*

PARASPINAL MUSCULATURE, LUMBAR

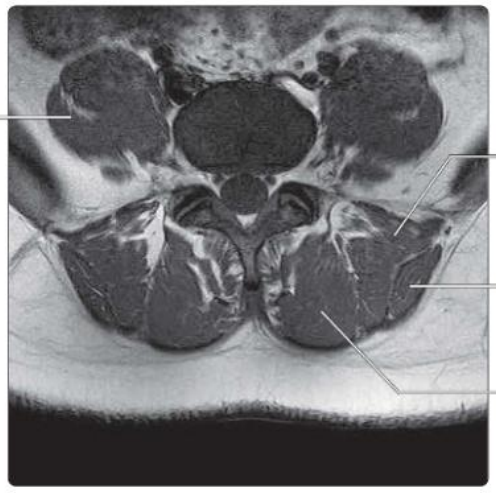

(Top) *Axial T1 MR at the L1 level shows the paraspinal musculature.* **(Middle)** *Axial T1 MR at the L3 level shows the paraspinal musculature.* **(Bottom)** *Axial T1 MR at the L5 level shows the paraspinal musculature.*

PARASPINAL MUSCULATURE, LUMBAR

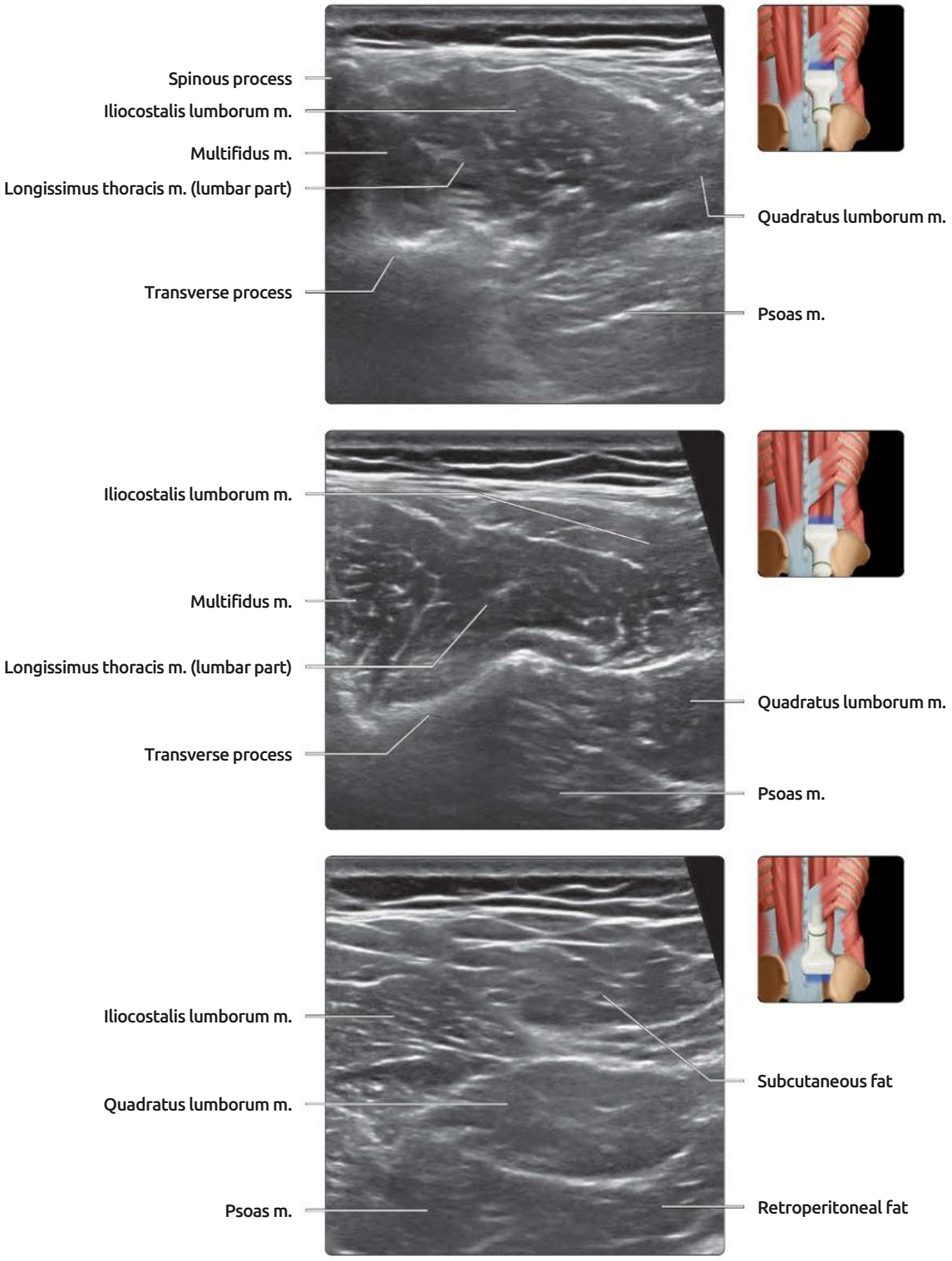

(Top) *Transverse US shows the paraspinal musculature at the upper lumbar level.* **(Middle)** *Transverse US shows the paraspinal musculature at the midlumbar level.* **(Bottom)** *Transverse US shows the paraspinal musculature at the midlumbar level, more lateral and caudad to the previous image.*

TERMINOLOGY

Abbreviations

- Origin (O)
- Insertion (I)
- Anterior superior iliac spine (ASIS)

IMAGING ANATOMY

Overview

- Groin is junctional region between trunk & thigh
- Incorporates lower abdominal wall, inguinal canal, femoral triangle, & femoral adductor muscles

Osseous Anatomy

- Pubic bone
  - **Pubic symphysis**: Cartilaginous joint between pubic bodies
    - Normal pubic apophysis often ossifies with irregular margins
  - **Pubic crest**: Anterosuperior aspect of pubic body
    - O of rectus abdominis muscle
    - I of transversus abdominis & external oblique muscles
  - **Pecten**: Ridge on superior aspect of superior pubic ramus close to pubic body
    - O of pectineus muscle
    - I of conjoint tendon (internal oblique & transverse abdominis)
  - **Pubic tubercle**: Small protuberance at lateral border of pubic crest
    - Attachment: Inguinal ligament

Anterior Abdominal Wall

- Abdominal wall muscles
  - **Rectus abdominis**: Paired midline muscles
  - **Linea alba** (literally "white line"): Aponeurotic junction of rectus abdominis, external, internal, & transversus abdominis muscles
  - **External oblique**: Most superficial
    - Lower border of external oblique aponeurosis contributes to inguinal ligament
  - **Internal oblique**: Between external oblique & transversus abdominis
    - Arches over inguinal canal, forming roof of canal
  - **Transversus abdominis**: Deepest layer
    - Remains posterior to inguinal canal

Inguinal Ligament

- Thickening & infolding of inferior border of external oblique aponeurosis
- Attachments: ASIS & pubic tubercle
- Separates pelvis from lower extremity
- Fascia lata of thigh attaches to inferior border
- **Subinguinal space**: Deep to inguinal ligament
  - Passageway for iliopsoas muscle & femoral vessels & nerve into femoral triangle
  - External iliac vessels become femoral vessels upon entering this space

Inguinal Canal

- **Entrance: Deep inguinal ring**
  - Located at midpoint of inguinal ligament
    - Just lateral & slightly cephalad to junction of inferior epigastric artery with external iliac artery
  - Opening in evaginated transversalis fascia
    - Permits contents of inguinal canal to leave abdomen & enter inguinal canal
    - Contents of inguinal canal: Ilioinguinal nerve; male: Spermatic cord; female: Round ligament; associated vessels
      - Covered by evaginated transversalis fascia
- **Exit: Superficial inguinal ring**
  - V-shaped opening in external oblique aponeurosis just superior & lateral to pubic tubercle
    - Permits contents of inguinal canal to leave canal & enter scrotum in males or labia majora in females

Spermatic cord

- Cordlike structure passing from deep inguinal ring, along inguinal canal, to superficial inguinal ring & scrotum
  - Contains vas deferens, testicular artery, cremasteric artery, vas deferens artery, testicular veins (i.e. pampiniform plexus), & lymphatics
    - Vessels normally seen on US are testicular artery & pampiniform veins

Adductor Musculature

- **Adductor longus muscle**: Tendon arises from anterosuperior aspect of pubic body
  - Overlies origins of gracilis & adductor brevis muscles
- **Gracilis muscle**: O from anterior aspect of symphysis pubis & medial aspect of inferior pubic ramus
  - O medial to adductor brevis muscle, deep to adductor longus muscle

Groin Nodes

- 2 groups of groin lymph nodes
- Superficial inguinal nodes
  - In subcutaneous tissues below inguinal ligament & alongside long saphenous vein
  - Subdivided into 3 groups of lymph nodes
    - Superomedial group located medial to saphenofemoral opening, drains perineum & external genitalia
    - Superolateral group located lateral to saphenofemoral junction, drains lateral buttock & lower anterior abdominal wall region
    - Inferior group located distal to saphenofemoral junction, drains lower limb
- Deep inguinal nodes
  - 3-5 nodes located in femoral triangle just medial to femoral vein
  - Cloquet node is most proximal of deep inguinal lymph nodes located just below inguinal ligament

ANATOMY IMAGING ISSUES

Imaging Recommendations

- Radiography & US for assessing groin pathology are complementary to each other
- If additional information is required, MR is next best investigation for most groin pathology

FEMORAL TRIANGLE

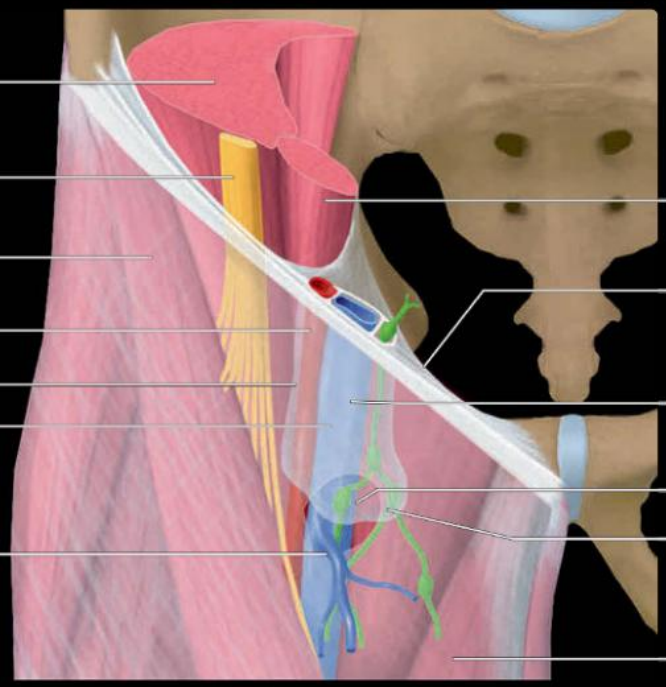

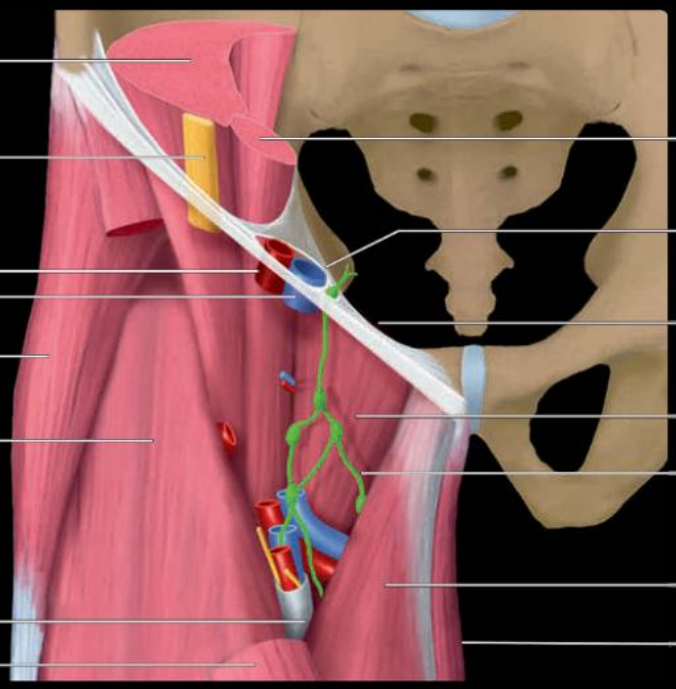

(Top) *Graphic shows the femoral triangle, the borders of which can be remembered by the mnemonic SAIL for sartorius, adductor longus, and inguinal ligament. The femoral triangle contents from medial to lateral are VAN for femoral vein, artery, and nerve. The femoral sheath is the fascial covering of the femoral triangle. Septa divide the sheath into compartments as seen at the cutaway proximal boundary. The medial compartment is known as the femoral canal. The femoral nerve initially lies superficial to the iliopsoas muscle. The fascia lata encases the thigh structures.* **(Bottom)** *Graphic shows the femoral triangle after removal of the fascia lata, the sartorius muscle, the femoral vessels, and nerve. The apex of the femoral triangle is at the intersection of the sartorius and the adductor longus muscles. The pectineus, adductor longus, and iliopsoas muscles form the floor of the triangle.*

GROIN MUSCLES

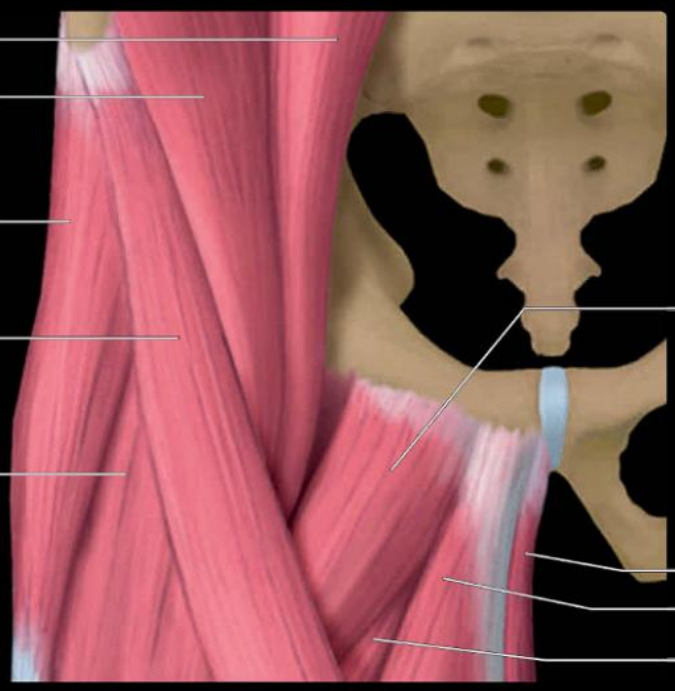

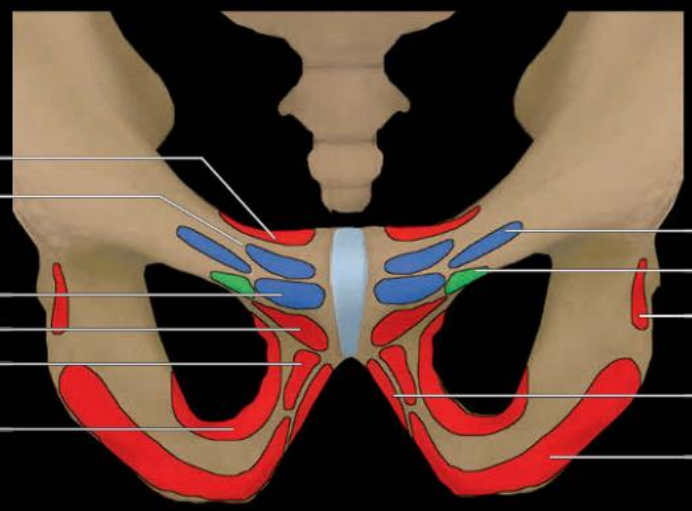

(Top) *Graphic shows the superficial muscles of the groin. The most lateral muscle is the obliquely oriented sartorius muscle. The psoas major and iliacus muscles dip deeply on passing over the superior pubic ramus. The most medial muscle is the gracilis muscle, medial to the adductor longus and pectineus muscles. The adductor brevis muscle lies deep to the adductor longus and pectineus muscles. The pectineus muscle originates from the pectineal line (a ridge on the superior pubic ramus) and runs laterally to insert on the pectineal line of the proximal femur, which is between the lesser trochanter and the linea aspera.* **(Bottom)** *Graphic shows the muscle attachments of the anterior aspect of the lower pelvis. Many muscles originate from or insert onto the anterior aspect of the lower pelvis. These muscles move and stabilize the trunk as well as the thigh and form the medial components of the groin.*

NERVES OF GROIN REGION

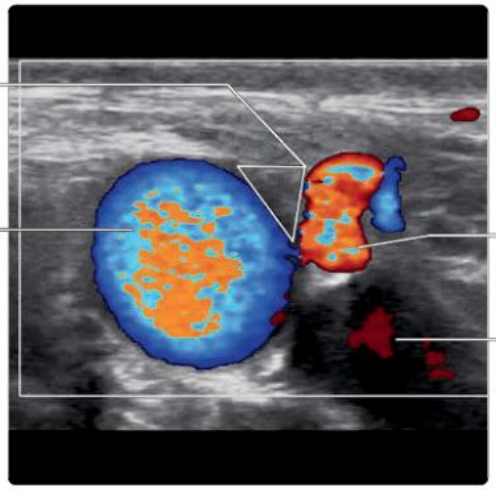

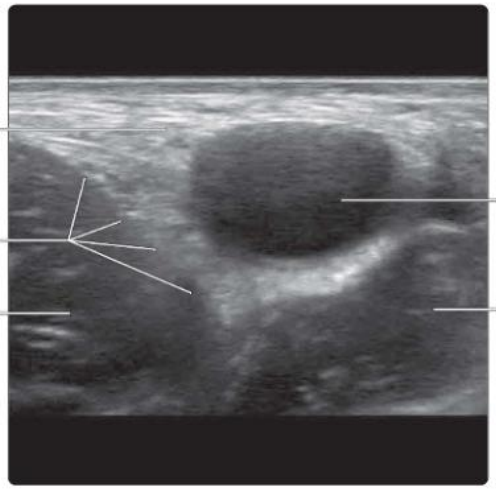

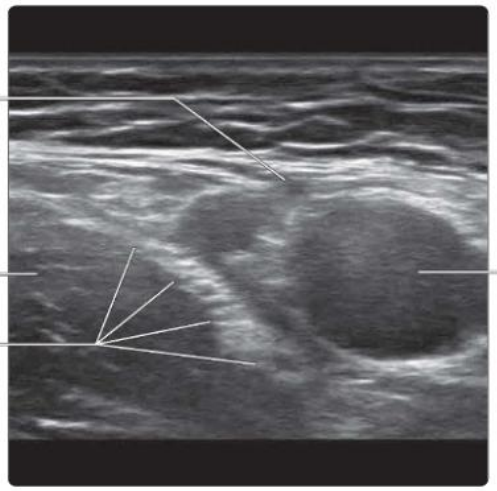

(Top) *Transverse color Doppler US at the origin of the inferior epigastric artery from the external iliac artery is shown. The small genital branch of the genitofemoral nerve is usually too small to be resolved on US though does lie alongside the external iliac artery as shown, before entering the inguinal canal. The genital branch of the genitofemoral nerve is usually located within the spermatic cord of male inguinal canals but may lie outside the cord.* **(Middle)** *Transverse US of the common femoral artery just distal to the inguinal ligament is shown. The femoral branch of the genitofemoral nerve lies just superolateral to the artery at this location.* **(Bottom)** *Transverse US of the common femoral artery just distal to the inguinal ligament shows the femoral nerve located just inferolateral to the common femoral artery.*

NERVES OF GROIN REGION

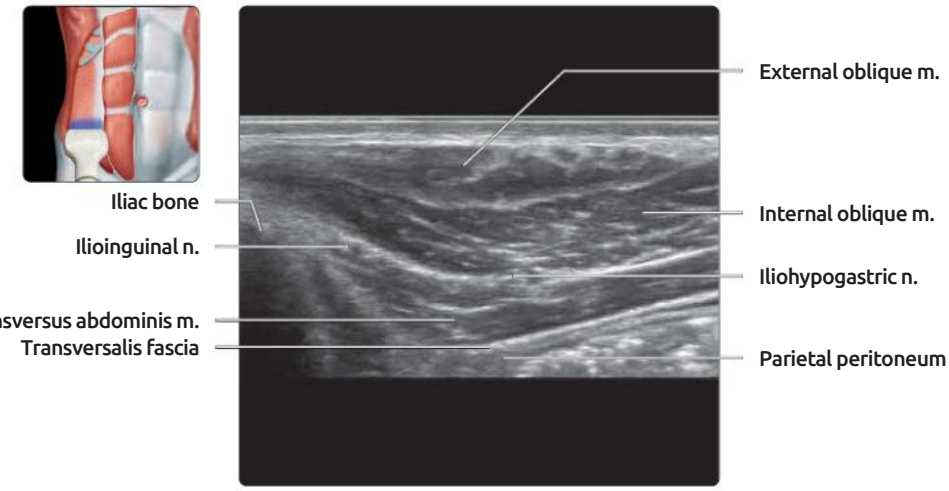

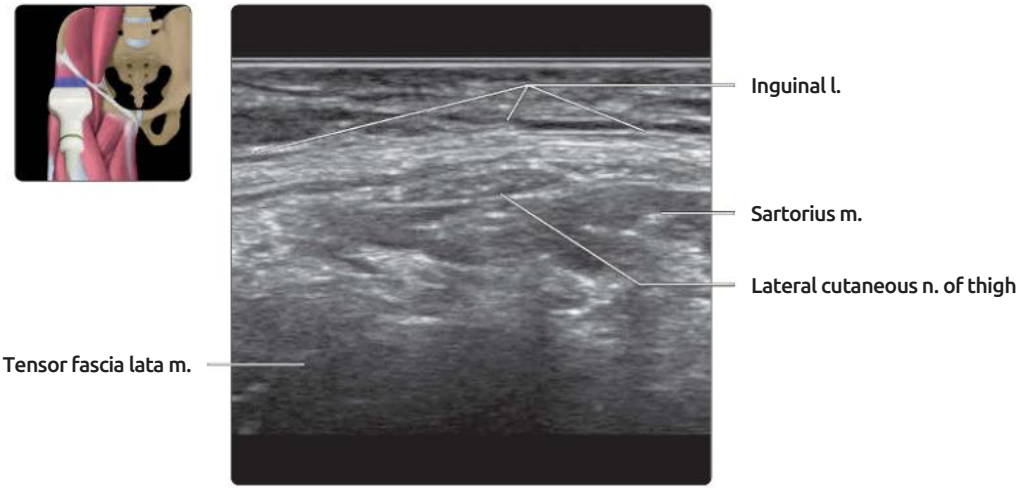

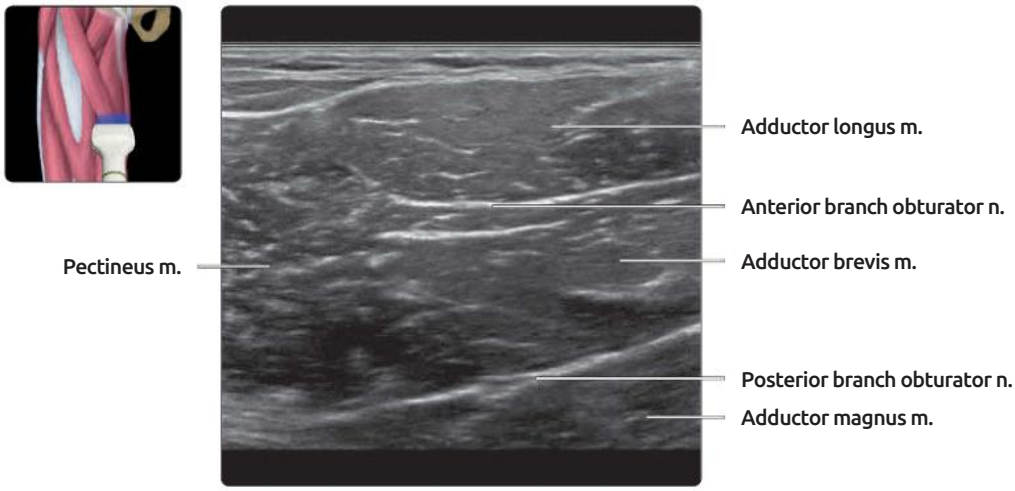

(Top) *Transverse US of the lower abdominal wall shows the ilioinguinal and iliohypogastric nerves located between the internal oblique and the transversus abdominis muscles of the anterior abdominal wall. The iliohypogastric nerve lies more medial to the ilioinguinal nerve. A useful way to remember this is that the iliohypogastric nerve is, as the name means, below the stomach.* **(Middle)** *Transverse US shows the eye-shaped lateral cutaneous nerve of the thigh (also called the lateral femoral cutaneous nerve) just deep to the lateral end of the inguinal ligament. This nerve innervates the skin on the anterolateral aspect of the thigh. Compression of this nerve, usually around the inguinal ligament, can give rise to the meralgia paresthetica condition.* **(Bottom)** *Transverse US medial aspect of the thigh shows the anterior and posterior branches of the obturator nerve lying anterior and posterior respectively to the adductor brevis muscle.*

PUBIC SYMPHYSIS AND INGUINAL LIGAMENT

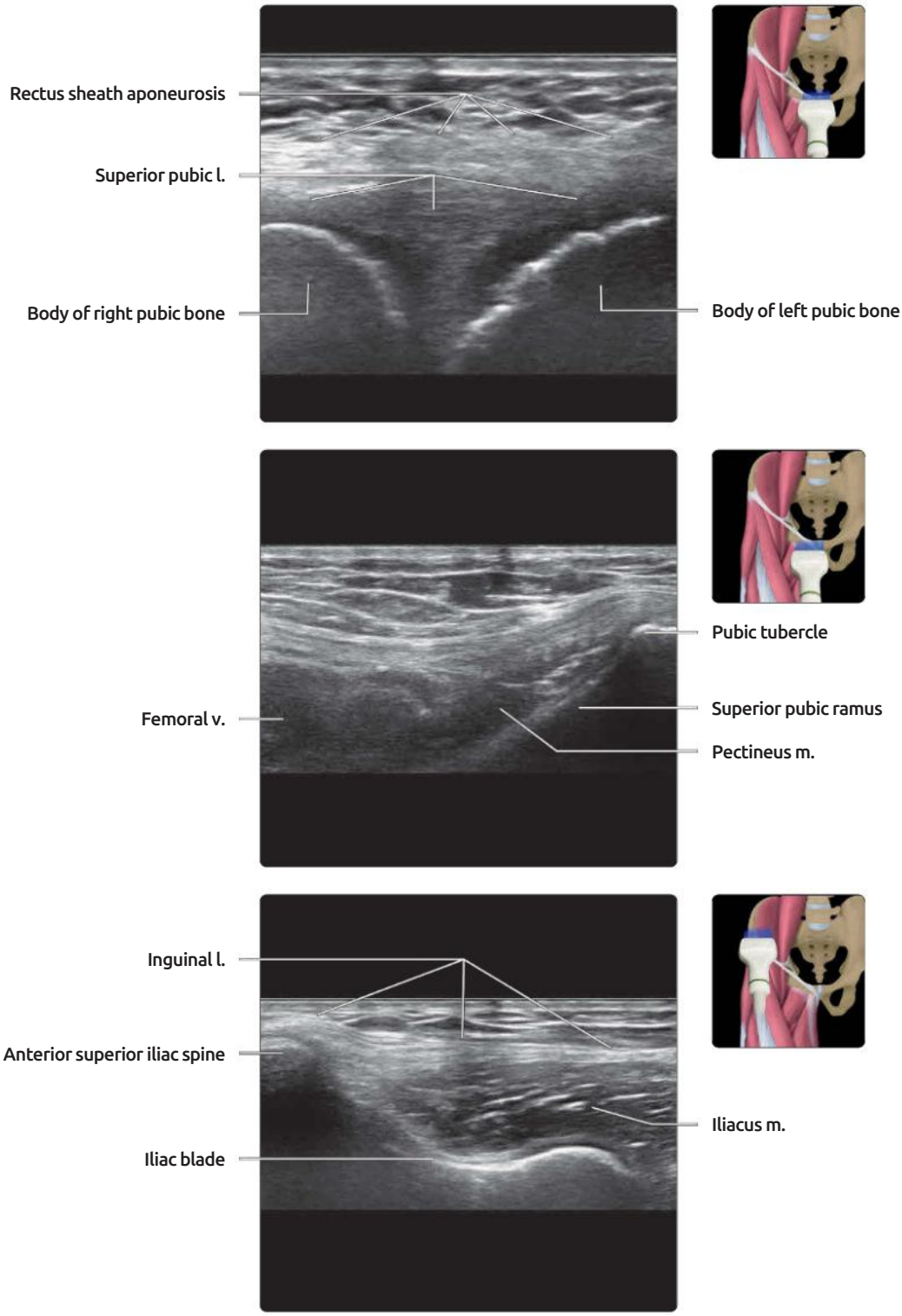

(Top) *Transverse US shows the pubic symphysis. The superior pubic ligament runs horizontally across the pubic symphysis. The morphology of the pubic symphysis varies considerably among asymptomatic subjects.* **(Middle)** *Transverse US shows the medial end of the inguinal ligament attached to the pubic tubercle. The pubic tubercle is the most lateral part of the pubic crest, which is the thickened superior part of the pubic body. The inguinal ligament is a thickening and infolding over of the external oblique aponeurosis.* **(Bottom)** *Transverse US shows the inguinal ligament attached to the anterior superior iliac spine (ASIS). The sartorius muscle (not shown) also attaches to the ASIS.*

DEEP AND SUPERFICIAL INGUINAL RINGS

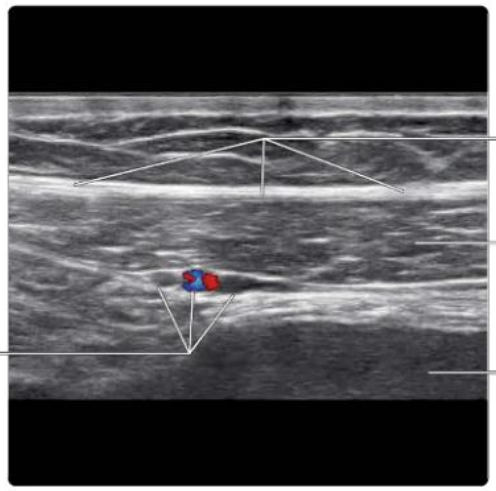

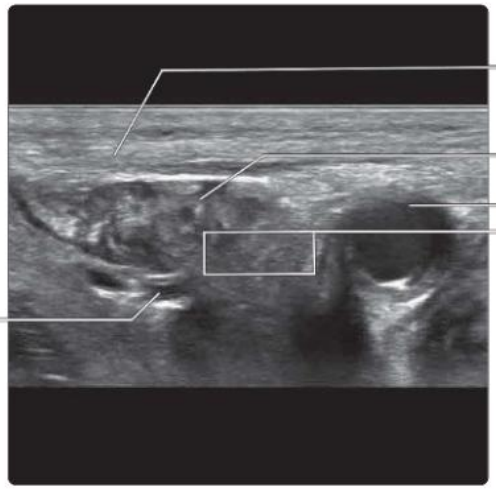

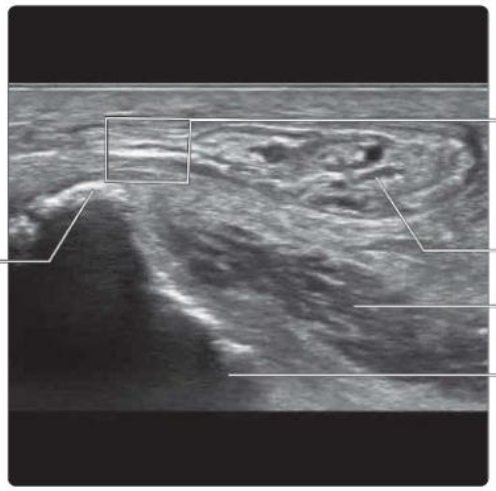

(Top) *Transverse color Doppler US shows the inferior epigastric artery and veins at the inferolateral margin of the rectus abdominis muscle. As this section is distal to the arcuate line, only the anterior layer of the rectus sheath exists. There is no posterior layer of the rectus sheath distal to the arcuate line. The inferior epigastric arteries are often most easily identified at the inferior margin of the rectus abdominis muscle and traced to the external iliac artery.* **(Middle)** *Transverse US shows the position of the deep inguinal ring between and just cephalad to the site of origin of the inferior epigastric artery from the external iliac artery.* **(Bottom)** *Transverse US at the medial end of the inguinal ligament shows the region of the superficial inguinal ring located superficial and lateral to the pubic tubercle. This patient has very little subcutaneous fat, making the spermatic cord particularly easy to see. Direct inguinal hernias occur cephalad to the inguinal ligament between the pubic tubercle and the inferior epigastric artery (the Hesselbach triangle).*

FEMORAL TRIANGLE AND LYMPH NODES

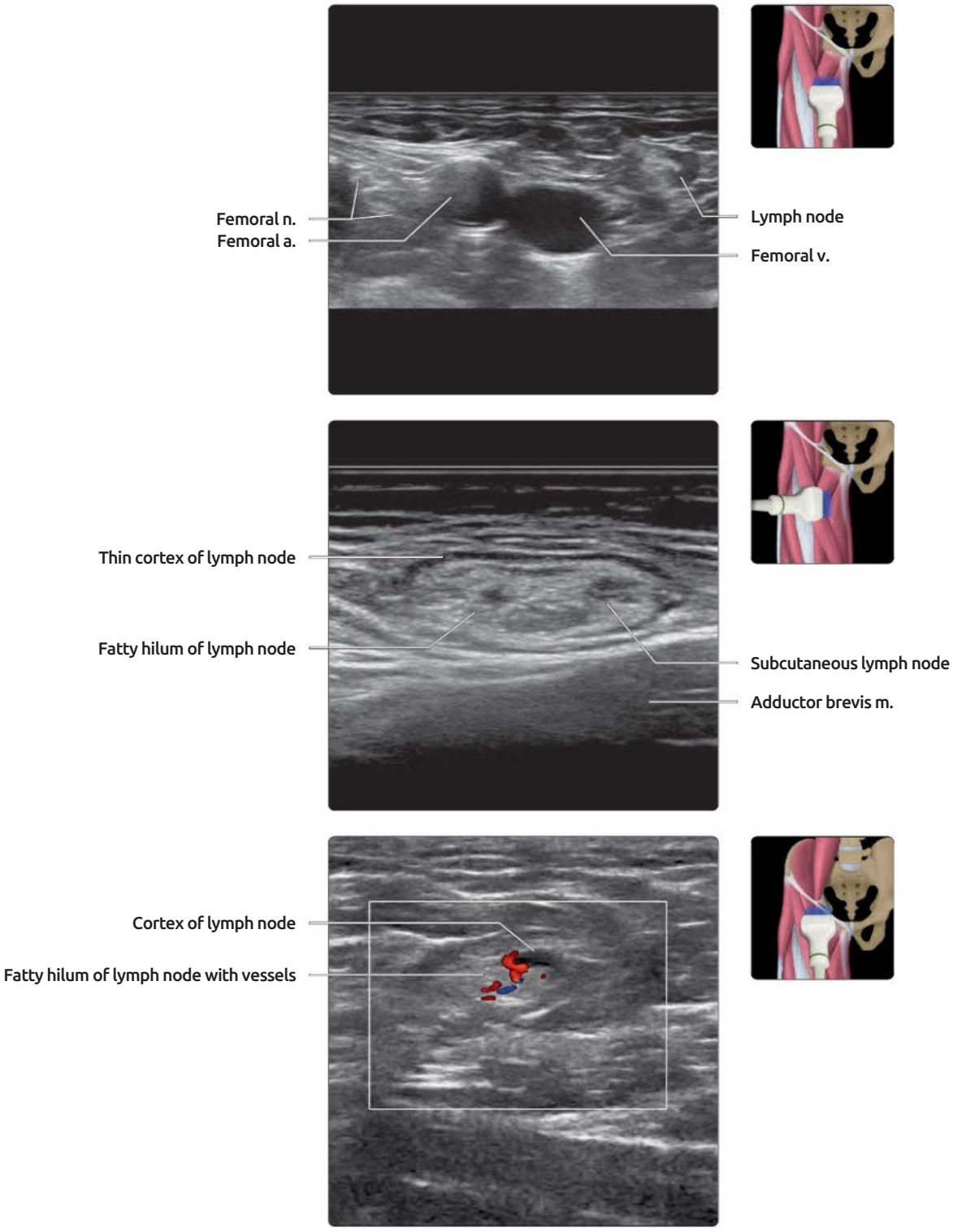

(Top) *Transverse US shows part of the femoral triangle just distal to the inguinal ligament. The main contents of the femoral triangle are the femoral vein, artery, and nerve from medial to lateral. There are also lymph nodes, most often located medial to the femoral vein.* **(Middle)** *Longitudinal US of the medial aspect of the proximal thigh shows a large thin-walled subcutaneous lymph node. An elongated lymph node with a thin cortex, such as the one shown, is usually located in the subcutaneous tissues on the medial aspect of the proximal thigh, medial to the femoral vein.* **(Bottom)** *Transverse color Doppler US shows a superficial inguinal lymph node within the subcutaneous tissues. The lymph node has a thin cortex with normal hilar vascularity. There are ~10 superficial inguinal lymph nodes normally, which are grouped in 3 groups based on whether they are located superomedial, superolateral, or inferior to the saphenofemoral junction (not shown).*

SPERMATIC CORD

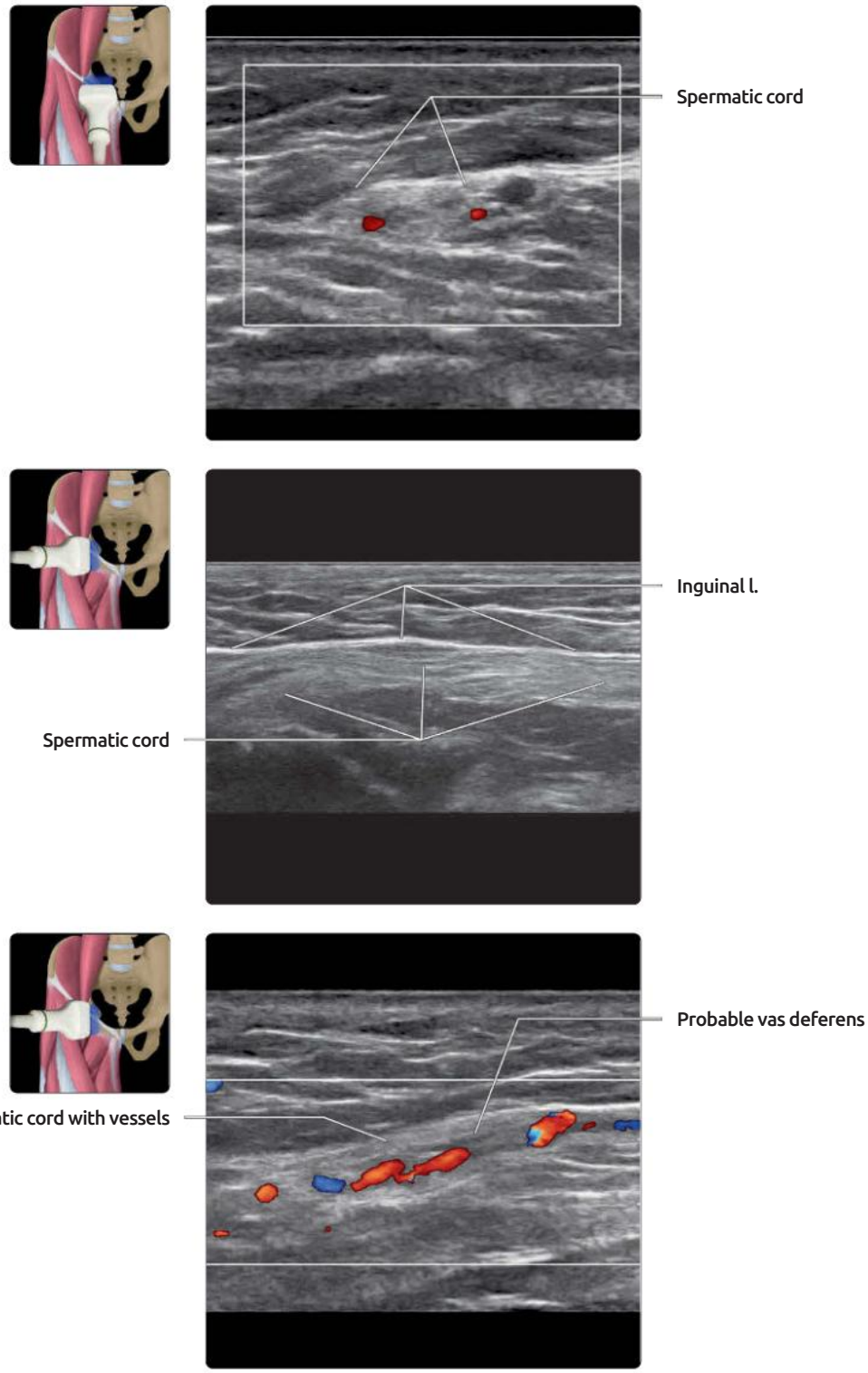

(Top) *Transverse color Doppler US shows the spermatic cord within the inguinal canal. The spermatic cord contains the vas deferens, processus vaginalis, and vessels (testicular artery, cremasteric artery and vein, artery to the vas deferens, and pampiniform plexus of testicular veins), as well as nerves (genital branch of genitofemoral nerve and autonomic nerves) and lymph vessels.* **(Middle)** *Longitudinal US shows the spermatic cord within the inguinal canal. The thick anterior band of the inguinal canal is evident anteriorly.* **(Bottom)** *Longitudinal color Doppler US shows vessels with the spermatic cord, most likely representing the testicular artery and pampiniform veins. Other thin hypoechoic tubular structures within the spermatic cord may represent the vas deferens.*

MEDIAL THIGH

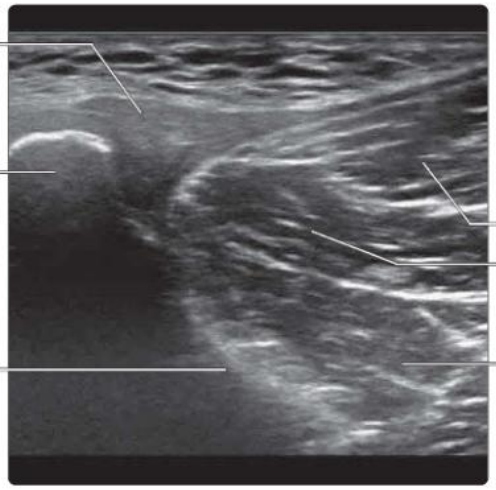

(Top) *Longitudinal US medial aspect of the groin shows the close relationship between the iliopsoas tendon and the anterior aspect of the hip joint. The iliopsoas bursa is located between the femoral head and the iliopsoas tendon but is not visible on US unless distended. The iliopsoas bursa communicates with the hip joint in 15% of the population. This communication may be congenital or acquired.* **(Middle)** *Longitudinal US shows the hypoechoic triangular-shaped common adductor tendon at the anterior margin of the pubic body with the connected bellies of adductor longus and brevis muscles. The adductor component of the adductor magnus muscle is attached to the inferior pubic ramus.* **(Bottom)** *Longitudinal US more lateral to the previous image shows the adductor longus, brevis, and magnus muscles, as well as the pectineus muscle.*

TERMINOLOGY

Abbreviations

- Ilioinguinal (II)
- Iliohypogastric (IH)
- Lateral femoral cutaneous nerve (LFCN)
- Anterior femoral circumflex nerve (AFCN)
- Intermediate femoral cutaneous nerve (IFCN)
- Medial femoral cutaneous nerve (MFCN)
- Posterior femoral cutaneous nerve (PFCN)
- Obturator nerve (ON)
- Anterior superior iliac spine (ASIS)

GROSS ANATOMY

Ilioinguinal & Iliohypogastric Nerves

- **Best seen** between transversus & internal oblique muscles
  - ~ 5 cm proximal to & lateral to ASIS scanning transversely long ASIS-xiphisternum line
    - IH nerve visible near posterior margin of transversus abdominis muscle
      - & between transversus & internal oblique muscles
    - Il nerve visible below iliohypogastric nerve near anterior part of iliac crest
- **Innervation**: Mixed sensory & motor nerves; arise from L1 & L2 roots
  - Supplies skin of lower abdomen, groin, & proximal thigh; motor innervation to transversus abdominis & external oblique muscles
- **Anatomy**: II & IH nerves run over psoas & quadratus lumborum muscles
- Pass posterior to kidney & enter transversus abdominis muscle dorsal to ASIS
  - In 30% of cases, II & IH nerves form common trunk initially
  - Both nerves measure 2-3 mm
- Deep circumflex iliac artery located in same fascial plane
- II & IH divide into lateral cutaneous, anterior cutaneous, & genital branches
- II nerve descends on surface of iliacus muscle to pierce internal oblique muscle deep to external oblique aponeurosis
  - Enters inguinal canal directly rather than passing through deep inguinal ring
- Distal to ASIS, external oblique muscle is purely aponeurotic

Lateral Femoral Cutaneous Nerve

- **Best seen** immediately below inguinal ligament running over sartorius muscle or between sartorius & tensor fascia lata muscle
  - Seen as thin, thread-like, slightly arched structure, similar to an eye
- **Innervation**: Anterolateral aspect of thigh
- **Anatomy**: Pure sensory nerve, arising from L2 & L3 nerve roots
  - Proximal to inguinal ligament, runs on surface of iliacus muscle deep to fascia iliaca
  - Passes inferolaterally either under (80%) or through (20%) inguinal ligament ~ 2 cm medial to ASIS
    - LFCN CSA near ligament is 1.04 ± 0.44 mm^2
  - Runs over sartorius muscle ± then runs between sartorius; tensor fascia lata muscle interface, superficial to rectus femoris muscle
  - A few cm distal to inguinal ligament, LFCN divides into 2-4 terminal branches that pierce fascia lata

Genitofemoral Nerve

- **Best seen** superficial to external iliac artery just proximal to origin of inferior epigastric artery (genital branch) & medial to distal part of common femoral artery (femoral branch)
- **Innervation**: Mixed nerve arising from L1 & L2 roots; genital branch innervates labia majora & mons pubis in females & scrotum, cremasteric reflex in men; femoral branch innervates femoral triangle
- **Anatomy**: Passes through & anterior to psoas & then anterior to common & external iliac arteries
- Above inguinal ligament, divides into genital & femoral branches
  - Both branches usually too small to be seen on US
  - Genital branch best seen just proximal to origin of inferior epigastric artery, lying superficial to external iliac artery
    - Genital branch passes through deep inguinal ring & descends to scrotum, usually within spermatic cord in men
      - Spermatic cord also contains testicular artery, artery to vas, & pampiniform venous plexus as well as vas deferens
  - Femoral branch passes deep to inguinal ligament to lie superficial & medial to common femoral artery
    - Femoral branch best seen medial to common femoral artery just proximal to bifurcation

Femoral Nerve

- **Best seen** just lateral to femoral artery proximal & distal to inguinal ligament
- **Innervation**: Arises from L2-L4 nerve roots & provides sensory innovation to anterior aspect of thigh
- **Anatomy**: Descends on surface of iliopsoas muscle & passes under inguinal ligament lying lateral to common femoral artery
- Divides into anterior & posterior divisions immediately below inguinal ligament
  - Lateral femoral circumflex artery located between anterior & posterior divisions
- **Anterior division** gives off AFCN located between superficial femoral artery & sartorius muscle
  - AFCN divides into intermediate femoral cutaneous nerve IFCN & MFCN
    - IFCN located superficial to rectus femoris muscle
    - MFCN located medial to rectus femoris muscle
    - Both IFCN & MFCN then pass to subcutaneous fat overlying sartorius, vastus medialis, & rectus femoris muscles
- **Posterior division** gives off saphenous nerve, which is terminal cutaneous branch of femoral nerve

Posterior Femoral Cutaneous Nerve

- **Best seen** medial to sciatic nerve at subgluteal fold level proximal thigh or deep to sartorius muscle medial knee
- **Innervation**: Purely sensory nerve arising from anterior divisions of S1 & S2 & posterior divisions of S2 & S3

- Innervates inferior gluteal region & posterior aspect of thigh
- **Anatomy**: Passes through greater sciatic foramen beneath piriformis muscle
  - Descends with inferior gluteal artery medial to sciatic nerve alongside ischial tuberosity & then superficial to long head of biceps femoris muscle
  - Then runs deep to sartorius muscle medial aspect of knee
  - Emerges from underneath sartorius muscle to penetrate deep fascia & accompany short saphenous vein to mid-leg region
    - Similar distal course to saphenous nerve

Obturator Nerve

- **Best seen** at medial border of pectineus muscle with adductor longus, brevis, & magnus muscles in sequence
  - Anterior branch of ON between adductor longus & adductor brevis muscles close to pectineus muscle
  - Posterior branch where pectineus, adductor brevis, & adductor magnus muscles meet
  - Obturator artery runs with ONs
- **Innervation**: Mixed nerve arises from anterior roots of L2-L4; provides motor innervation to adductor muscles & sensory innervation to medial aspect thigh & knee
- **Anatomy**: Runs through & along posteromedial surface of psoas major muscle in pelvis
- Enters medial aspect of thigh through obturator canal after where it divides into anterior & posterior branches
  - Bifurcation is intrapelvic (25%), within obturator canal (50%), & in medial thigh (25%)
  - Anterior & posterior branches run between pectineus & obturator externus muscle
  - **Anterior branch** runs between adductor brevis & adductor longus muscles
  - **Posterior branch** runs between adductor brevis & adductor magnus muscles

Pudendal Nerve

- **Best seen** near ischial spine between sacrotuberous & sacrospinous ligaments
  - Move slowly proximally from ischial tuberosity to locate ischial spine
    - Pass first over flat convex border of ischium with obturator internus muscle on top
    - Then pass over more rounded border of ischium with obturator internus muscle/tendon on top
    - See sharp ischial spine, which faces medially, bare on top though with sacrospinous ligament attached to deep medial surface
    - Find sacrotuberous & sacrospinous ligaments
      - Sacrotuberous ligament lies over sacrospinous ligament & runs obliquely to ischial tuberosity
      - Sacrospinous ligament runs horizontally from ischial spine to sacrum
    - Between these two ligaments, anterior to ischial spine, pudendal nerve lies medial (or lateral) to internal pudendal artery & inferior gluteal artery
    - Pudendal nerve cannot be seen in 50%, but internal pudendal artery consistently seen
    - Moving slightly distally, to level of lesser sciatic foramen, pudendal nerve lies on surface of obturator internus muscle
- **Innervation**: Mixed nerve; arises from anterior branches of S2-S4 nerve roots
  - Motor innervation to perineal muscle, external urethra, & anal sphincter; sensory to skin of external genitalia, anus, & perineum
- **Anatomy**: Exits pelvis through greater sciatic foramen & reenters pelvis by encircling sacrospinous ligament & ischial spine
  - Runs along lateral border of ischiorectal fossa with internal pudendal vessels within pudendal (Alcock) canal
  - Gives off inferior rectal & perineal nerves & continues as dorsal nerve of penis or clitoris
  - Alcock canal is deep to obturator internus myofascia

Sciatic Nerve

- **Best seen** inferolateral to ischial tuberosity; from here it can be followed
  - Distally deep to biceps femoris/semitendinosus conjoint tendon Mercedes sign
  - Proximally over ischium by angling transducer en-face to posterior wall of ischium
    - Rotate transducer into longitudinal plane to visualize sciatic nerve emerging from pelvis through greater sciatic foramen
      - In lower buttock region, sciatic nerve is accompanied by inferior gluteal artery
- **Innervation**: Mixed sensory & motor nerve; arises from L4 to S3 roots via lumbosacral plexus
  - Sensory to most of lower leg except for
    - Medial thigh; supplied by ON
    - Anterocentral & distal medial thigh; supplied by AFCN & MFCN
    - Anterolateral thigh; supplied by LCFN
  - Motor to most of lower limb except for
    - Quadratus femoris muscles; supplied by femoral nerve
    - Adductor muscles; supplied by ON
  - **Anatomy**: Descends on piriformis muscle & passes though greater sciatic foramen deep to piriformis muscle (76%)
    - Alternatively, SN divides in pelvis with both common peroneal & tibial nerves passing deep to piriformis muscle (16%)
    - Alternatively, SN divides in pelvis with common peroneal nerve passing through, & tibial nerve passing deep, to piriformis muscle (7%)
    - Other uncommon variations (1%)
  - Descends deep to gluteus maximus muscle on surface of obturator internus tendon & gemelli muscles
    - Passes lateral to ischial tuberosity on surface of quadratus femoris & adductor magnus muscles
  - Distal to ischial tuberosity, it runs deep to gluteus maximus muscle & then deep to biceps femoris-semitendinosus conjoint tendon

ILIOINGUINAL, ILIOHYPOGASTRIC, & GENITOFEMORAL NERVES

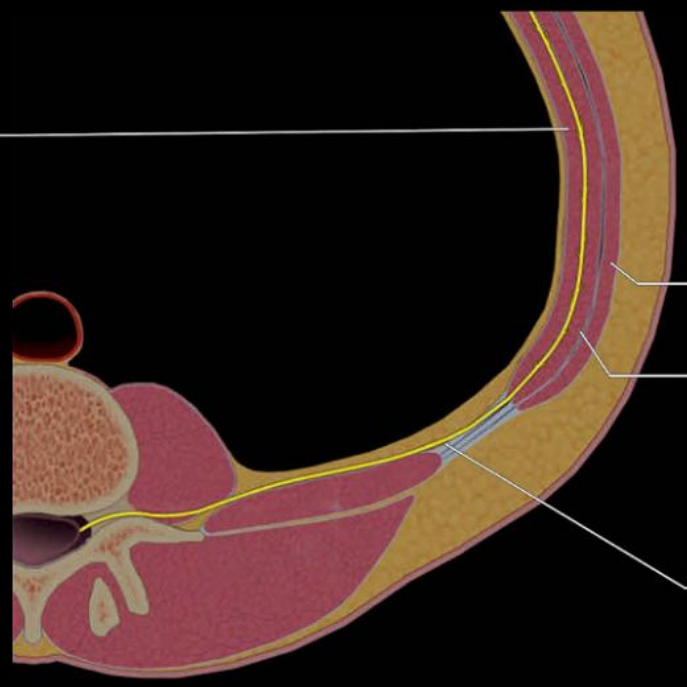

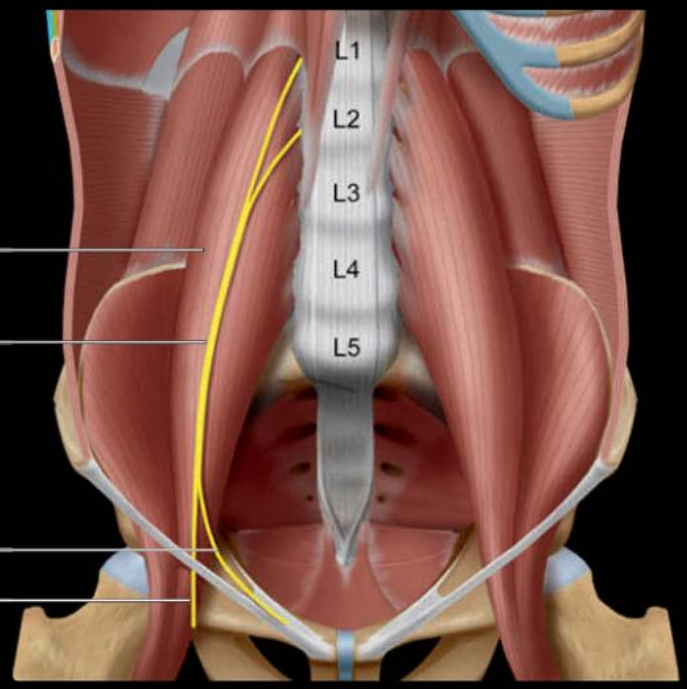

(Top) *Graphic shows course of the iliohypogastric and ilioinguinal nerves. In reality, the nerves run obliquely from superior to inferior and are not seen in the same axial plane, as depicted here. They run between the transversus and internal oblique muscles. The iliohypogastric nerve is located anterior to the ilioinguinal nerve. This relationship can be remembered by noting that "hypogastric" refers to "below the stomach." The external oblique musculature is aponeurotic anterior and below the level of the anterior superior iliac spine.* **(Bottom)** *Graphic shows the course of the genitofemoral nerve. The genital branch of the genitofemoral nerve is best depicted superolateral to the external iliac artery, at or just proximal to the origin of the inferior epigastric artery. The femoral branch continues distally and is best seen superior or superolateral to the common femoral artery.*

ILIOINGUINAL & ILIOHYPOGASTRIC NERVES

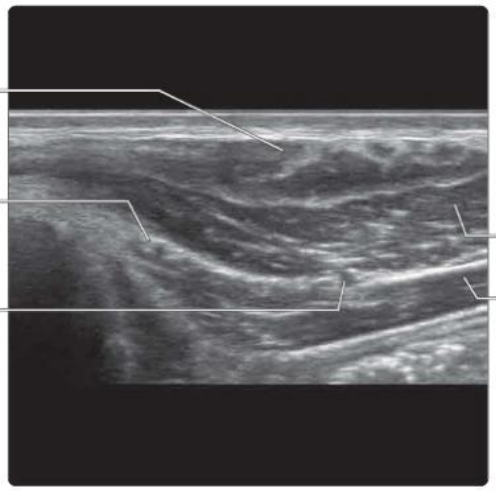

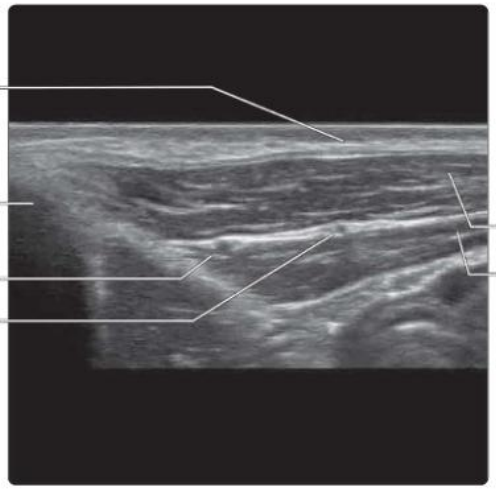

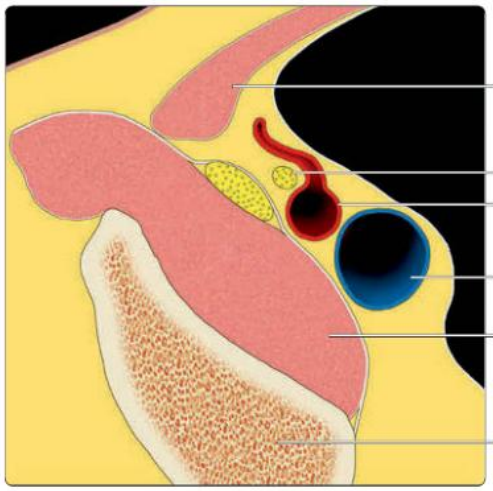

(Top) *Transverse US of the abdominal wall shows the ilioinguinal and the iliohypogastric nerves running in the plane between internal oblique and transversus abdominis muscles. This section is more posterior and proximal, as the external oblique muscle is still visible rather than being an aponeurosis.* **(Middle)** *Transverse US more distal to previous image is shown. The external oblique is now fully aponeurotic. The deep circumflex iliac artery travels in the same plane as the ilioinguinal and iliohypogastric nerves. Color Doppler imaging can help distinguish this artery from the nerves.* **(Bottom)** *Graphic shows the relationship of the femoral nerve and the external vessels to the femoral artery. The genital branch of the genitofemoral nerve is small and is best seen superficial or medial to the external iliac artery, close to where the inferior epigastric artery arises from the external iliac artery. From here, the genital branch will pass through the deep inguinal ring and descend to the scrotum or labia majora.*

GENITAL BRANCH OF GENITOFEMORAL NERVE

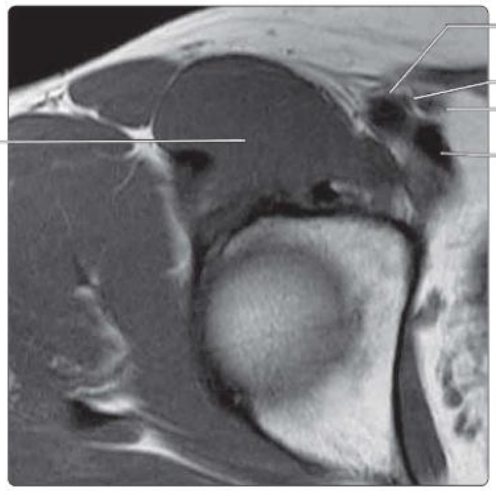

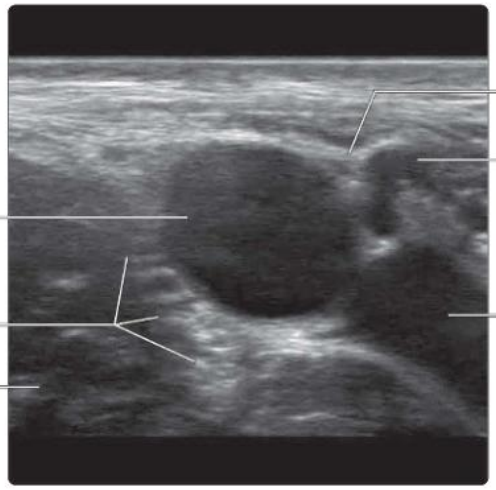

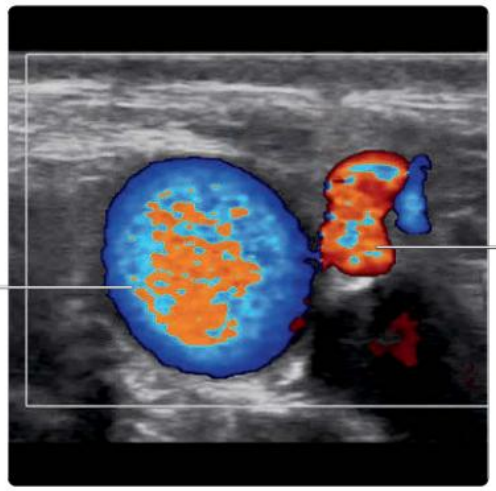

(Top) *Transverse intermediate-weighted PD MR shows the genital branch of the genitofemoral nerve between the inferior epigastric artery and the external iliac artery.* **(Middle)** *Transverse US corresponding to previous MR shows the genital branch of the genitofemoral nerve just medial to the external iliac artery, close to the origin of the inferior epigastric artery. The femoral nerve lies between the external iliac artery and the iliacus muscle.* **(Bottom)** *Transverse color Doppler US at the same location is shown. The resolution, as a result of the color Doppler mode, is reduced, obscuring detail with respect to the genital branch of the genitofemoral nerve and the femoral nerve.*

FEMORAL NERVE & FEMORAL BRANCH OF GENITOFEMORAL NERVE

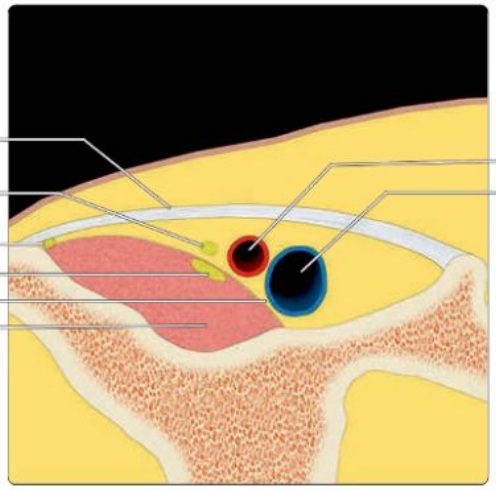

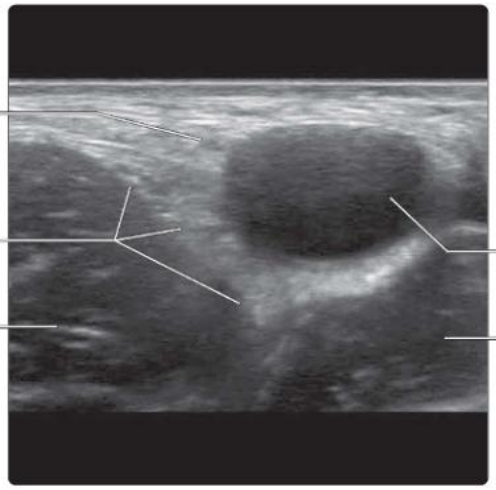

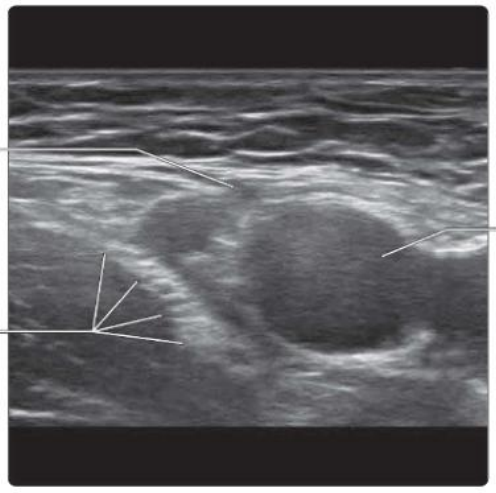

(Top) *Graphic shows the relation between the femoral nerve, the iliacus muscle, the femoral artery, and the femoral branch of the genitofemoral nerve. The lateral femoral cutaneous nerve (LFCN) of the thigh is also shown. Proximal to the inguinal ligament, both the femoral nerve and the LFCN lie deep to the iliacus fascia.* **(Middle)** *Transverse US just below the inguinal ligament shows the femoral nerve deep to the iliacus fascia. The femoral branch of the genitofemoral nerve is also shown.* **(Bottom)** *Transverse US slightly more distal to the previous image again shows the femoral nerve and the femoral branch of the genitofemoral nerve. The femoral nerve is a mixed nerve with sensory innervation to the anterior aspect of the thigh and motor innervation to the anterior thigh muscles. The femoral branch of the genitofemoral nerve innervates the femoral triangle.*

FEMORAL NERVE & LATERAL FEMORAL CUTANEOUS NERVE

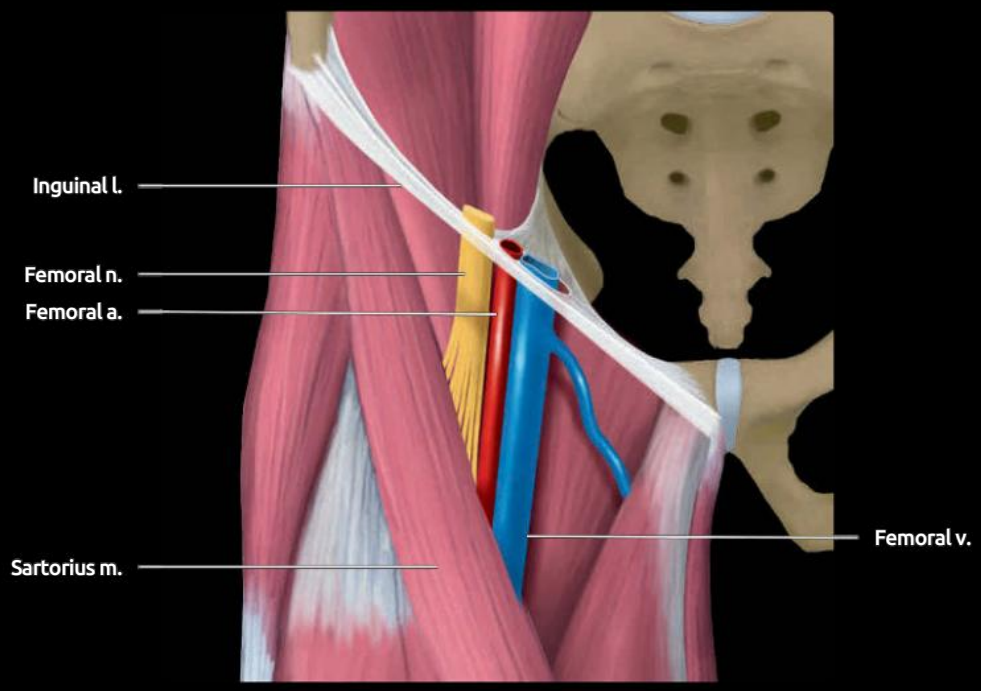

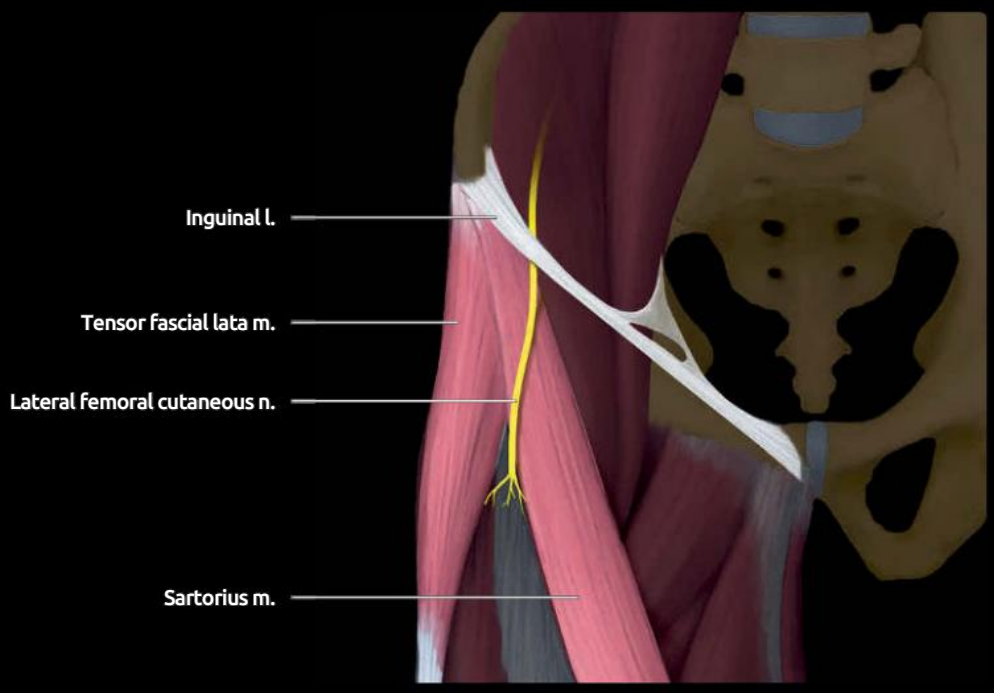

(Top) *Graphic shows the arrangement of the femoral neurovascular bundle at the femoral canal region near the midpoint of the inguinal ligament. The mnemonic is VAN, standing for vein, artery, nerve. The femoral nerve divides into anterior and posterior branches just distal to the inguinal ligament. Femoral hernias occur medial to the femoral vein.* **(Bottom)** *Graphic shows the relationship of the LFCN to the lateral aspect of the inguinal ligament as well as the sartorius and tensor fascia lata muscles. The LFCN usually runs over the sartorius muscle to the interspace between the tensor fascia lata and sartorius muscles overlying the rectus femoris muscle. A few centimeters below the inguinal ligament, it divides into 2-4 terminal branches.*

LATERAL FEMORAL CUTANEOUS NERVE

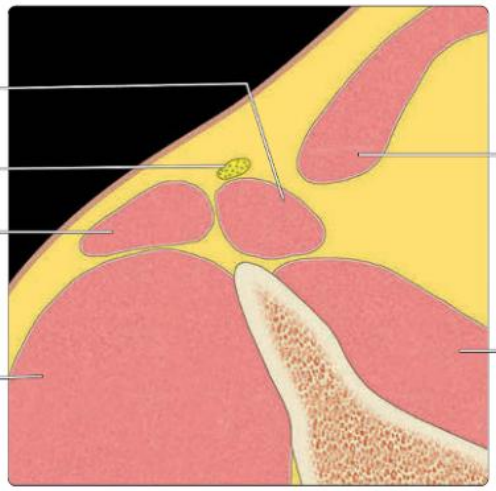

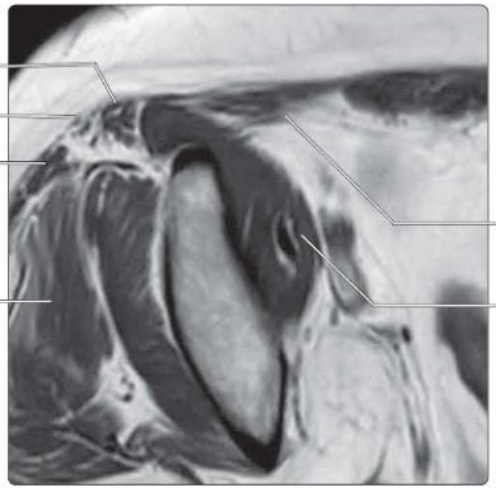

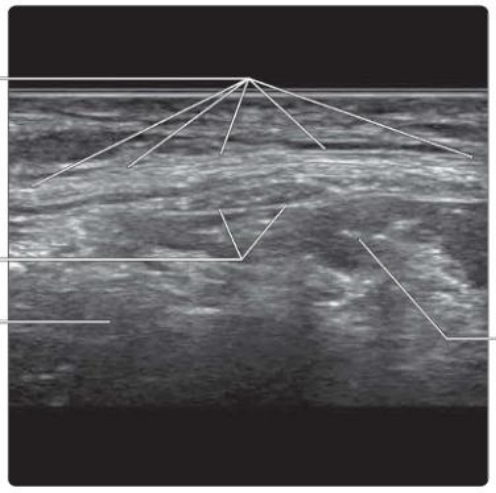

(Top) *Graphic shows the LFCN lying on the surface of sartorius muscle just distal to the inguinal ligament. More distally, the LFCN moves to the interspace between the sartorius and tensor fascia lata muscles.* **(Middle)** *Transverse intermediate-weighted PD MR shows the relationship between the proximal aspects of the sartorius muscle, and the tensor fascia lata muscle with the intervening LFCN, just below the inguinal ligament.* **(Bottom)** *Transverse US shows the flat eye-like LFCN located just below the inguinal ligament. The sartorius and tensor fascia lata muscles are located more deeply.*

OBTURATOR NERVE

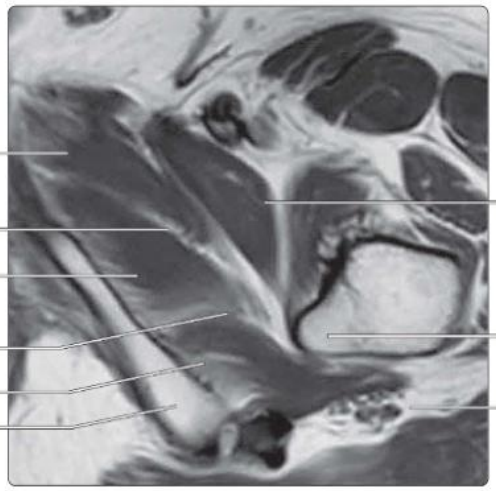

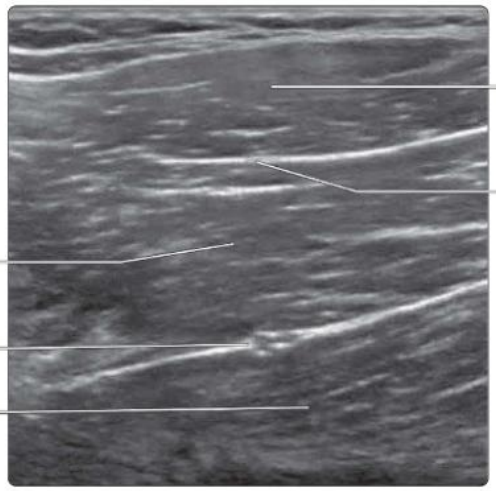

(Top) *Transverse PD MR shows the adductor musculature with the intervening anterior and posterior branches of the obturator nerve. The obturator artery runs with branches of the obturator nerve between the adductor muscles.* **(Middle)** *Transverse US shows the anterior and posterior divisions of the obturator nerve between the adductor muscles. The anterior division lies between the adductor longus and brevis. The posterior division lies between the adductor brevis and magnus.* **(Bottom)** *Transverse US more distal to previous image shows the obturator nerves lying between the adductor muscles on the medial aspect of the proximal thigh. These nerves supply the adductor muscles and provide sensory innervation to the medial aspect of the thigh and knee.*

PUDENDAL AND SCIATIC NERVES

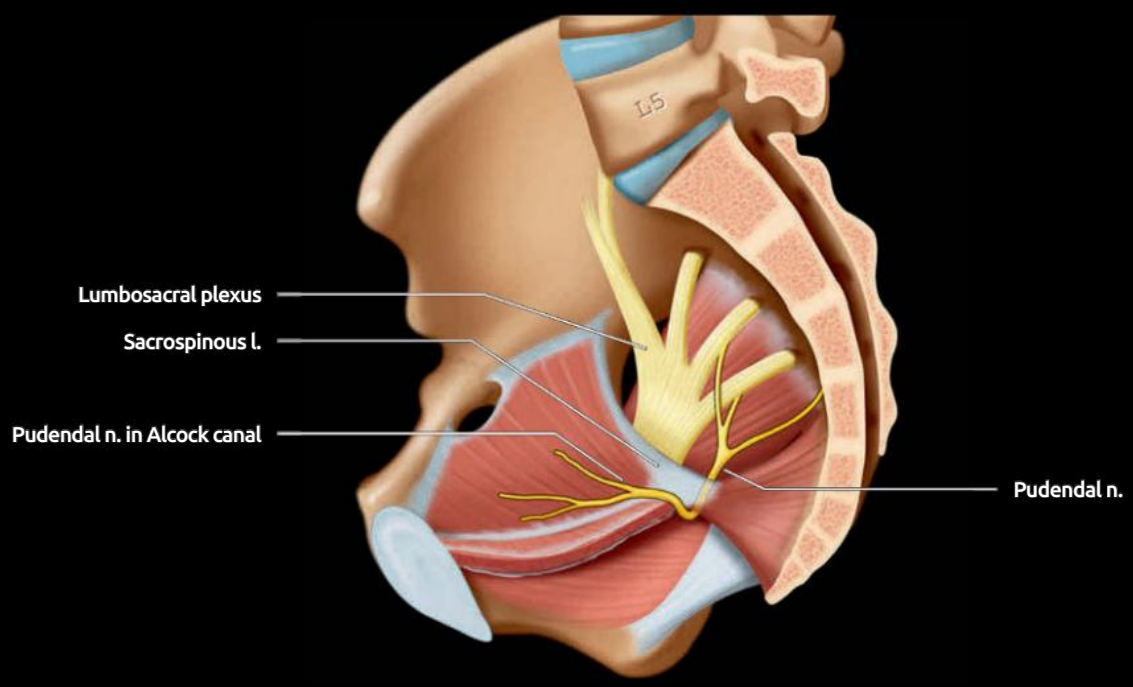

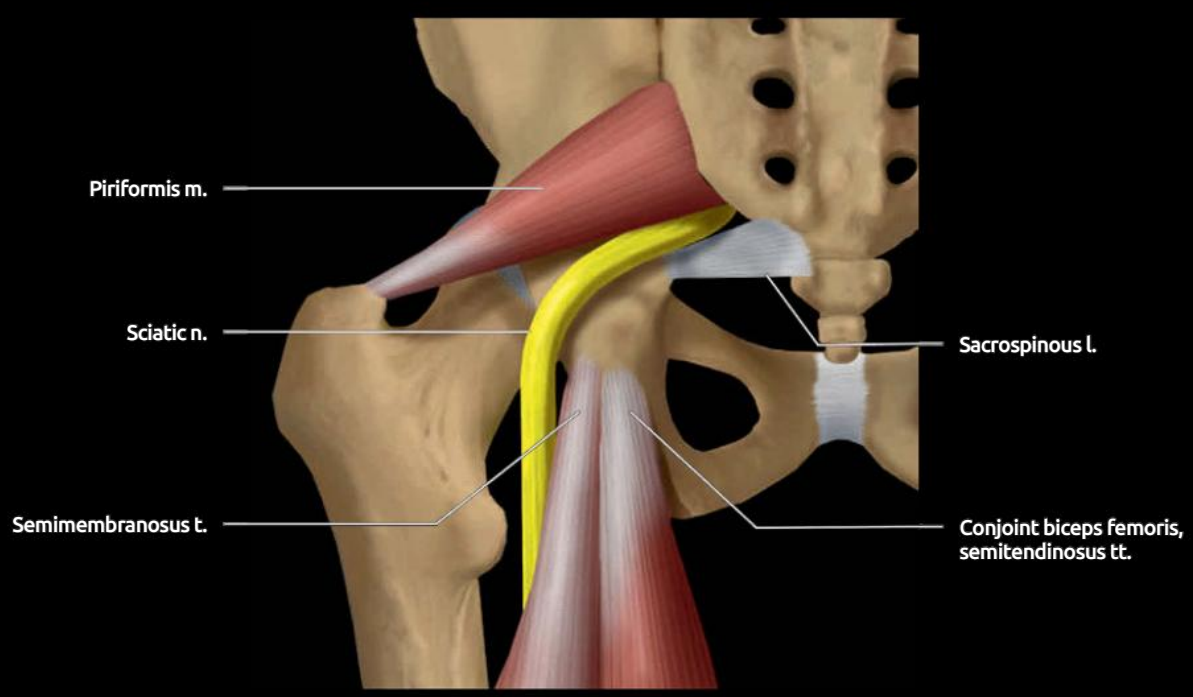

(Top) *Graphic shows the pudendal nerve arising from the S2-S4 nerve roots. It wraps around the sacrospinous ligament and then runs in the pudendal (Alcock) canal deep to the fascia of obturator internus muscle. The pudendal nerve supplies sensory innervation to the skin of the external genitalia, perineum, and anal region. It provides motor innervation to the perineal muscles, external urethra, and anal sphincter.* **(Bottom)** *Graphic shows the sciatic nerve through the greater sciatic foramen deep to the piriformis muscle. In ~ 25% of subjects, the sciatic nerve may bifurcate into the tibial nerve and the common peroneal nerves proximal to the greater sciatic foramen.*

PUDENDAL NERVE

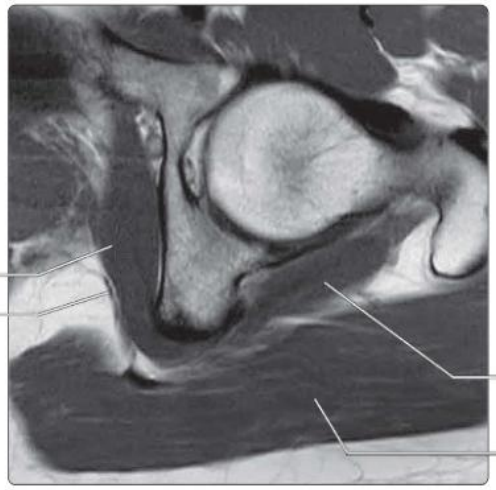

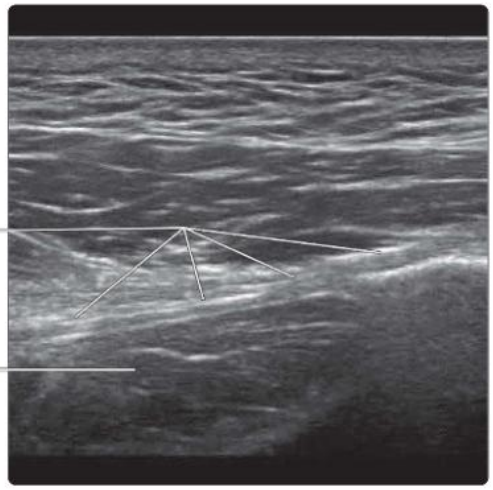

(Top) *Transverse intermediate-weighted PD MR shows the pudendal nerve within the Alcock canal, which is deep to the fascia covering the obturator internus muscle.* **(Middle)** *Transverse US shows longitudinal section of pudendal nerve extending along the Alcock canal.* **(Bottom)** *Transverse US just distal to the tissue spine shows the obturator internus muscle within the pelvis and the gemelli muscles attached to the obturator internus tendon on the lateral aspect of the acetabulum. At this level, the pudendal nerve is located within the Alcock canal. More proximally, it will lie alongside the pudendal artery.*

SCIATIC NERVE

Conjoint biceps femoris-semitendinosus t.
Semimembranosus t.
Ischial tuberosity

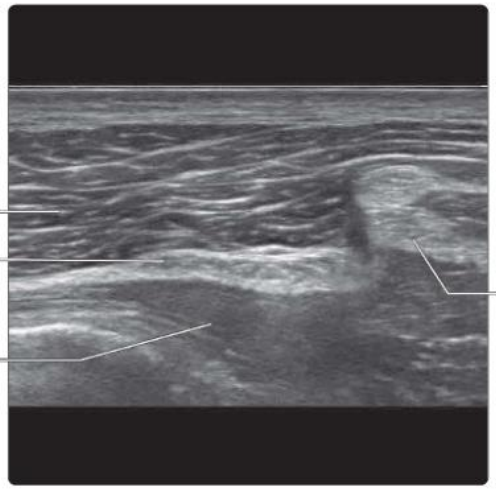

Conjoint t.

Semitendinosus m.
Semimembranosus aponeurosis

(Top) *Transverse US at the level of the ischial tuberosity is shown. The sciatic nerve lies just lateral to the hamstring tendon insertion on the ischial tuberosity. It is usually accompanied by the inferior gluteal artery.* **(Middle)** *Transverse US more distal to the previous image shows the sciatic nerve inferomedial to the biceps femoris-semitendinosus tendon.* **(Bottom)** *Transverse US slightly more distal to the previous image shows the sciatic nerve, just deep to the biceps femoris-semitendinosus conjoint tendon helping to form the Mercedes sign.*

PART I
SECTION 3

Lower Limb

Gluteal Muscles	214
Hip	226
Thigh	236
Lower Limb Arteries and Veins	248
Knee	264
Leg	282
Leg Nerves	294
Ankle	298
Hindfoot and Midfoot	316
Forefoot	334

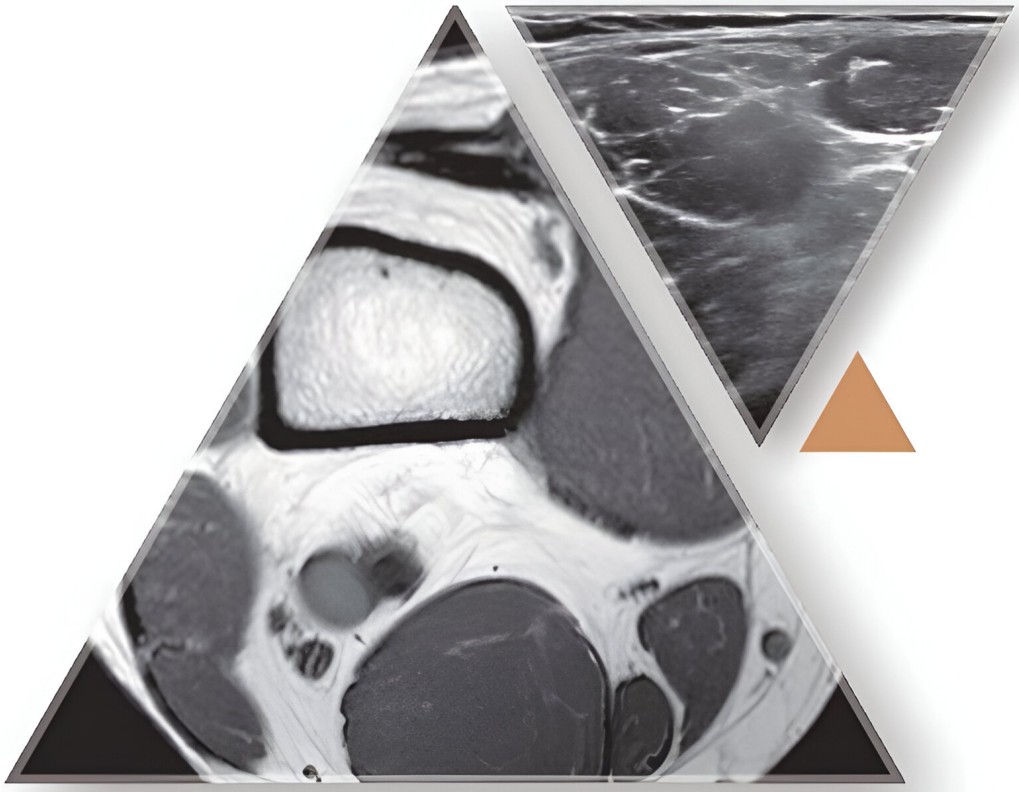

TERMINOLOGY

Abbreviations

- Anterior superior iliac spine (ASIS)

IMAGING ANATOMY

Gluteal Muscles

- Components: Gluteus maximus, gluteus medius, gluteus minimus, tensor fascia lata, piriformis, superior & inferior gemellus, obturator internus & externus, quadratus femoris
- **Gluteus maximus**
  - Origin (O): Posterior to posterior gluteal line of ilium, posterior sacrum & coccyx, sacrotuberous ligament
    - Passes superficial to ischial tuberosity
      - On hip flexion, gluteus maximus muscle moves laterally, exposing ischial tuberosity
    - Passes superficial to bare posterior facet of greater trochanter with interposed trochanteric bursa
  - Insertion (I): Iliotibial band (ITB) tract & proximal aspect of linea aspera on posterior aspect of proximal femur
    - Inserts via short tendon
  - Function (F): Hip extension, abduction, & external rotation
- **Gluteus medius**
  - O: Between anterior & posterior gluteal lines of ilium
  - I: Lateral (anterior band) & posterosuperior (posterior band) facets of greater trochanter with interposed subgluteus medius bursa
    - Inserts via short tendon
  - F: Hip abduction & internal rotation
- **Gluteus minimus**
  - O: External ilium between anterior & inferior gluteal lines
  - I: Anterior facet of greater trochanter with interposed subgluteus minimus bursa
  - F: Hip abduction & internal rotation
  - Gluteus minimus muscle fiber orientation varies from anterior to posterior
    - Anterior fibers run vertically in cephalad-to-caudad direction & can maintain this same orientation throughout their course
    - Posterior fibers run obliquely in posterior-to-anterior direction & need to change orientation just before inserting into anterior facet
- **Tensor fascia lata**
  - O: External lip of anterior iliac crest, external ASIS
  - I: ITB
    - ITB extends to Gerdy tubercle on anterolateral aspect of tibia
  - F: Hip flexion, abduction, & weak internal rotation
  - Tensor fascia lata muscle is prone to hypertrophy or pseudohypertrophy
    - Hypertrophy is when there is true increase in muscle size > 50% of contralateral side
    - Pseudohypertrophy is when fatty infiltration & paradoxical enlargement of muscle occurs due to lumbar radiculopathy or other denervation syndromes
- **Piriformis**
  - O: Anterior sacrum passes through greater sciatic foramen
  - I: Medial side of proximal aspect of greater trochanter
    - Insertion site for piriformis, superior & inferior gemelli, obturator internus tendons
  - F: Hip external rotation, assists abduction
    - Piriformis is only muscle to pass through greater sciatic foramen
    - Variation in sciatic nerve relationship through piriformis muscle
      - This variation is of questionable significance regarding piriformis syndrome
    - Piriformis means pear-shaped in Latin
- **Superior gemellus**
  - O: Ischial spine
  - I: Medial side of proximal aspect of greater trochanter
  - F: Hip external rotation, weak abduction
- **Inferior gemellus**
  - O: Ischial tuberosity
  - I: Medial side of proximal aspect of greater trochanter
  - F: Hip external rotation, weak abduction
- **Obturator internus**
  - O: Internal surface of obturator foramen & membrane
  - I: Medial side of proximal aspect of greater trochanter
  - F: Hip external rotation, weak abduction
    - As obturator internus muscle originates from inner aspect of obturator membrane, it can be seen rotating around ischium during hip internal-external rotation
- **Quadratus femoris**
  - O: Lateral border of ischial tuberosity
  - I: Intertrochanteric crest of femur
  - F: Strong hip external rotation
- **Obturator externus**
  - O: Outer surface of obturator foramen & obturator membrane
  - I: Trochanteric fossa at base of greater trochanters medially
  - F: Lateral rotation of hip

Rotator Cuff of Hip

- Gluteus medius & minimus tendons are particularly prone to tendinosis & spontaneous tear in older patients
  - Similar to rotator cuff tendons of shoulder, which also abduct
- Therefore, these tendons are sometimes referred to as rotator cuff of hip

Iliotibial Tract

- ITB is fascial band formed from conglomeration of fascial coverings of gluteus maximus & tensor fascia lata
  - Overlies gluteus medius tendon insertion into lateral facet
  - ITB can impinge against lateral aspect of greater trochanter during hip flexion & extension
  - ITB also impinges commonly against lateral femoral condyle, known as (distal) ITB syndrome (ITBS)
  - Proximal ITBS can also occur due to friction between proximal insertion of ITB & iliac tubercle (which is widest part of iliac crest just posterior to ASIS)

Bursa

- Greater trochanter bursa
  - Between gluteus maximus muscle/ITB & underlying luteus medius-minimus tendons

- Subgluteus medius & subgluteus minimus bursa
  - Between these tendons & underlying femur
- Ischiogluteal
  - Between ischial tuberosity & gluteus maximus muscle
- Gluteofemoral
  - Between ITB & vastus lateralis muscle
- Obturator internus
  - Between obturator internus muscle & ischium

Ischial Tuberosity

- Covered by gluteus maximus muscle when hip extended, uncovered in hip flexion
- Origin of hamstring tendons
  - Semitendinosus & biceps femoris as conjoint tendon posteromedially
  - Semimembranosus as separate tendon laterally
- Sciatic nerve passes just posterolateral to ischial tuberosity
- Ischiofemoral impingement: Compression of quadratus femoris muscle between ischial tuberosity & lesser trochanter
  - Narrowing of ischiofemoral space < 15 mm or quadratus femoris space < 10 mm

Sacroiliac Joint

- Anteroinferiorly synovial, posterosuperiorly syndesmotic
- Weight transfer from axial to appendicular skeleton
  - Limited gliding & rotation
- **Sacroiliac ligaments**
  - Extremely strong interosseous sacroiliac ligaments within joint
  - Anterior (weak) & posterior sacroiliac ligaments

Posterior Sacroiliac Ligaments of Pelvis

- Primary stabilizers of pelvis
  - **Sacrotuberous**: Superior & inferior posterior iliac spines, sacrum, & coccyx to ischial tuberosity
  - **Sacrospinous**: Lateral sacrum & coccyx to ischial spine
  - **Iliolumbar**: Tip of L5 transverse process to iliac crest

Greater Sciatic Foramen

- Greater sciatic notch converted to foramen by sacrospinous ligament
- Passageway from pelvis to thigh
- Structures identified as exiting pelvis above or below piriformis muscle
  - Above: Superior gluteal artery, vein, & nerve
  - Below: Pudendal nerve, internal pudendal artery & vein, nerve to obturator internus, sciatic nerve, inferior gluteal artery, vein, & nerve, posterior cutaneous nerve of thigh, nerve to quadratus femoris muscle
  - Relationship of structures
    - Most medial: Pudendal nerve
    - Most lateral: Sciatic nerve

Lesser Sciatic Foramen

- Lesser sciatic notch converted to foramen by intersection (crossing) with sacrotuberous & sacrospinous ligaments
- Contents
  - **Pudendal nerve & internal pudendal vessels**
    - Pass over sacrospinous ligament
    - Exit buttock, enter perineum
  - **Obturator internus muscle**

Nerves & Arteries

- **Sciatic nerve**
  - Exits pelvis inferior to piriformis muscle (typically)
    - Most lateral structure
  - Location of sciatic nerve to piriformis muscle varies
    - Passes below piriformis (normal) (85%)
    - Passes through & below piriformis (13%)
    - Passes through piriformis (< 1%)
    - Passes through & above piriformis (< 1%)
    - Passes above & below piriformis (< 1%)
    - Passes above piriformis (< 1%)
- **Superior gluteal nerve**
  - Exits pelvis superior to piriformis muscle
    - Ascends between gluteus medius & minimus muscles supplying these muscles & also tensor fascia lata muscle
- **Superior gluteal artery**
  - Continuation of posterior division of internal iliac artery
  - Exits pelvis superior to piriformis muscle
    - Accompanies superior gluteal nerve
  - Superior gluteal vein travels with artery, draining into internal iliac vein
- **Inferior gluteal nerve**
  - Exits pelvis posterior to sciatic nerve
    - Runs cranially to innervate gluteus maximus muscle
- **Inferior gluteal artery**
  - Larger terminal branch of anterior division of internal iliac artery
  - Exits pelvis below piriformis muscle
    - Posteromedial to sciatic nerve
    - Accompanies sciatic nerve & posterior cutaneous nerve of thigh
  - Inferior gluteal vein travels with artery, draining into internal iliac vein
- **Posterior cutaneous nerve of thigh**
  - Located close to medial border of sciatic nerve at ischial tuberosity level
- **Pudendal nerve**
  - Exits pelvis inferior to piriformis muscle
    - Nerve is most medial structure
  - Crosses over sacrospinous ligament & reenters pelvis via lesser sciatic foramen
    - Extends, along with internal pudendal artery & vein, along lateral margin of ischiorectal fossa in pudendal canal deep to obturator fascia
  - Innervates perineum

ANATOMY IMAGING ISSUES

Imaging Pitfalls

- Subcutaneous fat in gluteal region & thigh can be thick & mistaken for muscle
  - Look for investing fascia & fiber orientation to identify muscle layer
- Normal small bare area on lateral facet of greater trochanter anteriorly, close to anterior facet, should not be mistaken for gluteus medius tendon tear

GLUTEAL MUSCLES AND SCIATIC NERVE

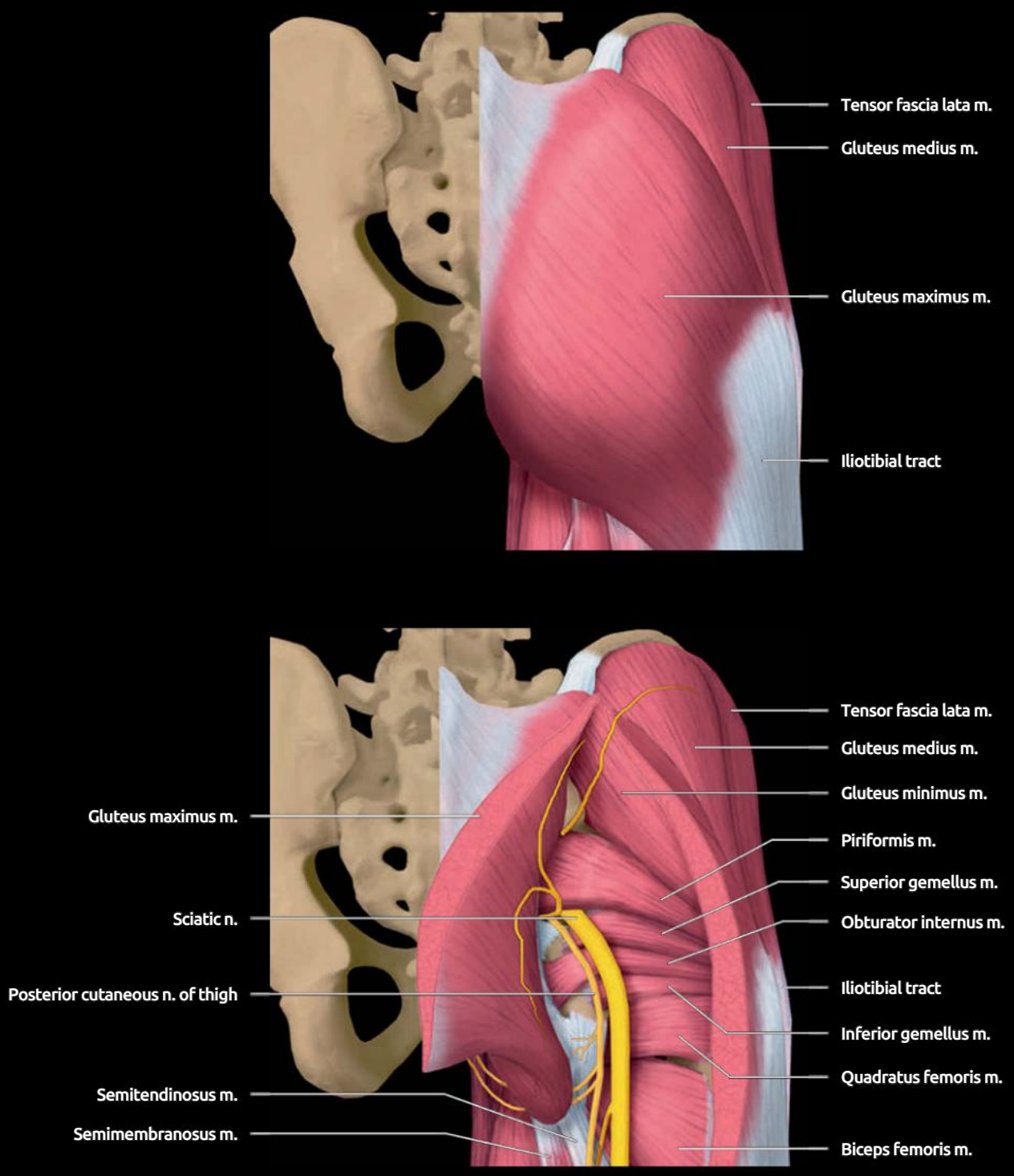

(Top) *The gluteus muscles from anterior to posterior and deep to superficial are the gluteus minimus, medius, and maximus. These muscles form the bulk of the gluteal region. The gluteus maximus, in particular, covers most of the deep gluteal structures.* **(Bottom)** *Graphic of the gluteal region with the gluteus maximus muscle reflected shows the close relationship between the deep short external hip rotators and the sciatic nerve. The sciatic nerve emerges from the pelvis below the piriformis muscle and then descends on the posterior aspects of the short external rotators along with the posterior cutaneous nerve of the thigh and the inferior gluteal artery (not shown).*

GLUTEAL MUSCLES AND SCIATIC NERVE

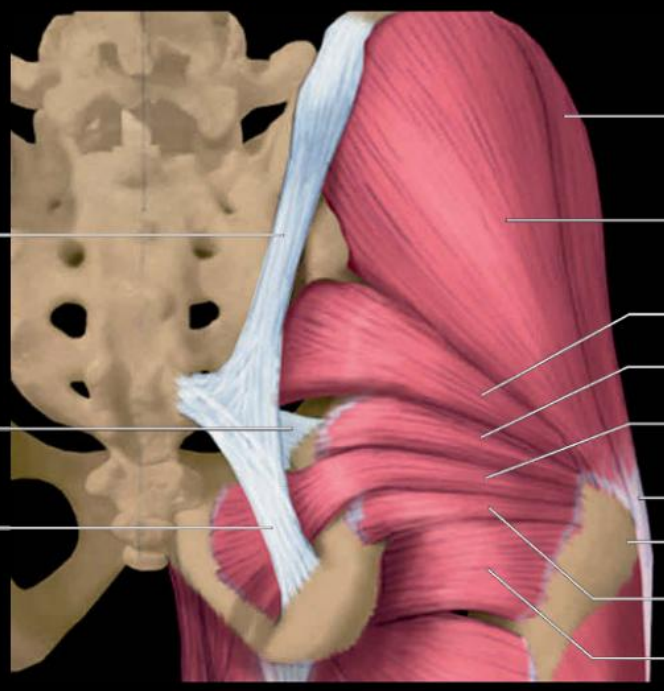

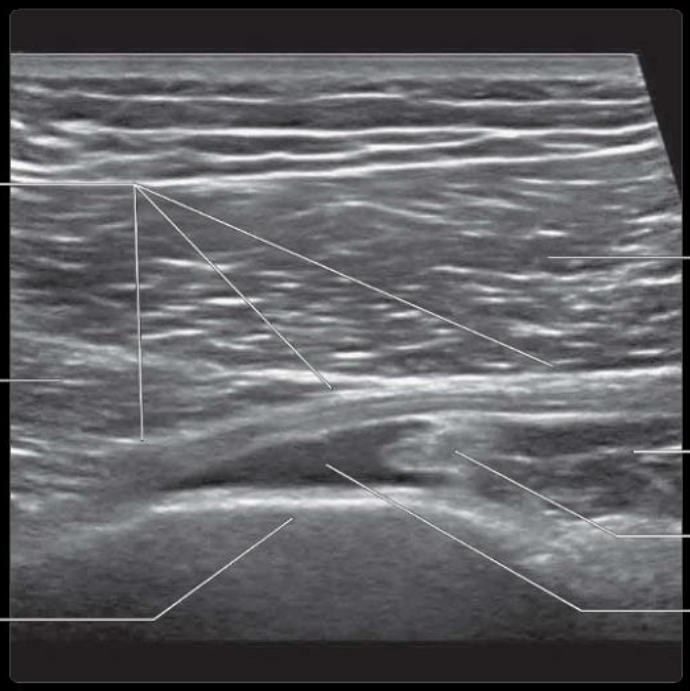

(Top) *After removing the gluteus maximus, the deep muscles are visible: Piriformis, superior gemellus, obturator internus, inferior gemellus, and quadratus femoris. These all externally rotate the hip. The piriformis muscle exits the pelvis via the greater sciatic foramen while the obturator internus muscle exits via the lesser sciatic foramen.* **(Bottom)** *Longitudinal US shows the sciatic nerve emerging from the greater sciatic foramen below the piriformis muscle and passing distally over the superior gemellus muscle, the obturator internus tendon, and the inferior gemellus muscle.*

MUSCULAR ATTACHMENTS, LATERAL ASPECT OF PELVIS

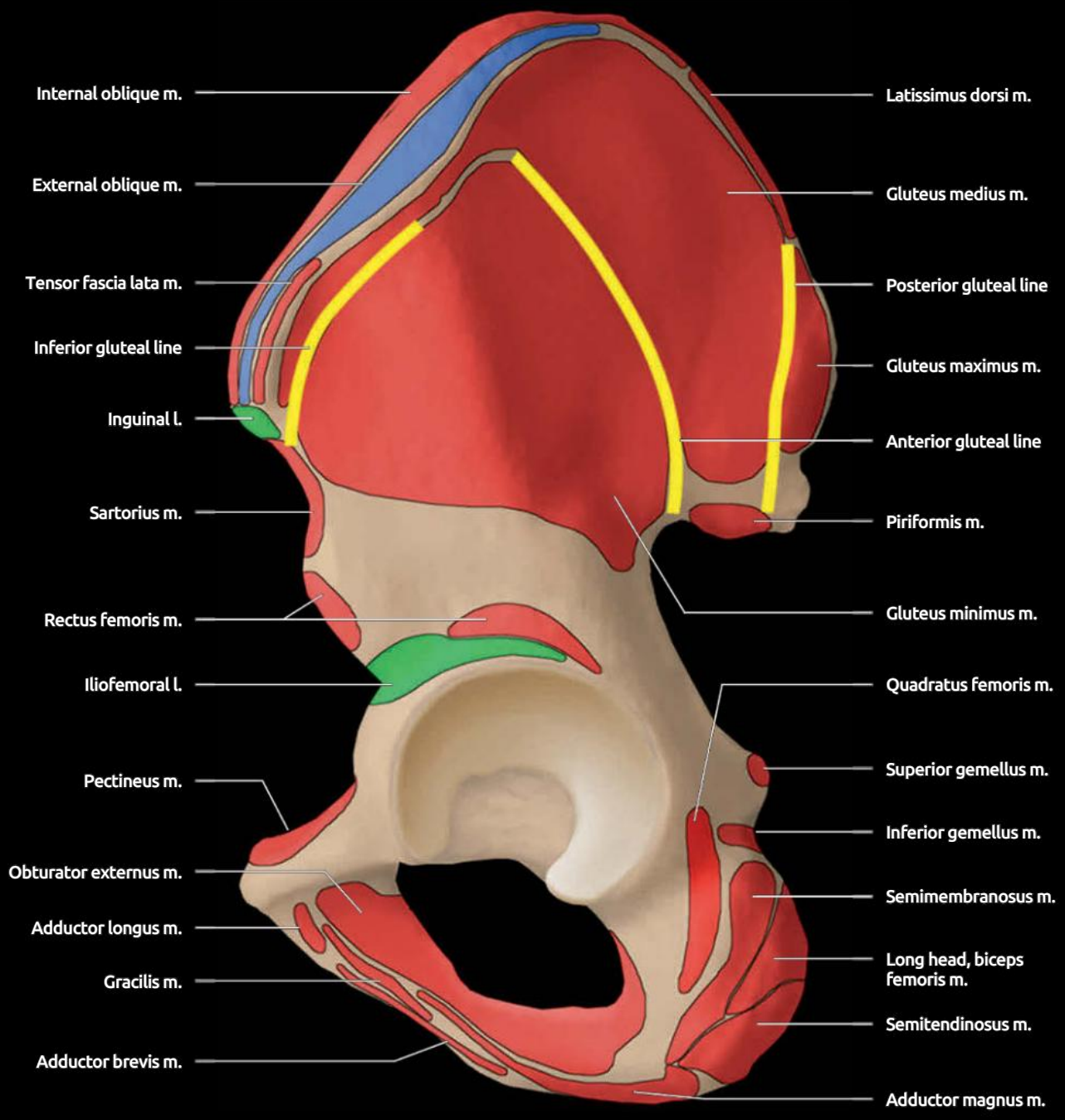

Graphic shows muscular attachments on the external surface of the pelvis. The gluteal lines are 3 curved, bony ridges on the posterior surface of the ilium. The gluteus maximus arises from the posterior gluteal line and the most posterior aspect of the iliac blade, as well as from the dorsal aspects of the sacrum, coccyx, and sacrotuberous ligament (not shown). The gluteus medius arises from the anterior gluteal line and between the anterior and posterior gluteal lines. The gluteus minimus arises from the inferior gluteal line and between the inferior and anterior gluteal lines.

GLUTEAL AND PIRIFORMIS MUSCLES

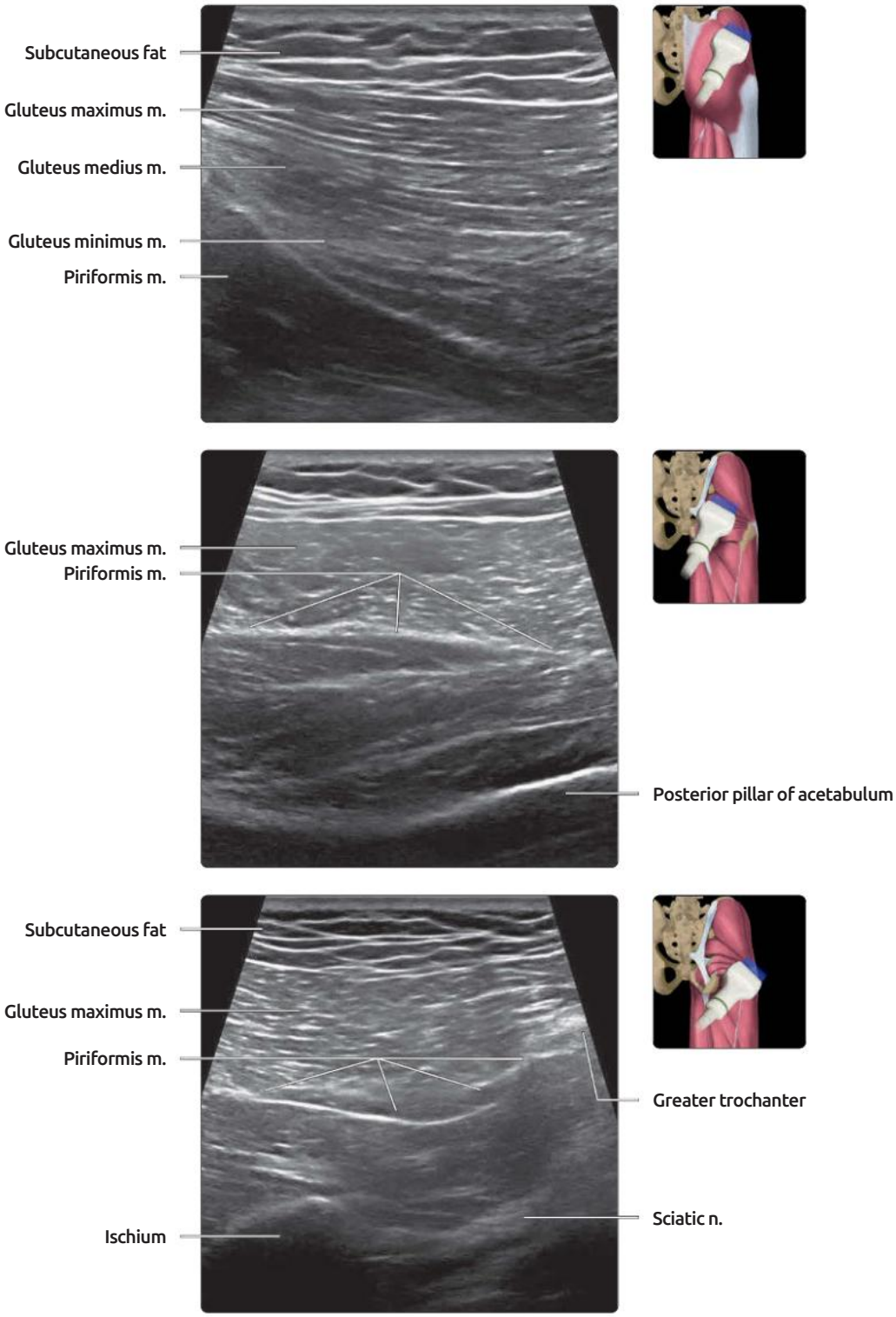

(Top) *Transverse US shows the gluteal muscles on the posterior surface of the ilium.* **(Middle)** *Transverse oblique US shows the piriformis muscle emerging from the greater sciatic foramen deep to the gluteus maximus muscle.* **(Bottom)** *Transverse oblique US shows the piriformis muscle and tendon with the tendon inserting onto the greater trochanter.*

SHORT EXTERNAL ROTATORS OF HIP

(Top) *Transverse US shows the superior gemellus muscle, which is attached to the obturator internus tendon, extending toward its attachment on the medial aspect of the greater trochanter.* **(Middle)** *Transverse US shows the inferior gemellus muscle, which is also attached to the obturator internus tendon, extending between the pelvis and the greater trochanter.* **(Bottom)** *Transverse US shows the quadratus femoris muscle just deep to the sciatic nerve, which lies just medial to the hamstring attachment on the ischial tuberosity.*

PROXIMAL THIGH

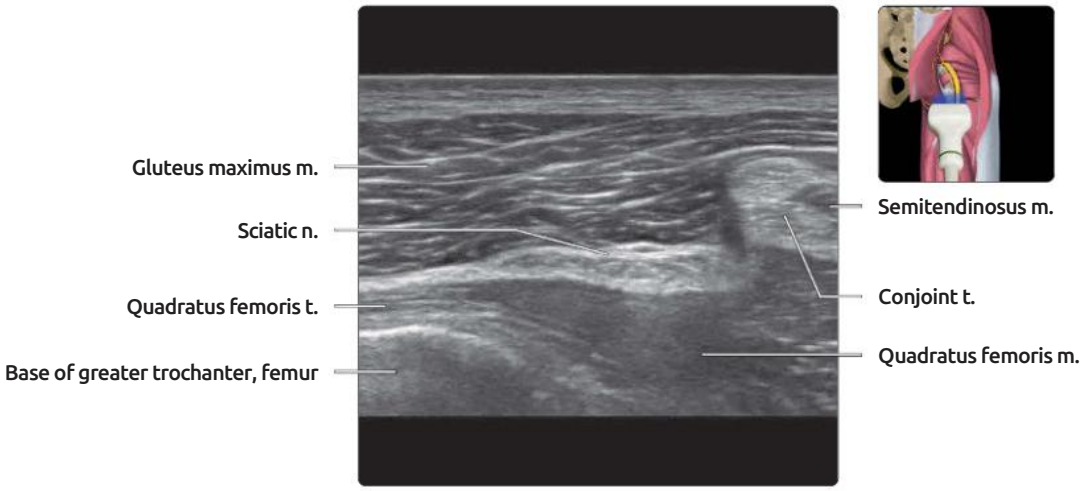

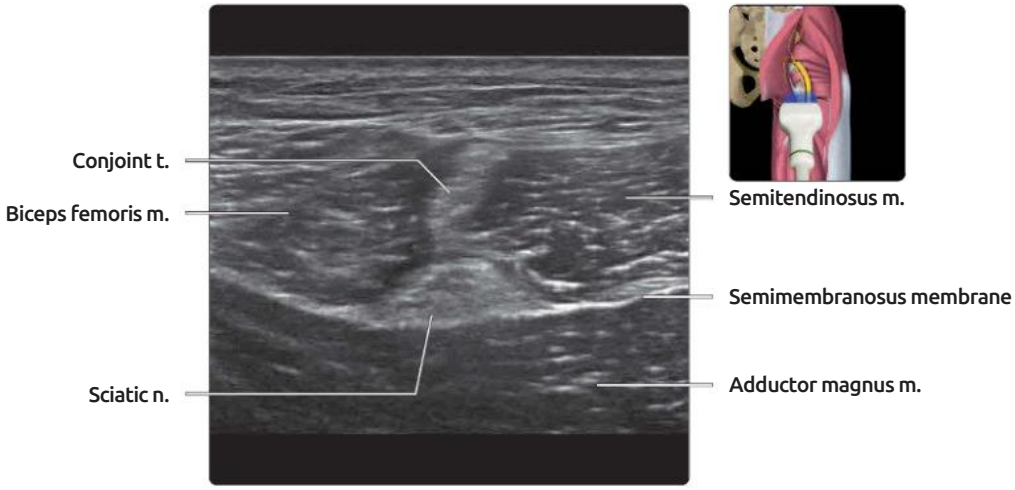

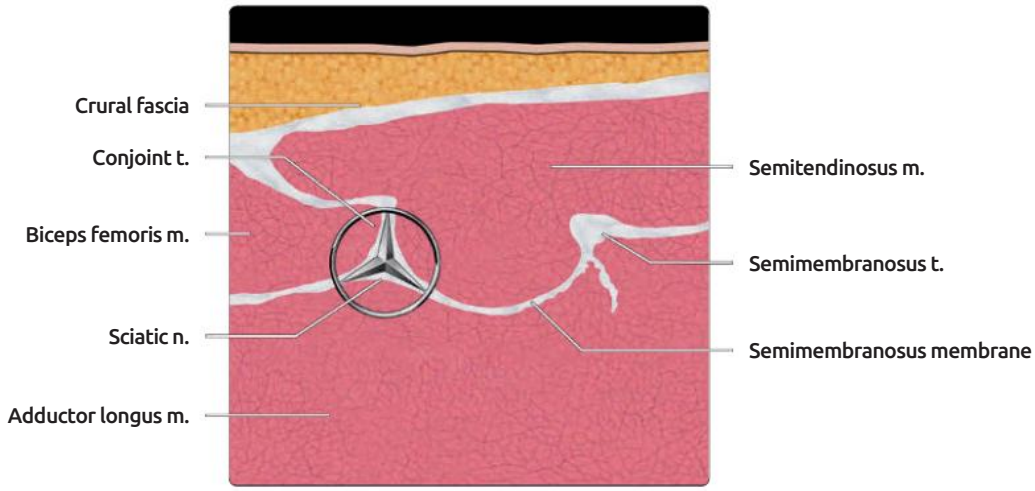

(Top) *Transverse US just distal to the ischial tuberosity shows the close relationship between the sciatic nerve and the conjoint tendon of the biceps femoris and semitendinosus.* **(Middle)** *Transverse US of the proximal thigh posteriorly shows the sciatic nerve just deep to the biceps femoris-semitendinosus conjoint tendon, producing the Mercedes sign.* **(Bottom)** *Graphic shows the Mercedes sign of the proximal thigh produced by the sciatic nerve lying deep to the conjoint biceps femoris-semitendinosus tendon. Laterally, the conjoint tendon is continuous with the semimembranosus membrane. The semimembranosus muscle is nearly entirely membranous in the proximal leg.*

GLUTEUS MINIMUS TENDON AND MUSCLE

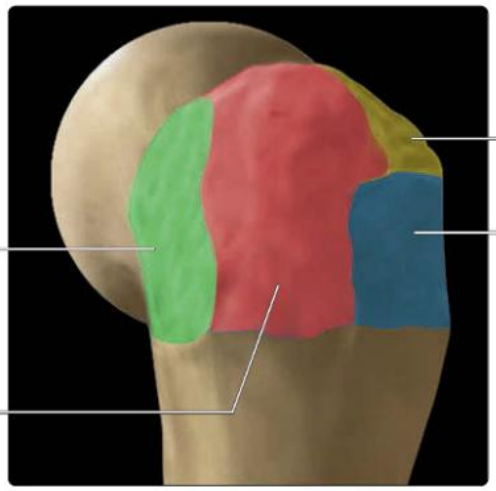

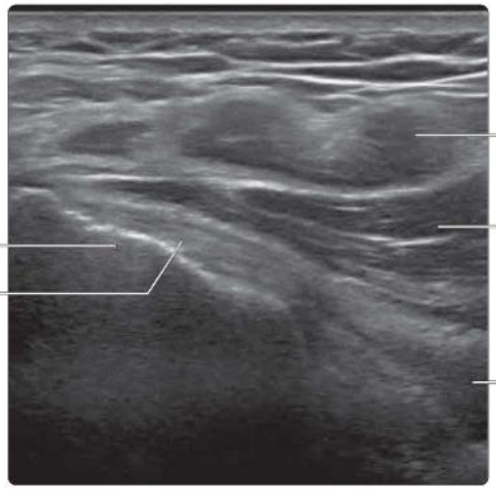

(Top) *Graphic shows the facets of the greater trochanter. The gluteus minimus tendon is attached to the anterior facet. The anterior band of the gluteus medius is attached to the lateral facet, while the posterior band is attached to the posterosuperior facet. The posterior facet of the greater trochanter is bare.* **(Middle)** *Longitudinal oblique US shows the gluteus minimus tendon attached to the anterior facet of the greater trochanter.* **(Bottom)** *Longitudinal US just anterosuperior to the previous image shows the gluteus minimus muscle and musculotendinous junction. The posterior fibers of the gluteus minimus muscle change orientation, from being aligned obliquely to aligned vertically, close to the insertion. As a result, the musculotendinous junction does not have the usual fibrillar appearance of other musculotendinous junctions.*

GLUTEUS MEDIUS TENDON AND MUSCLE

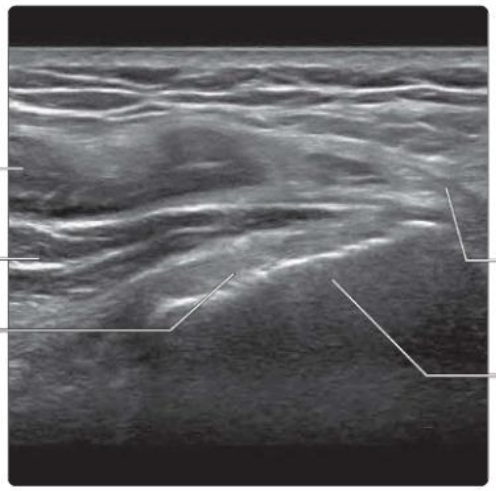

(Top) *Longitudinal oblique US shows the anterior band of the gluteus medius muscle attaching to the lateral facet of the greater trochanter.* **(Middle)** *Longitudinal oblique US just superior to the previous image shows the gluteus medius muscle.* **(Bottom)** *Longitudinal oblique US posterosuperior to the previous image shows the posterior band of the gluteus medius muscle attaching to the posterosuperior facet of the greater trochanter.*

PUDENDAL NERVE

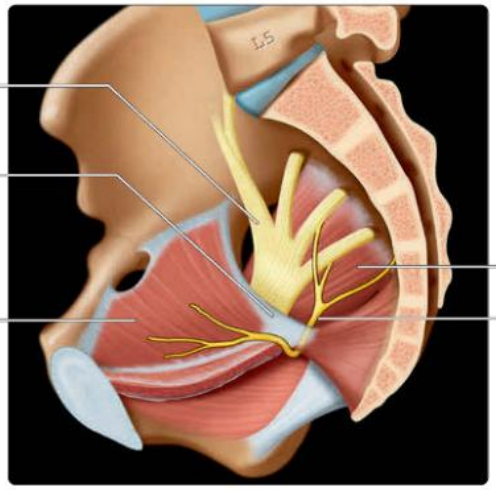

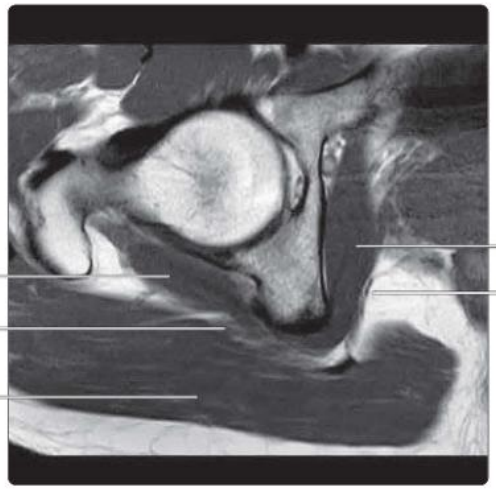

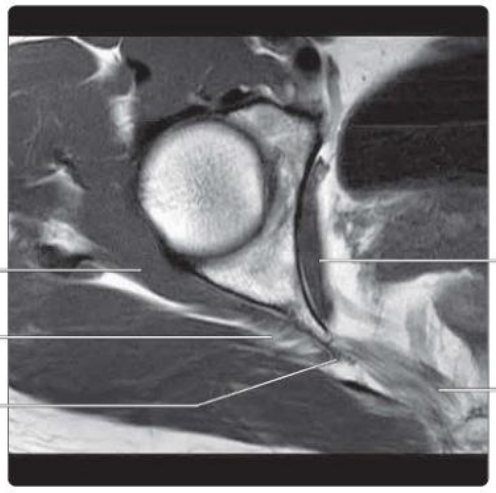

(Top) *Graphic shows the course of the pudendal nerve. The pudendal nerve arises from the anterior branches of the S2-S4 nerve roots. It comes out through the greater sciatic foramen and goes back into the pelvis by curving around the sacrospinous ligament. Back in the pelvis, it runs along the lateral border of the ischiorectal fossa with the internal pudendal vessels within the pudendal or Alcock canal, formed by the obturator internus muscle fascia.* **(Middle)** *Axial T1 MR shows the pudendal nerve within Alcock canal on the surface of the obturator internus muscle.* **(Bottom)** *Axial T1 MR shows the pudendal nerve at the tip of the ischial spine just caudad to the piriformis muscle.*

PUDENDAL NERVE

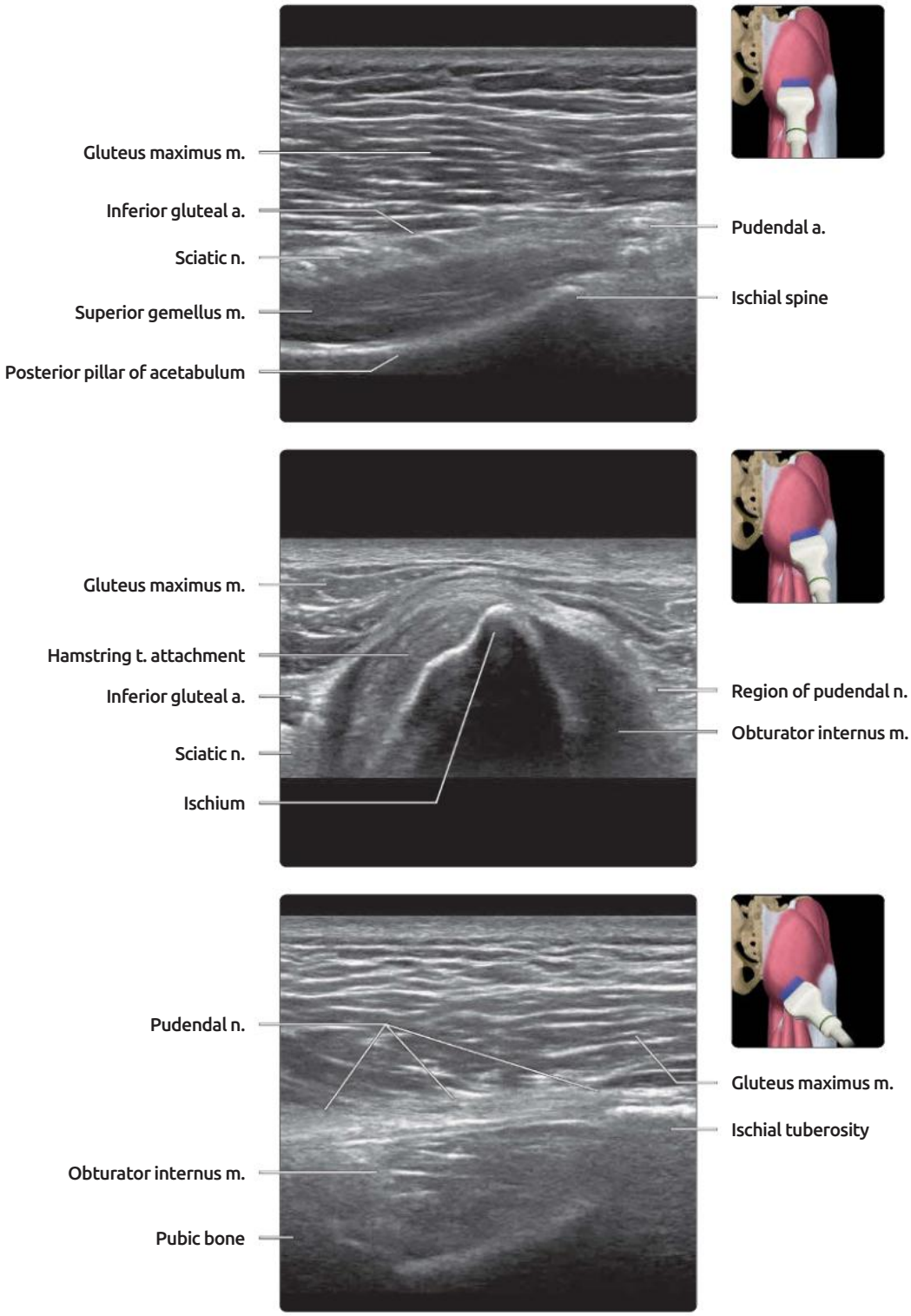

(Top) *Transverse US of the posterior aspect of the gluteal region shows the pudendal artery at the tip of the ischial spine. Although the pudendal nerve is not directly visible, it does lie in the vicinity of the pudendal artery.* **(Middle)** *Transverse US of the posterior aspect of the gluteal region at a level slightly distal to the previous image with the transducer tilted medially shows the posterior margin of the ischium with the hamstring tendon attachment laterally and the obturator internus muscle attached medially. The pudendal nerve will lie on the surface of the obturator internus muscle.* **(Bottom)** *Longitudinal oblique US shows the pudendal nerve running along Alcock canal superficial to the obturator internus muscle. This view is obtained by placing the transducer on the medial aspect of the ischial tuberosity from a medial approach and angling it in an oblique longitudinal plane toward the sacrococcygeal junction.*

IMAGING ANATOMY

Overview

- Ball & socket joint with wide range of motion 2nd only to glenohumeral joint

Acetabulum

- Formed by pubis, ilium, ischium
- Oriented anteriorly, inferiorly, & laterally
- Covers > 50% of femoral head
- **Anterior & posterior rims**: Osseous margins of acetabulum
- **Medial wall**: Quadrilateral plate ilium

Femoral Head

- 2/3 of sphere
- Covered by articular cartilage
  - Cartilage thickest superiorly
  - Cartilage thins at head/neck junction

Labrum

- Fibrocartilage lip deepens at acetabular rim
- Joins transverse ligament at margins of acetabular notch
- Thickest posteriorly & superiorly
- Widest anteriorly & superiorly
- Vascular supply: Branches of obturator, superior, & inferior gluteal arteries
  - Mainly on capsular surface
- Shape
  - Triangular in 66-94%
  - Variants: Rounded/blunt or absent
  - Absent labrum: Constellation of absent anterior labrum & small remnant superiorly
    - In 10% of asymptomatic individuals
- Function
  - Protects cartilage: Distributes forces by maintaining synovial fluid layer between articular surfaces
  - Prevents lateral translation of femoral head
- Labral tear
  - Frequently has associated paralabral ganglion cyst
  - Easier to detect in presence of joint effusion/arthrographic contrast
  - Most common anterosuperiorly & anteriorly

Joint Capsule

- 2 layers of fibers: Circular & longitudinal
- Attachments
  - Acetabulum
    - Base of labrum anteriorly & posteriorly
    - Several millimeters above labrum superiorly
  - Femur
    - Anterior: Intertrochanteric line
    - Posterior: Proximal to intertrochanteric crest
    - Anterior attachment more lateral than posterior attachment
  - Circular fibers known as zona orbicularis most abundant at inferior & posterior aspects of capsule
    - Forms collar around femoral neck
  - Longitudinal fibers most abundant at superior & anterior aspects of capsule
    - Reinforced by iliofemoral capsular ligament
    - Less important supporting capsular ligaments: Ischiofemoral & pubofemoral ligaments
  - **Perilabral recess**: Between labrum & capsule
    - Smaller anteriorly & posteriorly
    - Larger superiorly

Vascular Supply

- Branches of medial & lateral circumflex femoral, deep division of superior gluteal, inferior gluteal arteries, artery of ligamentum teres (branch of obturator artery)

Innervation

- Branches from nerve to rectus femoris, nerve to quadratus femoris, anterior division of obturator nerve, accessory obturator nerve, superior gluteal nerve

Major Adjacent Structures

- **Greater trochanter**
  - Insertion
    - Gluteus minimus tendon inserts to anterior facet
    - Gluteus medius tendon inserts to lateral facet (anterior band) & posterosuperior facet (posterior band)
  - Separated from overlying iliotibial tract by thin trochanteric bursa, imperceptible on imaging
    - Piriformis, superior gemellus, obturator internus, & inferior gemellus insert onto medial side of superior aspect of greater trochanter
    - Obturator externus inserts to trochanteric fossa at base of greater trochanter medially
    - Quadratus femoris inserts to intertrochanteric crest
- **Lesser trochanter**
  - Insertion
    - Iliopsoas muscle
- **Anterior inferior iliac spine**
  - Origin
    - Rectus femoris muscle
- **Iliopsoas muscle**
  - Runs inferomedially across anterior surface of hip joint
- **Femoral vessels**
  - Separated from hip joint by iliopsoas muscle
- **Iliotibial tract**
  - Merges with tensor fascia lata anteriorly & gluteus maximus posteriorly
    - Trochanteric bursa lies between iliotibial tract superficially & gluteus medius tendon deeply

Neonatal Hip

- High success rate in treatment of developmental dysplasia requires early recognition with US
- Established measurements of acetabular depth & coverage of femoral head

ANATOMY IMAGING ISSUES

Imaging Sweet Spots

- Small joint effusions best detected at anterior surface of femoral neck
  - Best site for aspiration or injection is head/neck junction
  - Zona orbicularis restricts potential space at midneck region

AXIAL AND SAGITTAL HIP SECTIONS

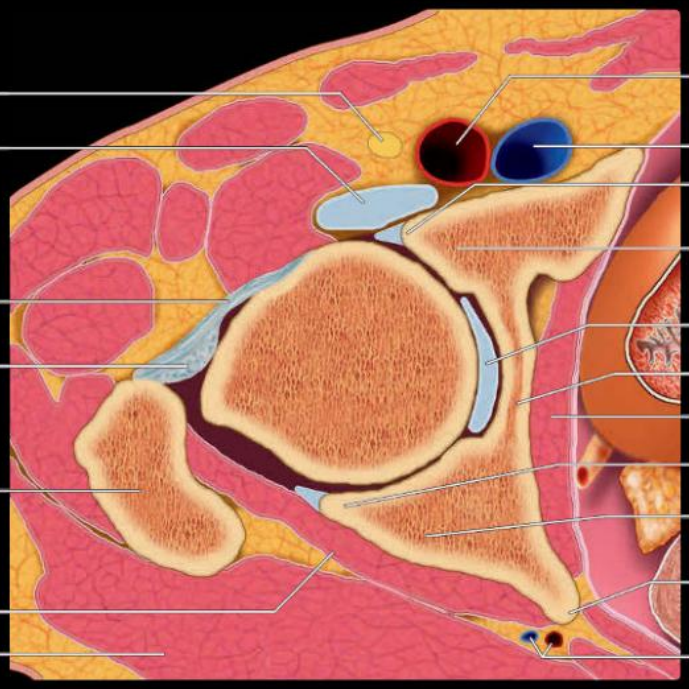

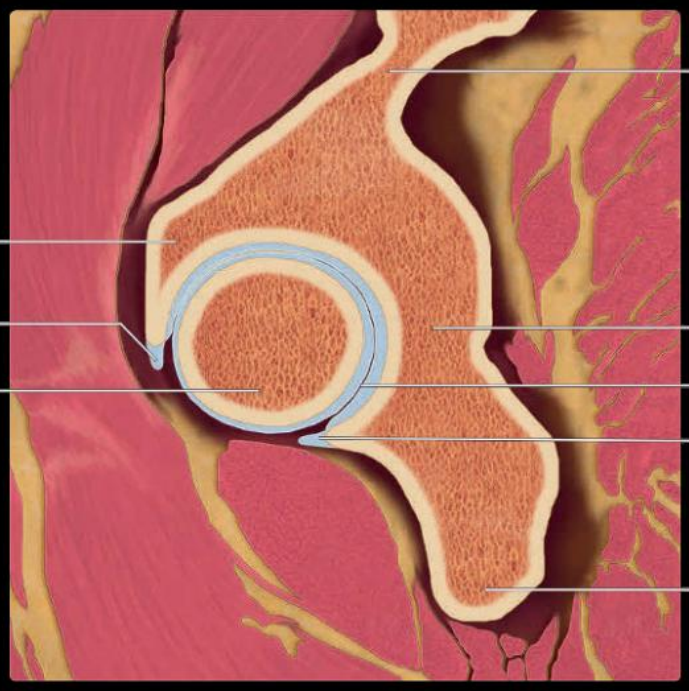

(Top) *Axial graphic shows the hip joint. The iliopsoas tendon is closely applied to the joint anteriorly. The bursa (not shown) lies between the anterior hip joint capsule and the iliopsoas tendon. The ligamentum teres is seen in profile as a flattened structure. The 2 layers of the external capsule, the more superficial longitudinal fibers and deep circular fibers, are visible.* **(Bottom)** *Sagittal graphic of the hip joint nicely demonstrates the inverted Y of the acetabulum. The ilium is the stem, and the limbs are the anterior and posterior acetabular columns.*

CORONAL HIP SECTION AND LIGAMENTS

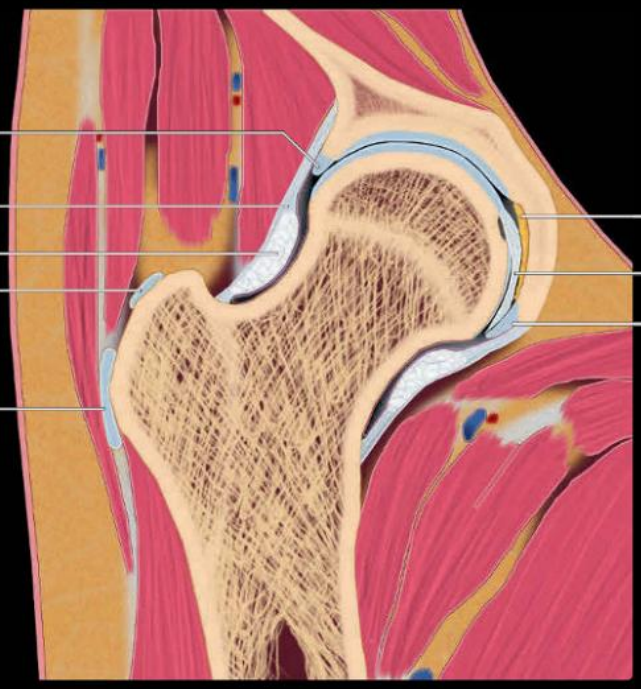

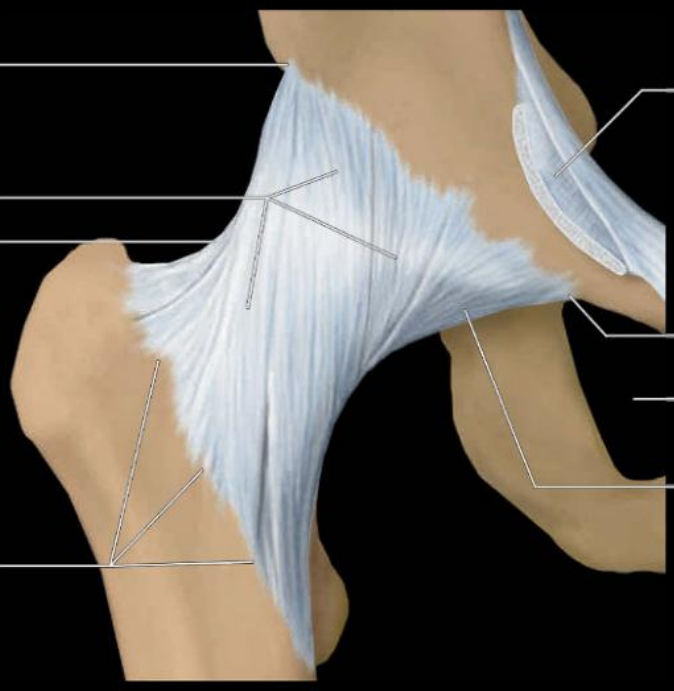

(Top) *Coronal graphic demonstrates many of the important structures of the hip joint. The longitudinally oriented fibers of the external joint capsule (iliofemoral ligament) and the deeper, circularly oriented fibers of the zona orbicularis are visible. The ligamentum teres is inserted by the transverse ligament. The pulvinar, which is a mass of fat and fibrous tissue, fills the acetabular fossa. The trochanteric and other bursa are not seen on US unless distended with fluid or synovial proliferation.* **(Bottom)** *Graphic shows the anterior capsular ligaments. The longitudinal spiral of the iliofemoral and pubofemoral ligaments is well seen with attachments to the anterior inferior iliac spine and pubic aspect of the obturator foramen, respectively. The ischiofemoral ligament is located on the posterior and posterosuperior aspect of the hip capsule, extending from the greater trochanter to insert along the posterior ischial border of the acetabulum.*

ANTERIOR HIP

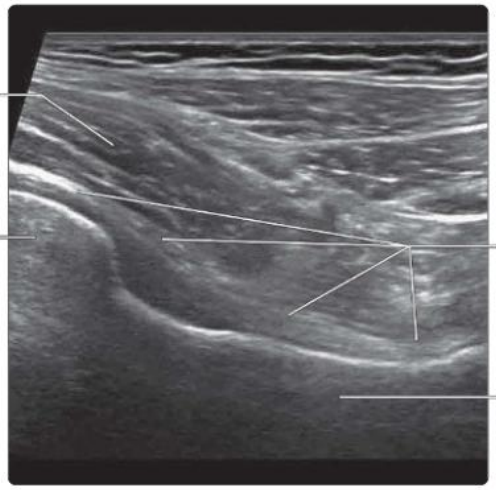

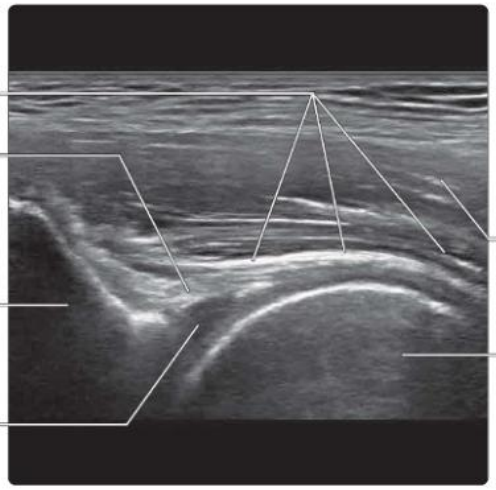

(Top) *Transverse oblique US along the femoral head and neck shows the anterior hip capsule. This is attached to the acetabular rim proximally and the intertrochanteric area distally.* **(Middle)** *Transverse US of the hip joint shows the anterior capsule and labrum, as well as the articular cartilage overlying the femoral head.* **(Bottom)** *Transverse US shows the close relationship between the iliopsoas tendon and the anterior labrum at the anterior aspect of the hip joint.*

GLUTEUS MEDIUS

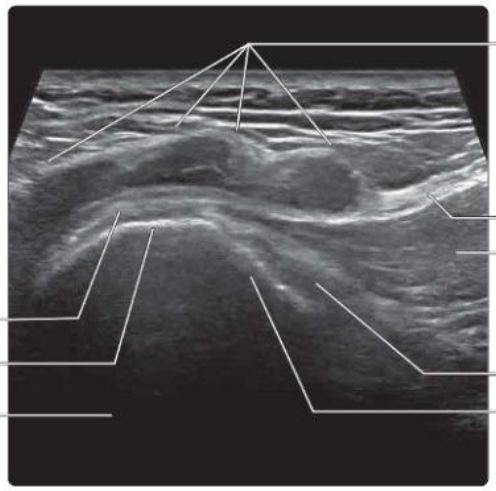

(Top) *Transverse US shows the lateral and anterior facets of the greater trochanter. The anterior band of the gluteus medius tendon is attached to the lateral facet. This attachment is V-shaped and wider proximally. The lateral facet lies deep to the gluteus maximus muscle, which is attached to the iliotibial band.* **(Middle)** *Longitudinal oblique US of the lateral facet shows the insertion of the anterior band of the gluteus medius tendon into the lateral facet.* **(Bottom)** *Longitudinal US shows the more posterior band of the gluteus medius tendon inserted into the posterosuperior facet of the greater trochanter.*

GLUTEUS MINIMUS

(Top) *Transverse US of the greater trochanter shows the fireman's helmet type of configuration of the greater trochanter with the badge area anteriorly being the anterior facet to which the gluteus minimus tendon is attached.* **(Middle)** *Longitudinal oblique US of the anterior facet shows the gluteus minimus musculotendinous junction and tendon. As the obliquely oriented posterior fibers of gluteus minimus rotate just proximal to their insertion, the posterior aspect of the musculotendinous junction is often not as fibrillar as is usually seen. The anterior fibers of the gluteus minimus do not undergo such rotation.* **(Bottom)** *Longitudinal oblique US more medial to the previous image shows the gluteus minimus and medius muscles deep to the iliotibial band.*

ILIOPSOAS MUSCLE AND TENDON

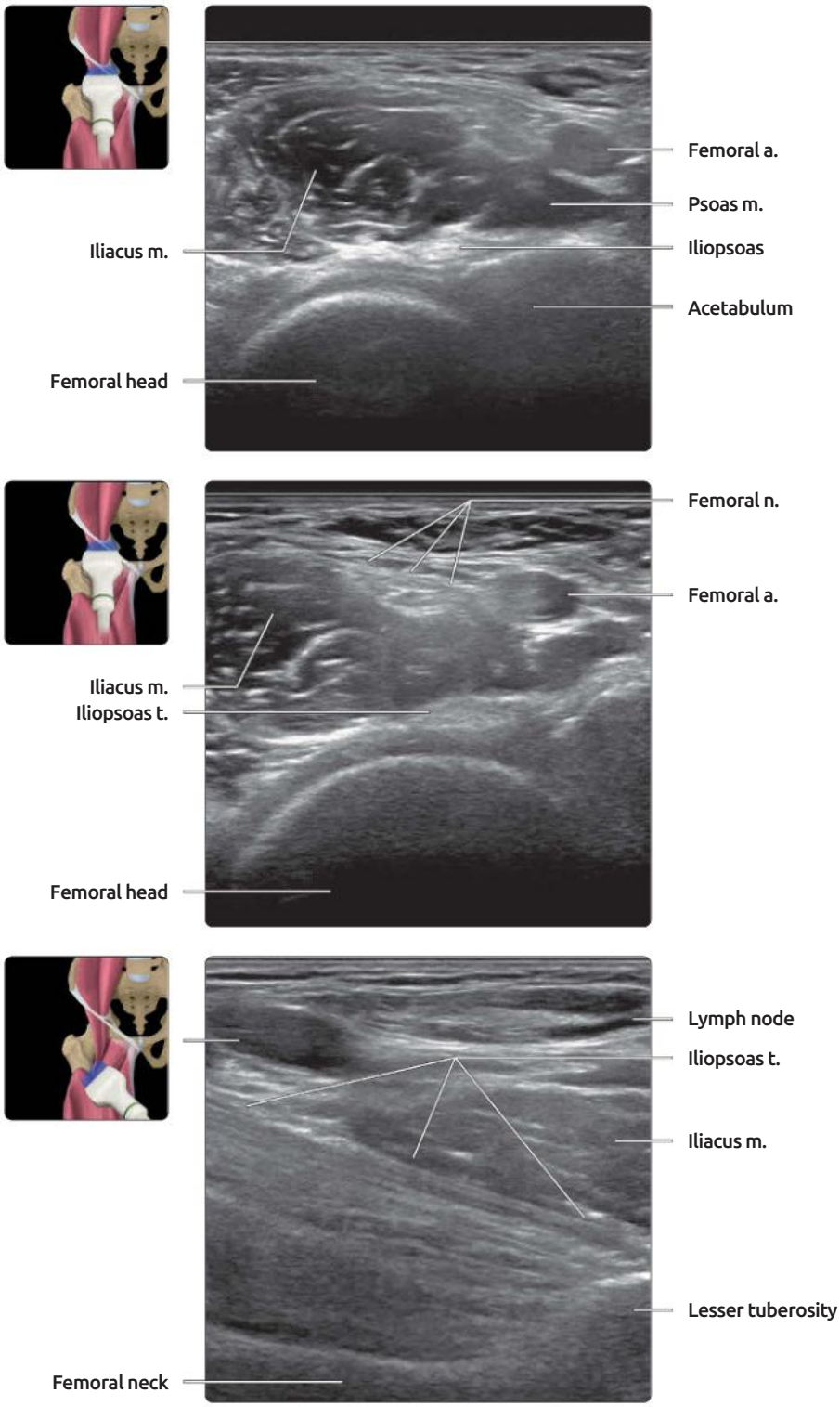

(Top) *Transverse US shows the structures anterior to the hip joint. There is a bursa positioned between the iliopsoas tendon and the anterior aspect of the hip joint, though this bursa is not visible unless distended.* **(Middle)** *Transverse US shows the structures anterior to the hip joint. One can appreciate the close apposition that exists between the iliopsoas tendon and the anterior aspect of the hip joint. The iliopsoas tendon can impinge on the anterior labrum and may be contributory to the development of anterior labral tears.* **(Bottom)** *Longitudinal oblique US with the hip flexed and externally rotated shows the iliopsoas tendon inserting onto the lesser trochanter.*

POSTERIOR HIP

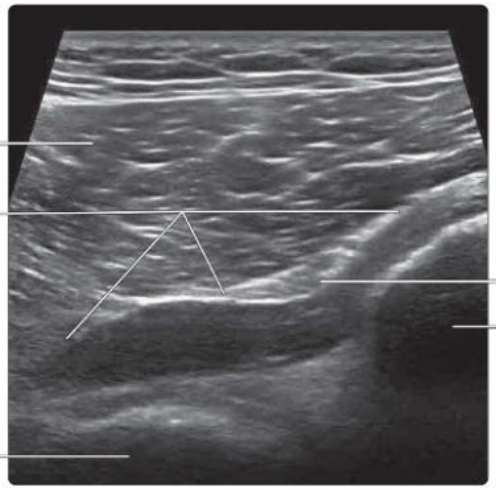

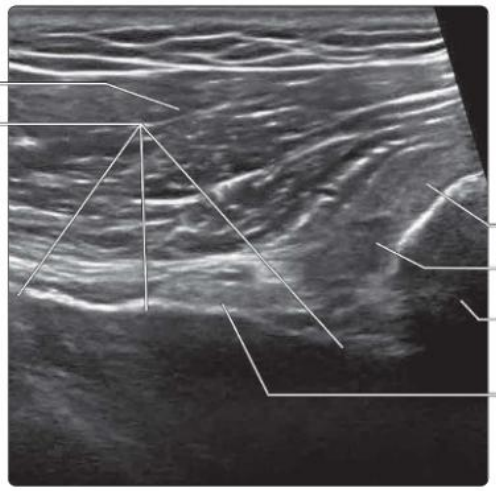

(Top) *Transverse US of the posterior aspect of the hip shows the superior gemellus, which is attached to the obturator externus tendon. Both tendons insert into the medial aspect of the greater trochanter.* **(Middle)** *Transverse US slightly more caudad to the previous image shows the obturator gemellus inferior muscle extending between the pelvis and the greater trochanter.* **(Bottom)** *Transverse US slightly more caudal to the previous image shows the quadratus femoris muscle, which is interposed between the lesser trochanter and the ischial tuberosity. The quadratus femoris tendon inserts onto the intertrochanteric crest at the posterior aspect of the proximal femur.*

PEDIATRIC HIP

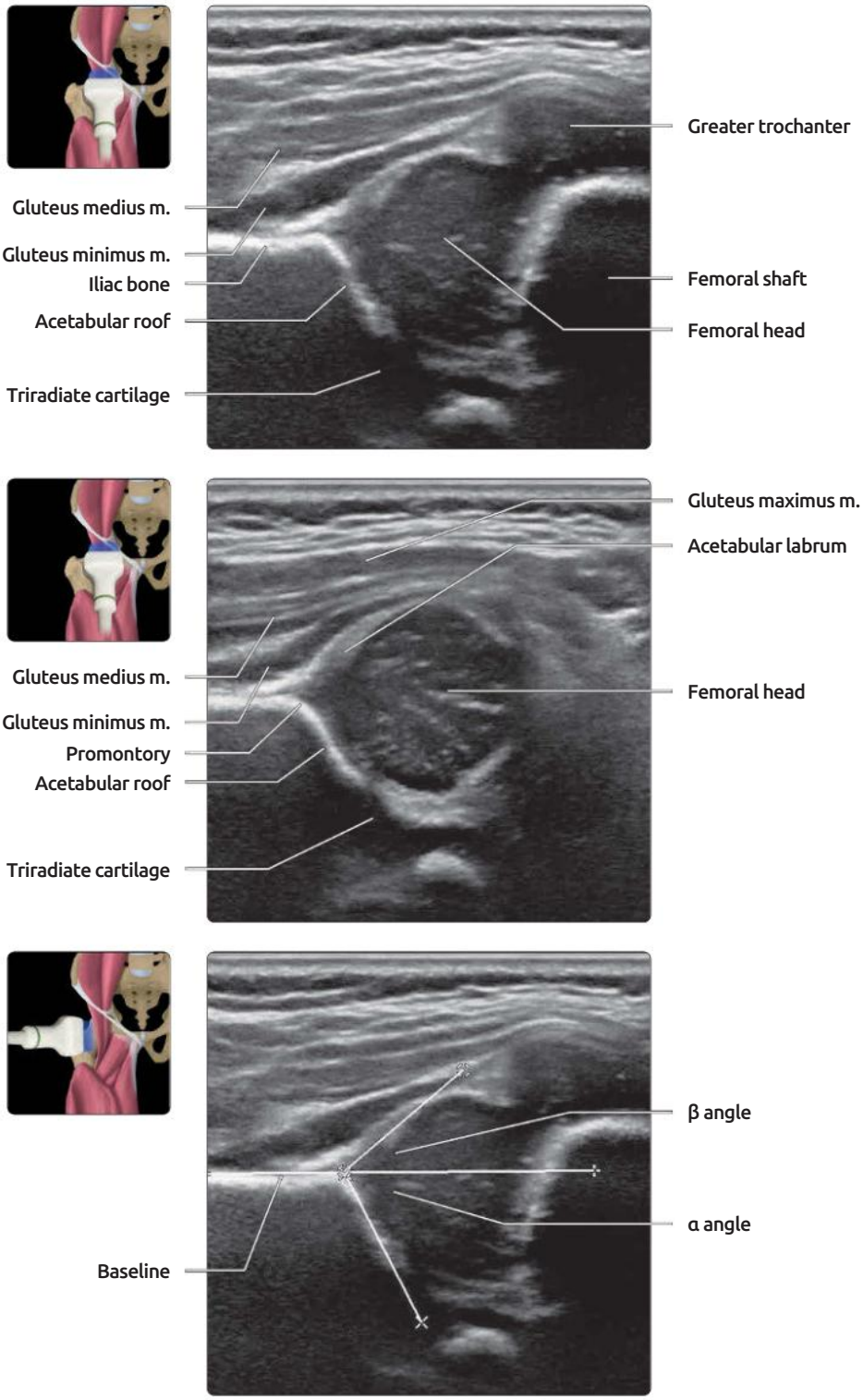

(Top) *Longitudinal US of the pediatric hip shows the unossified femoral head, neck, and trochanteric region.* **(Middle)** *Transverse US shows the transverse section of the unossified pediatric femoral head, which is likened to an ice-cream on a cone appearance.* **(Bottom)** *Longitudinal US shows the lines drawn for measurement of α and β angles to assess hip maturity. The baseline is drawn along the anterior cortex of the iliac bone. A line drawn from the promontory along the acetabular roof defines the α angle. A line drawn from the promontory to the tip of the labra defines the β angle.*

PEDIATRIC HIP

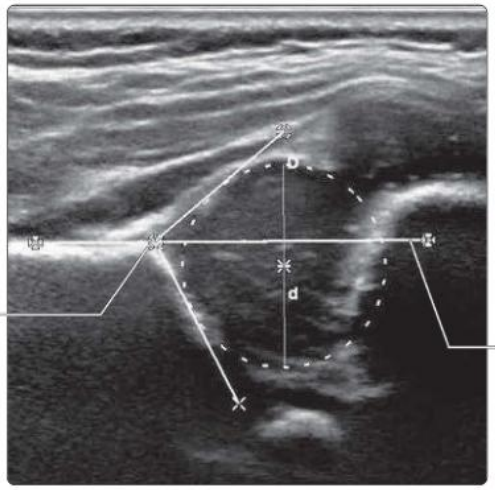

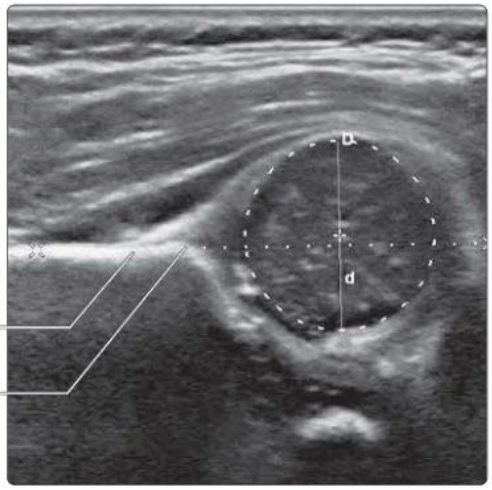

(Top) *Longitudinal US shows a best-fit circle drawn around the femoral head to help measure femoral head bony coverage. The proportion of the femoral head contained within the acetabulum is calculated by dividing the depth (d) of the femoral head below the baseline by the diameter (D) of the femoral head. In normal hips, at least 50% of the femoral head is covered by the acetabulum. Inadequate bony coverage of the femoral head is a feature of developmental dysplasia of the hip.* **(Middle)** *Longitudinal US during stress testing shows mild subluxation of the femoral head with reduced bony acetabular coverage. Less than 50% of the femoral head has bony coverage. In this young infant, this represents physiologic immaturity and laxity. The degree of acetabular bony coverage on stress testing will usually increase on repeat scanning in ~ 3-4 weeks as the hip joint matures and physiologic laxity decreases.* **(Bottom)** *Longitudinal US of a 4-month-old child shows a small area of ossification in the central aspect of the femoral head, indicating early femoral head maturation.*

TERMINOLOGY

Abbreviations

- Origin (O), insertion (I), function (F)

IMAGING ANATOMY

Compartment Anatomy

- **Compartmental anatomy is different from functional groupings**
- Thigh divided into anterior, medial, & posterior compartments
  - **Anterior compartment**: Iliotibial (IT) tract, tensor fascia lata (TFL) muscle, quadriceps muscles, sartorius muscle
  - **Medial compartment**: Gracilis muscle, adductor muscles
  - **Posterior compartment**: Hamstring muscles
- Additional muscles at junction of pelvis/thigh
  - Pectineus, iliopsoas, obturator externus, lateral femoral muscles
- Extensions from fascia lata divide compartments
  - Medial intermuscular septum separates anterior from medial compartment
  - Lateral intermuscular septum separates anterior from lateral compartment
  - Thin fascia separates medial from posterior compartment
- Compartment anatomy relevant to tumor staging & biopsy planning
  - When performing percutaneous biopsy, try not to cross between affected & nonaffected compartment

Medial Compartment Muscles

- Anterior muscles: Adductor longus & brevis, gracilis muscles
- Posterior muscles: Adductor magnus muscle
- Common function: Hip adduction; assist hip flexion, internal rotation
  - Obturator externus: Hip external rotation only
  - Gracilis also assists knee flexion
- **Adductor brevis**
  - O: Inferior pubic ramus
  - I: Inferior 2/3 of pectineal line, superior 1/2 of medial lip of linea aspera
- **Adductor longus**
  - O: Pubic body inferior to crest
  - I: Medial lip of linea aspera
- **Adductor magnus**: 2 separate muscles with different innervations & functions
  - Adductor portion
    - O: Ischiopubic ramus
    - I: Gluteal tuberosity, medial lip of linea aspera, medial supracondylar line
  - Ischiocondylar portion of adductor magnus (part of posterior compartment)
    - Adductor hiatus between 2 divisions of muscle in distal thigh
- **Gracilis**
  - O: Inferior pubic ramus, symphysis pubis
  - I: Medial proximal tibia (pes anserinus)
- **Obturator externus**
  - O: External margins of obturator foramen membrane
  - I: Piriformis fossa
- **Pectineus**
  - O: Superior pubic ramus, pecten
  - I: Pectineal line of femur

Anterior Compartment Muscles

- Common function: Knee extension
  - Sartorius: Hip flexion, abduction, external rotation; knee flexion
- **Quadriceps femoris**: Rectus femoris, vastus lateralis, vastus medialis, vastus intermedius muscles
  - Common tendon of insertion onto superior, lateral, medial patella
- **Rectus femoris**
  - O: Straight head = anterior inferior iliac spine; reflected head = groove above acetabulum
  - I: Superior patella, tibial tuberosity
  - F: Also hip flexion
    - Crosses 2 joints
- **Vastus lateralis**
  - O: Superior intertrochanteric line of femur, anterior & inferior greater trochanter, gluteal tuberosity, lateral lip of linea aspera, lateral intermuscular septum
  - I: Lateral tibial condyle (lateral patellar retinaculum), superolateral patella (quadriceps tendon)
    - Largest quadriceps muscle
- **Vastus medialis**
  - O: Entire medial lip of linea aspera, inferior intertrochanteric line, medial intermuscular septum
  - I: Tendon of rectus femoris muscle, superomedial patella (quadriceps tendon), medial condyle tibia (medial patellar retinaculum)
- **Vastus intermedius**
  - O: Anterior & lateral femoral shaft, inferior lateral lip of linea aspera, lateral intermuscular septum
  - I: Blends along deep aspect of rectus femoris, vastus medialis, vastus lateralis muscles
- **Sartorius**: Tailor's muscle
  - O: Anterior superior iliac spine, notch below
  - I: Proximal medial tibia (pes anserinus)
    - Crosses 2 joints
    - Longest muscle in body
- **TFL muscle**
  - O: Tubercle iliac crest
  - I: IT tract at level of greater trochanter
  - **IT tract has 3 fascial layers**
  - Superficial fascial layer arises from ilium superficial to TFL muscle
  - Intermediate fascial layer arises from ilium deep to TFL muscle
    - Superficial & deep layers merge at lower border of TFL muscle akin to tendon of TFL
  - Deep fascial layer arises from supraacetabular fossa between hip capsule & reflected tendon of rectus femoris
    - Merges with superficial & intermediate layers at lower border of TFL muscle
  - Proximally, IT tract receives fibers from gluteus maximus & gluteal aponeurotic fascia
  - In midportion, IT tract inserts to linea aspera of femur via lateral intermuscular septum

- Distally, IT tract inserts to anterior aspect of lateral tubercle of tibia (Gerdy tubercle)

Posterior Compartment Muscles

- Common functions: Hip extension, knee flexion
  - Biceps femoris also externally rotates flexed knee
  - Semimembranosus & semitendinosus also internally rotate flexed knee
- **Hamstrings**: Long head of biceps femoris, semimembranosus, semitendinosus, ischiocondylar portion of adductor magnus muscle
  - Does not include short head of biceps femoris muscle
  - Semimembranosus tendon arises from lateral facet of ischial tuberosity
  - Long head of biceps femoris tendon & semitendinosus arise from medial facet with the semitendinosus also arising from ischial tuberosity medial to conjoint tendon
- **Pes anserinus**
  - Common aponeurosis for insertion of gracilis, semitendinosus, sartorius tendons
  - Pes anserinus bursa between tendons & tibia
- **Biceps femoris**
  - Long head O: Ischial tuberosity (inferior, medial)
    - Common tendon with semitendinosus muscle
  - Short head O: Lateral lip of linea aspera femur, lateral supracondylar line, lateral intermuscular septum
    - Not part of hamstring muscles
  - I: Fibular head, lateral condyle tibia
- **Semimembranosus**
  - O: Ischial tuberosity (superior, lateral)
  - I: Posterior medial condyle tibia, popliteal fascia
    - Membranous in upper thigh
    - 5 insertional limbs distally
- **Semitendinosus**
  - O: Ischial tuberosity (inferior, medial)
    - Common tendon of long head of biceps femoris muscle
  - I: Medial proximal tibia (pes anserinus)
    - Entirely tendinous in distal thigh
- **Ischiocondylar portion of adductor magnus**
  - O: Ischial tuberosity
  - I: Adductor tubercle
    - Medial-most aspect of adductor magnus muscle

Hip Flexors

- **Iliopsoas** I: Lesser trochanter
  - Iliacus
    - O: Iliac crest, iliac fossa, sacral ala, sacroiliac joint capsule
  - Psoas major
    - O: Lateral vertebral body & intervertebral discs T12-L5, all lumbar transverse processes
  - Psoas minor
    - O: Lateral vertebral body T12, L1, & T12-L1 intervertebral disc
- Sartorius & pectineus

Femoral Triangle

- Superior border: Inguinal ligament
- Lateral border: Sartorius muscle
- Medial border: Adductor longus muscle
- Floor: Adductor longus & pectineus muscles (medial), iliopsoas muscle (lateral)
- Apex: Crossing of adductor longus & sartorius muscles
- Roof: Fascia lata
- Contents: Femoral nerve & branches, femoral vessels, lymph node (node of Cloquet), femoral sheath
  - Structures medial to lateral at entrance
    - Mnemonic is VAN: **V**ein, **a**rtery, **n**erve
- Femoral artery/vein relationships
  - Entrance: Artery lateral
  - Apex: Artery anterior
- Femoral nerve branches within triangle
  - Saphenous nerve & nerve to vastus medialis are only branches to exit triangle
- **Femoral sheath**: Transversalis fascia covers vessels proximally
  - 3 compartments
    - Medial: Lymph node (femoral canal)
    - Middle: Vein
    - Lateral: Artery
- **Femoral canal**: Medial compartment of femoral sheath
  - Anterior border: Inguinal ligament
  - Posterior border: Pubic bone
  - Medial border: Lacunar ligament
  - Lateral border: Femoral vein
  - Entrance: **Femoral ring**
    - Anterior border: Medial inguinal ligament
    - Posterior border: Superior pubic ramus
    - Medial border: Lacunar ligament
    - Lateral border: Femoral vein
    - Open to peritoneal cavity
  - Contents: Lymphatic vessels & nodes (node of Cloquet), fat, connective tissue
    - Groin nodes divided into superficial & deep groups
    - Superficial nodes are situated around superficial veins
    - Deep nodes lie medial to femoral vein
    - Node of Cloquet in most medial of deep group; located medial to femoral vein at femoral triangle
      - Large oblong node with prominent fatty hilum
  - **Femoral hernia**
    - Lie lateral & distal to pubic tubercle
    - Deep & distal to inguinal ligament
    - Hernia travels in femoral ring to femoral canal to saphenous opening to subcutaneous tissue

Adductor (Subsartorial or Hunter) Canal

- Fascial passageway for vessels in midthigh
  - Boundaries are fascial surfaces of adjacent muscles
- Anteromedial border: Sartorius muscle
- Anterolateral border: Vastus medialis muscle
- Posterior border: Adductor longus & magnus muscles
- Entrance: Apex femoral triangle
- Exit: **Adductor hiatus**
  - Gap adductor magnus muscle between adductor portion & ischiocondylar portion of distal thigh
- Vessel passageway from thigh to popliteal fossa
- Contents: Femoral artery & vein, saphenous nerve
  - Nerve initially anterior to artery, then medial
  - Artery anterior to vein
  - Descending geniculate artery arises in canal

AXIAL ANATOMY, THIGH

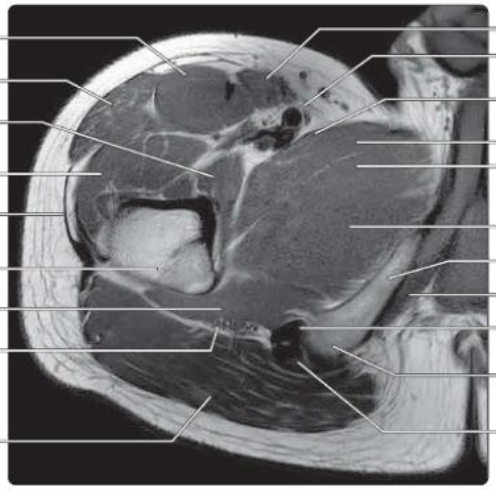

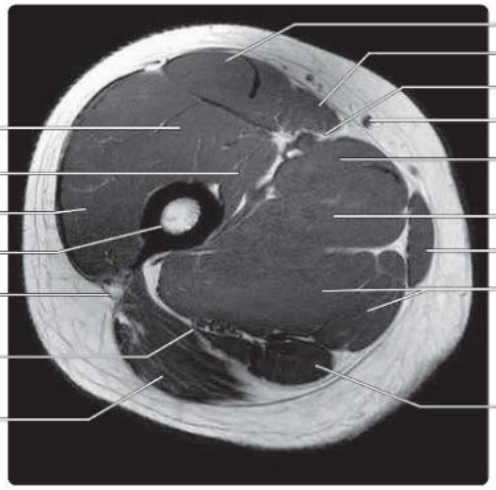

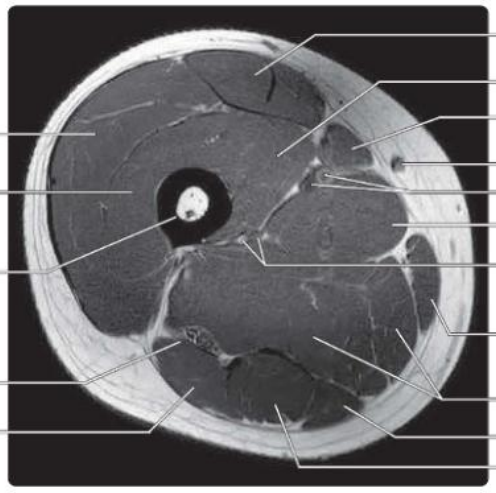

(Top) *Axial T1 MR of the thigh at the level of the lesser trochanter is shown.* **(Middle)** *Axial T1 MR of the thigh just below the lesser trochanter of the femur is shown. The saphenous nerve travels with the superficial femoral artery until the adductor hiatus (split in distal part of adductor magnus muscle). At this juncture, it leaves the superficial femoral neurovascular bundle to run on the medial aspect of the knee deep to the saphenous nerve.* **(Bottom)** *Axial T1 MR of the proximal to midthigh is shown. The sciatic nerve runs deep to the biceps femoris muscle.*

AXIAL ANATOMY, THIGH

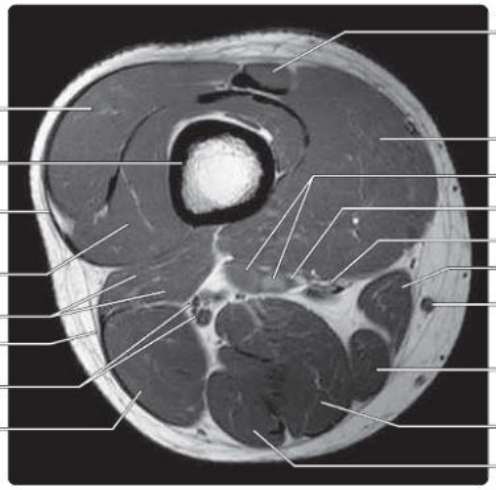

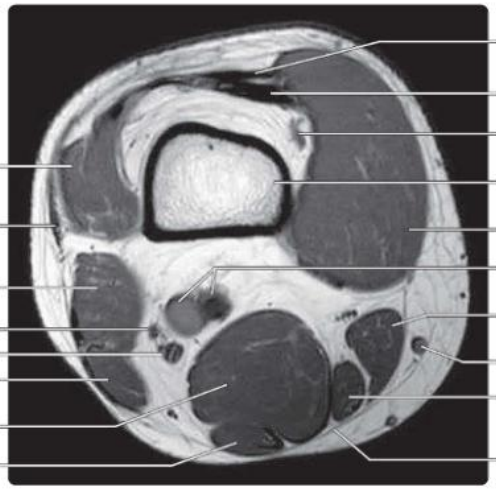

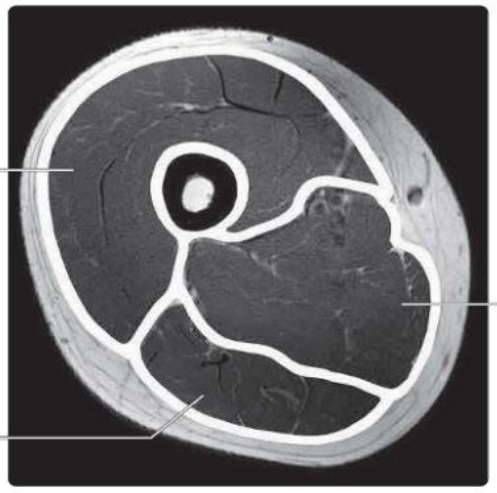

(Top) *Axial T1 MR of the mid to distal thigh is shown. The medial and posterior neurovascular bundles align quite closely together at the posterior aspect of the mid to distal thigh.* **(Middle)** *Axial T1 MR of the distal thigh is shown. The sciatic nerve has divided into the tibial nerve and common peroneal nerve branches. The common peroneal nerve will run deep to the biceps femoris muscle toward the proximal fibula.* **(Bottom)** *Axial T1 MR shows the 3 compartments of the thigh, which are separated by intermuscular septa (not shown). The anterior compartment is composed of the iliotibial tract, tensor fascia lata, sartorius, vastus muscles, and the rectus femoris muscle. The medial compartment is composed of the adductor muscles and the gracilis muscle. The posterior compartment is composed of the biceps femoris, semimembranosus, and semitendinosus muscles.*

ANTERIOR THIGH

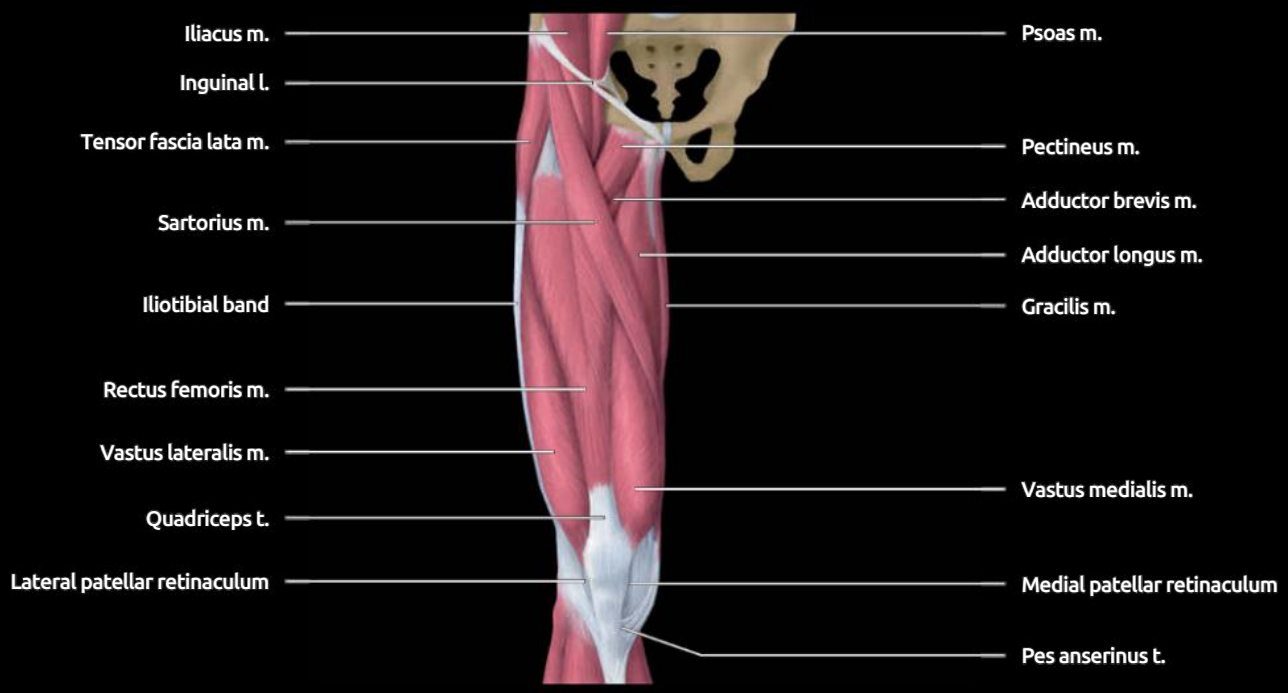

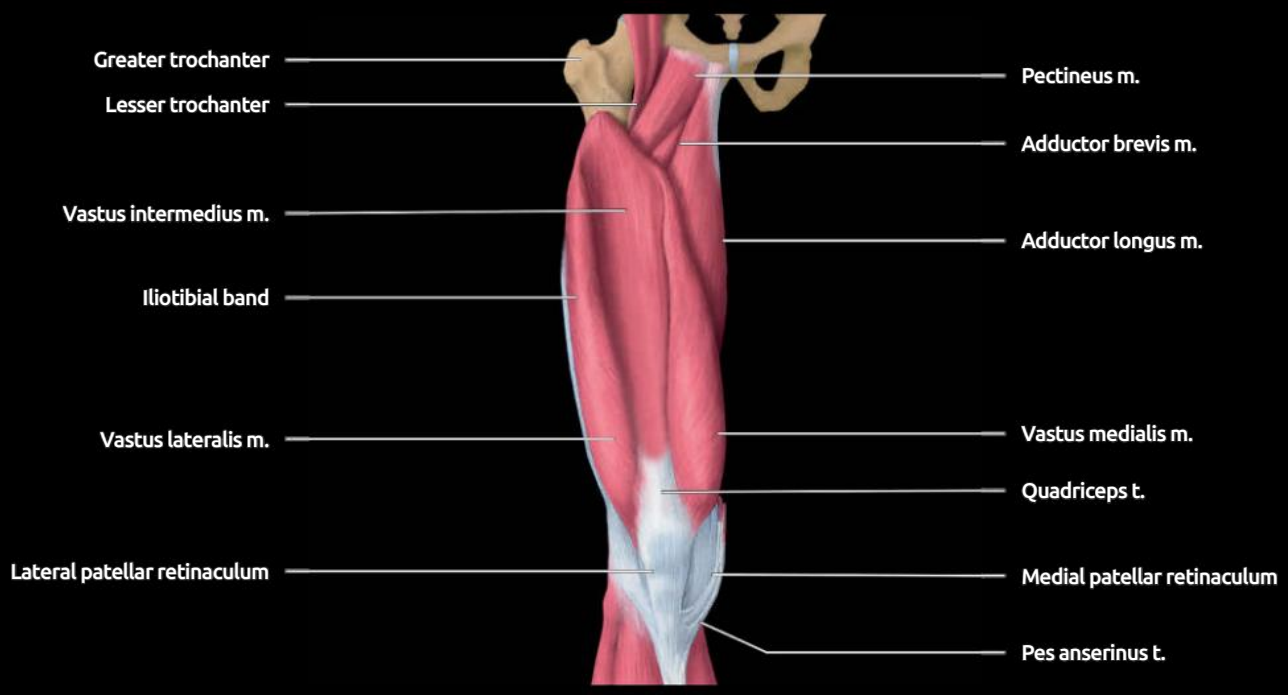

(Top) *Graphic shows the superficial anterior thigh muscles with the oblique course of the sartorius muscle being easily appreciated. The adductor brevis muscle is deep to the adductor longus and pectineus muscles. The most medial muscle is the vertically orientated gracilis muscle. The vastus lateralis and medialis muscles form the lateral and medial patellar retinacula, respectively, in addition to contributing to the quadriceps tendon.* **(Bottom)** *Graphic shows the deep muscles of the anterior thigh with the vastus intermedius muscle deep to the rectus femoris muscle. The vastus intermedius muscle tendon blends with the rectus femoris tendon along its deep surface. The iliopsoas muscle dives deeply after crossing over the pelvic brim. With removal of the sartorius muscle, a little more of the adductor brevis muscle is visible. The pes anserinus tendons (gracilis, sartorius, semitendinosus) have a conjoint insertion into the proximal tibia medially.*

ANTERIOR THIGH

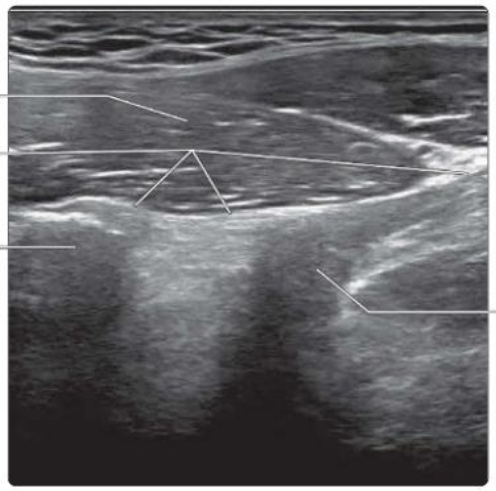

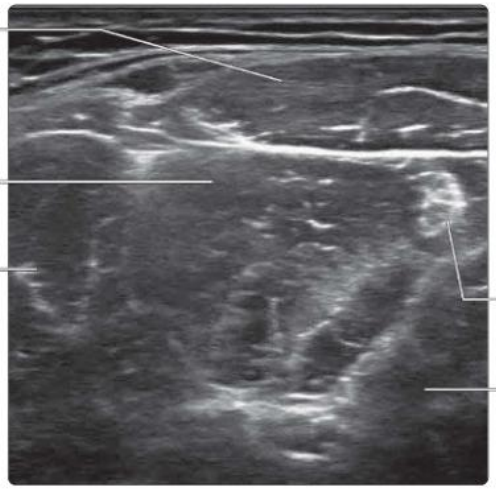

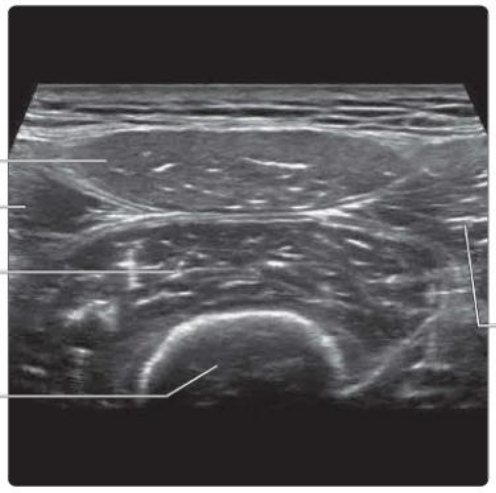

(Top) *Longitudinal US shows the direct head of the rectus femoris muscle attaching to the anterior inferior iliac spine. The deep connecting hypoechoic band is due to anisotropy from the merging indirect head of the rectus femoris tendon.* **(Middle)** *Transverse US shows the rectus femoris muscle deep to the sartorius muscle in the proximal thigh. The tendon of the rectus femoris is located on the medial aspect of the rectus femoris muscle bulk.* **(Bottom)** *Transverse US of the mid to distal thigh shows the 4 muscles of the quadratus femoris group, namely the rectus femoris, vastus intermedius, vastus lateralis, and vastus medialis muscles.*

ANTEROMEDIAL THIGH

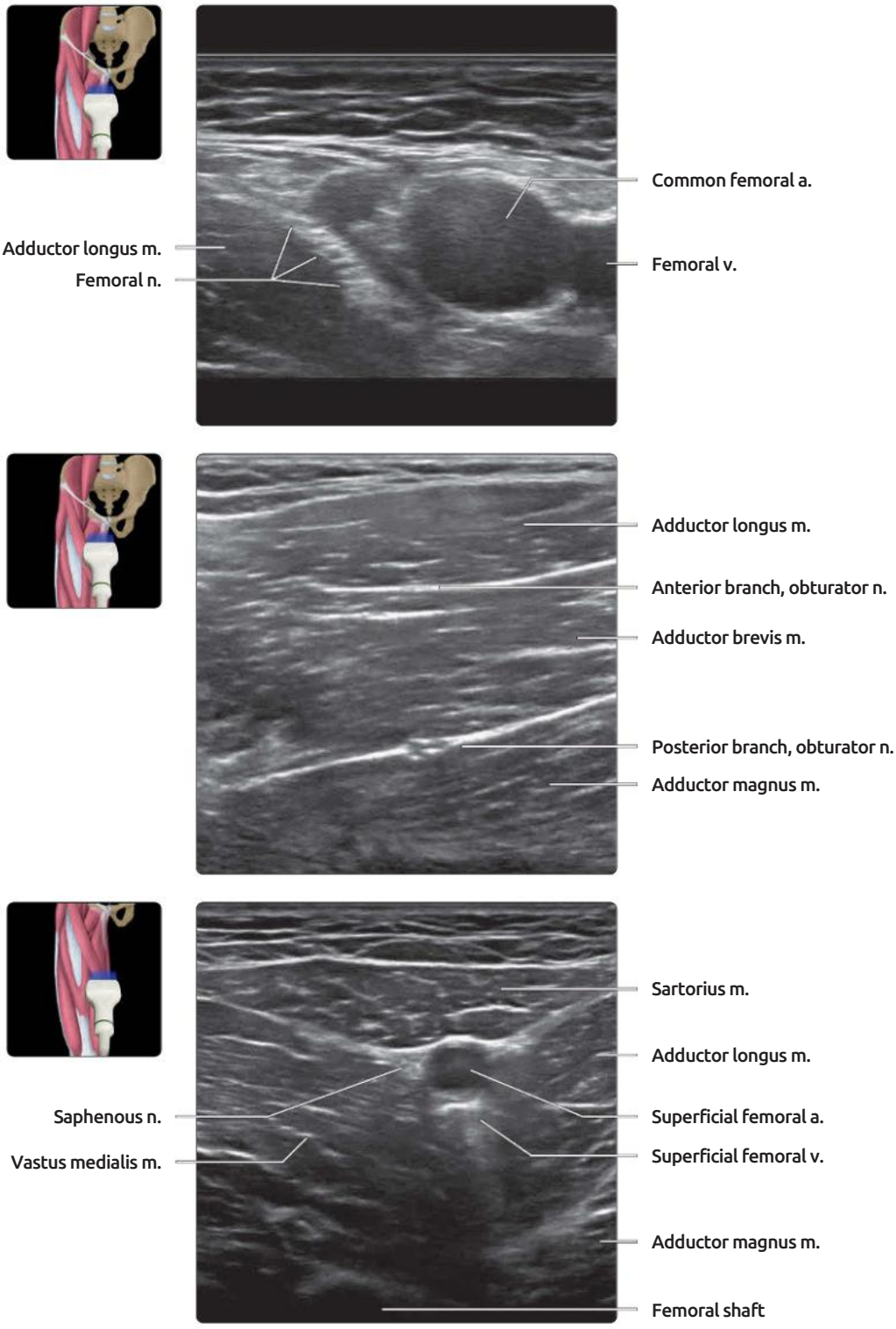

(Top) *Transverse US of the anteromedial aspect of the proximal thigh shows the femoral nerve inferolateral to the common femoral artery.* **(Middle)** *Transverse US of the anteromedial aspect of the proximal thigh shows the adductor longus, brevis, and magnus muscles. The anterior branch of the obturator nerve lies between the adductor longus and brevis muscles. The posterior branch of the obturator nerve lies between the adductor brevis and adductor magnus muscles.* **(Bottom)** *Transverse US of the anteromedial aspect of the mid to distal thigh shows the saphenous nerve alongside the superficial femoral artery. The superficial femoral vein is effaced by even mild transducer pressure.*

ANTEROLATERAL THIGH

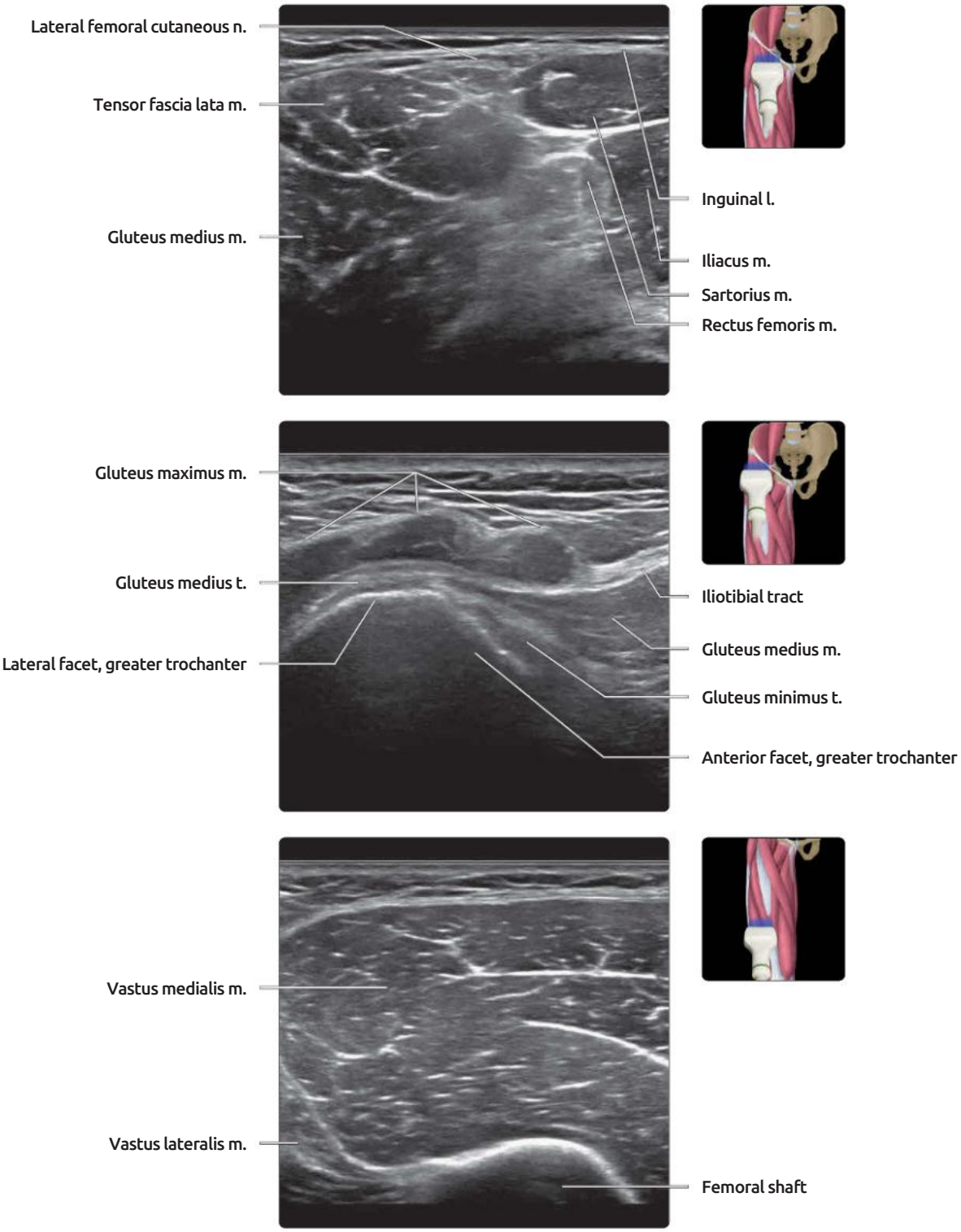

(Top) *Transverse US of the anterolateral aspect of the proximal thigh shows the muscles just below and distal to the inguinal ligament. The lateral femoral cutaneous nerve generally moves medially from the tensor fascia lata muscle/sartorius muscle interface to overlie the sartorius muscle as it divides into its terminal branches.* **(Middle)** *Transverse US shows the typical fireman's helmet configuration to the greater trochanter with the badge area anteriorly representing the anterior facet covered by the insertion of the gluteus minimus muscle. The gluteus medius tendon inserts into the lateral facet of the greater trochanter as well as into the posterosuperior facet (not shown). The lateral facet is covered by the iliotibial band/gluteus maximus muscle.* **(Bottom)** *Transverse US of the lateral aspect of the mid to distal leg shows the vastus medialis muscle, which extends around to the lateral aspect of the femoral shaft.*

MEDIAL AND POSTERIOR THIGH MUSCLES

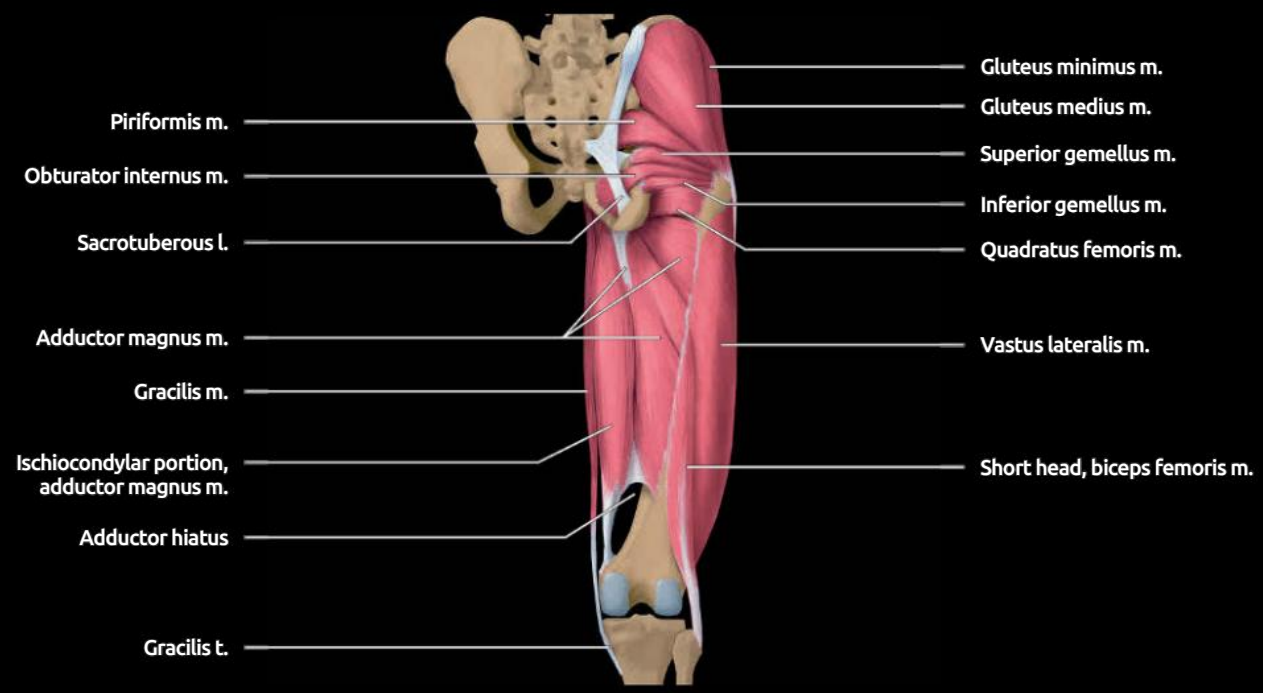

(Top) *Graphic of the medial muscles of the thigh shows how the gracilis muscle, which has a thin profile when viewed from the front, has a quite broad profile when viewed from the side. The semimembranosus muscle runs on the deep surface of the semitendinosus muscle and inserts onto the posteromedial aspect of the proximal tibia. Its insertion is hidden on this graphic. The iliopsoas muscle courses over the pelvic brim on its course to the lesser trochanter.* **(Bottom)** *Graphic shows the deep muscles of the posterior thigh with the hamstring and gluteus maximus muscles removed. The expansive adductor magnus muscle is visible. The muscle separates distally to form the adductor hiatus.*

MEDIAL THIGH

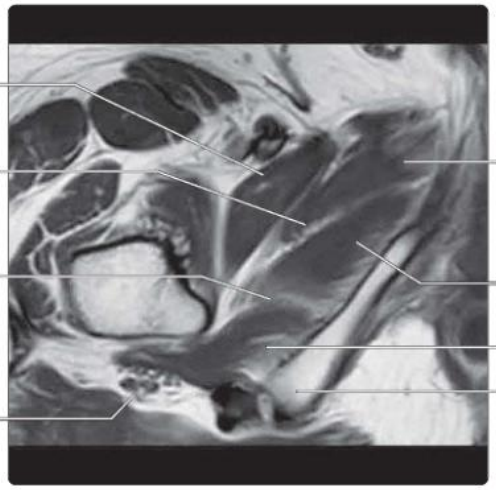

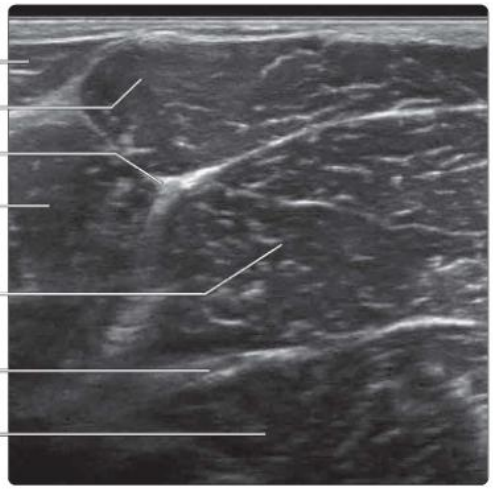

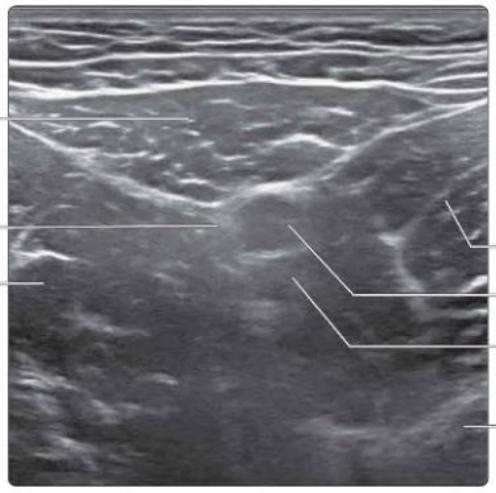

(Top) *Axial T1 MR shows the adductor musculature at the proximal end of the thigh medially. The adductor longus, brevis, and magnus muscles are aligned at almost right angles to the inferior pubic ramus.* **(Middle)** *Transverse US shows corresponding appearances to previous MR images with the adductor longus, brevis, and magnus muscles aligned. The anterior and posterior branches of the obturator nerve lie anterior and posterior to the adductor brevis muscle, respectively.* **(Bottom)** *Transverse US of the medial aspect of the distal leg shows the saphenous nerve alongside the superficial femoral artery. The superficial femoral neurovascular bundle lies deep to the sartorius muscle along nearly all of the thigh from proximal to distal.*

POSTERIOR THIGH

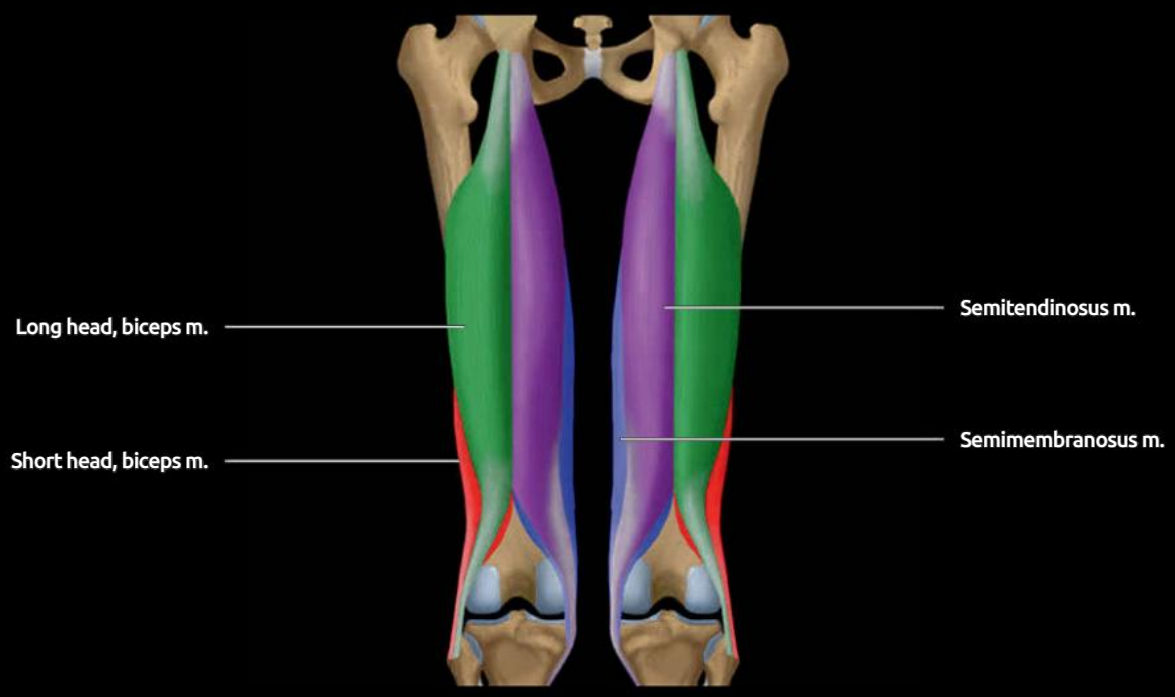

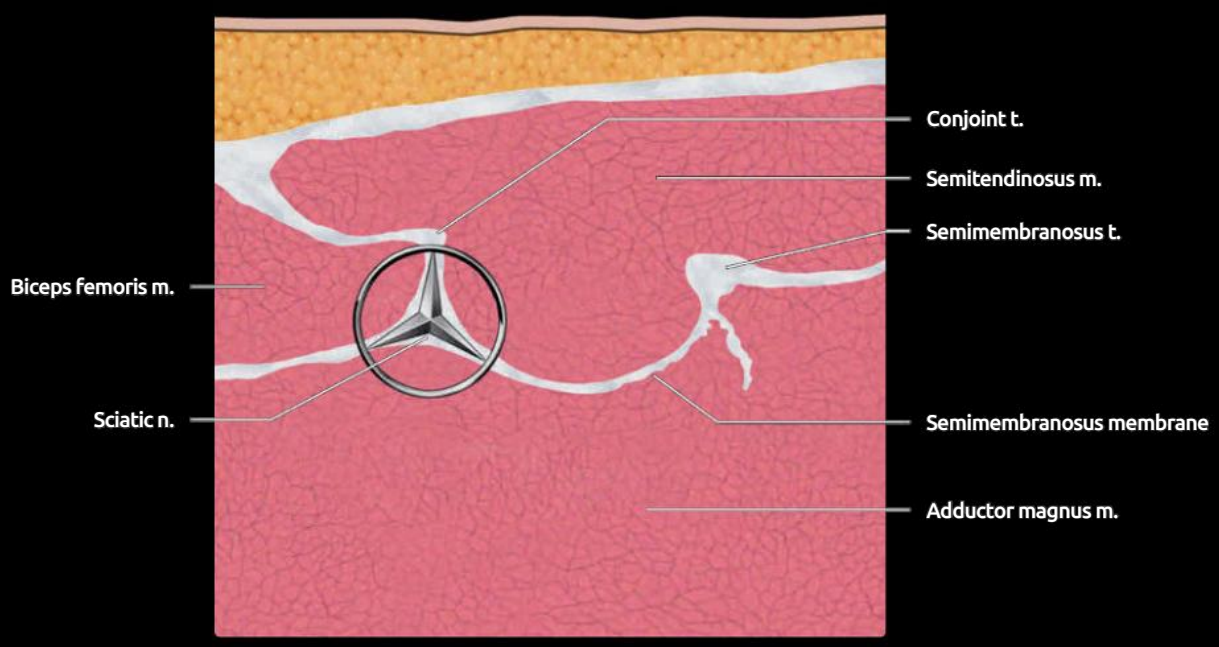

(Top) *Graphic shows the balanced configuration of the hamstring muscles with the semitendinosus and semimembranosus muscles on the posteromedial side of the leg counterbalancing the biceps femoris (long and short heads) on the lateral aspect of the posterior thigh. Semimembranosus muscle generally lies deep to the semitendinosus muscle while the short head of biceps muscle lies deep to the long head of biceps muscle.* **(Bottom)** *Graphic shows the Mercedes configuration formed by the conjoint biceps femoris-semitendinosus tendon, the sciatic nerve, and the semimembranosus membrane. The sciatic nerve lies just deep to the conjoint tendon of the biceps femoris muscle laterally and the semitendinosus muscle medially. Extending medially from the sciatic nerve is the hyperechoic semimembranosus membrane, which attaches to the semimembranosus tendon more medially. The semimembranosus is largely membranous in the upper thigh.*

POSTERIOR THIGH

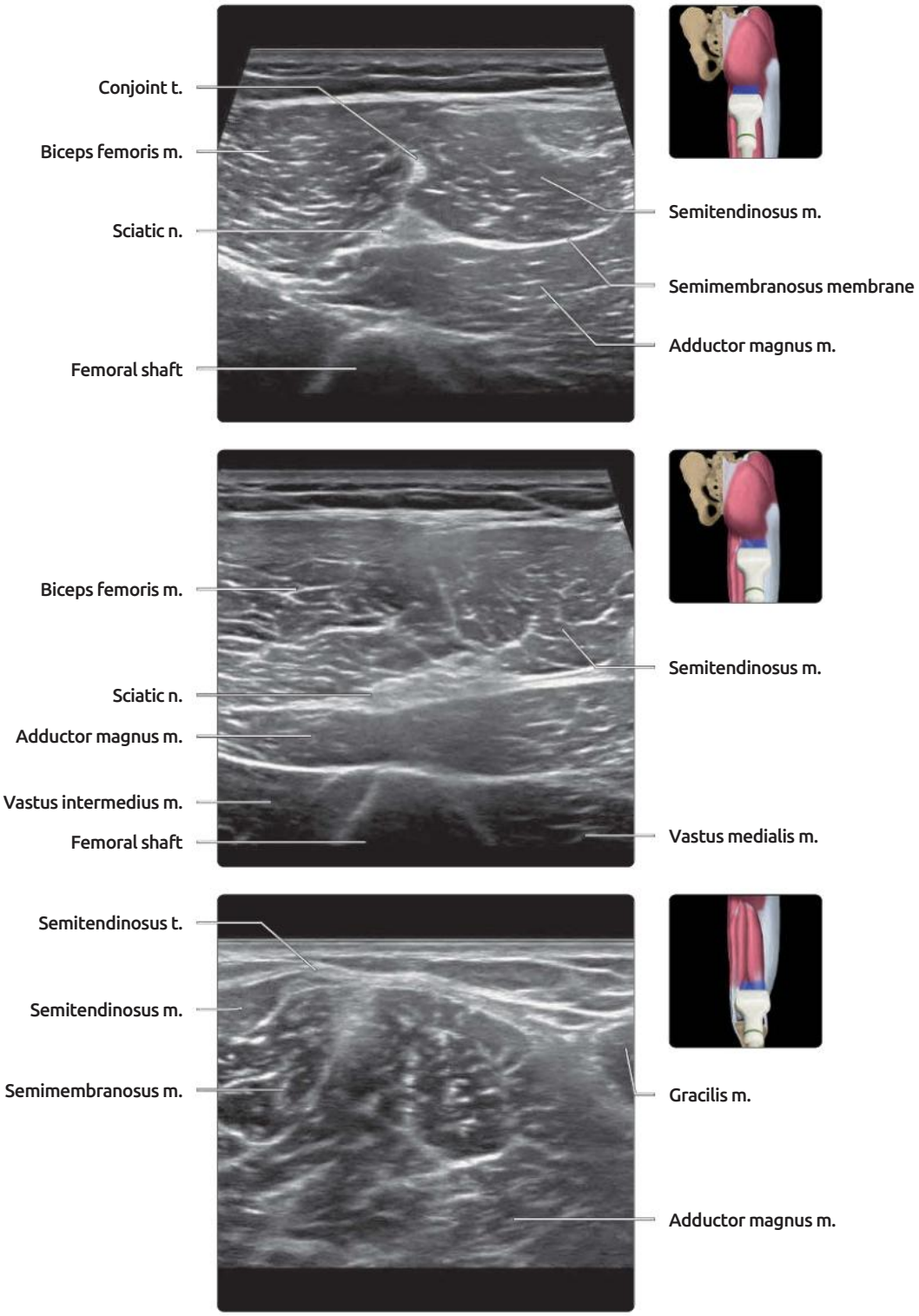

(Top) *Transverse US of the posterior thigh proximally shows the Mercedes configuration formed by the conjoint tendon of biceps femoris-semitendinosus, the sciatic nerve, and the semimembranosus membrane.* **(Middle)** *Transverse US of the posterior aspect of the proximal thigh shows the sciatic nerve lying deep to the biceps femoris muscle.* **(Bottom)** *Transverse US at the distal posterior aspect of thigh shows the semitendinosus tendon sitting on top of the semimembranosus muscle. This is known as the "cherry on a bun" appearance. The semimembranosus muscle is mainly aponeurotic at the proximal end of the thigh and bulky at the mid to distal end of the thigh. The reverse is true for the semitendinosus, which is mainly muscular proximally and tendinous distally.*

IMAGING ANATOMY

Arteries of Lower Limb

- Enter thigh deep to inguinal ligament midway between anterosuperior iliac spine & pubic symphysis
  - External iliac artery becomes common femoral artery
  - Vessels within femoral triangle
    - Vein, artery, nerve (VAN) from medial to lateral
- Adductor canal
  - 15-cm, triangular-shaped canal running from femoral triangle to adductor hiatus
    - Deep to sartorius muscle
  - At distal thigh, vessels pass from adductor canal through adductor hiatus to enter popliteal fossa
    - Adductor hiatus is gap between adductor magnus muscle & femoral shaft 10 cm proximal to knee
      - Saphenous nerve does not pass through adductor hiatus
    - Superficial femoral vessels become popliteal artery & vein
- **Common femoral artery**
  - Divides into superficial & deep branches
  - **Superficial femoral artery**
    - Main continuation of common femoral artery
    - Accompanied by saphenous nerve in thigh
  - **Deep femoral (profunda femoris) artery**
- **Popliteal artery**
  - Continuation of superficial femoral artery after it passes through adductor hiatus at distal end of adductor canal
  - Passes through fat of popliteal fossa where artery lies
    - Deep to vein in 40%
    - Deep & medial to vein in 40%
    - Deep & lateral to vein in 10%
    - Just medial or lateral to vein in 10%
  - Gives off for genicular branches around knee
    - Superomedial & lateral geniculate arteries
    - Inferomedial & lateral geniculate arteries
  - At distal end of popliteus muscle, divides into 2 branches
    - Anterior tibial artery
    - Tibioperoneal trunk
- **Anterior tibial artery**
  - Smaller of 2 terminal branches of popliteal artery
  - Original line is in posterior aspect of leg at distal border of popliteus muscle
  - Passes through upper part of interosseous membrane
  - Passes straight down along front of leg to become dorsalis pedis artery
  - Runs on interosseous membrane, deep to extensor muscles
- **Tibioperoneal trunk**
  - Larger of 2 terminal branches of popliteal artery
  - After short distance, divides into posterior tibial & peroneal arteries
- **Posterior tibial artery**
  - Main arterial supply to foot
  - Passes distally & slightly medially along with tibial nerve
  - Divides into medial & lateral plantar arteries in tarsal tunnel behind medial malleolus
- **Peroneal artery**
  - Runs obliquely downward & laterally deep to soleus muscle
  - Descends deep to flexor pollicis longus muscle

Veins of Lower Limb

- Paired venae comitantes follow corresponding arteries
- Much greater developmental variation exists in venous system compared to arterial system
- Veins of lower limb comprise superficial & deep veins
  - Superficial veins lie superficial to crural fascia
  - Deep veins lie deep to crural fascia
- Perforating veins traverse crural fascia to connect superficial & deep veins
- Communicating veins connect veins within same venous compartment, either deep to deep or superficial to superficial
- Deep veins drain muscular system
- Superficial veins drain subcutaneous tissues & skin
- **Deep veins**
  - **Superficial femoral, profunda femoris, & common femoral veins**
    - Follow corresponding arteries
  - **Popliteal vein**
    - Runs superficial to popliteal artery
    - Usually originates at inferior border of popliteus muscle from union of anterior & posterior tibial veins
    - Crosses from medial to lateral side of popliteal artery as it ascends in popliteal fossa
    - Becomes superficial femoral vein at adductor hiatus
    - Receives short saphenous vein in popliteal fossa
  - **Anterior tibial, posterior tibial, & peroneal veins**
    - Follow corresponding arteries
  - **Median & lateral plantar veins**
    - Arise from plantar venous arch to accompany medial & lateral plantar arteries
    - Median & lateral plantar veins form posterior tibial vein in tarsal tunnel & run proximally accompanying posterior tibial artery
  - **Plantar venous arch**
    - Receives venous drainage from dorsal & plantar aspects of forefoot
- **Superficial veins**
  - **Long saphenous vein**
    - Longest vein in body
    - Arises from medial part of dorsal venous arch of foot, passes anterior to medial malleolus, & ascends within subcutaneous tissues medial aspect of calf
      - Passes posteromedial to knee to medial aspect of proximal thigh, where it dives through cribriform fascia to join common femoral vein (saphenofemoral junction)
    - Accompanied by saphenous nerve in leg
  - **Short saphenous vein**
    - Arises from medial part of dorsal venous arch of foot, passes behind lateral malleolus, and ascends lateral to Achilles tendon
      - Accompanied by sural nerve at ankle region
      - At lower margin of popliteal fossa, pierces popliteal fascia & drains into popliteal vein

THIGH ARTERIES

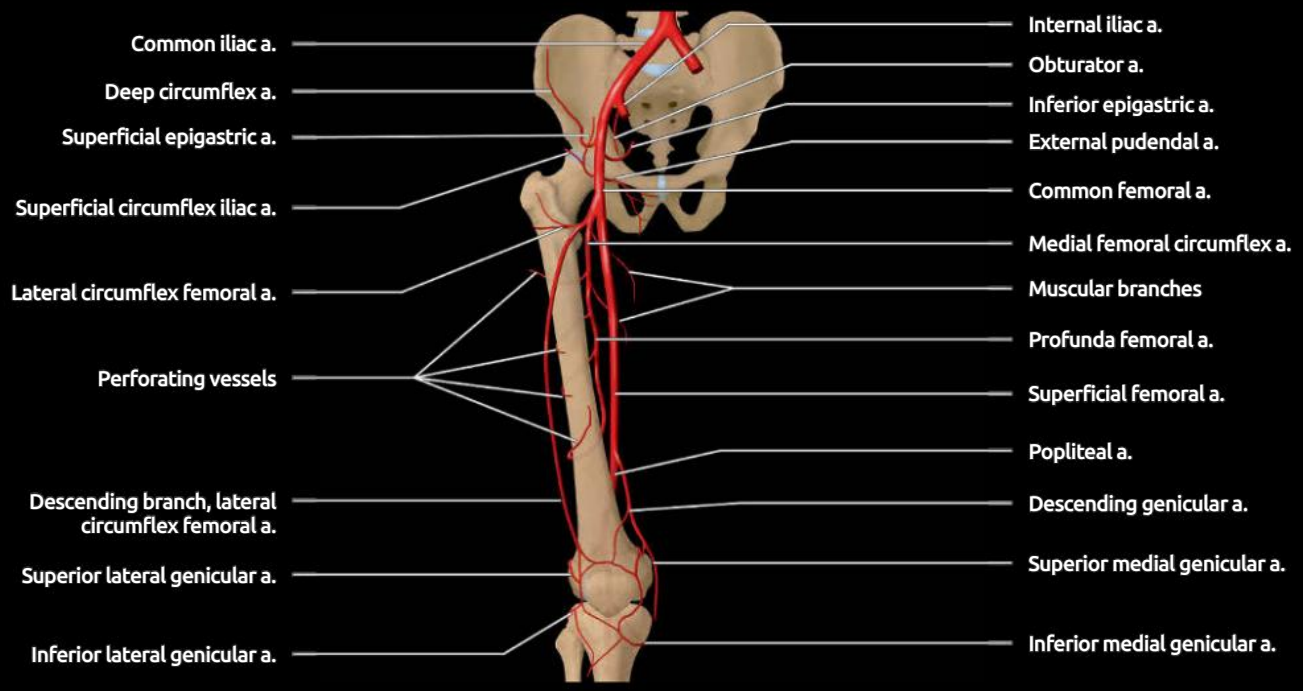

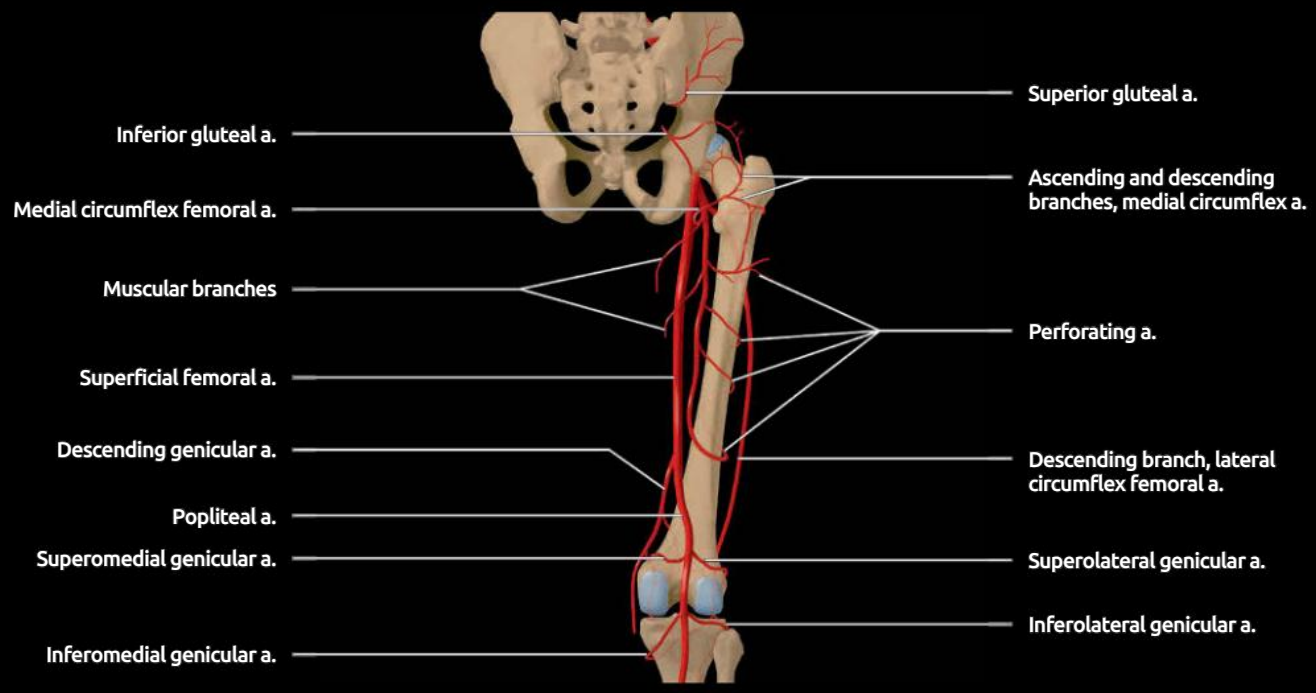

(Top) *Anterior view shows the external iliac, femoral, & popliteal arteries & their branches.* **(Bottom)** *Posterior view shows the femoral and popliteal arteries and the superior and inferior gluteal arteries of the greater sciatic notch. All of the main arteries and veins can be readily evaluated with US. CTA or MRA are the best investigations to provide an imaging roadmap of the main arteries in the lower limb. These investigations have replaced standard angiography in this respect. Standard DSA is still the best investigation to demonstrate the smaller arteries of the lower limb, such as those around the feet or hip.*

THIGH VEINS

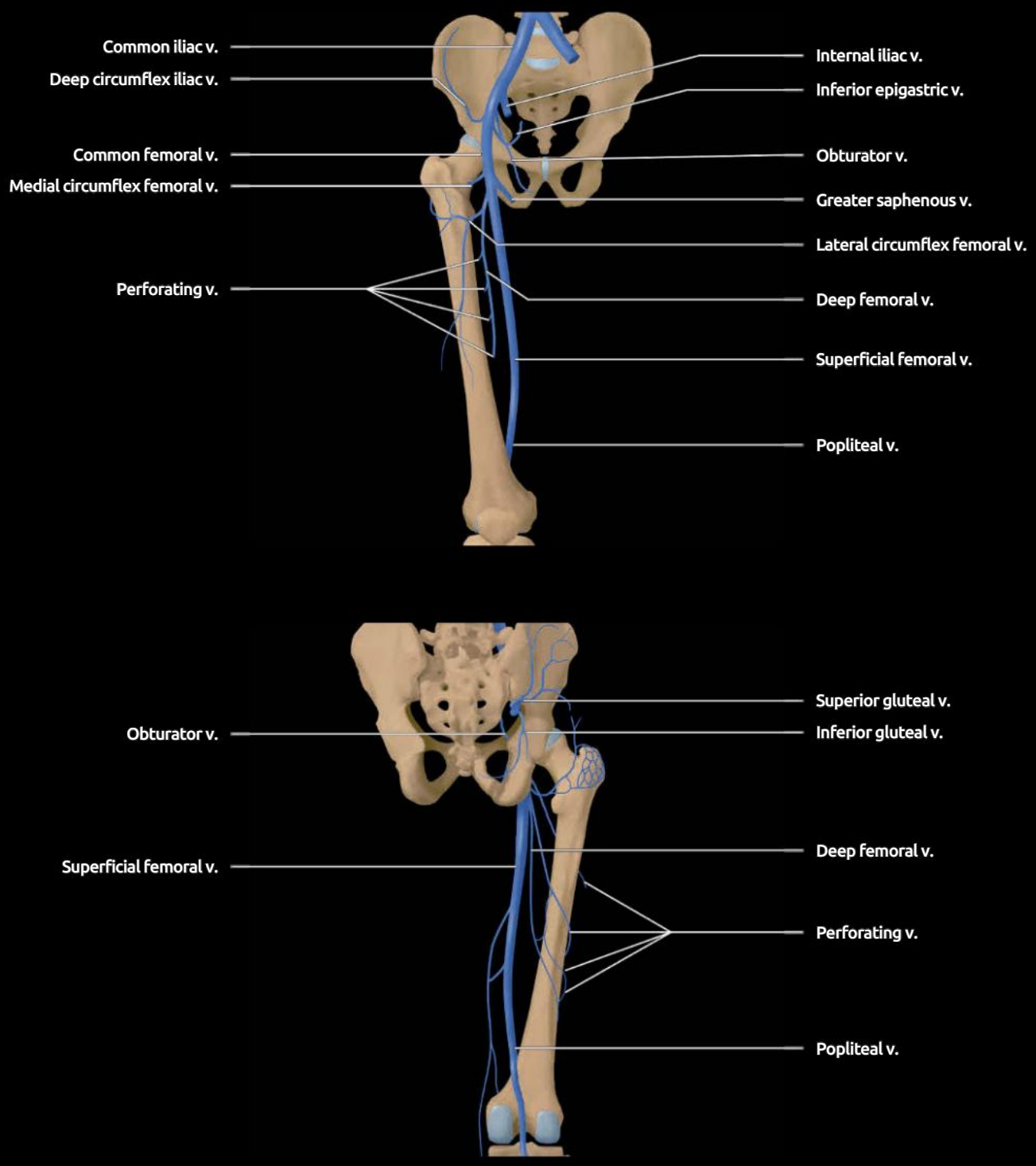

(Top) *Anterior view shows the veins of the thigh. The veins typically follow the arterial tree. The main venous drainage is the superficial femoral vein, which is actually a deep venous structure. Note the entrance of the greater saphenous vein into the femoral vein; the saphenous venous system has no accompanying artery.* **(Bottom)** *Posterior view shows the veins of the thigh and buttocks. The veins generally follow the arterial tree, although more variability is seen within the venous system.*

THIGH, COMMON FEMORAL VESSELS

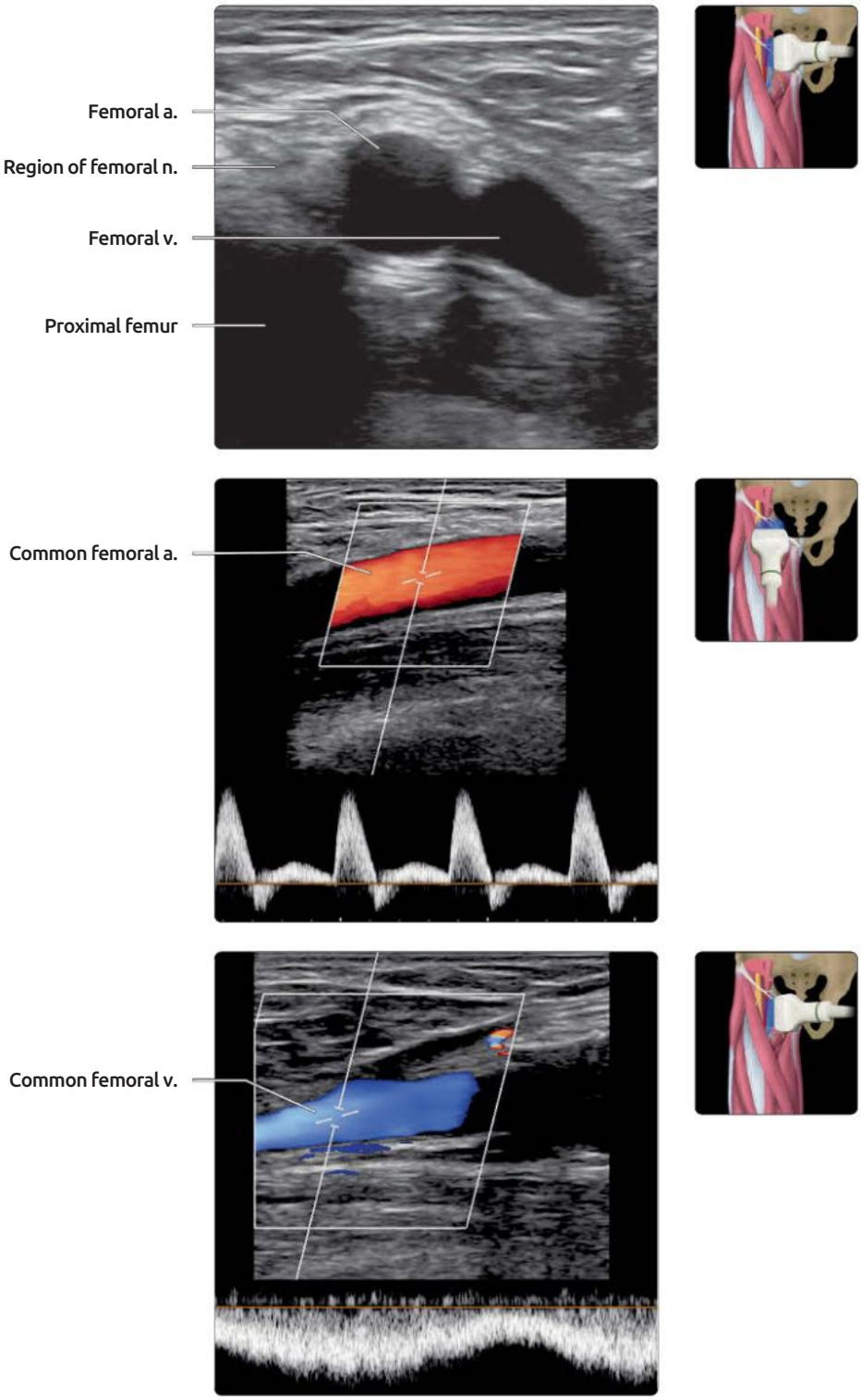

(Top) *Transverse US of the groin region shows the femoral artery and vein after emerging from underneath the inguinal ligament. The arrangement from medial to lateral is vein, artery, nerve (VAN).* **(Middle)** *Longitudinal color and spectral Doppler US shows the typical triphasic arterial waveform in the common femoral artery. This triphasic waveform comprises a forward sharp upstroke of forward (systolic) flow, followed by reverse flow (early diastolic), followed by slow forward flow (late diastolic).* **(Bottom)** *Longitudinal color and spectral Doppler US of the common femoral vein shows the typical biphasic venous waveform. Normal venous Doppler waveform is biphasic and varies with the phase of respiration. The flow velocity is much lower than that in the artery.*

THIGH, COMMON AND SUPERFICIAL FEMORAL VESSELS

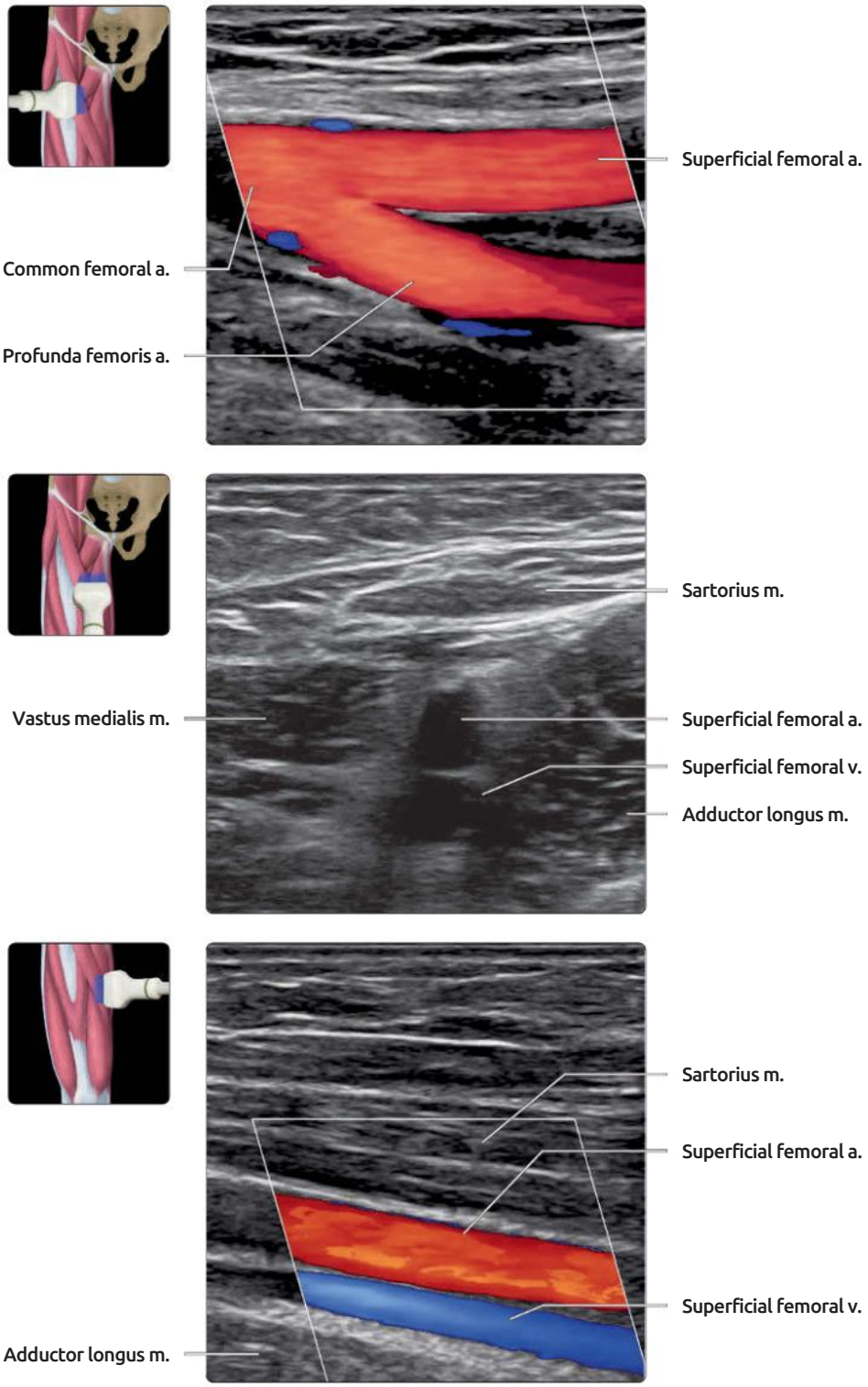

(Top) *Longitudinal color Doppler US shows the femoral bifurcation.* **(Middle)** *Transverse US of the anteromedial thigh shows the femoral vein lying deep to the femoral artery.* **(Bottom)** *Longitudinal color Doppler US shows normal flow in the superficial femoral artery and vein.*

THIGH, SUPERFICIAL FEMORAL ARTERY AND VEIN

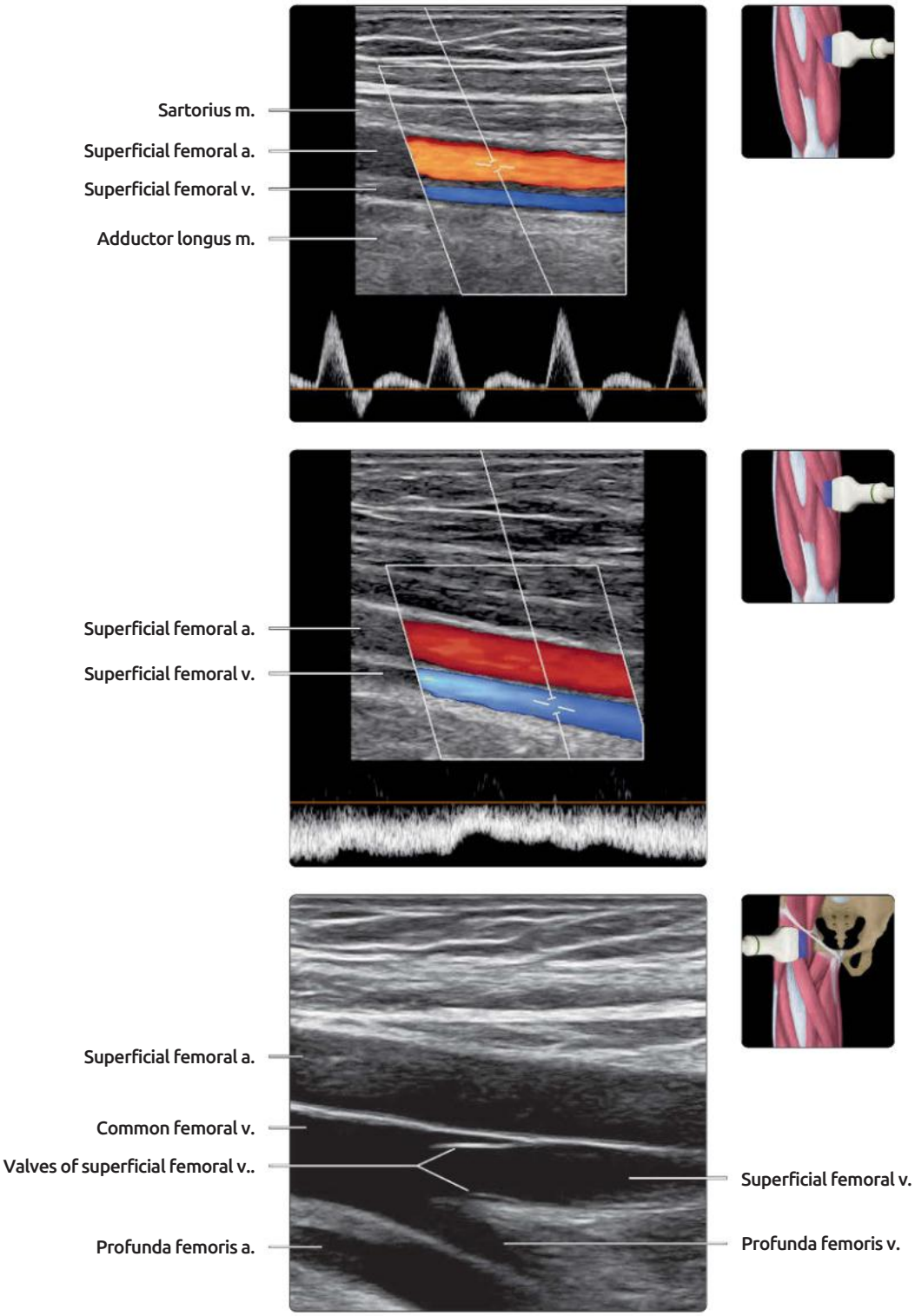

(Top) *Longitudinal color and spectral Doppler US shows normal triphasic waveform within the superficial femoral artery. In general, as one moves further away from the heart, peak systolic velocity will decrease.* **(Middle)** *Longitudinal color and spectral Doppler US of the superficial femoral vein shows normal biphasic venous waveform, varying with respiration. In general, as one moves further away from the heart, the effect of respiration on venous waveform lessens.* **(Bottom)** *Longitudinal US shows the confluence of the common femoral vein. The common femoral vein is formed by the superficial femoral vein and the profunda femoral vein, both accompanying the course of the corresponding arteries.*

THIGH, SAPHENOFEMORAL VENOUS JUNCTION

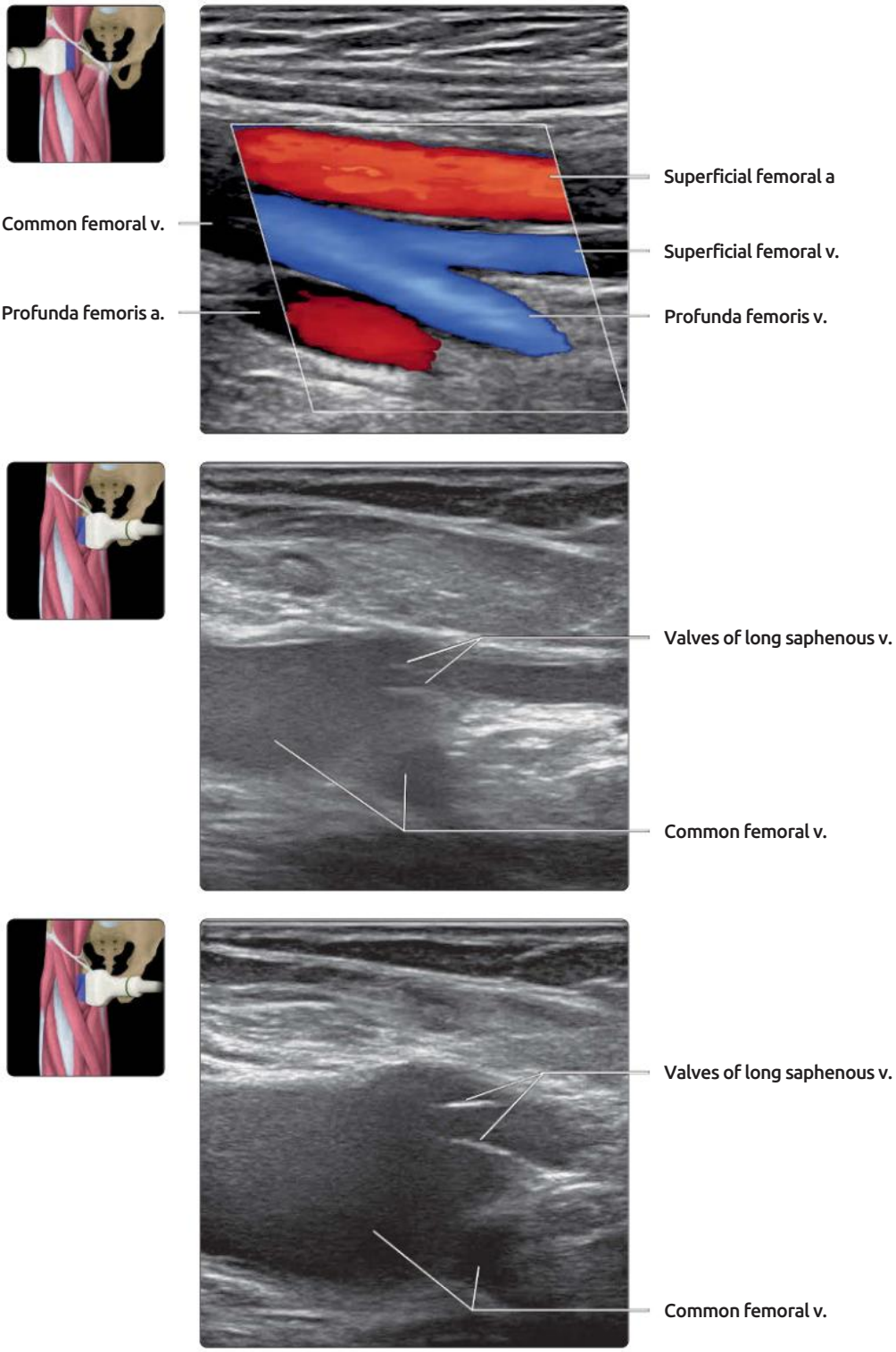

(Top) *Longitudinal color Doppler US shows the confluence of the common femoral vein with the accompanying arteries.* **(Middle)** *Longitudinal US of the saphenofemoral junction shows the long saphenous vein entering the common femoral vein. The valve of the common femoral vein in visible.* **(Bottom)** *Longitudinal US of the saphenofemoral junction during Valsalva maneuver is shown. With Valsalva, the common femoral vein has moderately distended while the long saphenous has mildly distended. This mild degree of distention of the long saphenous vein with Valsalva is acceptable. Saphenofemoral incompetence is shown by reversal of color Doppler US flow within the long saphenous vein during Valsalva maneuver (not shown). Valvular movement at the saphenofemoral junction is not used to gauge valvular competence.*

POPLITEAL ARTERY

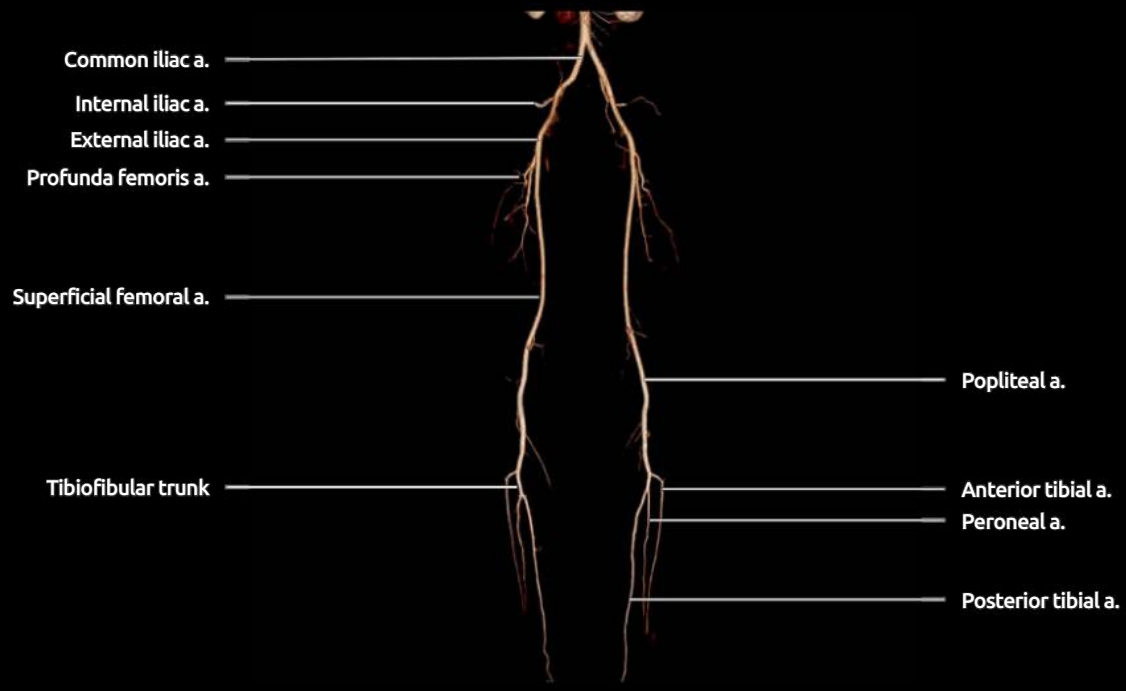

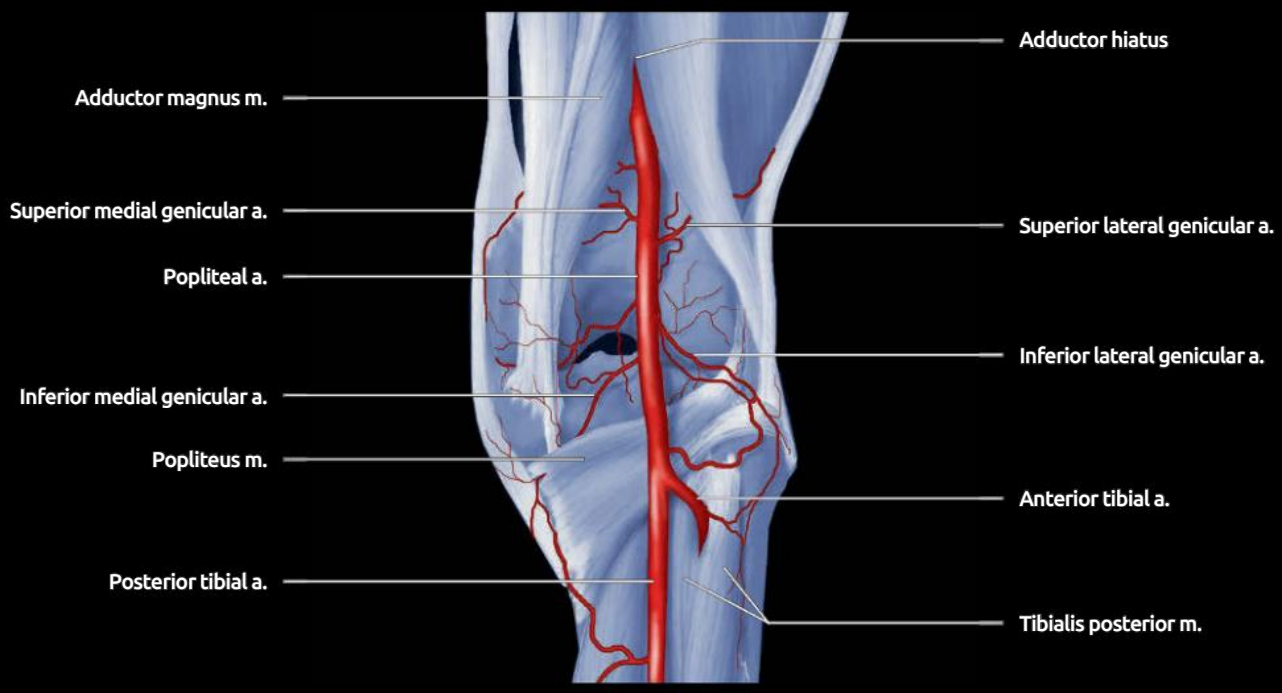

(Top) *CTA shows normal lower limb arteries. The attenuation of the anterior tibial and peroneal arteries is likely to be technical rather than pathological. This image is obtained by tracking a bolus of intravenous contrast, injected into an upper limb vein, as it passes through the arteries of the lower limb.* **(Bottom)** *Graphic shows the popliteal artery extending from the adductor hiatus in the adductor magnus muscle proximally to the lower border of the popliteus muscle distally. The popliteal artery gives rise to 4 geniculate arteries. The superior medial and lateral geniculate arteries pass around the femoral condyles. The inferior medial and lateral geniculate arteries pass around the tibial condyles. At the distal margin of the popliteal fossa, the popliteal artery bifurcates into anterior tibial and tibiofibular arteries. The anterior tibial artery is the smaller branch that extends through a slit in the tibialis posterior muscle and the interosseous membrane to descend along the anterior surface of the interosseous membrane.*

POPLITEAL ARTERY AND VEIN

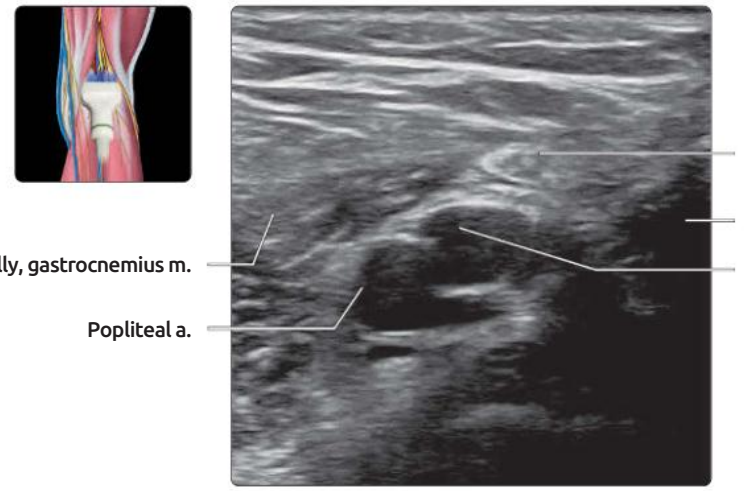

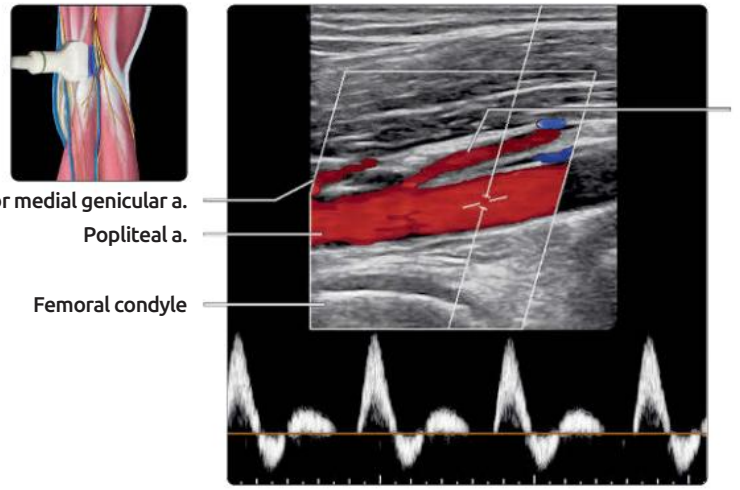

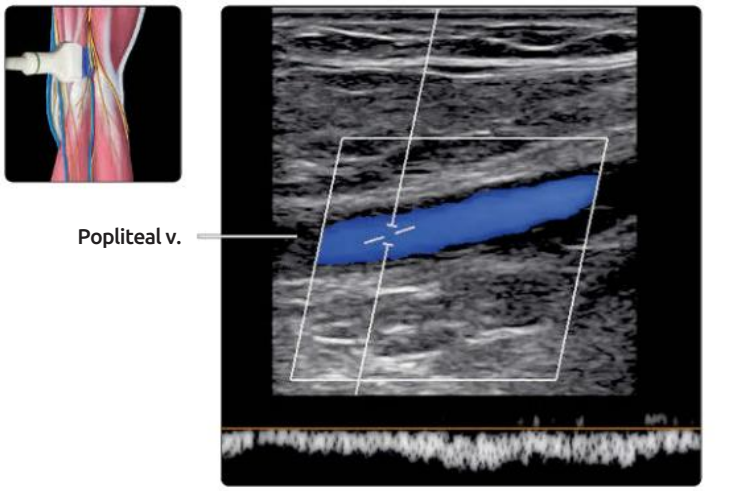

(Top) *Transverse US shows the tibial nerve, popliteal vein, and popliteal artery between the 2 heads of the gastrocnemius muscle. The popliteal vein always lies between the tibial nerve and the popliteal artery.* **(Middle)** *Longitudinal color Doppler US shows normal spectral arterial wave pattern of the popliteal artery. Geniculate branches are shown arising from the popliteal artery.* **(Bottom)** *Longitudinal spectral Doppler US shows normal phasic waveform of the popliteal vein.*

LEG ARTERIES

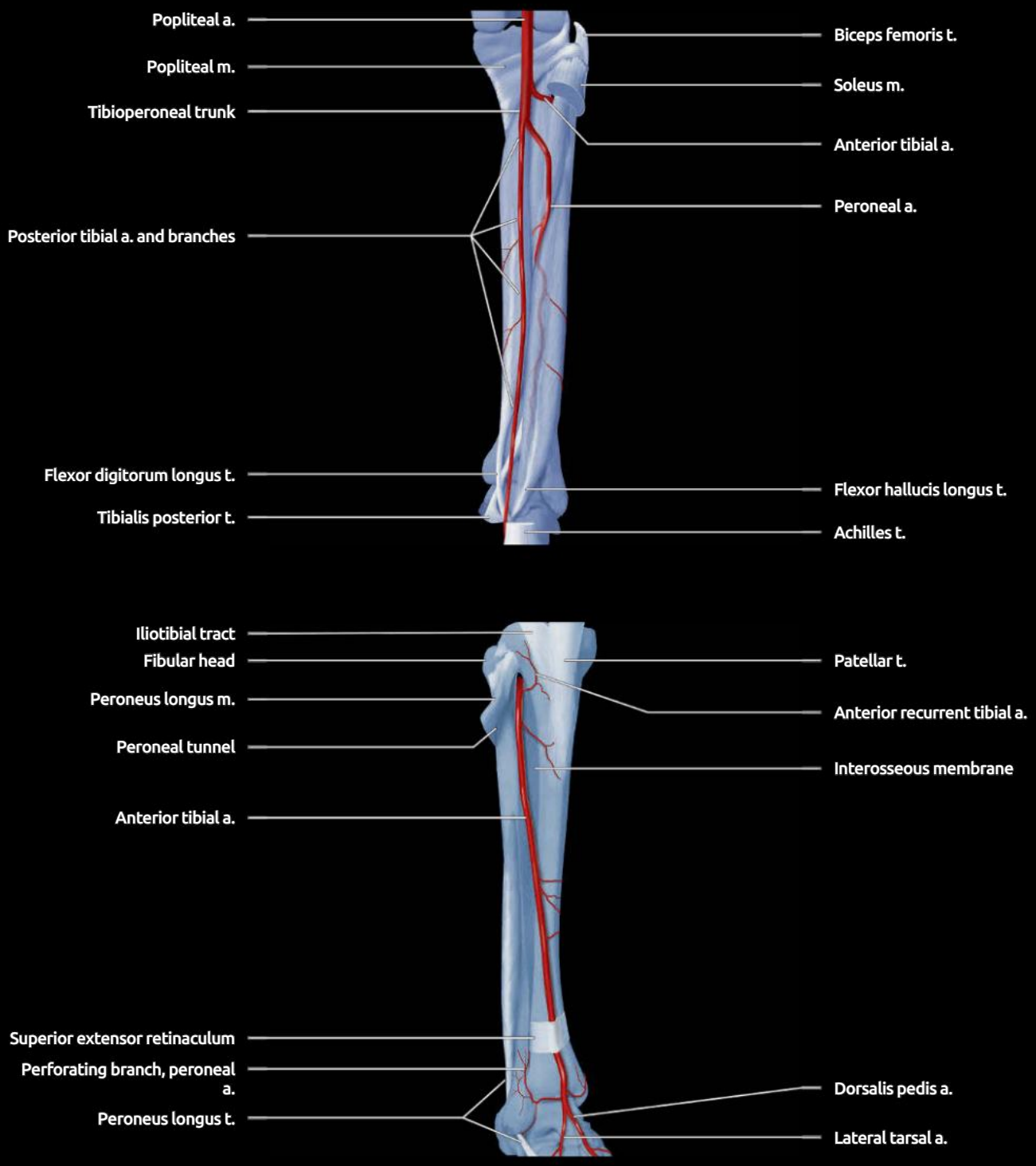

(Top) *Graphic of the posterior aspect of the leg shows the posterior tibial artery, which descends (with the tibial nerve) to the medial retromalleolar region. The tibioperoneal trunk is a direct communication of the popliteal artery distal to the origin of the anterior tibial artery. The tibioperoneal trunk bifurcates into the posterior tibial and peroneal arteries. The peroneal artery descends in the leg close to the fibula and deep to the soleus muscle.* **(Bottom)** *Graphic of the anterior aspect of the leg shows the anterior tibial artery perforating the interosseous membrane proximally and descending along the interosseous membrane down to the ankle to become the dorsalis pedis artery. Small collaterals can be appreciated between the leg arteries.*

LEG, ANTERIOR TIBIAL ARTERY

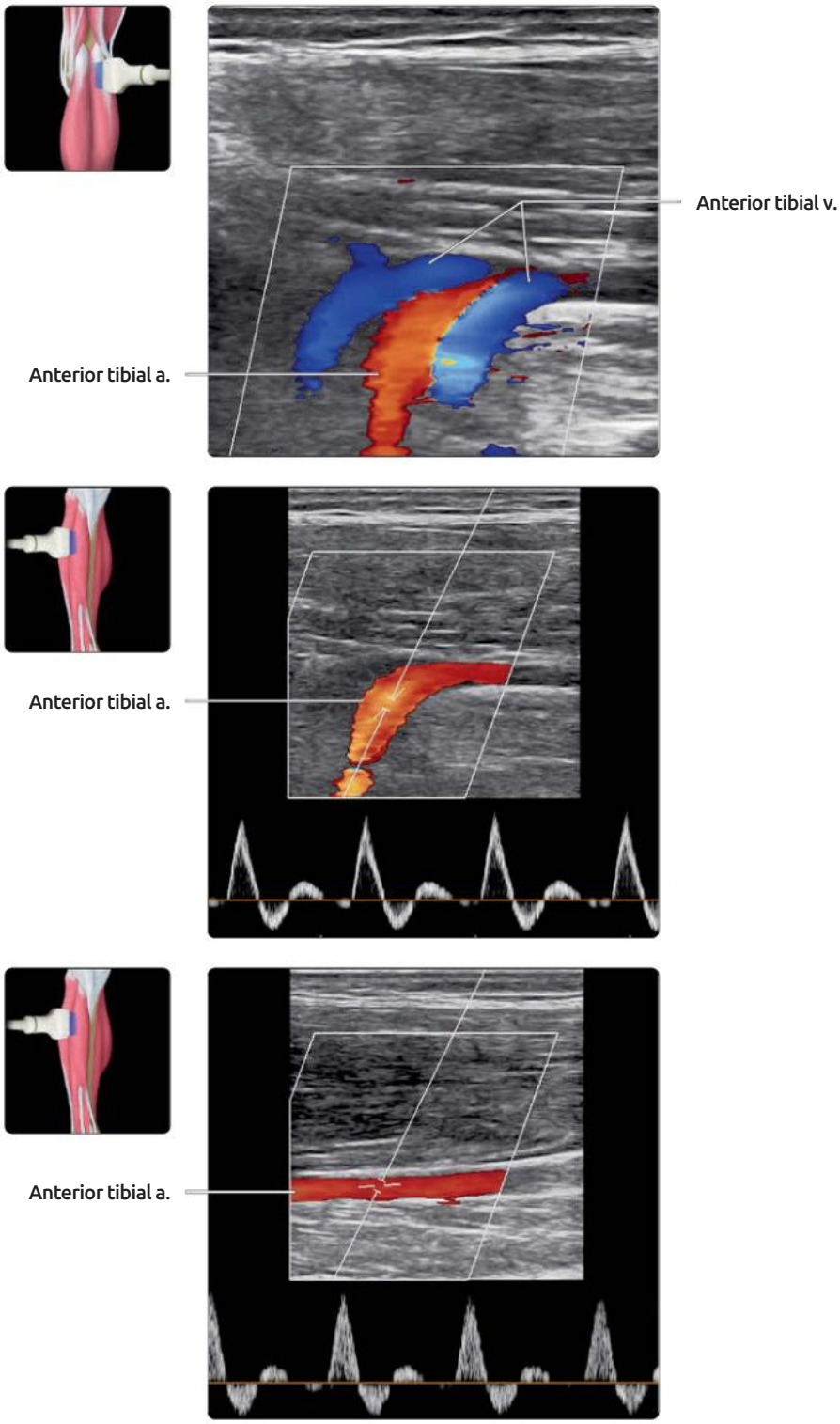

(Top) *Longitudinal color Doppler US shows the anterior tibial vessels as they branch from the popliteal vessels. The anterior tibial artery and paired anterior tibial veins pass anteriorly to penetrate the interosseous membrane and descend in the anterior compartment.* **(Middle)** *Longitudinal color and spectral Doppler US shows normal arterial wave pattern within the anterior tibial artery.* **(Bottom)** *Longitudinal color and spectral Doppler US of the anterior tibial artery shows a normal arterial triphasic waveform.*

LEG, PERONEAL ARTERY AND VEIN

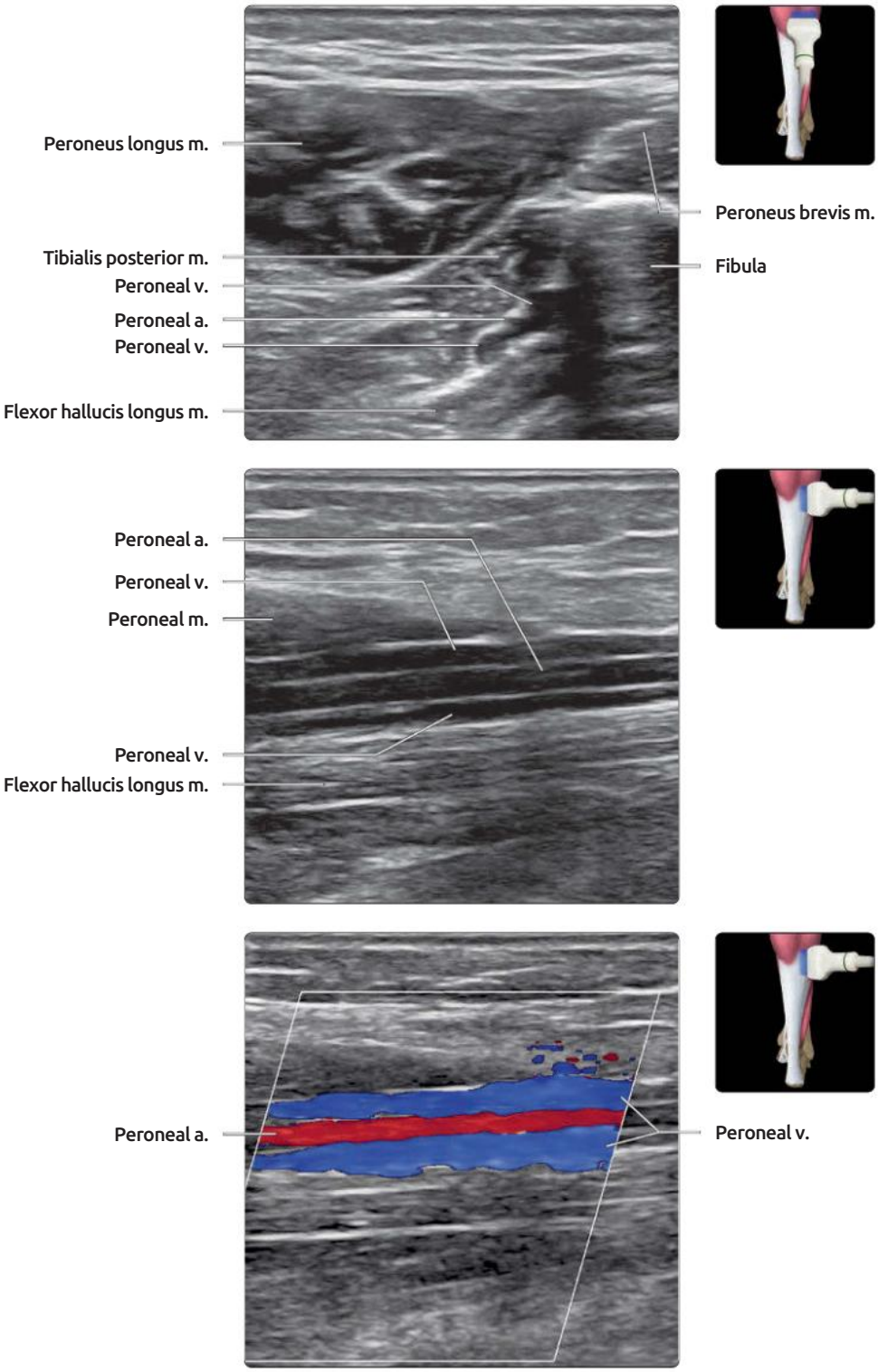

(Top) *Transverse US at the mid to distal leg shows the peroneal artery with 2 accompanying veins.* **(Middle)** *Longitudinal US shows the peroneal artery and accompanying veins in the lateral aspect of the posterior compartment of the mid to distal leg.* **(Bottom)** *Longitudinal color Doppler US shows flow in the peroneal artery and both accompanying veins.*

FOOT ARTERIES

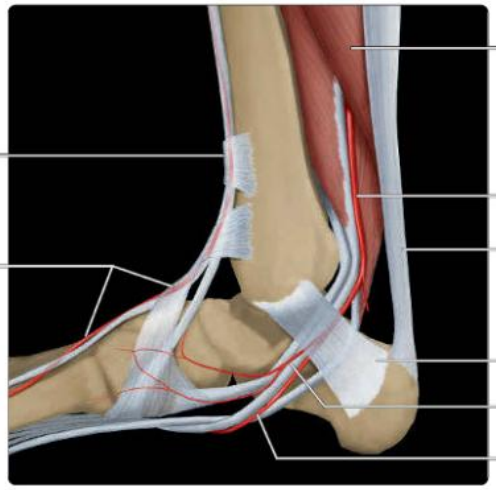

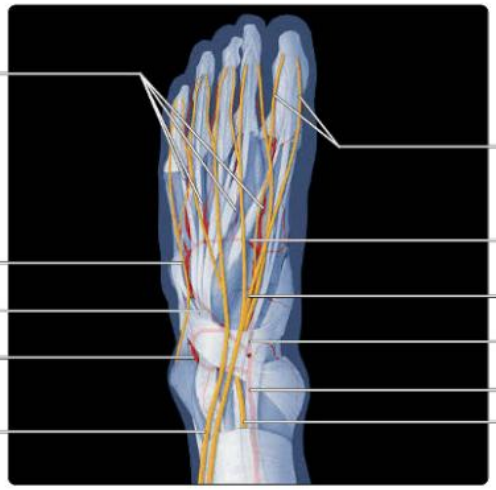

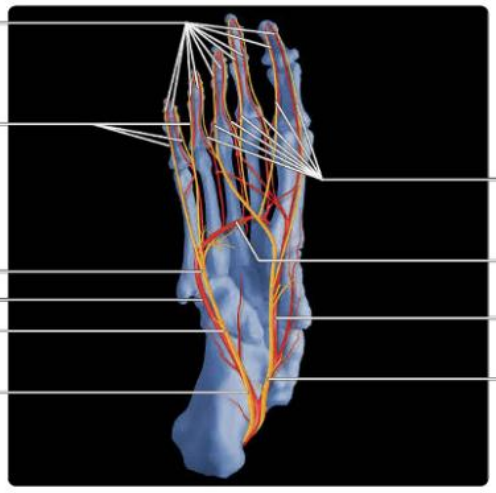

(Top) *Graphic shows the medial aspect of the ankle and the distal portions of the tibialis anterior and posterior tibial arteries. The dorsalis pedis artery is a direct continuation of the anterior tibial artery and supplies the dorsum of the foot. The posterior tibial artery passes beneath the medial malleolus where it divides into the medial and lateral plantar arteries.* **(Middle)** *Graphic shows the dorsal arteries and nerves of the foot. The deep peroneal nerve lies alongside the anterior tibial artery at the ankle. The anterior tibial artery is called the dorsalis pedis artery in the foot. It extends from the midpoint of the ankle to the 1st webspace. It terminates in the arcuate artery, which communicates with the plantar arterial arch and the digital arteries. The superficial peroneal nerve divides into medial and lateral branches in the distal 1/3 of the leg.* **(Bottom)** *Graphic shows the plantar arteries and nerves. The posterior tibial artery and nerve divide into medial and lateral plantar branches. These accompany each other to the forefoot. At the forefoot, they divide into into medial and lateral digital branches for each toe. The plantar arch communicates with the arcuate arch dorsally.*

FOOT ARTERIES

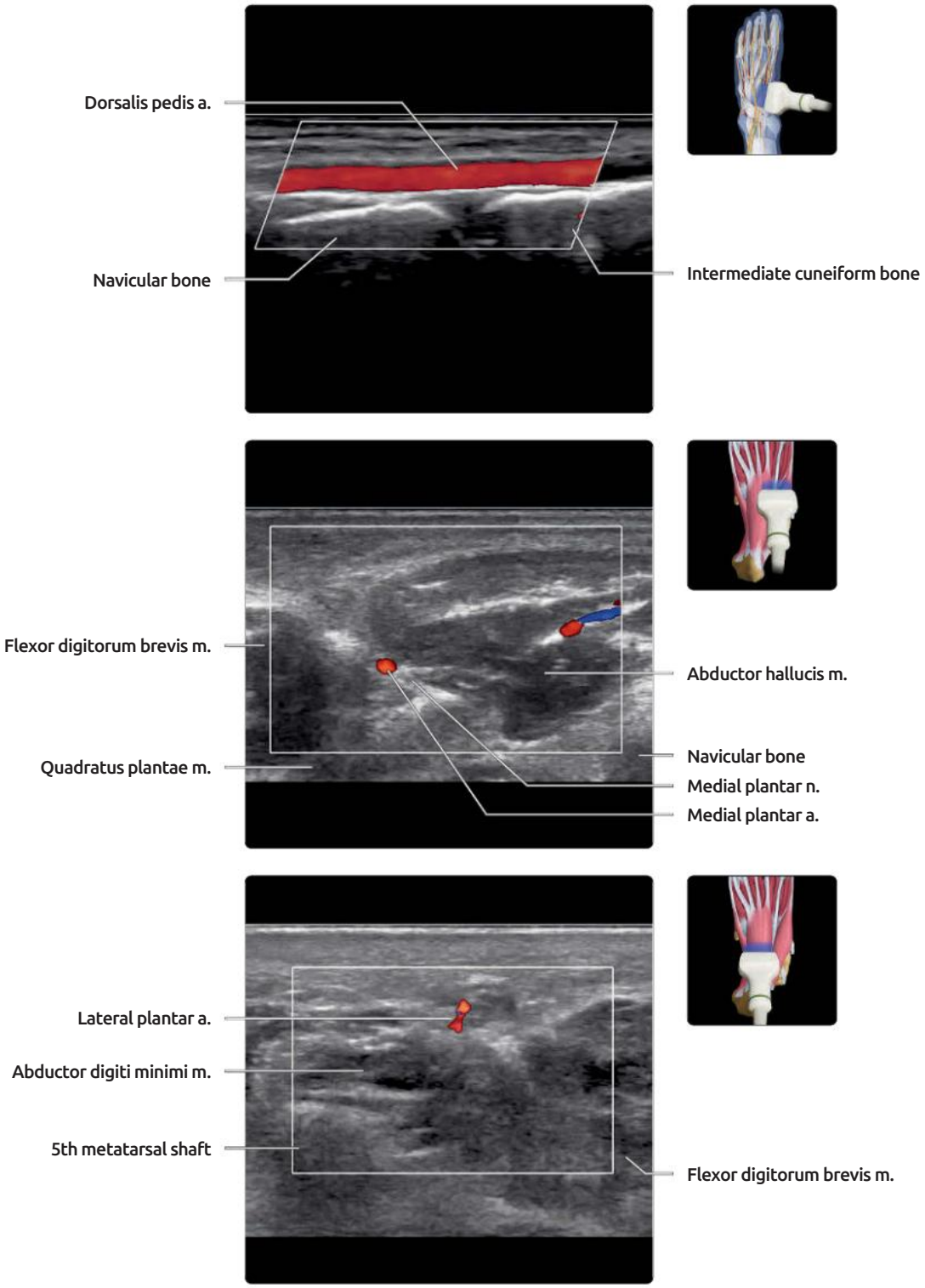

(Top) *Longitudinal color Doppler US shows the dorsalis pedis artery extending over the navicular and intermediate cuneiform bones.* **(Middle)** *Transverse color Doppler US shows the medial plantar artery on the lateral aspect of the adductor hallucis muscle. The medial plantar artery serves as a good landmark for the medial plantar nerve, which lies alongside the artery.* **(Bottom)** *Transverse color Doppler US of the lateral margin of the plantar aspect of the foot shows the lateral plantar artery located between the abductor digiti minimi muscle and the flexor digitorum brevis muscle. The lateral plantar artery serves as a good landmark for the lateral plantar nerve, which accompanies it.*

LEG, DEEP AND SUPERFICIAL VEINS

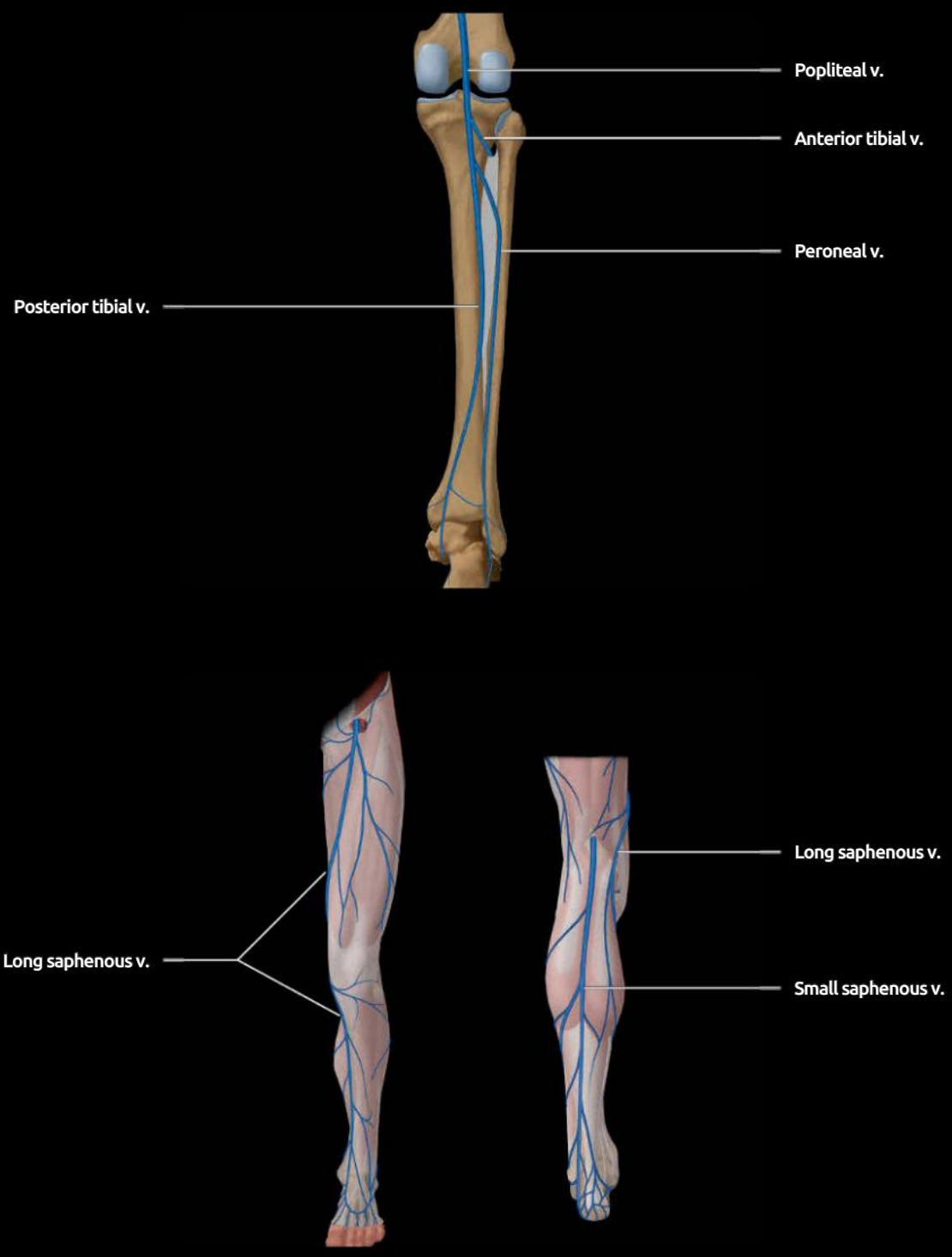

(Top) *Graphic shows the deep veins of the leg, which accompany the arteries of the same name and are often paired.* **(Bottom)** *Graphic shows the superficial veins of the lower limb. The long saphenous vein is the longest vein in the body. It begins in the dorsal medial aspect of the foot and passes anterior to the medial malleolus and posterior to the lateral femoral condyle. It then ascends obliquely along the anterior aspect of the thigh to join the common femoral vein. The short saphenous vein is located posterolateral to the lateral malleolus. It ascends in the midline on the posterior aspect of the calf.*

LEG, SUPERFICIAL VEINS

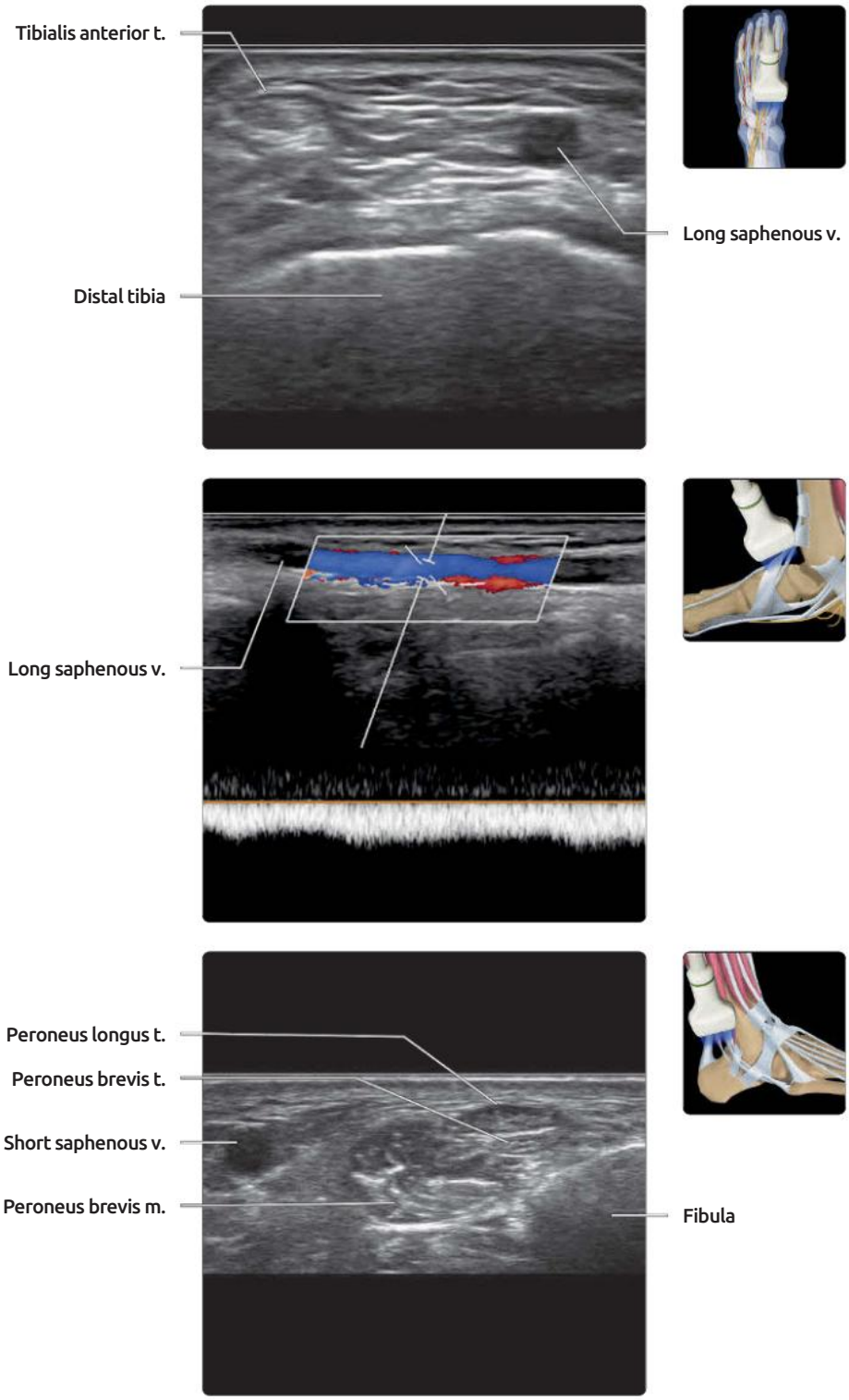

(Top) *Transverse US of the anteromedial aspect of the ankle region shows the long saphenous vein present within the subcutaneous tissues medial to the tibialis anterior tendon.* **(Middle)** *Longitudinal color Doppler US of the distal leg shows normal color flow in the long saphenous vein.* **(Bottom)** *Transverse US of the posterolateral aspect of the ankle shows the short saphenous vein located within the subcutaneous tissues lateral to the peroneal tendons.*

GROSS ANATOMY

Overview

- Largest & most complex joint
  - Hinge joint throughout main range of motion, though also has rotation element at end of extension
  - Stability maintained by ligaments, tendons, capsule, & menisci
- **Motion** of knee & relationship of osseous structures
  - In full flexion
    - Supporting ligaments are not taut, & rotation of leg is allowed
  - During knee extension
    - Patella slides upward on femur, engaging with femoral trochlea until near full extension
    - Femoral condyles roll forward on tibial condyles & menisci
    - Lateral femoral condyle is shorter anteroposteriorly than medial, thus, reaches full extension earlier
    - Medial tibial condyle continues to slide after lateral tibial condyle stops rotating slightly (~ 6°) laterally on femur (screw home mechanism)
      - Tightens cruciate ligaments & stabilizes knee in extension
  - Initiating flexion from fully extended knee
    - Requires slight medial rotation of tibia, produced by popliteus muscle
    - Unlocks joint, allowing remainder of motion to take place

IMAGING ANATOMY

Osseous Anatomy

- **Distal femur**
  - Medial femoral condyle larger than lateral
  - Anteriorly, V-shaped trochlear groove accommodates patella
- **Proximal tibia**
  - Gerdy tubercle anterolateral just distal to joint
  - Tibial tubercle (apophysis) anterior & slightly lateral, several cm distal to joint
- **Proximal fibula**
  - Posterolateral relative to tibia
- **Tibiofibular joint**
  - True synovial joint; subject to arthritic processes
  - Connects to knee joint in 10%
- **Patella**
  - Triangular sesamoid bone wider at base superiorly than at apex inferiorly
  - Bipartite (multipartite) patella: Always upper outer quadrant; osseous fragments may appear discordant, but cartilage is continuous over defect

Capsule

- Tight posteriorly to support knee in extension
- Loose anteriorly to allow flexion
- Many different elements all serving to provide knee stability

Extensor Mechanism

- **Quadriceps**
  - Quadriceps tendon inserts onto anterosuperior surface of patella
  - Tendon contributions from rectus femoris, vastus lateralis, medialis, & intermedius muscles
  - 3-layered structure but may have 1-5 laminae separated by fibrofatty connective tissue
    - Rectus femoris → anterior lamina, which continues over patella as prepatellar quadriceps continuation
    - Vastus lateralis & medialis → middle lamina
    - Vastus intermedius → posterior lamina
  - Tendons contribute not only to their own lamina but also to other lamina
- **Patellar tendon**
  - Runs from inferior pole of patellar to tibial tuberosity
    - Rectus femoris fibers that course over patella enhance continuity with quadriceps tendon
  - Fibers of vastus lateralis & medialis contribute to lateral & medial patellar retinacula, respectively
- **Medial retinaculum**
  - 3-layered fascial sheet between patella & medial femoral condyle
    - Superficial layer: Investing fascia of thigh (crural fascia)
    - Middle layer: Medial patellofemoral ligament (MPFL) & medial collateral ligament (MCL)
    - Deep layer: Knee joint capsule to which synovium is attached
  - MPFL is strongest component of medial retinaculum
    - Contributes 60% of medial patellar stability
    - Extends from superomedial aspect of patella to adductor tubercle where it merges with MCL femoral attachment
    - Femoral attachment of MPFL has transverse band (outer fibers) & oblique band (inner fibers)
      - Transverse fibers cross superficial to MCL
      - Oblique fibers attach superficially onto anterior fibers of MCL
- **Lateral retinaculum** (rarely injured)
  - 3-layered fascial sheet between patella & lateral femoral condyle
    - Superficial layer: Investing fascia of thigh (crural fascia)
    - Intermediate layer: Longitudinal fibers of iliotibial band & more transverse fibers from iliotibial band (iliotibial band-patella fibers)
    - Deep layer: Lateral patellofemoral ligament (indistinct thickening of joint capsule)

Fat Pads

- Suprapatellar: Anterior & posterior (prefemoral) to suprapatellar bursa
- Infrapatellar (Hoffa fat pad): Distal to patella, deep to capsule, & superficial to synovium
- Posterior: Posterior joint margin extending into intercondylar region

Medial Supporting Structures

- Superficial (layer 1)
  - Pes anserinus tendons: Anteromedial tibial insertion
    - Sartorius embedded in crural fascia
    - Gracilis immediately deep to sartorius
    - Semitendinosus immediately deep to gracilis
    - All insert onto anteromedial aspect of tibia

- Semimembranosus: Posteromedial insertion
  - Direct arm → posteromedial aspect of tibia
  - Oblique popliteal arm → oblique popliteal ligament (OPL) along posterior capsule knee
  - Anterior arm → medial aspect of tibia deep to superficial component MCL
  - Capsular arm → posterior oblique ligament (POL), at posteromedial corner of knee
  - Inferior arm → posterior tibia just proximal to popliteus muscle
- Middle (layer 2)
  - Superficial MCL (longitudinal & oblique components)
    - Runs slightly anteromedially from medial epicondyle to insert onto tibia 5 cm distal to joint line
    - Anteriorly, longitudinal component fascia blends with superficial layer
    - Posteriorly, oblique component blends with deep layer as POL
- Deep (layer 3)
  - Capsular layers (deep fibers of MCL) at midportion of knee
    - Meniscofemoral ligament: From outer superior aspect of meniscal body to either MCL or femur
    - Meniscotibial ligament: From outer inferior aspect of meniscal body to tibia
  - POL located posteromedially between MCL & posteromedial knee capsule
    - Discrete thickening of knee capsule
  - Posteromedial knee capsule
    - In continuity with posterior horn medial meniscus via meniscofemoral & meniscotibial capsular ligaments
      - Tear of these ligaments known as ramp lesion

Lateral Supporting Structures

- Superficial
  - Iliotibial band anteriorly, inserts onto Gerdy tubercle
  - Anterolateral ligament extends from at or just anterior to femoral lateral collateral ligament insertion to proximal tibia between Gerdy tubercle & fibular head
    - Segond fractures occur at this tibial insertion
  - Biceps femoris short & long heads
    - Long head: Extends from ischial tuberosity → fibular head
    - Short head: Extends from posterior aspect of distal femoral shaft → fibular head
      - There is also much smaller anterior arm, which inserts into lateral tibia just distal to anterolateral ligament
- Deep
  - Lateral collateral ligament extends superomedially from lateral aspect of fibular tip → lateral femoral epicondyle
  - Popliteofibular ligament extends superomedially from middle of fibular tip → popliteus tendon near musculotendinous junction
  - Posterolateral knee capsule
    - Sometimes known as arcuate ligament, though no such discrete ligament seems to exist

Internal Structures

- **Menisci**
  - Fibrocartilage cushion to stabilize knee
  - Only peripheral portion visualized by US
  - Medial attached to capsule medially & posteriorly
  - Lateral attached to capsule laterally & posteriorly (by popliteomeniscal fascicles)
- **Cruciate ligaments**
  - Major stabilizing structures to anteroposterior & rotatory motion

Synovial Recesses of Knee Joint

- Suprapatellar, medial patellar, lateral patellar
  - Increase in synovial fluid tends to first accumulate in either medial or lateral recess & then suprapatellar recess
  - Small amount of fluid in knee joint is normal but should not get more than small amount
  - Synovial proliferation best assessed at medial & lateral recesses
- Baker cyst is distention of gastrocnemius-semimembranosus bursa
  - Slit-like opening, too small to be seen, connects knee joint to Baker cyst
    - Between medial belly gastrocnemius & semimembranosus, semitendinosus tendons
  - Synovial fluid can be expressed from knee joint into Baker cyst if interconnectivity present

Neural Anatomy

- Tibial nerve superficial or lateral to popliteal vein
  - Medial cutaneous sural nerve & small saphenous vein lie superficial to tibial nerve
  - Slightly flex knee to see popliteal vein more clearly
- Common peroneal nerve passes obliquely through popliteal fossa along medial border of biceps femoris muscle & tendon
- Saphenous nerve initially posterior to sartorius muscle, then perforates fascia lata, between sartorius & gracilis tendons to join great saphenous vein
  - Best located posterior to sartorius muscle just proximal to knee, examined supine & externally rotated

ANATOMY IMAGING ISSUES

Imaging Approaches

- US very good for assessing extraarticular abnormalities, e.g., tendinosis, ligament disruption, bursitis, masses, etc.
- Targeted approach to knee US examination is best
  - e.g., posterior examination for popliteal mass, lateral examination for iliotibial band syndrome, etc.
- In acutely inflamed joint, US is accurate at defining effusion & synovitis, facilitating image-guided aspiration or synovial biopsy
- For assessment of ligaments & tendons, longitudinal examination is more helpful to confirm integrity
  - Flexion tenses many tendons & ligaments & accentuates straight course of fibers
  - Slightly flex knee for examination of anterior structures or as adjunct to examination of other areas
  - Dynamic assessment or stretching part under examination often helpful
  - Also, weightbearing when assessing severity of meniscal body extrusion

EXTENSOR MECHANISM & ANTERIOR FAT PADS

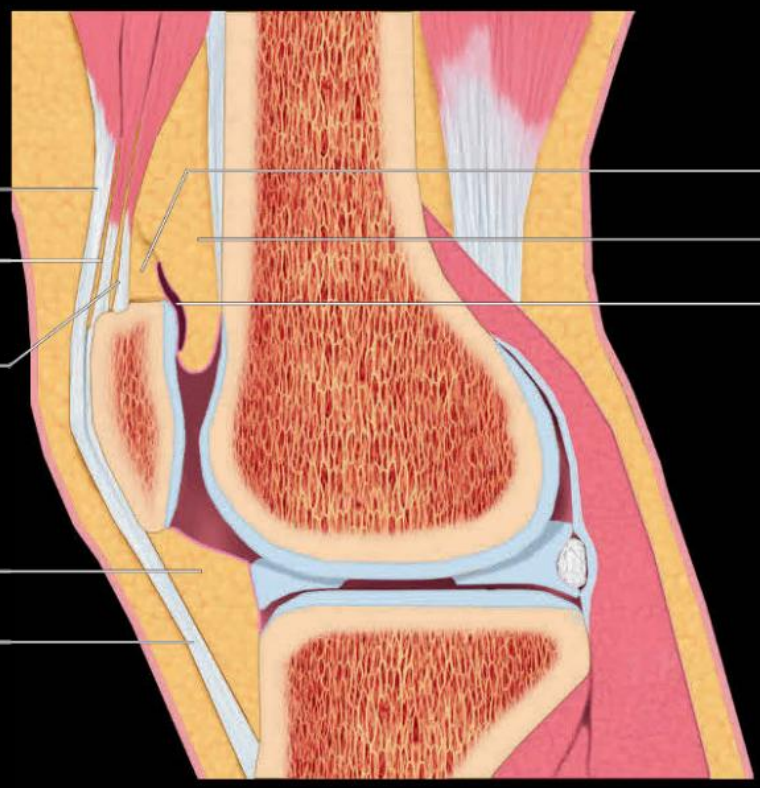

Graphic shows trilaminar configuration of the quadriceps tendon. The superficial lamina is formed by the rectus femoris tendon, the middle lamina is formed by the aponeurosis of the vastus medialis and lateralis tendons, and the deep lamina is formed by the vastus intermedius tendon.

EXTENSOR MECHANISM AND PES ANSERINUS

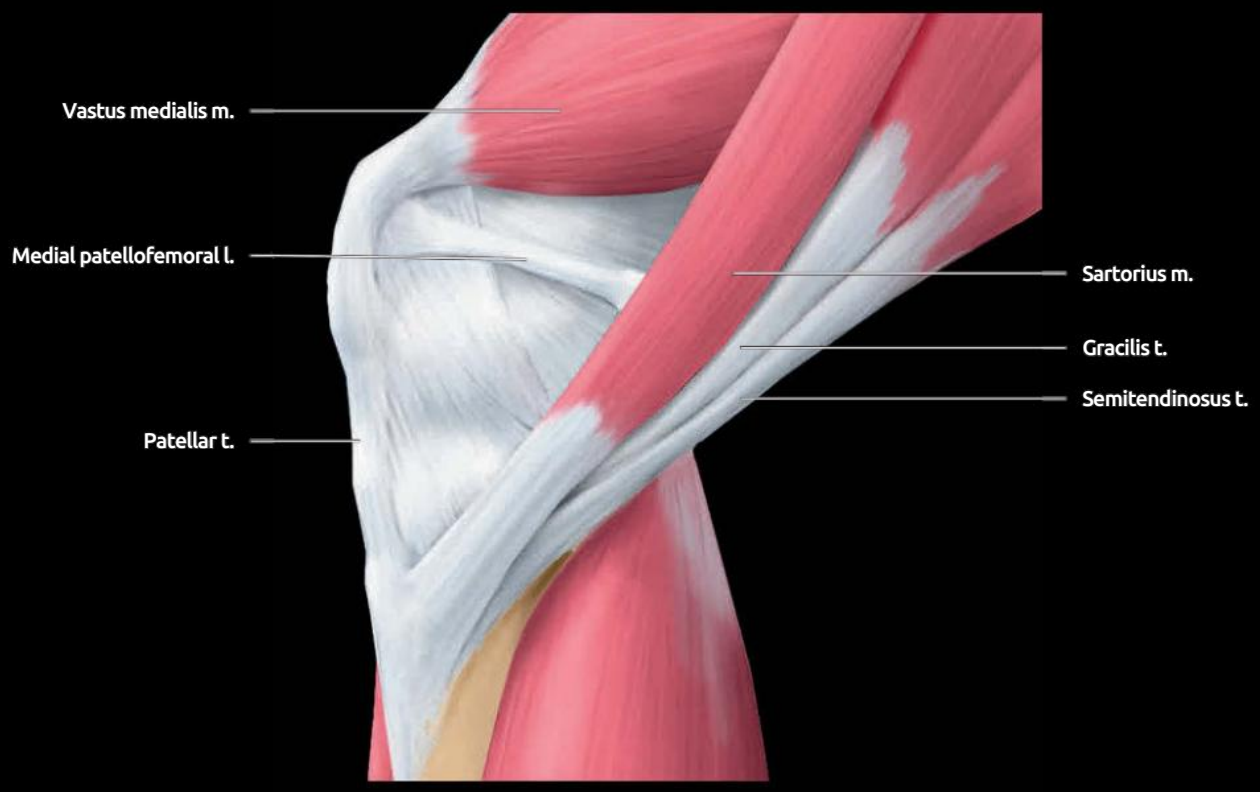

Graphic shows the extensor mechanism anteriorly and the attachment of pes anserinus tendons anteromedially. The quadriceps tendon is continuous with the patellar tendon over the anterior aspect of the patella (prepatellar quadriceps continuation). Anteromedially, the sartorius is the most anterior and superficial of the pes anserinus tendons. The gracilis tendon inserts immediately posterior and distal to the sartorius tendon, while the semitendinosus tendon inserts immediately posterior and distal to the gracilis tendon. The medial patellofemoral ligament (MPFL) is an hourglass-shaped condensation of medial retinacular fibers that runs from the superomedial aspect of the patella to the femur to insert at the interspace between the femoral attachment of medial collateral ligament (MCL), adductor tubercle, and femoral attachment of the medial head gastrocnemius muscle.

QUADRICEPS TENDON

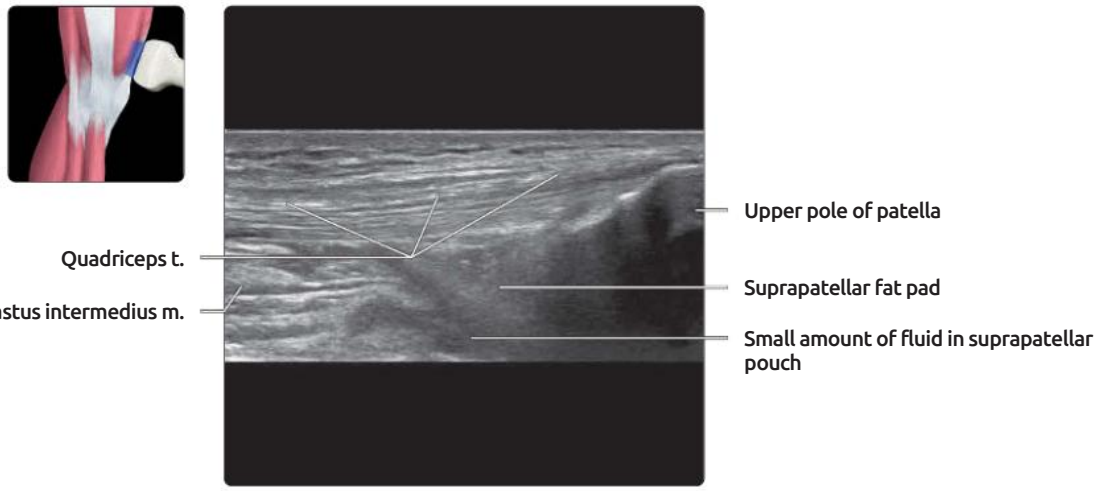

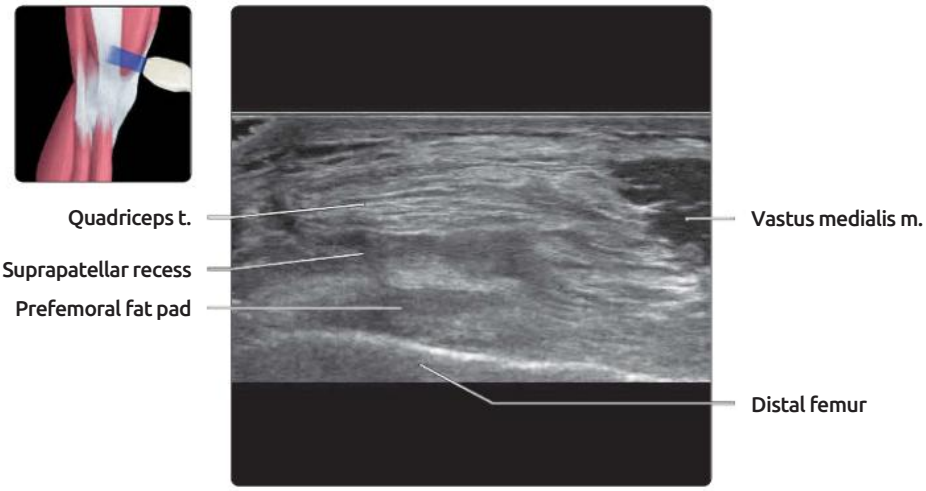

(Top) *Sagittal US shows the quadriceps tendon. The quadriceps tendon is the direct continuation of the rectus femoris with contributions medially and laterally from the vastus medialis and the vastus lateralis, respectively, and deeply from vastus intermedius. The tendon inserts on the superoanterior surface of the patella.* **(Middle)** *Longitudinal US of quadriceps tendon shows the layered appearance, although the 3 laminae (superficial from quadriceps femoris, middle from vastus medialis and lateralis, and deep from vastus intermedius) cannot usually be clearly defined.* **(Bottom)** *Transverse US of distal thigh shows the layered appearance of the quadriceps tendon. The fibers of the vastus medialis extend more distally than the other quadriceps muscle fibers and insert into the medial aspect of the quadriceps tendon and the medial part of the patella. This more distal medial part of the vastus medialis muscle is sometimes referred to as the vastus medialis obliquus muscle and may help prevent lateral subluxation of patella.*

PATELLAR TENDON

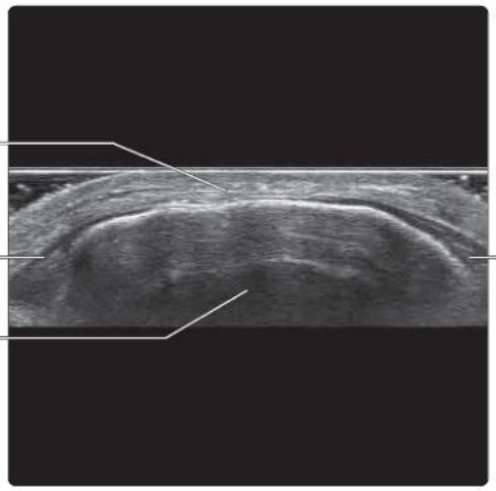

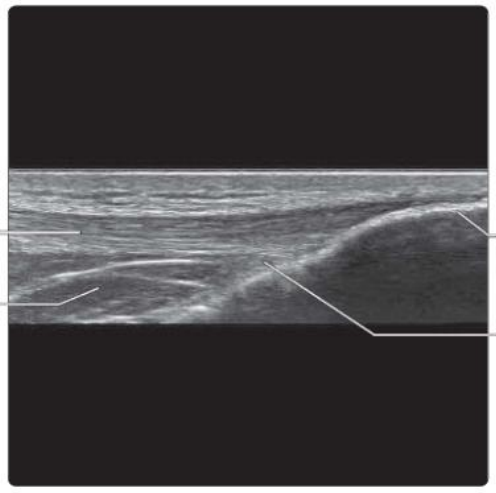

(Top) *Longitudinal US of patella shows the prepatellar quadriceps continuation over the anterior aspect of the patella to enhance continuity between the quadriceps and patellar tendons.* **(Middle)** *The prepatellar quadriceps continuation helps affirm the likelihood that the patellar bone represents a sesamoid bone within the quadriceps-patellar tendon. The patellar tendon immediately distal to the inferior pole of the patella is especially prone to tendinosis.* **(Bottom)** *Longitudinal US shows the anterior tibial tuberosity. The distal fibers of the patellar tendon are separated from the anterior surface of the tibial condyle by the infrapatellar bursa. A small amount of fluid (2-3 mm thick) may be normally present in this bursa. The bursa is not visible in this patient.*

PATELLAR TENDON & PARATENON

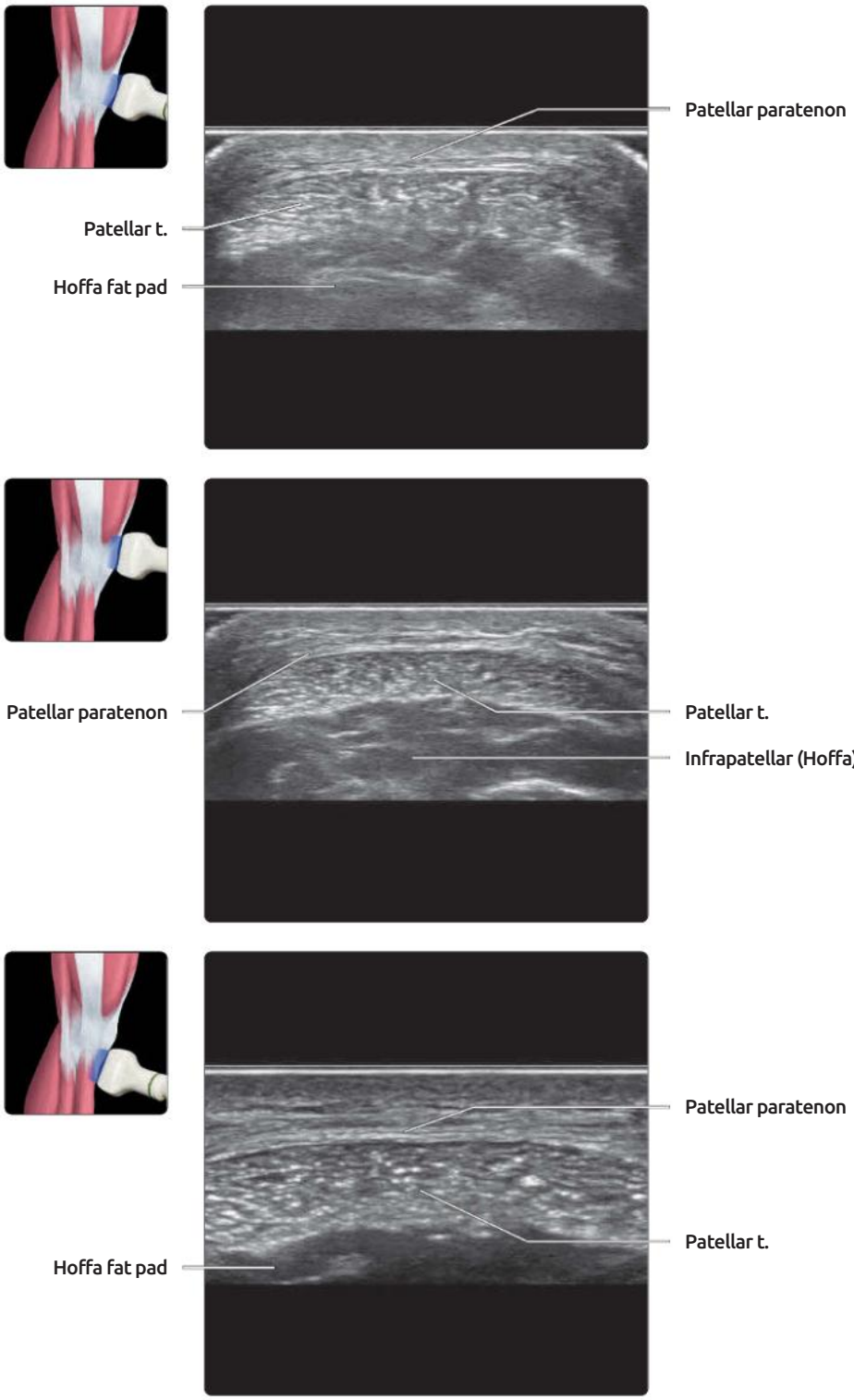

(Top) *Transverse US shows the proximal end of the patellar tendon, which has a biconcave configuration and is covered by a thin paratenon.* **(Middle)** *Transverse US of the midportion of the patellar tendon is shown. The normal cross-sectional area of the patellar tendon is ~ 100 mm². There is quite wide intrapopulation variability in patellar tendon caliber. As such, a cross-sectional area may not be useful for making a diagnosis of tendinosis, though it is useful for comparing different patient cohorts and for follow-up of tendinosis following treatment.* **(Bottom)** *Transverse US shows a more localized view of the patellar tendon and patellar tendon paratenon. The paratenon is seen as a thin echogenic line on the anterior surface and side walls of the tendon. The paratenon will be become thickened in patellar paratenonitis, though this is an infrequently encountered condition.*

PARAPATELLAR LIGAMENTS & RETINACULA

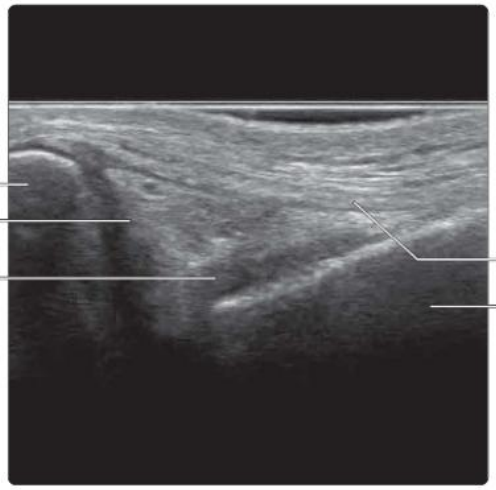

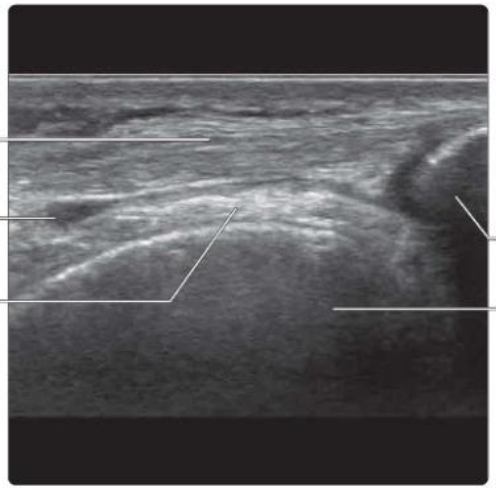

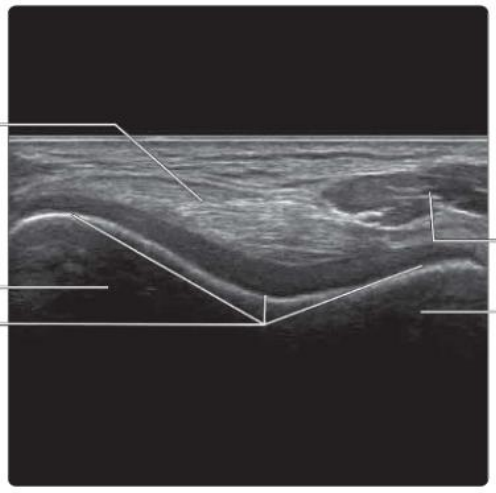

(Top) *Transverse US at the medial margin of the patella shows the medial patellofemoral ligament (MPFL). The MPFL extends from the superomedial aspect of the patella to the medial femoral condyle, attaching close to the MCL attachment and adductor tubercle. The MPFL helps prevent lateral patellar dislocation. Most patellar dislocations tend to occur laterally due to the lateral pull of the quadriceps muscle. As medial patellar dislocation is rare, there is no real MPFL counterpart on the lateral side.* **(Middle)** *Transverse US of the knee shows the lateral retinaculum and lateral parapatellar joint recess. The paired parapatellar and single suprapatellar recess are the 3 anterior joint recesses of the knee. In normal subjects, 1 of the 3 recesses will usually contain a small amount of physiological fluid. If > 1 recess is more than minimally distended with fluid, there is an increase in knee joint fluid, i.e., an effusion.* **(Bottom)** *Transverse US with the knee fully flexed shows the normal articular cartilage on the lateral (longer), apex, and medial trochlear facets. The quadriceps tendon lies flat against the femoral trochlea in this position.*

MEDIAL KNEE

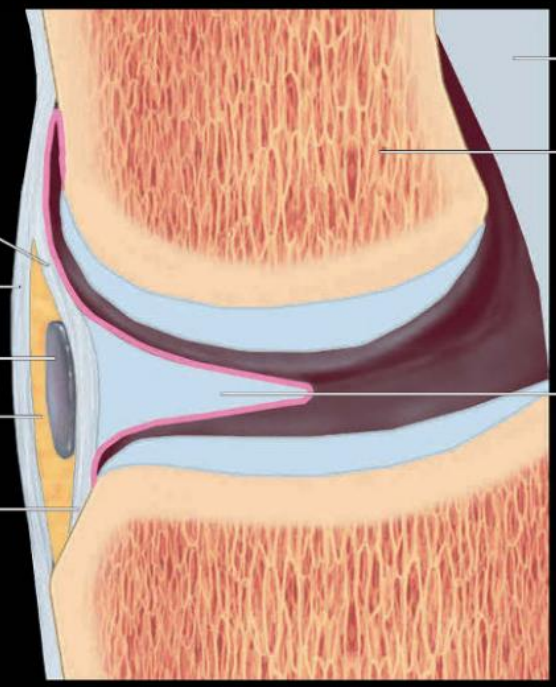

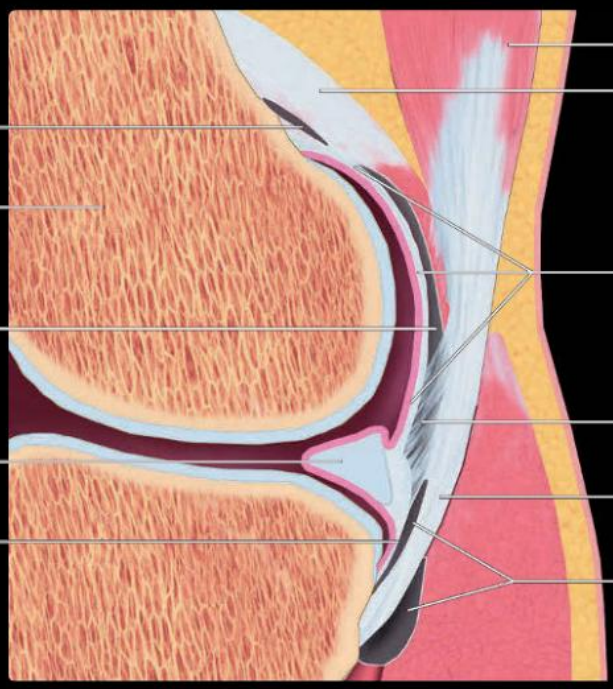

(Top) *Coronal graphic of the medial aspect of the knee shows superficial fibers of the MCL (sMCL) extending from the area close to the adductor tubercle to 5 cm below the joint line. The deeper fibers of the MCL are shorter. The meniscotibial (coronary) ligament extends from the inferomedial aspect of the meniscal body to the tibia adjacent to the joint line, while the meniscofemoral ligament extends from the superomedial aspect of the meniscal body to join either the femur or the superficial fibers of the MCL.* **(Bottom)** *Sagittal graphic shows the posteromedial aspect of the knee joint. The semimembranosus tendon has arm-like attachments to the posteromedial aspect of the knee joint. The most functionally important direct arm is shown here.*

MEDIAL KNEE

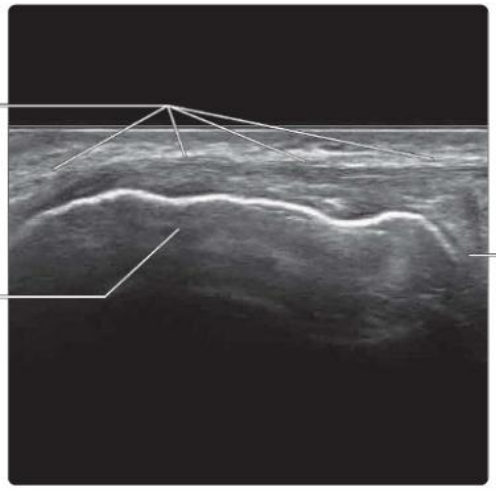

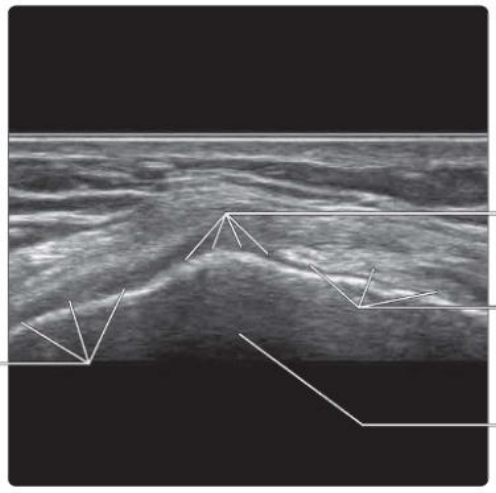

(Top) *Longitudinal US of the medial aspect of the knee joint shows the MCL superficial to the body of the medial meniscus. The MCL comprises superficial and deep fibers. The superficial fibers run from the medial epicondyle to ~ 5 cm along the tibial shaft. The deep fibers, which are difficult to appreciate on US, are the meniscofemoral and meniscotibial ligaments.* **(Middle)** *Longitudinal US of the medial aspect of the knee joint shows the femoral attachment of the MCL. The sMCLs are attached 1-2 cm distal to the adductor tubercle. This femoral attachment of the sMCL is the most common site of sMCL tears. The posterior oblique ligament (POL) (not shown) is attached ~ 1 cm posterior to the sMCL attachment at the same level.* **(Bottom)** *Transverse US of the medial femoral condyle shows the femoral attachment of the sMCL. The MPFL is attached just anterior to the femoral insertion of the sMCL. The POL is attached just posterior to the femoral insertion of the sMCL.*

LATERAL KNEE

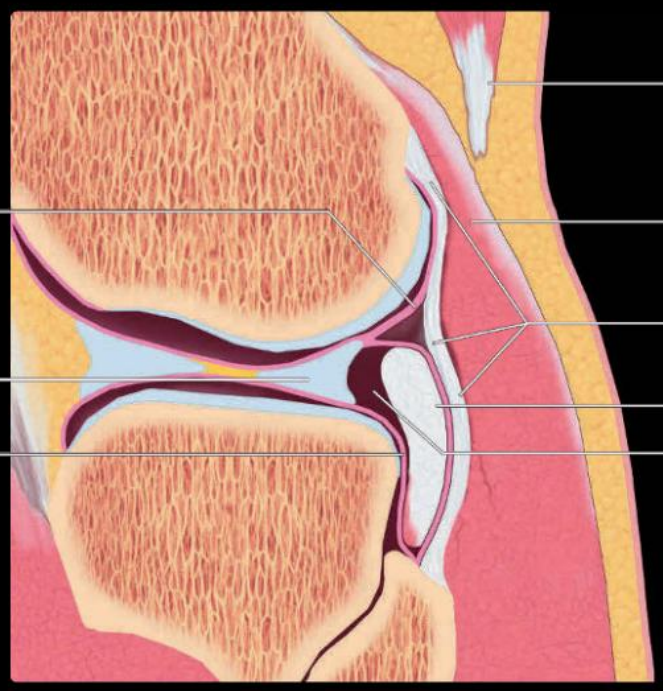

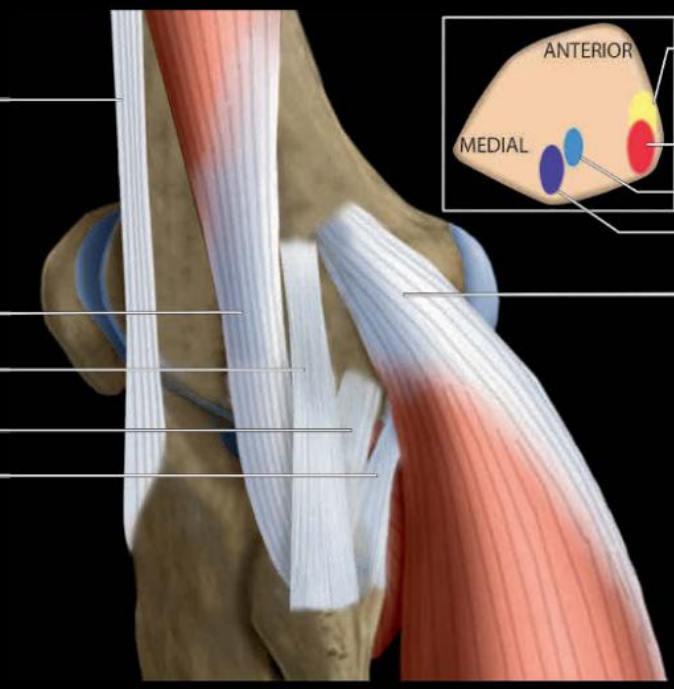

(Top) *Sagittal graphic of the posterolateral aspect of the knee joint is shown. The popliteus tendon is intraarticular but extrasynovial. The superior and inferior popliteomeniscal fascicles (PMF) extend from the posterior margin of the posterior horn of the lateral meniscus to the sheath surrounding the popliteus tendon. The PMFs cannot be seen on US examination. The recess around the popliteus tendon is in continuity with the knee joint and will distend with moderate to large knee joint effusions.* **(Bottom)** *Graphic shows the alignment of structures at the posterolateral aspect of knee. The main structures attached to the fibular tip are the lateral collateral ligament (LCL), the biceps femoris tendon, and the popliteofibular ligament. The fibular tip attachment sites are shown in the cross section of the fibular tip (inlet). The fabellofibular is a small inconsistent ligament. If the fabella is absent, as occurs in 80% of the population, this ligament attaches directly to the posterolateral capsule. The popliteus tendon, which lies deep to the LCL and the biceps femoris tendon, is not shown.*

LATERAL KNEE

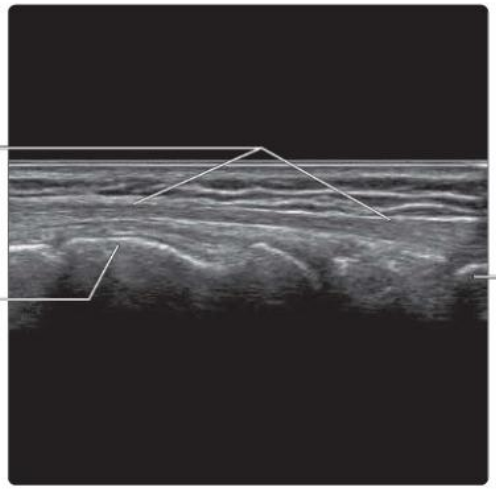

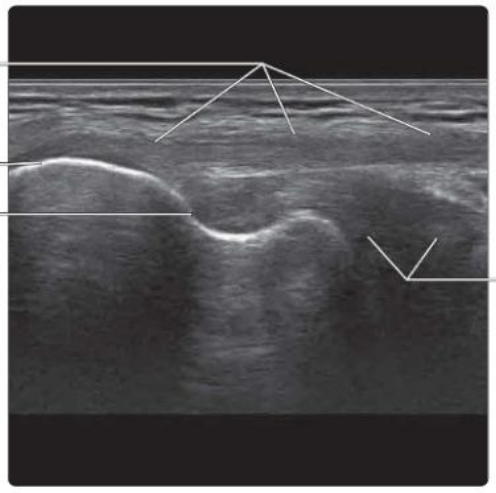

(Top) *Longitudinal US of the anterolateral aspect of the knee shows the iliotibial tract attaching to Gerdy tubercle on the proximal tibia. The iliotibial tract is a strong longitudinal band of the fascia lata (deep investing fascia) of the thigh. The gluteus maximus and tensor fascia lata muscles are the main muscular contributors to the iliotibial tract.* **(Middle)** *Longitudinal US of the lateral aspect of the proximal knee shows close proximity between the iliotibial band and the lateral femoral condyle. With overuse, iliotibial band friction syndrome may occur due to impingement of the iliotibial band against the femoral condyle at ~ 20° of knee flexion. In chronic cases, one may see thickening and inflammatory changes around the iliotibial band. Occasionally, the iliotibial bursa interposed between the iliotibial band and the lateral aspect of the femoral condyle may become inflamed.* **(Bottom)** *Longitudinal US of the lateral aspect of the knee joint shows the femoral attachment of the LCL. The LCL is attached just proximal and posterior to the lateral epicondyle of the femur. The popliteus tendon is attached close to the LCL attachment.*

LATERAL KNEE

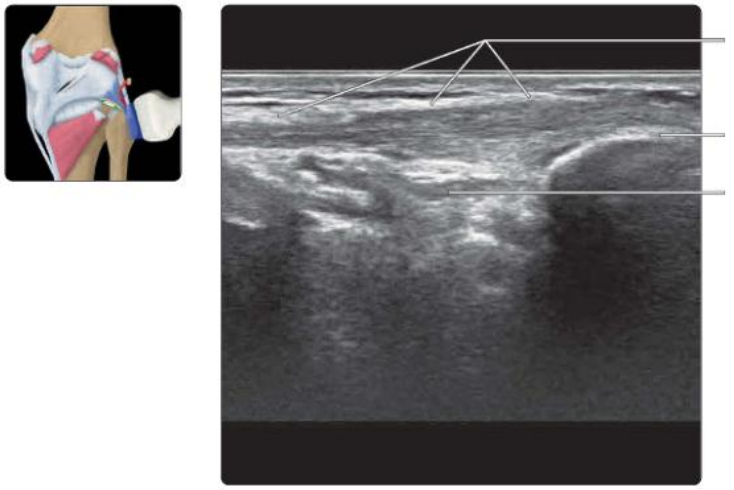

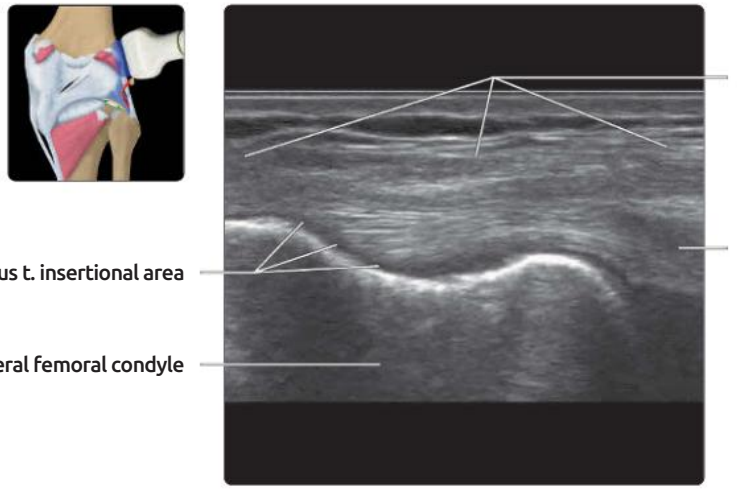

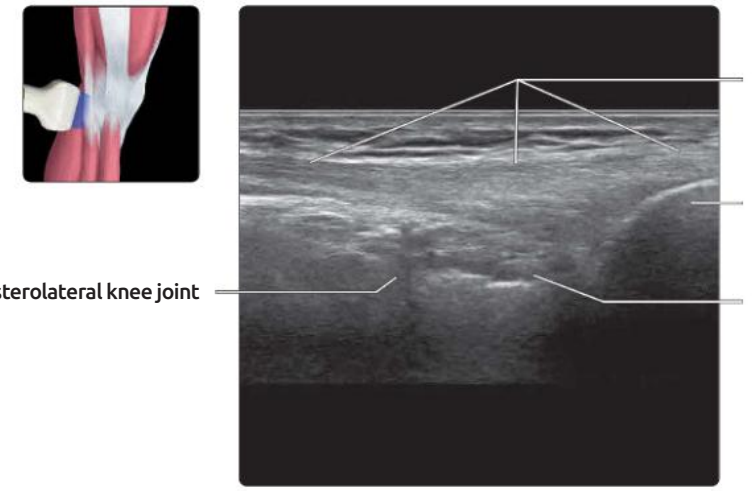

(Top) *Longitudinal US shows the LCL insertion into the fibular tip complex. Unlike the MCL, the LCL does not attach to the meniscus or joint capsule. The LCL is rarely injured in isolation. Most LCL injuries occur in conjunction with other posterolateral corner injuries.* **(Middle)** *Longitudinal US of the lateral aspect of the knee shows the popliteus tendon insertion. The popliteus tendon is inserted into the depression of the lateral aspect of the lateral femoral condyle. This attachment is just anterior and inferior to the attachment of the LCL.* **(Bottom)** *Longitudinal US of the posterolateral aspect of the knee shows the biceps tendon's attachment to the posterolateral aspect of the fibular head. Both the long and short heads of the biceps femoris have a conjoint attachment conjunction with the LCL. The biceps femoral tendon is vertically aligned, while the LCL tendon is angled slightly more anteriorly.*

POSTERIOR KNEE AND NERVES

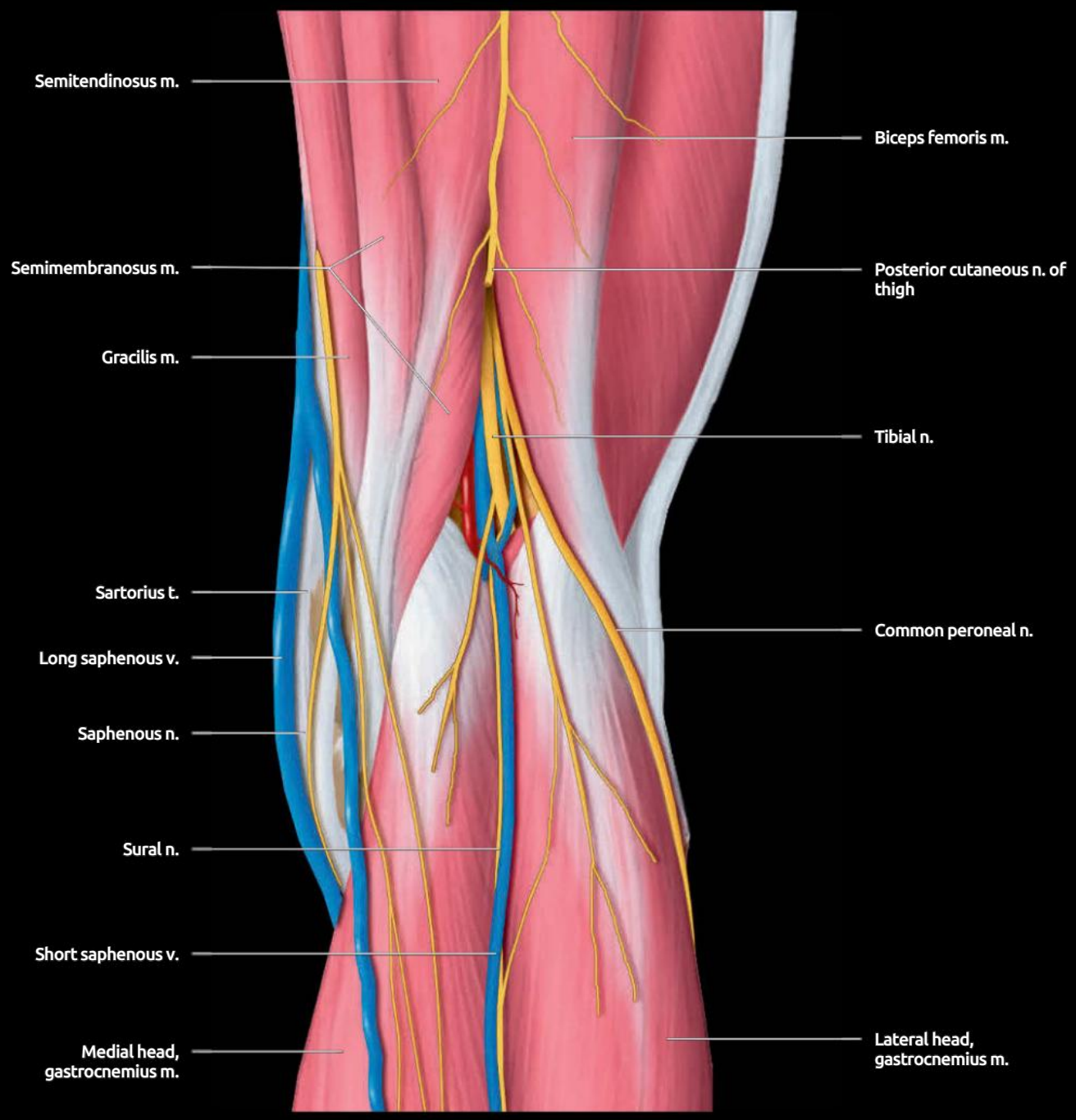

Graphic shows the more superficial posterior muscles and nerves. The popliteal fossa is a diamond-shaped fossa bordered superiorly by the hamstring muscles and inferiorly by the head of the gastrocnemius muscle. Superiorly, the medial margin is formed by the semimembranosus and semitendinosus muscles and laterally by the biceps femoris muscle. Inferiorly, the medial and lateral borders are formed by the medial and lateral heads of the gastrocnemius muscle. The fossa contains the popliteal vessels and the tibial nerve and its branches. The common peroneal nerve follows the biceps femoris muscle and tendon laterally to the fibula where it passes around the fibular neck.

POSTERIOR KNEE AND NERVES

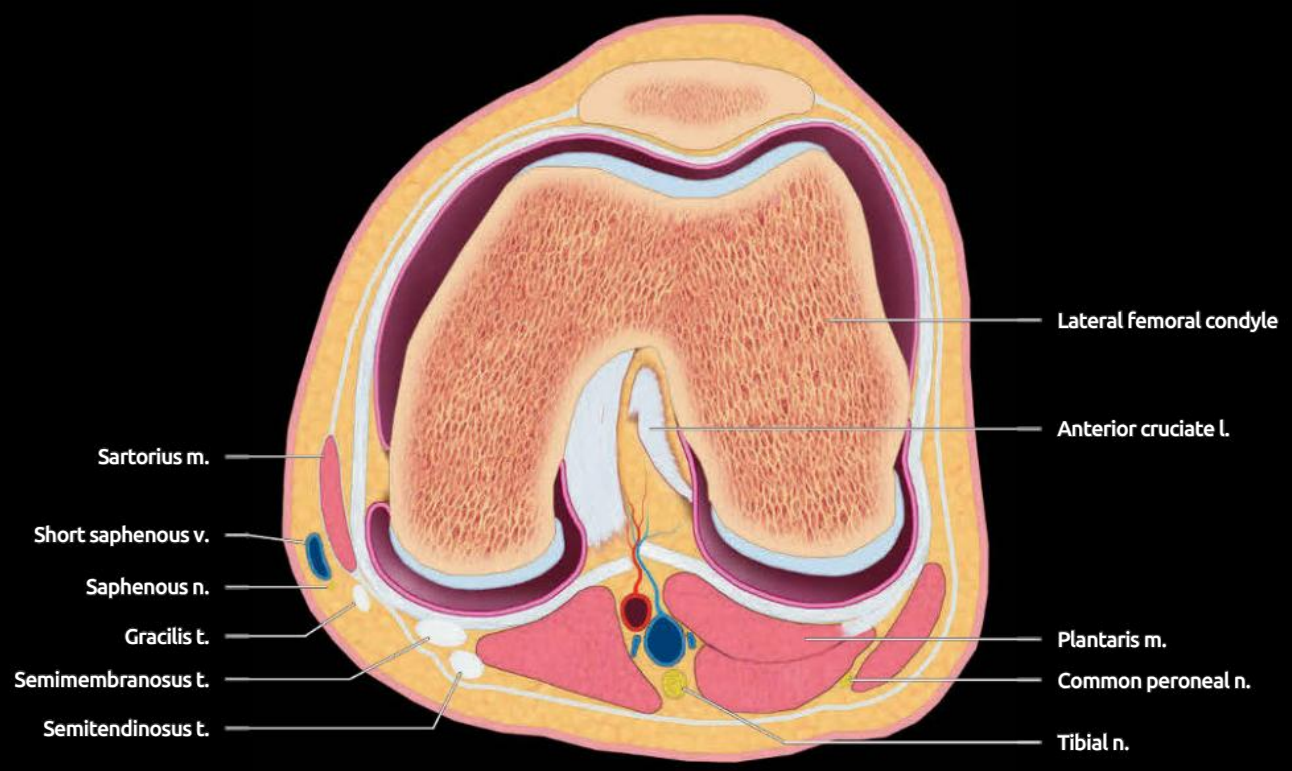

Graphic of cross section of knee joint demonstrates the posterior structures. The crural fascia of the thigh envelops the sartorius muscle and most of the structures around the knee. The posterior capsule (white) of the knee is tight to provide support, while the anterior capsule is lax to allow knee flexion. The pes anserinus tendons line up posteromedially. The position of the large tibial nerve, the medium-sized common peroneal nerve, and the small, short saphenous nerve is shown.

POSTERIOR KNEE

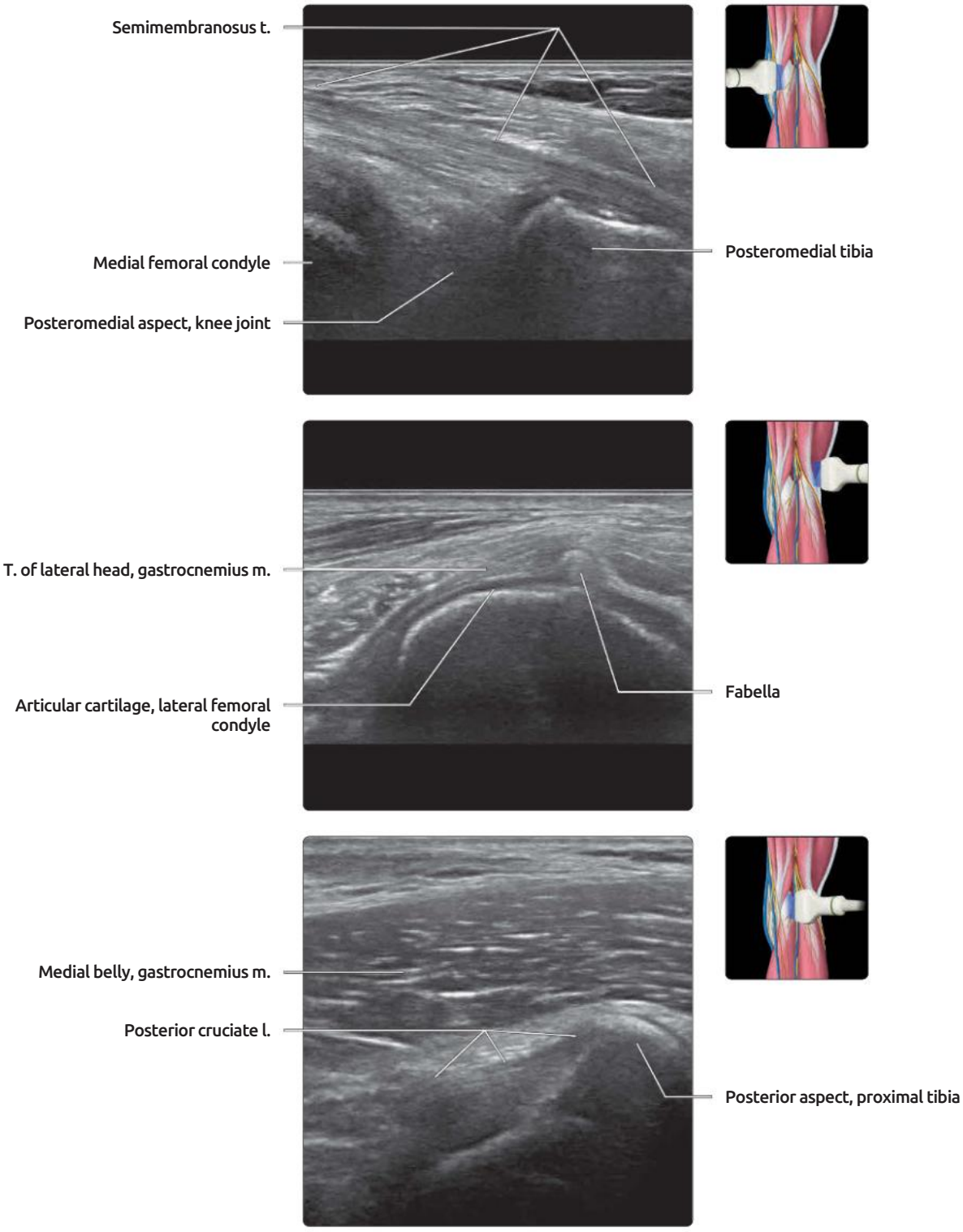

(Top) *Longitudinal US of the posteromedial aspect of the knee shows the large semimembranosus tendon inserted into the posteromedial aspect of the proximal tibia. The semimembranosus has 5 separate attachments to the knee joint with the direct arm, as shown here, being most readily seen on US. The anterior arm and the oblique popliteal arm can also be seen on axial imaging. A bursa (not shown) exists between the semimembranosus tendon and the medial belly of gastrocnemius tendon.* **(Middle)** *Longitudinal US of the posterolateral aspect of knee joint shows the articular cartilage and fabella on the posterior aspect of the lateral femoral condyle.* **(Bottom)** *Longitudinal US of the posterior aspect of the knee joint centrally shows the tibial end of the posterior cruciate ligament. This portion is consistently visible on US examination. The posterior cruciate ligament inserts into the lateral surface of the medial femoral condyle. The femoral attachment is not visible on US.*

POSTERIOR KNEE

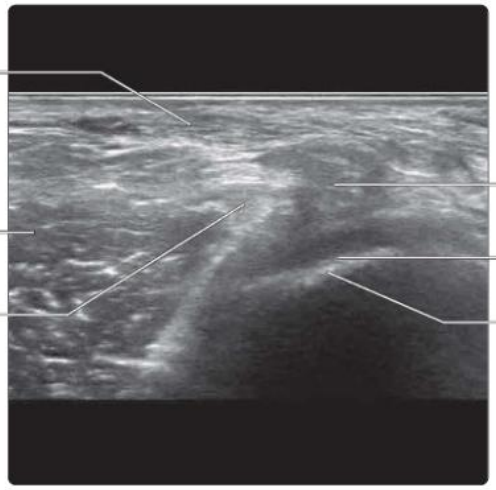

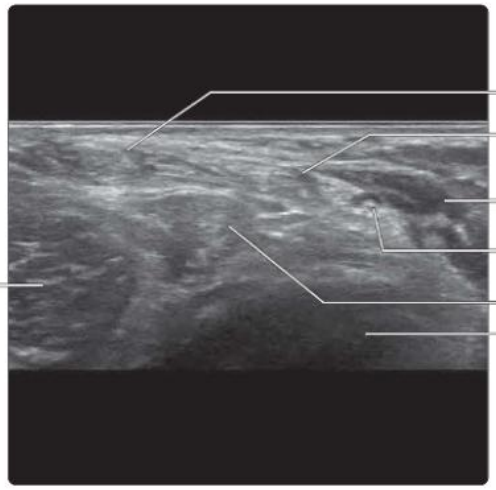

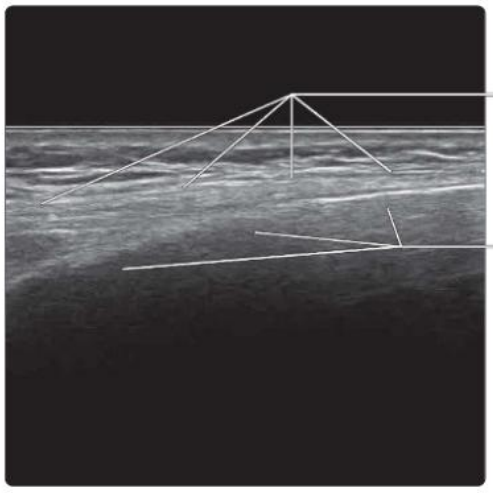

(Top) *Transverse US of the posteromedial aspect of the knee joint shows the site of origin of Baker cyst. The stalk of a Baker cyst classically emerges at the interface between the semitendinosus-semimembranosus tendons medially and the medial belly of the gastrocnemius laterally. It represents a distention of the semimembranosus/gastrocnemius bursa. In 50% of patients, this bursa communicates with the knee joint via a small transverse slit close to the femoral insertion of the medial belly of gastrocnemius. This transverse slit is not visible on US.* **(Middle)** *Transverse US of the posteromedial aspect of the knee joint shows the pes anserinus tendons, which comprise from anterior to posterior the sartorius, gracilis, and semitendinosus tendons.* **(Bottom)** *Longitudinal oblique US shows the insertion of the semitendinosus tendon into the posteromedial aspect of the proximal tibia.*

POSTERIOR KNEE NERVES

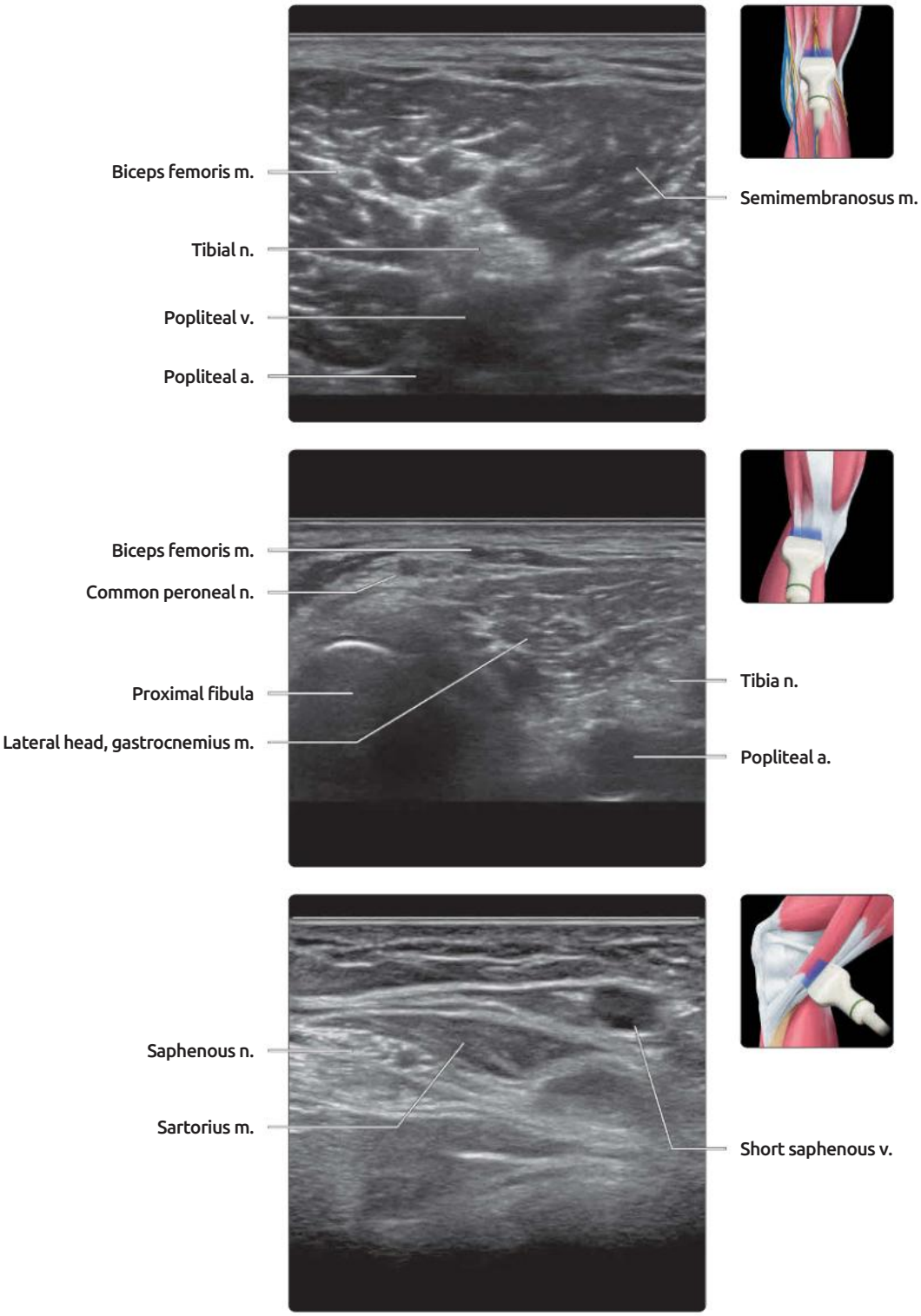

(Top) *Transverse US of the posterior knee in the midline at the proximal end of the popliteal fossa shows the tibial nerve lying superficial to the popliteal vein, which, in turn, lies superficial to the popliteal artery.* **(Middle)** *Transverse US of the lateral aspect of the popliteal fossa shows the common peroneal nerve close to the proximal fibula. The common peroneal usually leaves the tibial nerve at the proximal end of the popliteal fossa. It extends laterally deep to the biceps femoris muscle before winding around the fibular neck and entering the interspace between the peroneal muscles.* **(Bottom)** *Transverse US of the posteromedial aspect of the knee shows the saphenous nerve lying deep to the sartorius muscle. More distally, the nerve will arise from underneath the sartorius muscle and move superficially to lie alongside the short saphenous vein. It is a purely sensory nerve receiving sensory innervation from the skin on the anteromedial aspect of the leg.*

TERMINOLOGY

Abbreviations

- Artery (a.)
- Ligament (l.)
- Muscle (m.)
- Nerve (n.)
- Tendon (t.)
- Vein (v.)

GROSS ANATOMY

Interosseous Membrane

- Stretches between tibia & fibula
- Extends surface for origin of muscles
- Strong, oblique fibers run downward & laterally from tibia to fibula
- Proximally, below lateral condyle of tibia, there is opening for passage of anterior tibial vessels
- Distally, opening allows passage of perforating branch of peroneal artery
- Tibialis anterior, long toe extensors, & peroneus tertius partially originate from front of membrane
- Tibialis posterior & flexor hallucis longus partially originate from back of membrane

Muscles of Leg

- Compartments separated by deep fascia
- **Anterior compartment**
  - **Tibialis anterior muscle**
    - Origin: Upper 1/2 of lateral surface of tibia & interosseous membrane
    - Action: Dorsiflexes & inverts foot
  - **Extensor digitorum longus muscle**
    - Origin: Upper 3/4 of anterior surface of fibula
      - Descends behind extensor retinaculum to ankle
    - Action: Extends interphalangeal & metatarsophalangeal joints lateral 4 toes, dorsiflexes foot
  - **Peroneus tertius muscle**
    - Small muscle present in 90% of subjects
    - Origin: Continuous with extensor digitorum longus, arising from distal 1/4 of anterior surface of fibula & interosseous membrane
      - Extends distally, usually with extensor digitorum longus
    - Inserts onto dorsal surface base of 5th metatarsal bone
    - Action: Dorsiflexes ankle & everts foot
  - **Extensor hallucis muscle**
    - Thin muscle hidden between tibialis anterior & extensor digitorum longus muscles
      - Nearly entirely tendinous muscle
    - Origin: Middle 1/2 of anterior surface of fibula & interosseous membrane
    - Action: Extends great toe & dorsiflexes foot
- **Lateral compartment**
  - Peroneal compartment separated from extensors by anterior intermuscular septum & from posterior compartment by posterior septum
  - Common synovial sheath for peroneal tendons begins 5 cm above lateral malleolar & divides into 2 sheaths at inframalleolar level
  - **Peroneus longus muscle**
    - Origin: Upper 2/3 of lateral surface of fibula, intermuscular septa, & adjacent muscular fascia
      - Becomes tendinous few cm above lateral malleolus
      - Curves behind lateral malleolus, further from bone than peroneus brevis
    - Action: Everts & plantarflexes foot
  - **Peroneus brevis muscle**
    - Origin: Lower 2/3 of lateral surface of fibula, intermuscular septa, & adjacent muscular fascia
      - Muscle medial to peroneus longus at origin but overlaps peroneus longus in middle 1/3
      - Curves behind lateral malleolus, close to bone
    - Action: Everts & plantarflexes foot
  - **Peroneus quartus muscle**
    - Accessory muscle with prevalence of 10%
    - Originates from distal leg, frequently from peroneal muscles, with variable insertion sites at foot, usually to calcaneum (either peroneal tubercle or retrotrochlear eminence)
    - At level of malleolus, located medial or posterior to both peroneal tendons
  - **Peroneus digiti minimi muscle**
    - Accessory muscle with prevalence of 25%
    - Originates from peroneus brevis muscle & extends around lateral malleolus to foot
    - Tiny tendinous slips insert into metatarsal & proximal phalanx of little toe
  - **Peroneal nerves**
    - Common peroneal nerve wraps around fibular neck before dividing into superficial & deep peroneal nerves
    - Deep peroneal nerve passes deep to extensor digitorum longus muscle & onto interosseous membrane
    - Superficial peroneal nerve passes distally in fascial plane between peroneal musculature & extensor digitorum muscle
      - 10 cm proximal to lateral malleolus, it pierces crural fascia
- **Posterior compartment: Superficial muscles**
  - **Gastrocnemius muscle**
    - Origin: Medial from posterior femoral metaphysis; lateral from posterior edge of lateral femoral condyle
    - Heads separated from posterior capsule by bursa
    - Medial head of gastrocnemius muscle extends more inferiorly lateral to lateral head
      - Creates asymmetry in posterior calf muscle & predisposes medial belly gastrocnemius to distal myofascial tear
    - Join in thin aponeurotic tendon near midleg
    - Joins soleus aponeurosis to form Achilles tendon; concave in cross section; musculotendinous junction is 5 cm above calcaneal insertion
    - Action: Plantar flexor of ankle & flexor of knee
  - **Accessory medial & lateral gastrocnemius slips**
    - Accessory slips of medial or lateral bellies can result in popliteal artery entrapment syndrome (PAES)

  - 5 different types of PAES
- **Plantaris muscle**
  - Origin: Superior & medial to lateral head of gastrocnemius origin as well as from oblique popliteal ligament
  - Continues deep to lateral head of gastrocnemius
  - Myotendinous junction at level of origin of soleus (muscle is 5-10 cm long)
  - Tendon then lies between medial head of gastrocnemius & soleus
  - Follows medial side of Achilles to insert either anteromedially on Achilles or on calcaneus
  - Plantaris absent in 10% of population
  - Action: Acts with gastrocnemius
- **Soleus muscle**
  - Origin: Extensive, from posterior surface fibular head & upper 1/3 of fibular shaft, from soleal line & middle 1/3 medial border of tibia, & from tendinous arch across popliteal vessels
  - Flat, thick, powerful muscle
  - Joins with tendon of gastrocnemius to form Achilles tendon
  - Action: Stabilizes ankle in standing, plantarflexes ankle
- **Achilles tendon**
  - Formed from conjoined tendon of soleus & gastrocnemius muscles
  - Soleus contributes to deep & medial fibers; gastrocnemius contributes to superficial fibers
    - These fibers rotate 90° distally such that, at the calcaneum, soleus attaches superficially & medially, while gastrocnemius attaches deep & laterally
  - Paratenon covers sides & superficial margin of Achilles tendon
- **Accessory soleus muscle**
  - Accessory muscle, prevalence < 5%
  - Originates from posterior aspects of tibia ± fibula & inserts into Achilles or calcaneum anteromedially to Achilles tendon
  - May present as soft tissue mass
    - Hypertrophied accessory soleus muscle may compress tibial nerve before nerve enters tarsal tunnel
- **Tibiocalcaneus internus muscle**
  - Accessory muscle with prevalence of < 1%
  - Originates from distal tibia & passes distally deep to flexor retinaculum
    - Implicated in tarsal tunnel syndrome
  - Inserts onto medial border of calcaneum 1-2 cm anterior to Achilles tendon insertion
    - Similar to accessory soleus in being located anteromedial to Achilles tendon
    - Different to accessory soleus muscle in extending deep to flexor retinaculum
- **Posterior compartment: Deep muscles**
  - **Popliteus muscle**
    - Origin: Tendon from popliteal groove of lateral femoral condyle
    - Passes through popliteal hiatus posteriorly & medially, pierces posterolateral knee capsule
    - Muscle fibers attached to posterior surface of tibia proximal to soleal line
    - Action: Flexes knee & medially rotates tibia with respect to femur at onset of flexion, i.e., unlocks "screw home mechanism"
  - **Tibialis posterior muscle**
    - Origin: Interosseous membrane & adjoining parts of posterior surfaces of tibia & fibula
      - Superior end is bifid enabling anterior tibial vessels to pass forward between both attachments
    - Distally, it inclines medially, under flexor digitorum longus
      - Grooves & curves behind medial malleolus
    - Action: Plantarflexes & inverts foot
  - **Flexor digitorum longus muscle**
    - Origin: Posterior surface of tibia, below popliteus, & medial to vertical ridge
      - Crosses superficial to distal part of tibialis posterior tendon
      - Tendon grooves lower end of tibia lateral to tibialis posterior tendon, passes around medial malleolus to foot
    - Action: Flexes interphalangeal & metatarsophalangeal joints of lateral 4 toes; plantarflexes & inverts foot
  - **Flexor hallucis longus muscle**
    - Origin: Posterior surface of fibula, below origin of soleus
      - Passes medially, descends down posterior to midtibia
      - May be compressed by os trigonum, which is unfused lateral tubercle of posterior talus, found in 20% of population
    - Tendon occupies deep groove on posterior surface of talus, passes around medial malleolus, under sustentaculum tali, to great toe
    - Action: Flexes interphalangeal & metatarsophalangeal joints of great toe; plantarflexes foot
  - **Flexor digitorum accessorius longus muscle**
    - Accessory muscle with prevalence of < 10%
    - Originates from distal tibia or fibula posteriorly & passes down into tarsal tunnel
      - May contain fleshy fibers in tarsal tunnel, which is distinguishing feature
      - ± implicated in tarsal tunnel syndrome
    - Inserts into quadratus plantae or flexor digitorum longus tendon
  - **Peroneocalcaneus internus muscle**
    - Accessory muscle with prevalence of 1%
    - Originates from distal fibula beyond origin of flexor hallucis longus, passes through tarsal tunnel & deep to sustentaculum tali
      - Fully tendinous before it enters tarsal tunnel
      - Not implicated in tarsal tunnel syndrome
    - Inserts onto anterior aspect of calcaneum

ANATOMY IMAGING ISSUES

Imaging Sweet Spots

- Common indication of leg US is suspected muscle tear
  - Most common site of muscle tear is at distal myofascial junction medial belly of gastrocnemius
  - Look carefully for preservation of arrowhead appearance of myofascial junction at this location

AXIAL ANATOMY: LEG

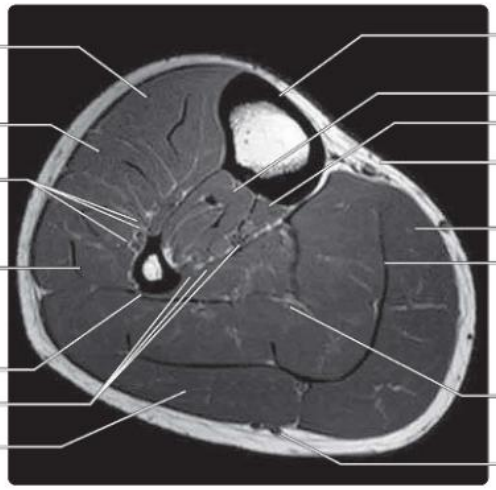

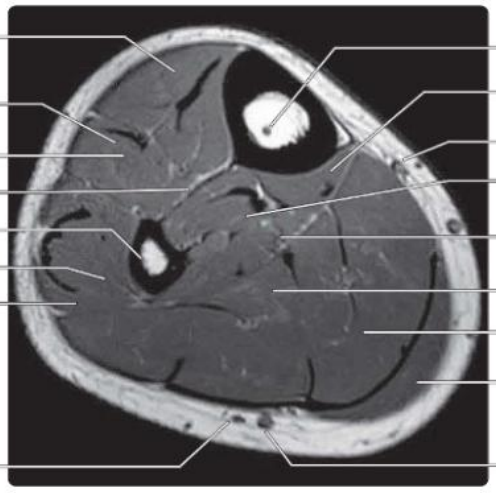

(Top) *Axial T1 MR of the proximal leg shows the common peroneal nerve passing around the fibular neck. The popliteus muscle is the "key" to unlocking the extended knee joint, as it laterally rotates the femur on the tibia by ~ 6° at the start of flexion.* **(Middle)** *Axial T1 MR of the proximal-mid leg shows the interosseous membrane present with the anterior tibial artery and vein as well as the deep peroneal nerve on its anterior surface. The posterior tibialis muscle separates the posterior tibial artery and vein as well as the tibial nerve from the interosseous membrane.* **(Bottom)** *Axial T1 MR of the proximal-mid leg shows the interosseous membrane present with the anterior tibial artery and vein as well as the deep peroneal nerve on its anterior surface. The posterior tibialis muscle separates the posterior tibial artery and vein as well as the tibial nerve from the interosseous membrane.*

AXIAL ANATOMY: LEG

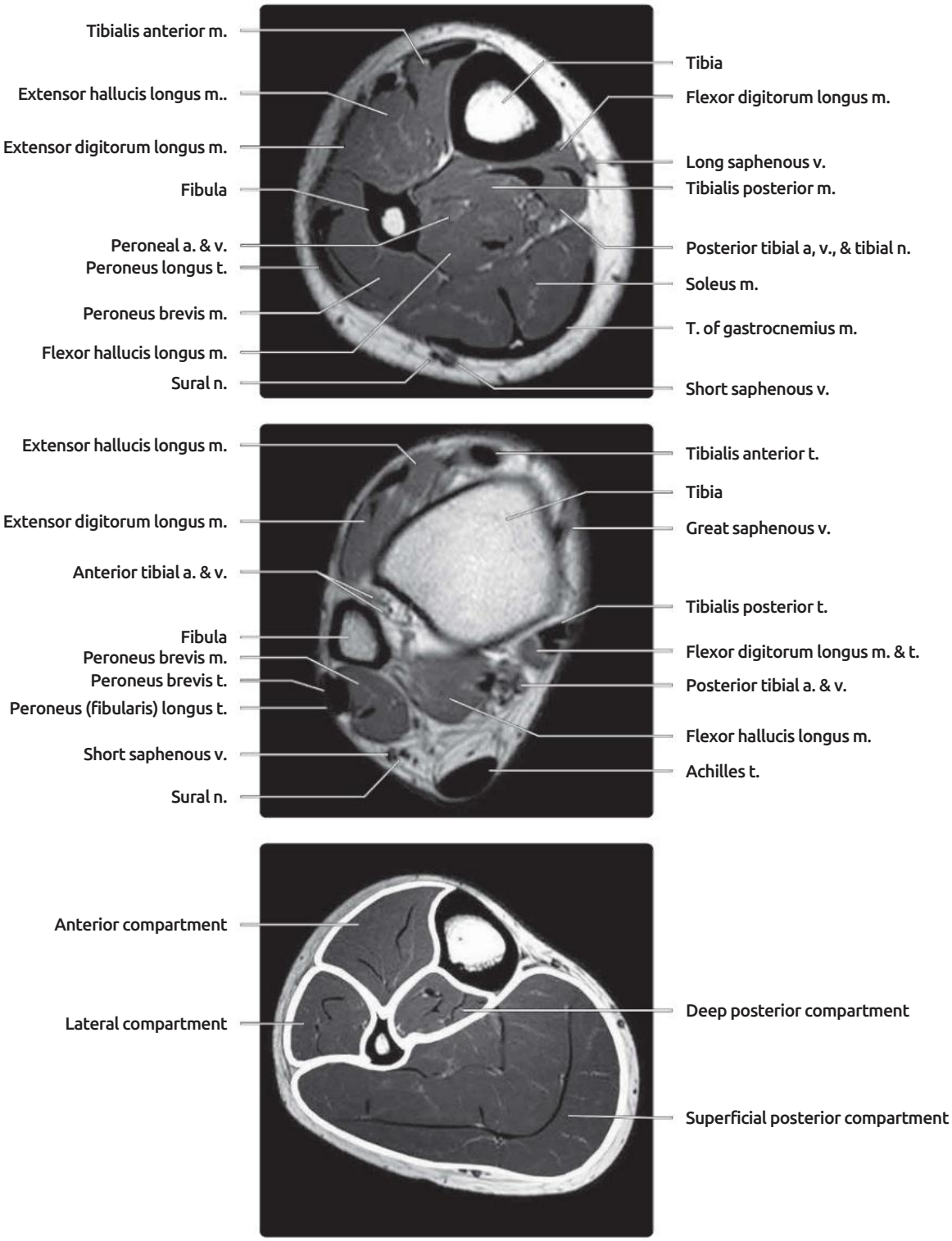

(Top) *Axial T1 MR of the mid-distal leg is shown. This section is just below the level of the medial and lateral belly of gastrocnemius muscle. The peroneus longus muscle is no longer visible at this level; however, there is a large popliteus longus tendon present. All of the muscle lateral to the fibula is the peroneus brevis muscle.* **(Middle)** *Axial T1 MR of the distal leg just above the distal tibiofibular joint shows the interosseous membrane is no longer present at this juncture. The peroneus brevis muscle remains almost to the fibular tip. The large Achilles tendon has formed posteriorly. The sural nerve lies alongside the short saphenous vein between the lateral aspect of the Achilles tendon and the peroneal tendons.* **(Bottom)** *Graphic shows the 4 leg compartments. The anterior compartment contains tibialis anterior, extensor hallucis longus, extensor digitorum longus, and peroneus tertius muscles. The lateral compartment contains peroneus longus and brevis muscles. The deep posterior compartment contains popliteus, flexor hallucis longus, flexor digitorum longus, and tibialis posterior muscles, while the superficial posterior compartment contains gastrocnemius, soleus, and plantaris muscles.*

ANTERIOR COMPARTMENT

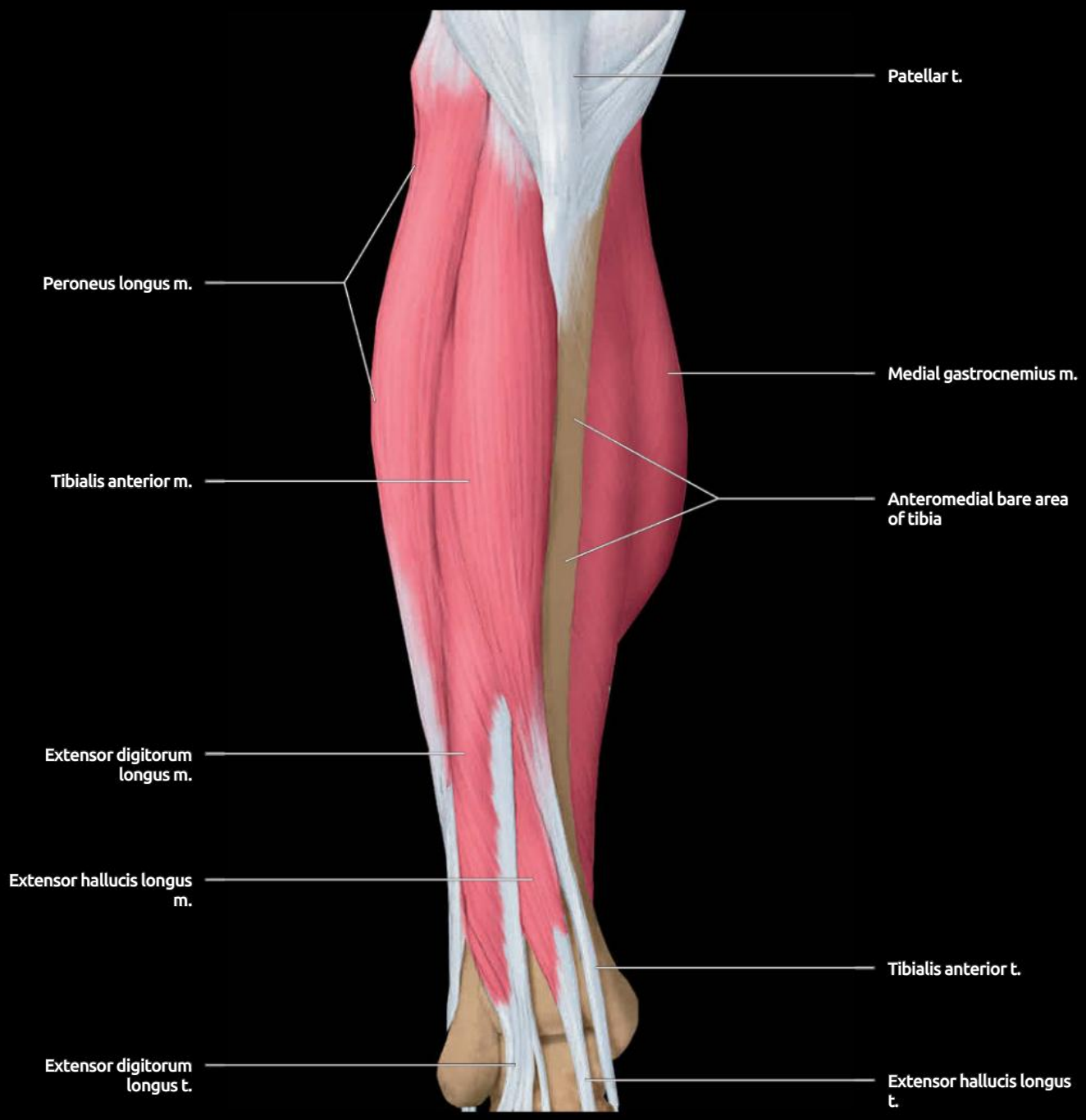

Graphic shows the anterior leg muscles. The entire anteromedial aspect of the tibia is bare of muscle. As a result, it is relatively poorly vascularized, making it prone to slow fracture healing and stress fracture. The tibialis anterior, with an extensive origin from both the tibia and the interosseous membrane, is the most substantial muscle of the anterior compartment. The extensor digitorum longus muscle originates from the fibula. The extensor hallucis longus originates from the fibula and the interosseous membrane. These 3 muscles retain the same orientation as they become tendinous anterior to the ankle.

ANTERIOR COMPARTMENT

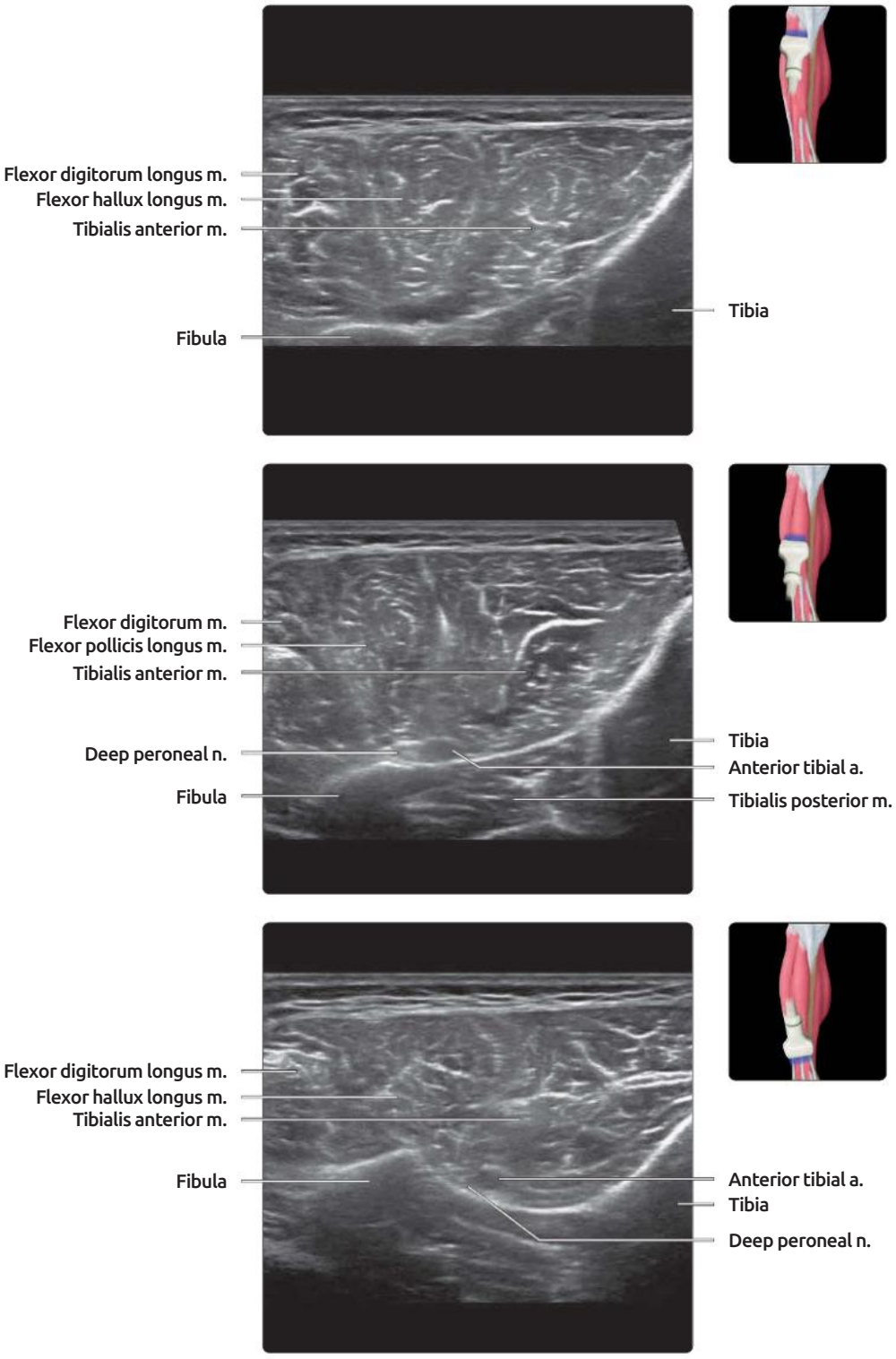

(Top) *Transverse US of the anterior proximal leg shows the 3 anterior compartment muscles. The muscles originate from the anterolateral aspect of the tibia, the interosseous membrane, and the fibula, with the tibialis anterior being the largest muscle.* **(Middle)** *Transverse US of the mid leg level shows how the anterior leg muscles are similarly ordered.* **(Bottom)** *Transverse US of the anterior aspect of the distal leg shows the same muscular arrangement.*

PERONEAL COMPARTMENT

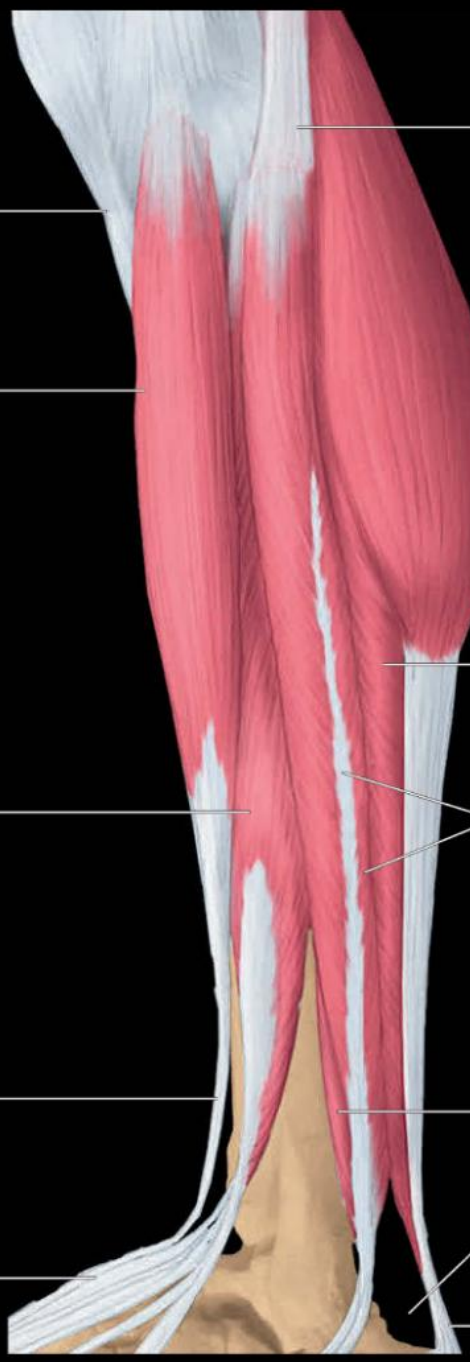

Graphic of the lateral leg shows the anterior compartment (extensors), lateral compartment (peroneals), and superficial muscles of the posterior compartment. As the peroneus brevis lies closest to the bone, it is more prone to trauma, particularly in the retromalleolar region. Typically, this tear consists of a longitudinal split in which the overlying peroneus longus tendon pushes into the peroneus brevis tendon, splitting it into 2 sections. One will then see 3 rather than 2 tendons behind the lateral malleolus. Another reason to see 3 tendons behind the lateral malleolus is when there is a peroneus quartus tendon present.

PERONEAL COMPARTMENT

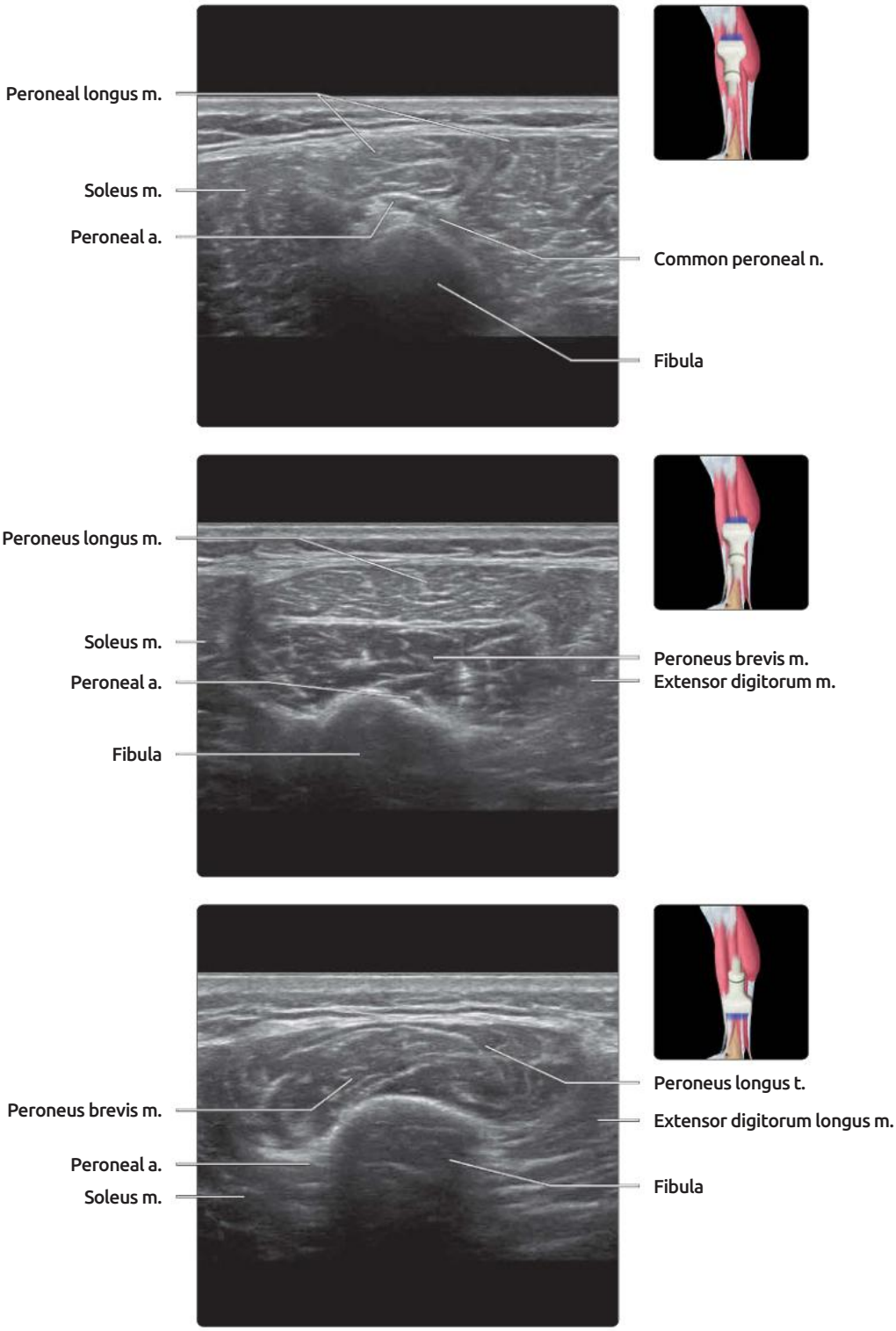

(Top) *Transverse US of the lateral aspect of the proximal 1/3 of the leg shows the peroneal nerve curving around the peroneal neck deep to the peroneus longus muscle. The peroneus longus mainly occupies the proximal 1/2 of the fibula laterally. The peroneus brevis muscle largely occupies the distal 1/2 of the fibula laterally.* **(Middle)** *Transverse US of the lateral aspect of the middle 1/3 of the peroneal compartment laterally is shown. The peroneus brevis muscle emerges between the peroneus longus muscle and the bone.* **(Bottom)** *Transverse US of the lateral aspect of the distal 1/3 of the leg is shown. The peroneus brevis muscle and peroneus longus tendon lie lateral to the distal fibula.*

SUPERFICIAL PERONEAL NERVE

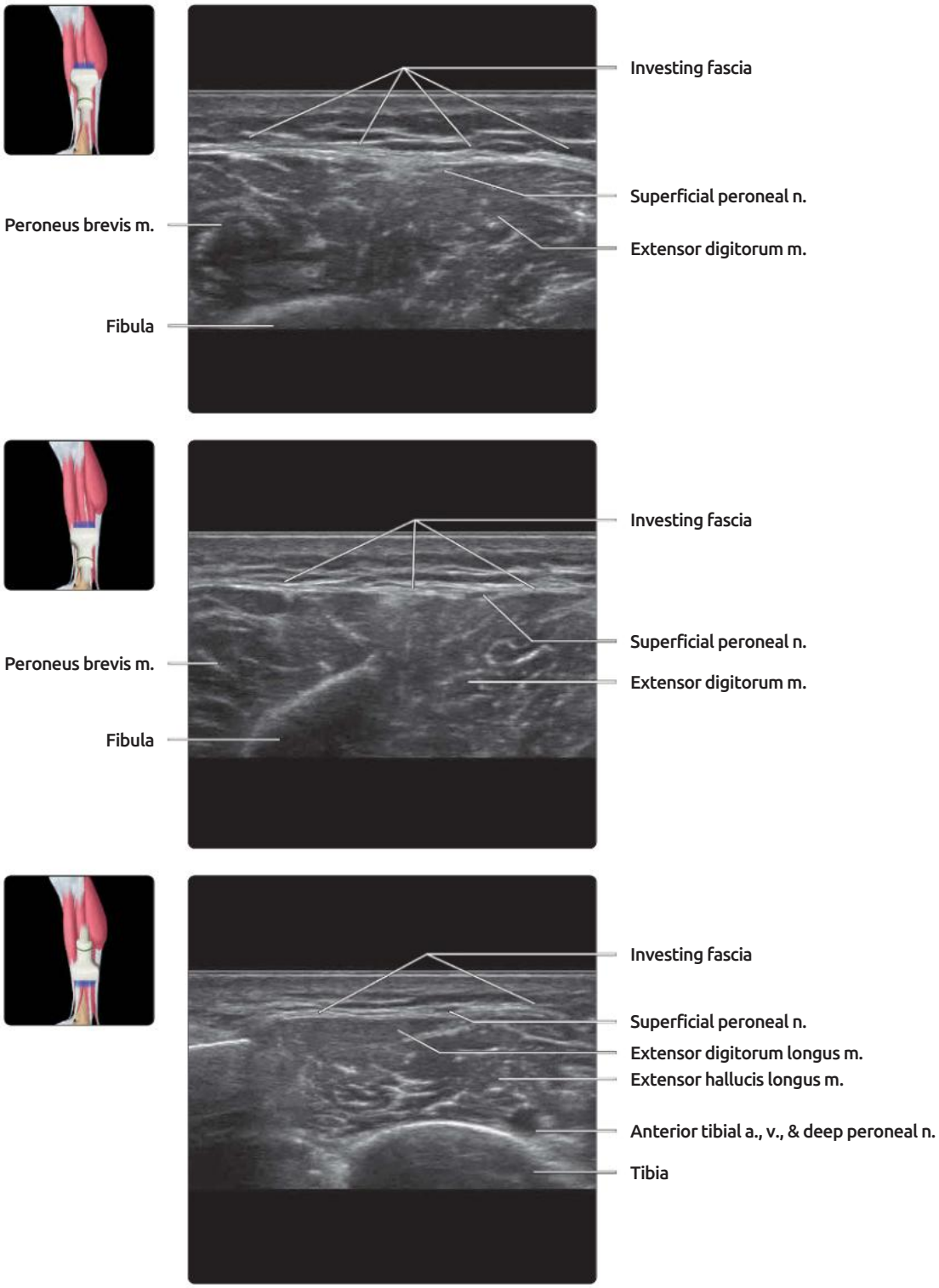

(Top) *Transverse US of the lateral aspect of the midleg shows the superficial peroneal nerve emerging between the peroneus brevis and extensor digitorum muscles ~ 10 cm above the fibular tip. The nerve still lies deep to the investing fascia.* **(Middle)** *Transverse US of the lateral aspect on the mid to distal part of the leg shows the superficial branch of the common peroneal nerve passing through the investing fascia of the leg. Traction on the investing fascia due to inversion injury of the ankle can cause a traction injury of the nerve as it passes though the fascia.* **(Bottom)** *Transverse US of the lateral aspect of the distal part of the leg shows the superficial branch of the common peroneal nerve now lying superficial to the investing fascia of the leg.*

POSTERIOR COMPARTMENT

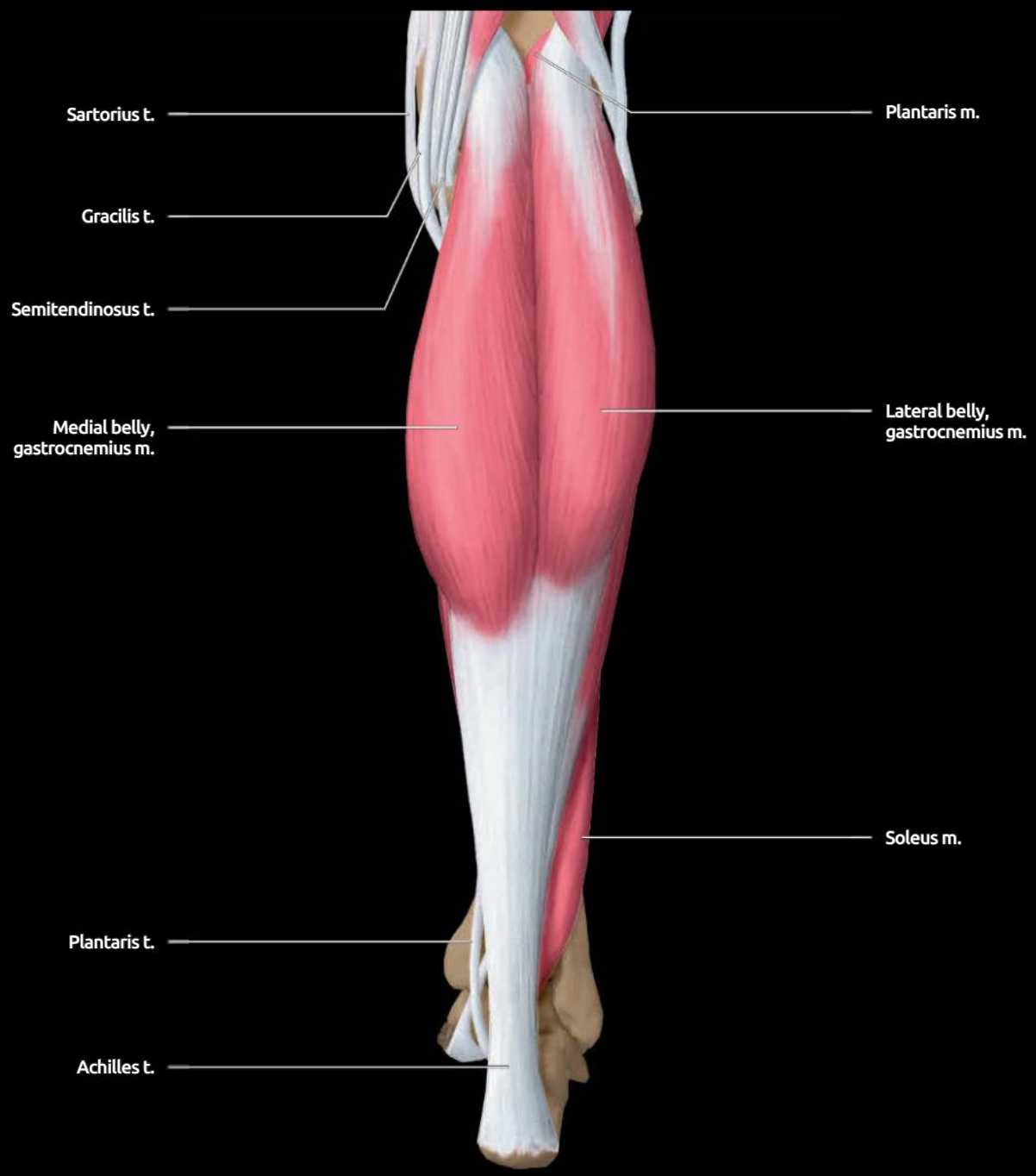

Graphic shows the superficial muscles and tendons of the posterior leg. The gastrocnemius muscles are bulky in the proximal 1/2 of the leg and taper to an aponeurosis, which blends with the soleus tendon more distally to become the Achilles tendon.

POSTERIOR COMPARTMENT

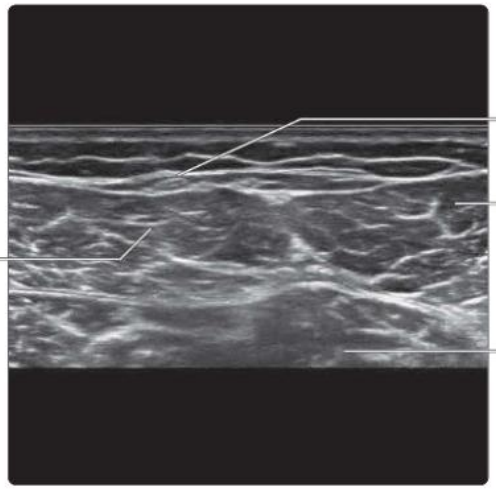

(Top) *Transverse US of the proximal aspect of the posterior compartment of the leg is shown.* **(Middle)** *Transverse US of the posterior aspect of the mid-lower leg is shown.* **(Bottom)** *Longitudinal US shows at midcalf the distal myofascial junction insertion of the medial belly of gastrocnemius muscle. This is the most common site of a calf muscle tear ("tennis leg").*

POSTERIOR COMPARTMENT

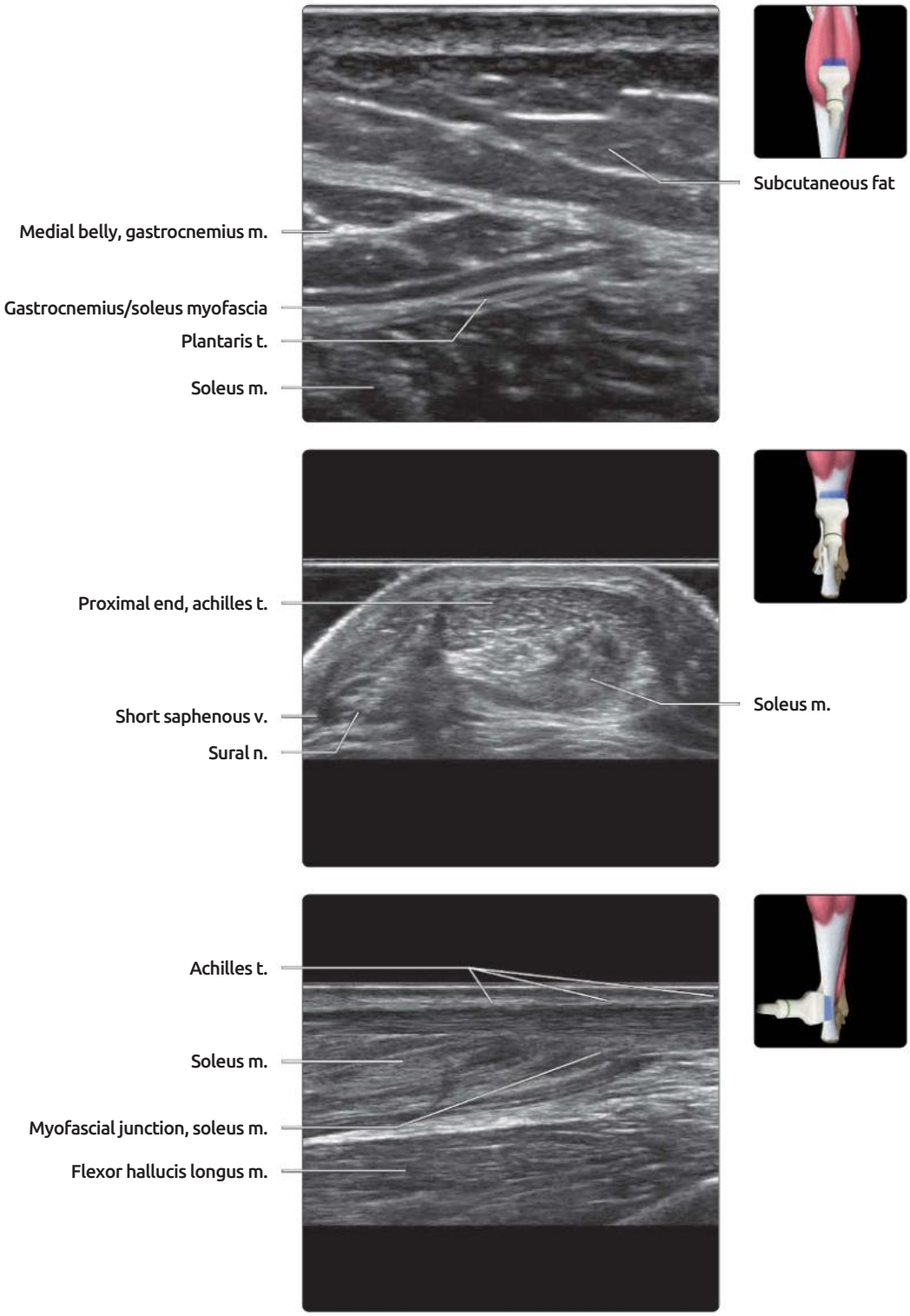

(Top) *Transverse US of the posterior aspect of the midleg shows the narrow plantaris tendon located between the gastrocnemius and soleus myofascial layers deep to the medial border of the gastrocnemius muscle.* **(Middle)** *Transverse US of the distal leg shows the soleus musculotendinous junction forming the Achilles tendon. The short saphenous vein and accompanying sural nerve are also shown.* **(Bottom)** *Longitudinal US of the posterior aspect of the distal leg shows the soleus myofascial junction.*

GROSS ANATOMY

Sciatic Nerve

- Comprises common peroneal & tibial nerves

Common Peroneal Nerve

- Smaller of 2 terminal divisions of sciatic nerve
- Separates from tibial nerve midthigh, at superior angle of popliteal fossa
- Leaves popliteal fossa by passing posterior to head of fibula
- Winds in subcutaneous tissues around lateral aspect of fibular neck
  - Passes into fibular tunnel between fibular neck & peroneus longus aponeurosis
  - After exiting fibular tunnel, nerve trifurcates into 3 terminal branches (articular, deep, & superficial)
    - **Recurrent articular branch**
      - Extends to proximal tibiofibular joint
      - Acts as intraneural conduit for transmission of ganglion arising from joint
    - **Deep peroneal nerve**
      - Pierces anterior intermuscular septum & extensor digitorum longus to enter anterior compartment
      - Descends between tibialis anterior & long extensors supplying anterior compartment muscles
      - 1.5 cm proximal to ankle, divides into medial sensory & lateral motor branches
      - Passes deep to extensor retinaculum & is crossed by extensor hallucis longus tendon
      - Traverses ankle alongside dorsalis pedis artery
      - Medial sensory branch runs alongside dorsalis pedis artery to 1st web space; crossed by extensor hallucis brevis tendon in midfoot
      - Lateral motor branch runs alongside lateral tarsal artery to supply extensor digitorum brevis, tarsal joints, & 2nd-4th metatarsophalangeal joints
    - **Superficial peroneal nerve**
      - Descends in substance of peroneus longus until it reaches peroneus brevis
      - Passes obliquely over anterior border of brevis to descend in groove between peroneus brevis & extensor digitorum longus
      - 10 cm proximal to fibular tip, it pierces deep fascia to enter subcutaneous tissues & divide into intermediate & medial dorsal cutaneous nerves

Tibial Nerve

- Runs along midaxis of popliteal fossa between 2 heads of gastrocnemius
- Descends under fascial septum between deep & superficial posterior muscle compartments of leg
  - In upper 2/3 of leg, lies on fascia of tibialis posterior & flexor digitorum longus
  - In lower 1/3 of leg, located midway between Achilles tendon & medial border of tibia
- Crosses posterior surface of ankle joint alongside posterior tibial vessels
- At medial ankle, under flexor retinaculum within tarsal tunnel, divides into lateral & medial plantar nerves
  - 1st branch of lateral plantar nerve is inferior calcaneal nerve (Baxter nerve)
    - Neuritis of this nerve, which supplies calcaneal periosteum, can simulate plantar fasciitis
  - Medial plantar nerve may compress between navicular bone & abductor hallucis muscle ("jogger's foot")

Saphenous Nerve

- Longest branch of femoral nerve, arises 2 cm below inguinal ligament & descends with superficial femoral artery via adductor canal
- Passes posterior to sartorius posteromedial to knee before piercing deep fascia to subcutaneous tissues
- In leg, accompanies long saphenous vein

Sural Nerve

- Purely sensory nerve arises in midcalf with contributions from tibial & common peroneal nerves
- Runs in posterior midline subcutaneous fat with short saphenous vein
- 12 cm proximal to heel, it passes to lateral side of Achilles tendon & descends behind lateral malleolus
- Provides sensory innervation to lateral aspect of ankle & lateral aspect of foot

ANATOMY IMAGING ISSUES

Imaging Approaches

- **Common peroneal nerve**
  - Best located posterior & lateral to fibular head & neck
  - Most frequently entrapped around fibular neck
    - Thick arch of peroneus longus aponeurosis, fracture, trauma, osteophytosis, & ganglia
      - Compressed nerve may appear enlarged proximally
      - Compression may be dynamic
- **Tibial nerve**
  - Best located between 2 heads of gastrocnemius in proximal calf, alongside posterior tibial artery in mid- to distal calf, & beneath medial malleolus at ankle
  - Entrapped in tarsal tunnel
    - Talocalcaneal hyperostosis, synovitis, ganglia, or accessory muscles
      - Encroachment onto tibial nerve seen, but tibial nerve caliber usually normal
- **Deep peroneal nerve**
  - Best located in lower leg between anterior tibial artery & tibialis anterior muscle
  - Entrapped deep to extensor retinaculum, by extensor hallucis longus tendon, midfoot osteophytosis, or extensor hallucis brevis tendon
- **Superficial peroneal nerve**
  - Best located in fat plane between anterior & lateral compartments of distal leg
  - Entrapped passing through deep fascia of distal leg
    - Stretching injury to fascia during ankle trauma
      - Fascial thickening ± nerve thickening
- **Saphenous nerve**
  - Best located near knee alongside long saphenous vein 10 cm proximal to posteromedial knee or near ankle between medial malleolus & anterior tibialis tendon
- **Sural nerve**
  - Best located subcutaneously alongside short saphenous vein between lateral malleolus & Achilles tendon

ANTERIOR & POSTERIOR LEG NERVES

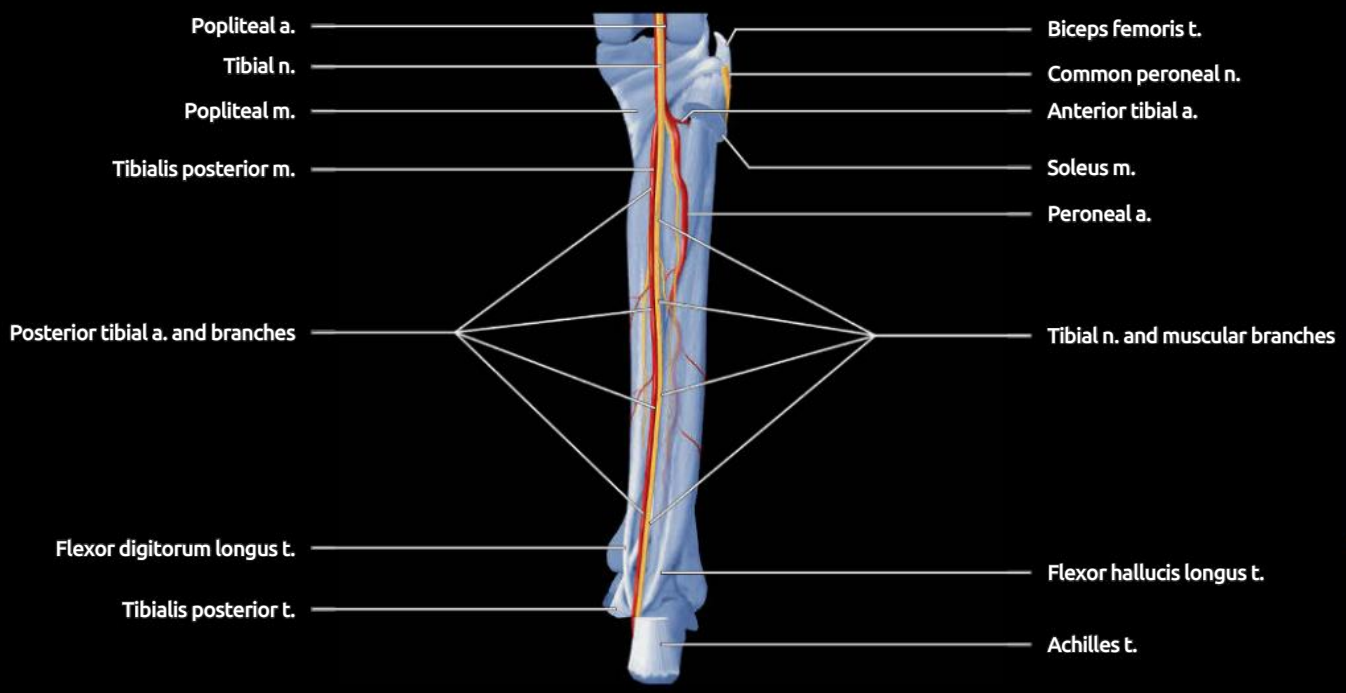

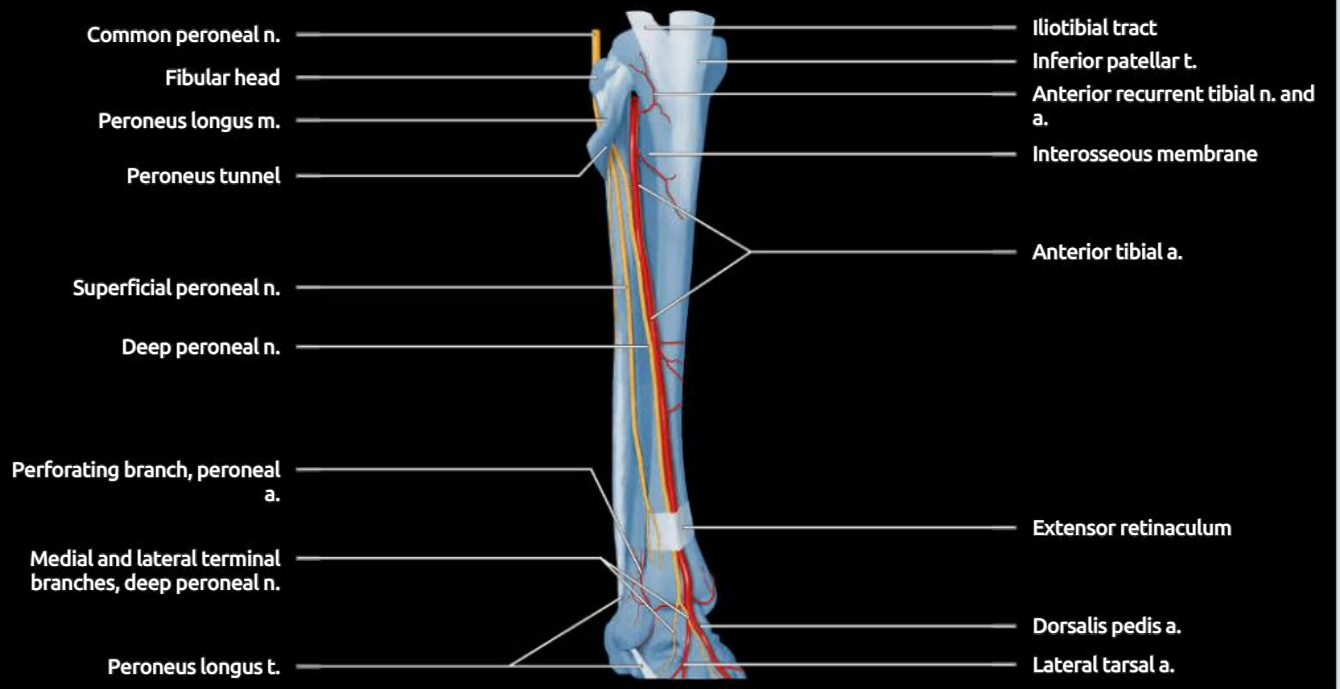

(Top) *Graphic shows posterior leg nerves and arteries. The sciatic nerve divides into common peroneal and tibial branches. The common peroneal nerve then follows the biceps femoris around the lateral fibular neck. The tibial nerve descends between the deep and superficial posterior leg muscles, paralleling the posterior tibial artery.* **(Bottom)** *Graphic of the anterior leg shows the common peroneal nerve extending through the peroneal tunnel (between the peroneus longus tendon and the fibular neck), branching into deep and superficial components. Both have muscular branches along their length. The deep peroneal nerve parallels the anterior tibial artery and terminates in the medial and lateral branches to the dorsum of the foot and ankle, respectively.*

TIBIAL NERVE

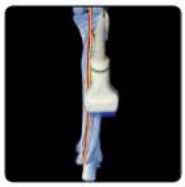

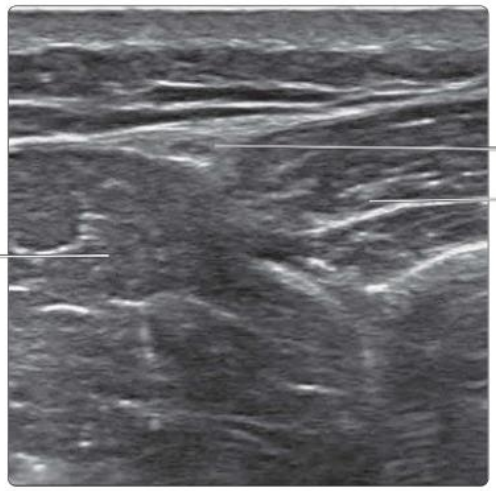

(Top) *Transverse US shows the proximal aspect of the popliteal fossa. The tibial nerve demonstrates the typical neural signature of small, black dots within a bright matrix. It lies superficial to the popliteal artery and vein, which are partially effaced.* **(Middle)** *Transverse US at the proximal end of the popliteal fossa shows the common peroneal nerve, having branched from the tibial nerve, alongside the biceps femoris muscle as it moves laterally toward the fibular head. At the fibular head area, it will divide into superficial and deep branches. It also gives rise to an articular branch to the proximal tibiofibular joint.* **(Bottom)** *Transverse US of the lateral aspect of the leg ~ 10 cm proximal to the lateral malleolus shows the superficial peroneal nerve just deep to the crural fascia at the interspace between the peroneus brevis and the extensor digitorum longus muscles.*

PERONEAL NERVE

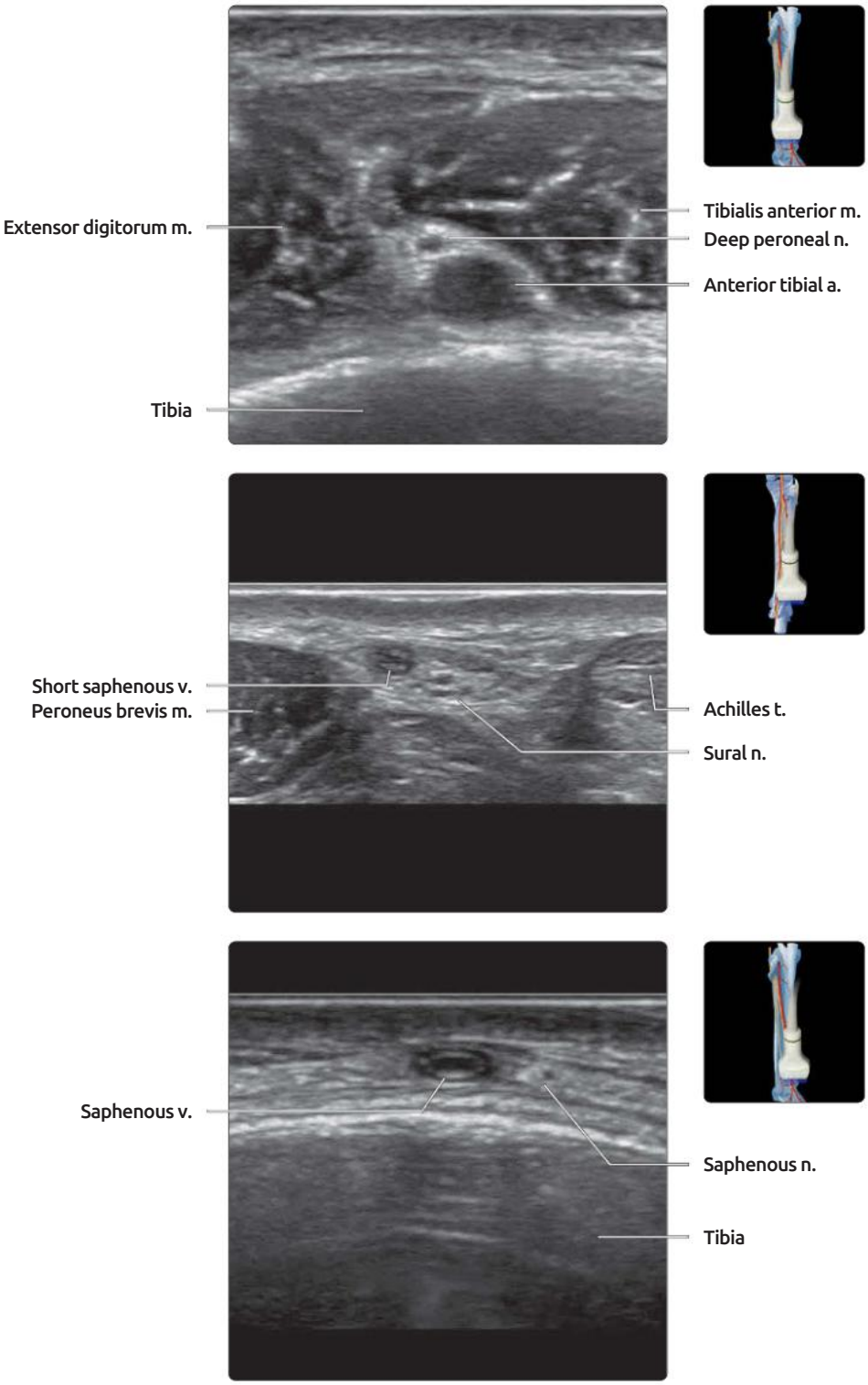

(Top) *Transverse US of the leg just proximal to the ankle joint shows the deep peroneal nerve passing superficial to the anterior tibial artery. The deep peroneal nerve passes from the medial to the lateral side of the anterior tibial artery as it approaches the ankle joint.* **(Middle)** *Transverse US of the distal leg posterolaterally shows the sural nerve lateral to the small saphenous vein. This vein, which lies between the peroneus brevis muscle and the Achilles tendon, acts as a good marker for the sural nerve. The sural nerve provides sensory sensation to the lateral ankle region and lateral aspect of the foot.* **(Bottom)** *Transverse US at the anteromedial aspect of the ankle shows the saphenous nerve medial to the great saphenous vein. This nerve, which is difficult to demarcate clearly from the surrounding subcutaneous fat with US, lies between the medial malleolus and the tibialis anterior muscle.*

GROSS ANATOMY

Osseous Anatomy

- **Ankle (talocrural) joint**
  - Tibia, fibula, & talus form synovial joint
  - Supported by lateral & medial collateral ligaments
  - Mainly uniaxial hinge joint with dorsi- & plantar flexion
- **Distal tibiofibular joint**
  - Fibrous joint (syndesmosis)
  - Supported by syndesmotic ligaments
  - Synovial recess from ankle joint extends into distal tibiofibular joint
  - May have articular cartilage at far distal margin
  - Minimal stretch during dorsiflexion allows increase in malleolar gap & slight fibular lateral rotation

Ligaments

- 3 sets bind ankle: Distal tibiofibular syndesmotic complex, lateral collateral ligaments, & deltoid ligaments
- **4 tibiofibular syndesmotic ligaments**
  - **Anterior & posterior tibiofibular ligaments**
    - Extend obliquely between anterior & posterior tibial & fibular tubercles, widest at tibial attachment
    - Inferior fascicle of anterior tibiofibular ligament known as Bassett ligament
      - Can cause ankle impingement if thickened to ~ 2.5 mm
      - Tends to thicken in association with osteochondral lesions of talar dome
  - **Transverse ligament**: From fibula to distal tibia
    - May partially coalesce with posterior talofibular ligament
  - **Interosseous ligament**: Distal thickening of interosseous membrane
    - 1 cm above ankle joint
- **3 lateral collateral ligaments**
  - **Anterior talofibular ligament (ATFL)**
    - Originates from anterior aspect of lateral malleolar tip & inserts on talar neck; 2 mm thick
    - Superior & inferior fascicles
      - 1 fascicle (25%), 2 fascicles (65%), & 3 fascicles (10%)
    - Stabilizes talus against anterior displacement, internal rotation, & inversion
    - Weakest, most commonly torn ankle ligament
      - Tear of only superior fascicle → microinstability
      - Tear of all fascicles → clinical instability
    - Rich arterial supply → occasionally large hematoma with tear
  - **Calcaneofibular ligament (CFL)**
    - Originates from lateral malleolar tip and inserts on calcaneal trochlear eminence
      - Runs deep to peroneal tendons
    - Lateral restraint of subtalar joint
    - Lateral ankle sprain: ATFL tears first followed by CFL
      - CFL rarely tears in isolation
  - **Posterior talofibular ligament**
    - Extends from lateral malleolar fossa to lateral talar tubercle
    - Strongest ligament, rarely tears
- **Deltoid ligament (medial collateral ligament)**
  - Fan-shaped; originates from anterior, apex, & posterior aspects of medial malleolus; inserts on talus, sustentaculum tali, spring ligament, & navicular bone
  - Deep: Anterior & posterior tibiotalar bands
  - Superficial: Tibiocalcaneal, tibiospring, tibionavicular, & posterior tibiotalar (variable) bands
- **Spring ligament (plantar calcaneonavicular ligament)**
  - Binds calcaneus to navicular; 3 components
    - **Superomedial**: Sustentaculum tali → superomedial navicular & tibiospring deltoid ligament
    - **Medioplantar oblique**: Calcaneal coronoid fossa → inferomedial navicular
    - **Inferoplantar longitudinal**: Coronoid fossa → inferolateral navicular

Retinacula

- Focal thickening of deep fascia
- Prevent bowstringing of tendons & binds downs extensor muscles near ankle
- **Superior extensor retinaculum**
  - Few cm above ankle joint
  - Attaches to anterior fibula laterally & tibia medially
  - Proximally continual with crural fascia
  - Distally attaches to inferior extensor retinaculum
- **Inferior extensor retinaculum**
  - At ankle joint, Y-shaped, stem laterally, proximal & distal bands medially
  - Stem attaches laterally to upper calcaneus
    - Loops around extensor tendons
    - Roots extend into sinus tarsi
  - Proximal medial band has deep & superficial layers, which loop around extensor hallucis longus tendon & occasionally tibialis anterior tendon
  - Distal medial band lies superficial to extensor hallucis longus & tibialis anterior tendons
    - Attaches to plantar aponeurosis
  - Dorsalis pedis vessels & deep peroneal nerve run deep to all layers of inferior extensor retinaculum
- **Flexor retinaculum**
  - Attaches to medial malleolus
  - Proximally continuous with deep crural fascia of leg
  - Distally continuous with plantar aponeurosis
  - Abductor hallucis muscle partly attached to it
  - Binds deep flexor tendons to tibial & calcaneal grooves
  - Forms lateral border of tarsal tunnel
- **Superior peroneal retinaculum**
  - Origin: Lateral malleolus & inserts into crural fascia of leg & calcaneus
  - Binds peroneal tendons into retrofibular groove
- **Inferior peroneal retinaculum**
  - Continuous with inferior extensor retinaculum
  - Inserts on peroneal tubercle & forms inferior peroneal tunnel
    - Separates & binds peroneus brevis & longus tendons to calcaneus

Tendons

- **Anterior (extensor) compartment**
  - **Tibialis anterior tendon**

- Most medial & largest tendon in anterior compartment
- Inserts on medial cuneiform & base of 1st metatarsal
- Dorsiflexes ankle, inverts foot, tightens plantar aponeurosis
- Supports medial longitudinal arch during walking

- **Extensor hallucis longus tendon**
  - Inserts on dorsal base of 1st distal phalanx
  - Extends 1st metatarsophalangeal (MTP) joint & dorsiflexes foot
- **Extensor digitorum longus tendon**
  - Divides into 4 slips on dorsum of foot
  - Slips receive tendinous contributions from extensor digitorum brevis, lumbricals, & interosseous muscles
  - Each slip divides into 3: Central slip inserts on dorsal base of middle phalanx & 2 collateral slips, which reunite & insert on bases of 2nd-5th distal phalanges
  - Dorsiflexes ankle, extends toes, tightens plantar aponeurosis
- **Peroneus tertius tendon**
  - Typically part of extensor digitorum longus tendon
  - Inserts on dorsal base of 5th metatarsal

- **Lateral compartment**
  - **Peroneus longus tendon**
    - Posterolateral to peroneus brevis tendon in retrofibular groove, deep to superior peroneal retinaculum
      - Groove deepened by triangular fibrocartilaginous lip, which is adherent to fibular cortex
    - Proximally has common tendon sheath with peroneus brevis
    - Separate tendon sheaths beyond fibular tip
    - Descends inferior to peroneal tubercle, deep to inferior peroneal retinaculum
    - Curves in cuboid groove deep to long plantar ligament
    - Inserts on plantar base of 1st metatarsal & medial cuneiform bones
    - Plantarflexes ankle, everts foot, supports longitudinal & transverse arches during walking
    - Os peroneum in 20% of individuals
  - **Peroneus brevis tendon**
    - Anteromedial to peroneus longus tendon in retrofibular groove, deep to superior peroneal retinaculum
    - Descends superior to peroneal tubercle of calcaneus, deep to inferior peroneal retinaculum
    - Inserts into base of 5th metatarsal
    - Everts foot, limits foot inversion
    - Peroneal brevis & longus tendons lie above & below peroneal tubercle
      - Peroneal tubercle may hypertrophy
- **Superficial posterior compartment**
  - **Achilles tendon**
    - Largest & strongest tendon in body
    - Most common tendon to rupture
    - Conjoint tendon of medial & lateral gastrocnemius & soleus muscles
      - Medial head of gastrocnemius forms more posterior fibers & lateral head of anterior fibers
      - Soleus contributes to central & medial areas of Achilles tendon
    - Partially enclosed by paratenon
    - Inserts into posterior calcaneal tuberosity
    - Crescent-shaped calcaneal insertion
    - Retrocalcaneal bursa between distal tendon & calcaneal tuberosity
    - Main plantar flexor of ankle & foot
    - Midsection of Achilles tendon is supplied by peroneal artery
    - Proximal & distal portions supplied by posterior tibial artery
- **Plantaris tendon**
  - Slender tendon, medial to Achilles tendon
  - Merges with Achilles tendon or inserts to calcaneum
- **Deep posterior (flexor) compartment**
  - **Tibialis posterior tendon**
    - Crosses flexor digitorum longus tendon above ankle joint to become most posteromedial tendon
    - Shares tibial groove with flexor digitorum longus tendon
    - Inserts on navicular tuberosity, cuneiforms, bases of 2nd-4th metatarsals
    - Main invertor of foot, aids in plantar flexion
    - Supports medial longitudinal arch
  - **Flexor digitorum longus tendon**
    - Lateral to tibialis posterior tendon in tibial groove
    - Crosses flexor hallucis longus tendon at knot of Henry with exchange of tendon fibers at this crossing
    - Divides into 4 slips, which give origin to lumbricals
    - Slips pass through openings in corresponding tendons of flexor digitorum brevis
    - Slips insert on bases of 2nd-5th distal phalanges
    - Flexes distal phalanges, helps ankle plantar flexion
  - **Flexor hallucis longus tendon**
    - Traverses 3 fibroosseous tunnels: Between medial & lateral talar tubercles, under sustentaculum tali, & between medial & lateral sesamoid bones
    - Crosses & sends slip to flexor digitorum longus at knot of Henry
    - Inserts on base of 1st distal phalanx
    - Weak plantar flexor of ankle

ANATOMY IMAGING ISSUES

Imaging Recommendations

- **US**
  - As accurate as MR in revealing tendon & ligament pathology
  - Most tendons best assessed in short axis
    - Preinsertional portion of posterior tibialis tendon best assessed in long axis
  - Follow tendons one by one around malleoli
    - Do not follow more than 1 tendon at a time
  - Achilles tendon best assessed in long axis
    - If tear found, mark position of tear on skin as helpful for surgical planning
  - Ligaments best assessed in long axis
    - Previously torn ligaments can remain swollen for years
    - Reparative periligament fibrosis may cause impingement

ANTERIOR ANKLE

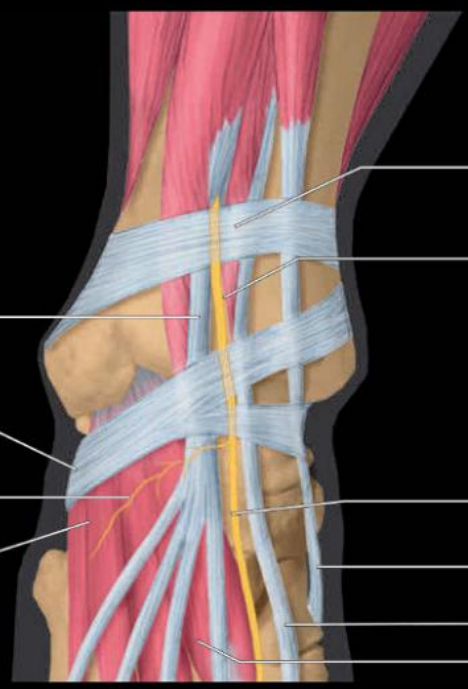

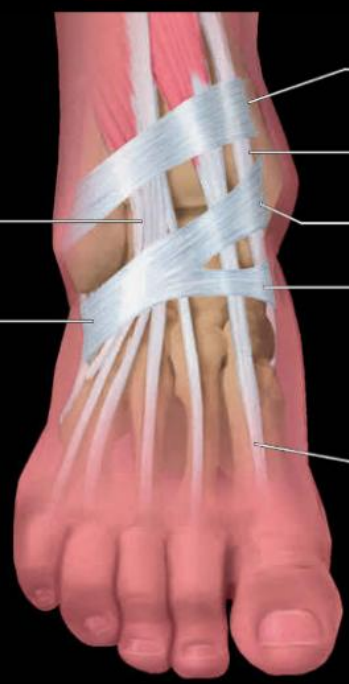

(Top) *Graphic of anterior ankle shows how the deep peroneal nerve passes deep to the superior and inferior extensor retinacula alongside the anterior tibial artery (not shown). It gives off a lateral motor branch to the extensor digitorum brevis muscle. The medial branch continues along the medial longitudinal arch to provide mainly sensory, but some motor, supply to the 1st webspace.* **(Bottom)** *Graphic of anterior ankle and foot shows how the tibialis anterior tendon inserts on the medial cuneiform and the base of the 1st metatarsal bone. This tendon can be bifid distally as a normal feature. Tendinosis and partial tears most commonly affect the medial cuneiform rather than the metatarsal insertion. There is a small bursa between the tibialis anterior tendon and the median cuneiform bone. The extensor digitorum and extensor hallucis tendons insert on the digits. The extensor tendons are held in place by the superior and inferior extensor retinacula.*

ANTERIOR ANKLE

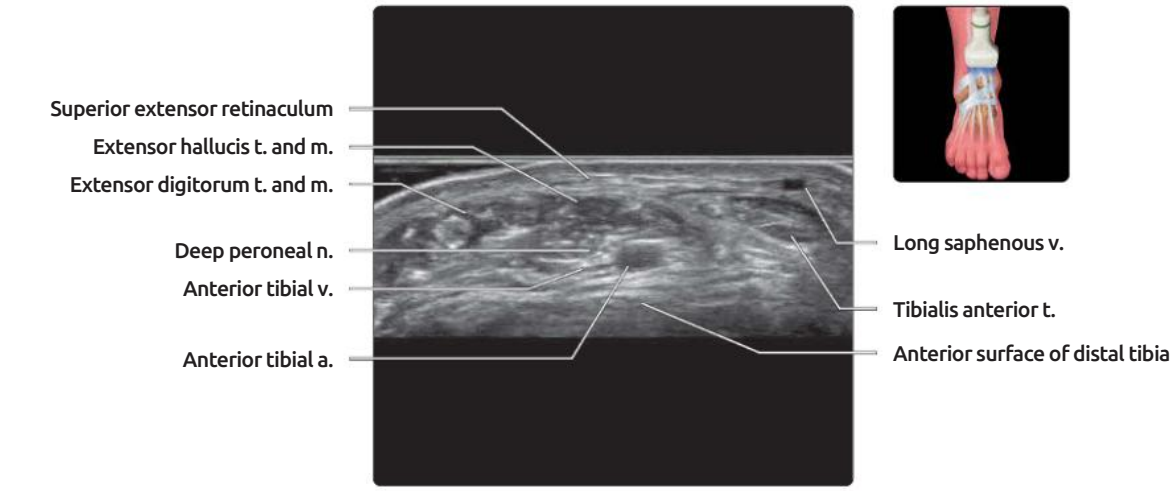

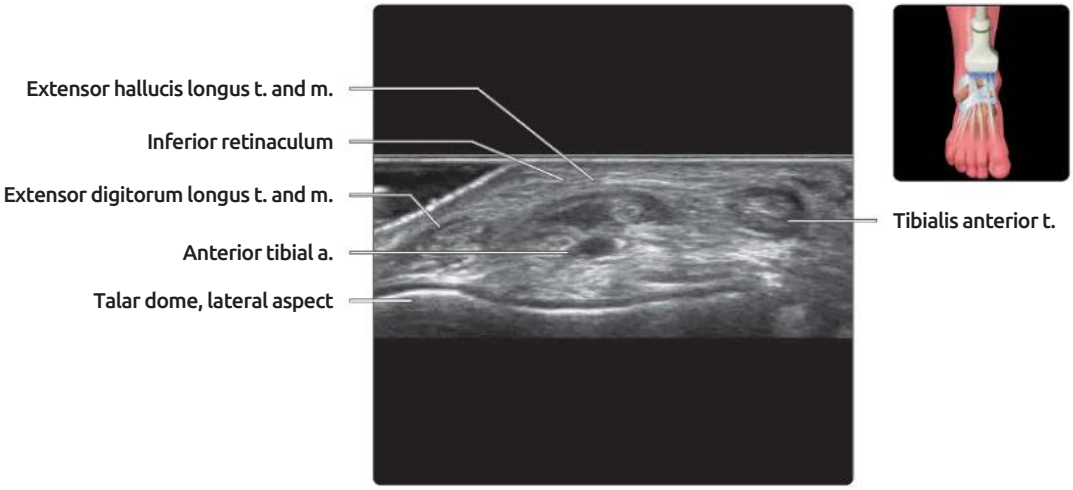

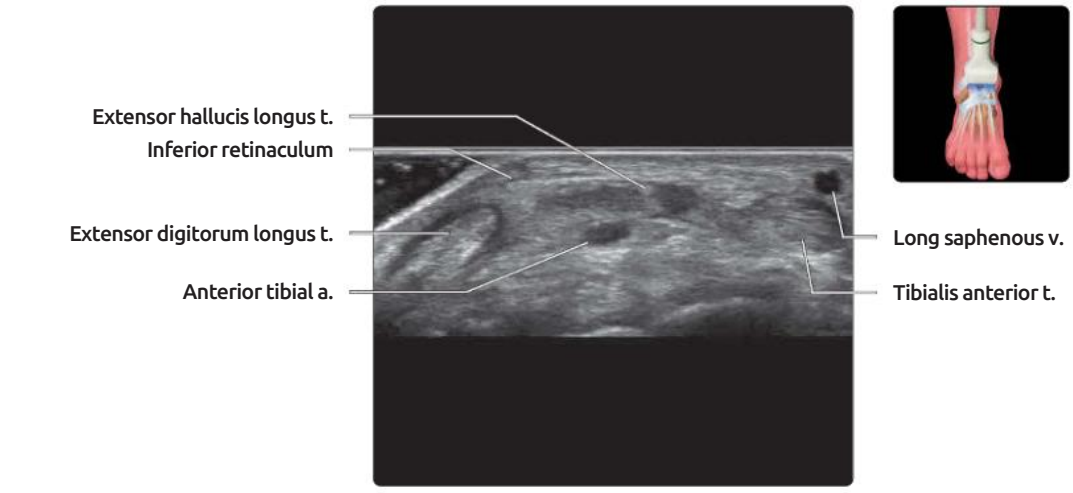

(Top) *Transverse US above the level of the ankle joint shows the relationship of the main structures anterior to the ankle. From medial to lateral, the structures are the tibialis anterior, extensor hallucis longus (EHL), anterior tibial artery and vein, deep peroneal nerve, and extensor digitorum longus (EDL) tendon.* **(Middle)** *Transverse US at the level of the ankle joint is shown. At this level, the inferior retinaculum is present. The superior retinaculum is located proximal to the ankle joint. The lateral aspect of the talar dome is positioned more anteriorly than the medial aspect. The anterior tibial neurovascular bundle, including the deep peroneal nerve, lies deep to the EHL tendon and muscle. The musculotendinous junction of EHL and EDL is at the level of the ankle joint, while the tibialis anterior musculotendinous junction lies more proximally.* **(Bottom)** *Transverse US just distal to the ankle joint is shown. The inferior retinaculum is still visible. The long saphenous vein lies on the medial aspect of the ankle.*

LONGITUDINAL ANTERIOR ANKLE

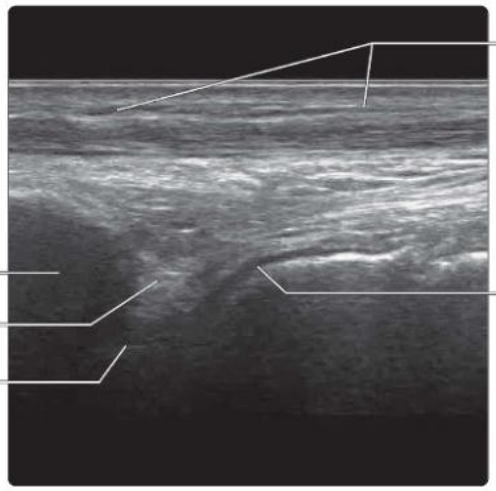

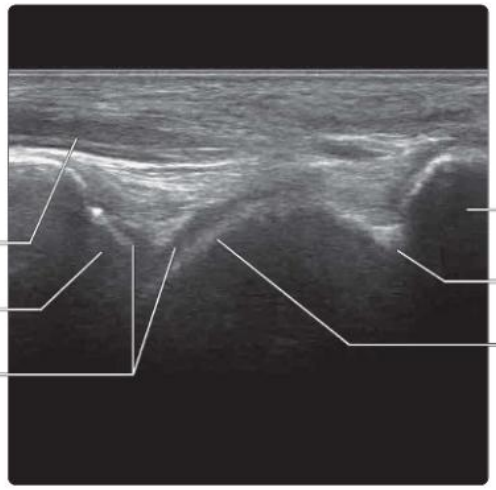

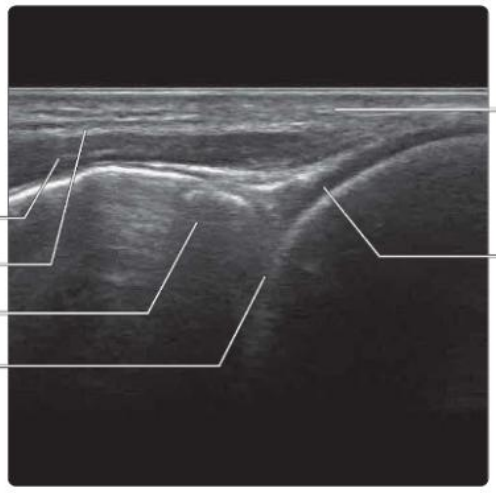

(Top) *Longitudinal US shows the tibialis anterior tendon anterior to the medial aspect of the ankle joint. The medial aspect of the ankle joint is farther from the skin than the lateral aspect.* **(Middle)** *Longitudinal US at the middle of the ankle joint shows the anterior fat pad, which is intracapsular but extrasynovial, separating the anterior ankle recess into superior and inferior recesses. The anterior ankle capsule extends from the anterior aspect of the distal tibia to the talar neck. The anterior recess will distend with large ankle joint effusions compressing the anterior fat pad.* **(Bottom)** *Longitudinal US shows the extensor digitorum tendon deep to the superior and inferior retinacula on the lateral aspect of the ankle joint. The close proximity between the lateral aspect of the ankle joint and the skin can be appreciated.*

MEDIAL & CORONAL ANKLE

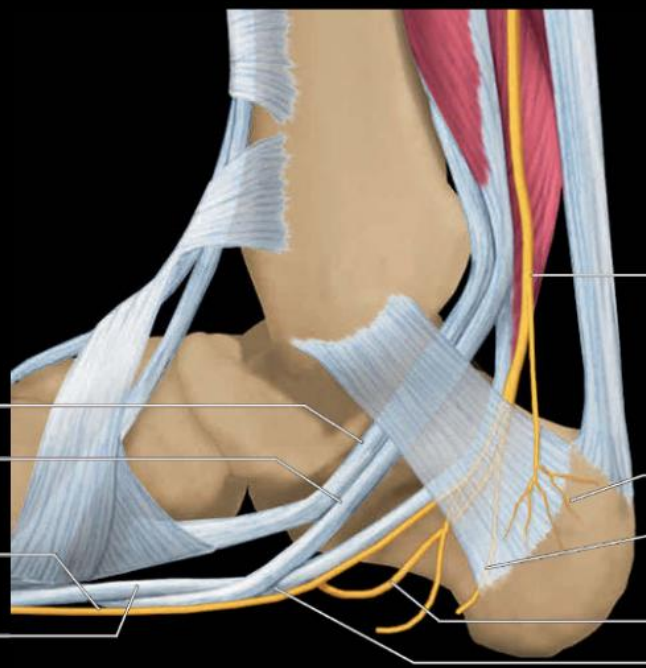

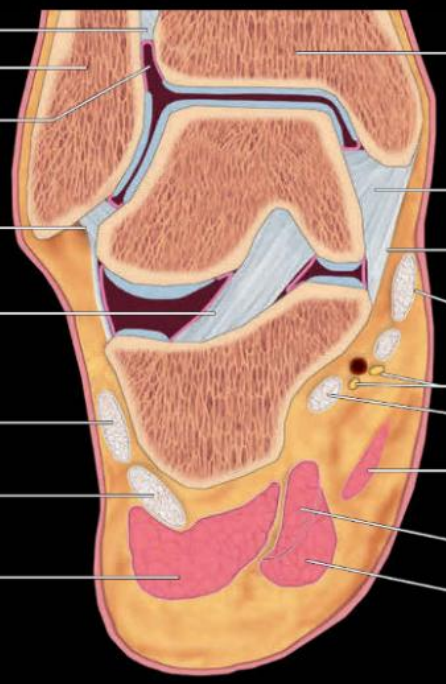

(Top) *Graphic shows the tarsal tunnel deep to the flexor retinaculum on the posterior and inferior aspects of the medial malleolus. The medial calcaneal nerve supplies the skin of the medial aspect of the heel. The medial plantar nerve supplies the 3 medial flexor muscles (flexor hallucis brevis, abductor hallucis, flexor digitorum brevis), and 1st lumbrical muscles and receives sensory innervation from the medial 2/3 of the plantar foot. The lateral plantar nerve supplies all other plantar muscles, including the 2nd-4th lumbricals, plus sensation from the lateral 1/3 of the plantar foot. The inferior calcaneal nerve (Baxter nerve) receives sensory innervation from the heel and mainly supplies the abductor digiti minimi muscle.* **(Bottom)** *Graphic shows how the medial malleolus is connected via the deep and superficial components of the deltoid ligament to the hind- and midfoot. The tibialis posterior tendon passes over the deltoid ligament as it curves below the medial malleolus. The sinus tarsi ligament, which has at least 4 discrete components, maintains apposition between the talus and calcaneus during hindfoot eversion and inversion.*

MEDIAL ANKLE

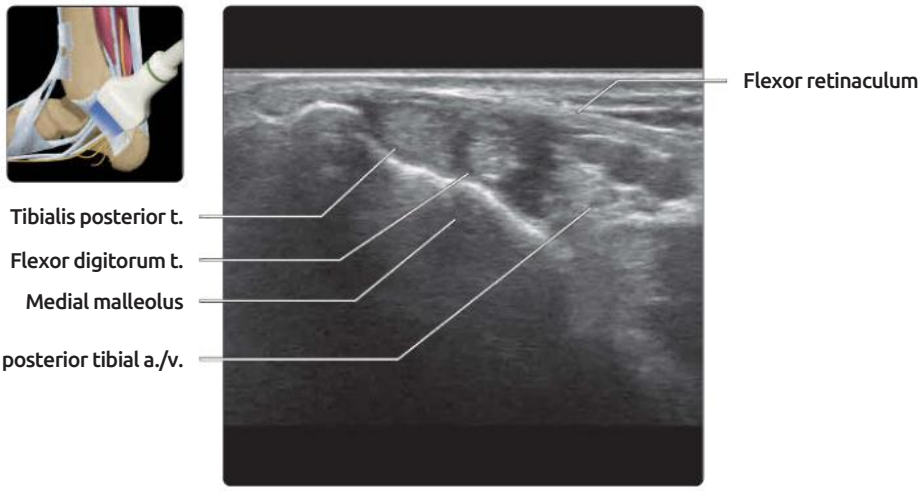

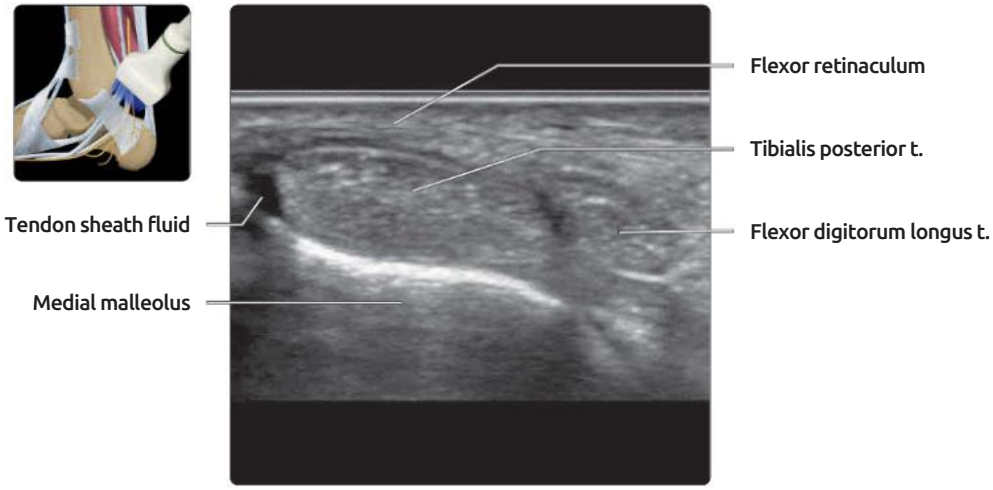

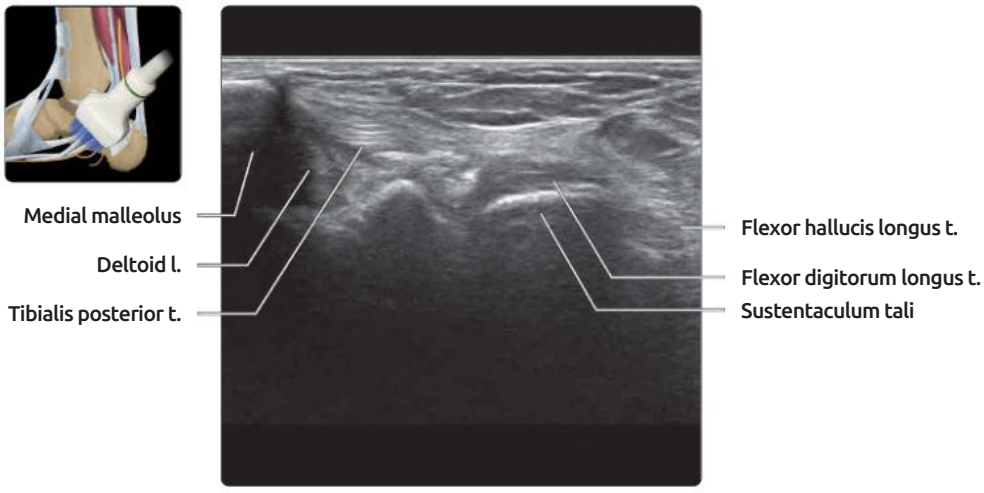

(Top) *Transverse US of the retromalleolar area shows the contents of the tarsal tunnel held in place by the flexor retinaculum. Within the tarsal tunnel are the tibialis posterior tendon, flexor digitorum longus (FDL) tendon, artery, vein, and nerve, and flexor hallucis longus tendon (mnemonic: Tom, Dick, and Harry).* **(Middle)** *Transverse US of the medial retromalleolar area shows the larger posterior tibialis tendon and the smaller FDL tendon, lying deep to the flexor retinaculum. The normal posterior tibialis tendon is 2x the size of the FDL. The posterior tibialis tendon cross-sectional area (CSA) is < 20 mm² at the retromalleolar and inframalleolar regions and < 30 mm² at the preinsertional area near the navicular bone. The posterior tibialis tendon sheath, which extends from the perimalleolar region to just proximal to the insertion, can normally contain a small amount of fluid in the more dependent distal areas.* **(Bottom)** *Longitudinal US of the medial aspect of the ankle and hindfoot shows the FDL tendon, which runs deep to the sustentaculum tali before crossing the flexor pollicis longus tendon at the knot of Henry.*

MEDIAL ANKLE

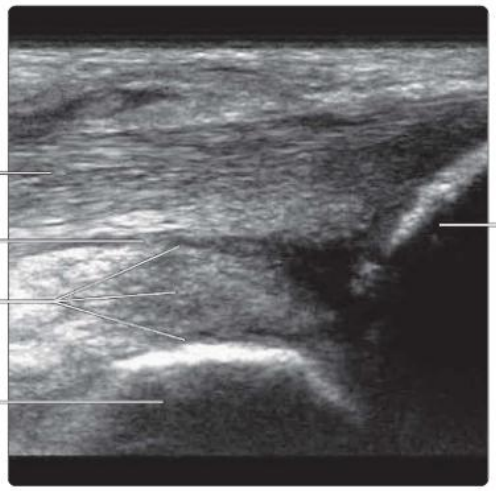

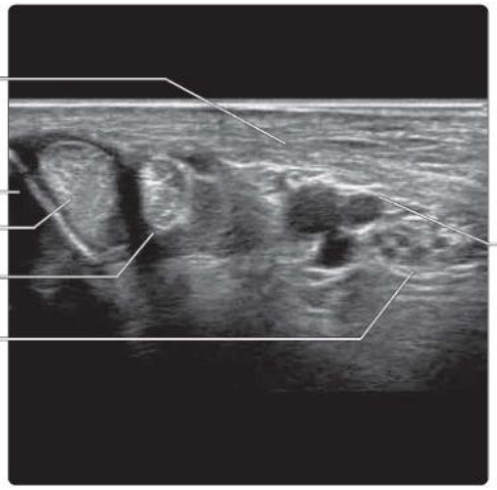

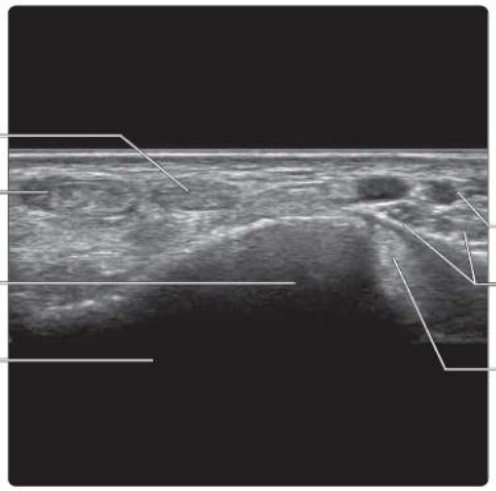

(Top) *Longitudinal US shows the posterior tibialis tendon inserting onto the medial pole of the navicular bone. It also attaches to the medial and intermediate cuneiform bones. Located deep to the posterior tibialis tendon is the superomedial calcaneonavicular ligament, 1 of the 3 components of the spring ligament. The superomedial component extends from the sustentaculum tali to the superomedial aspect of the navicular bone. It has a fibrocartilaginous "gliding zone" on its superficial aspect. The component is normally < 5 mm thick.* **(Middle)** *Transverse US of the tarsal tunnel is shown. The tibial nerve splits into the medial and lateral plantar nerves either within or just proximal to the tarsal tunnel.* **(Bottom)** *Transverse US shows the medial and lateral plantar branches at the distal end of the tarsal tunnel.*

MEDIAL & POSTERIOR LIGAMENTS

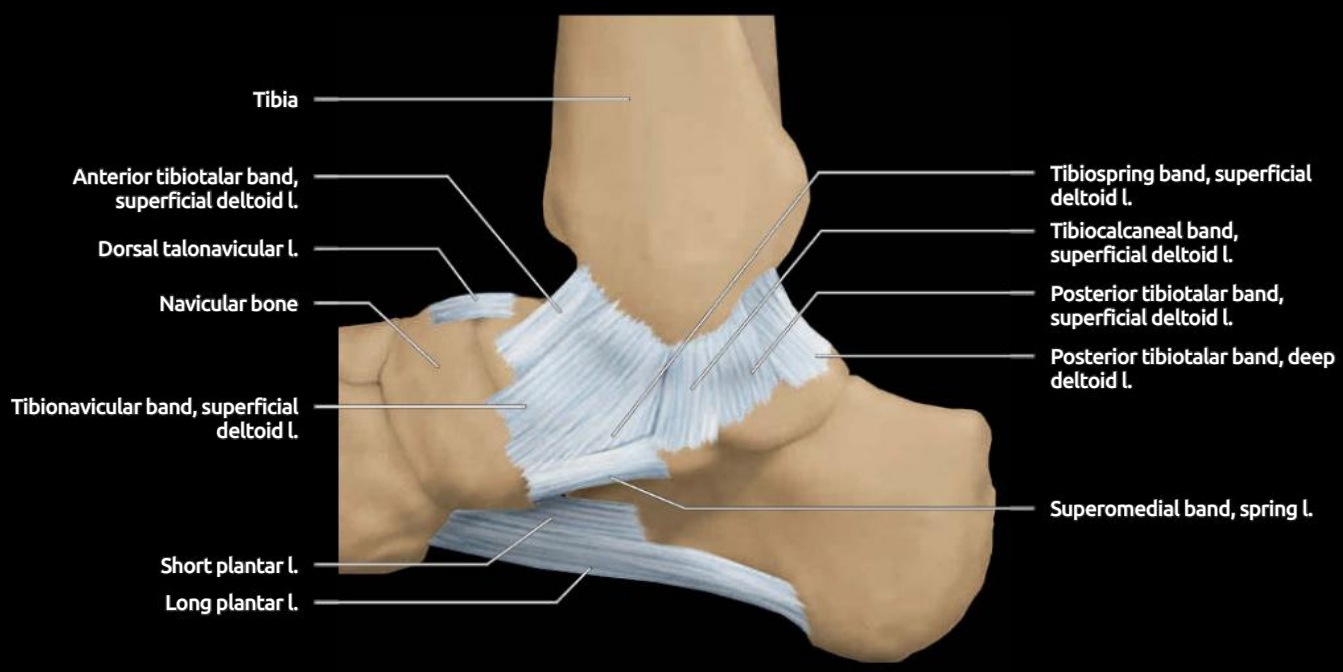

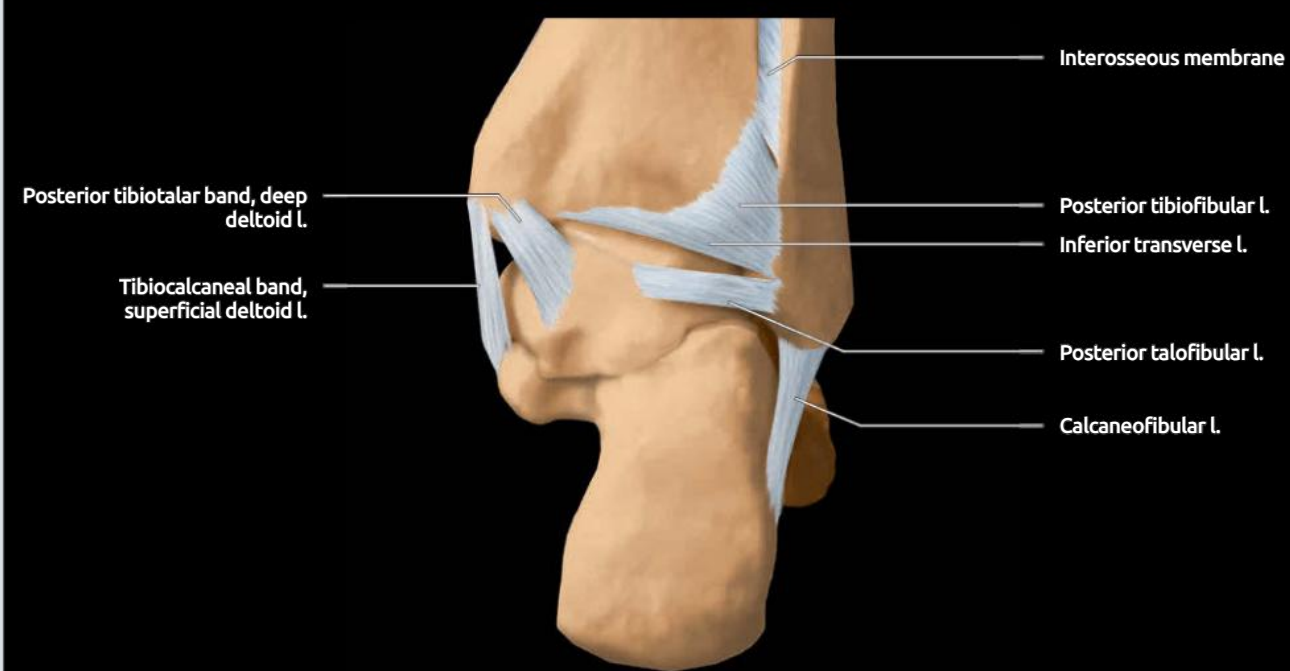

(Top) *Graphic shows the deltoid ligament on the medial aspect of the ankle. The deltoid ligament has deep anterior and posterior tibiotalar components and superficial anterior and posterior tibiotalar, tibiocalcaneal, tibiospring, and tibionavicular components. The superficial deltoid fibers are differentiated based on their insertion areas.* **(Bottom)** *Graphic shows the ligaments on the posterior aspect of the ankle. The inferior transverse ligament lies between the posterior tibiofibular and posterior talofibular ligaments at the level of the distal tibia. The posterior talofibular ligament passes posterior to the ankle joint to insert on the lateral tubercle of the talus.*

DELTOID LIGAMENT

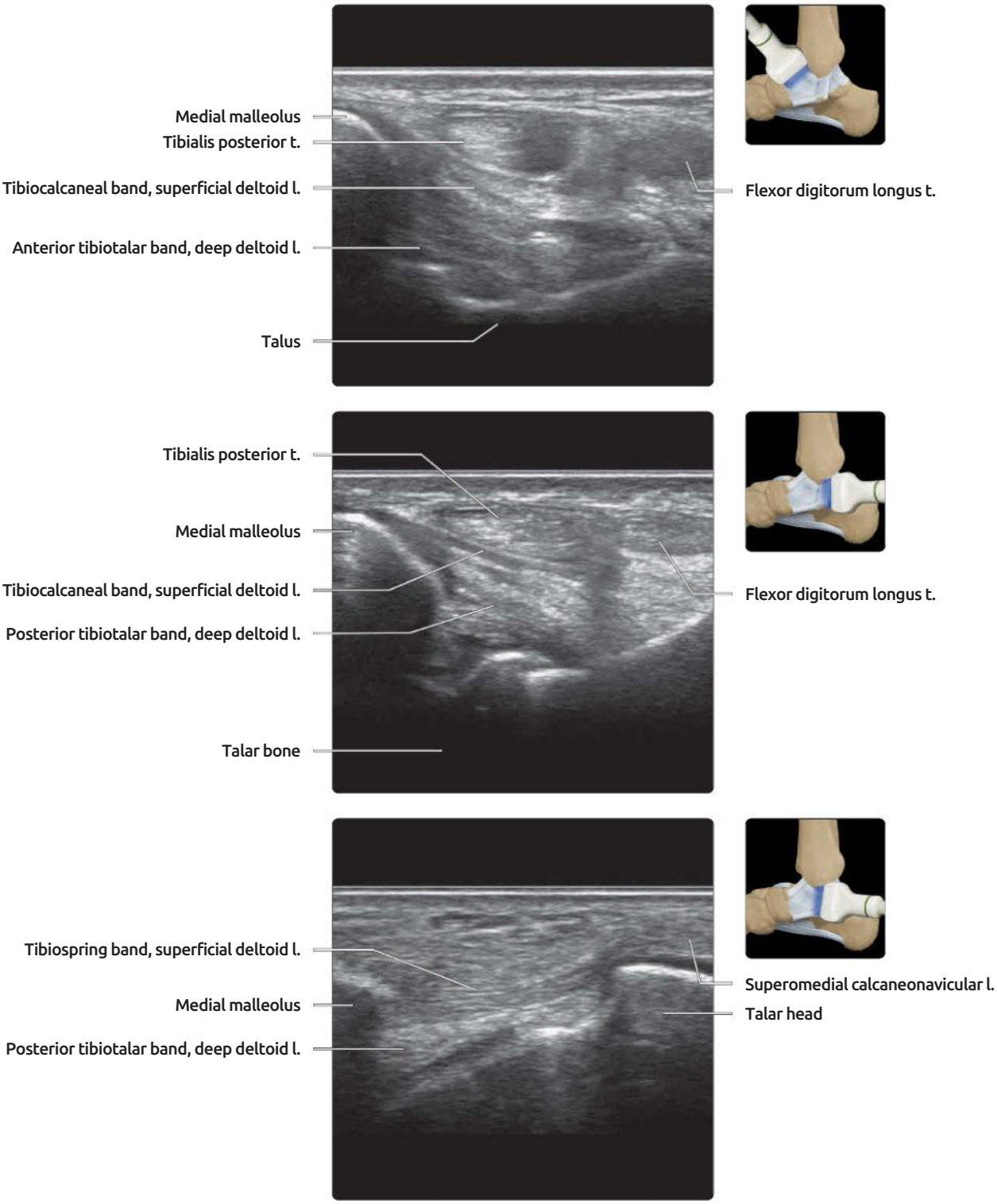

(Top) *Longitudinal US shows the deep anterior tibiofibular and the superficial tibiocalcaneal components of the deltoid ligament. The tibiocalcaneal superficial fibers of the deltoid ligament attach to the sustentaculum tali.* **(Middle)** *Longitudinal US more posteriorly shows the posterior tibiotalar fibers of the deltoid ligament as well as the superficial tibiocalcaneal fibers.* **(Bottom)** *Longitudinal US shows the superficial tibiospring component of the deltoid ligament extending between the medial malleolus and the superomedial calcaneonavicular ligament, which lies on the medial aspect of the talar head.*

ANTEROLATERAL LIGAMENTS

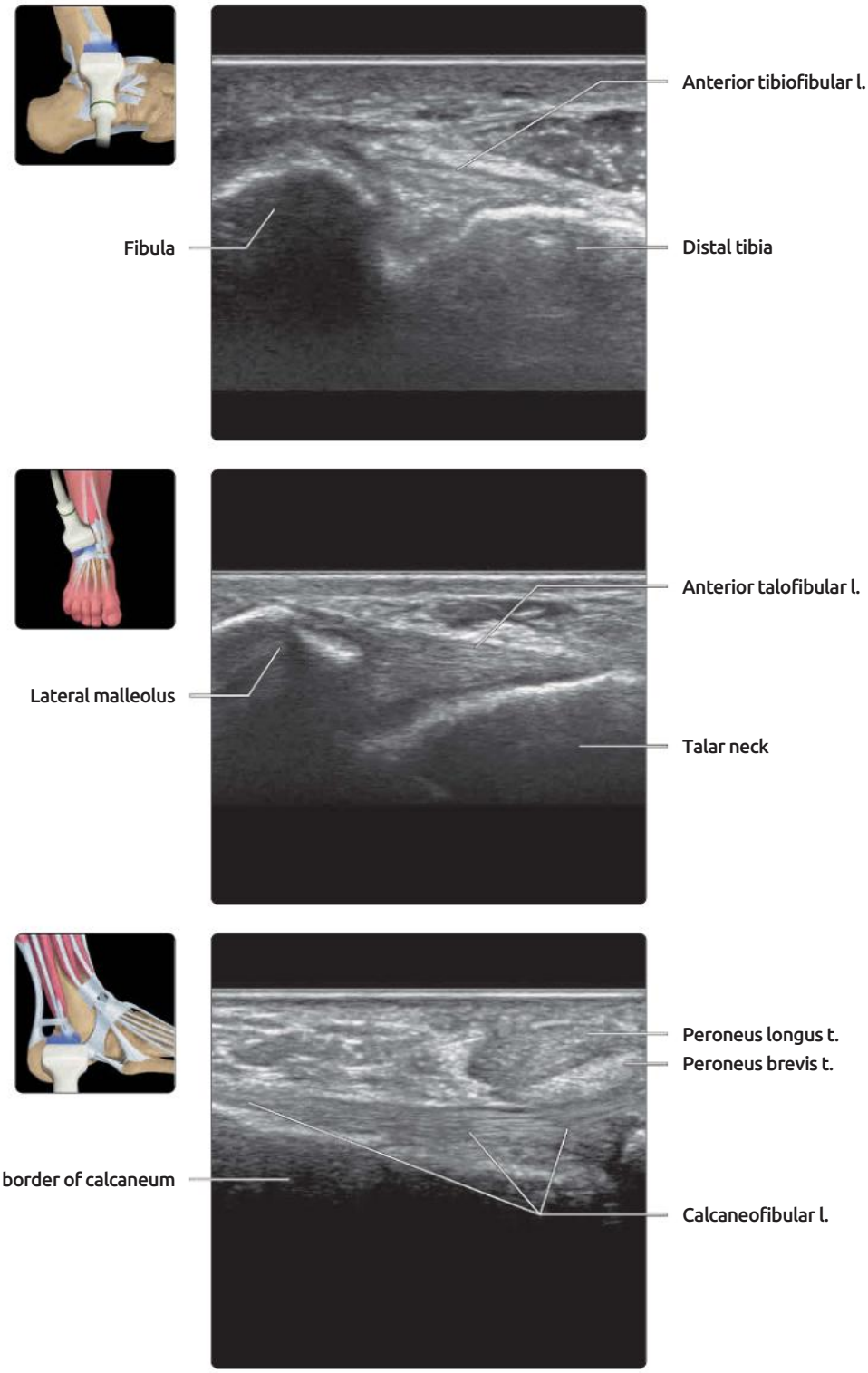

(Top) *Transverse US shows the fan-shaped anterior tibiofibular ligament, which is widest at the tibial insertion. It is the strongest restraint of the distal tibiofibular syndesmosis and is located in a transverse plane immediately above the ankle joint.* **(Middle)** *Transverse US shows the anterior talofibular ligament (ATFL), which is the most commonly injured ankle ligament, passing between the fibular tip and the lateral aspect of the talar neck. The ATFL normally has both superior and inferior fascicles.* **(Bottom)** *Transverse US shows the calcaneofibular ligament (CFL), which extends from the anterolateral aspect of the distal fibula to the lateral border of the calcaneum, just posterior to the peroneal tubercle. More proximally, the CFL curves upward to attach to the fibula. The CFL is attached to the undersurface of the peroneal tendon sheath. The normal different echogenicity of the peroneus longus and brevis tendons, due to anisotropy, is shown.*

LATERAL LIGAMENTS & TENDONS

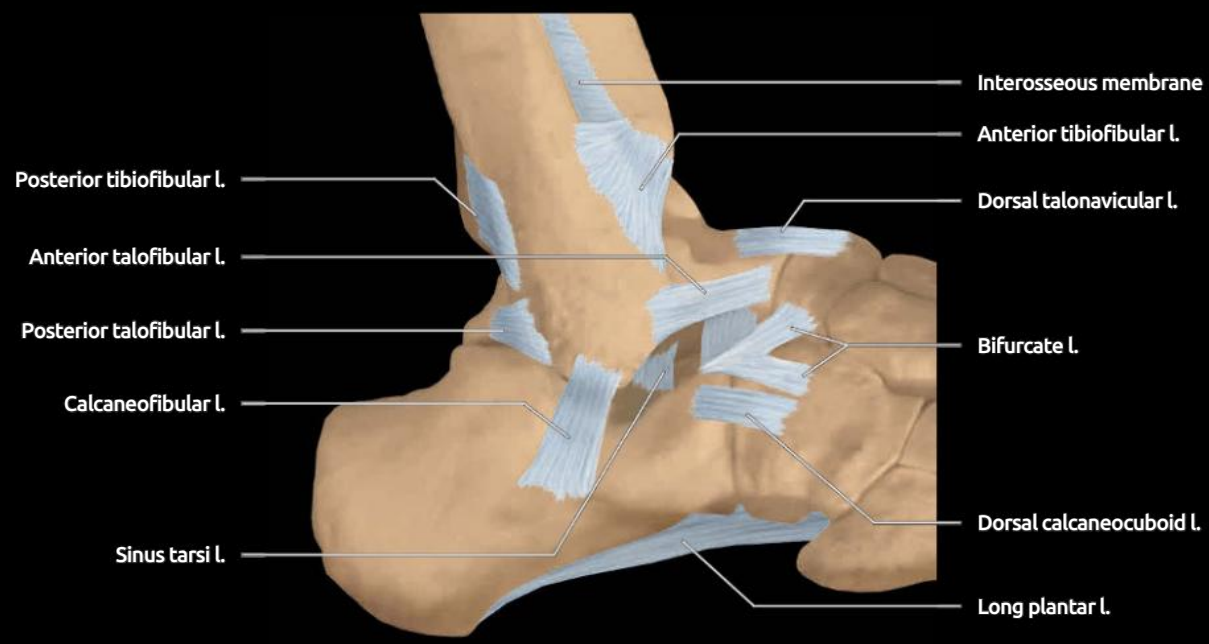

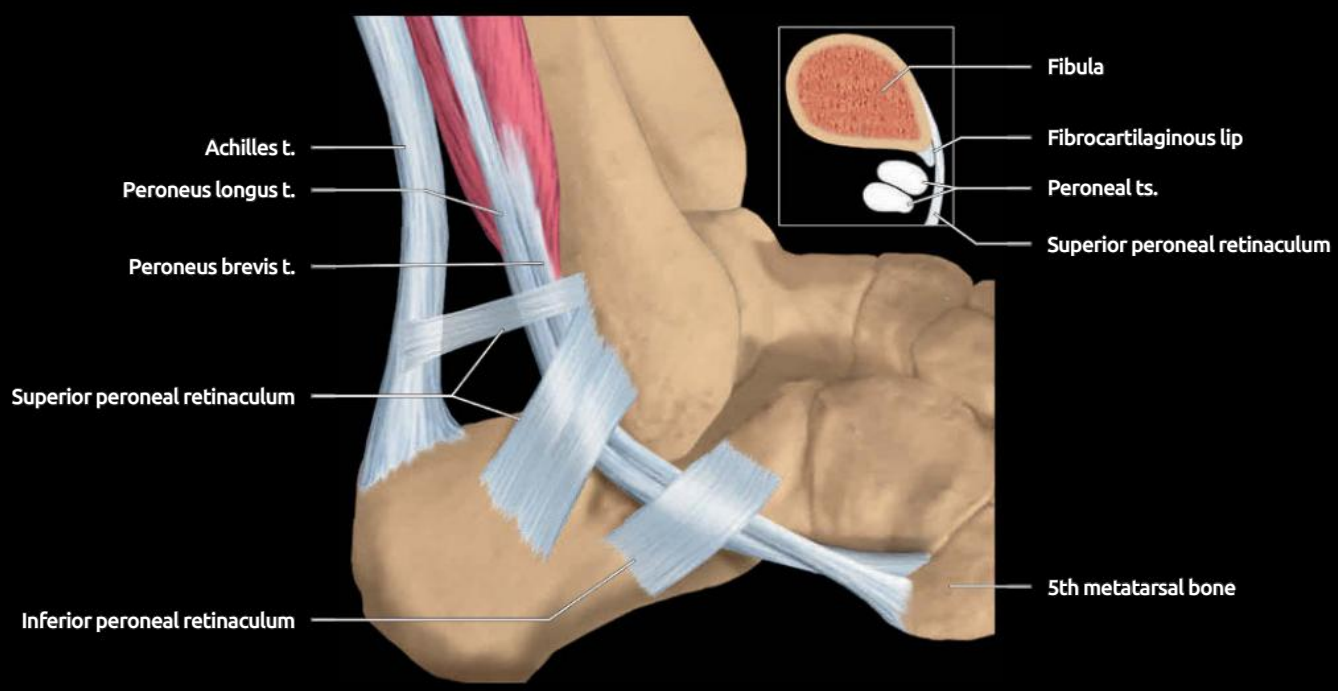

(Top) *Graphic shows the lateral ankle ligaments. The syndesmotic ligaments comprise the anterior and posterior tibiofibular ligaments as well as the interosseous ligament. The lateral collateral ligament includes the anterior talofibular, posterior talofibular, and calcaneofibular ligaments. Also shown are the bifurcate ligament of the midfoot, which extends from the calcaneus to the navicular and the cuboid as well as the dorsal talonavicular ligament.* **(Bottom)** *Graphic shows the peroneal retinacula and peroneal tendons. The superior peroneal retinaculum is attached to the distal fibula and calcaneum. It holds the peroneal tendons in the retromalleolar groove. The superior retinaculum is variable and can also connect to the anterior talofibular ligament (not shown), the inferior peroneal retinaculum, and to the tissues overlying the Achilles tendon. The inferior peroneal retinaculum holds the peroneal tendons against the lateral border of the calcaneum. Insert shows the fibrocartilaginous lip of the distal fibula, which serves to deepen the retromalleolar groove.*

LATERAL ANKLE

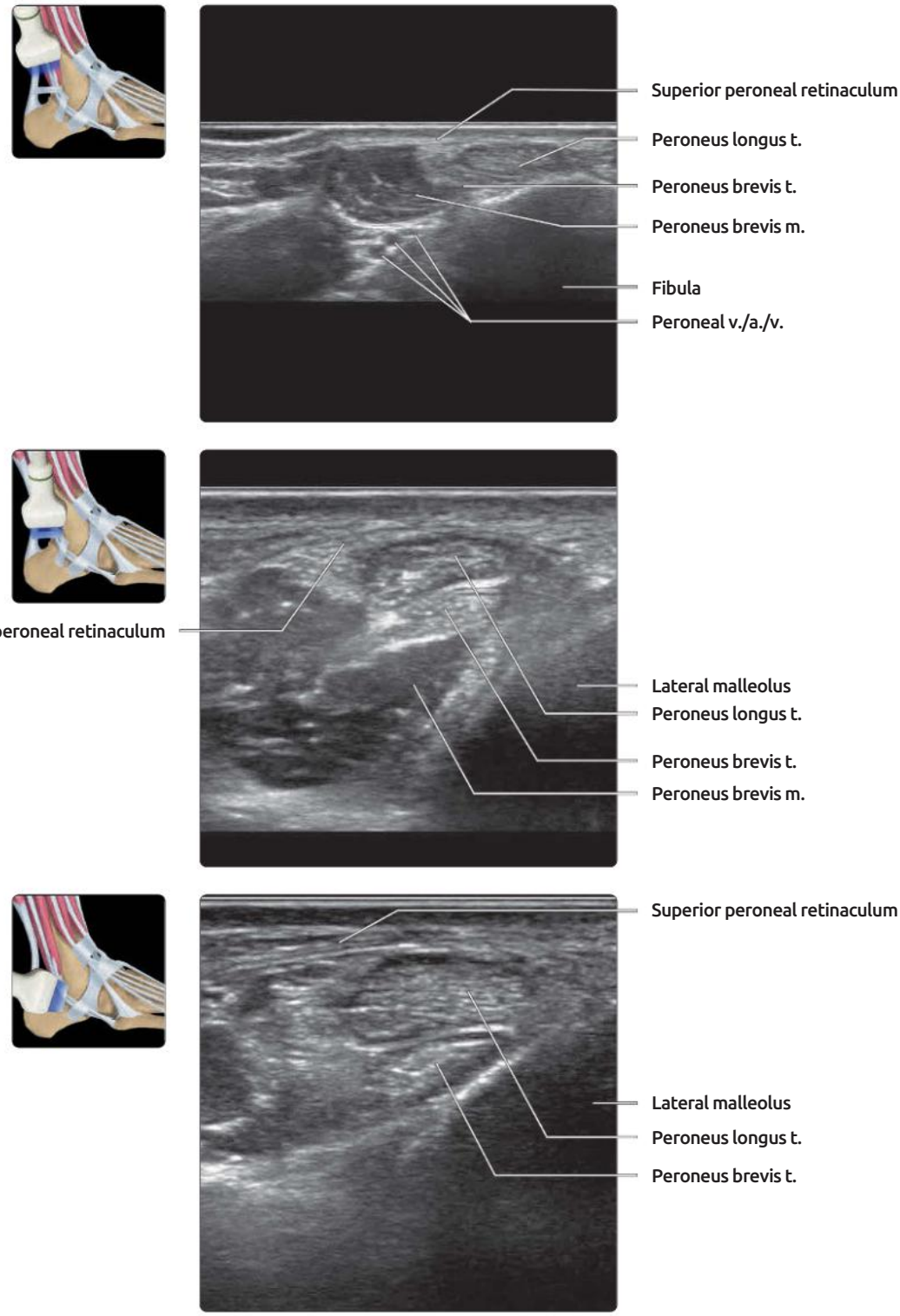

(Top) *Transverse US of the posterior aspect of the distal fibula shows the peroneus longus tendon running anterior to the peroneus brevis. The peroneus brevis is closest to the bone and is also identified by its muscle component, which remains almost to the fibular tip.* **(Middle)** *Transverse US just proximal to the tip of the lateral malleolus shows the peroneal tendons held down by the superior peroneal retinaculum, which prevents tendon subluxation and bowstringing.* **(Bottom)** *Transverse US posterior to the distal aspect of the lateral malleolus shows the peroneal tendons. The peroneus brevis muscle is no longer visible at this level. The peroneus brevis tendon is considerably flattened against the bone.*

LATERAL ANKLE

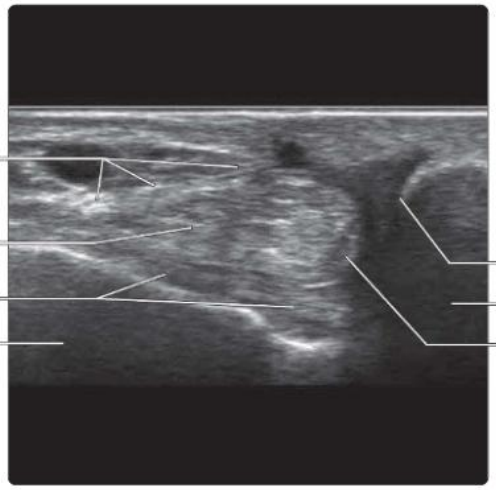

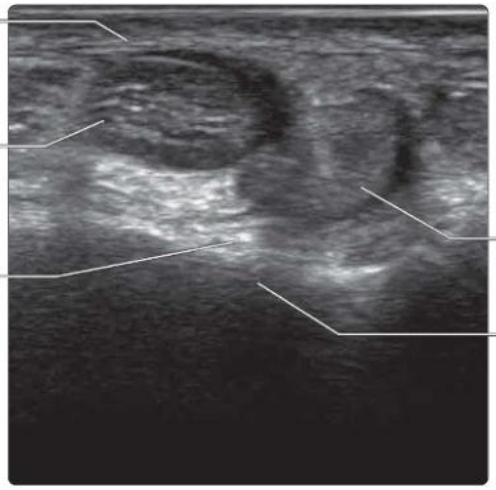

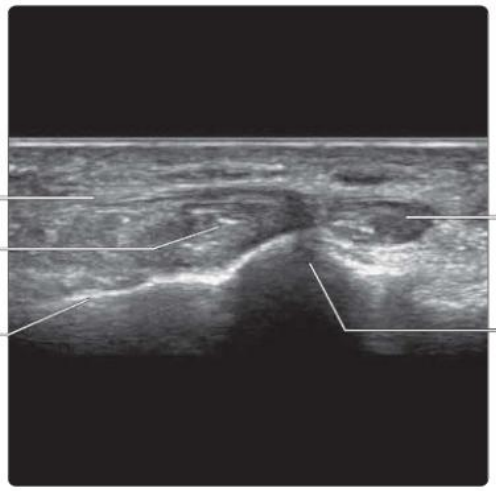

(Top) *Transverse US at the tip of the lateral malleolus shows the fibrocartilaginous lip as a triangular, hypoechoic structure on the distal fibula. This helps to deepen the retromalleolar groove.* **(Middle)** *Transverse US of the lateral surface of the calcaneus shows the peroneal tendons held down by the inferior peroneal retinaculum.* **(Bottom)** *Transverse US at the lateral aspect of the calcaneum shows the peroneal tubercle, which is a bony prominence on the middle 1/3 of the lateral calcaneum. It is present in 90% of normal subjects and is of variable size. The tubercle separates the peroneal tendons just distal to the end of the common peroneal tendon sheath. The inferior peroneal retinaculum attaches to the tubercle, separating the peroneal tendons with the peroneus longus tendon running below and the peroneus brevis tendon running above the tubercle. Peroneal tubercle hypertrophy may result in peroneus longus tendinosis or tenosynovitis.*

NERVES OF ANKLE

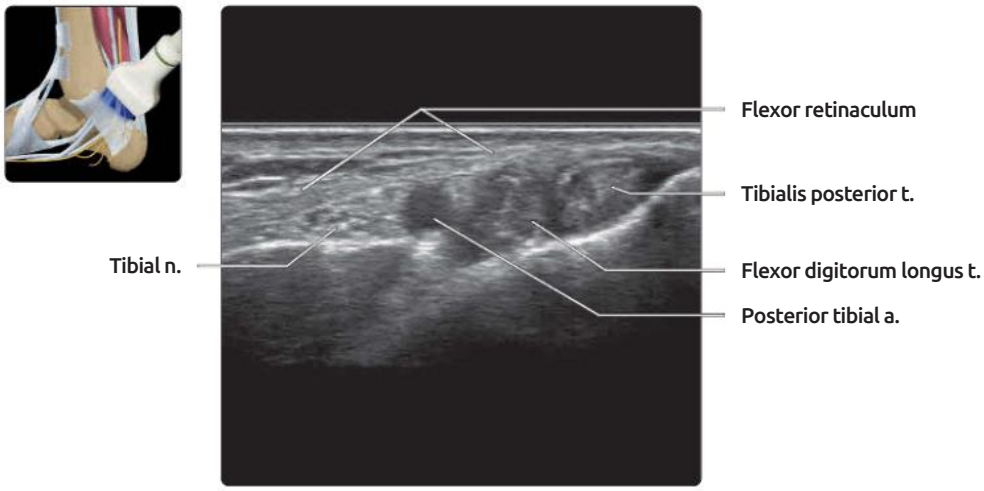

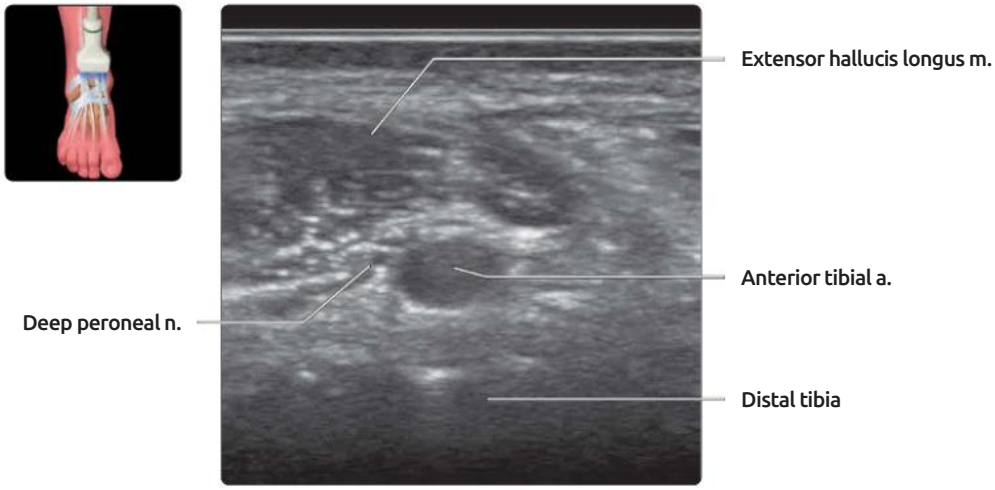

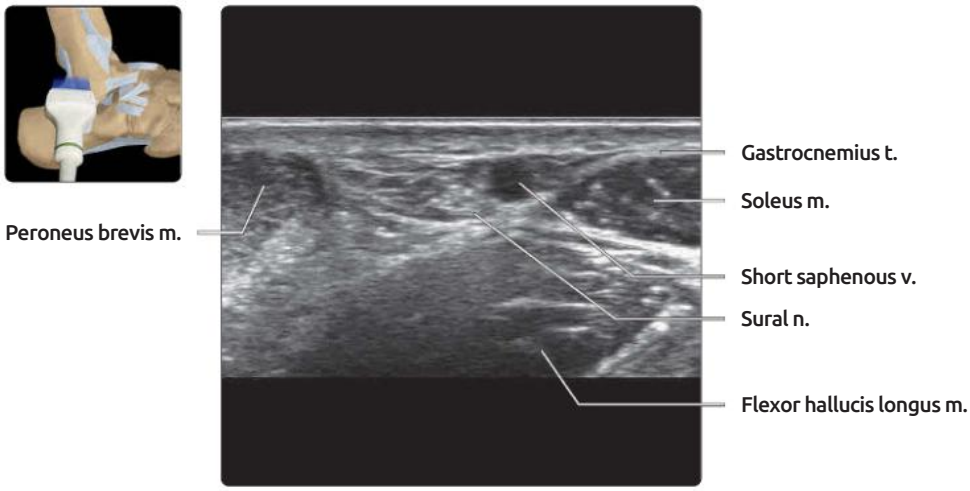

(Top) *Transverse US shows the tibial nerve in the tarsal tunnel deep to the flexor retinaculum. Tarsal tunnel syndrome is nearly always secondary in nature and is usually due to ganglia or other masses within the tarsal tunnel compressing the tibial nerve.* **(Middle)** *Transverse US just proximal to the ankle joint shows the anterior tibial artery, which is a good landmark to locate the deep peroneal nerve. The deep peroneal nerve passes over the anterior tibial artery from medial to lateral. The deep peroneal nerve innervates the dorsal foot muscles (extensor digitorum brevis, extensor pollicis brevis) and receives sensory innervation from the interspace between the 1st and 2nd toes.* **(Bottom)** *Transverse US of the posterolateral aspect of the distal leg shows the sensory sural nerve located between the Achilles tendon and the peroneal tendons. Proximally, the sural nerve is posterior to the gastrocnemius tendon and then runs lateral to the Achilles tendon, alongside the short saphenous vein, which is a good landmark for this small nerve. The sural nerve receives sensory innervation from the lateral aspects of the distal leg, ankle, and foot.*

NERVES AROUND ANKLE & ACHILLES TENDON

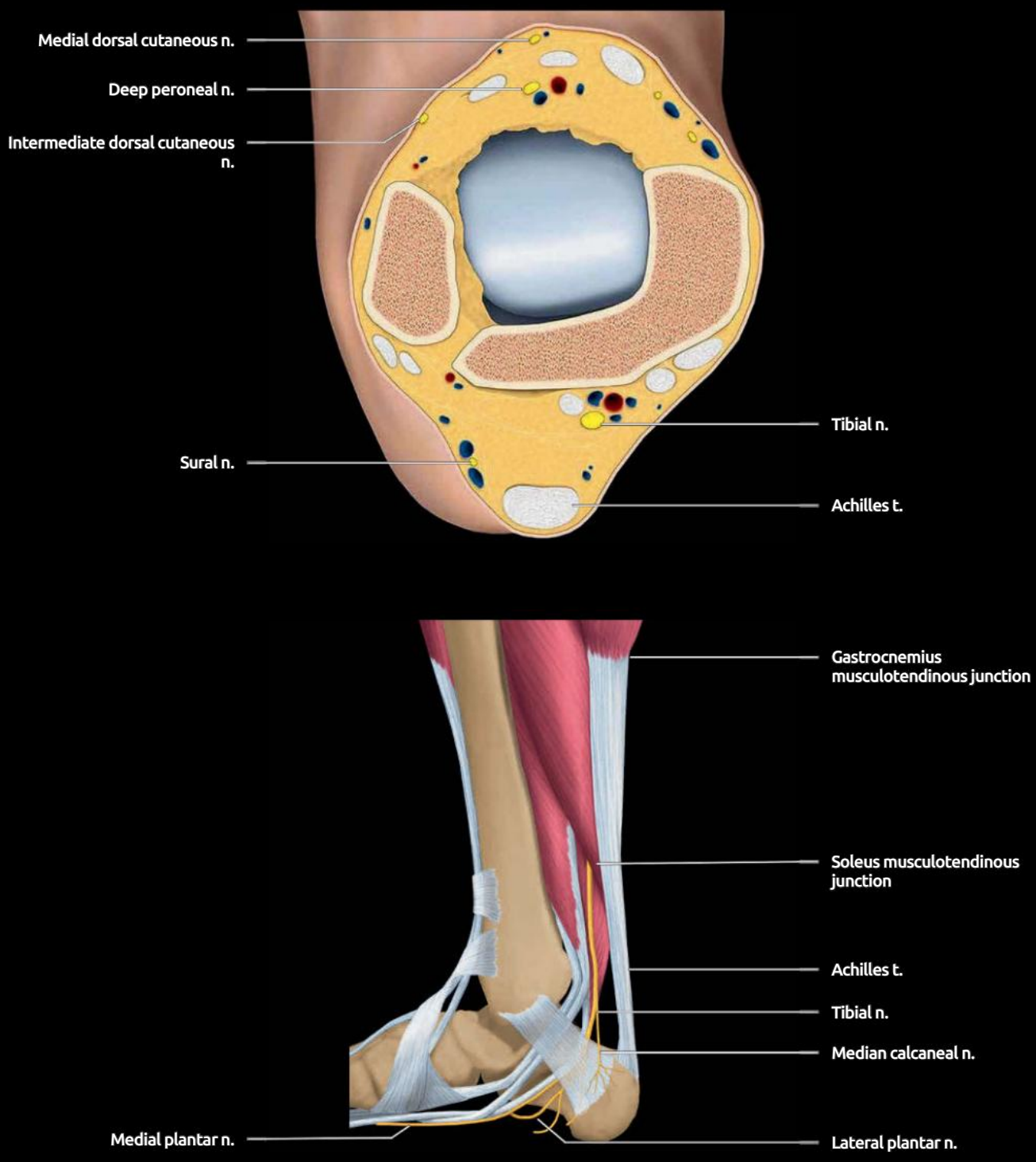

(Top) *Transverse graphic shows the fairly constant location of the nerves around the ankle joint. The medial and intermediate dorsal cutaneous nerves are the terminal branches of the superficial peroneal nerve. They receive sensory innervation from the dorsum of the 3rd to 5th toes.* **(Bottom)** *Graphic shows the Achilles tendon. The position of the soleus musculotendinous junction is variable, compromising assessment of normal Achilles tendon length. The Achilles tendon, from the soleus musculotendinous junction to the distal aspect of the calcaneal attachment is generally considered to be 6 cm in length. The gastrocnemius musculotendinous junction is located in the midcalf region, i.e., much more proximal than the soleus musculotendinous junction.*

LONGITUDINAL ACHILLES TENDON & TRANSVERSE PLANTARIS TENDON

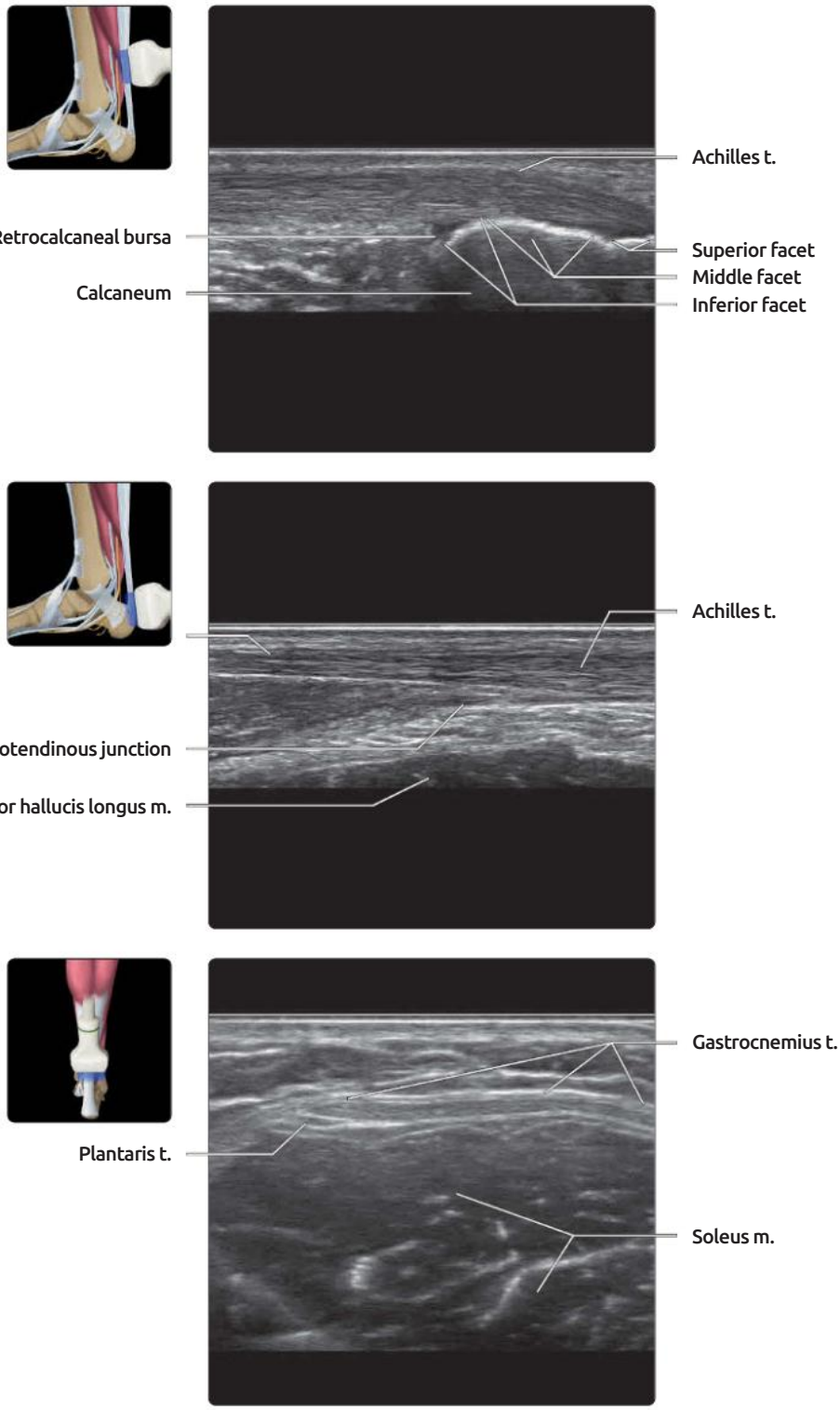

(Top) *Longitudinal US shows the broad insertion of the Achilles tendon onto the posterior aspect of the calcaneum. This posterior calcaneum is divided into superior, middle, and inferior facets. The superior facet is the location of the retrocalcaneal bursa. The Achilles tendon inserts into the middle facet (soleus fibers medially, lateral gastrocnemius fibers laterally), and the inferior facet (medial gastrocnemius fibers). The different Achilles tendon fibers spiral and intertwine as they move distally to their insertional sites. This twisting of the fibers provides biomechanical strength to the Achilles tendon, similar to a braided rope.* **(Middle)** *Longitudinal US shows the soleus musculotendinous junction onto the undersurface of the gastrocnemius tendon to form the Achilles tendon. A high soleus musculotendinous junction is associated with Achilles tendinosis.* **(Bottom)** *Transverse US of the distal calf shows the plantaris tendon deep to the medial aspect of the gastrocnemius tendon close to the musculotendinous junction. More proximally, the plantaris tendon will run between the medial belly of the gastrocnemius muscle and the soleus muscle.*

AXIAL ACHILLES TENDON

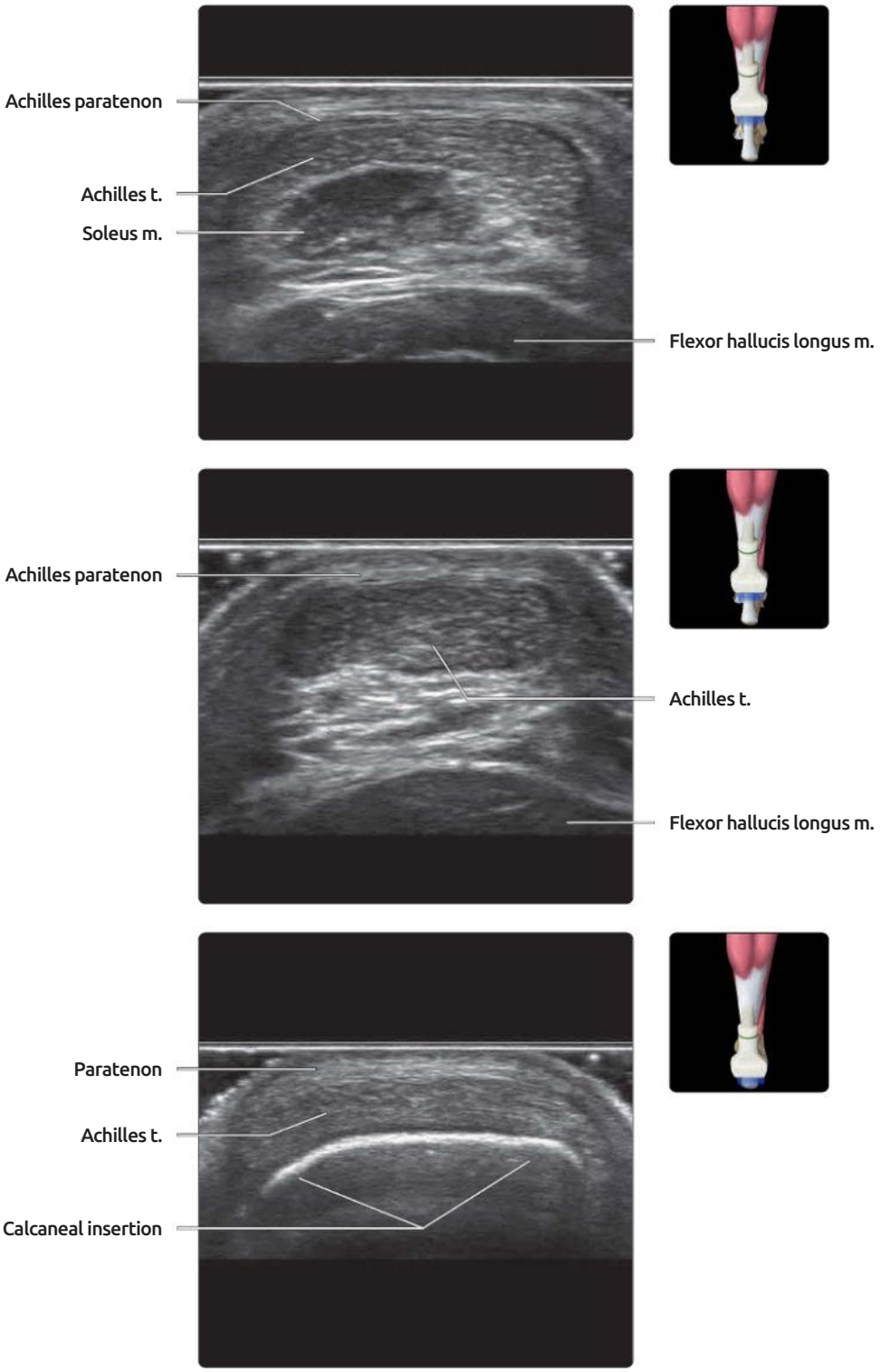

(Top) *Transverse US shows the Achilles tendon musculotendinous junction. The Achilles tendon is formed from both the gastrocnemius and soleus tendons. At the musculotendinous junction, the Achilles tendon is crescent-shaped to accommodate the soleus muscle. Normal CSA of the Achilles tendon at this location is 0.54 ± 0.11 cm².* **(Middle)** *Transverse US shows the Achilles tendon at its midportion. The tendon now has an ovoid contour. The fibrils within the tendon produce a coarsely dotted appearance. Normal CSA of the Achilles tendon at this location is 0.54 ± 0.12 cm². Normal anteroposterior thickness of the Achilles tendon is < 6 mm. Normal paratenon is < 2 mm thick.* **(Bottom)** *Transverse US of the Achilles tendon at its insertion into the calcaneum is shown. The Achilles tendon becomes flattened and broader. Normal CSA of the Achilles tendon at this location is 0.72 ± 0.15 cm².*

TERMINOLOGY

Abbreviations

- Metatarsophalangeal (MTP)
- Abductor hallucis (AbdH)
- Flexor hallucis brevis (FHB)
- Flexor digitorum brevis (FDB)
- Quadratus plantae (QP)
- Adductor hallucis (AddH)
- Abductor digiti minimi (AbdV)
- Flexor digiti minimi brevis (FDVB)
- Extensor hallucis brevis (EHB)
- Extensor digitorum brevis (EDB)

Definitions

- **3 major divisions**
  - Hindfoot: Calcaneus & talus
  - Midfoot: Navicular, cuneiforms, & cuboid
  - Forefoot: Metatarsals & phalanges
- **2 columns of foot**
  - Medial column: Talus, navicular, cuneiforms, & digits 1-3
  - Lateral column: Calcaneus, cuboid, & digits 4 & 5
- **Occasionally, forefoot divided into 3 columns**
  - Medial column: 1st toe
  - Middle column: 2nd-4th toes
  - Lateral column: 5th toe

IMAGING ANATOMY

Foot Arches

- Foot is arched longitudinally & transversely
- **Longitudinal arches of foot**
  - From posterior process calcaneus to metatarsal heads
  - Medial longitudinal arch is higher than lateral longitudinal arch
    - Apex of arch is at navicular & cuneiform bones
  - Metatarsals slant downward from apex of arch to MTP joint
    - This is called inclination angle
    - Inclination angle decreases from 20° at 1st MTP to 5° at 5th MTP
  - Major supporting structures of longitudinal arches
    - Plantar fascia
    - Long & short plantar ligaments
    - Spring ligament
    - Posterior tibial tendon, peroneus longus tendon
- **Transverse arch of foot**
  - Cuneiform bones form keystone of arch due to triangular shape
  - Major supporting structures of transverse arch
    - Spring ligament
    - Lisfranc ligament & intermetatarsal ligaments
    - Intertarsal ligaments
- **Radiographic assessment of normal longitudinal arch**
  - Evaluate talometatarsal alignment
    - Normal: Axis of talus continues along axis of 1st metatarsal
    - Pes planus: Axis of talus points below axis of 1st metatarsal bone due to flattened arch
    - Pes cavus: Axis of talus points above axis of 1st metatarsal bone due to exaggerated arch

Distribution of Weight Bearing

- 50% of weight is borne on subtalar joint & calcaneus
- Remainder is transmitted via arch anteriorly to MTP joints, greatest weight on 1st toe

Bony Anatomy

- **Cuboid bone**
  - Roughly cuboidal shape
  - Articulates with calcaneus, navicular, 3rd cuneiform, & 4th & 5th metatarsals, rarely head of talus
    - Dorsal ligaments (calcaneocuboid, cubonavicular, cuneocuboid, cubometatarsal) strengthen each of these articulations
    - Short & long plantar ligaments attach to plantar surface
  - Sulcus at lateral margin, under which passes peroneus longus tendon
  - 5th metatarsal base extends beyond lateral margin
- **Navicular bone**
  - Curved shape, concave proximally & convex distally
  - Articulates with talus, cuboid, cuneiforms
    - Dorsal ligaments strengthen each of these articulations
    - Single facet proximally for articulation with head of talus
    - 3 facets distally for cuneiform articulations
    - 1 facet laterally for articulation with cuboid
    - Connected to anterior process of calcaneus by bifurcate ligament
    - Connected to sustentaculum tali by spring ligament
  - Large median eminence for attachment of posterior tibial tendon
    - Located more plantar than main body of navicular
    - If enlarged, known as cornuate configuration of navicular bone
  - **Accessory navicular bone**
    - Accessory bone at tuberosity (medial pole) of navicular bone
    - 10% global prevalence, 50% in Asian populations
    - Strongly associated with pes planus
    - 3 types of accessory navicular bone
      - Type 1: Small (2-3 mm) sesamoid bone embedded in posterior tibialis tendon; 20% of accessory navicular bones
      - Type 2: Roundish or trapezoid-shaped bone, 8-12 mm long, connected to navicular tuberosity by 1- to 2-mm fibrocartilage or hyaline cartilage layer; 50% of accessory navicular bones
      - Type 3: Prominent navicular tuberosity known as cornuate configuration of navicular bone; 30% of accessory navicular bones
- **Cuneiform bones**
  - Wedge-shaped with base of wedge in dorsal surfaces of bones forming arch
  - Medial cuneiform
    - Articulates with navicular, 2nd cuneiform, & 1st metatarsal
    - Largest of cuneiform bones

- Intermediate cuneiform
  - Articulates with navicular, 1st & 3rd cuneiforms, & 2nd metatarsal
  - Smallest of cuneiforms
- Lateral cuneiform
  - Articulates with navicular, 2nd cuneiform, cuboid, & 3rd metatarsal

- **Metatarsal bones**
  - 1st metatarsal has epiphysis at proximal end, others at distal end
  - 2nd-5th metatarsals have articulations at bases with adjacent metatarsals
  - 1st metatarsal
    - Largest of metatarsals
    - Articulates with 1st cuneiform, 1st proximal phalanx, & sesamoids of metatarsal head
    - Variable articulation with 2nd metatarsal base
  - 2nd-3rd metatarsals
    - Articulate with respective cuneiforms & proximal phalanges
    - 2nd metatarsal base recessed relative to 1st & usually 3rd
  - 4th-5th metatarsals
    - Articulate with cuboid & respective proximal phalanges
    - Styloid process of 5th metatarsal extends lateral to cuboid
- **Phalanges**
  - 1st toe is biphalangeal, other toes are triphalangeal
  - 5th toe sometimes has failure of segmentation of middle & distal phalanges

Plantar Fascia (Aponeurosis)

- Strong connective tissue structure that helps maintain longitudinal arches of foot
- **Central band**: Extends from calcaneal tuberosity to MTP joints
  - Thick proximally & thin distally
  - Normal thickness < 4 mm at calcaneal tuberosity
  - Superficial to FDB muscle
  - Distally, divides into 5 digitations that insert into MTP joints
- **Lateral band**: Extends from calcaneal tuberosity to base of 5th metatarsal bone
  - Thick proximally & thin distally
  - Normal thickness < 2.3 mm
  - Superficial to abductor digiti minimi muscle
- **Medial band**: Midportion of central band → fascia on dorsum of foot; mean maximal thickness of plantar fascia has been reported as 4 mm in its central bundle, 2.3 mm in its lateral bundle, & 0.6 mm in its medial bundle
  - Thin, normal thickness < 0.6 mm
  - Superficial to AbdH muscle

Musculature

- **Plantar muscles**: 4 muscle layers from superficial to deep
  - 1st layer: AbdH, FDB, & AbdV muscles
  - 2nd layer: Quadratus plantae & lumbricals muscles
  - 3rd layer: Flexor hallucis brevis & adductor hallucis muscles
  - 4th layer: Plantar (3) & dorsal interossei (4) muscles
  - Muscle layers are grouped into medial, central, & lateral groups
- **Medial group**
  - AbdH muscle: Extends from calcaneal tuberosity to proximal phalanx of 1st toe
  - FHB muscle: Extends from cuboid-lateral cuneiform to base of proximal phalanx of hallux with medial & lateral sesamoid bones embedded into medial & lateral heads respectively
- **Central group**
  - FDB muscle: Extends from calcaneal tuberosity to form 4 tendons, which insert to middle phalanges of lesser toes, passing around flexor digitorum longus tendons
  - QP muscle: 2 heads from medial & lateral aspects of calcaneus, separated by long plantar ligament, which insert into flexor digitorum longus tendon
  - Lumbrical muscles: 4 muscles arising from flexor digitorum longus tendons, which insert into extensor hoods of lesser toes
  - AddH muscle: 2 heads arising from 3-5th metatarsal head (transverse head, smaller) and 2nd-4th metatarsal bases (oblique head, larger), which insert into proximal phalanx & lateral sesamoid of hallux
  - Interossei muscles: 3 plantar & 4 dorsal muscles located in intermetatarsal spaces, which insert into proximal phalangeal bases of lesser toes
- **Lateral group**
  - AbdV muscle: Extends from calcaneal tuberosity to proximal phalanx of little toe
  - FDVB muscle: Extends from 5th metatarsal base to proximal phalanx of little toe
- **Dorsal muscles**
  - EHB: Extends from calcaneus to lesser toes
  - EDB: Extends from calcaneus to hallux
- **Muscle innervation**
  - Medial plantar nerve supplies LAFF, i.e., lumbrical (1st), AbdH, & 2 flexor muscles (FDB & FHB)
  - All other plantar muscles are supplied by lateral plantar nerve
  - Dorsal muscles supplied by deep peroneal nerve
- **Aide-mèmoire to remember larger foot muscles during US scanning: Remember "2 of everything"**
  - 2 muscles medial side of foot: AbdH & FHB
  - 2 muscles central aspect of foot: FDB & QP
  - 2 muscle lateral aspect of foot: AbdV & FDVB
  - 2 heads of AddH
  - 2 other muscles: Interossei & lumbricals
  - 2 muscles dorsum of foot: EHB & EDB

Compartments

- **Plantar compartments: 4 plantar compartments located deep to plantar fascia**
  - Divided by fascial layers
  - Lateral & medial intermuscular septa determine major compartment divisions
  - **Medial plantar compartment**
    - Contains AbdH muscle, flexor hallucis longus muscle, & FHB tendons
  - **Central plantar compartment**
    - Superficial subcompartment: Contains FDB muscle, distal portion of flexor digitorum longus tendons

    - Intermediary subcompartment: Contains proximal plantar portion of flexor digitorum longus tendon, QP muscle, lumbrical muscles
    - Deep subcompartment: Limited to forefoot, contains AddH muscle
  - **Lateral plantar compartment**
    - Contains AbdV muscle & FDVB muscle
  - **Interosseous compartment**
    - Contains plantar & dorsal interosseous muscles
- **Dorsal compartment**
  - Superficial layer: Extrinsic extensor tendons
  - Deep layer: Intrinsic extensor muscles

Major Ligaments

- Long plantar ligament
  - Originates at calcaneal tuberosity, inserts at cuboid & bases of 2nd-4th metatarsal bones
  - Forms retinaculum for peroneus longus tendon as it courses medially on plantar aspect of foot
- Short plantar (plantar calcaneocuboid) ligament
  - Deep to long ligament, inserts more proximally on cuboid
- Plantar calcaneonavicular (spring) ligament
  - 3 components
  - Originates on sustentaculum tali, inserts on plantar aspect navicular bone
    - Superomedial
    - Medioplantar oblique
    - Inferoplantar longitudinal
- Bifurcate ligament: Originates on anterior process of calcaneus dorsally, inserts on navicular & cuboid bones

Nerves

- **Tibial nerve** divides into larger medial & smaller lateral plantar branches at level of tarsal tunnel
  - **Medial plantar nerve**
    - Travels along medial aspect of foot between AbdH & QP muscles, accompanied by medial plantar artery
    - Passes superficial to knot of Henry where compression may lead to "jogger's heel"
    - More distally, courses along medial border of FDB muscle
    - At base of 1st metatarsal bone, divides into plantar digital nerves to 1st-3rd toes, medial aspect of 4th toe
  - **Lateral plantar nerve**: Has deep & superficial divisions
    - Initially deep to AbdH muscle along with medial plantar nerve, then passes laterally between FDB & QP muscles, accompanied by lateral plantar artery
    - Plantar digital nerves to 5th toe, lateral aspect of 4th toe
- **Medial calcaneal nerve**
  - Sensory nerve that usually arises from tibial nerve proximal to carpal tunnel
  - Courses superficial to flexor retinaculum to medial aspect of heel & calcaneus
- **Inferior calcaneal nerve**
  - 1st branch of lateral plantar nerve
  - Above 5 mm anterior to medial calcaneal tuberosity deep to FDB & superficial to QP muscle
  - Provides sensory innovation to anterior aspect of calcaneus & motor branches to abductor digiti minimi muscle
  - Compression known as Baxter neuropathy
- **Deep peroneal nerve**: Extends along dorsum of foot, between tibialis anterior & extensor hallucis longus tendons
- **Superficial peroneal nerve**: Divides into medial & lateral branches on dorsum of foot
  - Sensory branches to dorsal foot
- **Sural nerve**: Lateral, superficial branch of tibial nerve
  - Extends along lateral margin of foot
  - Sensory branches to lateral foot
- **Digital nerves**
  - Common plantar digital nerves are branches of medial & lateral plantar nerves
    - 1st, 2nd, & 3rd common plantar digital nerves usually arise from medial plantar nerve, while 4th common plantar digital nerve arises from lateral plantar nerve
    - Each common plantar digital nerve makes sharp turn superficially to run over intermetatarsal ligament & bifurcate into medial & lateral digital nerves to supply opposing sides of adjacent toes
  - Medial digital nerve of hallux susceptible to friction neuritis (Joplin toe)

Arteries

- Posterior tibial artery divides into medial & lateral plantar arteries at level of tarsal tunnel
  - Plantar arteries accompany medial & deep lateral plantar nerves
- Anterior tibial artery continues into foot as dorsalis pedis artery, deep to extensor retinaculum
  - Extends from middle of ankle joint to 1st web space
  - Divides into multiple branches in midfoot, forming arcade

Bursae

- Extensor digitorum longus: Between tendon & dorsolateral neck of talus (Gruberi bursa)
- EDB: Between muscle & 2nd cuneiform & metatarsal bases
- Extensor hallucis longus: Between tendon & 1st cuneiform & metatarsal bases
- AbdV: Between muscle & tuberosity of 5th metatarsal
- MTP joints: Dorsally between metatarsal heads & medial to 1st metatarsal head

DORSAL FOOT

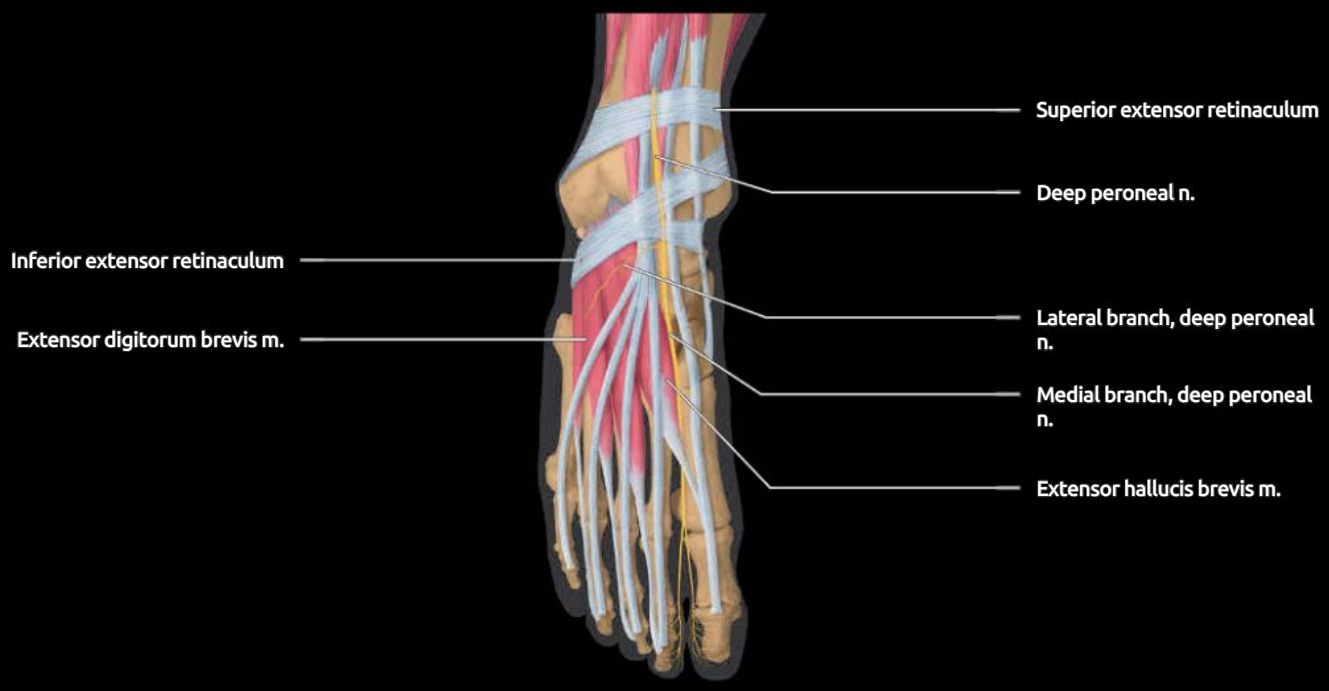

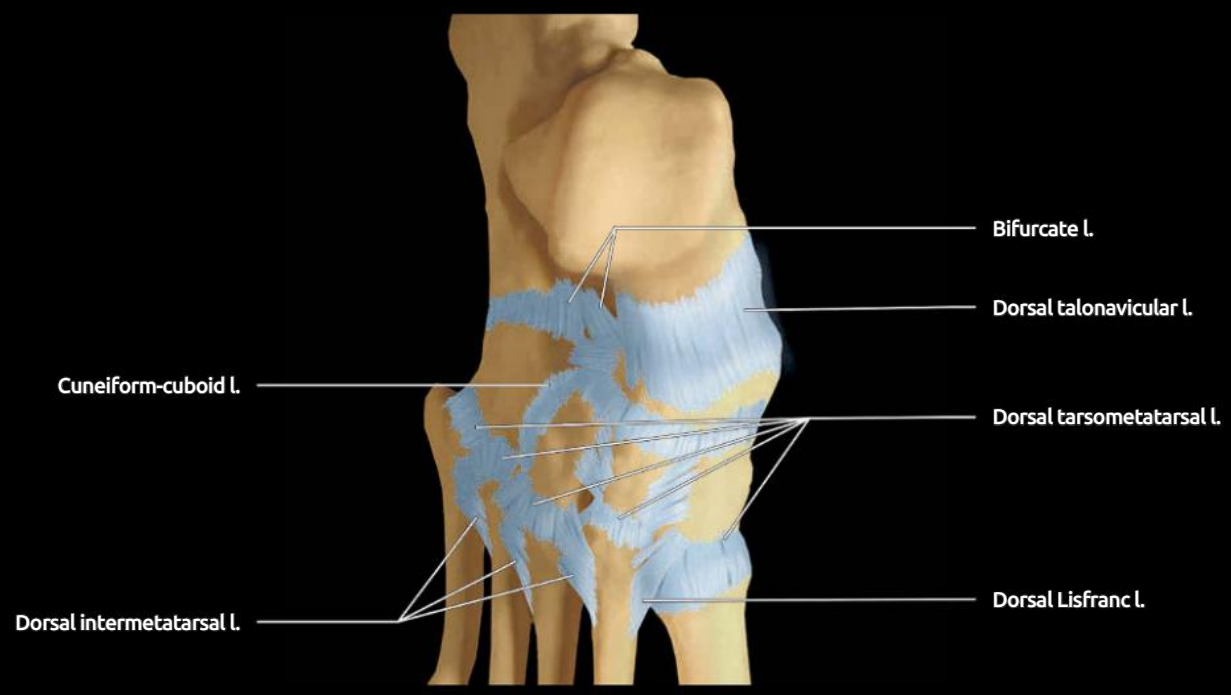

(Top) *The deep peroneal nerve travels deep to the extensor retinaculum, in the anterior tarsal tunnel, and gives a lateral motor branch to the extensor digitorum brevis muscle. The medial branch continues dorsal to the talonavicular joint, middle cuneiform, and in between the 1st and 2nd metatarsals to provide mostly sensory, but some motor, supply to the 1st web space.* **(Bottom)** *Graphic of the dorsal ligaments shows dense ligaments between the tarsal bones and between tarsals and metatarsals. Ligaments are generally named for the bones they bridge. Exceptions are the bifurcate ligament, which extends from the anterior process of the calcaneus to the cuboid and the navicular, and the dorsal Lisfranc ligament, which extends from the 1st cuneiform to the 2nd metatarsal bone.*

BONES

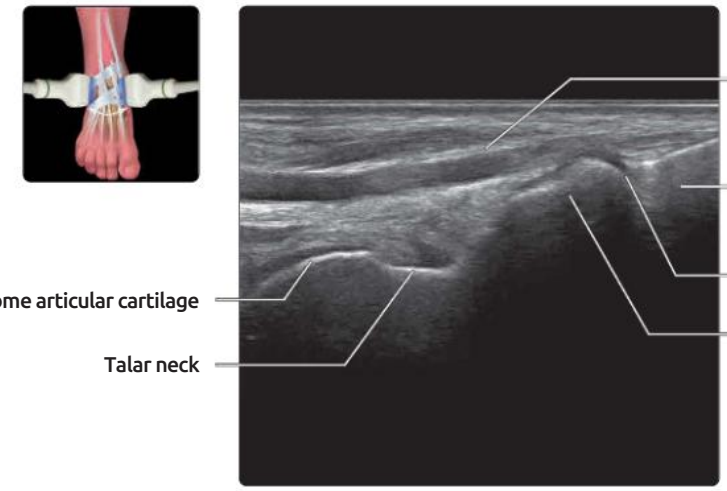

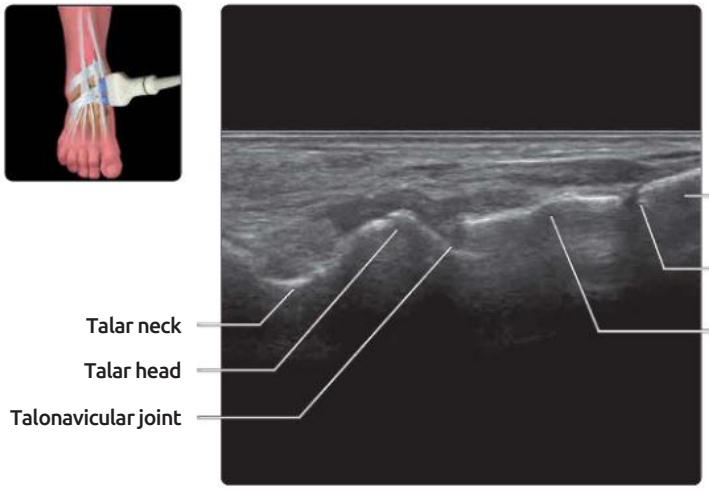

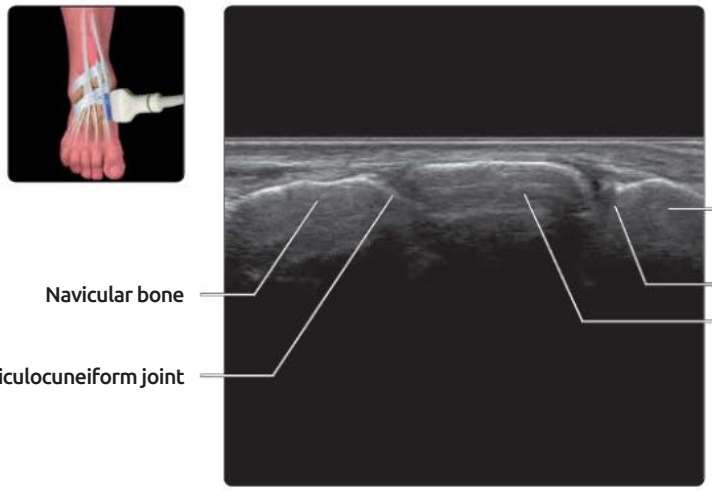

(Top) *Longitudinal US shows the anterior part of talar dome covered with articular cartilage, the talar neck, and the talar head articulating with the navicular bone. These bones form the proximal part of the medial longitudinal arch.* **(Middle)** *Longitudinal US shows the alignment of the talar head and the navicular and cuneiform bones. The navicular and cuneiform bones are at the apex of the medial longitudinal arch.* **(Bottom)** *Longitudinal US shows the alignment of the navicular and medial cuneiform bones, and the base of the 1st metatarsal head. Infective or inflammatory arthritis as well as moderate to severe degrees of osteoarthritis of the midfoot bones can be well evaluated with US.*

JOINTS

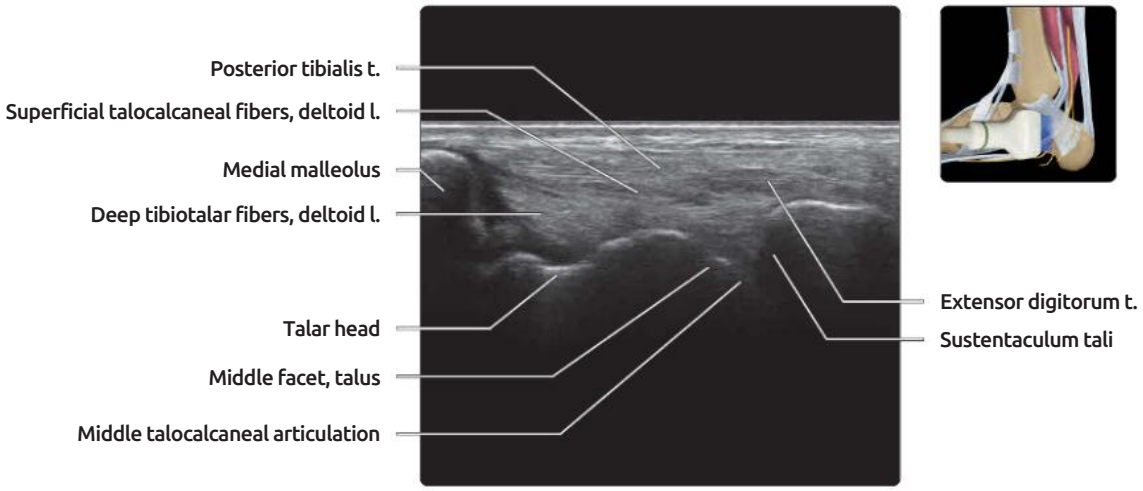

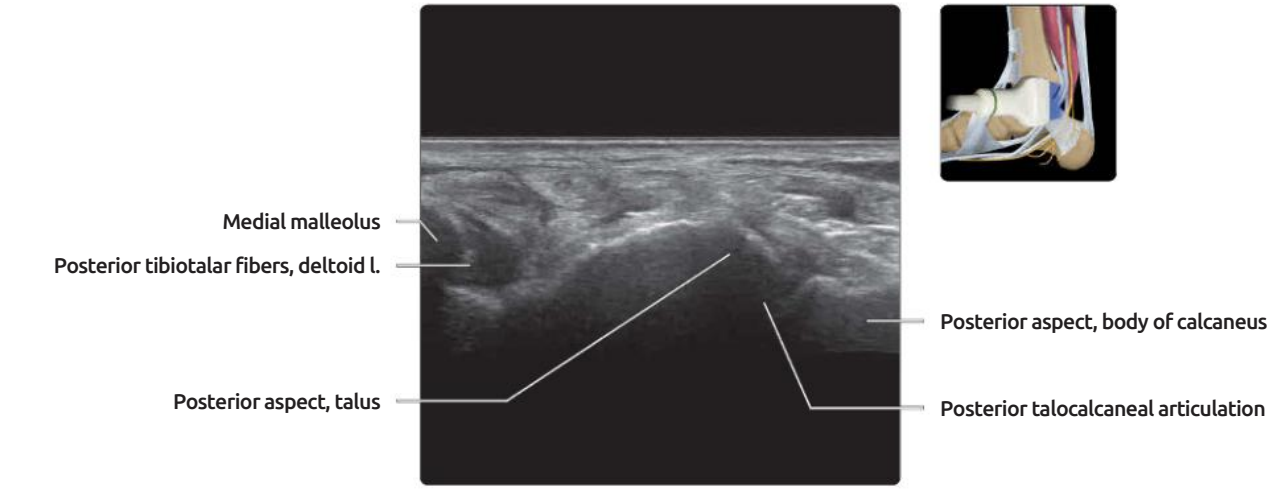

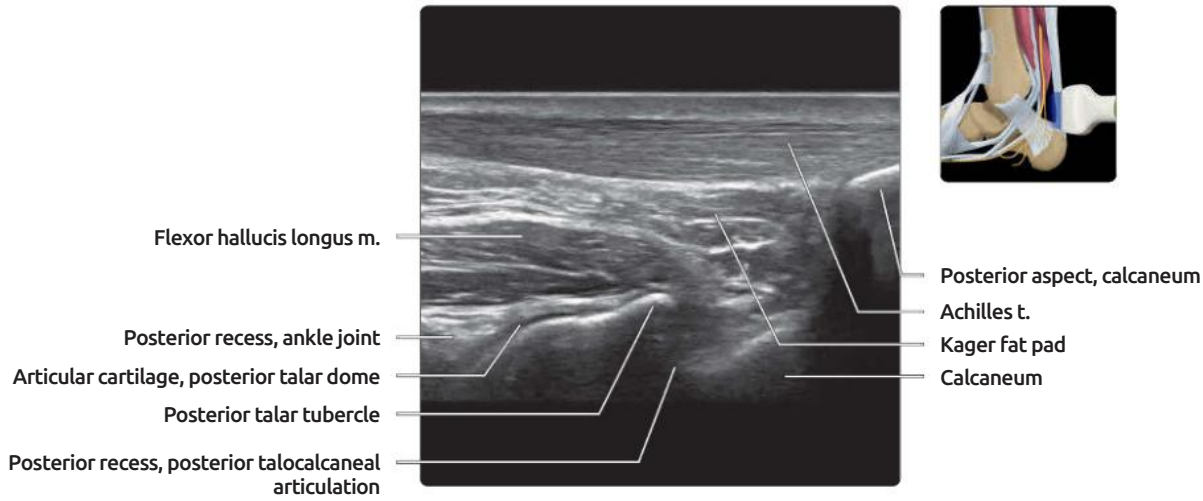

(Top) *Longitudinal US of the medial aspect of the hindfoot shows the middle talocalcaneal articulation. The deep and superficial fibers of the deltoid ligament are also shown.* **(Middle)** *Longitudinal US of the medial aspect of the hindfoot shows the posterior talocalcaneal articulation.* **(Bottom)** *Longitudinal US of the posterior ankle region shows the posterior talocalcaneal joint as well as the ankle joint. The close proximity between the posterior talus and the flexor hallucis longus muscle can be appreciated.*

DORSUM FOOT

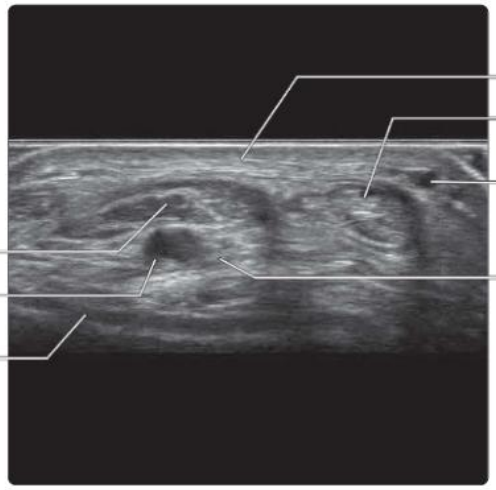

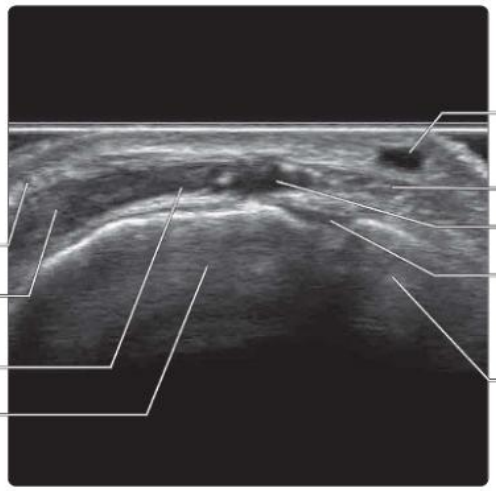

(Top) *Transverse US of the proximal aspect of the dorsum of the hindfoot shows the tendons and vessels lying deep to the extensor retinaculum.* **(Middle)** *Transverse US of the dorsomedial aspect of the proximal midfoot shows the extensor digitorum brevis and extensor hallucis brevis muscles. The extensor digitorum and extensor hallucis longus tendons lie superficially to these muscles. The short saphenous vein is also shown.* **(Bottom)** *Transverse US of the dorsal aspect of the distal aspect of the midfoot shows the proximal margin of the 2 extensor muscles on the dorsum of the midfoot.*

LIGAMENTS

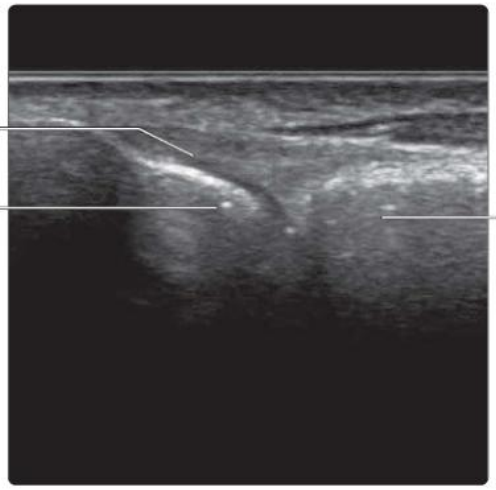

(Top) *Longitudinal US shows the dorsal talonavicular ligament between the distal part of the talus and the proximal part of the navicular bone.* **(Middle)** *Longitudinal US of the lateral aspect of the hindfoot shows the calcaneo-cuboid ligament. The calcaneonavicular ligament (not shown) arises from the same part of the calcaneus, extending medially toward the navicular bone. Both these ligaments form part of the bifurcate ligament, which is a key stabilizer of the Chopart joint, which lies between the hindfoot and the midfoot.* **(Bottom)** *Longitudinal US of the medial aspect of the midfoot shows the superomedial calcaneonavicular fibers of the spring ligament overlying the medial aspect of the talar head. The superficial fibers of the deltoid ligament are attached to this ligament. The fibrocartilaginous gliding zone between the superomedial fibers and the posterior tibialis tendon are also shown.*

PERONEAL TENDONS

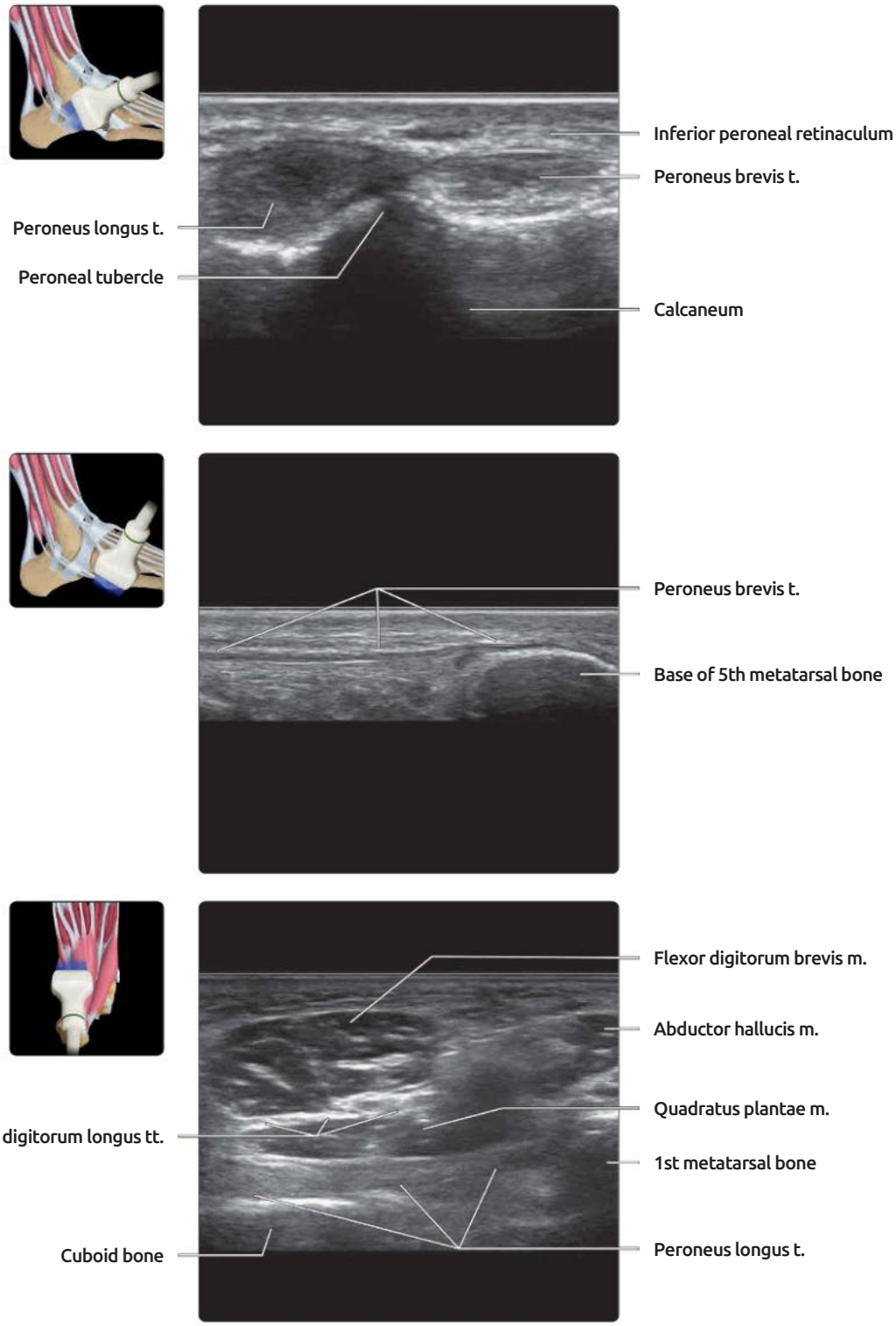

(Top) *Longitudinal US of the lateral aspect of the calcaneus shows the peroneal tubercle with the peroneus longus tendon located more anterior to the peroneus brevis tendon.* **(Middle)** *Longitudinal US of the lateral aspect of the midfoot shows the peroneus brevis tendon attached to the base of the 5th metatarsal bone.* **(Bottom)** *Transverse US of the plantar-lateral aspect of the midfoot shows the peroneus longus tendon on the undersurface of the cuboid bone. The tendon crosses the foot obliquely to insert onto the lateral aspects of the medial cuneiform bone and base of the 1st metatarsal bone.*

TARSAL TUNNEL

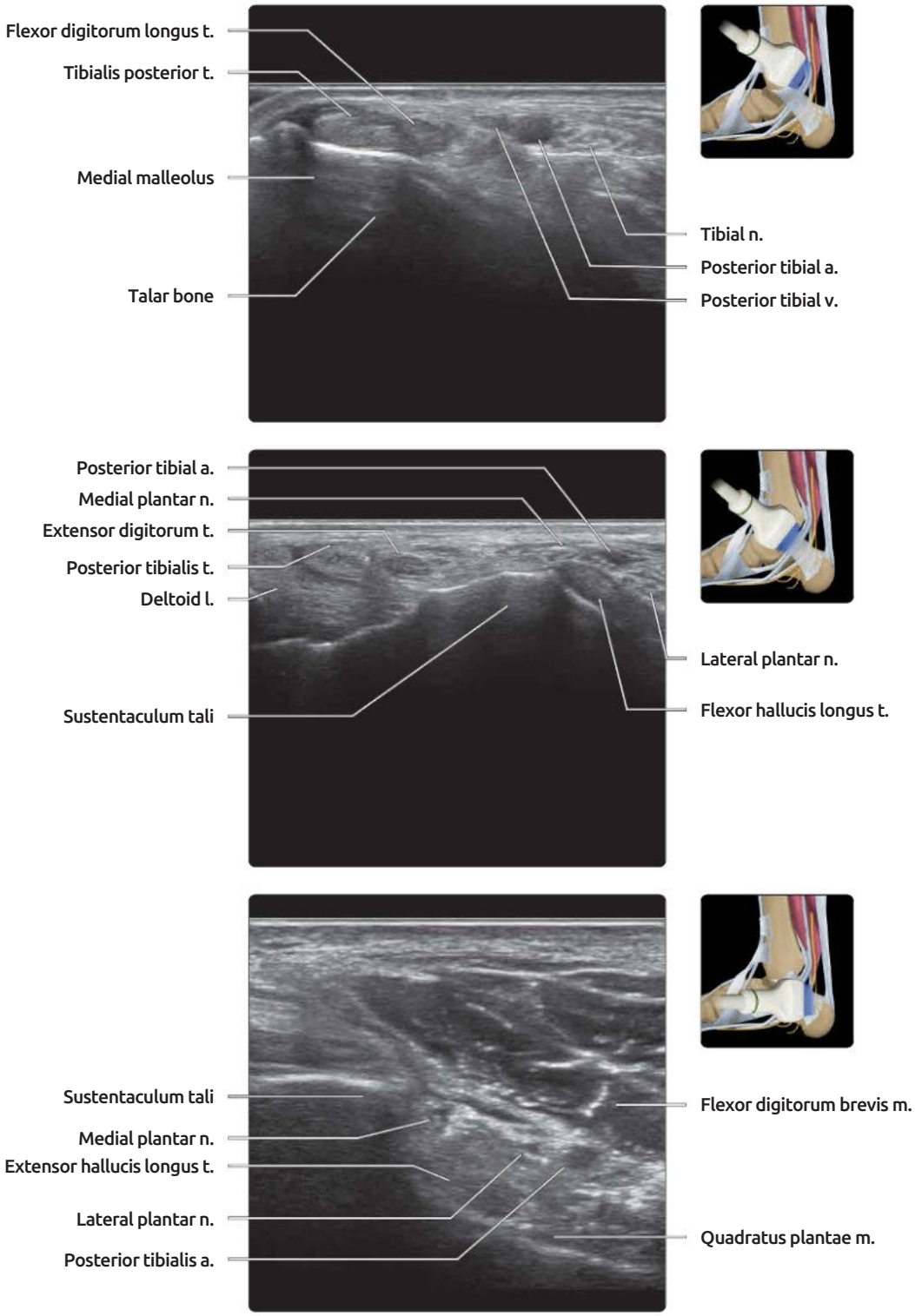

(Top) *Longitudinal US of the medial aspect of the ankle and hindfoot shows the proximal part of the tarsal tunnel.* **(Middle)** *Longitudinal US of the medial aspect of the calcaneus shows the mid to lower part of the tarsal tunnel.* **(Bottom)** *Longitudinal US of the medial aspect of the hindfoot shows the lower part of the tarsal tunnel.*

PLANTAR APONEUROSIS

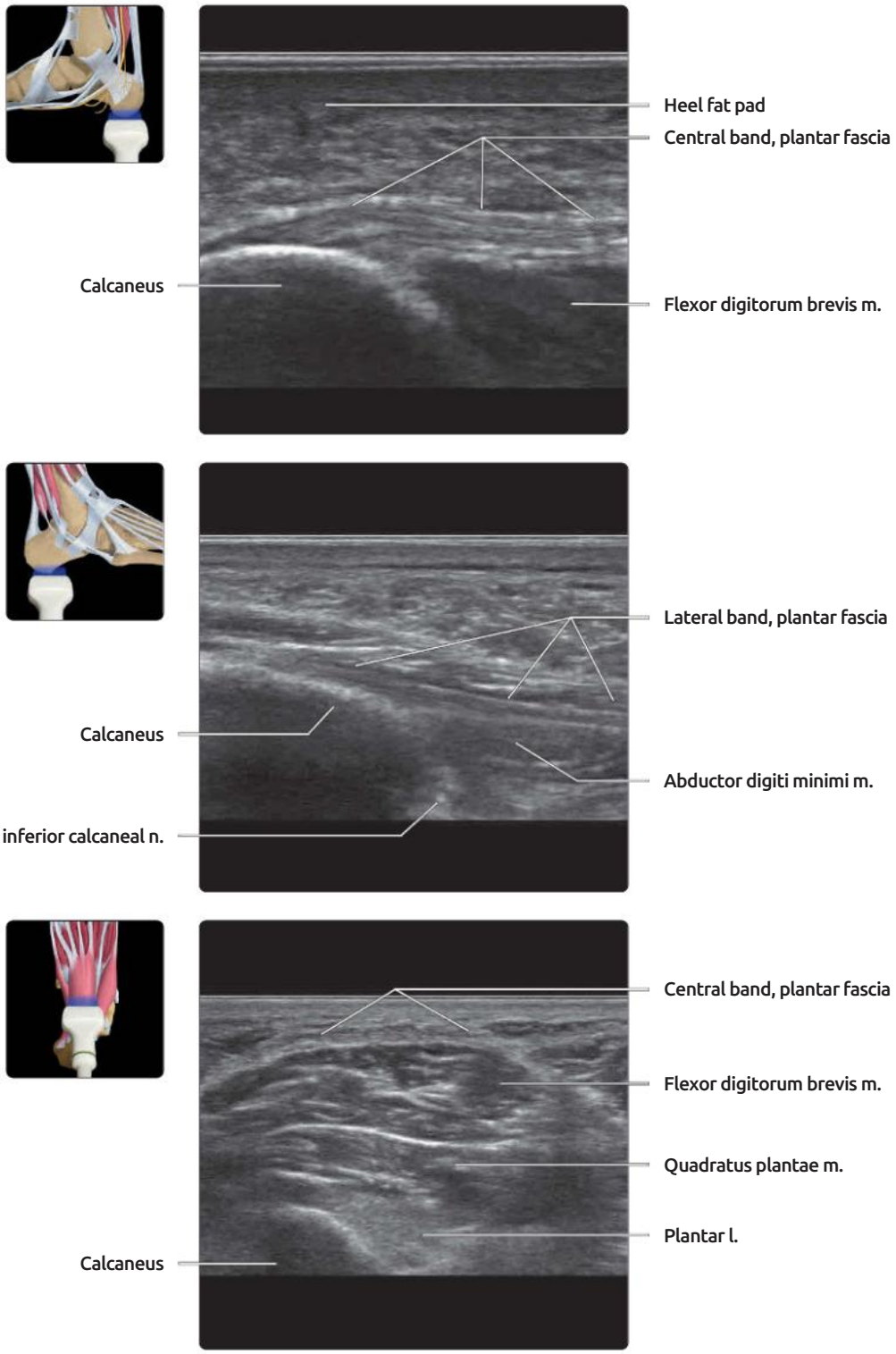

(Top) *Longitudinal US of the plantar aspect of the foot shows the calcaneal insertion (medial calcaneal tuberosity) of the central band of the plantar fascia. Plantar fasciitis occurs at the calcaneal insertion. The heel fat pad is a specialized compartmental fat pad superficial to the calcaneus.* **(Middle)** *Longitudinal US of the plantar aspect of the hindfoot shows the lateral band of plantar fascia at the calcaneal insertion. This is thinner than the medial band and lies superficial to the adductor digiti minimi muscle. The inferior calcaneal nerve lies at the interface between the abductor digiti minimi muscle and the underlying quadratus plantae muscle (not shown).* **(Bottom)** *Transverse US shows the central band of plantar fascia overlying the flexor digitorum brevis muscle. The lateral band (not shown) overlies the abductor digiti minimi muscle.*

MUSCLES OF FOOT, 1ST & 2ND LAYERS

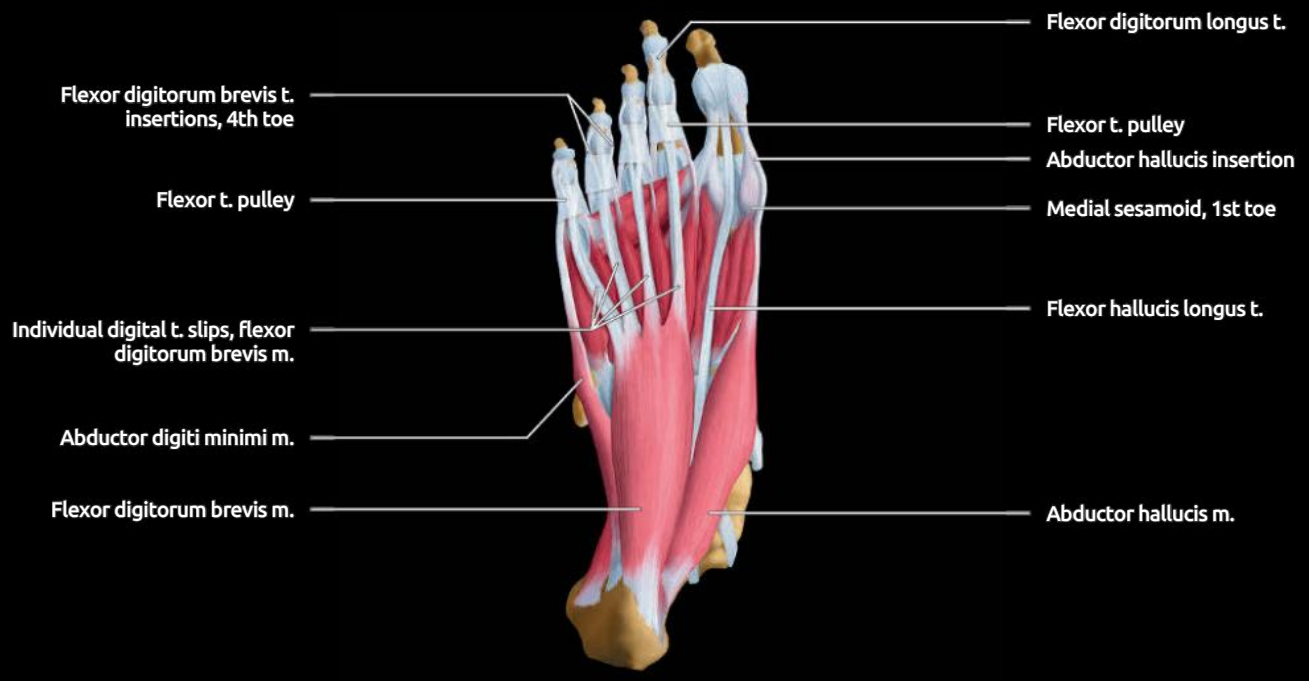

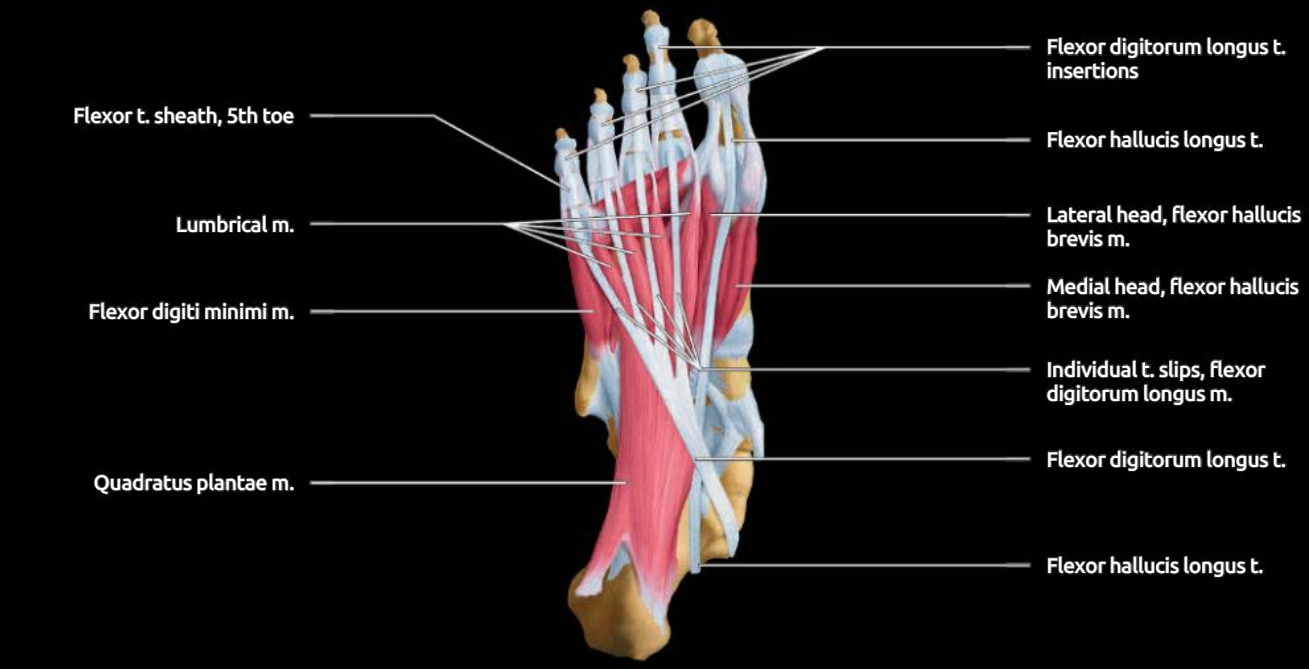

(Top) *Graphic shows the superficial layer of the plantar foot muscles: Abductor digiti minimi, flexor digitorum brevis, and abductor hallucis. The deep muscles are partially visible deep to the superficial layer. The flexor digitorum brevis tendons split in each digit (4th digit labeled), attaching at lateral aspects of the middle phalangeal bases. The flexor tendon pulley system of the toes is similar to that of the fingers with 5 annular pulleys, A1-A5.* **(Bottom)** *Graphic shows the 2nd layer of plantar muscles. The interesting arrangement of interactions between the flexor tendons is well seen: Quadratus plantae inserts onto the flexor digitorum longus tendon, while the lumbricals arise from individual flexor digitorum longus tendon slips. In the toes, the flexor tendons are contained within fibrous annular pulleys similar to the fingers.*

MUSCLES OF FOOT, 3RD AND 4TH LAYERS

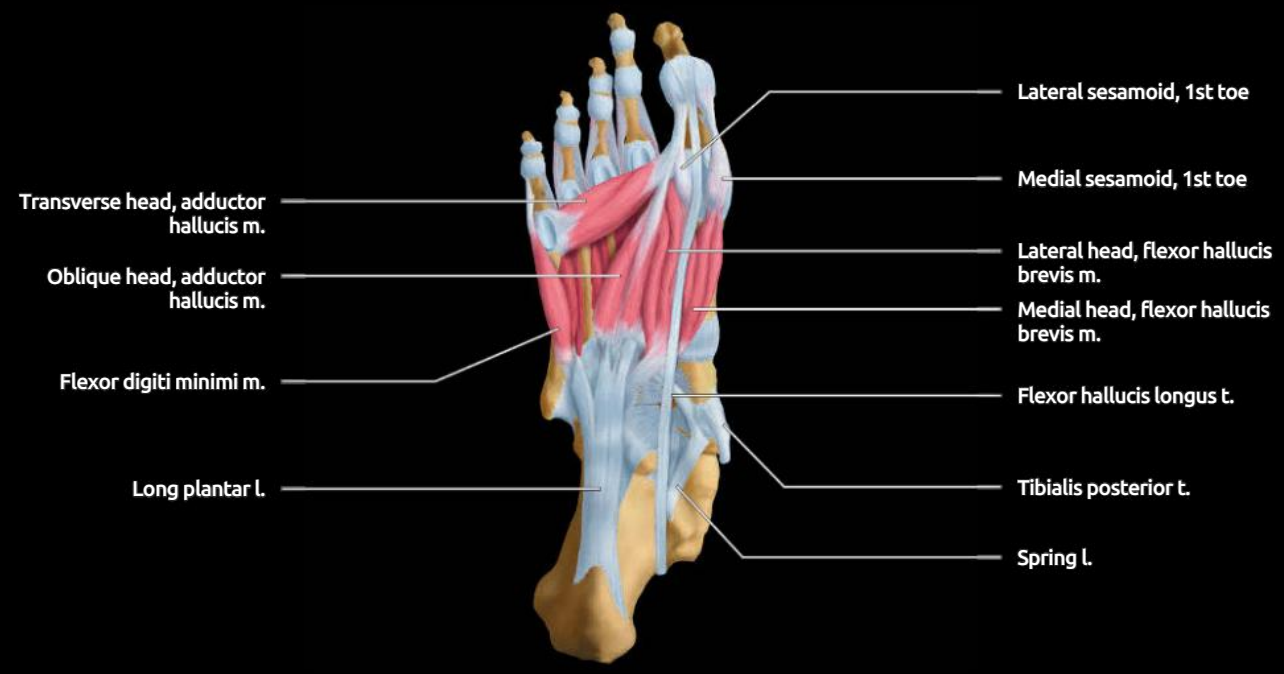

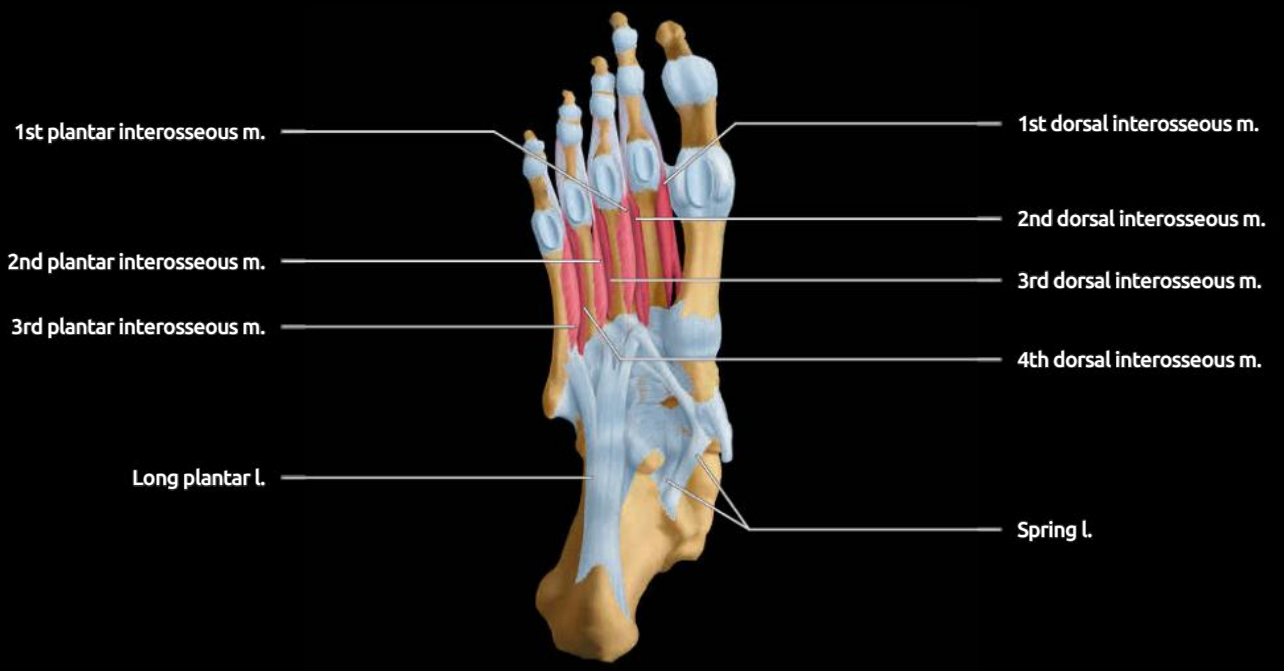

(Top) *Graphic shows the 3rd layer of plantar muscles, which contains the flexor hallucis brevis, flexor digiti minimi, and adductor hallucis muscles. The oblique head of the adductor hallucis is thick and broad, whereas the transverse head is thin.* **(Bottom)** *Graphic shows the 4th layer of plantar muscles, the interosseous muscles. There are 4 dorsal interossei, which have bipennate origins from 2 adjacent metatarsal bones. Additionally, there are 3 plantar interossei. The 1st plantar interosseous muscle originates from the medial side of the 3rd metatarsal bone and inserts on the medial side of the 3rd proximal phalanx. The 2nd and 3rd plantar interossei originate on the medial sides of the 4th and 5th metatarsals, respectively, and insert on the medial side of the corresponding proximal phalanges.*

MUSCLES OF FOOT, CORONAL

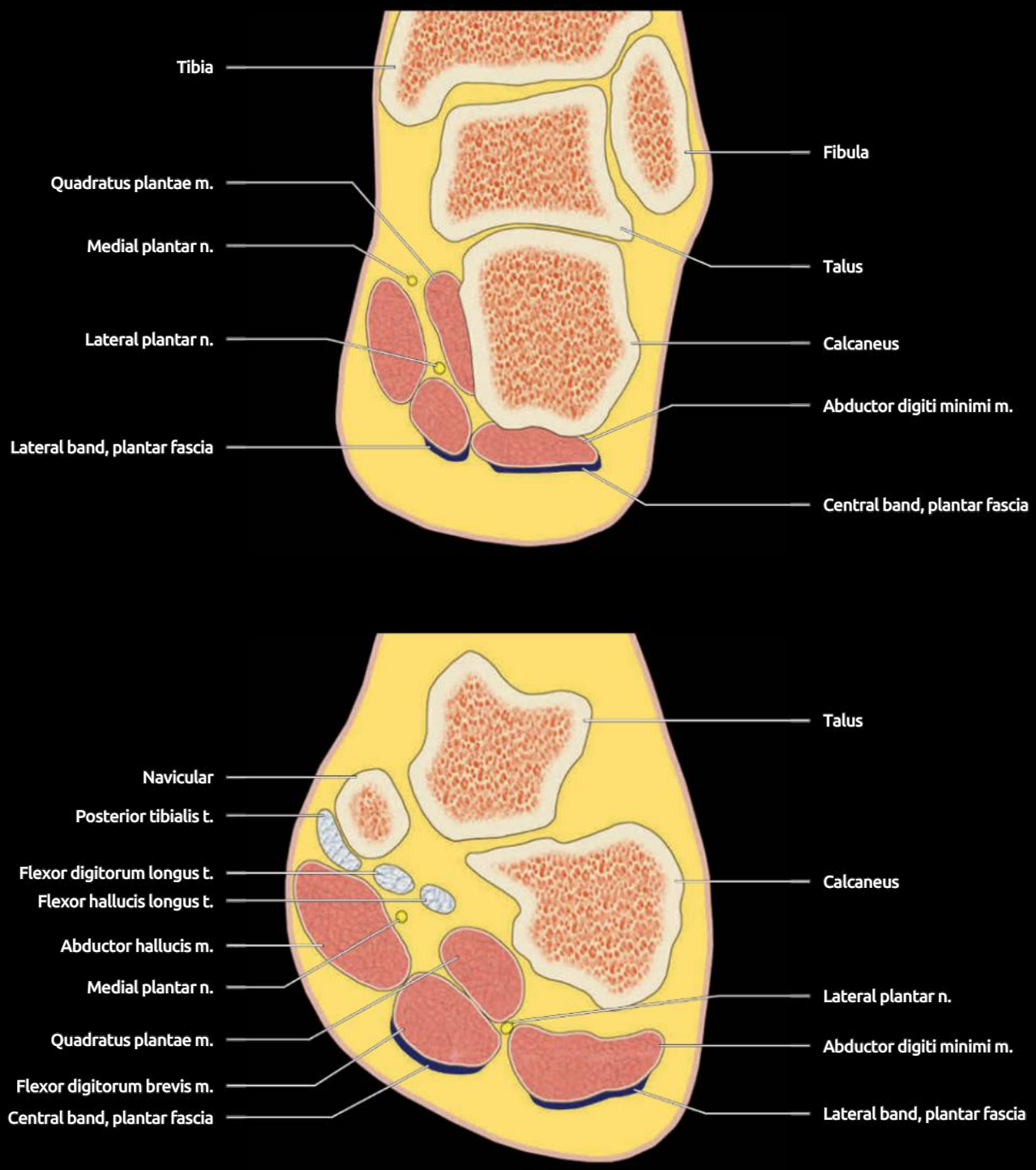

(Top) *Coronal graphic of the midhindfoot level shows the arrangement of plantar foot muscles and intervening plantar nerves.*
(Bottom) *Coronal graphic of the anterior aspect of the hindfoot shows the arrangement of plantar foot muscles and intervening plantar nerves.*

MUSCLES OF FOOT, CORONAL

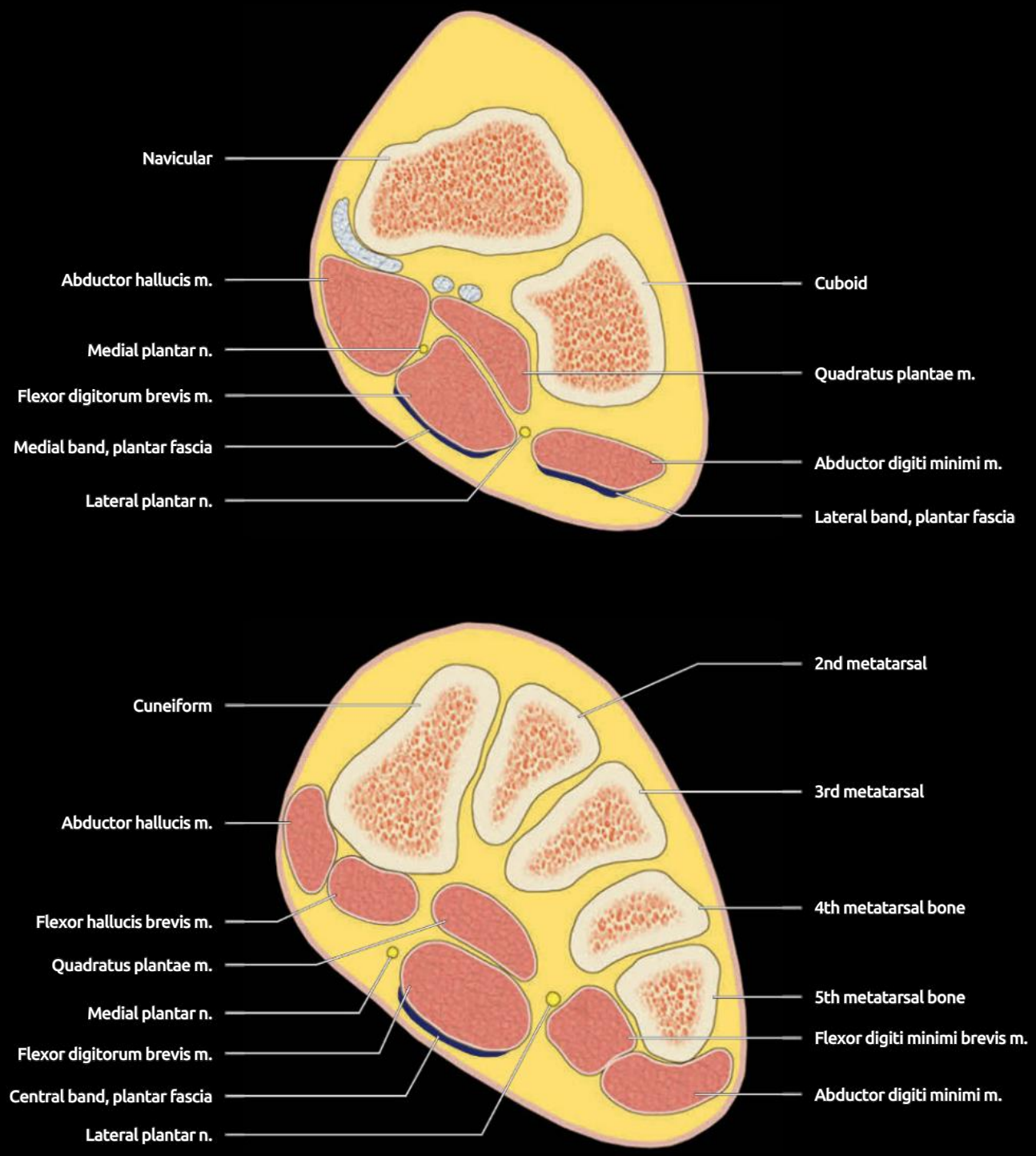

(Top) *Coronal graphic of the proximal midfoot shows the arrangement of foot muscles and intervening plantar nerves.* **(Bottom)** *Coronal graphic of the proximal forefoot shows the arrangement of foot muscles and intervening plantar nerves.*

MEDIAL PLANTAR MUSCLES, HIND- AND MIDFOOT

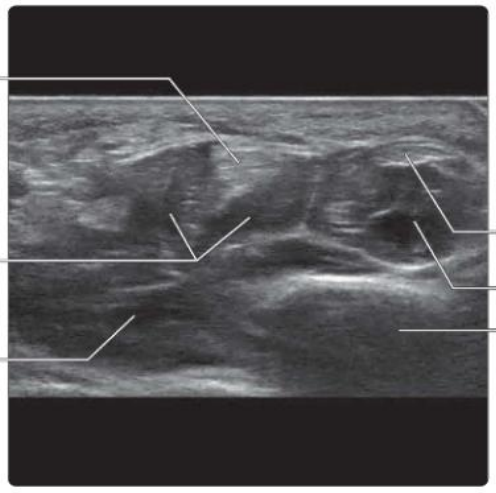

(Top) *Transverse US of the medial aspect of the midfoot shows 1 of the 2 main muscles on the medial aspect of the midfoot, mainly the abductor hallucis muscle. The medial plantar artery and nerve lie between this muscle and the more centrally located flexor digitorum brevis and quadratus plantae muscles. The intersection between the flexor digitorum longus tendon and the flexor hallucis longus tendon is located deep to the proximal margin of the abductor hallucis muscle.* **(Middle)** *Transverse US of the mid to distal portion of the medial plantar aspect of the foot shows the flexor hallucis brevis muscle arising on the lateral aspect of the abductor hallucis muscle. The flexor hallucis longus tendon indents the flexor hallucis brevis muscle. The medial plantar artery serves as a good landmark for the medial plantar nerve.* **(Bottom)** *Transverse US of the distal medial plantar aspect of the foot shows the abductor hallucis muscle, flexor hallucis brevis muscle, and the oblique head of the abductor hallucis muscle all lined up just proximal to the 1st metatarsophalangeal joint.*

CENTRAL PLANTAR MUSCLES, HIND- AND MIDFOOT

(Top) *Transverse US of the proximal end middle 1/3 plantar aspect of the foot shows the 2 muscles on the plantar aspect of the foot centrally, namely, the flexor digitorum brevis muscle more superficially and the quadratus plantae muscle more deeply. The lateral plantar artery, vein, and nerve run between these muscles from medial to lateral. The central band of the plantar fascia is attached to the superficial margin of the flexor digitorum brevis muscle.* **(Middle)** *Transverse US of the plantar aspect of the central midfoot more distally shows the tendons of the flexor digitorum longus muscle spreading out between the flexor digitorum brevis and the quadratus plantae muscles. The flexor digitorum brevis tendons attach to the bases of the middle phalanges. The quadratus plantae inserts onto the flexor digitorum longus tendons.* **(Bottom)** *Longitudinal oblique US of the midfoot shows the central band of the plantar fascia attached to the planter aspect of the flexor digitorum brevis muscle. Between this and the underlying quadratus plantae muscle is the flexor digitorum longus tendon.*

LATERAL PLANTAR MUSCLES, HIND- AND MIDFOOT

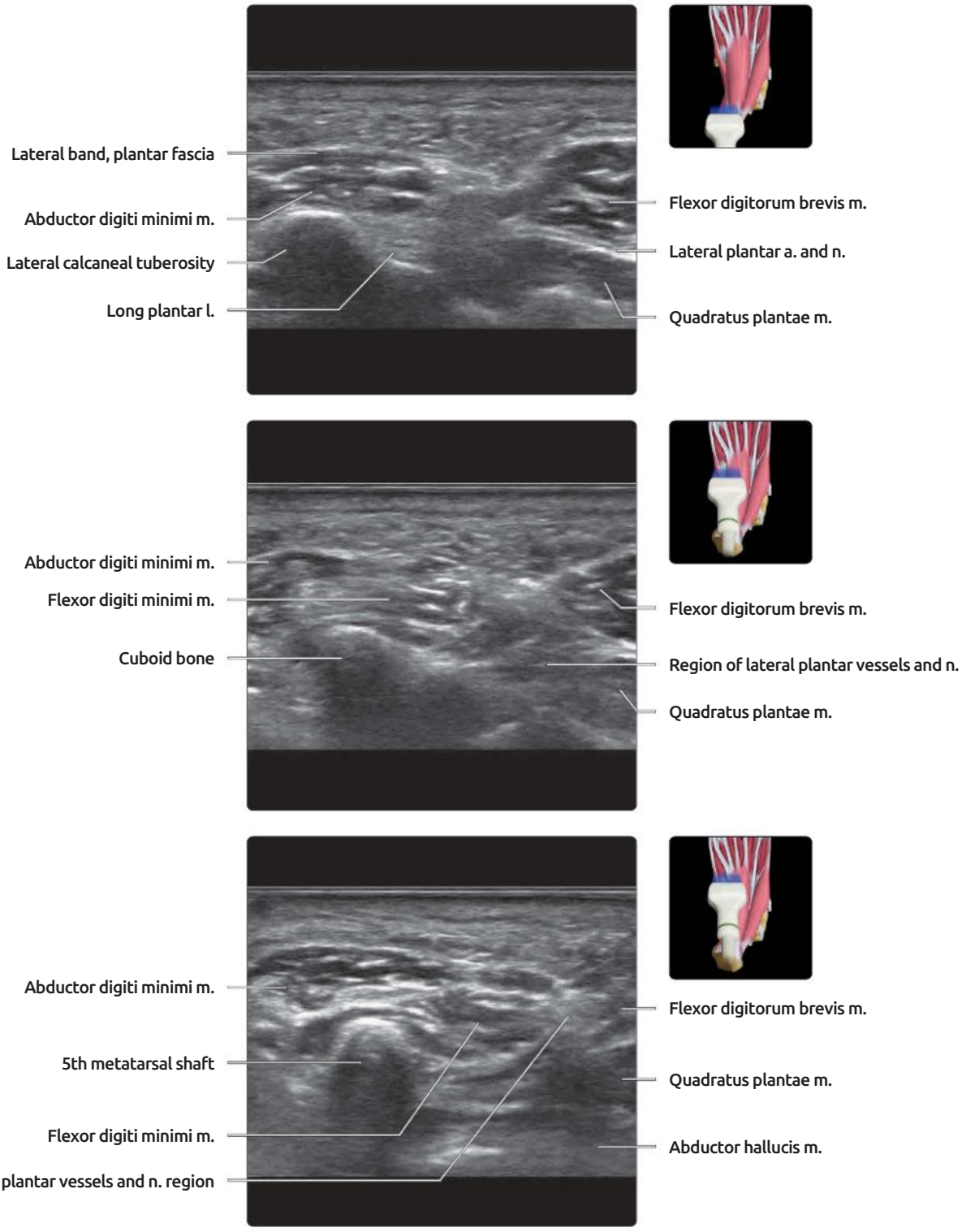

(Top) *Transverse US of the proximal lateral aspect of the sole shows the abductor digiti minimi muscle, which arises from the inferior and lateral aspects of the calcaneal tuberosity, the plantar aponeurosis and the intermuscular septum with the flexor digitorum brevis muscle. It inserts into the lateral aspect of the base of the proximal phalanx little toe.* **(Middle)** *Transverse US of the lateral aspect midportion of the sole shows the flexor digiti minimi muscle, which runs from the 5th metatarsal base to the lateral aspect of the base of the proximal phalanx little toe. Along its course, the flexor digiti minimi tendon is accompanied medially and superficially by the lateral branch of the lateral plantar nerve.* **(Bottom)** *Transverse US of the lateral aspect of the mid to distal sole shows the flexor digiti minimi muscle located on the medial aspect of the abductor digiti minimi muscle.*

IMAGING ANATOMY

Metatarsal Bones

- 1st metatarsal bone
  - Tibialis anterior tendon attaches medially; peroneus longus tendon attaches at plantar aspect
  - 1st dorsal interosseous muscle attaches laterally
- 2nd-4th metatarsal bones
  - Gradually smaller & shorter moving laterally
  - Interosseous muscles attached to medial & lateral sides
- 5th metatarsal bone
  - Peroneus brevis & tertius tendons insert to base laterally; lateral band plantar fascia inserts to base medially

Phalanges

- Flexor & extensor digitorum longus tendons inserts to distal phalanges
- Flexor & extensor digitorum brevis tendons inserts to middle phalanges
- Interosseous muscles & lumbricals inserts to 2nd-4th proximal phalanges

Digital nerves

- Medial & lateral plantar nerves give rise to common digital nerves at metatarsal base level
  - Common digital nerves give rise to median & lateral proper digital nerves at metatarsophalangeal (MTP) joint
    - Proper digital nerves run along medial & lateral sides of digits

1st MTP Joint

- Metatarsal head has 2 concave facets on plantar surface, 1 for each sesamoid, separated by ridge (crista)
- **Sesamoid bones**
  - Either sesamoid may be bipartite or tripartite, medial > lateral
    - Bipartite sesamoid typically larger than single sesamoid with irregular opposing contour
  - Alternatively, either sesamoid may be hypoplastic or aplastic
  - Sesamoids fixed mainly relative to proximal phalangeal base, move relative to 1st metatarsal bone
    - Therefore, displaced laterally in hallux valgus
  - Fixed in position though tendon & ligament attachment
    - Medial head flexor hallucis brevis, abductor hallucis tendons attach to medial sesamoid bone
    - Lateral head flexor hallucis brevis, oblique & transverse heads adductor hallucis tendons attach to lateral sesamoid bone
  - Medial & lateral sesamoid bones joined by intersesamoid ligament
    - Intersesamoid ligament provides floor for flexor hallucis longus tendon
  - Sesamoid bones are also supported by paired medial & lateral sesamoid-phalangeal & sesamoid-metatarsal ligaments
  - Both sesamoid bones are also partially embedded in MTP plantar plate
- **Plantar plate**
  - Fibrocartilaginous plantar plate extending from metatarsal neck to base of proximal phalanx
    - Firmly attached & thicker at phalangeal base
      - Loosely attaches to metatarsal neck
      - May have small, echogenic central recess, up to 2.5 mm long, near phalangeal base
  - Prevents hyperextension of MTP joint

Lesser MTP Joints

- Sesamoid bones variably present, most commonly at 5th toe
- **Plantar plate**
  - Fibrocartilaginous plate extending from metatarsal neck to base of proximal phalanx
    - Attached firmly to phalangeal base, loosely to metatarsal neck
    - Small central recess near phalangeal base is normal
  - Attached to medial & lateral accessory collateral ligaments, intermetatarsal ligament, plantar fascia, & flexor digitorum longus tendon sheath
  - Similar in composition to knee menisci

Flexor Tendon Pulleys

- Flexor tendons of toes have rather similar arrangement to that of fingers

CLINICAL IMPLICATIONS

Turf Toe

- Broad term referring to any injury of MTP joint
  - Usually plantar plate or sesamoid injury
- Plantar plate may, similar to menisci, undergo chronic degeneration ± acute tear
- Plantar plate tear of 1st MTP does not induce exuberant reactive capsular/pericapsular fibrosis, as it is not attached to accessory collateral ligament

Lesser MTP Joint Plantar Plate Injury

- Most commonly injured is 2nd MTP joint plantar plate
  - Typically, at inferolateral aspect of MTP joint at junction between plantar plate & accessory collateral ligament, near phalangeal base
  - May give rise to exuberant fibrosis eccentrically at inferolateral aspect of joint
    - Should not be confused with Morton neuroma
      - Morton neuroma lies centrally in intermetatarsal space, while reactive fibrosis lies eccentrically
- Dynamic US during MTP dorsiflexion or dorsal drawer (Lachman) test can help assessment of plantar plate integrity & MTP joint stability

Morton Neuroma

- Reactive-type fibrous mass around plantar common digital nerve, typically at bifurcation
  - Most commonly occurs at interspace between 3rd & 4th metatarsal heads
- Digital nerves located superficial to intermetatarsal ligament while intermetatarsal bursa located deeper
- Pressure with thumb on dorsal aspect forefoot or squeeze test (Mulder maneuver) helps move hypoechoic neuroma toward plantar-placed transducer

Joplin Neuroma

- Rare perineural fibrosis of medial proper plantar digital nerve alongside medial sesamoid of hallux
  - May result from bunion surgery

FOREFOOT MUSCLES AND LESSER METATARSOPHALANGEAL JOINT

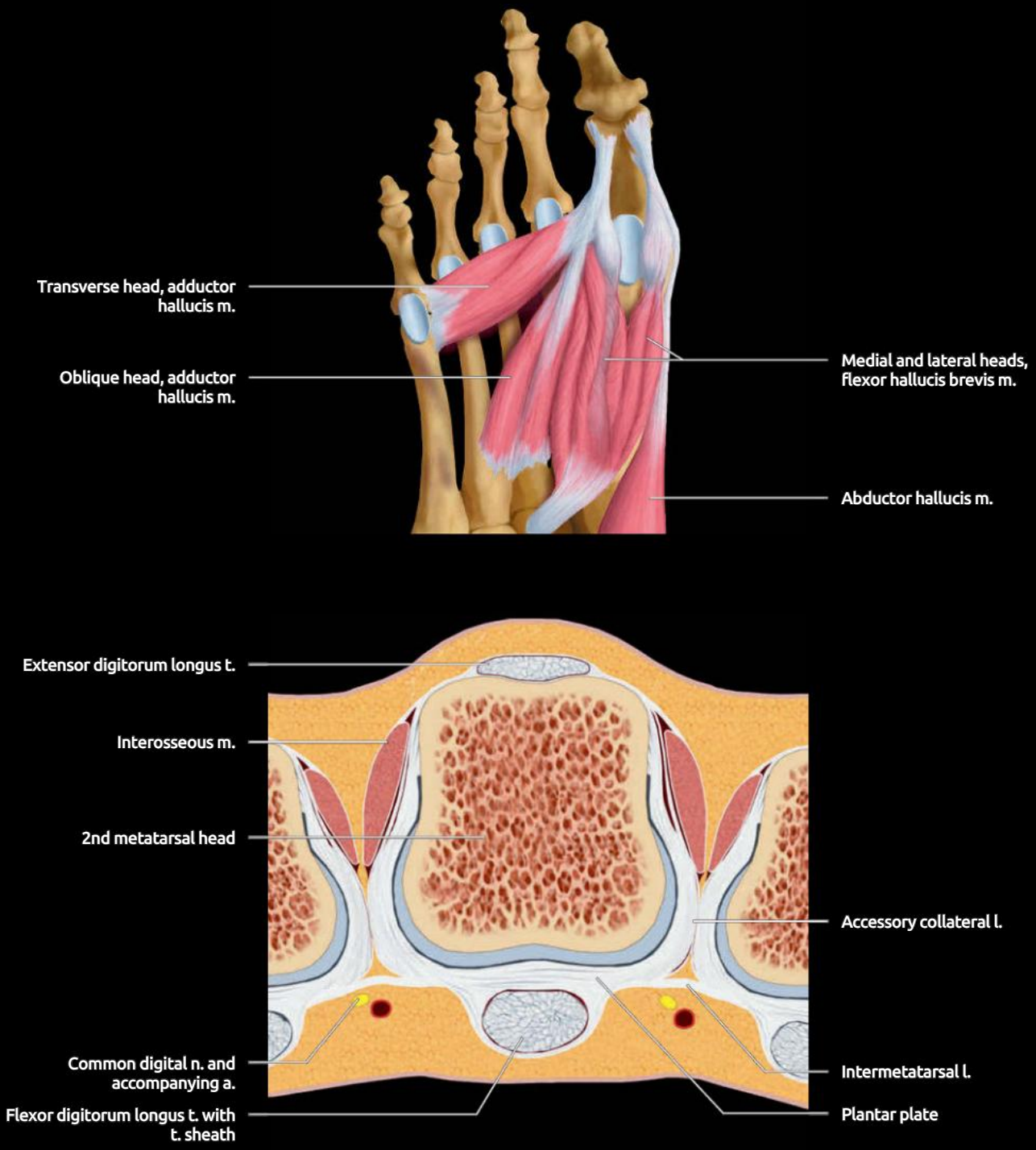

(Top) *Graphic shows the tendon attachments to the sesamoid bones of the 1st metatarsophalangeal (MTP) joint. The tendons of the abductor hallucis muscle and the medial head of the flexor hallucis brevis muscle attach to the medial sesamoid bone. The tendons of the lateral head of the flexor hallucis brevis muscle and both the oblique and transverse heads of the adductor hallucis muscle attach to the lateral sesamoid bone.* **(Bottom)** *Graphic of the 2nd MTP joint shows the plantar plate firmly connected to the accessory collateral ligaments bilaterally. The plantar plate is also connected to the flexor digitorum longus tendon sheath and the intermetatarsal ligaments. The digital nerves lie on the plantar aspect of the intermetatarsal ligaments. The intermetatarsal bursa (not shown) lies deep to the intermetatarsal ligaments.*

FOREFOOT PLANTAR MUSCLES

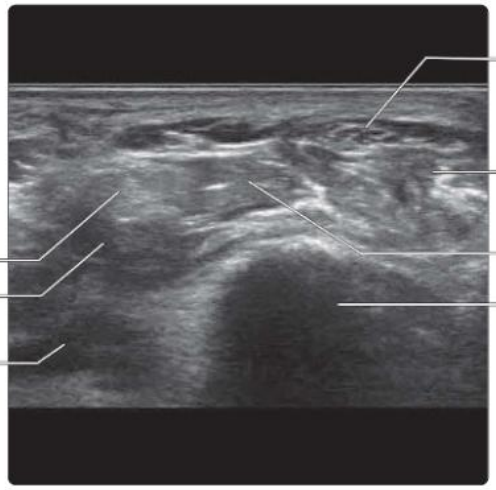

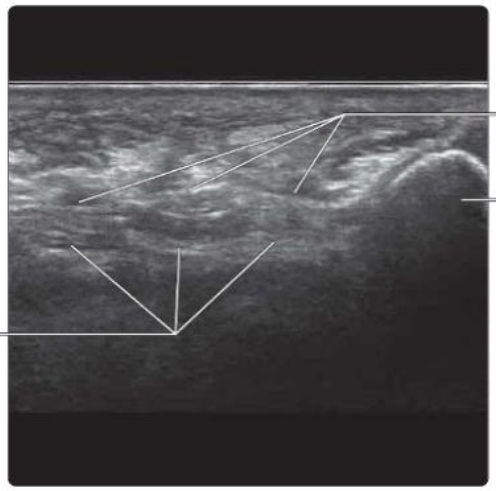

(Top) *The main muscles on the medial aspect of the midforefoot are the abductor hallucis muscle and the medial and lateral heads of the flexor hallucis brevis muscle. The flexor hallucis longus (FHL) tendon separates the 2 heads of the flexor hallucis brevis muscle. The FHL tendon can be readily identified on US by passively flexing and extending the big toe. Lateral to the flexor hallucis brevis muscle lies the oblique head of the adductor hallucis muscle.* **(Middle)** *Transverse oblique US of the forefoot shows the large oblique head of the adductor hallucis muscle extending toward the medial sesamoid bone of the 1st MTP joint.* **(Bottom)** *Transverse US shows the much smaller transverse head of the adductor hallucis muscle. This muscle is aligned transversely along the forefoot at the level of the metatarsal heads with the medial end attaching to the medial sesamoid bone of the 1st MTP joint.*

2ND METATARSOPHALANGEAL JOINT

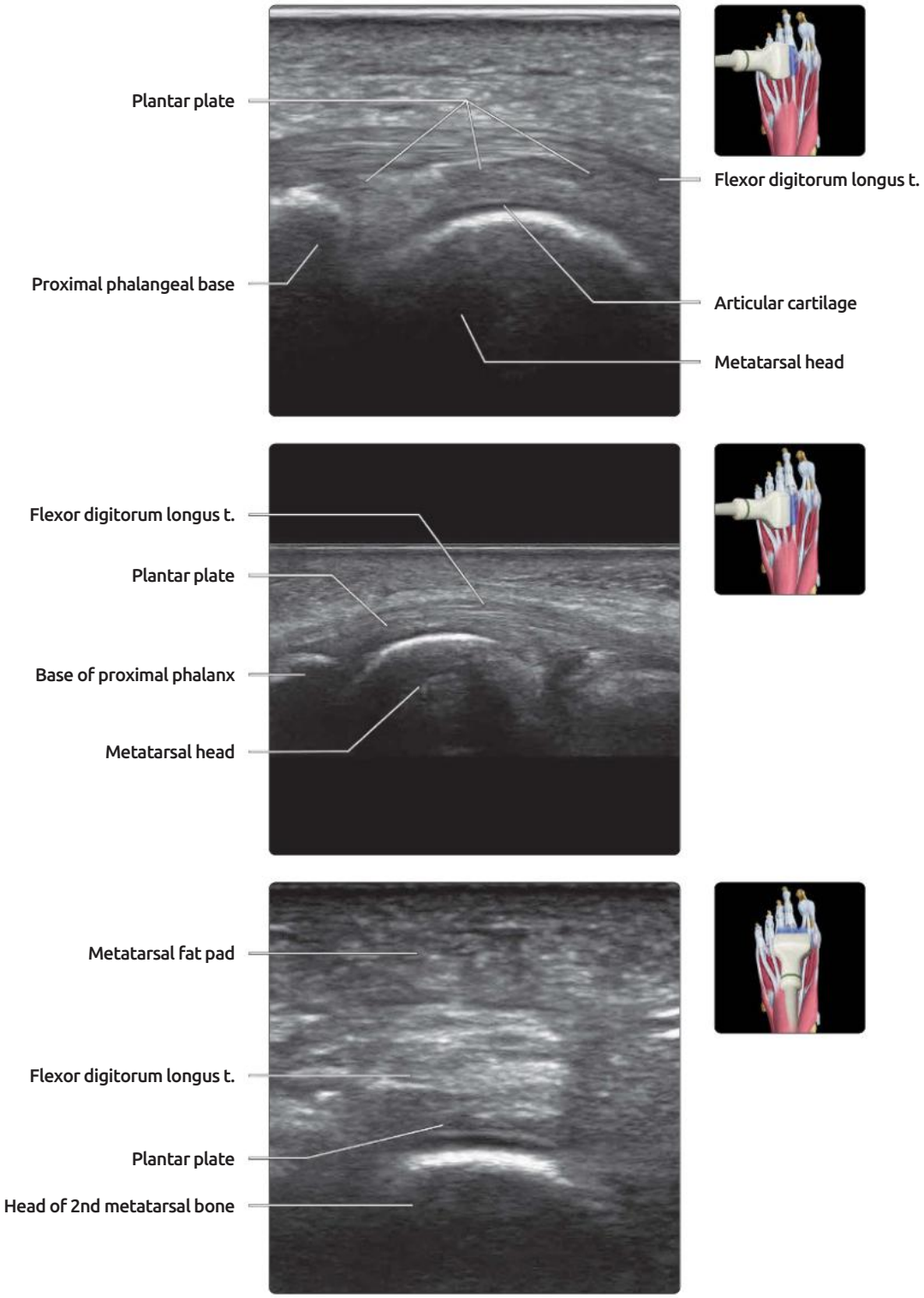

(Top) *Longitudinal US of the 2nd MTP joint shows the fibrocartilaginous plantar plate located deep to the flexor digitorum longus tendon. The plantar plate attaches firmly to the base of the proximal phalanx and loosely to the metatarsal neck (not shown). It is similar in consistency to the knee menisci.* **(Middle)** *Longitudinal US with wider field-of-view than previous image shows the plantar plate overlying the metatarsal head.* **(Bottom)** *Transverse US shows the plantar plate deep to the flexor digitorum longus tendon of the 2nd MTP joint. Most plantar plate tears occur at the junction between the accessory collateral ligament and the lateral aspect of the plantar plate. Chronic tear may result in exuberant reactive fibrosis at the site of tear, typically at the inferolateral aspect of the MTP joint.*

DORSAL AND PLANTAR FOOT ARTERIES AND NERVES

(Top) *Graphic shows arteries and nerves on the dorsum of the foot. The deep peroneal nerve accompanies the anterior tibial artery. The superficial peroneal nerve divides into medial and lateral branches in the distal 1/3 of the leg. The anterior tibial artery is called the dorsal pedis artery on crossing the ankle joint. The dorsalis pedis artery terminates in the arcuate artery, which communicates with the plantar arterial arch and the digital arteries.* **(Bottom)** *Graphic shows arteries and nerves on the plantar aspect of the foot. The posterior tibial artery and the tibial nerve divide into medial and lateral plantar branches. The median and lateral plantar nerves follow the median and lateral plantar arteries, respectively. Identification of the medial and lateral plantar arteries on US to the midfoot provides a good indicator as the location of the accompanying medial and lateral plantar nerves. Thereafter, the arteries accompany the common digital nerves to the MTP joints and then the proper digital nerves to the toes.*

LAYERS 1 AND 2 OF PLANTAR MUSCLES WITH FLEXOR TENDONS

(Top) *Graphic shows the superficial layer of muscles. The central band of the plantar fascia (not shown) overlies the flexor digitorum brevis muscle, while the lateral band of the plantar fascia (not shown) overlies the abductor digiti minimi muscle. The flexor digitorum brevis tendon splits in each digit, attaching at the lateral aspect of the middle phalangeal bases. The flexor pulley system in the toes is similar to that in the fingers.* **(Bottom)** *Graphic shows the 2nd layer of the plantar muscles. The quadratus plantae muscle arises from the medial and lateral sides of the calcaneum, separated by the plantar ligaments. It inserts into the flexor digitorum longus tendon slips.*

1ST METATARSOPHALANGEAL JOINT

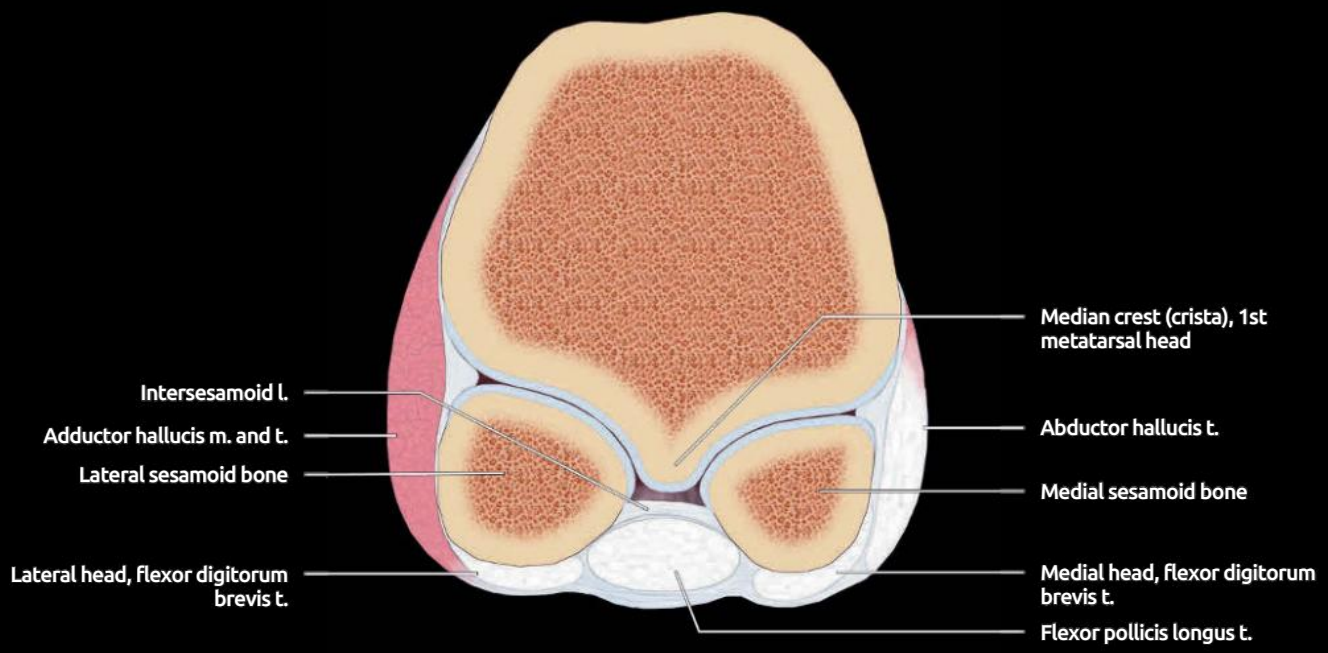

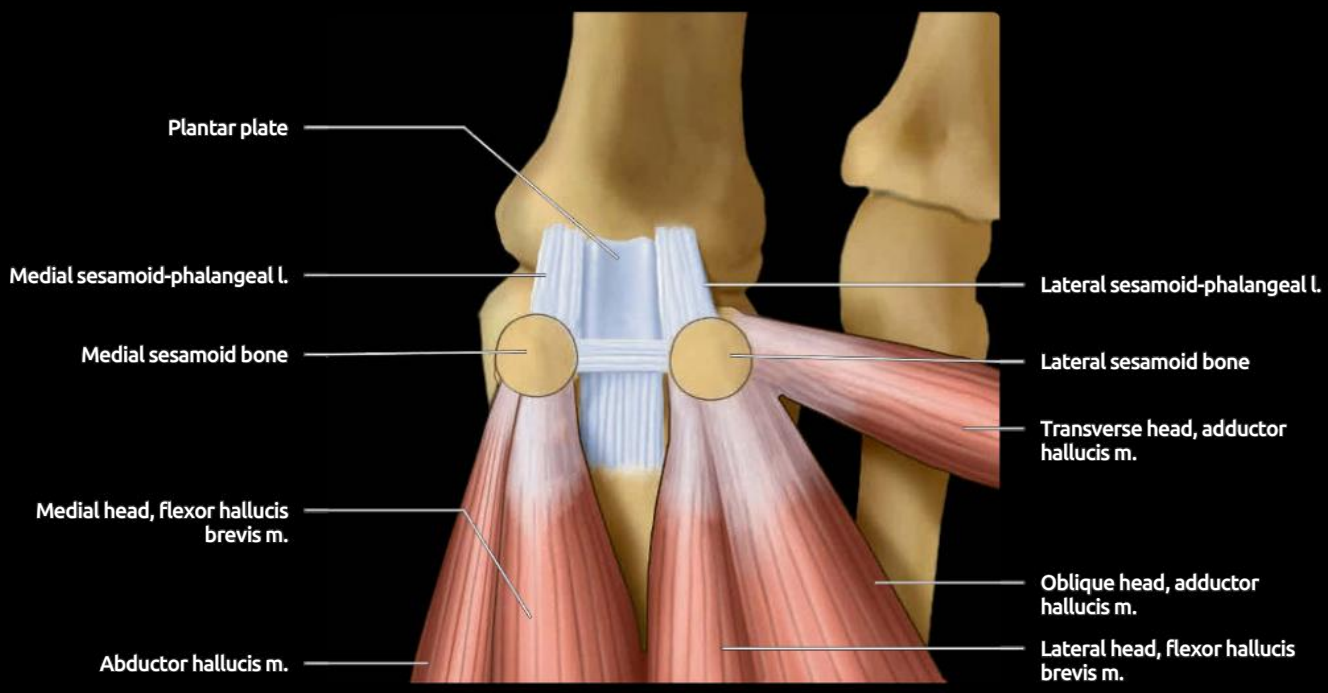

(Top) *Graphic shows the sesamoid bones located on the plantar surface of the 1st metatarsal head, separated by the median crest (crista) of the metatarsal head. The sesamoids are united by the intersesamoid ligament. The intersesamoid ligament forms a floor for the FHL tendon.* **(Bottom)** *Graphic shows the tendon attachments to the medial and lateral sesamoid bones on the plantar aspect of the MTP joint. The abductor hallucis tendon and the tendon from the medial head of the flexor digitorum brevis muscle are attached to the medial sesamoid bone. The tendon from the lateral head of the flexor digitorum brevis muscle as well as the tendons from the oblique and transverse heads of the adductor hallucis muscle are attached to the lateral sesamoid bone. The sesamoid bone is also supported by the intersesamoid ligament as well as the paired sesamoid-phalangeal and sesamoid-metatarsal (not shown) ligaments.*

PLANTAR ASPECT, 1ST METATARSOPHALANGEAL JOINT

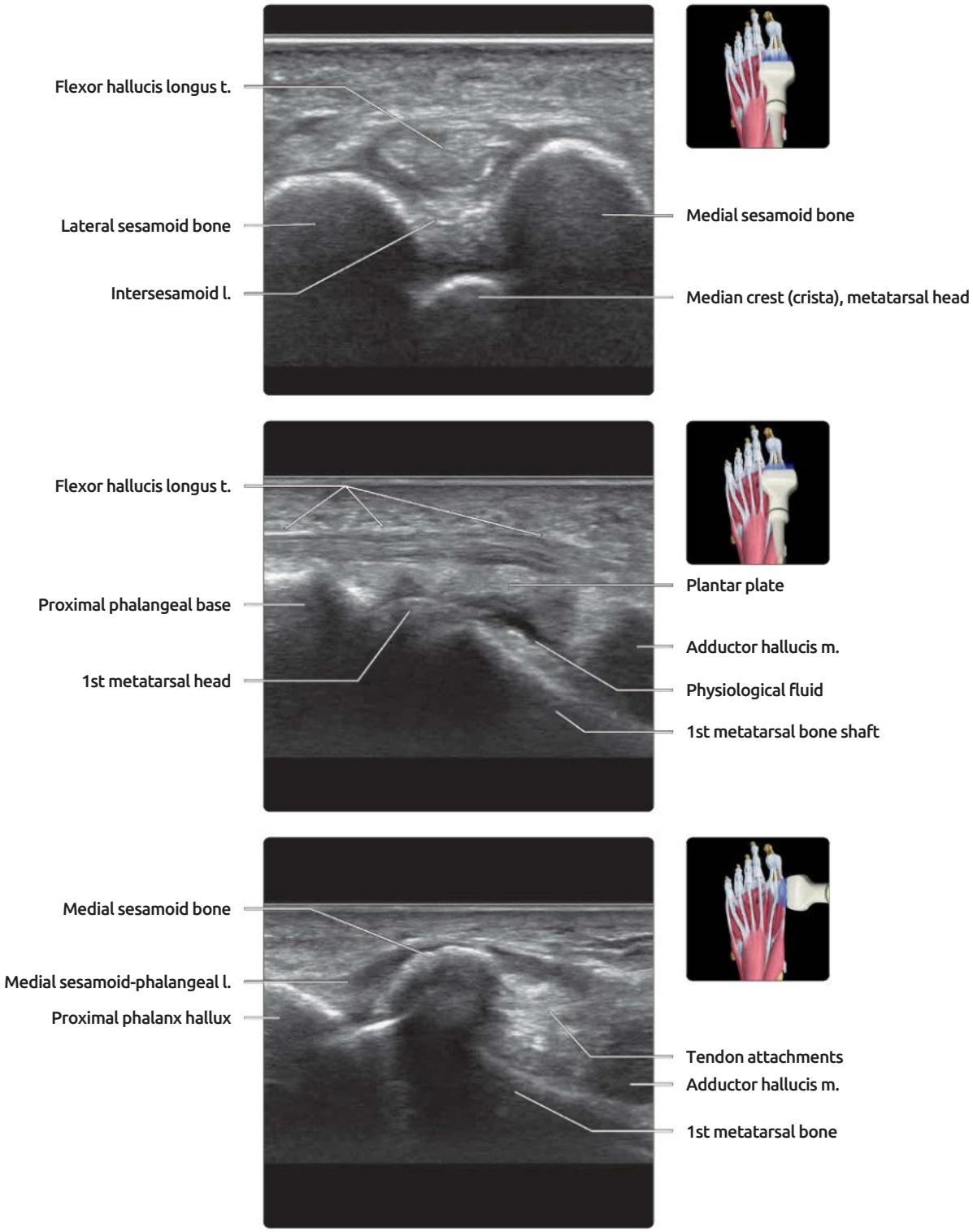

(Top) *Transverse US of the plantar aspect of the 1st MTP joint shows the medial and lateral sesamoid bones with the intervening intersesamoid ligament and the FHL tendon. The crista of the metatarsal head is also shown.* **(Middle)** *Longitudinal US of the plantar aspect of the 1st MTP joint shows the FHL tendon overlying the plantar plate. There is a small amount of physiological joint fluid present within the proximal recess of the MTP joint.* **(Bottom)** *Longitudinal US shows the medial sesamoid bone at the 1st MTP joint. This sesamoid bone is attached distally via the sesamoid-phalangeal ligament to the base of the proximal phalanx. The tendons of the adductor hallucis muscle and the medial head of the flexor digitorum brevis muscle attach to the medial sesamoid bone.*

PLANTAR ASPECT HALLUX

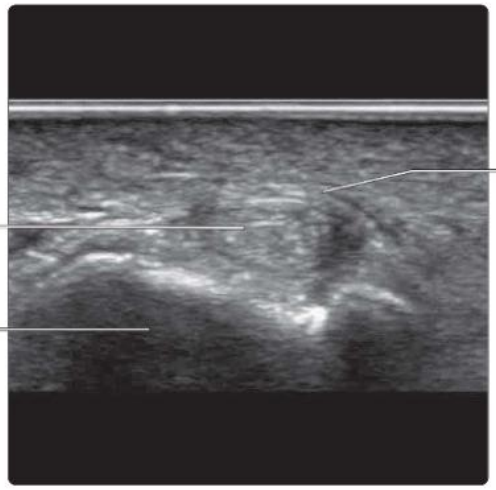

(Top) *Longitudinal US shows the plantar aspect of the hallux. There is a single ossicle deep to the FHL tendon. A single central or 2 laterally placed ossicles are common on the plantar aspect of the interphalangeal joint of the hallux. These are not sesamoid bones, as they are not embedded in the flexor tendon. A bursa may exist between the ossicles and the flexor tendon. The FHL tendon inserts into the base of the distal phalanx.* **(Middle)** *Transverse US of the proximal phalanx of the hallux shows the flexor digitorum longus tendon with an overlying annular pulley. The annular pulley system in the toes is similar to that in the fingers though not as distinct.* **(Bottom)** *Transverse US at the head of the proximal phalanx shows the volar plate and the overlying FHL tendon.*

DORSAL ASPECT FOREFOOT AND HALLUX

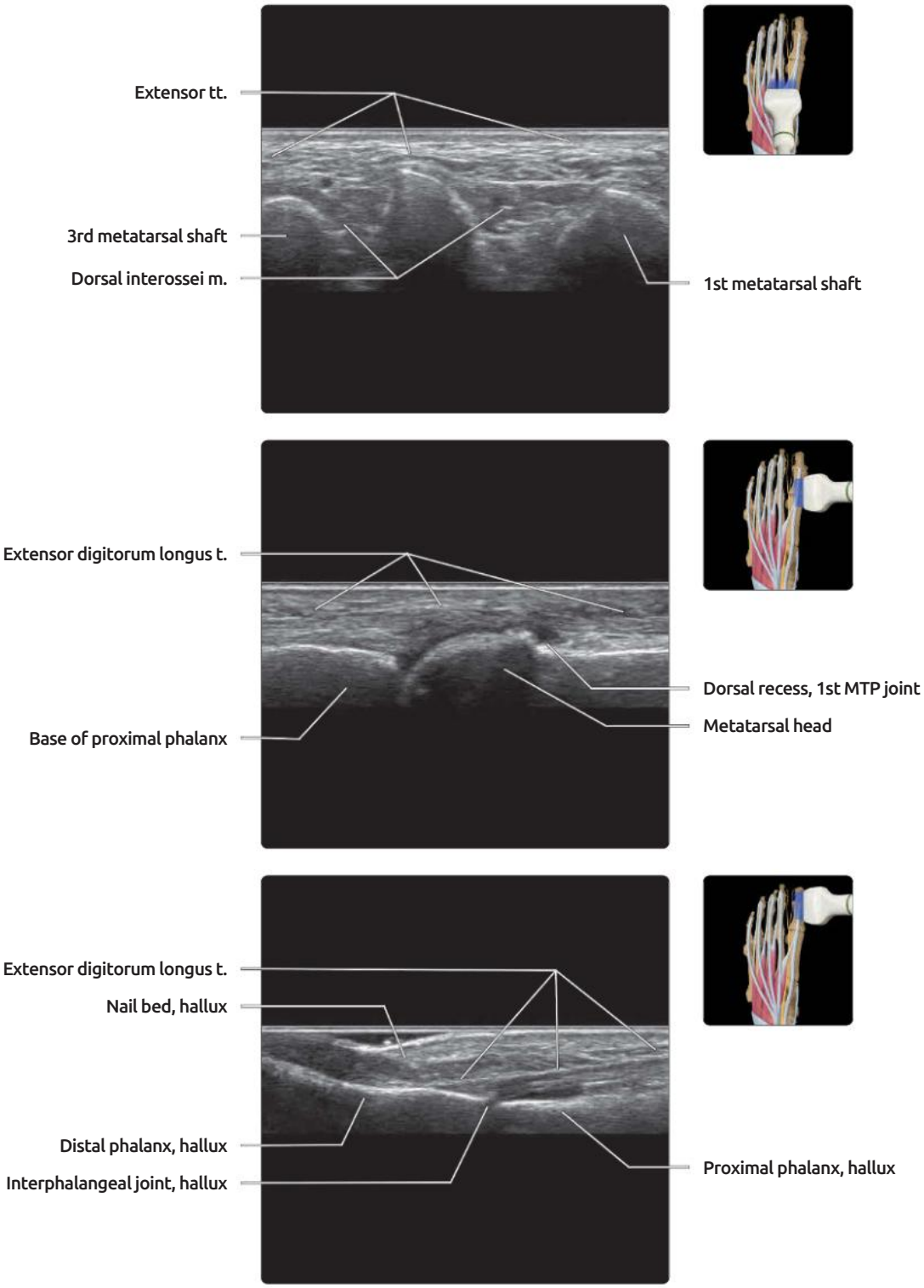

(Top) *Transverse US shows the dorsal surfaces of the medial 3 metatarsal bones. The dorsal interossei lie between the metatarsal shafts and abduct the toes. The plantar interossei adduct the toes.* **(Middle)** *Longitudinal US of the MTP joint hallux shows the extensor digitorum longus tendon overlying the MTP joint capsule.* **(Bottom)** *Longitudinal US of the hallux shows the extensor digitorum tendon insertion into the base of the distal phalanx, just distal to the interphalangeal joint and just proximal to the nail base.*


Transducer
Transducer

PART II
SECTION 1

Approach

Approach to Musculoskeletal Ultrasound 346
Musculoskeletal Ultrasound Artifacts 350
Writing an Ultrasound Report 358

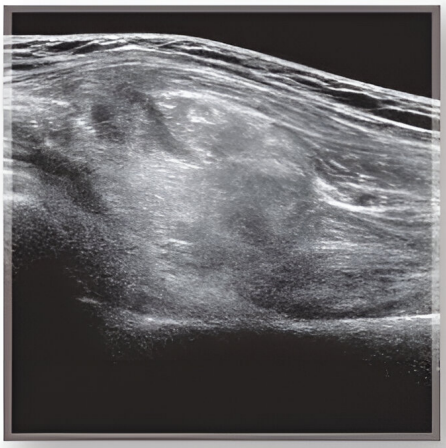

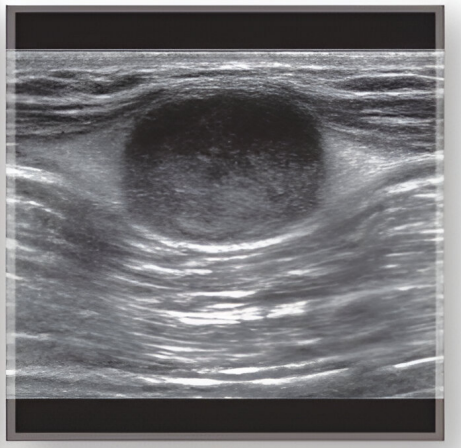

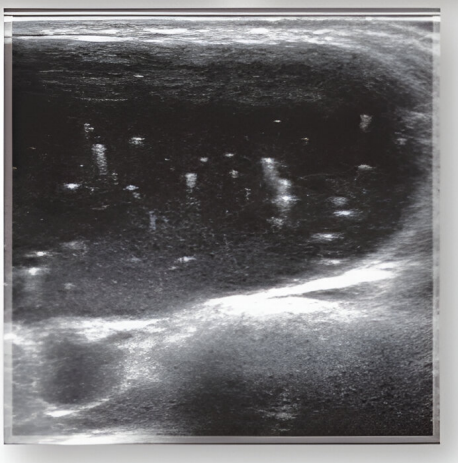

Ultrasound Machine

To perform musculoskeletal US, you first need access to a US machine equipped with a high-resolution transducer. Second, you need to understand, at least, the very basics of US technology. High-resolution transducers range from 10-22 MHz & are ideal for examining the superficial soft tissues. Similar to MR & increasing field strength, the relationship between increasing US transducer frequency & resolution is not linear. Most musculoskeletal US can be performed with a linear transducer in the 10- to 12-MHz range. Moving from 12-17 MHz will improve resolution to a mild degree but usually does not significantly alter diagnostic capability. In other words, access to 1 high-frequency transducer is usually sufficient to begin musculoskeletal US. A disadvantage of high-resolution transducers is limited depth penetration; for deeper areas (gluteal region, proximal thigh) & large masses, a lower frequency transducer, such as a 5-MHz or 7.5-MHz transducer, is needed. The transducer is a delicate (& expensive) piece of equipment & must be handled with care. The transducer contains an interlinked array of piezoelectric crystals. These crystals convert an electrical signal into a US wave & vice versa. The same array of piezoelectric crystals emits & receives the US signal. This is like the transducer shouting out into tissues & then listening for a returning sound or echo. This "shouting & listening" happens many thousands of times a second (pulse repetition frequency). To improve transmission of sound waves, US gel is applied between the skin & the transducer. Sound waves are transmitted from the transducer through the US gel to the skin & deeper tissues. The ability of tissues to transmit sound waves is known as acoustic impedance. At tissue interfaces where there is a large difference in acoustic impedance, most sound waves are reflected back to the transducer, producing a bright echo. At interfaces where there is little or no difference in acoustic impedance, most sound waves are transmitted & not reflected back to the transducer, producing a dark echo. As expected, most sound waves that contact an interface parallel to the transducer face will be reflected back to the transducer. Sound waves impacting an irregular surface will be retracted away from the transducer (refraction). Sound wave attenuation also results from acoustic absorption, which is greater in tissues of higher viscosity.

Getting Started

The best & only real way to learn musculoskeletal US is to get started. In general, the more US examinations you perform, the better you should become. Be conscious of working posture, etc. at the outset. Ensure that both you & the patient are in the most comfortable & effective position to examine the area of interest. Take a brief clinical history from the patient, & palpate any lumps or swelling, if present. This is tremendously helpful when interpreting the subsequent US findings. Warm the US gel using a dedicated US gel warmer, especially if examining the chest or abdomen. Hold the transducer between your thumb & finger. You should have either your little finger or the hypothenar eminence in contact with the patient's skin. This helps to anchor the transducer & ensure sufficient, but not excessive, transducer pressure on the skin. When assessing superficial structures, & especially when assessing color flow in the superficial tissues, you should actively almost lift the transducer from the skin using plenty of intervening US gel to avoid distorting the tissues or effacing the vascularity. Develop a systematic examination procedure for each joint or region that includes all critical anatomic structures. Start your examination at the most symptomatic area & at least include the immediate surrounding area in your examination. For time efficiency, it is not necessary to complete the whole joint examination in every patient. For example, if the patient has medial ankle pain, concentrate on examining the medial & ankle joint proper; there is little to be gained from routinely examining the lateral or posterior ankle structures if there are no symptoms related to these areas. In children, a full examination may not be possible before the child may become restless, so, again, concentrate on the most critical area. Sedation is not usually necessary or beneficial in children.

Machine Setup & Scanning

Understanding proper US machine setup is crucial to conducting a high-quality US. US is a more operator-dependent examination than CT or MR. You should be pedantic about trying to obtain the best possible quality US examination in every patient. There should be no such thing as a "quick US examination"; this is a recipe for missing significant pathology. Optimize image quality before & during scanning. It is helpful to begin by examining the contralateral normal side, as this allows you to both familiarize yourself with normal US anatomy & also set up the machine properly for that body part. The initial setup will often need frequent readjustment throughout the US scan. It is better to take a few high-quality images than many suboptimal images. Orient the image so that the proximal end is on the left side of the image & the distal end is on the right. Make sure there is no shadowing artifact from too little gel at the sides of the image, adjust the depth to the minimum needed to see all structures of interest, adjust the focal position & zone, overall image gain, & the time gain compensation to optimize image quality. During scanning, tissues can be compressed by the transducer to broadly gauge their stiffness. This dynamic capability of US is also helpful when differentiating between fluid & soft tissue in a suspected abscess or hematoma or between synovial proliferation & effusion. The dynamic capability of US is also helpful when assessing tendon tears, tendon subluxation, or shoulder impingement. Color or power Doppler is used routinely in the assessment of soft tissue inflammation, synovitis, & soft tissue masses. The relative sensitivity of color or power Doppler does vary from machine to machine. Color Doppler is flow-direction sensitive, whereas power Doppler is not flow-direction sensitive, though it is considered more sensitive overall to detecting slow flow & flow in small vessels. Low-frequency transducers reveal slow velocity flow better. Reducing the pulse repetition frequency & lowering the wall filter will also improve detection of slow vascular flow.

Recognizing Pathology

Good-quality musculoskeletal US is dependent on a good understanding of musculoskeletal anatomy. You do not want your US technique to be hampered by trying to recall relevant anatomy. It is helpful to familiarize yourself with the normal anatomy on the asymptomatic side before examining the symptomatic side. Be aware, however, of using the normal side as an internal reference of normality. Tendinosis & nerve entrapment, in particular, are often asymptomatic, & US often shows abnormal findings (to a comparable or lesser degree) on the asymptomatic normal side. Therefore, you need a good idea as to what the normal appearances are before proceeding to diagnose tendon or nerve pathology. Another prerequisite is knowledge of the likely pathologies in specific

areas. Most musculoskeletal pathology is site specific. "You only find what you look for; you only look for what you know." Most tissues (tendons, nerves, ligaments) have the same appearance, irrespective of location. Also, tissue-specific pathology has a similar appearance, irrespective of location. For example, tendinosis, tendon tears, or tenosynovitis appear similar irrespective of location. Tendons, nerves, & ligaments are prone to anisotropy. This is the most common artifact you will encounter, & it can often be put to good use. To overcome this artifact, frequent transducer realignment to examine different areas of curved structures is necessary. For example, anterior & posterior aspects of the supraspinatus tendon need to be assessed separately on transverse imaging. For soft tissue masses, evaluate location, extent, internal structure, consistency, vascularity, & relationship to adjacent critical structures, surrounding tissues, & regional nodes.

Clinical Implications

US is the best 1st-line investigation for most soft tissue pathology. An explanation for the patient symptoms can usually be found. Musculoskeletal US is most useful when symptoms are localized to a specific area, e.g., if the patient has point tenderness. US is much less useful when symptoms are not well localized, e.g., pain related to the whole knee or ankle joint. Try to grade every abnormality encountered; there is little benefit in saying that there is supraspinatus tendinosis present. You need to know if this tendinosis is minimal, mild, moderate, or severe. Most superficial soft tissue masses can be accurately diagnosed with US. US diagnosis is formulated not on a basis of 1 or 2 US signs but on the relative strength of multiple recognized US signs interpreted in conjunction with the clinical presentation. When following tendon or nerves along the limb or around a joint, follow each nerve or tendon in turn rather than together. In other words, do not try to follow 2 tendons, such as the peroneal brevis & longus tendons, at the same time. If the US findings are indeterminate, you can either follow them up with repeat US, proceed to an alternative investigation, such as MR, or proceed to US-guided biopsy (or fine-needle aspiration for cytology). Similarly, if a satisfactory explanation for nontumoral symptoms is not found on US, it is usually best to proceed to further investigation, usually MR. There is usually no benefit to be gained from repeating the US examination. MR has particular advantages over US, & in these situations it is usually best to proceed directly to MR. MR is useful for examining areas not accessible to US, e.g., intraarticular or intraosseous abnormalities. MR allows improved perception of large objects (particularly deep, ill-defined lesions & large tumors) & provides a clear anatomic surgical roadmap. MR allows a more reliable quantification of many structures (e.g., synovial volume) & is more sensitive in depicting soft tissue edema, as in myositis. US should ideally precede MR for most soft tissue problems. MR examination, if necessary, can then be tailored to answer only those specific questions not answered by US. For example, there is no need to examine regional lymph nodes if US assessment has already been performed, nor is there a need to give intravenous contrast if tumor vascularity has always been determined by US. If deemed necessary, review additional imaging, such as radiography, CT, or MR, either before, during, or at the end of the US examination. This too, in some instances, can greatly help with US interpretation. At the end of the examination, explain the findings to the patient.

Elastography

Elastography measures tumor stiffness**.** Shear wave elastography (SWE) is less operator dependent than strain wave elastography & allows both qualitative & quantitative measurements. While elastography may serve as a helpful adjunct to standard US examination, it is not specific enough to act as a standalone technique in characterizing soft tissue masses or differentiating benign from malignant masses. Three areas where elastography seems to be most helpful currently is in the assessment of (1) carpal tunnel syndrome (CTS), (2) Achilles tendinopathy, & (3) plantar fasciitis. Median nerve shear wave velocity is increased in CTS & seems to be higher in patients with moderate to severe CTS compared to those with mild CTS or no CTS. Combining median nerve grayscale measurements with SWE may further improve the US diagnostic accuracy for CTS. Tendinopathic tendons have lower SWE values. SWE may increase the sensitivity & diagnostic accuracy of US for detecting early tendinosis when standard US is negative. SWE may also be able to detect early plantar fasciitis in patients with normal plantar fascial thickness. Plantar fasciitis is associated with lower SWE values. SWE may also be more sensitive than grayscale US for monitoring treatment response of plantar fasciitis. Currently, lack of a universally accepted threshold limits the more widespread usage of SWE. This, in part, reflects lack of uniformity in SWE measurements between different US machines as well as lack of standardization of SWE technique. SWE measurement is strongly influenced by anatomic location & transducer angulation.

Contrast-Enhanced Ultrasound

Contrast-enhanced US (CEUS) enables real-time assessment of tumor microvascularity with time-intensity curve analysis. For tumor characterization, while perfusion patterns parameters can be applied together with other discriminators of malignancy, they are not sufficiently accurate to be used as a standalone measure to distinguish benign & malignant soft tissue tumors. CEUS may, however, be helpful in assessing tumor activity & treatment response. Also, CEUS can be helpful in assessing fracture nonunion with higher rates of perfusion seen in patients with subsequent fracture union than those with persistent nonunion. CEUS can also be used to improve identification of adhesive capsulitis, showing increased vascularity in & around the rotator interval. CEUS is also more sensitive to detecting & quantifying synovial hyperemia as well as detecting tendon vascularity in tendinosis.

Other Techniques

Superb microvascular imaging applies an algorithm to differentiate low-velocity blood flow from vascular clutter & motion artefact, enabling the detection of small vessels with greater sensitivity than color or power Doppler US. **Extended field-of-view imaging** provides a panoramic view, which is helpful for measuring large masses, comparing tissue echogenicity in different tissues, & perceiving anatomic relationships. **3D US** acquires volumetric US data, which can be reconstructed along any plane. This has been used to evaluate rotator cuff tears, soft tissues masses, & synovial proliferation. **Fusion imaging** allows real-time US imaging to be superimposed onto preloaded CT or MR imaging & viewed simultaneously on the US screen. Fusion imaging has been used in rheumatoid arthritis, bone biopsy, & sacroiliac joint injection.

(Left) *Schematic shows a US transducer ± external casing. An electrical impulse stimulates the piezoelectric crystal, which emits a sound wave ➡. The returning, weaker sound wave of similar frequency ➡ is detected by the same crystal stimulating an electrical pulse.* **(Right)** *Extended field-of-view US shows an Achilles tendon ➡ following repair. Thickening of the whole tendon ➡ can be readily perceived. Thickening is a typical postoperative finding and can persist for years.*

Ultrasound Transducer

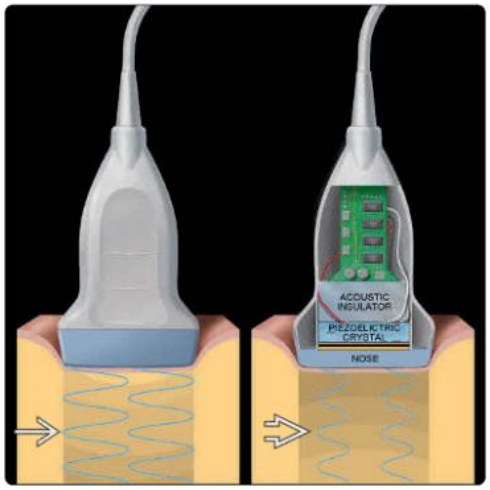

Extended Field-of-View Imaging

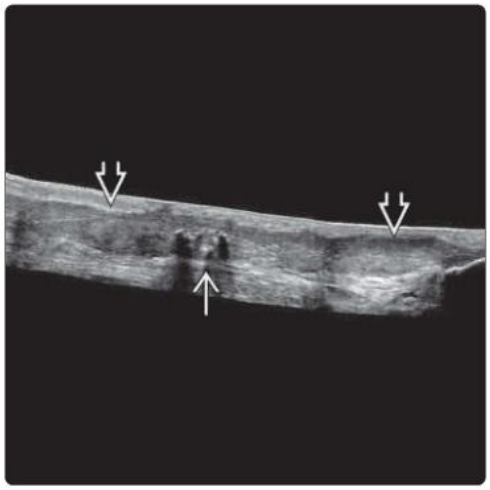

(Left) *Transverse US of the shoulder shows distended subacromial-subdeltoid bursa ➡ with multiple discrete rice bodies ➡. No color flow was evident on color Doppler US compatible with low-grade inflammation.* **(Right)** *Color Doppler US shows a mass initially suspected to be an infected epidermoid cyst ➡. Color Doppler US signal is typically most pronounced in the more superficial components of masses. There is layering of the cyst content ➡. Histology, following excision, revealed an atypical hiradenomatous neoplasm.*

Grayscale Ultrasound

Color Doppler Ultrasound

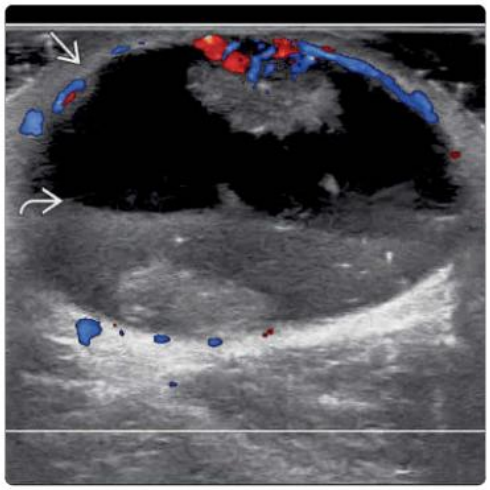

(Left) *Transverse US of 68-year-old man with groin swelling shows a large, wide-necked ➡ pseudoaneurysm of the lateral circumflex femoral artery ➡. There is a large hematoma ➡ surrounding the pseudoaneurysm lumen.* **(Right)** *Spectral Doppler US in the same patient of pseudoaneurysm neck shows the typical to-and-fro pattern ➡ representing bidirectional flow.*

Power Doppler Ultrasound

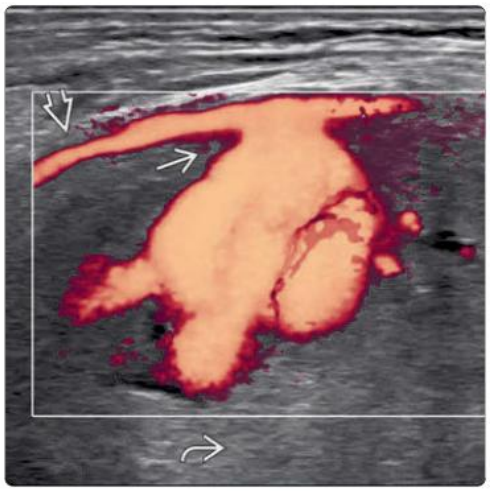

Spectral Doppler Ultrasound

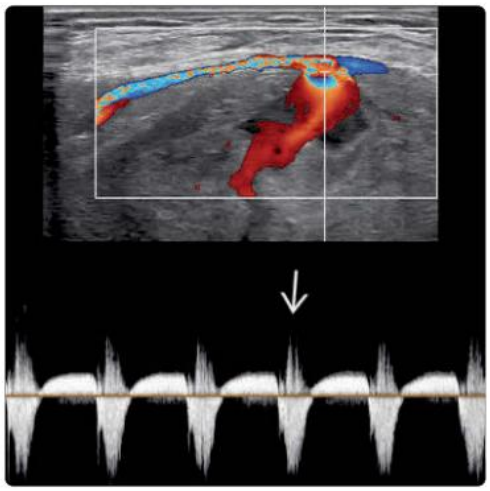

Strain Elastography

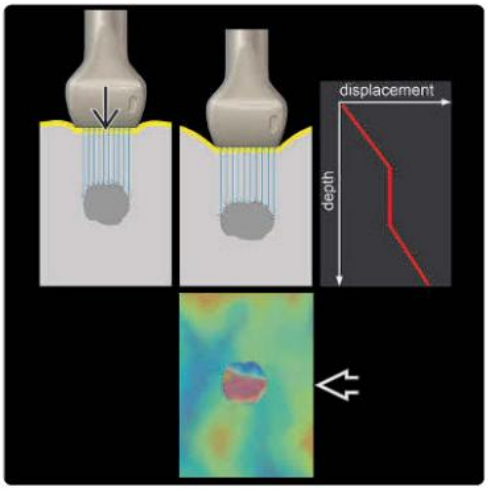

Shear Wave Elastography



(Left) *Strain elastography schematic shows probe pressure ⇨ causing axial tissue displacement. Echoes during compression are used to measure relative displacement (strain) ⇨ and are displayed as color maps without units. Stiff tissue has relatively lower strain.* **(Right)** *Shear wave elastography (SWE) schematic shows a modified probe sending push pulses ⇨ into tissues, inducing shear waves ⇨, which are tracked by diagnostic images. Color maps have quantitative units [m/s or kilopascal (kPa)]. (Courtesy K. Bhatia, MD.)*

Elastography Achilles Tendon

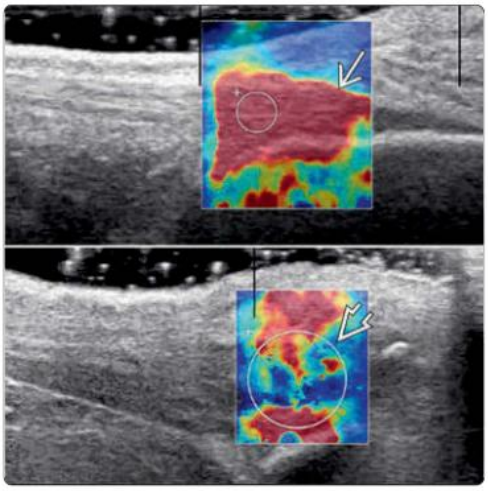

Elastography Soft Tissue Tumor

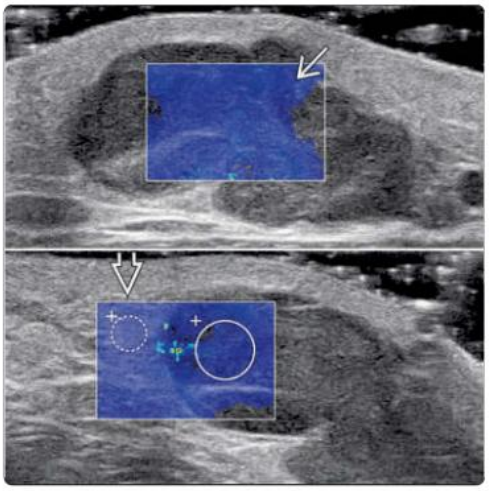

(Left) *Longitudinal SWE US shows a normal Achilles tendon ⇨ with stiff tissues (expressed as red) and elasticity of 497 kPa compared with SWE US of severe Achilles tendinosis ⇨ with softer heterogenous tissues (expressed as blue) and elasticity of 133 kPa.* **(Right)** *SWE shows known sarcoma recurrence with a mean SWE modulus of 19 kPa ⇨. SWE ratio with subcutaneous fat (dashed circle) ⇨ was 1.49. Elastography measurements are not useful at differentiating benign soft tissue masses from sarcoma.*

Grading CEUS

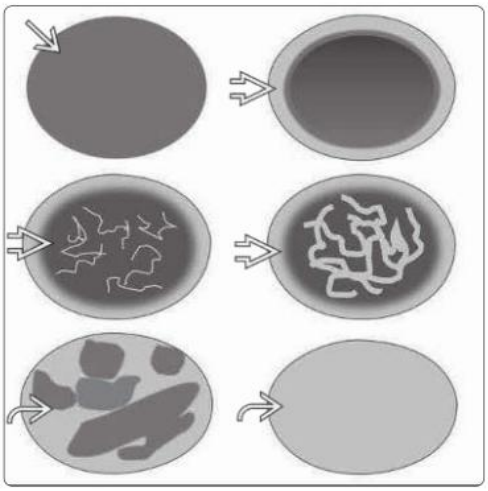

CEUS Time Intensity Curve

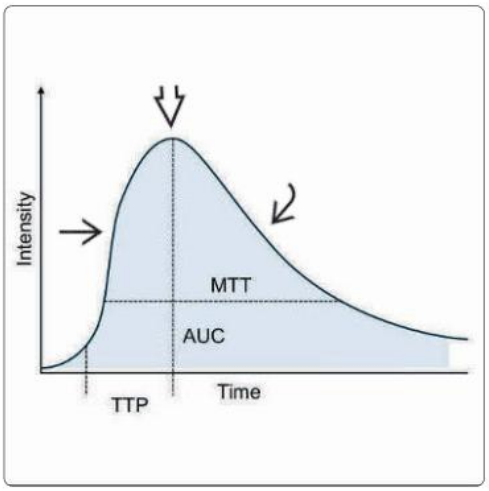

(Left) *Schematic shows CEUS perfusion patterns. No enhancement ⇨ is characteristic of benign tumors. Partial enhancement ⇨ is nondiscriminatory, while more uniform enhancement ⇨ is more common in malignant tumors. CEUS patterns are not sufficiently specific to diagnosis malignancy* **(Right)** *Typical CEUS time-intensity curve shows rapid wash-in ⇨, peak ⇨, and rapid washout ⇨. The usual parameters measured are time to peak (TTP), mean transit time (MTT), and area under the curve (AUC).*

Introduction

US images are generated by ultrasonic waves being transmitted into and reflected back from the tissue under interrogation. These US waves, produced by the transducer, may be absorbed, refracted, or reflected back to the transducer. The time between the pulse being transmitted and it being received is directly proportional to the depth of the signal shown on the US monitor. Artifacts are quite common in musculoskeletal US imaging and can lead to erroneous interpretation or, alternatively, may enhance interpretation.

Artifact

A US artifact is a feature seen on an image that is not representative of the tissue being scanned. These may be either technology or technique related and can take 1 of 4 forms.

- Feature seen on image does not exist
- Feature that should be seen on image is missing
- Feature is misplaced (misregistered) on image
- Feature is of incorrect brightness, shape, or size

Technological Aspects

US technology works on some basic assumptions. These assumptions are not always correct and can lead to artifact formation. Not all US artifacts will be encountered in musculoskeletal US.

- Speed of sound propagation is same for all tissues (1,540 m/sec)
- US beam travels in straight line
- Attenuation of sound is uniform
- All echoes detected by transducer have primarily arisen from transducer
- Time taken for echo to return to transducer is directly related to distance of reflecting interface from transducer

Artifacts Due to Beam Characteristics

Anisotropy

Anisotropy is one of the most common artifacts encountered in musculoskeletal US. Anisotropy refers to a property being directionally dependent, as opposed to isotropy, which implies identical properties in all directions. Anisotropy can result in a structure appearing hypoechoic if the US beam is not directly perpendicular to the structure. It is seen particularly in tendons, ligaments, nerves, and, to a lesser degree, muscle due to their oblique course and parallel reflective surfaces. Anisotropy can occur when the US beam is angled as little as 5° off perpendicular. It can mimic pathology, such as tendinosis or tendon tear, or may make a biopsy needle less conspicuous. It is particularly noticeable when the structure being imaged is curving, e.g., the ankle tendons curving around the malleoli or the supraspinatus tendon fibers curving to their insertional area. Anisotropy is eliminated by angulating (toggling) the transducer head so that the US beam is aligned perpendicular to the area of interest. It is important to evaluate only the part of the structure that is perpendicular to the US beam and to not be tempted to diagnose pathology in other adjacent parts. The anisotropic effect can also be used to more clearly demarcate a structure of interest, such as the median nerve in the carpal tunnel or the ankle ligaments.

Off-Axis Lobe Artifact

Off-axis lobe artifact includes side lobe and grating lobe artifacts. Side lobes are multiple beams of low amplitude that project radially from the primary beam axis and are mainly seen with linear transducers. Grating lobes are additional off-axis beams that are stronger than side lobes. Both side and grating lobes are weaker than the primary lobe and, as such, do not normally give echoes of sufficient strength to be displayed. However, if a side lobe or a grating lobe encounters a more highly reflective structure outside the primary beam, their echoes may be incorrectly displayed on the image along the path of the main beam. Off-axis lobe artifacts in musculoskeletal imaging are usually seen as spurious echoes within an expected anechoic structure, such as a cyst or an effusion. Side lobe artifacts will be seen at the edge of Baker cysts. Much less commonly, off-axis lobe artifacts may give rise to multiple needle paths during US-guided intervention.

Beam-Width Artifact

This artifact is due to incorrect focal zone positioning too superficial to the area of interest. A strong reflector located within the widened beam beyond the focal zone will generate detectable echoes. These echoes are assumed to have originated from the narrow primary beam and are displayed on the primary beam image even though they have not arisen with the primary beam area. Beam-width artifact is typically seen either as spurious echoes displayed at the edges of an anechoic structure or as reduced contrast at the borders of a lesion. Beam-width artifact can be improved by optimizing the focal zone. Off-axis lobe artifacts will not improve with optimization of the focal zone.

Slice-Thickness Artifact

Slice-thickness artifact is similar to beam-width artifact but instead of being predominantly in a mediolateral direction, it occurs due to an aberration in the anteroposterior direction. Slice-thickness artifact occurs due to the thickness of the beam, which is 90° to scan plane and equates to the thickness of the piezoelectric element in the transducer head. The transducer will receive echoes from in front of and behind the assumed plane of origin, which will be included in the displayed image. Increasing the thickness of the transducer head will increase the propensity to develop slice-thickness artifact.

Artifacts Due to Multiple Echoes

Ring-Down Artifact

Ring-down (resonance) artifact is similar in its appearance to comet-tail artifact but is generated by a different mechanism. When a transmitted US beam passes through small gas locules or fluid bubbles, the US energy leads to vibration of these bubbles, which emit and return sound waves back to the transducer. The effect is a larger artifact than expected.

Reverberation Artifact

Multiple reflections (reverberations) can occur between any 2 strong reflectors parallel to each other or between the transducer and a strong parallel reflector. As a result of these strong reflectors, echoes are reflected back and forth repeatedly. This leads to spuriously reflected echoes being displayed beneath the real reflector at intervals equal to either the distance between the transducer and real reflector or the distance between the 2 strong reflectors. Each subsequent reflection is weaker than the previous one due to sound beam attenuation. Reverberation artifact in musculoskeletal imaging is most commonly seen when the US

beam encounters a strongly reflecting surface, e.g., a biopsy needle or a metal prosthesis. An advantage of seeing this artifact is that it ensures your transducer is at a right angle to the structure being imaged. Comet-tail artifacts are a particular type of reverberation artifact usually seen in echo-free regions and are composed of a dense tapering trail of echoes behind a highly reflective small structure, such as calcification, crystal aggregate in gout, or colloid aggregate in a ganglion cyst.

Mirror Image Artifact

Mirror image artifact occurs when an object is located directly in front of a highly reflective smooth surface. The US beam is totally reflected by the strong reflector back toward the object. When the beam hits the object, part of the energy is reflected back to the strong reflector, which then redirects this echo back toward the transducer. True and false images are created equidistant from but on opposite sides of the strong reflector. In musculoskeletal imaging, a mirror image artifact most commonly manifests as an extraosseous structure being mirrored within bone. The mirror image is inverted and, rather than being an exact copy, is often a distorted view of the real image.

Artifact Due to Velocity Errors

Propagation Speed Artifact

The speed of sound varies within different tissues, though US technology assumes that all tissues have a constant speed of 1,540 m/sec. If the speed of sound through tissues is > 1,540 m/sec, the returning echo will return faster to the transducer, leading to the structure being displayed more superficially on the image than expected. Conversely, if the average speed through the tissues is < 1,540 m/sec, the structure will appear deeper than it is in reality. Sound travels ~ 10% slower through fat, which has a sound transmission speed of 1,440 m/sec as opposed to lean tissue (1,585 m/sec). Propagation speed artifact can lead to a needle appearing to spuriously bend as it passes between fat and muscle tissue. It can also lead to spurious irregularity of deeper structures.

Refraction Artifact

Refraction of the US beam at a boundary between 2 media of different acoustic impedance will result in image misregistration. In refraction artifact, a nonperpendicular incident US beam will refract and change direction at a boundary between 2 materials of different acoustic impedance. Since US display technology assumes that the sound beam travels in a straight line, it will misplace any returning refracted echoes to the side of the true object location. Refraction artifact may result in a structure appearing longer than expected or a misplaced duplication of a structure ("ghost image").

Defocusing Artifact (Edge Shadowing Artifact)

In defocusing artifact (edge shadowing artifact), refraction produces shadowing at the edges of a relatively large, curved structure. Refraction occurs at the edge of the structure due to the curved edge and also differences in acoustic impedance between the 2 tissue types involved. The US beam at the edge of a structure, such as a cyst or soft tissue mass, is deviated from its original path. This is commonly seen in musculoskeletal imaging. Edge shadowing artifact is also the reason for shadowing seen commonly in full-thickness Achilles tendon tear.

Artifact Due to Attenuation Error

Acoustic Shadowing Artifact (Posterior Acoustic Shadowing)

This is the most commonly encountered artifact in musculoskeletal US and is the reason US, e.g., cannot look deep into joints. Acoustic shadowing artifact is caused by severe attenuation of the US beam at an interface, either by reflection, absorption, or, less commonly, refraction, resulting in reduced sound being transmitted beyond that interface. This leads to an area of hypoechogenicity behind a strongly reflecting interface or strongly attenuating tissue. In musculoskeletal imaging, this is seen as shadowing posterior to calcification, bone, foreign bodies, or dense fibrous tissue. The main implication is that the tissues behind that structure are not visible on US. This can cause problems, e.g., in examination of the knee, it may be difficult to see whether or not a large osseous structure is attached to the bone. It is also an advantageous sign, e.g., acoustic shadowing behind noncalcified tissue would make it very likely that this tissue is composed of dense fibrous tissue. Acoustic shadowing, in the absence of calcification, is a good clue to the presence of fibrosis. Objects with a small radius or a rough surface are more inclined to produce a clean posterior shadow, whereas objects with a large radius or smooth surface are more inclined to produce a "dirty" shadow as a result of reverberation echoes superimposed on the acoustic shadow.

Acoustic-Enhancement Artifact (Increased Through Transmission)

This is caused by low-attenuating structures, such as fluid, resulting in no weakening of the US beam as it passes through these tissues relative to adjacent tissues. This leads to an area of high-amplitude echoes behind the area of low-attenuating tissue. This artifact is seen when examining fluid, myxoid tissue, or associated low-attenuating tissue structures, such as ganglion cysts, nerve sheath tumors, or giant cell tumor of tendon sheath. Tissues deep to the low-attenuation structure appear hyperechoic.

Artifact Due to Improper Machine Setting

Range Ambiguity Artifact

US technology assumes that each pulse of echoes is received by the transmitter before the next pulse is emitted. If returning 1st pulse echoes arrive after the 2nd pulse has been transmitted, returning 1st pulse echoes are interpreted incorrectly as having originated from the 2nd pulse and will be incorrectly placed nearer to the transducer. Range ambiguity artifact is not commonly seen now, as the US machine automatically reduces pulse repetition frequency during imaging of deeper structures.

Equipment-Generated Artifact

Incorrect use of equipment controls, such as gain or time-gain compensation, can result in the visualized echoes being either too bright or too dark. To avoid these artifacts, time-gain compensation should be properly set up and adjusted frequently during the course of the examination.

Artifact Seen During Doppler Imaging

Transducer Pressure

Too much transducer pressure may obliterate vascular flow, particularly in soft superficial vascular structures. To avoid this, use a large amount of US gel and actively lift the transducer off the skin when assessing tissue vascularity.

Noise Artifact
Noise is caused by increased color or power Doppler settings. Noise can be recognized as small, spurious, inconsistent color dots. Color gain settings should be adjusted to minimize noise. To achieve maximum color sensitivity, increase color gain until noise pixels are clearly seen in the Doppler box, then slowly decrease gain until nearly all of the noise has disappeared.

Aliasing Artifact
Aliasing artifact occurs when the velocity range exceeds the scale available to display and is only seen with color and spectral Doppler imaging. Aliasing is not seen with power Doppler, as it does not provide flow-directional information. The sample rate on color or pulsed Doppler is equal to the pulse repetition frequency, which limits maximum velocity scale. The Nyquist limit is the upper limit of Doppler shift that can be detected accurately and is equal to 1/2 the pulse repetition frequency. If Doppler shift signal is higher than the Nyquist limit, aliasing artifact occurs with inaccurate display of color or spectral Doppler velocity. In color Doppler, the display wraps around the scale and overwrites existing data, while in spectral Doppler, velocity peak is displayed below the baseline. Aliasing can be overcome by increasing the pulse repetition frequency, though this limits assessment of low velocities.

Range Ambiguity Artifact
As expected, range ambiguity artifact can occur in Doppler imaging with increasing pulse repetition frequency used to overcome aliasing artifact. This should be identified in order to avoid detection of frequency shifts deeper than the target object.

Directional Ambiguity/Indeterminate Flow Direction Artifact
This artifact leads to the spectral waveform being displayed with nearly equal amplitude above and below spectral analysis baseline in a mirror image pattern. It is caused by the US beam intercepting the vessel at a 90° angle, particularly for small vessels moving in and out of the imaging plane. True bidirectional flow is a rare occurrence and is only seen in the neck of a pseudoaneurysm or when there is reversed diastolic flow near a high-resistance vascular stenosis. True bidirectional flow is never simultaneously symmetric above and below baseline and may be seen to vary across the cardiac cycle.

Improper Doppler Angle With No-Flow Artifact
Since Doppler imaging is angle dependent, the angle formed between the interrogating sound beam and vascular flow should be optimized. The angle can be changed by electronic steering. When the angle between the US beam and the vessel being studied approaches 90°, no Doppler shift is detected, and color may not present even though flow is present. The color box should be steered to make the insonation angle to flow closer to 0° or 180° and not close to 90°. This Doppler angle effect artifact is seen in color, power, and spectral Doppler imaging. The ideal Doppler imaging angle is either 0° or 180° but is generally not anatomically achievable when imaging vasculature. A Doppler angle of 60° has traditionally been accepted as a standard.

Blooming Artifact ("Color Bleed")
This artifact is usually caused by high Doppler gain settings, leading to color signal extending beyond the true grayscale vessel margin. It leads to color display outside a vessel wall, making vessels appear larger, and also potentially masking luminal detail, such as the presence of thrombus. Decreasing color Doppler gain will minimize blooming artifact, though it will also reduce sensitivity to flow detection in small vessels. This can lead to errors in semiquantitatively estimating the amount of synovium filled with vascularity.

Flash Artifact
Movement of either the patient or the transducer during Doppler imaging gives rise to random flashes of color covering a large area of the image. These flashes, which resemble fireworks, are easily distinguishable from true intravascular flow and are not repeatable in the same place. Power Doppler is most susceptible to this artifact. Setting the wall filter too high will also produce flash artifact. Superb microvascular imaging (SMI) uses a multidimensional filter to identify and remove tissue motion, enabling preservation of slow-flow blood signal. SMI can lead to spurious flow signal at the surface of bone, cartilage, and tendon.

Mirror (or Ghost) Image Artifact
This is caused by the same mechanism as that seen with grayscale imaging and is a feature of color, spectral, or power Doppler imaging. It most commonly occurs adjacent to highly reflective surfaces, such as the lung, when, e.g., imaging the supraclavicular region where one may see duplication of the subclavian artery or vein with the false images being displayed deeper than the real image.

Pseudoflow Artifact
The presence of fluid flow in nonvascular cystic collections can mimic real blood flow in color or power Doppler imaging. However, no arterial or venous spectral waveform will be seen if this apparent fluid flow is subjected to spectral Doppler analysis.

Twinkling Artifact
Twinkling artifact can be seen behind any strongly reflecting surface, such as calcification, bone, or foreign body. It is seen as a mosaic of rapidly changing colors, mimicking turbulent flow, and presents deep to the strongly reflecting surface, such as a calcified nodule, on both color and power Doppler. It is most likely caused by narrow bandwidth noise induced by "phase jitter" in the Doppler circuitry of the US system.

Edge Artifact
Occurs at the margin of a strong, smooth reflector (such as a calcified mass or cortical bone), resulting in persistent color along the rim of a strong reflector. Spectral analysis in this case will show no vascular flow pattern. Edge artifact is seen more commonly with power Doppler than color Doppler imaging.

Motion Artifact
Even a small amount of motion will give rise to noise on color or power Doppler imaging. Noise appears as random dot-like flashes on color or power Doppler imaging. It is caused by low-frequency Doppler shifts and can be minimized by high-pass wall filters, though these filters will reduce sensitivity to detect slow-flowing blood. Very slow-flowing blood is best detected on grayscale imaging alone when moving red cell aggregates will be seen as slow-moving intravascular echoes.

Selected References

1. Dewilde M et al: A Case of a mirror image artifact in the forearm. J Belg Soc Radiol. 108(1):68, 2024
2. Shokoohi H et al: Ultrasound physics. Emerg Med Clin North Am. 42(4):711-30, 2024

Ultrasound Beam

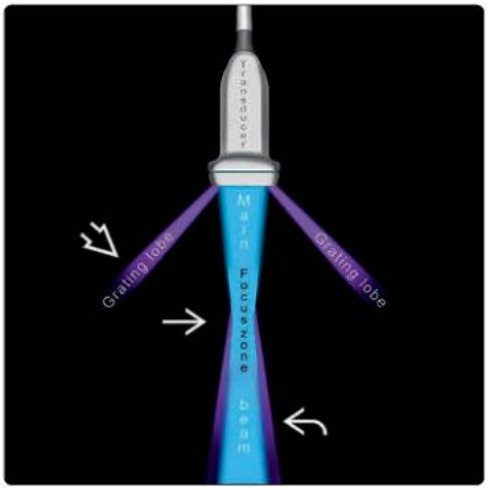

Anisotropy

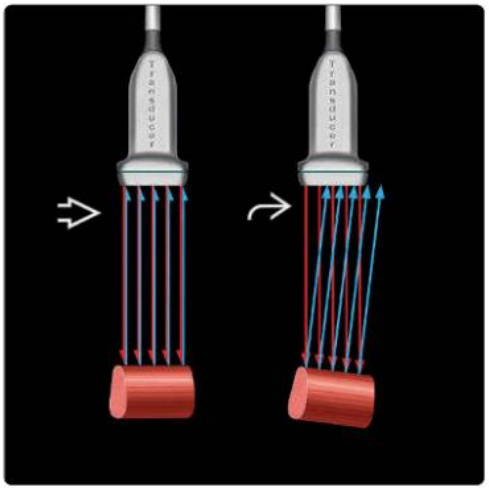

(Left) *Schematic of a US beam shows the primary (main) beam narrowing at the focal zone ⇨ and then diverging. Grating lobes ⇨ and side lobes ⇨ are both off-axis lobes.* **(Right)** *Schematic shows anisotropy effect. If the structure scanned is parallel to the transducer, all of the reflected echoes ⇨ can be detected. When the structure is not parallel to the transducer, only some or none of the reflected echoes ⇨ will be detected, leading to the structure becoming hypoechoic.*

Anisotropy

Anisotropy

(Left) *Longitudinal US shows moderate hypoechogenicity ⇨ of the distal fibers of the supraspinatus tendon, which could simulate a tendon tear.* **(Right)** *Longitudinal US of the same tendon following angulation of the transducer so that the fibers lie more parallel to the transducer head shows reduction in hypoechoic anisotropic effect ⇨. No tear is present.*

Beam-Width Artifact

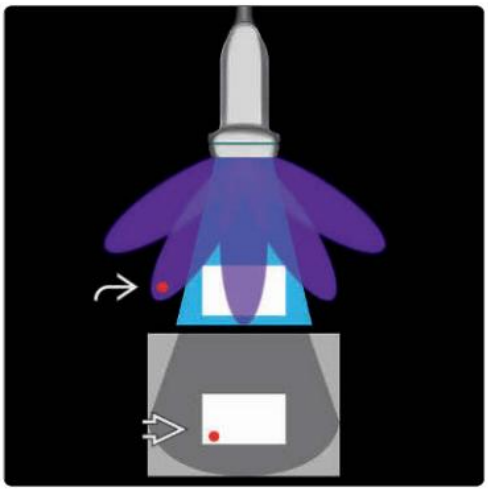

Off-Axis Lobe Artifact

(Left) *Schematic shows beam-width artifact. The purple beams represent multiple side lobes, which encounter an object (red dot) ⇨. The display, assuming that all returning echoes came from the main beam, will misplace and duplicate the structure ⇨ as shown.* **(Right)** *Transverse US shows off-axis lobe artifact resulting in spurious echoes ⇨ from subcutaneous fat appearing in knee joint effusion. This is commonly seen at the edges of cystic structures and can simulate fluid debris.*

Beam-Width Artifact

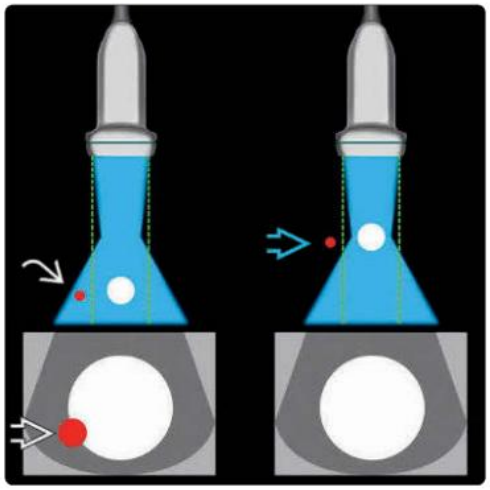

Beam-Width Artifact

(Left) *Schematic shows beam-width artifact. The blue beams represent multiple side lobes, which encounter an object (red dot). The display, assuming all returning echoes came from the main beam (dotted lines), will misplace the structure. This artifact is corrected by correct positioning of focal zone.* **(Right)** *Transverse US shows blurring of the lateral margin of a lipoma and adjacent tissue due to either beam-width or off-axis lobe artifact. Optimization of the focal zone will help reduce the former, but not the latter, artifact.*

Beam-Width Artifact

Beam-Width Artifact

(Left) *Transverse US of a radial tunnel shows a blurred posterior interosseous nerve and supinator muscle due to a US beam focus being positioned too superficial to the area of interest.* **(Right)** *Transverse US of the same area with the correct positioning of a US beam focus shows a more sharply delineated posterior interosseous nerve and supinator muscle.*

Ring-Down Artifact

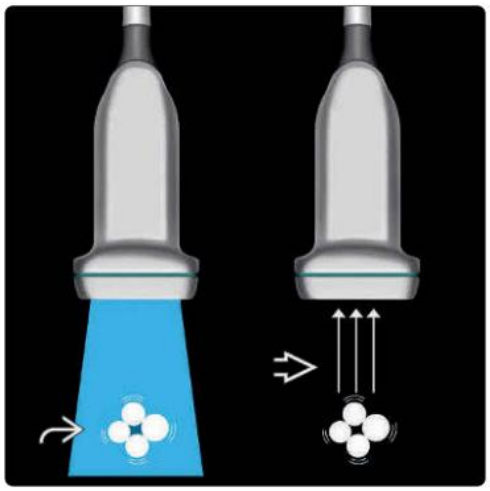

Ring-Down Artifact

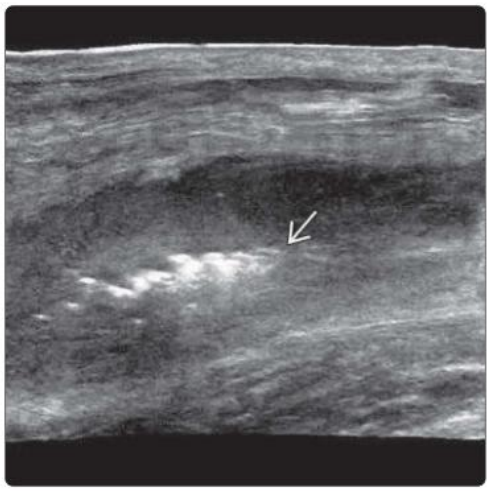

(Left) *Schematic shows a ring-down artifact. If the main beam encounters air bubbles, it can induce vibrations in these bubbles, causing a continuous source of sound energy transmitted back to the transducer. Therefore, the artifact appears larger than expected.* **(Right)** *Longitudinal US shows increased echogenicity of gas bubbles due to ring-down artifact within hypoechoic granulation tissues as a result of low-grade soft tissue infection.*

Schematic of Reverberation Artifact

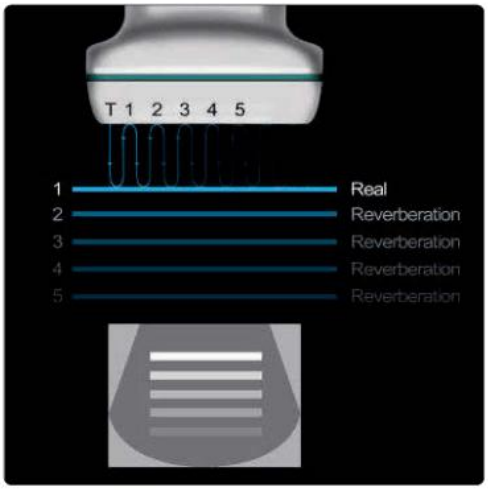

Reverberation Artifact

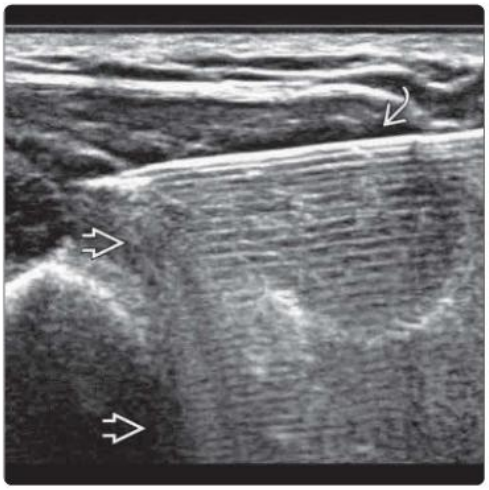

(Left) *Schematic of reverberation artifact shows repeated reflections from a strongly reflecting interface causing reverberations to appear at intervals below the interface.* **(Right)** *Longitudinal US shows reverberations ⇨ deep to the strongly reflecting biopsy needle ⇨. This artifact occurs from reverberation between the outer coaxial needle and the inner biopsy needle.*

Reverberation Artifact

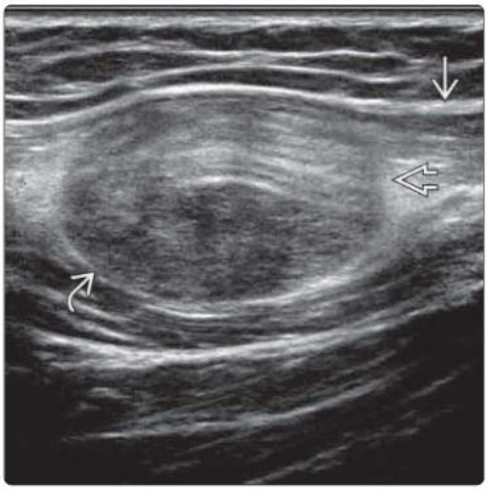

Comet-Tail Artifact

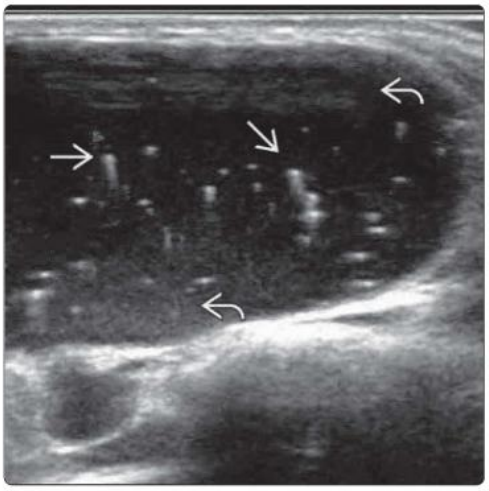

(Left) *Longitudinal US shows linear echoes ⇨ within a nerve sheath tumor ⇨ due to reverberations from an overlying strongly reflective investing fascia ⇨.* **(Right)** *Transverse US of a ganglion cyst shows comet-tail artifacts ⇨ due to colloid aggregates within the mucopolysaccharide fluid content. There is also some slice-thickness artifact simulating echogenic fluid content in the superficial and deep ⇨ parts of the cyst.*

Propagation Speed Artifact

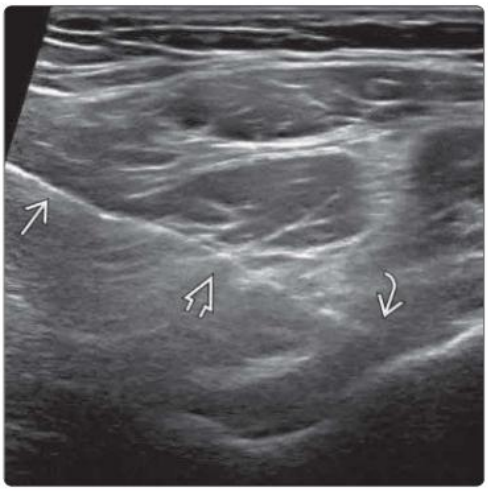

Propagation Speed Artifact

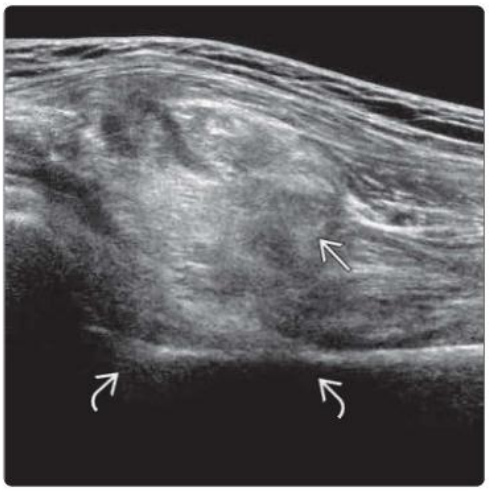

(Left) *Longitudinal US shows apparent bending of a hip aspiration needle as it passes from mainly fatty tissue to mainly muscle tissue. Since sound travels slower in fat than muscle, the needle part passing mainly through fat ⇨ appears deeper than that passing mainly though muscle ⇨. Needle tip in the hip joint ⇨ is shown.* **(Right)** *Longitudinal US of the thigh shows ill definition of proximal femur cortex ⇨ due to propagation speed artifact from intramuscular soft tissue sarcoma ⇨ on anterolateral aspect of the thigh.*

(Left) *Longitudinal US shows inverted, distorted, and incompletely portrayed mirror image artifact ⇨ of a juxtacortical giant cell tumor ⇨ due to strong cortical bone reflection.* **(Right)** *Schematic shows mirror image artifact. Reflections from a strong reflector encounter another object and are first reflected back to the highly reflective surface before returning to the transducer. This produces an inverted mirror image of the object ⇨.*

Mirror Image Artifact

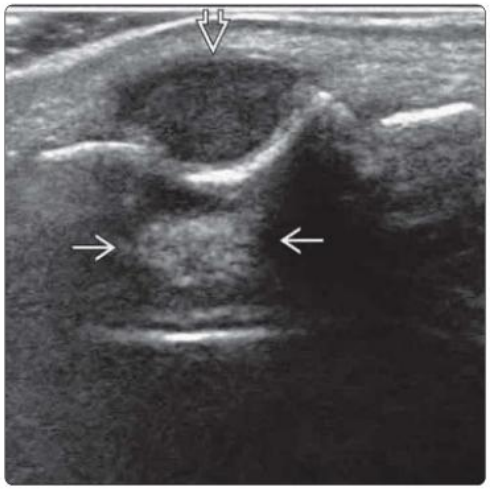

Mirror Image Artifact

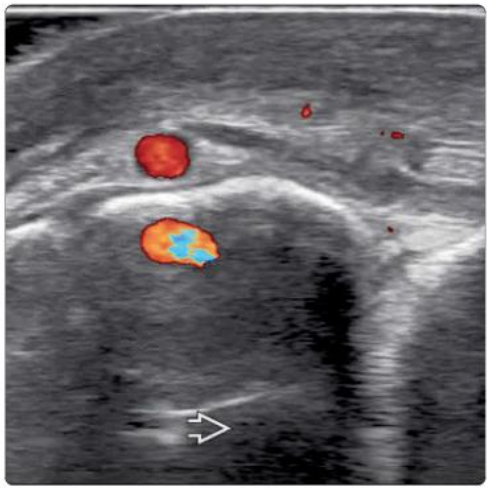

(Left) *Longitudinal US shows characteristic acoustic enhancement ⇨ posterior to a nerve sheath tumor ⇨ in the thigh.* **(Right)** *Longitudinal US of the thigh shows acoustic shadowing ⇨ posterior to a small area of subcutaneous calcification ⇨.*

Acoustic Enhancement Artifact

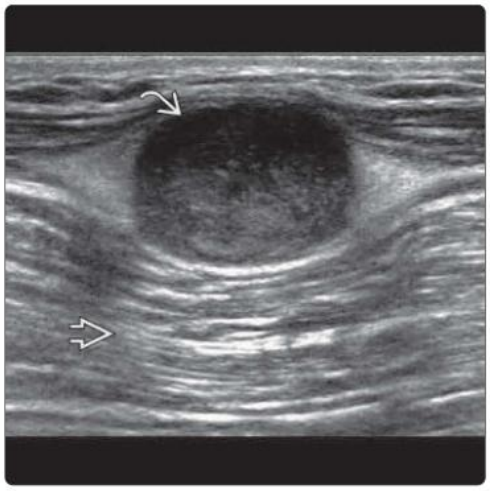

Acoustic Shadowing Artifact

(Left) *Transverse US of the gluteal region shows dense acoustic shadowing ⇨ deep to a subcutaneous calcified granuloma ⇨.* **(Right)** *Transverse US shows range ambiguity artifact ⇨ with alternating echogenic bands at the sides of a cystic structure due to soft tissue echoes returning from deeper tissues. Increased through transmission ⇨ mainly in the central part of the cyst is seen.*

Acoustic Shadowing Artifact

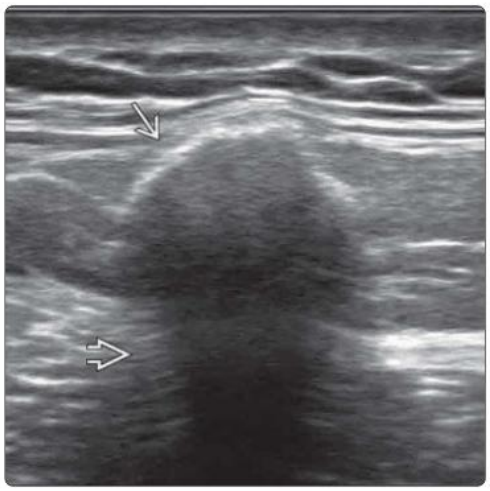

Range Ambiguity Artifact

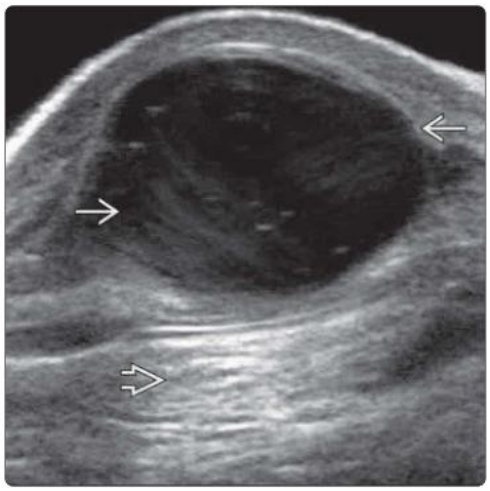

Transducer Pressure Artifact

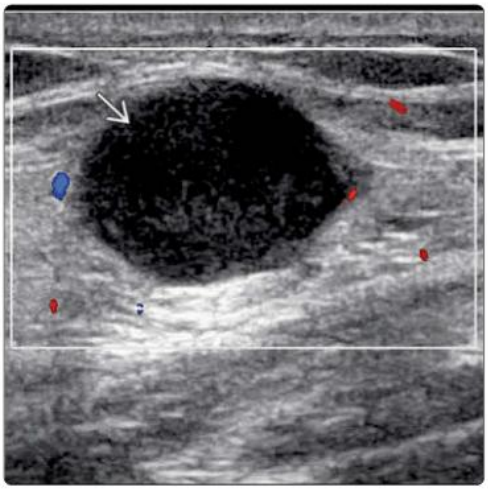

Transducer Pressure Artifact

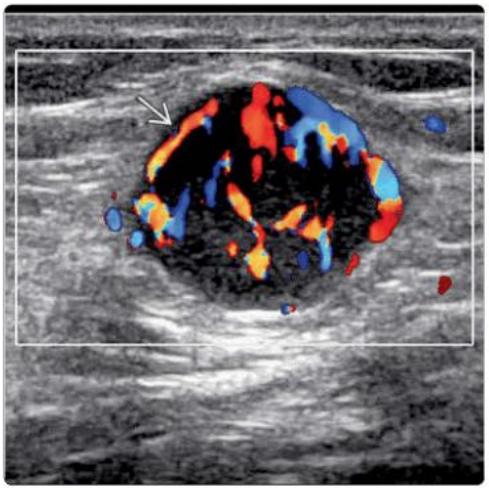

(Left) *Longitudinal color Doppler US shows a subcutaneous nerve sheath tumor with moderate transducer pressure. No intratumoral hyperemia is evident* ➡. **(Right)** *Longitudinal US of the same tumor with minimal transducer pressure now shows moderate intratumoral hyperemia* ➡. *Transducer pressure should be kept to a minimum, especially when assessing vascularity of superficial structures.*

Blooming Artifact

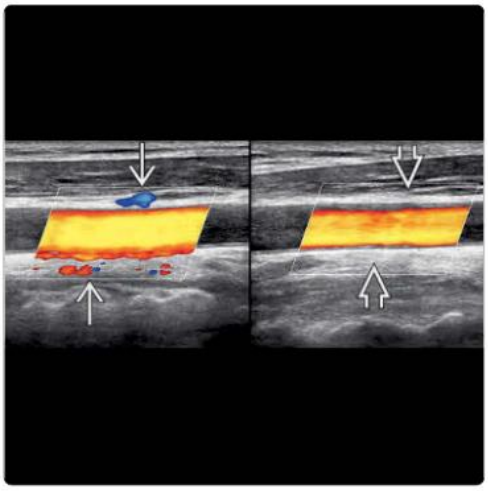

Directional Ambiguity Artifact

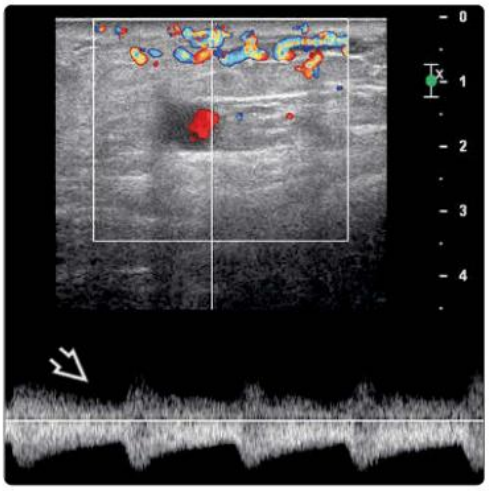

(Left) *Longitudinal color Doppler US shows blooming artifact* ➡ *("color bleed"). After lowering the color Doppler gain settings, the blooming artifact is no longer present* ➡. **(Right)** *Longitudinal color Doppler spectral US of a venous vascular malformation shows directional ambiguity artifact* ➡ *in which the waveform is displayed with nearly equal amplitude above and below the baseline in a mirror image pattern.*

Noise Artifact

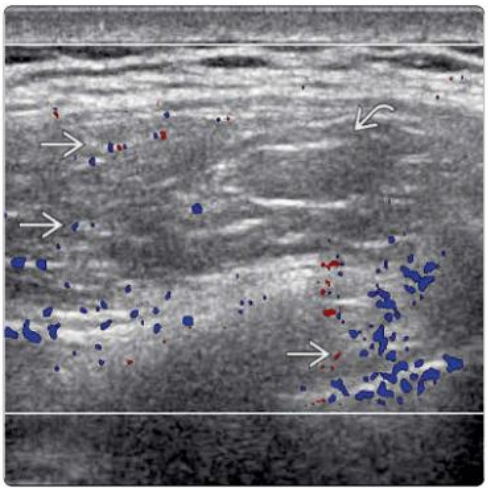

Doppler Edge Artifact

(Left) *Transverse color Doppler US of a subcutaneous lipoma* ➡ *shows a noise artifact* ➡ *as a result of a color Doppler gain setting that was too high. When the gain was turned down, no increased "vascularity" was present.* **(Right)** *Transverse color Doppler US shows Doppler edge artifact with persistent color* ➡ *signal around the rim of the strong reflector* ➡ *(calcified structure).*

Key General Principles

The operator dependency of US means that a clear US report is more relevant for conveying information than other imaging studies.

Write the report as soon as possible after finishing the US examination.

Address & answer the clinical question.

Make the report brief, clear, precise, & pertinent.
- The longer the report, the more likely it will not be read in full
- Report length is considered inversely proportional to confidence of report writer

Minimize reporting of largely irrelevant pathology, such as "small humeral head cortical defects."

Report clinically relevant, but not clinically irrelevant, negative findings.
- Rather than reporting exhaustive list of negative findings, best to say something similar to "otherwise unremarkable appearances"

Avoid ambiguous terminology, such as "prominent," "pronounced," or "significant."
- Also avoid terms like "gross," "obvious," or "significant," e.g., "no obvious mass is seen"
- Use more precise qualitative descriptors, such as "mild," "moderate," "severe" or "small," "medium," "large"
- Avoid ambiguous statements, such as "There is no mass noted" or "There is no mass seen," as this suggests that there may be a mass present, but it was simply not seen

Minimize use of US descriptors, such as describing a "hypoechoic mass with posterior enhancement though no flow on color Doppler imaging."
- Decide on likely pathology & then describe in pathologic, rather than sonographic, terms

If certain about the US findings, use definite language in the report, e.g.,
- "There is medium-sized subcutaneous lipoma present"
- "There is small nerve sheath tumor located eccentric to radial nerve in..."
- "There is medium-sized (mm mediolateral x mm anteroposterior) avulsive tear of anterior fibers supraspinatus tendon"

If uncertain about the type of tissue present, use "-like" or "-type" classifiers, such as
- "There is small lipomatous-type mass present in..."
- "There is large irregular area of fibrotic-type tissue present in..."

If uncertain about the nature of the mass, use terminology, such as
- "There is a nodal-type mass present"
- "The appearances are nonspecific, although this most likely represents..."
- & give 3 most likely diagnoses in order of likelihood

If it is possible to completely confirm or exclude a pathology based on US findings, use definite language in report & include the term "present."
- e.g., "There is no mass present"

If it is not possible to completely exclude a pathology based on US findings, use the term "evident" rather than "present."
- e.g., "There is no myositis evident"

Minimize use of abbreviations & only use after abbreviation has first been spelled out in the report.
- e.g., "There is severe partial tear of anterior talofibular ligament (ATFL); the torn ATFL fibers have retracted"

Grading Severity of Disease

Every abnormality mentioned in report should be graded.
- If qualitative, use "minimal," "mild," "moderate," "severe" or use "minimal to mild," "moderate to severe"
- If quantitative, use "small," "medium sized," "large" or use "small to medium sized," "medium sized to large"

There is little benefit in stating, for example, that "there is supraspinatus tendinosis present," as that can mean anything from a minuscule degree to a severe degree of tendinosis.

Measurements

Do not use "mm" for one measurement & "cm" for another measurement in the same report.

Insert a table, whenever possible, if multiple measurements are being provided, as, for example, in carpal tunnel syndrome assessment.

If providing measurement as a measure of pathology, also providing the normal range makes the stated measurement more meaningful.
- e.g., "Plantar fascia is thickened 6.4 mm (normal < 4.0 mm) close to the calcaneal attachment"

Terminology Best Avoided

"Malignancy cannot be excluded."
- This term should preferably not be used, as malignancy cannot be fully excluded in any situation

"Clinical correlation is required."
- This is stating the obvious
- Clinical correlation is part & parcel of US examination

Differential Diagnosis

When appropriate, provide a short differential diagnosis, usually up to 3 possibilities.

Providing a long list of differential diagnoses is not helpful, as it adds little to clinical assessment.

State the relative likelihood of each differential diagnosis & suggest alternative tests.
- e.g., "This most likely represents nerve sheath tumor; organizing hematoma is another less likely possibility; sarcoma is considered unlikely; US-guided biopsy is recommended"

Conclusion

Be precise & address the clinical question.

List abnormalities found in order of clinical relevance.

Propose the next course of action when US findings are not definitive.

Selected References

1. Griffith JF: Practical approach to ultrasound of soft tissue tumors and the added value of MRI: how I do it. J Ultrason. 23(95):e299-312, 2023

Pretibial Myxoedema

Pretibial Myxoedema

(Left) *Clinical photograph shows a 61-year-old woman with a pretibial skin rash* ⇨ *and swelling for 2 years.* **(Right)** *Longitudinal US shows localized hypoechoic dermal* ⇨ *and subdermal thickening displacing the mildly edematous subcutaneous fat* ⇨ *deeply. On direct questioning, the patient was being treated for hyperthyroidism. In this clinical context, the appearances are consistent with pretibial myxoedema. No further investigation was undertaken.*

Venous Vascular Malformation

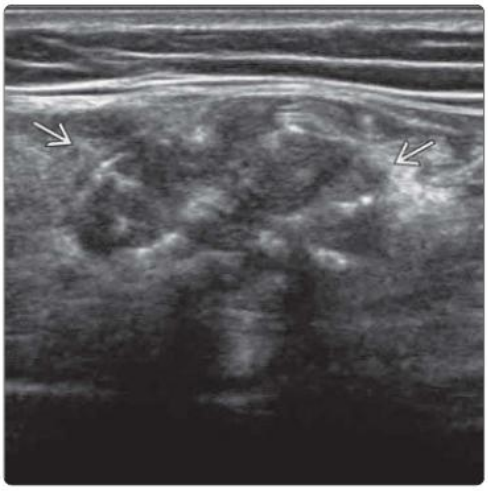

Venous Vascular Malformation

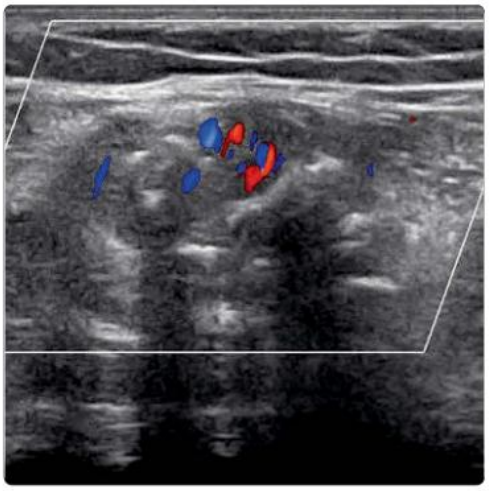

(Left) *Longitudinal US shows the calf in a 28-year-old woman with calf muscle swelling for several years slowly increasing in size. There is a quite well-defined, partially calcified mass* ⇨ *within the soleus muscle.* **(Right)** *Color Doppler imaging shows mild hyperemia. Overall, a venous vascular malformation was considered the most likely diagnosis. Other possibilities included an organizing chronic hematoma, previous myositis, or synovial sarcoma. Biopsy confirmed a vascular malformation.*

Myositis Ossificans

Seroma

(Left) *Longitudinal US in a 51-year-old woman with thigh swelling shows a well-demarcated mass in the vastus medialis muscle with solid rim-like calcification* ⇨*. Myositis ossificans was the most likely diagnosis. Radiographs confirmed progressive ossification of the mass. No further investigation was undertaken.* **(Right)** *Transverse panoramic US in an 88-year-old woman 1 month after paraumbilical incisional hernia repair shows a large seroma* ⇨ *located between the surgical mesh* ⇨ *and the subcutaneous tissue* ⇨*.*

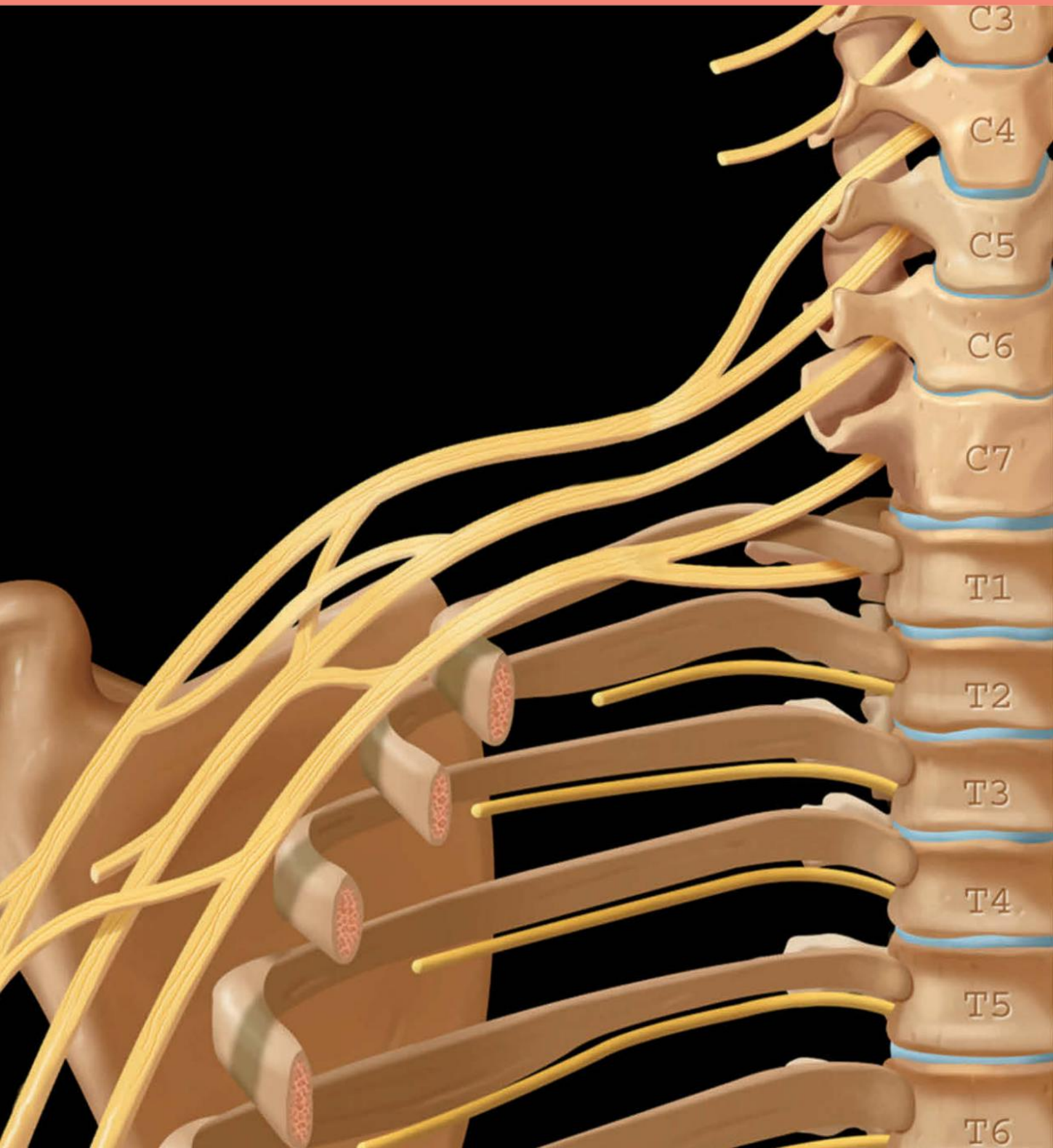
C3
C4
C5
C6
C7
T1
T2
T3
T4
T5
T6

PART II
SECTION 2

Technique

Shoulder Ultrasound	362
Brachial Plexus Ultrasound	370
Elbow Ultrasound	374
Wrist Ultrasound	382
Hand Ultrasound	390
Groin Hernia Ultrasound	394
Hip Ultrasound	402
Knee Ultrasound	410
Ankle Ultrasound	418
Foot Ultrasound	426

KEY FACTS

GENERAL CONSIDERATIONS

- Common specific indications are rotator cuff and long head of biceps as well as bursal, glenohumeral pathology and diagnostic/therapeutic US-guided intervention
- Less common specific indications are acromioclavicular joint, rotator cuff muscle pathology, suspected paralabral cysts, and labral pathology

TECHNIQUE

- Perform full standardized examination in all patients
- **Supraspinatus**
  - Crass position
  - Modified Crass position
- **Infraspinatus and teres minor**
  - Hand placed on contralateral shoulder or supinated resting on contralateral thigh
- **Biceps tendon**
  - Arm by side, elbow flexed, and examiner holding wrist and finely rotating arm to bring bicipital groove into view
- **Rotator interval**
  - Arm extended and externally rotated (i.e., elbow tucked in) (jogger position)
- **Subscapularis**
  - Arm externally rotated with flexed elbow placed against ipsilateral iliac crest
  - As subscapularis tendon is orientated from inferior to superior, scan in long and short axis along this plane
- **Glenohumeral joint recesses**
  - Lateral decubitus for posterior joint recess
  - Supine with arm externally rotated for anterior joint recess
- **Dynamic scanning for subacromial impingement**
  - Aim to recreate patient's pain
  - Place transducer in long axis either at lateral edge of acromion or over coracoacromial ligament
  - Raise pronated arm at angle ~ 45° forward from shoulder and assess symptoms/degree of impingement

(Left) *Clinical photograph shows Crass position during examination of supraspinatus tendon on long-axis view. Back of the hand is placed across the back, which internally rotates the shoulder, bringing the tendon out from underneath the acromion.* **(Right)** *Clinical photograph shows the modified Crass position. The hand is placed on the ipsilateral back pocket, producing less internal rotation than the Crass position. The anterior edge of supraspinatus can be more clearly seen, especially on short-axis views.*

Crass Position

Modified Crass Position

(Left) *Longitudinal US along the supraspinatus tendon shows anterior fibers inserting into the anterior facet ⇨ of the greater tuberosity. Focal anisotropy ⇨ due to fiber orientation is present. This is a common site for anisotropy.* **(Right)** *Longitudinal US of the supraspinatus tendon in the same location shows alteration in the tendon fiber orientation with lessening of anisotropic effect ⇨. Insonation angle can be changed by angling the transducer or altering the patient's position.*

Supraspinatus Tendon: Crass Position

Supraspinatus Tendon: Modified Crass Position

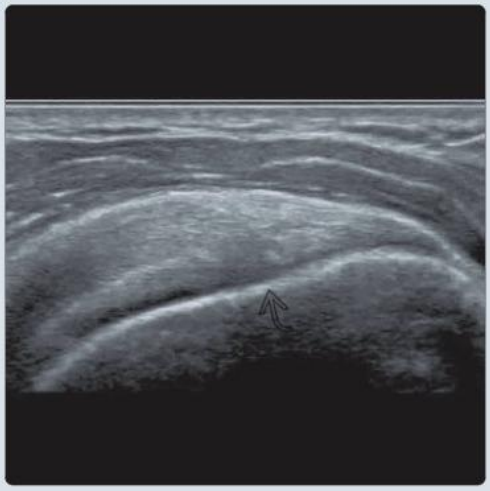

GENERAL CONSIDERATIONS

Clinical Indications for Shoulder US

- Most commonly examined joint with US
- Common specific indications are rotator cuff and long head of biceps as well as bursal, glenohumeral pathology and US-guided intervention
- Less common specific indications are acromioclavicular (AC) joint, rotator cuff muscle pathology, suspected paralabral cysts, and labral pathology
- Patients prefer US to MR

TECHNIQUE

Full Standardized Examination

- Necessary in all patients
- Shoulder pain is poorly localized as large subacromial-subdeltoid bursa is main pain initiator
- Subclinical rotator cuff tendinosis is common; therefore, do not use contralateral asymptomatic shoulder as internal reference of normality

Patient Position and Approach

- Anterior approach with examiner sitting on high seat facing patient sitting on low stool
- Posterior approach with patient sitting on couch or revolving stool with back to examiner
- Each tendon is examined from its musculotendinous junction to its insertion with tendon on stretch and moved away from overlying bone that may limit transducer access
- For all tendons, need to continually toggle transducer or move arm position to minimize anisotropy

Supraspinatus Tendon

- **Best position**
  - At least 4 different positions can be used to examine supraspinatus tendon
    - Crass position
    - Modified Crass position
    - Partial internal rotation ("shrug" position)
    - Neutral position
  - In practice, consider scanning supraspinatus long axis in Crass position and short axis in modified Crass position
- **Scan technique**
  - Align transducer longitudinally over supraspinatus tendon
    - Scan from anterior-most portion (i.e., biceps tendon margin) to posterior where supraspinatus tendon imperceptibly merges with infraspinatus
    - Focus primarily on those fibers deep to transducer
  - Turn transducer 90° so that it is aligned transverse to tendon and scan from medial to lateral using biceps tendon to mark anterior edge of supraspinatus tendon
    - Scan anterior, middle, and posterior fibers in turn angling transducer over insertional area to main correct insonation angle

Infraspinatus Tendon

- **Best position**
  - Hand placed on contralateral shoulder or supinated resting on contralateral thigh
- **Scan technique**
  - Align transducer in longitudinal plane along infraspinatus tendon using musculotendinous junction as guide
    - Scan infraspinatus to its most lateral attachment into middle facet
    - Cortical defects of humeral head deep to infraspinatus tendon are common and usually of no clinical significance
  - Turn transducer 90° to align transverse to infraspinatus tendon and scan from myotendinous junction to insertion

Teres Minor Tendon

- **Best position**
  - Similar to infraspinatus
- **Scan technique**
  - Rotate transducer more vertically than infraspinatus to align along teres minor tendon
    - Teres minor has more vertical course than infraspinatus as it arises on inferolateral side of infraspinatus
    - ± turn transducer 90° to align transverse to teres minor tendon and scan from myotendinous junction to insertion

Long Head of Biceps Tendon

- **Best position**
  - Arm by side, elbow flexed, and finely rotate arm to bring bicipital groove into view
- **Scan technique**
  - Align transducer transversely across bicipital groove
  - Scan proximally to uppermost aspect of bicipital groove and distally to where pectoralis major tendon passes over biceps tendon
  - Slightly extending arm will allow one to see more of proximal biceps tendon
  - ± internally/externally rotate arm to test for biceps subluxation
  - Rotate transducer 90° to align longitudinal to biceps tendon, focusing particularly on proximal end of tendon

Rotator Interval

- **Best position**
  - Arm extended and externally rotated (i.e., elbow tucked in) (jogger position)
  - Mild changes in extension and external rotation can improve visibility
- **Scan technique**
  - Scan transversely across biceps tendon at and proximal to uppermost portion of bicipital groove
  - Proximal, mid-, and distal portions of rotator interval should be examined
  - Uppermost part of bicipital groove equates to distal end of rotator interval
  - Coracohumeral ligament (CHL) seen as echogenic band, ~ 1.5 mm thick, superficial to biceps tendon
  - CHL joins with superior glenohumeral ligament medially forming bicipital sling
  - Distally, superficial subscapularis fibers passing over biceps tendon to lateral lip of bicipital groove support lateral border of biceps tendon

Subscapularis Tendon

- **Best position**
  - Arm externally rotated with flexed elbow placed against ipsilateral iliac crest
    - Limited external rotation is sign of adhesive capsulitis
  - As subscapularis tendon is orientated from inferior to superior, scan in long and short axis along this plane
  - ± helpful to scan upper fibers with arm more extended
- **Scan technique**
  - On longitudinal scanning, obverse narrow tendon insertion into lesser tuberosity and medial part of surgical neck
    - Toggle transducer or rotate arm slightly to reduce anisotropy
  - Sweep transducer proximally and distally to see full width of tendon
    - Superior 2/3 of tendon is tendinous → lesser tuberosity
    - Inferior 1/3 of tendon is muscular → lesser tuberosity and adjacent part of humeral surgical neck
  - Cortical defects deep to tendon are common
  - Also scan medially deep to coracoid ± check for subcoracoid impingement by rotating arm
  - On transverse scanning, 5-6 tendon slips from multipennate muscle converge onto tendon insertion
    - Do not confuse alternating hypoechoic/hyperechoic pattern with tears or tendinosis
  - Tendon tears of upper fibers more common
  - Uppermost fibers merge with supraspinatus/CHL forming roof and floor of rotator interval over and under biceps tendon

Subacromial-Subdeltoid and Subcoracoid Bursae

- **Best position**
  - Same as for supraspinatus tendon bursa and subscapularis bursa
- **Scan technique**
  - Scan in longitudinal or transverse planes with tissues in relatively relaxed position
  - Supraspinatus tendon bursa is seen between deltoid muscle and supraspinatus tendon
    - Seen as thin (< 0.8-mm) hypoechoic line sandwiched between layers of peribursal fat (< 2-mm thick normally)
  - Subscapularis bursa located between coracoid process and short head of biceps tendon superficial to subscapularis tendon and muscle
    - Should not be confused with subcoracoid recess, which protrudes over upper end of subscapularis tendon

Dynamic Assessment of Subacromial Impingement

- **Best position**
  - Aim to recreate patient's pain
- **Scan technique**
  - Place transducer in long axis either at lateral edge of acromion or over coracoacromial ligament
  - Raise pronated arm at angle ~ 45° forward from shoulder and assess symptoms/degree of impingement
    - Grade 0: No painful arc; no demonstrable impingement
    - Grade 1: Painful arc; no demonstrable impingement
    - Grade 2: Painful arc; demonstrable soft tissue impingement
    - Grade 3: Painful arc; demonstrable humeral impingement

Acromioclavicular Joint

- **Best position**
  - Neutral
- **Scan technique**
  - Scan transversely over superior aspect of AC joint
  - Capsule normally bulges slightly superficially, which is increased in AC joint osteoarthritis
    - Downward transducer pressure inducing pain may help confirm AC joint as source of pain
  - Normal AC joint width is 4 mm
  - AC joint widened > 7 mm at midportion ± > 3 mm wider than opposite side is considered abnormal
  - Dynamic scanning can improve detection of AC joint laxity
    - Moving ipsilateral hand from ipsilateral knee to contralateral shoulder
    - Pull down ipsilateral arm by examiner whilst patient resists and compare to contralateral side
    - Stress imaging with patient holding weights akin to radiographic stress examination

Rotator Cuff Musculature and Suprascapular/Spinoglenoid Notches

- **Best position**
  - Neutral
- **Scan technique**
  - Scan in longitudinal and transverse plane along axis of muscle
  - Assess muscle bulk and also compare echogenicity to central tendon as well as trapezius muscle
  - Align transducer along tendon and trace toward tendon insertion
  - Suprascapular notch seen by scanning in transverse plane deep to supraspinatus muscle at upper margin of scapula
  - Spinoglenoid notch seen by scanning in transverse plane located between posterior glenohumeral joint and scapular spine

Glenohumeral Joint and Glenoid Labra

- **Best position**
  - Lateral decubitus for posterior joint recess
  - Supine with arm externally rotated for anterior joint recess
- **Scan technique**
  - Posterior recess: Scan longitudinally over infraspinatus close to musculotendinous junction
  - Anterior recess: Scan transversely deep to subscapularis tendon, though more difficult to assess
  - Visibility of joint recesses improved by slowly, passively, externally, and internally rotating patient's arm

Symptomatic Area

- Examine symptomatic area if removed from shoulder, such as midarm or supraclavicular region, to avoid missing unexpected pathology

Scan Position for Short-Axis View of Supraspinatus Tendon

Supraspinatus Tendon: Short Axis

(Left) *Clinical photograph shows modified Crass position with transducer location for short-axis view of the supraspinatus. The modified Crass position produces less internal rotation of the shoulder, improving visibility of the anterior edge of the supraspinatus and the biceps tendon.* **(Right)** *Transverse US of supraspinatus tendon at its insertion is shown. The biceps tendon ⇨ marks the anterior edge ⇨ of supraspinatus tendon. Mild anisotropy ⇨ is due to fiber orientation and intermingling of supraspinatus and infraspinatus tendons.*

Scan Position for Long-Axis View of Infraspinatus Tendon

Infraspinatus Tendon: Long Axis

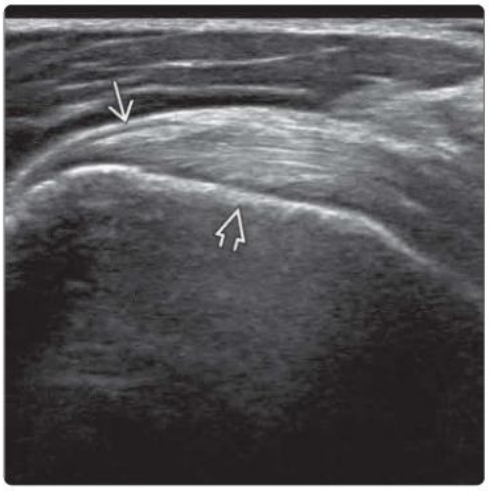

(Left) *Longitudinal US shows the patient and transducer position for examination of the infraspinatus tendon in long axis. The hand is placed on the contralateral shoulder. Alternatively, the hand can be placed on the contralateral thigh with the hand facing upward.* **(Right)** *Longitudinal US shows the long-axis view of the infraspinatus tendon inserted into the middle facet of the greater tuberosity ⇨. Peribursal fat overlies the tendon. The thin, hypoechoic bursal line ⇨ can be appreciated more laterally.*

Teres Minor: Long Axis

Infraspinatus and Teres Minor Tendons: Short Axis

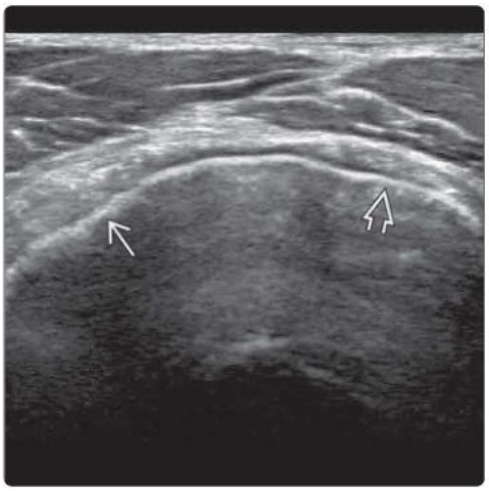

(Left) *Longitudinal US shows the long-axis view of teres minor insertion into the inferior facet of greater tuberosity ⇨. Teres minor musculotendinous junction ⇨ can also be appreciated.* **(Right)** *Transverse US along the posterosuperior aspect of the humeral head shows the infraspinatus ⇨ and teres minor ⇨ tendons inserting into the middle and inferior facets of the greater tuberosity, respectively.*

(Left) *Clinical photograph shows the patient and transducer position for rotator interval (jogger position), which is similar to the modified Crass position except that the hand is forward and upward and the elbow is more tucked in.* **(Right)** *Transverse US across the rotator interval shows the anterior edge of supraspinatus ➡, long head of biceps tendon (LHBT) ➡, and superior edge of subscapularis ➡. The coracohumeral ligament ⇨ lies superficial, and superior glenohumeral ligament/bicipital sling ⇨ is medial and inferior to LHBT.*

Scan Position for Rotator Interval

Rotator Interval: Short Axis

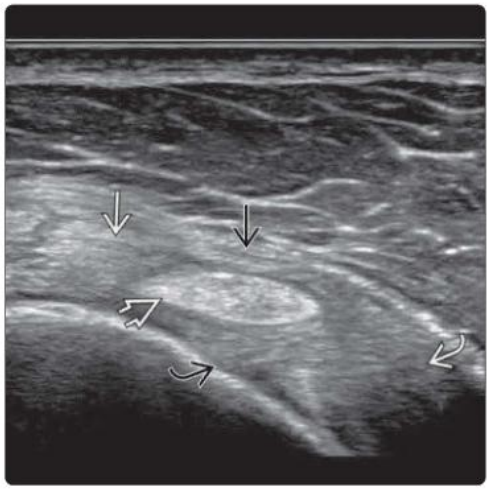

(Left) *Clinical photograph shows the scan position for the biceps tendon. The arm should be rotated slightly to align the bicipital groove and LHBT anteriorly. Greater degree of rotation of the arm allows assessment of LHBT laxity.* **(Right)** *Transverse US shows the normal oblong shape of LHBT ➡ at the upper end of the bicipital groove. This portion of the tendon, known as the genu, is most prone to tendinosis and tear. The superficial fibers ➡ of subscapularis pass over LHBT to insert onto the lateral lip of the bicipital groove.*

Scan Position for Biceps Tendon

Biceps Tendon: Proximal Portion

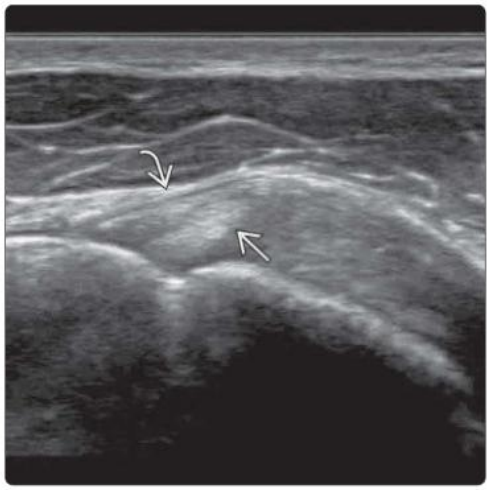

(Left) *Transverse US shows a more rounded appearance of LHBT ➡ within the midportion of the bicipital groove. Traversing superficial fibers ➡ from the subscapularis help retain LHBT in position.* **(Right)** *Transverse US shows a much more flattened, distal LHBT ➡ deep to the pectoralis major insertion ➡ into the lateral lip of the bicipital groove.*

Biceps Tendon: Midportion

Biceps Tendon: Distal Portion

Biceps Tendon: Long Axis

Scan Position for Long-Axis View of Subscapularis Tendon

(Left) *Longitudinal US shows the longitudinal view of the mid- to proximal end of LHBT ➡. Slight adduction of the arm may help with visualization. Mild arm extension can help increase visibility of the intraarticular portion of the LHBT ➡.* **(Right)** *Clinical photograph shows the arm and probe position for the long-axis subscapularis tendon. Note how long axis of the transducer should be angled slightly upward as the subscapularis tendon moves from inferior to superior toward its insertion.*

Subscapularis Tendon: Long Axis

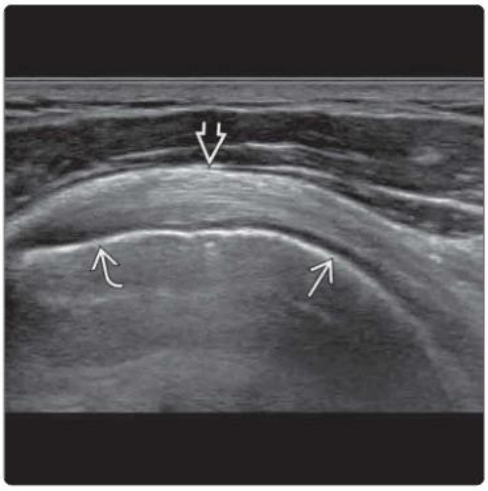

Subscapularis Tendon: Short Axis

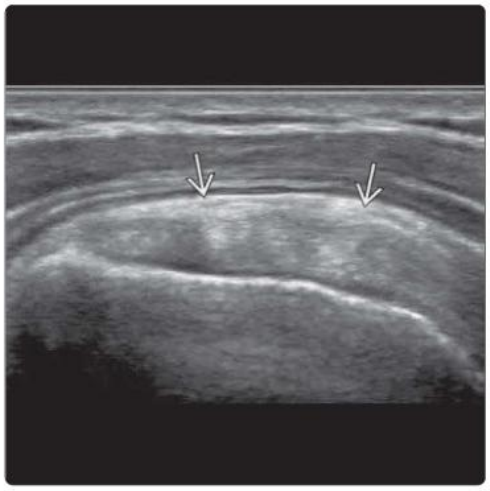

(Left) *Transverse US shows the long-axis view of the subscapularis tendon ➡ inserting into the lesser tuberosity ➡. Hypoechoic articular cartilage ➡ is visible deep to the tendon medially.* **(Right)** *Longitudinal US shows the transverse section of the subscapularis tendon ➡. The multipennate structure of the subscapularis muscle produces several tendon slips, which lead to the normal alternating hyperechoic/hypoechoic appearance of this tendon.*

Scan Position for Glenohumeral Joint: Posterior

Glenohumeral Joint: Posterior

(Left) *Clinical photograph shows the patient and transducer position for examination of the posterior recess of the glenohumeral joint in short axis.* **(Right)** *Transverse US of the posterior aspect of the glenohumeral joint is shown. The humeral head is covered with hypoechoic articular cartilage ➡, posterior glenoid rim ➡, posterior labrum ➡, and overlying infraspinatus tendon ➡. The posterior recess of the glenohumeral joint is effaced and not distended.*

(Left) *Clinical photograph shows the transducer position for assessment of the acromioclavicular joint (AC). Dynamic assessment for AC joint laxity can be performed by either specific arm movement or axial traction on the arm.* **(Right)** *Transverse US shows a normal AC between the acromion ➡ and clavicle ➡. Normal capsuloligamentous thickening is visible superiorly ➡. The intraarticular disc is normally not seen. The clavicle usually lies higher than the acromion. AC joint width should be < 7 mm.*

Scan Position for Acromioclavicular Joint

Acromioclavicular Joint

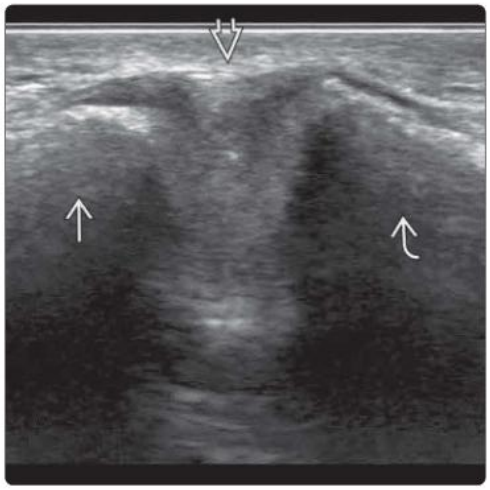

(Left) *Clinical photograph shows the patient and transducer position for dynamic assessment of subacromial or subcoracoacromial ligament impingement. Starting from a neutral position, the arm is abducted to recreate the patient's symptoms.* **(Right)** *Longitudinal US along the length of the coracoacromial ligament ➡ shows stretching between acromion ➡ and coracoid process ➡. The supraspinatus muscle ⇨ lies deep to the coracoacromial ligament, and the deltoid muscle ⇨ is superficial.*

Scan Position for Subacromial Impingement

Coracoacromial Ligament: Long Axis

(Left) *Longitudinal US of the normal supraspinatus tendon shows the rotator cable ➡ at the midlower part of the supraspinatus tendon. The alignment is different than that of the remaining supraspinatus fibers. The hypoechoic line ⇨ superiorly is due to a normal, nondistended subacromial-subdeltoid bursa.* **(Right)** *Transverse US shows altered supraspinatus tendon echogenicity ➡ due to the rotator cable in short axis. This should not be misinterpreted as tendinosis. Biceps tendon lies medially ➡.*

Rotator Cable: Long Axis

Rotator Cable: Short Axis

Scan Position for Dorsal Scapular Region

Supraspinatus Muscle: Short Axis

(Left) *Clinical photograph shows the patient position to assess the parascapular muscle. These muscles can be viewed in short axis or long axis along their orientation. The suprascapular notch and spinoglenoid notch are usually scanned in the transverse plane.* **(Right)** *Longitudinal US shows the transverse section of the normal supraspinatus muscle ➡ filling the supraspinatus fossa. Echogenicity can be compared to the overlying trapezius muscle ➡ and to the central tendon of the supraspinatus muscle.*

Infraspinatus Muscle: Short Axis

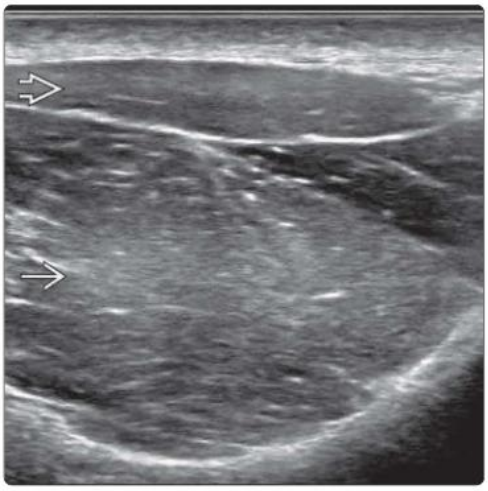

Teres Minor Muscle: Short Axis

(Left) *Longitudinal US shows the transverse section of the normal infraspinatus muscle ➡ filling the infraspinatus fossa. Muscle echogenicity can be compared to the overlying trapezius muscle ➡ and the central tendon of the infraspinatus muscle.* **(Right)** *Longitudinal US shows the transverse section of the normal teres minor muscle ➡ at the inferomedial tip of the infraspinatus muscle ➡. Teres minor muscle bulk may be spared when the other rotator cuff muscles are atrophied. Trapezius ➡ lies superiorly.*

Suprascapular Notch

Spinoglenoid Notch

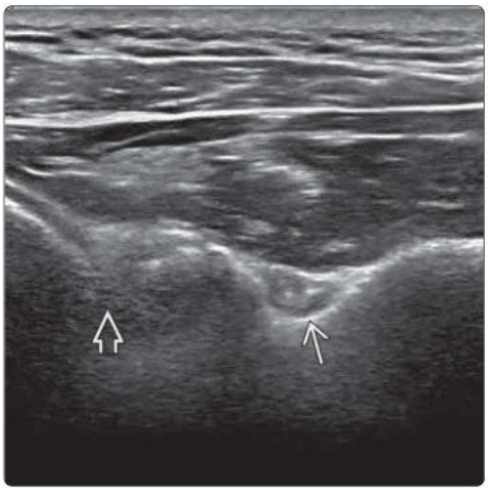

(Left) *Transverse US shows the suprascapular notch ➡ at the superior margin of the scapula bone ➡. The suprascapular notch is variable in shape and size and often may not be seen as a distinct notch. The supraspinatus ➡ and trapezius ⇨ muscles lie superiorly.* **(Right)** *Transverse US shows the spinoglenoid notch ➡ located between the lateral end of the scapular spine and posterior margin of glenohumeral joint ➡. At this location, the suprascapular nerve may be compressed by paralabral cysts originating from the posterior labrum.*

KEY FACTS

IMAGING ANATOMY

- Brachial plexus (BP) is neural network to upper limb
- BP extends from ventral rami of C5-T1 roots to terminal branches in axilla
- Considerable variation in appearances of trunks, divisions, & cords of BP among individuals exists
- Contralateral normal or less-affected side axis is good internal reference as to expected brachial morphology on affected side
- 2/3 of BP US or MR examinations are normal
- US is as accurate as MR in detecting most BP pathologies
  - Likelihood of finding abnormality on MR following negative US examination is extremely low
- BP US is standardized examination with all parts of BP examined in all patients
- Imperative to examine BP on both sides, starting with unaffected or least affected side

TECHNIQUE

- Best to start examination at intrascalene region
  - Observe trunks & check for compression of lower trunk (wedge-sickle sign)
- Move transducer medially in same transverse plane to examine roots emerging from cervical spine
  - Thumb-up sign & V-sign
- Return to intrascalene region & observe suprascapular nerve
- Scan in same transverse plane lateral to scalene muscles & observe divisions of BP
  - Akin to bunch of grapes
- Ask patient to abduct arm to 90° & examine subpectoralis space
  - Median, lateral, & posterior cords aligned around axillary artery
- Fully abduct arm to examine axillary region
  - Median, ulnar, radial, & musculocutaneous nerve aligned in quite consistent position around axillary artery

Scan Position for Supraclavicular Region

"Traffic Light Sign"

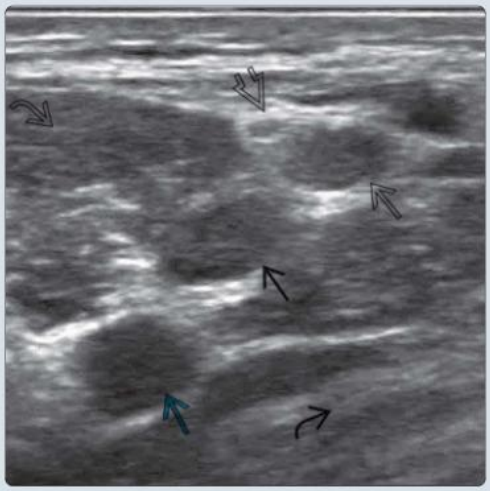

(Left) *Clinical photograph shows the scan position for the supraclavicular portion of the brachial plexus, which includes the roots, trunks, divisions, and suprascapular nerve.* **(Right)** *Transverse US of supraclavicular region shows the classic "traffic light sign" with the upper ➡, middle ⇨, and lower ⇨ trunks of the brachial plexus lined up between the scalenus anterior ⇨ and medius ➡ muscles. The suprascapular nerve ➡ arising from the upper trunk is also shown.*

Interscalene Triangle

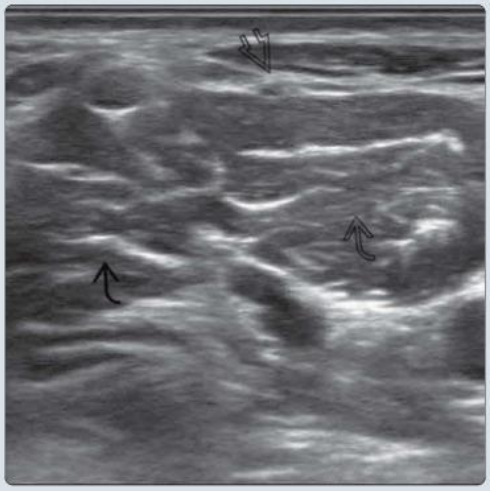

Brachial Plexus Components

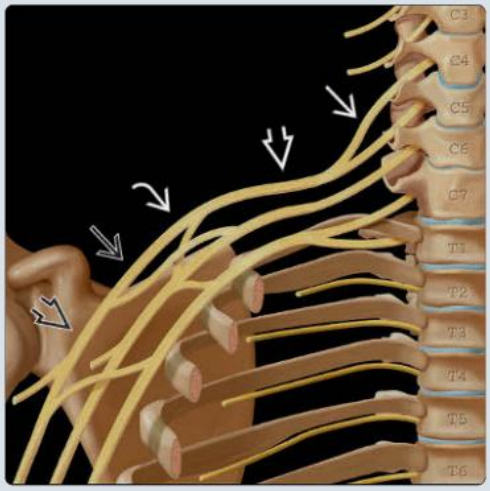

(Left) *Transverse US shows a more typical appearance of the interscalene triangle in another patient. Rather than the classic "traffic light sign," a mixture of roots, trunks, and divisions is seen between the scalenus anterior ➡ and medius ⇨ muscles. The phrenic nerve ➡, passing over the scalenus anterior muscle, is also shown.* **(Right)** *Graphic shows the 5 roots ➡, 3 trunks ➡, 6 divisions ➡, 3 cords ⇨, and 5 terminal branches ⇨ of the brachial plexus. The brachial plexus is the neural highway to the upper limb.*

TERMINOLOGY

Abbreviations

- Brachial plexus (BP)

IMAGING ANATOMY

General Anatomic Considerations

- BP is neural network to upper limb
- BP extends from ventral rami of C5-T1 roots to terminal branches in axilla
- Considerable variation in appearances of trunks, divisions, & cords of BP among individuals exists
  - Fortunately, little intrinsic side-to-side variability exists
    - Contralateral normal or less-affected side axis is good internal reference as to expected brachial morphology on affected side
- Clinical localization of symptoms to BP is difficult
  - 2/3 of BP US or MR examinations are normal

Limitations of Brachial Plexus US

- BP is accessible to US in vast majority of patients
  - Intraforaminal or intraspinal portions of nerve roots are not accessible to US examination
    - Not part of BP, which starts at ventral rami
  - Small segment of BP deep to clavicle (costoclavicular gap) not accessible on US examination
    - BP immediately proximal & distal to costoclavicular gap is consistently seen
    - Dynamic spectral Doppler analysis enables assessment of vascular compression in this area
  - Large open wound or severe soft tissue swelling may preclude US examination
  - Inability to abduct arm limits examination of axilla
  - BP US is also limited in young children with small necks

Benefits of Brachial Plexus US

- US is as accurate as MR in detecting most BP pathologies
  - Likelihood of finding abnormality on MR following negative US examination is extremely low
  - US is very helpful at excluding BP pathology
- Allows ready examination of extraplexal nerves
- Facilitates US-guided biopsy of suspicious masses
- Facilitates US-guided therapeutic injection

Technique

- BP US is usually performed with patient lying supine & head slightly elevated
  - Gown should be tied below shoulders so that neck & shoulders fully exposed
- BP US is standardized examination with all parts of BP examined in all patients
- Imperative to examine BP on both sides, starting with unaffected or least affected side
- Contralateral normal side provides good internal reference as to expected BP morphology on affected side
- BP US is primarily performed in transverse plane
  - Longitudinal plane is helpful when assessing
    - Neural swelling following trauma to evaluate for transection or neuroma-in-continuity
    - BP tumors to assess tumor eccentricity with respect to parent nerve
    - Neural constriction in neuralgic amyotrophy
- Roots, trunks, & divisions are monofascicular & hypoechoic, while cords & terminal branches are polyfascicular
- **Best to start examination at interscalene region**
  - Observe "traffic light sign" of upper, middle, & lower trunks
    - Often, "traffic light sign" not seen with roots, trunks, & divisions variably present in interscalene region
    - Check for compression of lower trunk (wedge-sickle sign)
- **Move transducer medially in same transverse plane to examine roots emerging from cervical spine**
  - C7 root identified by recognizing thumbs up sign
  - C6 & C5 roots more cephalad between tubercles of C6 & C5 transverse processes (V-sign)
  - C8 & T1 caudad to C7 root
- Check for compression of lower trunk & roots (seen as wedge-sickle sign)
  - Compression usually caused by fibromuscular band or medial edge of 1st rib
- **Return to interscalene region & observe suprascapular nerve**
  - Trace this nerve laterally deep to omohyoid muscle
    - Normal cross-sectional area < 2.8 ± 0.8 mm²
- **Scan in same transverse plane lateral to scalene muscles & observe divisions of BP**
  - Follow divisions, aligned superolateral to subclavian artery & akin to bunch of grapes, in transverse plane to costoclavicular gap, angling transducer behind clavicle
- **Ask patient to abduct arm to 90° & examine subpectoralis space**
  - Observe cords aligned lateral & inferior to axillary artery
    - Subclavian termed axillary artery beyond 1st rib
- In patients with suspected vascular thoracic outlet syndrome, check for dynamic compression of axillary artery
  - Undertake spectral Doppler analysis in subclavian & axillary arteries in neutral position & then of axillary artery with arm hyperabducted & externally rotated
  - Significant hemodynamic disturbance indicated by 2-fold increase in peak systolic velocity (dynamic stenosis), cessation of arterial flow (dynamic occlusion), or poststenotic tardus-parvus spectral pattern
- **Fully abduct arm to examine axillary region**
  - Identify brachial artery in proximal arm & follow it proximally to axilla where median, ulnar, & radial nerves lie in quite consistent position around axillary artery
    - Likened to dog's paw
  - Median nerve lies superolaterally closest to arm muscles
  - Ulnar nerve lies superomedially
  - Radial nerve lies inferomedially
  - Musculocutaneous nerve lies between biceps & coracobrachialis muscles

CLINICAL IMPLICATIONS

Indications for US Examination

- BP US is helpful for assessing irradiation plexopathy, nerve sheath tumors, metastases, BP trauma, thoracic outlet syndrome, neuralgic amyotrophy, inflammatory polyneuropathies

(Left) *Transverse US shows the prominent posterior tubercle ➡ of C7 transverse process (outlined). This is known as the thumbs-up sign and is a good marker for the C7 root ➡, located anterior to the tubercle. The C7 vertebral body has either no anterior tubercle or a small rudimentary one.* **(Right)** *Transverse US shows typical V-shaped appearance (V-sign) of the anterior ➡ and posterior ➡ tubercles of the C6 transverse process. Between the tubercles is the C6 root ➡, which exits the C5/C6 exit foramen cephalad to this level.*

C7 Transverse Process and Nerve Root

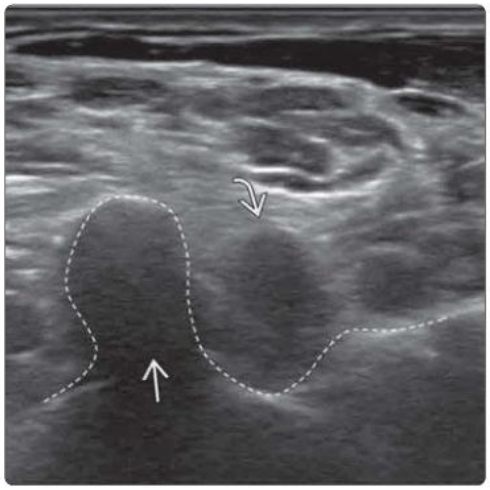

C6 Transverse Process and Nerve Root

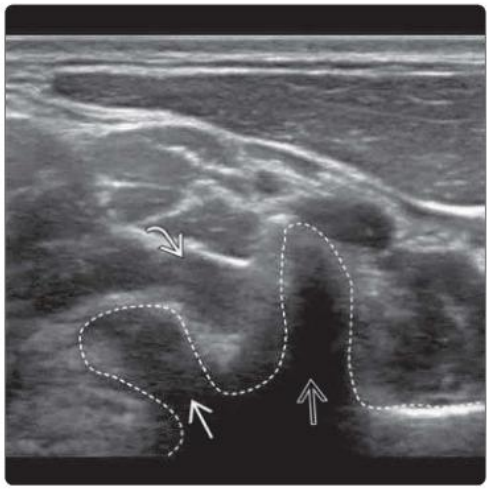

(Left) *Transverse US shows the suprascapular nerve ➡ lying more lateral to the scalene muscles and deep to the omohyoid muscle ➡. The suprascapular nerve has a similar course to the omohyoid muscle, which inserts on the scapula just lateral to the suprascapular notch.* **(Right)** *Transverse US shows the divisions ➡ of the brachial plexus, akin to a bunch of grapes, located superior to the subclavian artery ➡.*

Suprascapular Nerve

Divisions of Brachial Plexus

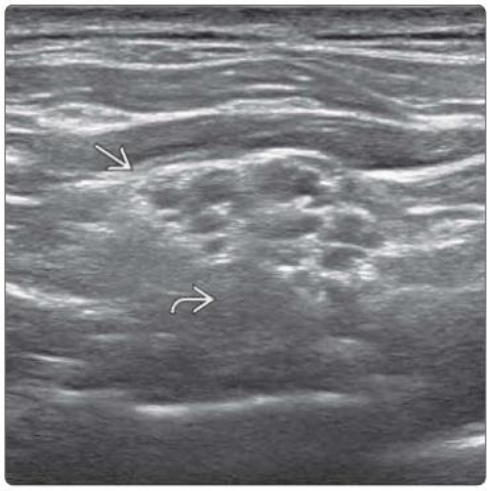

(Left) *Transverse color Doppler US shows the transverse cervical artery, which frequently passes over the divisions ➡ of the brachial plexus. This proximity to the brachial plexus is not of any known clinical significance. The subclavian artery ➡ is located more deeply.* **(Right)** *Transverse US shows the divisions ➡ of the brachial plexus lined up lateral to the subclavian artery ➡ just proximal to the costoclavicular gap. The lateral end of the clavicle ➡ and pleura ➡ are shown.*

Divisions of Brachial Plexus

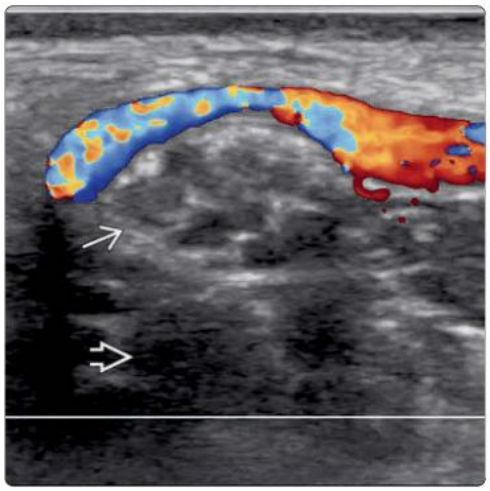

Divisions of Brachial Plexus

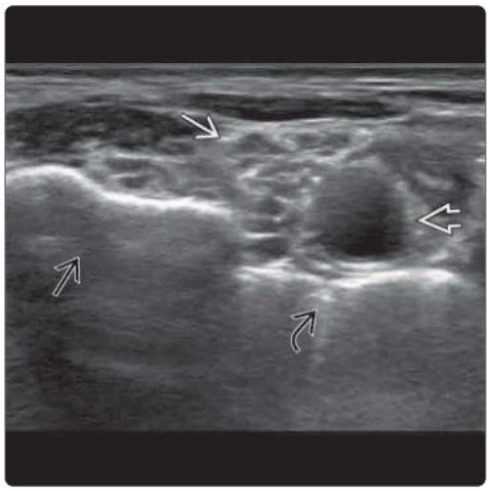

Costoclavicular Gap

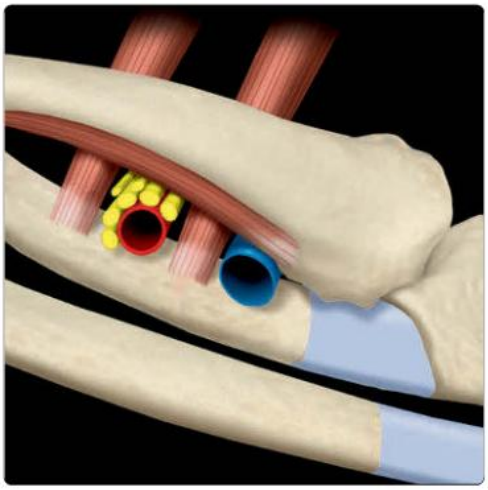

Scan Position for Subpectoralis Space

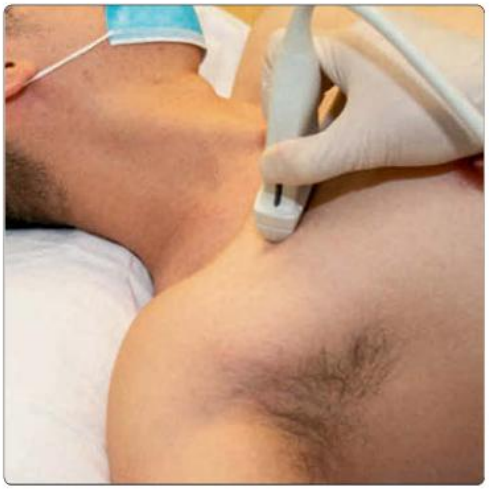

(Left) *The costoclavicular gap is the narrowest portion of the brachial plexus passageway from the spine to the axilla. It is the most common site of vascular compression and also a common site of neural compression in patients with thoracic outlet syndrome. Most compression is due to anomalies within the costoclavicular region rather than previous fractures of the clavicle or 1st rib.* **(Right)** *Clinical photograph shows the transducer position for the subpectoralis space. The arm is abducted to 90°.*

Cords of Brachial Plexus

Scan Position for Axilla

(Left) *Transverse US shows the medial ➡, lateral ➡, and posterior ➡ cords of the brachial plexus lying alongside the axillary artery ⇨ deep to the pectoralis minor muscle ⇨. The subclavian artery becomes the axillary artery on crossing over the 1st rib. The subclavian vein ⇨ lies medially.* **(Right)** *Clinical photograph shows the scan position for the axilla. The arm is fully abducted.*

Neural Arrangement Around Axillary Artery

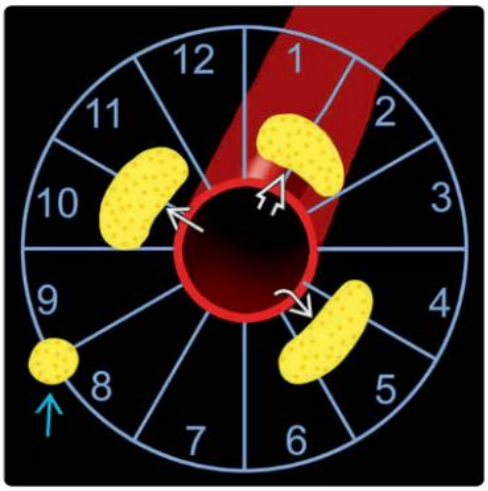

Neural Arrangement at Axilla

(Left) *Graphic shows neural arrangement around the axillary artery as a clock face. Median nerve ➡ lies superolaterally, ulnar nerve ➡ lies superomedially, and radial nerve ➡ lies inferomedially. Musculocutaneous nerve ⇨ lies inferomedially between the biceps and coracobrachialis muscles.* **(Right)** *Transverse US shows median ➡, ulnar ➡, and radial ➡ nerves aligned alongside the axillary artery ⇨. Musculocutaneous nerve ⇨ lies between the biceps and coracobrachialis muscles.*

KEY FACTS

GENERAL CONSIDERATIONS

- Common specific indications
  - Suspected joint effusion, synovitis, epicondylitis, & cubital tunnel syndrome
- Less common specific indications
  - Olecranon bursitis, distal biceps & triceps pathology, supinator & radial tunnel syndromes

TECHNIQUE

- **Anterior elbow**
  - Seated opposite examiner with elbow extended on examination couch
  - Increase height of examination table so that elbow is almost horizontal
    - Anterior aspect of elbow joint
    - Distal biceps tendon
    - Brachialis
    - Median nerve
    - Radial nerve
- **Medial elbow**
  - Patient facing examiner with elbow extended & forearm externally rotated
    - Common flexor tendon origin
    - Medial collateral ligament complex
    - Cubital tunnel
- **Lateral elbow**
  - Elbow flexed toward examiner & hand pronated
    - Common extensor tendon origin
    - Radial collateral ligament
    - Lateral ulnar collateral ligament
    - Synovial fringe
    - Annular ligament
- **Posterior elbow**
  - Elbow flexed toward examiner with palm resting on examination couch ("crawling crab" position)
    - Triceps tendon
    - Posterior aspect of elbow joint

Scan Position for Anterior Elbow

Distal Biceps Tendon

(Left) *Clinical photograph shows the scan position for the anterior elbow. The elbow can be placed on a firm pad ⇨ to bring it into a more horizontal orientation. This helps the examination of the anterior elbow region.* **(Right)** *Transverse US shows the biceps tendon ➡ just proximal to the elbow joint located between the subcutaneous tissues & the brachialis muscle ⇨. The bicipital aponeurosis ➡ extending over the brachial artery & median nerve helps maintain the position of the distal biceps tendon.*

Distal Biceps Tendon

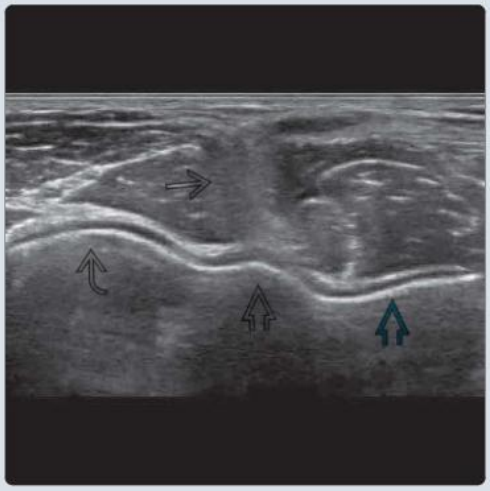

Brachialis Muscle Insertion

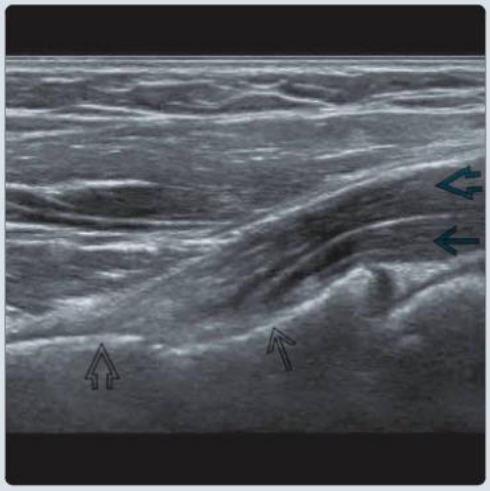

(Left) *Transverse US at the proximal aspect of elbow joint shows the hypoechoic artifact ➡ from the distal biceps tendon as it descends toward the radial tuberosity. The hypoechoic hyaline cartilage overlying the capitellum ⇨ & lateral ➡ & medial ⇨ pillars of the trochlea is seen.* **(Right)** *Longitudinal US of the anterior elbow shows the broad musculoaponeurotic insertion of the deep head of brachialis muscle ⇨ onto the coronoid process ➡ & the smaller tendinous insertion of the superficial head ⇨ onto the ulnar tuberosity ➡.*

GENERAL CONSIDERATIONS

Clinical Indications for Elbow US

- Nearly all elbow conditions are best imaged with US
- Common indications: Suspected joint effusion, synovitis, epicondylitis, & cubital tunnel syndrome
- Less common indications: Olecranon bursitis, distal biceps pathology, radial tunnel syndrome, & triceps pathology

Targeted Approach Most Efficient

- Take brief history regarding site & duration of symptoms, trauma history, etc.
- Check for joint effusion/synovitis & then focus on symptomatic area

TECHNIQUE: ANTERIOR ELBOW

Patient Position

- Seated opposite examiner with elbow extended on examination couch
  - ± place pad under elbow for full extension
- Increase height of examination table so that elbow is almost horizontal

Specifically Examine

- **Anterior aspect of elbow joint**
  - Saddle-shaped trochlea covered with anechoic articular cartilage articulating with pointed triangular coronoid process; medial ridge larger than lateral ridge
  - More rounded capitellum laterally articulates with square-shaped radial head
    - Capitellum faces more anteriorly & is not visible using posterior approach
- **Distal biceps tendon**
  - Seen between subcutaneous tissue & brachialis at distal end of humerus
    - Medial nerve lies medial to brachial artery, while biceps tendon lies lateral
      - Bicipital aponeurosis passes from biceps over artery & nerve to pronator teres myofascia
  - Tendon is hypoechoic on transverse imaging & best seen on longitudinal imaging
  - Long & short heads are barely separable
    - Long head is attached to radial tuberosity & is thus stronger supinator of elbow
    - Short head is attached more medial & distal to radial tuberosity & is mainly elbow flexor
    - Normal bicipitoradial bursa located between biceps & tuberosity not visible
  - To most readily see distal biceps tendon, hypersupinate forearm, which moves radial tuberosity forward, & angle transducer longitudinally (heel-toe) parallel to tendon
  - Alternatively
    - Medial approach: Elbow flexed to 25° & forearm supinated
      - Scan longitudinally along proximal radius
      - When distal biceps tendon comes into view, minimally adjust forearm & probe position to optimize visibility
    - Lateral approach: Elbow flexed to 90° & forearm pronated
      - Scan longitudinally along distal humerus similar to flexed abducted supinated (FABS) MR view
      - As transducer is moved slowly anteriorly, biceps tendon will come into view parallel to brachial artery
    - Cobra position: Elbow flexed to 90° with forearm pointing upward & pronated
      - Scan in transverse plane over proximal radius at distal end of supinator muscle
      - Distal biceps identified during pronation; hyperflexion of elbow will accentuate biceps tendon visibility
- **Brachialis**
  - Larger superficial head inserts onto ulnar tuberosity as short tendon over small area
  - Smaller deep head inserts onto ulnar tuberosity & anterior surface coronoid process as musculoaponeurotic attachment over broad area
- **Median nerve**
  - Medial to brachial artery
    - Usually (80%) just alongside artery but occasionally (20%) separate from artery
  - Trace median nerve transversely deep to pronator teres & flexor digitorum superficialis (FDS)
    - Potential sites of compression are between 2 heads of pronator teres & deep to fibrous arcade proximal end of FDS
    - Gives off anterior interosseous branch (purely motor) between pronator teres heads
- **Radial nerve**
  - Best identified deep to brachioradialis
    - Trace along radial tunnel, which is located between radiocapitellar joint & proximal border of supinator
      - Uncommon site of compression by vascular arcade ("leash of Henry")
      - Recurrent radial artery traveling with nerve can be identified by color Doppler
    - Identify radial nerve dividing into superficial & deep branches
  - Deep branch enters supinator muscle as posterior interosseous nerve (PIN)
    - Gently pronate/supinate forearm to help see nerve passing through & exiting supinator tunnel
    - Proximal end of supinator tunnel (arcade of Frohse) is common site of PIN compression
      - Focal angulation & flattening of PIN at arcade of Frohse is common, normal finding
    - Normal size of deep branch of radial nerve is 2.3 mm^2
  - Superficial branch ascends to subcutaneous tissues

TECHNIQUE: MEDIAL ELBOW

Patient Position

- Seated opposite examiner with extended elbow & forearm externally rotated

Specifically Examine

- **Common flexor tendon origin (CFTO)**
  - Place finger on medial epicondyle, then place transducer along imaginary line of flexor tendons, converging on epicondyle
  - Individual components of CFTO cannot be discriminated

- Pronator teres, flexor carpi radialis longus & brevis, palmaris longus, flexor carpi ulnaris, flexor digitorum superfiicalis
- CFTO is short & forward facing

- **Medial collateral ligament complex**
  - Anterior band is most important & easiest to see
  - Anterior band is best seen with elbow in long axis with elbow in flexion & slight valgus stretch
    - Degree of flexion varies but may be up to full flexion
  - Extends from medial epicondyle to sublime tubercle of ulna slightly anterior to CFTO
- **Cubital tunnel**
  - 2 components to cubital tunnel
    - Proximal portion in retrocondylar groove is most common site of compression
    - Distal portion between ulnar & humeral heads of flexor carpi ulnaris ("cubital tunnel proper")
  - Elbow placed on pad & externally rotated with patient leaning away, enabling transducer access to posteromedial elbow
  - Alternatively, examine cubital tunnel with arm extended over edge of examination table & elbow facing upward
    - Dynamic scanning of tunnel more difficult for this position
  - Transverse imaging of cubital tunnel is preferable
    - Measure cross-sectional area of ulnar nerve
    - Ulnar nerve is usually more hypoechoic within cubital tunnel with increased size by ~ 15% compared to distal arm
    - Normal size of ulnar nerve in cubital tunnel is 8 mm^2
    - Accompanied by recurrent ulnar artery & veins
  - Continue scanning nerve in transverse plane distally through & beyond distal cubital tunnel
  - Dynamic assessment of ulnar nerve movement
    - Lightly place transducer across cubital tunnel while slowly, passively flexing elbow
    - Continual adjustment of transducer position is required to ensure it remains positioned over medial epicondyle
    - See if ulnar nerve subluxes or dislocates ± subluxation of medial head of triceps ("double snap")

TECHNIQUE: LATERAL ELBOW

Patient Position

- Elbow flexed toward examiner with hand pronated
  - Alternatively, both elbows extended with thumbs upward & hands together ("prayer" position)

Specifically Examine

- **Common extensor tendon origin (CETO)**
  - Place finger on lateral epicondyle, then place transducer along imaginary line of extensor tendons, converging on epicondyle
  - Individual components of CETO cannot be discriminated
  - Extensor carpi radialis brevis (ECRB) lies most deeply & inseparable from radial collateral ligament (RCL)
    - ECRB = most commonly torn CETO tendon
  - ECRB, extensor carpi ulnaris, extensor digiti minimi, extensor digitorum (ED); ED is most superficial
  - Examine in longitudinal & transverse planes
    - On longitudinal imaging, normal CETO has straight or slightly concave superficial contour
    - On transverse imaging, CETO has oblong shape over flat area of lateral epicondyle
- **RCL**
  - Best examined in longitudinal plane with transducer angled slightly anterior at anterior edge of CETO tendons
  - Extends from lateral epicondyle to annular ligament overlying radial head
- **Lateral ulnar collateral ligament (LUCL)**
  - For proximal aspect, place transducer on lateral epicondyle of flexed elbow & identify LUCL lateral to radial head
    - Then move probe distally so that proximal end is on radial head & rotate distal end of probes 80-90° to scan lateral aspect of proximal ulna in region of supinator crest
    - Supinator crest = bone ridge along radial aspect of proximal ulna to which supinator muscle is attached
  - For distal portion, scan in transverse plane posterolaterally close to anterolateral corner of anconeus muscle
    - LUCL seen deep to anconeus muscle
- **Synovial fold**
  - Seen on long axis as triangular hyperechoic tissue at posterolateral periphery of radiocapitellar joint
    - Occurs posteriorly (95%), anteriorly (70%), & laterally (15%) at radiocapitellar joint
- **Annular ligament**
  - Seen as belt-like hyperechoic band overlying radial head
  - Passive rotation of forearm during scanning allows differentiation of annular ligament from radial head

TECHNIQUE: POSTERIOR ELBOW

Patient Position

- Elbow flexed toward examiner with palm resting on examination couch ("crawling crab" position)
- Or patient supine with elbow flexed across abdomen
  - This position is easier for right elbow
- Or patient prone with posterior aspect of elbow facing examiner

Specifically Examine

- **Posterior aspect of elbow joint**
  - Posterior fat pad deep to distal part of triceps filling olecranon fossa of distal humerus
  - Mild flexion of elbow joint will encourage fluid into posterior aspect of joint
- **Triceps tendon**
  - Examine in both transverse & longitudinal planes
    - Triceps tendon tends to be located slightly medial to midline
  - On longitudinal imaging, triceps tendons show striations as they widen to their olecranon insertion
    - Lateral & long heads contribute mainly to posterior insertion
    - Medial head is inserted mainly onto ulnar side of olecranon process
  - Normal olecranon bursa cannot be appreciated

Anteromedial Aspect of Elbow

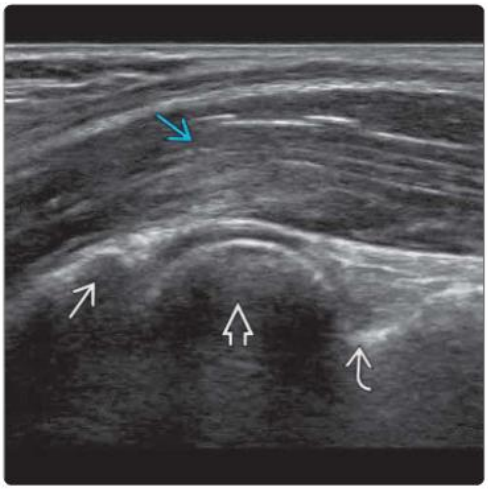

Anterolateral Aspect of Elbow

(Left) *Longitudinal US of the anteromedial aspect of the elbow shows the triangular anterior tip ⇨ of the coronoid process & rounded trochlea process ⇨. The anterior fat pad filling the coronoid fossa ⇨ of the humerus is seen with the brachialis muscle located anteriorly ⇨.* **(Right)** *Longitudinal US in the anterolateral aspect of the elbow shows the square-shaped radial head ⇨ articulating with the rounded capitellum ⇨. Hypoechoic cartilage covers the forward-facing capitellum & the sides of the radial head.*

Annular Ligament

Distal Biceps Tendon: Anterior Approach

(Left) *Longitudinal US in the anterolateral aspect of the elbow shows an echogenic annular ligament ⇨ surrounding the radial head ⇨. There is hypoechoic hyaline cartilage deep to the ligament for articulation at the proximal radioulnar joint. More distally is the supinator muscle ⇨.* **(Right)** *Longitudinal US shows the distal end of the biceps tendon ⇨. The transducer is angled heel to toe to bring it more parallel to the biceps tendon, & the forearm is hypersupinated to bring the radial tuberosity ⇨ forward.*

Scan Position for Biceps Medial Approach

Distal Biceps Tendon

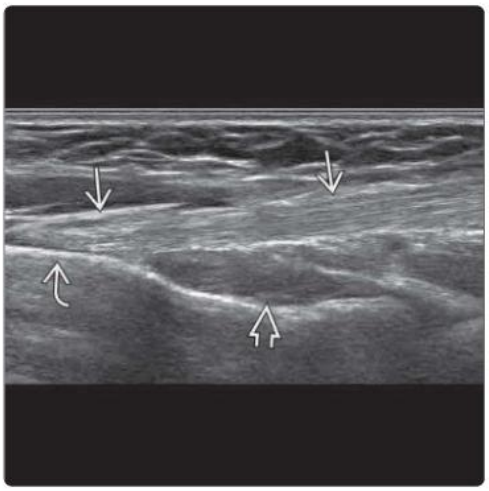

(Left) *Clinical photograph shows the scan position for the distal end of the biceps tendon using a medial approach. The elbow is flexed to about 25°. From a medial approach, identify the radial head & neck. Then, angle the transducer very slightly to bring the biceps tendon into view.* **(Right)** *The medial approach provides the best overall view of the distal biceps tendon ⇨ inserting into the radial tuberosity ⇨. The supinator muscle ⇨ lies just proximal to this insertion.*

(Left) *Clinical photograph shows the scan position for the lateral approach to the distal biceps. This is similar to the flexed abducted supinated (FABS) view described for MR examination with the elbow flexed, the shoulder abducted, & the wrist supinated. The transducer is aligned almost parallel to the humeral shaft & then angulated more laterally.* **(Right)** *Longitudinal US from the lateral approach shows the distal part of the biceps tendon ➡ lying deep to the proximal radius ⇨, supinator ➡, & brachialis ➡ muscles.*

Scan Position for Biceps Lateral Approach

Distal Biceps Tendon: Lateral Approach

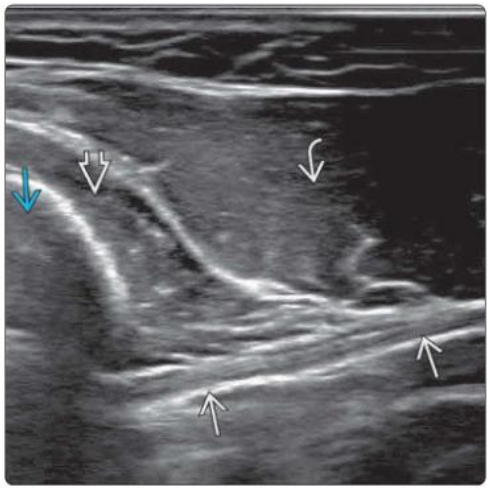

(Left) *Clinical photograph shows the cobra position for examining the radial insertion of the biceps tendon. The transducer is placed over the proximal radius, & the forearm is pronated to bring the distal biceps insertion into view.* **(Right)** *Transverse US shows the biceps tendon insertion ➡ into the radial tuberosity ➡. Distal fibers of the supinator muscle ➡ overlie the insertion. Visibility of the biceps insertion can be further accentuated by mild hyperflexion of the elbow. Proximal ulna & anconeus muscle ⇨ are also seen.*

Scan Position for Biceps Tendon Insertion

Biceps Tendon Insertion: Cobra Position

(Left) *Clinical photograph shows the scan position for the common flexor tendon origin (CFTO). The elbow is slightly flexed & rotated externally. The probe is first placed on the medial epicondyle along the assumed path of the flexor tendons & then, using US, is aligned properly along this path.* **(Right)** *Longitudinal US of the medial epicondyle shows the CFTO ➡. The anterior band of the ulnar collateral ligament (UCL) ➡ is present deep to the CFTO. The ulnar aspect of the ulnohumeral joint is seen ➡.*

Scan Position for Common Flexor Tendon Origin

Common Flexor Tendon Origin

Ulnar Collateral Ligament Complex

Anterior Band of Ulnar Collateral Ligament

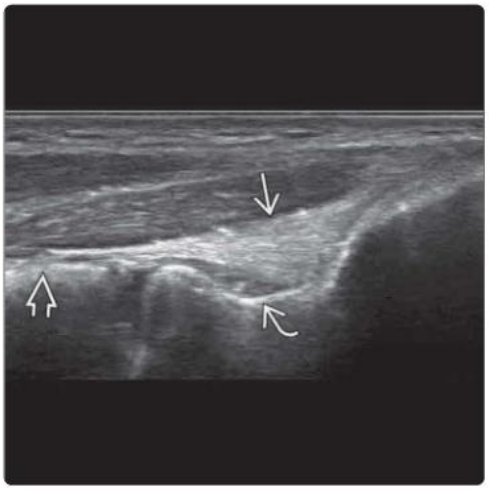

(Left) *Graphic shows the anterior (strongest) ➡, posterior ➡, & transverse (weakest) ➡ bands of the UCL complex.* **(Right)** *Longitudinal US obtained at the anterior edge of the common extensor tendon origin (CETO) in flexion & mild valgus stretch shows the anterior band of the UCL ➡, which passes between the sublime tubercle ➡ of the ulna & the medial epicondyle of the humerus. A small joint recess ➡ is present deep to the ligament.*

Scan Position for Cubital Tunnel

Cubital Tunnel: Proximal Aspect

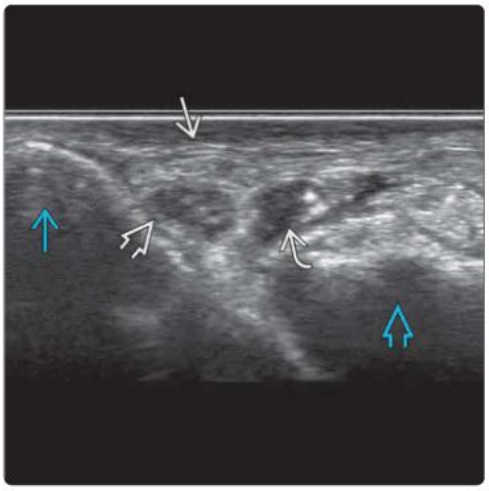

(Left) *Clinical photograph shows the scan position for cubital tunnel. The elbow is externally rotated & placed at the edge of a firm pad. This facilitates transducer access to the cubital fossa as well as dynamic scanning of the ulnar nerve during elbow flexion.* **(Right)** *Transverse US in the posteromedial aspect of the elbow shows the cubital tunnel located between the medial epicondyle ➡ & the olecranon process ➡. The tunnel, which is covered by the Osborne ligament ➡, contains ulnar nerve ➡ & medial belly of triceps muscle slips ➡.*

Cubital Tunnel: Distal Aspect

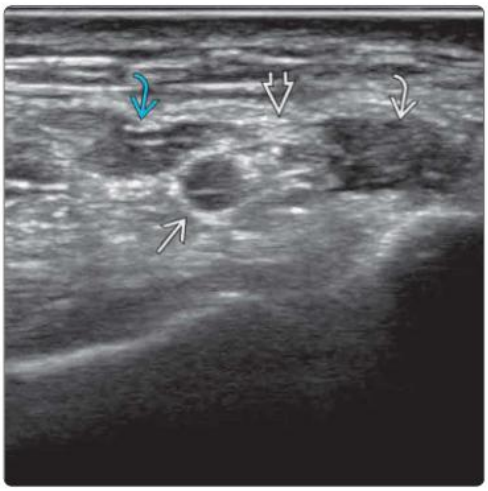

Cubital Tunnel During Elbow Flexion

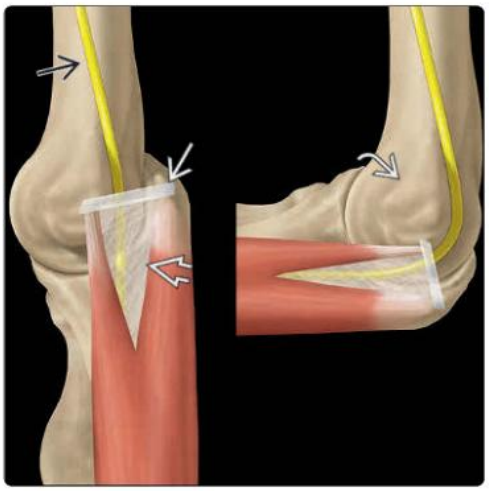

(Left) *Transverse US shows the ulnar nerve ➡ deep to the arcuate ligament ➡ between the humeral ➡ & ulnar ➡ heads of the flexor carpi ulnaris. The ulnar nerve may also be compressed at this location.* **(Right)** *Graphic shows how the Osborne ➡ & the arcuate ➡ ligaments move distally relative to the medial epicondyle ➡ during elbow flexion. The resultant undercoverage of the ulnar nerve ➡ facilitates subluxation/dislocation over the medial epicondyle during elbow flexion.*

(Left) *Clinical photograph shows the scan position for the CETO. The elbow is flexed. The probe is first placed on the lateral epicondyle along the assumed path of the extensor tendons & then, using US, is aligned properly along this path.* **(Right)** *Longitudinal US shows the CETO ➡ attached to the lateral epicondyle ➡. The lateral epicondyle is flatter & more lateral facing than the medial epicondyle. Notice how the superficial contour of the normal CETO is flat or concave.*

Scan Position for Common Extensor Tendon Origin

Common Extensor Tendon Origin: Long Axis

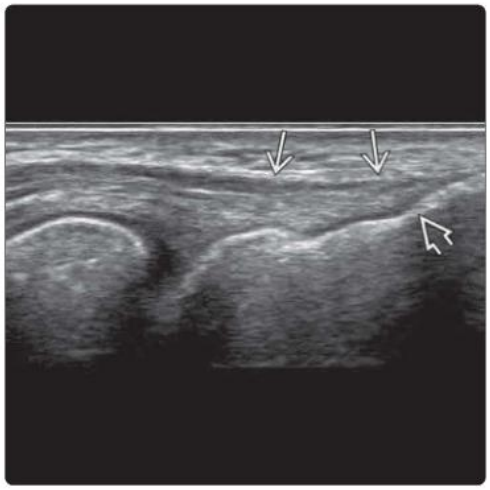

(Left) *Transverse US shows the oblong-type configuration of the CETO ➡ at the lateral epicondyle ➡ immediately proximal to the insertion. Extensor digitorum ➡ & flexor carpi ulnaris muscles ➡ are seen.* **(Right)** *Graphic shows the radial collateral ligament (RCL) complex. This is composed of the RCL ➡, which inserts into the annular ligament ➡, & the lateral UCL (LUCL) ➡, which inserts into the supinator crest of the proximal ulna.*

Common Extensor Tendon Origin: Short Axis

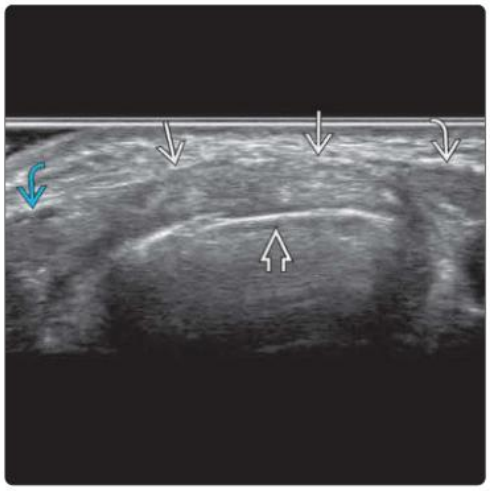

Radial Collateral Ligament Complex

(Left) *Longitudinal US shows the RCL ➡ passing to the annular ligament ➡. The RCL fibers are deep to & barely separable from the CETO fibers ➡. The deeper 1/3 of the CETO/RCL complex fibers comprise the RCL. A radiocapitellar synovial flange ➡ is present.* **(Right)** *Transverse US in the posterolateral aspect of the elbow shows the mid- to distal portion of the LUCL ➡ inserting into supinator crest of proximal ulna ➡. Anconeus muscle ➡ is superficial to the ligament, while the radial head ➡ is deep.*

Radial Collateral Ligament

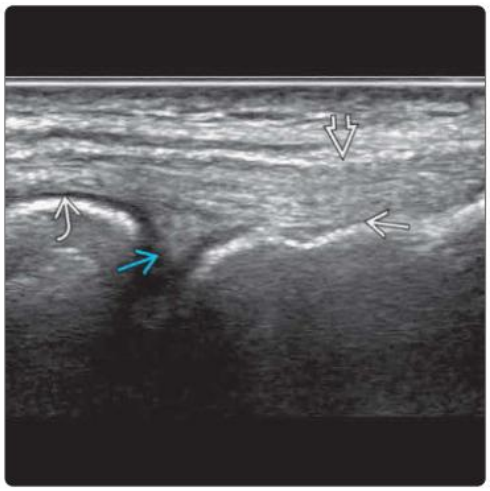

Lateral Ulnar Collateral Ligament

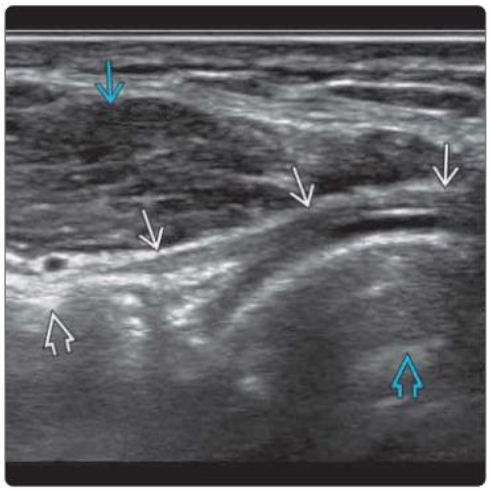

Radial Tunnel: Short Axis

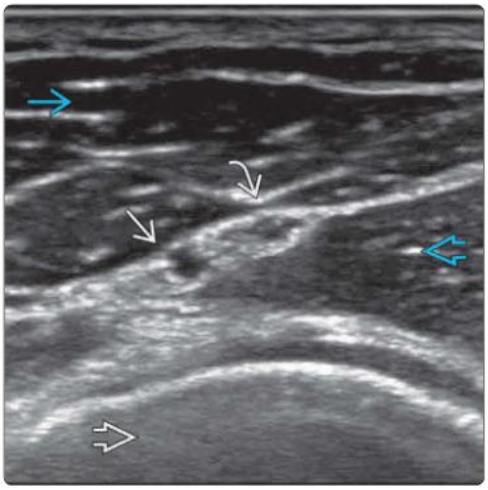

Supinator Tunnel: Short Axis

(Left) *Transverse US of the anterolateral elbow shows the radial tunnel with the radial nerve having divided into its deep ➡ & superficial ➡ branches just superficial to the radial head ➡. The nerves lie between the brachioradialis ➡ & the brachialis ➡ muscles.* **(Right)** *Transverse US in the anterolateral aspect of the elbow shows the inlet to the supinator tunnel with the deep branch of the radial nerve, now known as the posterior interosseous nerve ➡, between the superficial ➡ & deep fibers ➡ of the supinator muscle.*

Scan Position for Posterior Elbow

Olecranon Recess

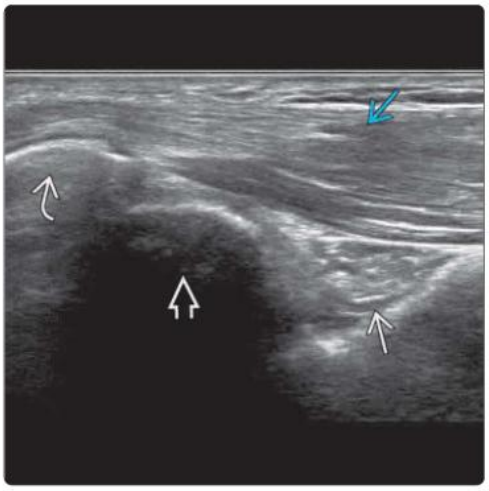

(Left) *Clinical photograph shows the "crawling crab" position used to examine the posterior aspect of the elbow.* **(Right)** *Longitudinal US along the posterior aspect of the elbow joint shows the posterior fat pad filling the olecranon recess ➡ of the distal humerus. The trochlea ➡, olecranon process ➡, & triceps ➡ are also visible. The fat pad is intraarticular but extrasynovial. An effusion will displace the fat pad posteriorly.*

Longitudinal Triceps Tendon Insertion

Transverse Triceps Tendon

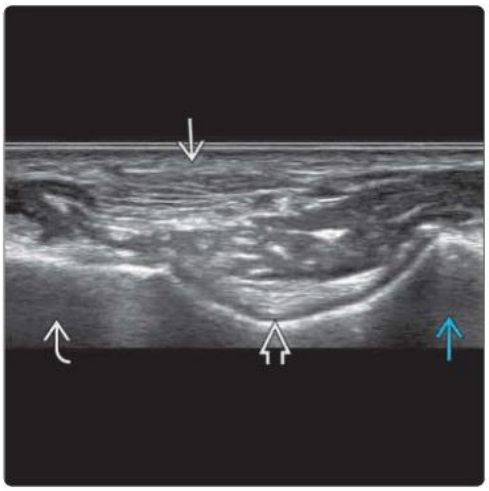

(Left) *Longitudinal US in the posterior aspect of the elbow shows the triceps tendon ➡ inserting onto the olecranon process ➡. The long & lateral heads of the triceps muscles insert into the posterior aspect of the olecranon process 1.1 cm from the tip. The medial belly insertion is more muscular & into the medial aspect of the olecranon process.* **(Right)** *Transverse US in the posterior aspect of the elbow shows the triceps tendon ➡. This is overlying the capitellum ➡, posterior fat pad ➡, & trochlea ➡.*

KEY FACTS

GENERAL CONSIDERATIONS

- Common specific indications are suspected ganglia, joint effusion, synovitis, septic arthritis, tendon disorders, carpal tunnel syndrome
- Less common specific indications are Guyon canal syndrome, scaphoid & other fractures, other neural pathology, & wrist ligaments

TECHNIQUE

- **Dorsal wrist**
  - Patient seated across examiner with wrist resting prone on adjustable table
  - ± small pad under hypothenar eminence to align wrist & carpus in more horizontal position
  - Wrist in lateral position ± ulnar deviation to scan scaphoid/1st extensor compartment
  - Wrist in lateral position ± radial deviation to scan ulnocarpal articulation/6th extensor compartment
    - Dorsal wrist joint
    - 1st extensor compartment (abductor pollicis longus & extensor pollicis brevis)
    - 2nd extensor compartment (extensor carpi radialis longus & extensor carpi radialis brevis)
    - 3rd extensor compartment (extensor pollicis longus)
    - 4th (extensor digitorum, extensor indicis proprius) & 5th (extensor digiti minimi) extensor compartments
    - 6th extensor compartment (extensor carpi ulnaris)
    - Posterior interosseous nerve
    - Dorsal ulnar cutaneous nerve
- **Volar wrist**
  - Patient seated across examiner with wrist resting supine on adjustable table
  - ± scan in wrist flexion to see insertion of flexor carpi radialis tendon
    - Volar wrist joint, tendons outside carpal tunnel, median nerve & carpal tunnel, ulnar nerve & Guyon tunnel, superficial radial nerve, palmar ulnar cutaneous nerve

Scan Position for Dorsal Wrist

Dorsal Wrist Midline

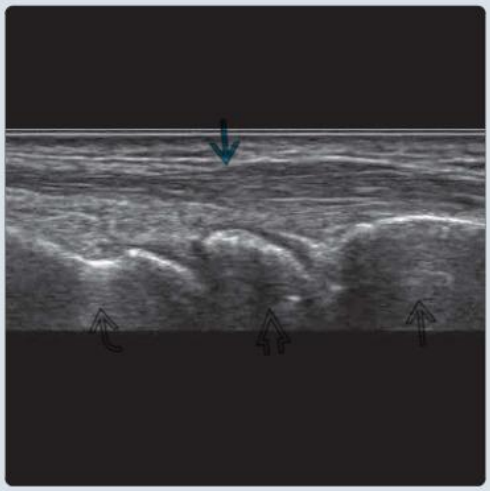

(Left) *Clinical photograph shows the scan position for the dorsal wrist. A small pad ⇨ can be placed under the ulnar aspect of the wrist to align the dorsal wrist more horizontally.* **(Right)** *Longitudinal US shows the distal radius ⇨, lunate ⇨, & capitate ⇨ all aligned. The soft tissue interposed between the carpus & extensor digitorum tendon ⇨ is composed of joint synovium, extrinsic ligaments, & loose areolar tissue. These individual elements cannot be discerned.*

Dorsal Wrist Scaphoid

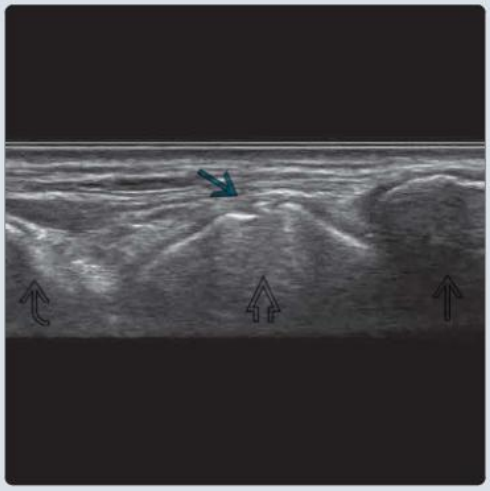

MR of Proximal Wrist

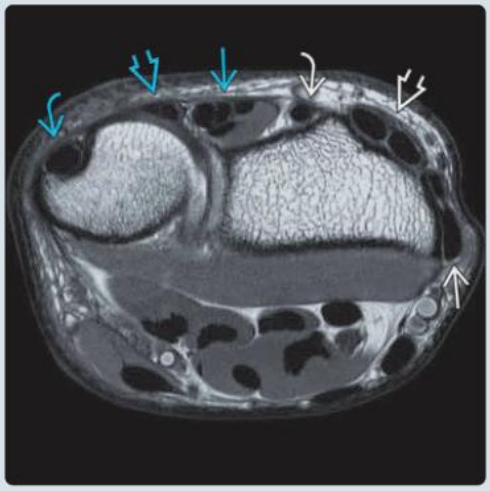

(Left) *Longitudinal US shows the distal radius ⇨, scaphoid ⇨, & trapezoid ⇨ all aligned. The bony irregularity ⇨ on the dorsum of the scaphoid is normal. Such irregularity of normal bone contour does somewhat limit US assessment of a carpal fracture.* **(Right)** *Axial intermediate-weighted MR of the wrist at the level of the distal radioulnar joint shows the 1st ⇨, 2nd ⇨, 3rd ⇨, 4th ⇨, 5th ⇨, & 6th ⇨ extensor compartments.*

GENERAL CONSIDERATIONS

Clinical Indications for Wrist US

- US is best investigation for suspected joint effusion/synovitis & all nonarticular pathology
- Common specific indications are suspected ganglia, joint effusion, synovitis, septic arthritis, tendon disorders, & carpal tunnel syndrome (CTS)
- Less common specific indications are Guyon canal syndrome, scaphoid & other fractures, other neural pathology, & wrist ligaments
- As wrist symptoms are usually well localized, exam can usually be targeted to symptomatic area
- Very different causes of radial-sided, central, & ulnar-sided wrist pain exist

TECHNIQUE: DORSAL WRIST

Patient Position

- Patient seated across examiner with pronated wrist resting on adjustable table
  - ± small pad under hypothenar eminence to align wrist & carpus in more horizontal position
- Place wrist in lateral position ± ulnar deviation to examine scaphoid/1st extensor compartment
- Place wrist in lateral position ± radial deviation to examine ulnocarpal articulation/6th extensor compartment

Specifically Examine

- **Dorsal wrist joint**
  - Composed of 3 distinct compartments
    - Distal radioulnar joint (DRUJ), radiocarpal & ulnocarpal joints, midcarpal joint
  - All 3 joints are best viewed using dorsal approach, as joints are more superficial
  - Scan transversely over distal radius/ulna to view DRUJ
    - Located deep to 5th extensor compartment tendon
    - Mild passive pronation & supination helps assessment of DRUJ content
  - Rotate transducer into longitudinal plane to view radiocarpal/ulnocarpal & midcarpal joints
    - Echogenic lip of distal radius & rounded proximal contours of lunate & capitate longitudinally aligned provides good starting landmark
    - Then, identify other wrist bones by scanning from landmark in both longitudinal or transverse planes
  - Note joint distention, hypoechoic/hyperechoic synovial proliferation, & joint fluid deep to echogenic capsule
  - Color Doppler imaging & especially, to lesser degree, compression can help differentiate fluid from synovitis
    - For hyperemia, optimize settings, use minimal transducer pressure, & record as mild, moderate, severe
- **Dorsal wrist tendons**
  - Best scanned primarily in transverse plane moving along length of tendon
  - Lister tubercle on dorsal aspect of distal radius is useful landmark
- **1st extensor compartment [abductor pollicis longus (APL) & extensor pollicis brevis (EPB)]**
  - Place ulnar border of wrist on table ± resting on pad used to help ulnar deviate wrist
  - Note larger APL & smaller EPB
  - Both tendons rest on shallow groove in radial styloid covered by echogenic extensor retinaculum (< 0.5 mm thick)
  - 1/3 of wrists have septum (90% complete, 10% partial) between APL & EPB
    - This septum is always associated with intervening osseous ridge on underlying radial styloid process
    - Therefore, osseous ridge provides good clue as to likelihood of 1st extensor compartment septum
  - 95% of APL tendons have multiple slips, while < 5% of EPB tendons have > 1 slip
    - EPB may occasionally (5%) be absent & replaced with ligamentous structure
  - Superficial radial nerve branches pass over (or under) 1st extensor compartment from volar to dorsal wrist
- **2nd extensor compartment (extensor carpi radialis longus & extensor carpi radialis brevis)**
  - Isolated pathology of this compartment uncommon
  - Just proximal to wrist, 1st compartment tendons pass superficial to 2nd compartment tendons (intersection syndrome)
  - Dorsal scapholunate ligament seen deep to 2nd compartment tendons
    - Side-to-side discrepancy in scapholunate joint space should not be > 2 mm
- **3rd extensor compartment [extensor pollicis longus (EPL)]**
  - EPL uses Lister tubercle as pulley
  - Passes over 2nd extensor compartment tendons (distal intersection) to reach base of distal phalanx of thumb
  - Follow in transverse plane, rotating transducer to ensure it is maintained at right angles to tendon
- **4th [extensor digitorum (ED), extensor indicis proprius (EIP)] & 5th [extensor digiti minimi (EDM)] extensor compartments**
  - 4th compartment contains 4 ED tendons (1 for each finger) & EIP tendon
  - 4th compartment of extensor retinaculum is thickest
  - Passive finger movement can help identify tendons
  - 5th extensor compartment is fibrous rather than fibroosseous & overlies DRUJ
  - Visibility of small EDM can be improved by moving little finger; EDM typically joins ED tendon just proximal to metacarpophalangeal joint
- **6th extensor compartment [extensor carpi ulnaris (ECU)]**
  - Best examined with wrist fully pronated & ulna facing up
  - Observe ECU within groove on ulnar head covered by fibrous retinaculum (ECU subsheath)
    - ECU is only extensor tendon with its own retinaculum, serving to keep ECU in its groove
  - For dynamic assessment of ECU, flex elbow with ulnar head facing examiner
    - Use light transducer pressure over ulnar groove
    - First, supinate forearm, & then allow wrist to drop passively into flexion & ulnar deviation
    - % of ECU displacement from ulnar groove: < 50% = normal; > 50% = subluxation; 100% = dislocation
    - If abnormal, compare with opposite side to exclude physiologic laxity of subsheath
- **Posterior interosseous nerve**

- Sensorimotor branch of radial nerve; average size on US is 1.5 mm²
  - Located deep to radial aspect of 4th extensor compartment at distal radius
    - Enlarges to form small "pseudoganglion" before dividing into its terminal branches
- **Dorsal ulnar cutaneous nerve**
  - Superficial sensory nerve; average size on US is 0.3 mm²
  - Arises from ulnar side of ulnar nerve (UN) 5-6 cm proximal to ulnar styloid process
  - Passes close to ulnar styloid when extending from radial to dorsal aspect of wrist
    - Innervates mediodorsal hand & ulnar 1.5 digits

TECHNIQUE: VOLAR WRIST

Patient Position

- Patient seated across examiner with supinated wrist resting on adjustable table
- ± scan in wrist flexion to see insertion of flexor carpi radialis (FCR) tendon

Specifically Examine

- **Volar wrist joint**: Best scanned in longitudinal plane, noting distal radius, ulna, & bones of proximal carpal row
- **Tendons outside carpal tunnel**
  - Scan in transverse plane over distal radius & ulna, noting pronator quadratus, flexor tendons, & radial/ulnar arteries
  - FCR → 2nd metacarpal base
  - FCR has its own synovial sheath & runs in separate fibroosseous tunnel covered by extension of transverse carpal ligament
    - Floor of FCR tunnel is distal scaphoid, trapezium, & trapezoid
    - Angle probe & flex wrist to best see distal part of FCR
  - Flexor carpi ulnaris (FCU) → pisiform
    - Some fibers continue to hook of hamate (as pisohamate ligament) & 4th metacarpal base (as pisometacarpal ligament)
    - FCU has no tendon sheath
- **Median nerve (MN) & carpal tunnel**
  - MN best scanned in transverse section from midforearm through carpal tunnel
  - In distal forearm, MN becomes more superficial & is located in midline
    - Palmar cutaneous nerve is small (0.5-0.7 mm²) branch of MN seen in 80% of wrists with high-resolution US
    - Arises from MN at point where it crosses between FCR & radial border of flexor digitorum superficialis muscle, 5 cm proximal to wrist
      - Remains closely bound to MN for first 2 cm before traveling between palmaris longus & FCR
  - Just proximal to wrist crease, MN lies in more superficial position over deep flexors & deep to palmaris longus
  - MN then dips down to enter carpal tunnel by passing below transverse carpal ligament
    - Recognition of leading edge of transverse carpal ligament is best way to recognize tunnel inlet
  - Carpal tunnel contains 4 pairs of tendons (1 for each finger), 1 unpaired tendon for thumb [flexor pollicis longus (FPL)], & MN
    - FPL has its own tendon sheath (radial bursa)
    - Finger flexor tendons encased by 3 layers of synovium in "E" shape (ulnar bursa)
  - MN normally flatter, more hypoechoic, & more difficult to see at narrower tunnel outlet
  - MN then rises on exiting carpal tunnel & quickly divides into its digital branches
    - Recognition of trailing edge of transverse carpal ligament is best way to recognize tunnel inlet
  - Measure MN cross-sectional area (CSA) of distal forearm, proximal to tunnel, at tunnel inlet, at tunnel outlet, & just distal to tunnel
  - Check hyperemia at most swollen level
  - Bifid MN seen in 20% of population & usually, but not always, accompanied by persistent median artery
    - In this case, measure CSA of both components & summate, applying usual diagnostic criteria for CTS
    - Report presence of persistent median artery, as it may be injured during arthroscopic release of transverse carpal ligament
- **UN & Guyon tunnel**
  - UN best scanned in transverse section from midforearm to Guyon tunnel
    - UN located on medial aspect of distal forearm between FCR & ulnar artery
    - Guyon canal contains UN, ulnar artery, & accompanying veins ± abductor digiti minimi muscle slips
  - At distal end of Guyon canal beyond pisiform, UN divides into superficial sensory branch & deep motor branch
    - Superficial sensory branch runs with ulnar artery over hook of hamate
    - Deep motor branch courses alongside outer margin of hook of hamate
- **Superficial radial nerve**
  - Superficial sensory nerve; average size on US is 3.9 mm²
  - Prone to iatrogenic injury at wrist in vascular cannulation & fracture fixation
  - Superficial radial nerve divides into 2-3 branches 4.5-6.0 cm proximal to radial styloid tip
    - In 90% of subjects, superficial radial branch passes dorsal to 1st extensor compartment when traveling from volar to dorsal aspect of waist & hand
      - Provides sensory innervation to skin on dorsal aspect of thumb & dorsoradial sides of hand & fingers
    - In smaller percentage, superficial radial branch passes dorsal to 1st extensor compartment when traveling from volar to dorsal aspect of waist & hand
- **Palmar ulnar cutaneous nerve**
  - Superficial sensory nerve; average size on US is 0.3 mm²
  - Arises from UN radially in midforearm & travels distally deep to FCU
    - Innervates skin of hypothenar eminence
- **Lateral antebrachial cutaneous nerve**
  - Terminal branch of musculocutaneous nerve; another nerve that can be potentially injured at wrist
  - Difficult to see on US of wrist, as at this level, nerve is very small, almost intradermal, & quite variable in position

1st Extensor Compartment

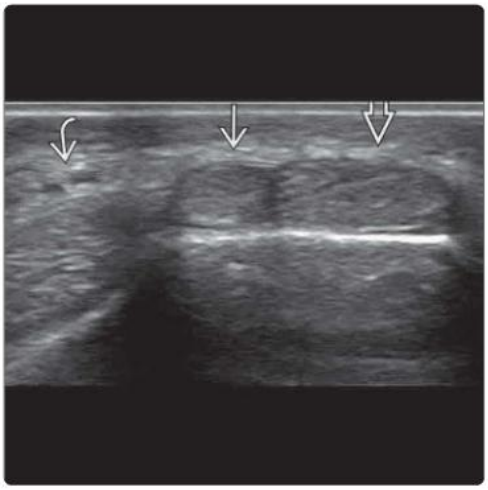

2nd Extensor Compartment

(Left) *Transverse US of the 1st extensor compartment shows smaller extensor pollicis brevis (EPL) alongside larger abductor pollicis longus. There is no intervening septum. A thin extensor retinaculum overlies the tendons. The lateral branch of the superficial radial nerve passes dorsal to the 1st extensor compartment.* **(Right)** *Transverse US shows 2nd extensor compartment. EPL is passing over flexor carpi radialis brevis tendon, which is closely apposed to the extensor carpi radialis longus tendon.*

3rd Extensor Compartment

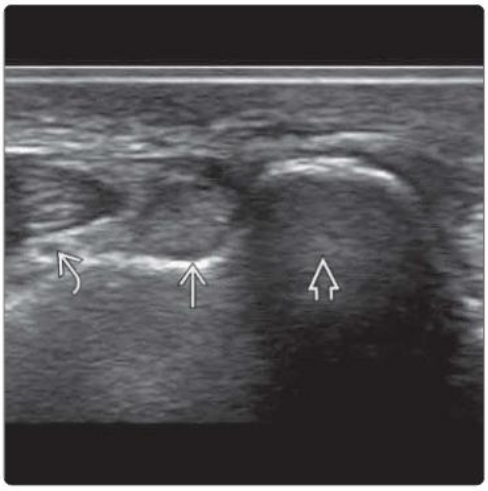

4th Extensor Compartment

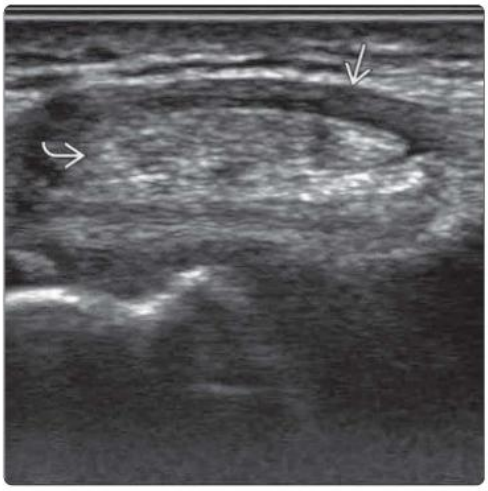

(Left) *Transverse US of the 3rd extensor compartment shows the EPL tendon lying alongside the Lister tubercle. This tubercle acts as a pulley for the EPL. Tears of the EPL at this location are quite common. The posterior interosseous nerve lies nearby.* **(Right)** *Transverse US of the 4th extensor compartment shows the closely packed extensor digitorum tendons lying deep to the extensor retinaculum. This extensor retinaculum is thickest over the extensor digitorum tendons.*

5th Extensor Compartment

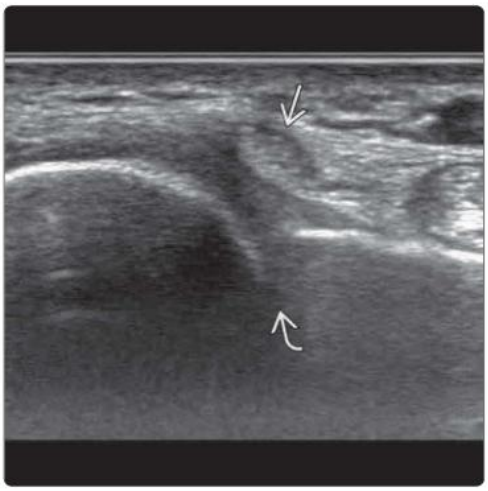

6th Extensor Compartment

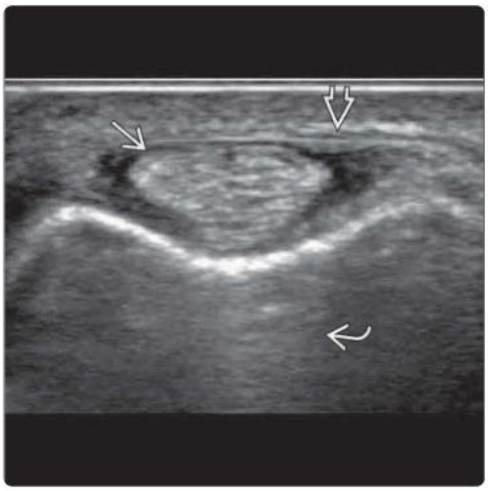

(Left) *Transverse US shows the 5th extensor compartment tendon (extensor digiti minimi), lying on the dorsal aspect of the distal radioulnar joint. The 5th compartment is a purely fibrous compartment that is not in direct contact with the underlying bone.* **(Right)** *Transverse US of the 6th extensor compartment shows the extensor carpi ulnaris (ECU) tendon lying within a groove on the dorsoulnar aspect of the ulnar head. The ECU has its own restraining subsheath in addition to the extensor retinaculum.*

(Left) *Clinical photograph during US assessment for ECU subluxation from the ulnar groove of the ulnar head is shown. The ECU will tend to sublux most when the wrist is supinated, flexed, & ulnar deviated.* **(Right)** *Transverse US during dynamic testing of ECU stability shows slight movement of the ECU toward the side of the ulnar groove ⇗. This degree of laxity is normal. The hypoechoic line ⇒ within the ECU is also normal, representing physiologic splitting of the more distal ECU fibers.*

Extensor Carpi Ulnaris Subluxation Test

Dynamic Testing of Extensor Carpi Ulnaris

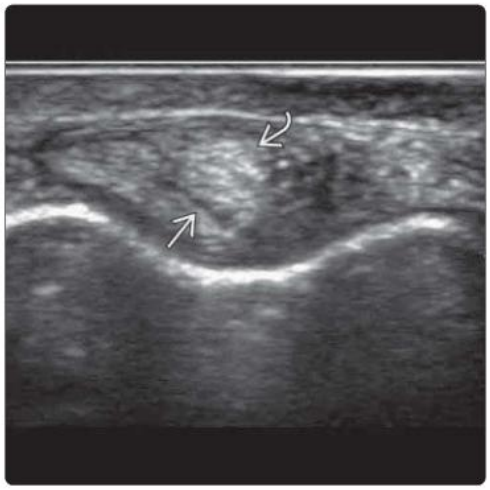

(Left) *Transverse US of the wrist just beyond the radiocarpal joint shows the diverging extensor digitorum tendons ⇒ on the dorsum of the carpus. Deep to the extensor tendons is a dorsal extrinsic ligament ⇒.* **(Right)** *Transverse US shows the dorsal component of the strong intrinsic scapholunate ligament ⇒ traversing between the dorsal aspects of the scaphoid ⇗ & lunate ⇒. The volar component of the scapholunate ligament is less readily appreciated on the volar aspect of the wrist.*

Extensor Digitorum Tendons

Dorsal Scapholunate Ligament

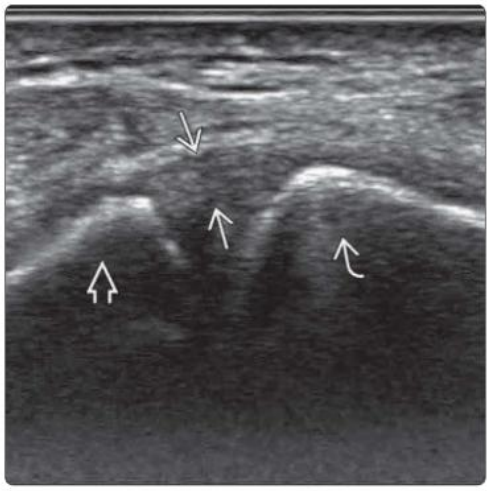

(Left) *Axial intermediate-weighted MR of the proximal carpal tunnel shows the transverse ligament ⇒ covering the carpal tunnel. The carpal tunnel contains 9 tendons (4 paired tendons for each finger & 1 tendon to the thumb) as well as the median nerve ⇗.* **(Right)** *Clinical photograph shows the scan position for the volar wrist. The wrist should be horizontal & neither flexed nor extended.*

MR of Carpal Tunnel

Scan Position for Volar Wrist

Volar Aspect of Carpus

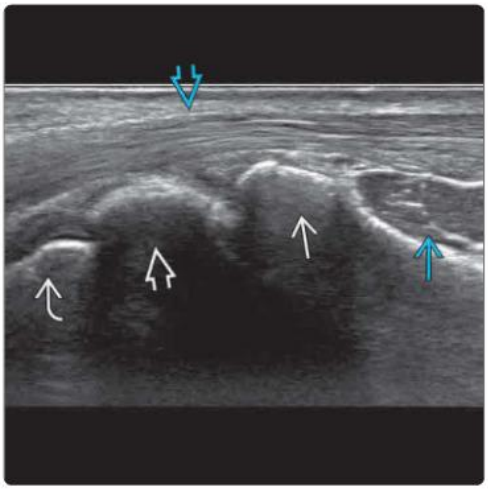

Volar Aspect of Radial Side of Wrist

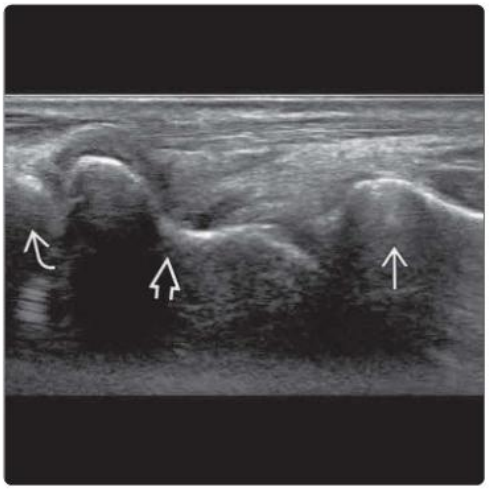

(Left) *Longitudinal US shows the volar aspect of the carpus in the midline with the distal radius ➡, lunate ➡, & capitate ➡ all aligned. The pronator quadratus muscle ⇨ is visible proximally. The flexor tendons ⇨ lie superficially.* **(Right)** *Longitudinal US shows the volar aspect of the radial side of the wrist with distal radius ➡, scaphoid ➡, & trapezoid ➡ aligned. The wrist has been ulnar deviated to show more of the volar surface of the scaphoid. US is commonly used to diagnose scaphoid fractures.*

Flexor Carpi Radialis of Neutral Wrist

Flexor Carpi Radialis of Flexed Wrist

(Left) *Longitudinal US with the wrist in a neutral position shows the hypoechoic appearance of the normal flexor carpi radialis tendon ➡ due to anisotropy as it descends ➡ to the base of the 2nd metatarsal.* **(Right)** *Longitudinal US with the wrist in a flexed position shows how the distal end ➡ of the normal flexor carpi radialis tendon ➡ can be more readily appreciated than when the wrist is in a neutral position.*

Flexor Carpi Ulnaris Tendon

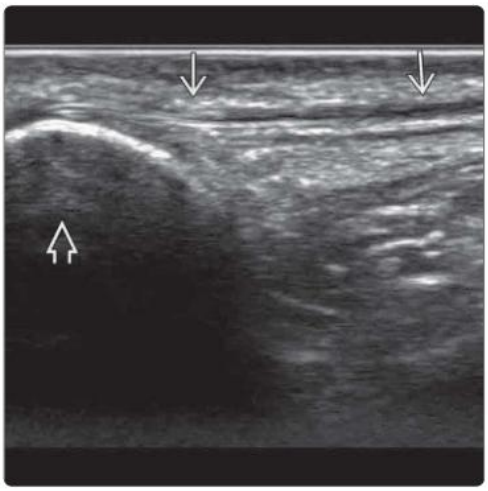

Ulnocarpal Articulation

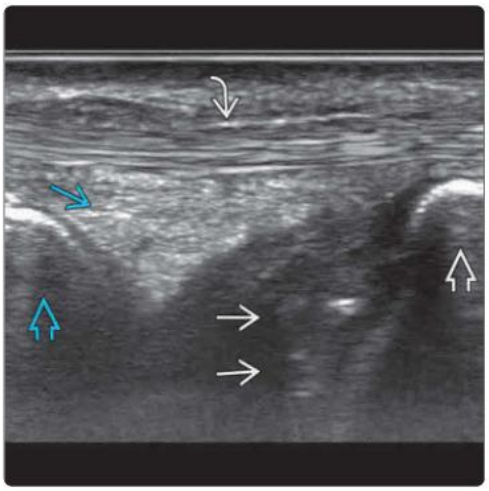

(Left) *Longitudinal US shows flexor carpi ulnaris (FCU) tendon ➡ inserted into the volar aspect of the pisiform bone ➡. Some FCU fibers continue as the restraining ligaments of the pisiform bone. FCU tendon does not have a tendon sheath.* **(Right)** *Longitudinal US of the ulnar aspect of the wrist joint shows the ulnar head ➡, ECU tendon ➡, meniscal homologue ⇨, & triquetrum ⇨. Articular disc ➡ of triangular fibrocartilaginous complex (TFCC) is barely discernible. TFCC injury is best imaged by MR.*

(Left) *Transverse US shows the median nerve ➡ alongside the flexor digitorum superficialis muscles & tendons ➡ on the volar aspect of the distal forearm. The flexor digitorum ➡ & pronator quadratus muscle ➡ lie deep to the nerve.* **(Right)** *Transverse US shows the median nerve ➡ just proximal to the tunnel inlet. The median nerve at this level is covered by the thin antebrachial fascia ➡, which is normally slightly thickened just proximal to the tunnel inlet. This should not be mistaken for the transverse carpal ligament.*

Median Nerve of Distal Forearm

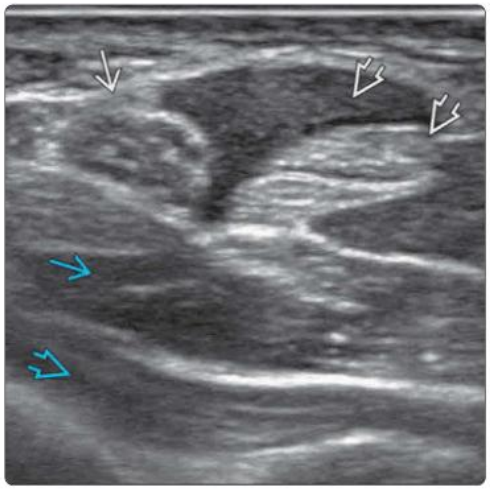

Median Nerve Proximal to Tunnel Inlet

(Left) *Transverse US shows the median nerve ➡ at the tunnel inlet just deep to the thick transverse carpal ligament ➡. The median nerve dives deep to enter the carpal tunnel inlet. The flexor tendons ➡ are crowded together within the carpal tunnel.* **(Right)** *Transverse US at the tunnel outlet shows the normally more flattened median nerve ➡ just deep to the thick distal edge of the transverse carpal ligament ➡.*

Median Nerve at Tunnel Inlet

Median Nerve at Tunnel Outlet

(Left) *Transverse US just distal to the tunnel outlet shows the median nerve dividing into its digital branches ➡. This branching usually occurs immediately distal to the tunnel outlet. Part of the thenar muscle is seen ➡. The diverging flexor tendons ➡ lie deep to the digital nerves.* **(Right)** *Longitudinal US shows median nerve ➡ passing deep to transverse carpal ligament ➡. Flexor tendons ➡ lie mainly deep to the nerve. The coarse fibrillar pattern of the nerve compared to the fine fibrillar pattern of the tendons can be appreciated.*

Distal to Carpal Tunnel

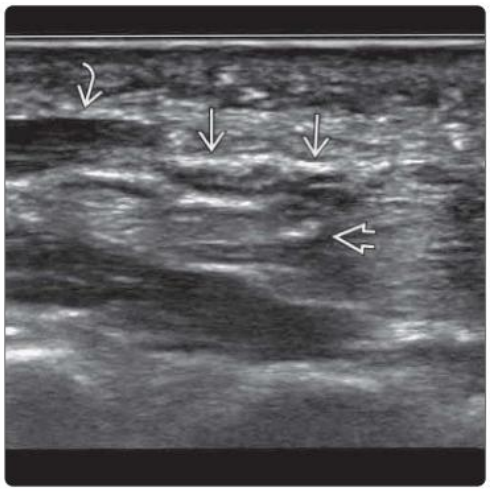

Median Nerve to Carpal Tunnel: Long Axis

Bifid Median Nerve

Ulnar Nerve & Palmar Ulnar Cutaneous Nerve

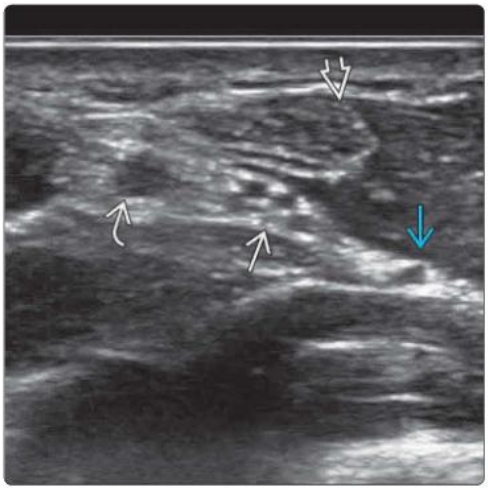

(Left) *Transverse US just proximal to the carpal tunnel shows the bifid median nerve with several vessels comprising arteries & veins separating both median nerve bundles.* **(Right)** *Transverse US at the distal forearm levels shows the ulnar nerve alongside the ulnar artery deep to the FCU tendon & muscle. The palmar ulnar cutaneous nerve has just branched off the parent ulnar nerve & will travel to the hand deep to the FCU.*

Proximal Aspect of Guyon Canal

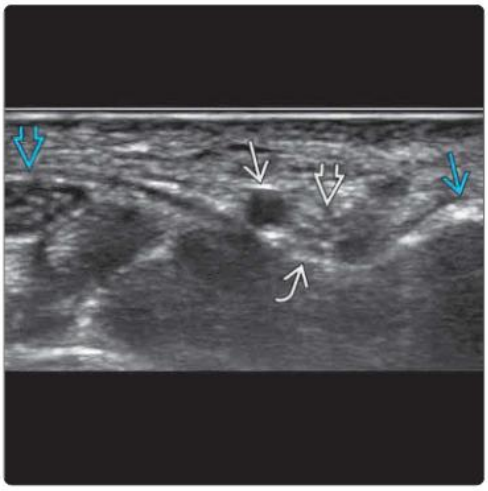

Proximal Aspect of Guyon Canal MR

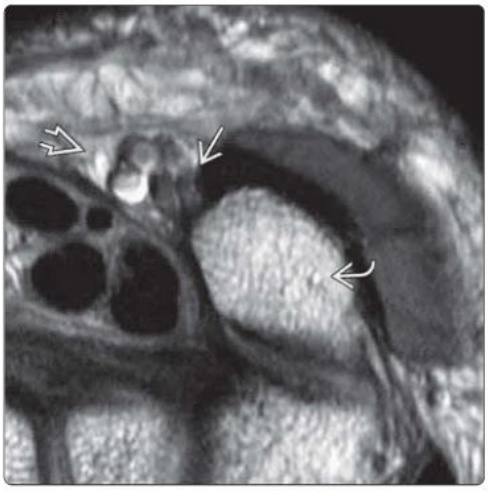

(Left) *Transverse US shows the ulnar artery & the ulnar nerve at the proximal end of the Guyon canal alongside the pisiform bone. The transverse carpal ligament lies deep to the canal. The median nerve within the carpal tunnel is seen.* **(Right)** *Axial PD MR shows proximal end of the Guyon canal alongside pisiform bone. The ulnar nerve is on the ulnar side of the ulnar artery. Note how thin the palmar carpal ligament is for the roof of Guyon canal compared to the thicker transverse carpal ligament deeply.*

Distal Aspect of Guyon Canal

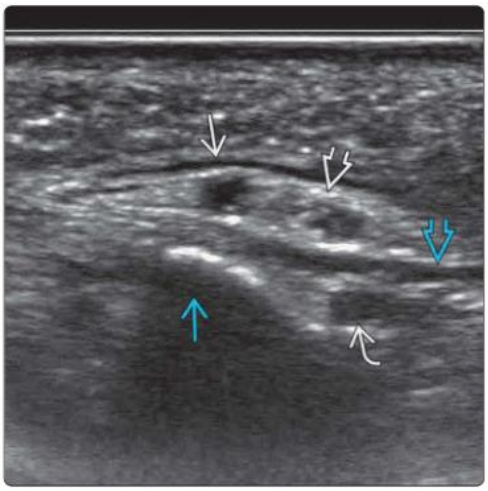

Distal Aspect of Guyon Canal MR

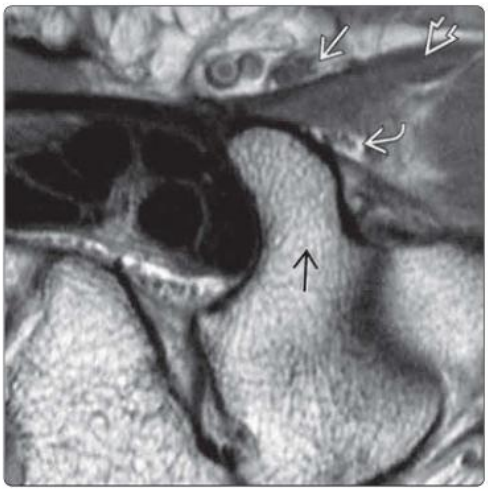

(Left) *Transverse US shows the ulnar artery & superficial & deep branches of the ulnar nerve at the distal end of the Guyon canal alongside the hook of hamate. These nerves are separated by a flexor digiti minimi muscle slip.* **(Right)** *Axial PD MR shows the distal end of the Guyon canal alongside the hook of hamate. The superficial & deep branches of the ulnar nerve are separated by the flexor digiti minimi muscle slip.*

KEY FACTS

GENERAL CONSIDERATIONS

- Common specific indications: Tenosynovitis, tendinosis, trigger finger, tendon rupture, & other tendon disorders, joint inflammation, & ulnar collateral ligament (UCL) injury
- Left common specific indications: 1st carpometacarpal joint osteoarthritis, sagittal band injury, pulley rupture, specific small tumors of hand, tendon xanthoma

TECHNIQUE: DORSAL HAND

- Palm flat on examination table or couch with wrist in neutral position, fingers relaxed
  - Extensor tendons of fingers: To assess sagittal band integrity, scan dorsal hood at metacarpophalangeal (MCP) joint during flexion & extension
  - Extensor tendon of thumb
  - UCL of MCP joint of thumb
    - Scan in longitudinal plane
    - Flexion at interphalangeal (IP) joint will help identification of adductor aponeurosis
    - Careful thumb abduction during scanning will stress UCL & widen ulnar aspect of MCP joint

TECHNIQUE: VOLAR HAND

- Dorsum of hand flat on examination table or couch with wrist in neutral position, fingers extended
  - Flexor tendon pulleys of fingers
    - Passively flex & extend of finger while observing movement of flexor tendons deep to pulley
    - For bowstringing, examine finger in resting extended position & during forced flexion
  - Flexor tendon pulleys of thumb
  - Flexor tendons of fingers
  - Flexor tendon of thumb
  - MCP & IP joints
    - Collateral ligaments on radial & ulnar sides, examine in flexion & extension
  - Carpometacarpal joint of thumb

Extensor Digitorum Tendons

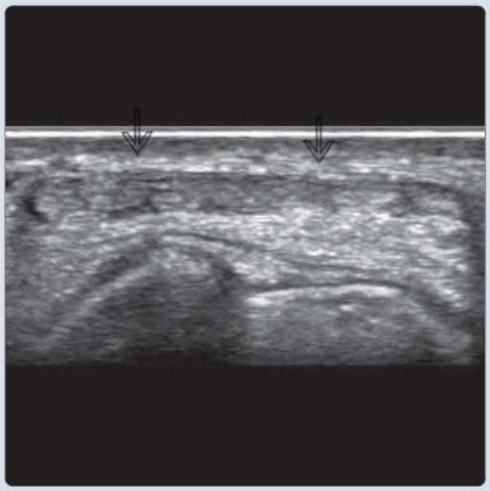

Extensor Digitorum Tendons

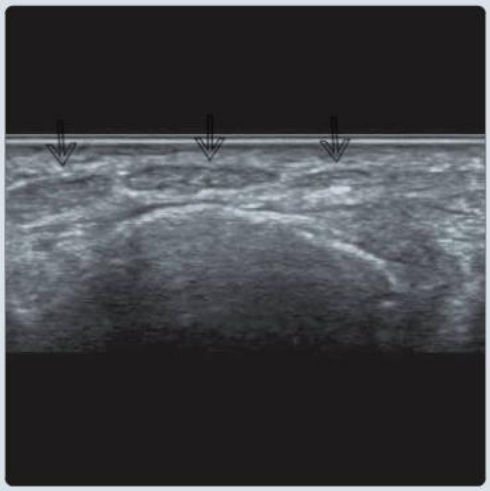

(Left) *Transverse US shows the tightly packed extensor digitorum tendons ⇨ on the dorsum of the carpus.* **(Right)** *Transverse US of the dorsal aspect of the metacarpal bones shows the extensor digitorum tendons ⇨ diverging to the individual fingers. Each tendon should be followed individually in the transverse plane initially.*

Extensor Tendons of Fingers

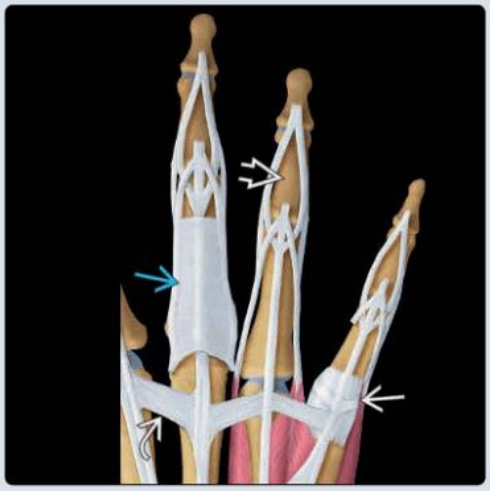

Sagittal Bands: Short Axis

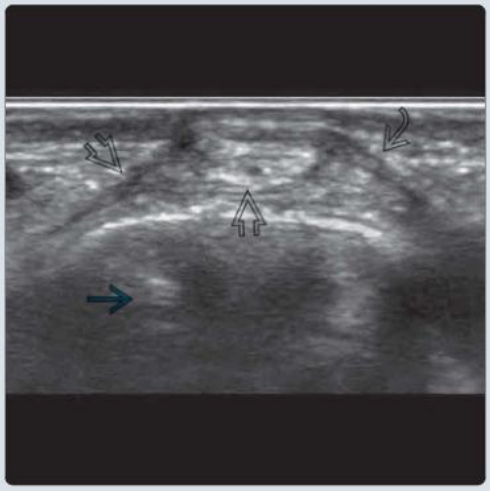

(Left) *Graphic shows the arrangement of the extensor tendons on dorsum of fingers. Note radial & ulnar sagittal bands ⇨, deep transverse metacarpal ligaments ⇨, extensor hood ⇨, & absence of central extensor tendon on proximal aspect of the middle phalanx ⇨.* **(Right)** *Transverse US of the dorsum of the metacarpal head ⇨ of middle finger shows radial ⇨ & ulnar ⇨ sagittal bands overlying extensor tendon. The sagittal bands attach to the volar plates on palmar aspects of the metacarpophalangeal (MCP) joints.*

GENERAL CONSIDERATIONS

Clinical Indications for Hand US

- US is excellent modality for assessing all suspected soft tissue & joint abnormalities of hand
- Common specific indications: Tenosynovitis, tendinosis, trigger finger, tendon rupture, & other tendon disorders, joint inflammation, & ulnar collateral ligament (UCL) injury
- Left common specific indications: 1st carpometacarpal joint osteoarthritis, sagittal band injury, pulley rupture, small tumors of hand, tendon xanthoma

TECHNIQUE: DORSAL HAND

Patient Position

- Palm flat on examination table or couch with wrist in neutral position, fingers extended

Specifically Examine

- **Extensor tendons of fingers**
  - Ring & middle fingers have 1 extensor tendon; remaining fingers have 2 extensor tendons
  - Radial & ulnar sagittal bands (dorsal hood) help maintain position of extensor tendons on dorsum of metacarpophalangeal (MCP) joint
    - More distally, extensor expansion provides stability with contributions from lumbricals & interossei
  - Extensor tendons on dorsum of fingers do not have tendon sheath
    - Cannot get tenosynovitis on dorsum of fingers
- Transverse scanning is best to identify individual tendons on dorsum of hand & follow them proximally/distally
  - Follow each tendon individually rather than following 2 tendons simultaneously
  - When abnormality is found, tendon can be examined in longitudinal plane
    - Long axis is good for assessing extensor tendons on dorsum of fingers, including tendon insertion, dynamic movement, & tendon morphology
  - To assess sagittal band integrity, scan dorsal hood during flexion & extension
- **Extensor tendon of thumb**
  - Extensor pollicis longus inserts in base of distal phalanx
    - Has extensor hood similar to fingers
- **UCL of MCP joint of thumb**
  - Scan in longitudinal plane
  - Extends from innominate tubercle & groove distal end of 1st metacarpal bone to base of proximal phalanx
  - Covered by adductor pollicis aponeurosis, which is seen as thin, echogenic band overlying UCL
    - Interphalangeal (IP) joint flexion helps identify adductor aponeurosis
    - On dorsal aspect of 1st web space, adductor pollicis muscle is seen as 1st muscle deep to thick dorsal interosseous muscle
  - Careful thumb abduction during scanning will stress UCL & widen ulnar aspect of MCP joint
    - Excessive abduction can potentially induce Stener lesion

TECHNIQUE: VOLAR HAND

Patient Position

- Dorsum of hand flat on examination table or couch with wrist in neutral position, fingers extended

Flexor Tendon Pulleys

- A1-A5 annular pulleys; A1 being most clinically important (trigger finger)
- A1, A3, & A5 are seen as hyperechoic or hypoechoic bands looping over flexor tendons at MCP joint & proximal & distal IP joint level
  - Fuse with volar plates & bases of more distal phalanges
  - A1 pulley is thickest & should be < 0.5 mm thick, measured at 11 o'clock or 1 o'clock position
    - A2 is longest & strongest pulley
  - Passively flex & extend finger while observing movement of flexor tendons deep to pulley
  - Normally, tendon movement should be unrestricted, & pulley should not have to lift up to allow flexor tendons to glide underneath
- A2 & A4 pulleys occur at proximal & middle phalangeal shaft level; A2 & A4 are particularly relevant to climbing injuries as they prevent bowstringing
  - For bowstringing, examine finger in resting extended position & during forced flexion
    - Forced flexion of IP joints against pressure to fingertips with MCP joint extended
    - Distance between flexor tendons & phalangeal shafts should not increase with forced flexion

Flexor Tendons of Thumb

- Only 1 long flexor tendon (flexor pollicis longus)
  - Has continuous tendon sheath (radial bursa of wrist) that starts 3 cm proximal to radial styloid
  - Best identified passing through thenar muscle
  - Has A1 & A2 pulleys & also Y-shaped pulley across proximal phalanx

Metacarpophalangeal & Interphalangeal Joints

- Examined from volar & dorsal aspects &, if symptomatic, radial & ulnar aspects
- On dorsal side, observe proximal capsular recess, hypoechoic articular cartilage, joint space, bony margins, extensor tendon ± sagittal bands
- On volar side, observe proximal capsular recess, fibrocartilaginous volar plate, hypoechoic articular cartilage, joint space, bony margins, flexor tendons & pulleys
- Collateral ligaments on radial & ulnar sides
  - Collateral ligament proper runs roughly in line with joint & is taut in flexion
  - Accessory collateral ligament runs obliquely across joint from dorsal to volar, fusing with volar plate distally, & is taut in extension
  - MCP joint collateral ligament assessment is limited except for thumb, radial aspect of 2nd MCP, & ulnar aspect of 5th MCP joint

Carpometacarpal Joint of Thumb

- Examined from volar & dorsal aspects
- Assess triscaphe (scaphotrapeziotrapezoid) joint at same time, as it is closely related clinically

Extensor Mechanism of Fingers

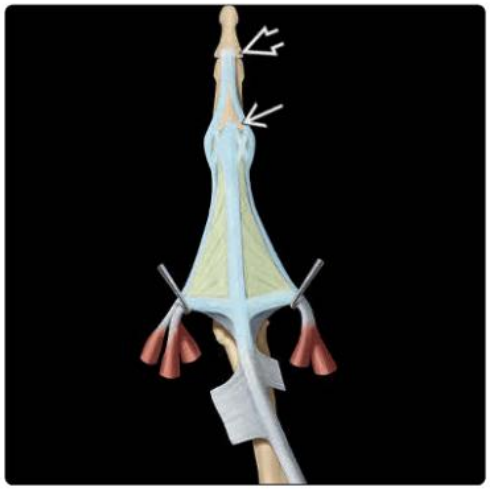

Extensor Digitorum of Middle Finger

(Left) *Near the MCP joint, the extensor tendon divides into 2 lateral slips & a central portion. The central portion inserts into the base of the middle phalanx. Lateral slips converge at the distal end of the middle phalanx & insert into the base of the distal phalanx. No central tendon is present on the proximal part of the shaft of the middle phalanx.* **(Right)** *Transverse US shows flattened central tendon on the dorsal aspect of the proximal phalanx of the middle finger. Extensor hood is too thin to clearly depict with US.*

Extensor Digitorum Insertion

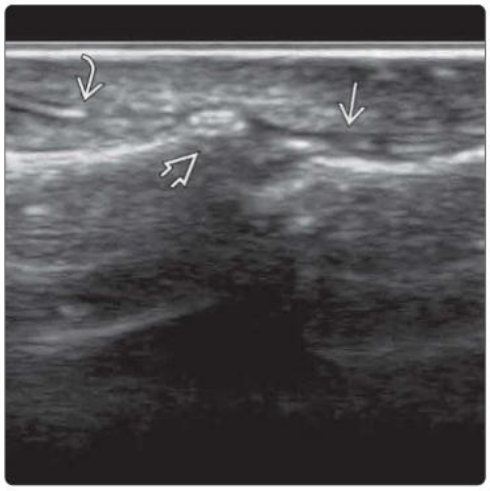

Ulnar Collateral Ligament of Metacarpophalangeal Joint of Thumb

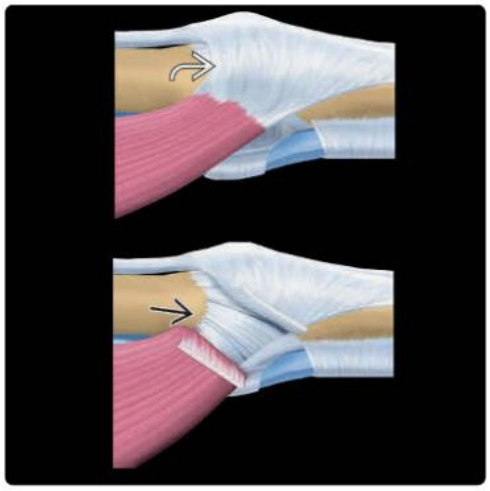

(Left) *Longitudinal US shows a thin extensor digitorum tendon inserting into the base of the distal phalanx. The extensor digitorum tendon in people with small fingers can be very thin. The base of the nail is shown.* **(Right)** *Graphic shows the ulnar aspect of the MCP joint of the thumb. The adductor pollicis aponeurosis attaches to the extensor expansion on the dorsum of the MCP joint. The lower image shows a reflected adductor aponeurosis with the ulnar collateral ligament (UCL) beneath.*

Scan Position for Ulnar Collateral Ligament of Thumb

Ulnar Collateral Ligament of Metacarpophalangeal Joint of Thumb

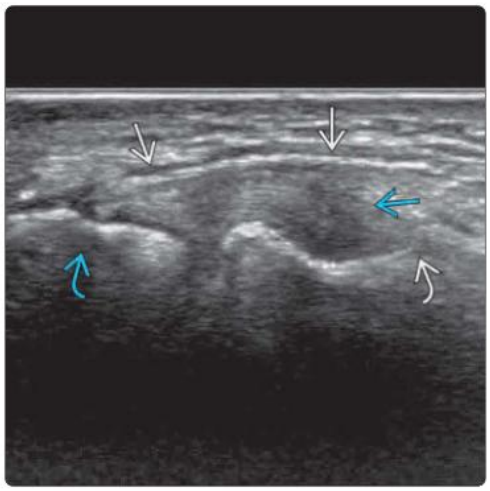

(Left) *Clinical photograph shows the scan position for the UCL of the thumb. The ligament can either be examined with the thumb fully abducted and the hand flat or placed on a pad as shown.* **(Right)** *Longitudinal US shows the hypoechoic UCL at the MCP joint of the thumb. The thin, echogenic line superficial to the ligament represents the adductor aponeurosis. The UCL runs from the metacarpal bone to the proximal phalanx.*

Flexor Pulley System

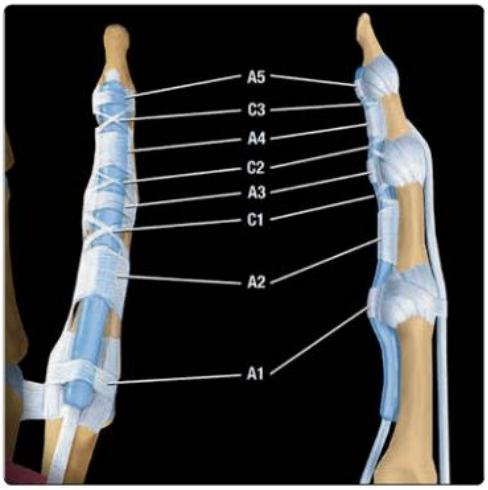

A1 Pulley: Short Axis

(Left) *Graphic shows the flexor pulley system of the fingers comprising annular (A1-5) & cruciate (C1-C3) pulleys. The most important pulley is the A1 pulley (trigger finger) followed by the A2 & A4 pulleys (bowstringing).* **(Right)** *Transverse US of the volar aspect of the metacarpal head ➡ shows the flexor digitorum superficialis (FDS) & flexor digitorum profundus (FDP) tendons deep to the A1 pulley ➡. Deep to the tendons is the MCP joint volar plate ➡. Normal A1 pulley thickness, measured at either the 11 or 1 o'clock position is < 0.5 mm.*

A1 Pulley: Long Axis

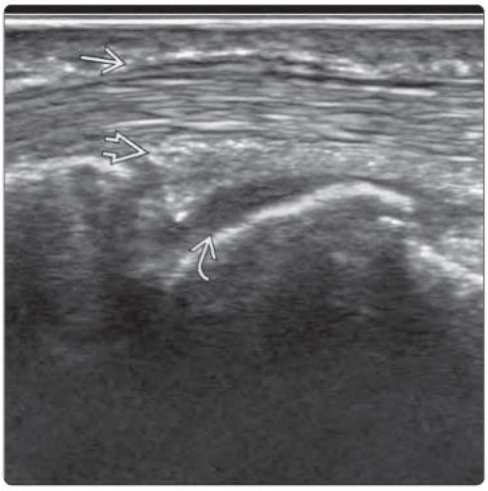

A2 Pulley: Short Axis

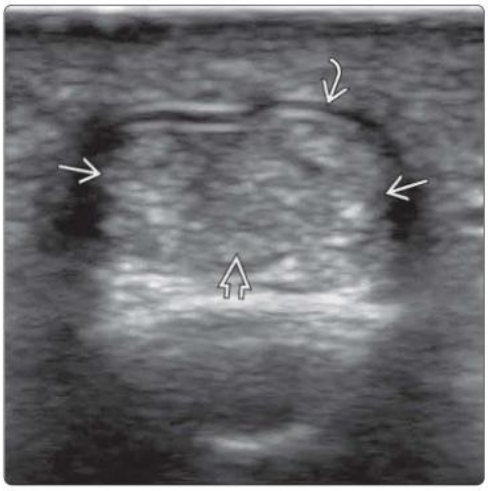

(Left) *Longitudinal US at the MCP joint level shows the A1 pulley ➡ overlying the flexor tendons. The fibrocartilaginous volar plate ➡ is deep to the tendons. The hyaline cartilage ➡ of the metacarpal head is deep to the volar plate.* **(Right)** *Transverse US at the level of the proximal phalangeal head shows the A2 pulley ➡ covering the 2 FDS tendons ➡ & the central FDP tendon ➡.*

Flexor Digitorum Profundus Tendon Insertion

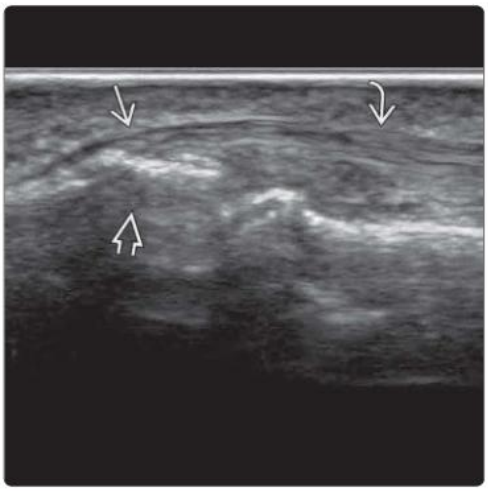

1st Carpometacarpal Joint

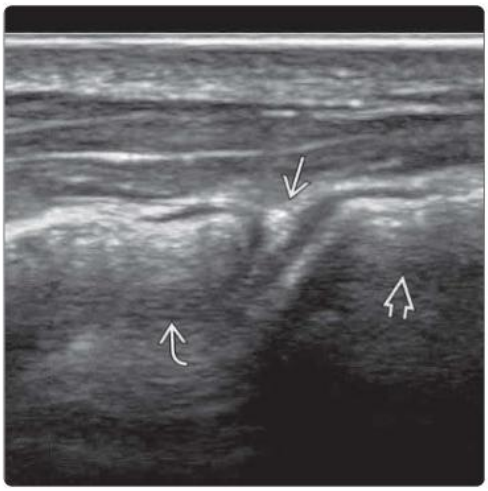

(Left) *Longitudinal US of the volar aspect of the finger shows the insertion ➡ of the FDP tendon ➡ into the base of the distal phalanx ➡.* **(Right)** *Longitudinal US shows the 1st carpometacarpal joint ➡ between the trapezium ➡ & the base of the 1st metacarpal bone ➡. The hypoechoic articular cartilage can be appreciated. The echogenic line within the joint is due to either gas or a synovial fold. This joint does not have an intraarticular disc.*

KEY FACTS

TECHNIQUE

- Adequate exposure of lower abdominal wall from umbilicus to groin
- Specifically examine deep inguinal ring, Hesselbach triangle, and femoral canal

IDENTIFICATION OF IMPORTANT LANDMARKS

- Deep inguinal ring: Situated just proximal and lateral to confluence of inferior epigastric vessels with external iliac vessels; spermatic cord passes through deep ring into peritoneal cavity in males
- Inferior epigastric vessels: Trace transversely from lateral aspect of rectus abdominis muscle distally to external iliac vessels
- Spermatic cord: Trace transversely from scrotum, along inguinal canal before it dips into peritoneal cavity through deep ring
- Inguinal ligament: Trace longitudinally from pubic tubercle to anterior superior iliac spine

TECHNIQUE IN CLASSIFICATION OF GROIN HERNIA

- Inguinal hernia: Neck of sac is above inguinal ligament, extends along inguinal canal
- Indirect: Neck of sac is above inguinal ligament, extends along inguinal canal
- Direct: Neck of sac is wide and medial to inferior epigastric vessels in Hesselbach triangle
- Femoral hernia: Neck of sac is below inguinal ligament

PROTOCOL

- Identify inferior epigastric vessels, inguinal ligament, spermatic cord (in males)
- Examine deep ring, Hesselbach triangle, femoral canal
- In each area, ask patient to perform Valsalva maneuver
- If present, pay particular attention to edges of surgical mesh
- Reexamine patient in standing position, particularly if this clinically accentuates symptoms

(Left) *Graphic shows relevant groin anatomy for depicting groin hernia. The inguinal ligament extends from pubic tubercle (PT) to the anterior superior iliac spine (ASIS). Hesselbach triangle (yellow triangle) lies medial to inferior epigastric vessels and lateral to rectus abdominis above inguinal ligament. Deep ring (DR) (orange circle) lies lateral to inferior epigastric vessels.* **(Right)** *Direct inguinal hernia ➡ tends to arise with a wide neck through Hesselbach triangle. Indirect inguinal hernia ➡ passes through the deep inguinal ring.*

Landmarks of Inguinal Canal

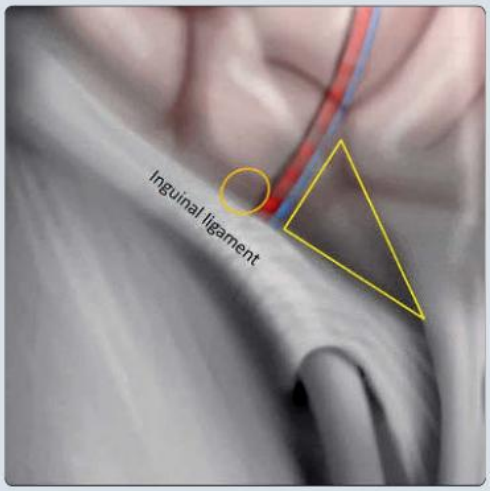

Landmarks of Inguinal Hernia

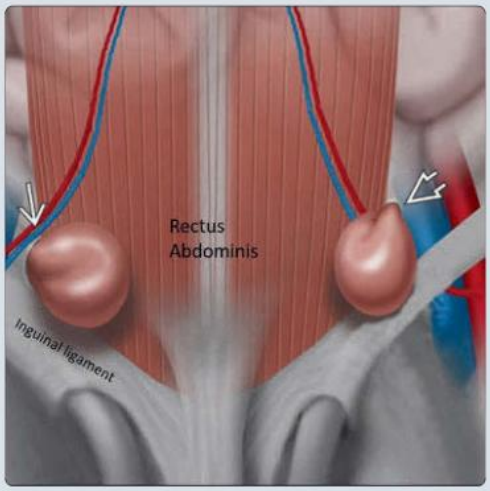

(Left) *Graphic shows the femoral canal (yellow arrow) lying under the inguinal ligament medial to the femoral vein.* **(Right)** *Graphic shows the neck of a femoral hernia along the femoral canal ➡ and under the inguinal ligament. The common femoral vessels are usually slightly displaced laterally.*

Landmarks of Femoral Canal

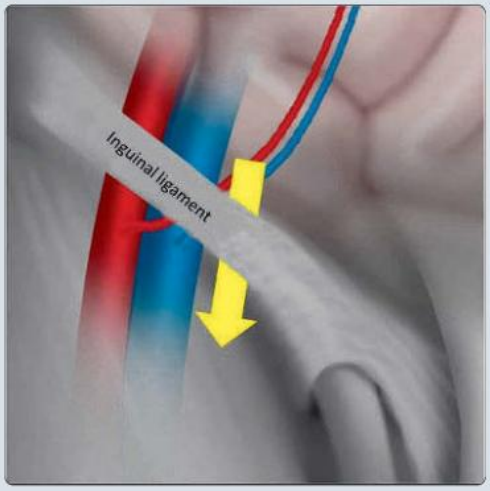

Landmarks of Femoral Hernia

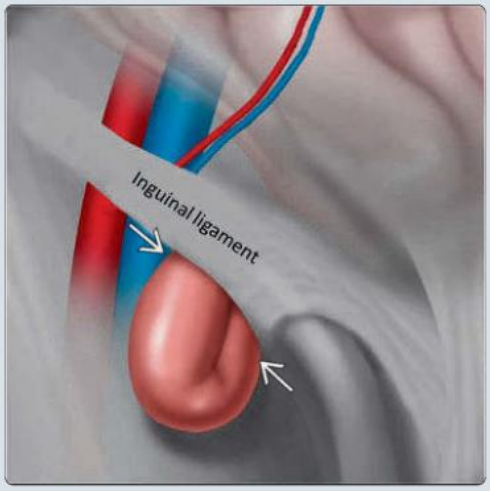

IMAGING ANATOMY

Critical Anatomic Structures

- Inguinal ligament
  - Thickened inferior border of external oblique aponeurosis
  - Runs from pubic tubercle → anterior superior iliac spine (ASIS)
- Inferior epigastric vessels
  - From external iliac artery, just above inguinal ligament
  - Ascends to lateral border of rectus abdominis muscle
- Inguinal canal
  - 4 cm long from deep → superficial inguinal ring
    - Deep inguinal ring
      - Opening in transversalis fascia through which spermatic cord/round ligament passes
      - 1 cm above midpoint inguinal ligament and 1 cm lateral to inferior epigastric vessels
    - Superficial inguinal ring
      - Opening in external oblique aponeurosis just lateral to pubic tubercle
      - Contains ilioinguinal nerve, spermatic cord (male), round ligament (female), and associated vessels
- Spermatic cord
  - Originates from vas deferens in scrotum
  - Enters superficial ring and passes along inguinal canal
  - Passes into peritoneal cavity through deep ring
  - Contains pampiniform plexus, testicular artery, cremasteric artery, artery of vas, lymphatics, sympathetic nerves, and vas deferens

TECHNIQUE

Standard Examination

- Patient supine with legs extended
- Expose lower abdomen from umbilicus to groin
- First, identify (1) inguinal ligament, (2) inferior epigastric vessels, and (3) spermatic cord (in males)
  - Normal round ligament in females not seen on US
- Inguinal ligament
  - Trace in longitudinal plane from pubic tubercle → ASIS
  - Hyperechoic structure with linear striated appearance
    - Most inferior edge of external aponeurosis
    - Deep ring at midpoint of inguinal ligament (i.e., halfway between pubic tubercle and ASIS)
      - Deep ring lies between inferior epigastric and external iliac vessels
    - Femoral vessels deep to midinguinal point (i.e., halfway between pubic symphysis and ASIS)
- Inferior epigastric vessels
  - Trace in transverse plane from rectus abdominis muscle → external iliac vessels
    - Artery, 2 veins seen as 3 small, hypoechoic dots
    - Color Doppler aids identification in obese patients
- Spermatic cord (in males)
  - Trace in either longitudinal or transverse plane from upper scrotum → inguinal canal → deep ring
  - Reasonably distinct echogenic, rounded, tubular structure containing arteries and vas deferens
- Then, specifically perform Valsalva maneuver at deep inguinal ring, Hesselbach triangle, and femoral canal
  - Deep inguinal ring
    - 1 cm lateral to inferior epigastric vessels
    - Site of origin of indirect inguinal hernia
  - Hesselbach triangle
    - Medial to inferior epigastric vessels above inguinal ligament
    - Site of origin of direct inguinal hernia
  - Femoral canal
    - Medial to femoral vein below inguinal ligament
    - Site of origin of femoral hernia
- Use only mild transducer pressure to avoid impeding emergence of hernia
- Examine in erect position if no hernia visible in supine position and symptoms worsen when standing upright

Points to Note

- **If hernia visible**
  - Confirm hernia emerges through abdominal wall
    - Determine whether hernia is indirect inguinal, direct inguinal, or femoral in type
      - By assessing relationship of neck to inferior epigastric vessels and inguinal ligament
    - Examine hernia at rest and during Valsalva
      - Best to perform Valsalva by asking patient to blow onto back of hand
    - Assess contents of hernia (mesenteric fat ± bowel) and maximum size, extent
    - Measure width of fascial defect
    - Check whether hernia reduces fully during relaxation
    - If hernia is found, still examine other locations, as double hernia may occur
- **If recurrent hernia present following surgical mesh repair**
  - Identify surgical mesh, which is usually seen as thin, echogenic interface with posterior acoustic shadowing
    - Mesh may be wavy in appearance and can be differentiated from bowel by lack of peristalsis
  - Inspect and perform Valsalva at margins of mesh
- **If no hernia present**
  - Assess whether painful or symptomatic area is located at deep ring, Hesselbach triangle, or femoral canal
  - Look for any abnormalities, such as scarring at these locations, undue bulging of fascia at these locations during Valsalva, indicating laxity
  - Reexamine with patient standing if uncertain about diagnosis and symptoms worsen when standing
- **If mass other than hernia present**
  - Discriminate other masses, such as hematoma, lipoma, seroma, cysts, canal of Nuck hydrocele
    - Canal of Nuck hydrocele or cyst due to incomplete obliteration of canal (patent processus vaginalis)
- **If unsure regarding US findings**
  - Arrange either CT or MR of groin region

Protocol

- Identify inferior epigastric vessels, spermatic cord, inguinal ligament
- Examine deep ring, Hesselbach triangle, femoral canal
- In each area, ask patient to perform Valsalva maneuver
- Reexamine patient in standing position, particularly if this clinically accentuates symptoms

(Left) *Clinical photograph shows the probe position (white box) at the umbilical level to identify inferior epigastric vessels (red and blue lines). The inferior epigastric vessels are located under the lateral border of the rectus abdominis muscle. Inguinal ligament (black line) extends from the ASIS to the PT.* **(Right)** *Corresponding transverse US shows the inferior epigastric artery ➡ accompanied by the inferior epigastric veins ➡ under the lateral border of the rectus abdominis muscle ➡.*

Identify Inferior Epigastric Vessels

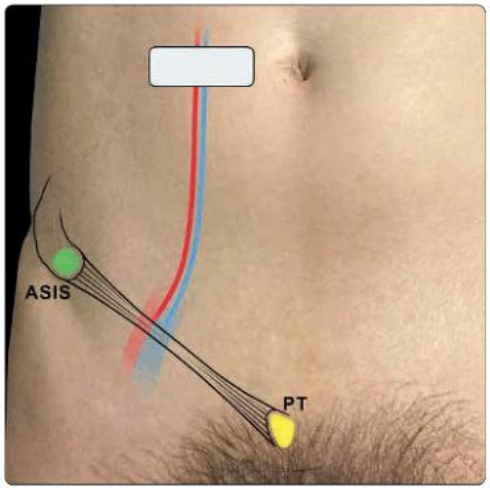

Identify Inferior Epigastric Vessels

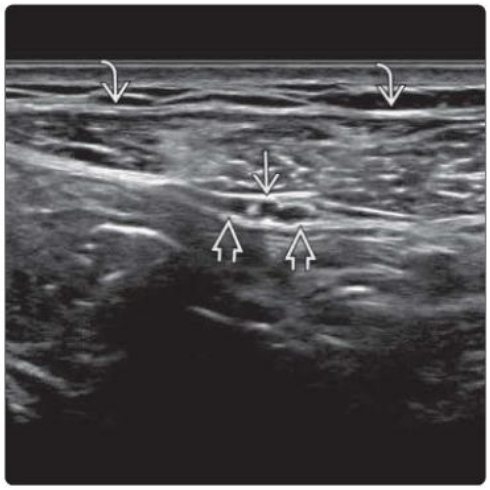

(Left) *Clinical photograph shows the probe position (white box) moving down to the right lower quadrant. The inferior epigastric vessels (red and blue lines) are located beneath the lateral border of the rectus abdominis muscle.* **(Right)** *Corresponding color Doppler US shows the inferior epigastric artery ➡ accompanied by inferior epigastric veins ➡ under the more lateral border of the rectus abdominis muscle ➡. Color Doppler US is useful to identify the inferior epigastric vessels.*

Identify Inferior Epigastric Vessels

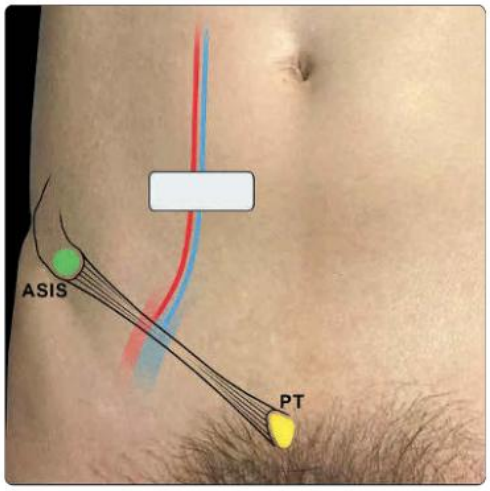

Identify Inferior Epigastric Vessels

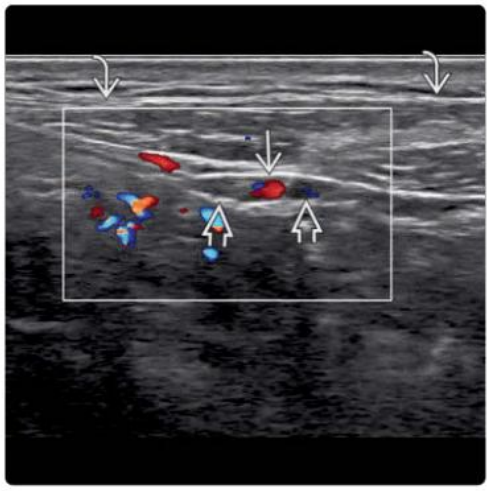

(Left) *Clinical photograph shows the probe position (white box) at the medial groin region. The inferior epigastric vessels (red and blue lines) lie above the inguinal ligament (black line) just before they join the external iliac vessels. The DR lies lateral to the inferior epigastric vessels at this point.* **(Right)** *Corresponding transverse US shows the inferior epigastric vessels ➡ immediately before joining the external iliac artery ➡ and vein ➡. The DR ➡ is a potential space between the external iliac and inferior epigastric vessels.*

Identify Deep Ring of Inguinal Canal

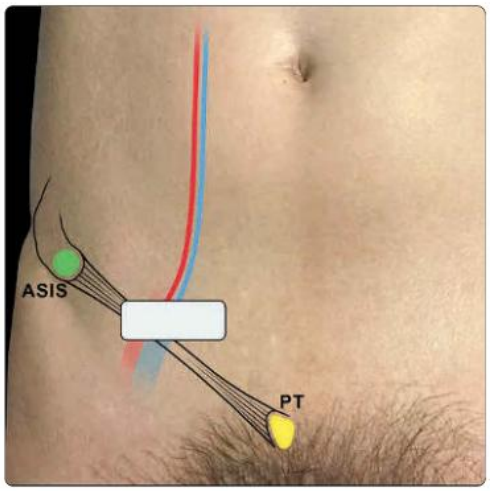

Identify Deep Ring of Inguinal Canal

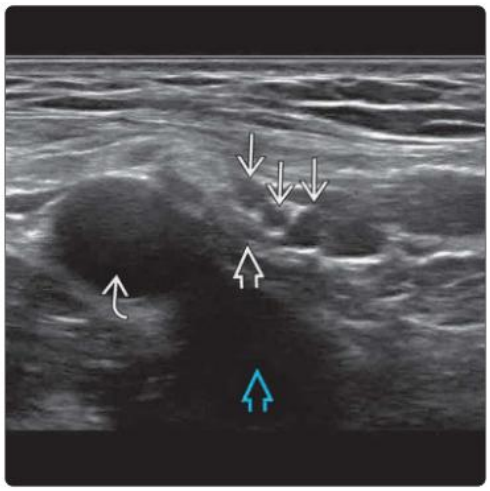

Identify Spermatic Cord

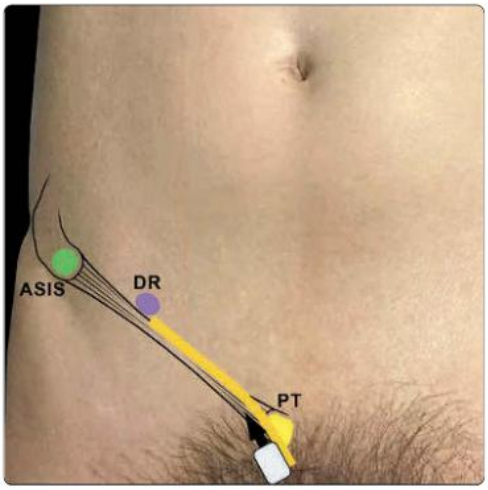

Identify Spermatic Cord

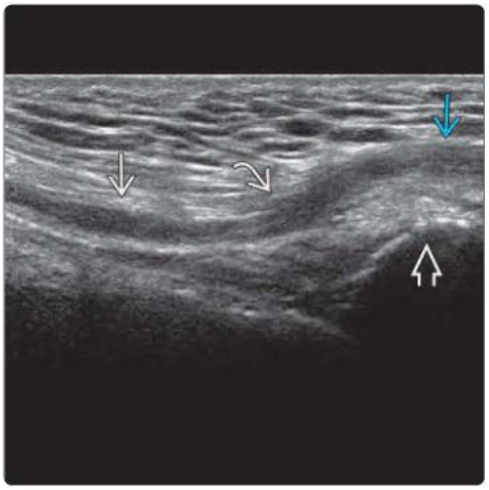

(Left) *Clinical photograph shows the probe position (white box) at the pubic region. The spermatic cord (orange line) is traced from the high scrotal region below the PT along the inguinal canal before it dips through the DR into the peritoneal cavity.* **(Right)** *Oblique longitudinal US shows the spermatic cord ➡ coursing from the high scrotal region ⇨ over the PT ➡ before extending through the superficial inguinal ring ➡ into the inguinal canal.*

Identify Spermatic Cord

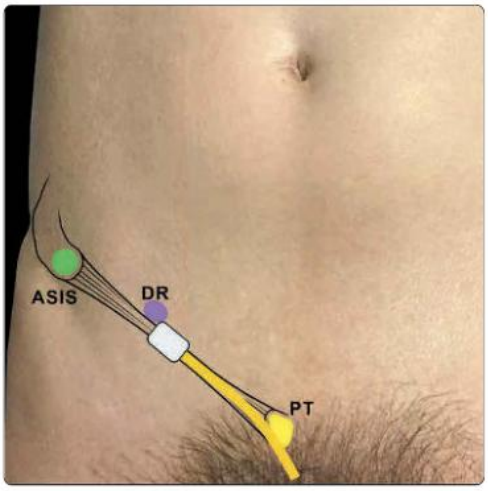

Identify Spermatic Cord

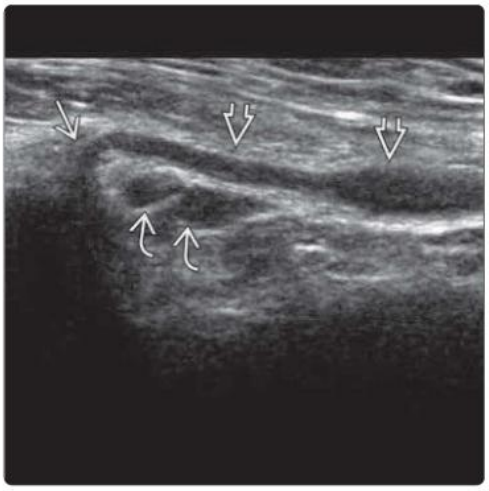

(Left) *Clinical photograph shows the probe position (white box) at the midinguinal region. At this region, the spermatic cord (orange line) descends through the DR into the peritoneal cavity.* **(Right)** *Oblique longitudinal US shows the spermatic cord ➡ coursing along the inguinal canal before dipping through the DR ➡ into the peritoneal cavity. The DR lies immediately lateral to the inferior epigastric vessels ➡.*

Identify Inguinal Ligament

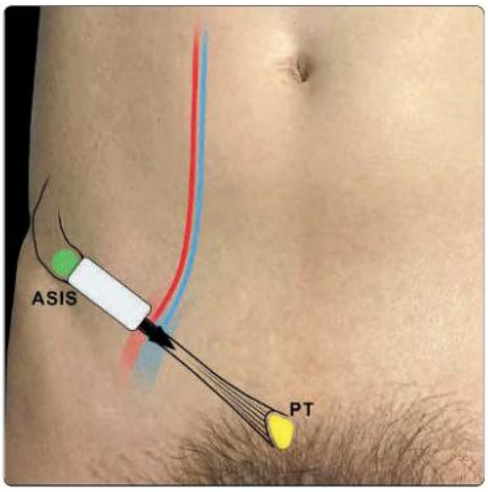

Identify Inguinal Ligament

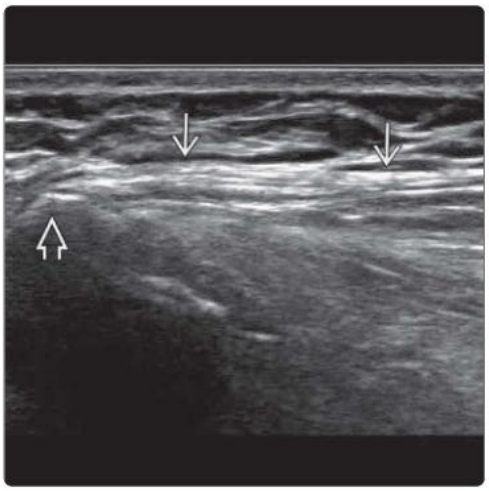

(Left) *Clinical photograph shows the probe position (white box) at the ASIS orientated inferomedially along the inguinal ligament toward the PT.* **(Right)** *Oblique longitudinal US shows the lateral 1/3 of the inguinal ligament ➡, which is an echogenic striated structure extending from the ASIS ➡ to the PT. The inguinal ligament is the free-rolled inferior border of the external oblique aponeurosis.*

(Left) *Clinical photograph shows the probe position (white box) on the inguinal ligament (black line) at the midinguinal point, which is midway between the pubic symphysis and the ASIS. The femoral vessels lie deep to the midinguinal point.* **(Right)** *Oblique longitudinal US at the midinguinal point shows the echogenic striated inguinal ligament lying immediately superficial to the common femoral artery and vein.*

Identify Inguinal Ligament

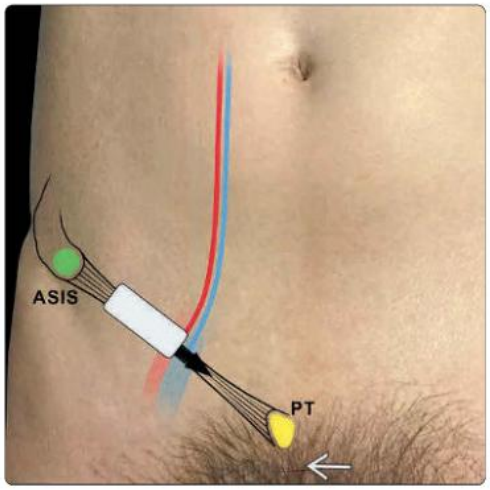

Identify Inguinal Ligament

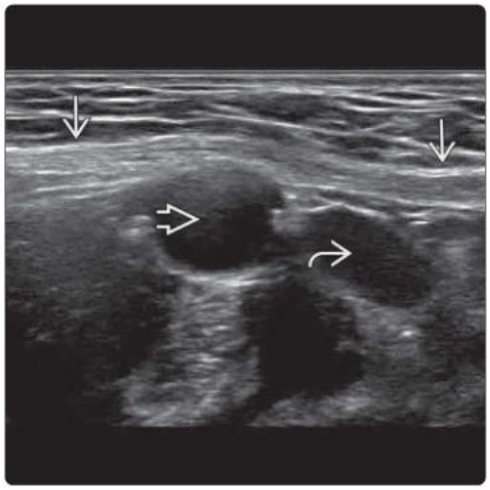

(Left) *Clinical photograph shows the probe position (white box) moved to the lower groin region overlying the medial 1/3 of the inguinal ligament (black line).* **(Right)** *Oblique longitudinal US shows the medial 1/3 of the inguinal ligament seen as a thick, echogenic striated structure attached to the PT.*

Identify Inguinal Ligament

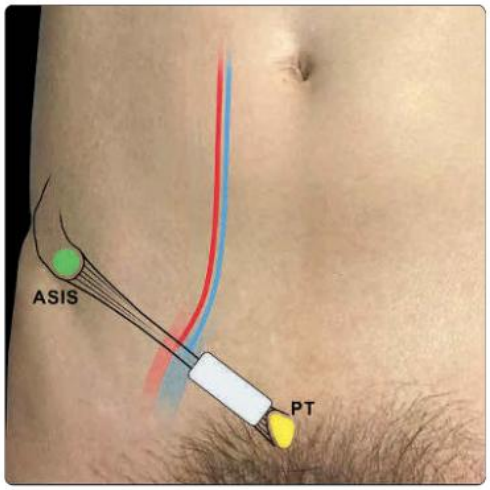

Identify Inguinal Ligament

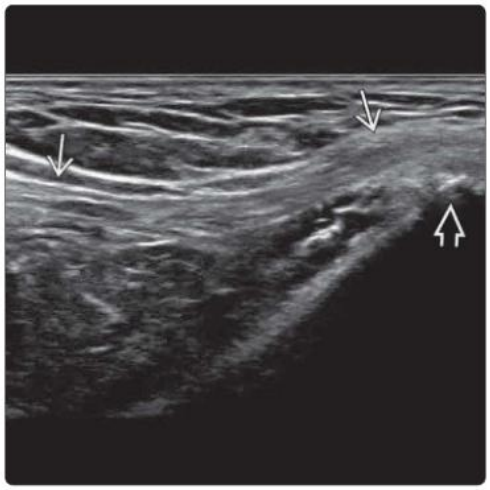

(Left) *Transverse US shows an echogenic mass present in the right groin region lateral to the inferior epigastric vessel and medial to the external iliac artery and vein. This is an indirect inguinal hernia.* **(Right)** *Corresponding US during Valsalva maneuver shows how the mass is now bulged more, helping to confirm an indirect inguinal hernia. The hernia is between the femoral artery, femoral vein, and the partially effaced inferior epigastric vessels.*

Indirect Inguinal Hernia at Rest

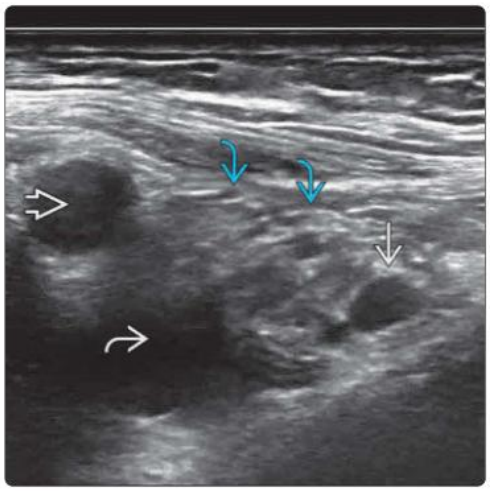

Indirect Inguinal Hernia During Valsalva

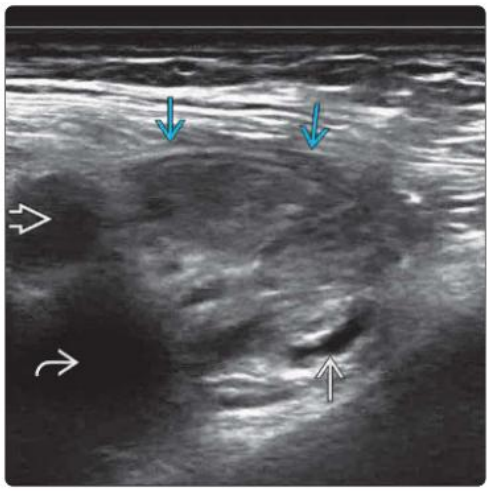

Identify Indirect Inguinal Hernia

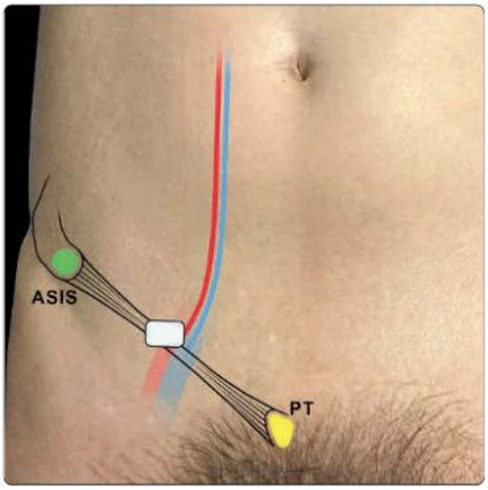

Indirect Inguinal Hernia

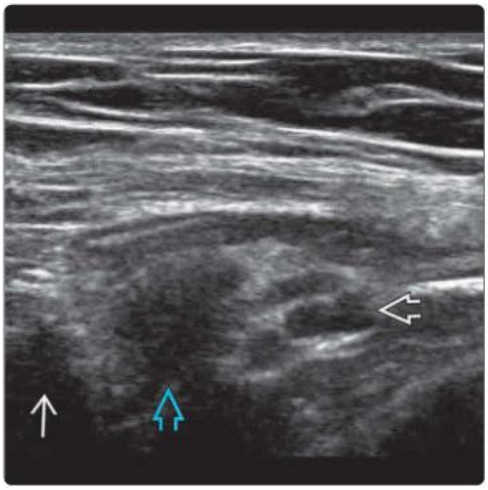

(Left) *Clinical photograph shows probe position (white box) at the DR, the point of origin of indirect inguinal hernia. The DR is located at the midpoint of the inguinal ligament, i.e., midway between PT and ASIS. The neck of an indirect hernia is lateral to the inferior epigastric vessels and above the inguinal ligament (black line).* **(Right)** *Transverse US shows the neck of an indirect inguinal hernia present at the DR, i.e., lateral to inferior epigastric vessels and medial to external iliac vessels.*

Identify Direct Inguinal Hernia

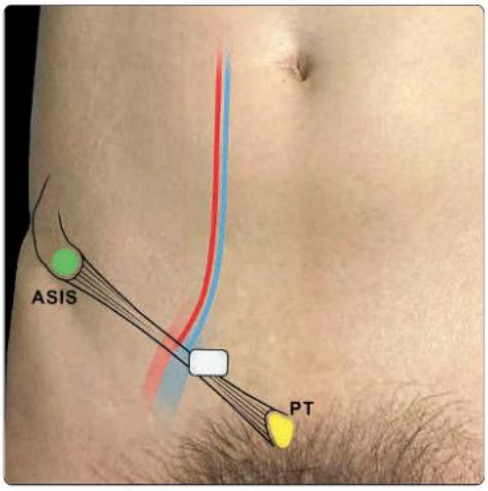

Direct Inguinal Hernia

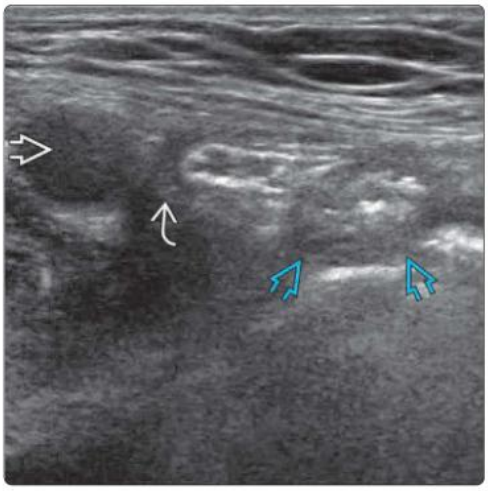

(Left) *Clinical photograph shows the probe (white box) position at the Hesselbach triangle, i.e., at the site of the origin of a direct inguinal hernia. The neck of a direct inguinal hernia is medial to the inferior epigastric vessels and proximal to the inguinal ligament (black line).* **(Right)** *Oblique transverse US shows the wide direct hernial neck located medial to the partially effaced inferior epigastric vessels just before these vessels join the external iliac vessels.*

Identify Femoral Hernia

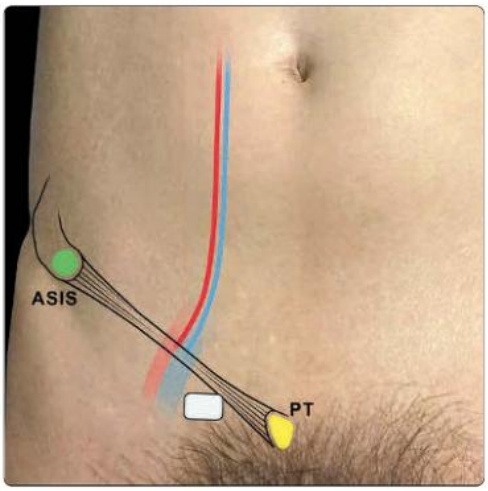

Femoral Hernia

(Left) *Clinical photograph shows the probe (white box) position at the femoral canal, i.e., the point of origin of a femoral hernia. The neck of the femoral hernia is located medially to the common femoral vein and distally to the inguinal ligament (black line).* **(Right)** *Oblique longitudinal US shows the neck of a femoral hernia in the femoral canal, i.e., inferior to the inguinal ligament and medial to the common femoral vein (not shown). The sac of this femoral hernia contains fluid, though no bowel or mesentery.*

(Left) *Oblique transverse US shows an indirect hernial sac containing bowel. The echostructure of bowel is visible with 2 hypoechoic lines: The superficial one representing muscularis propria ➡ and the deeper one representing submucosa ➡. The neck of the hernia ➡ lies lateral to the inferior epigastric vessels.* **(Right)** *Oblique longitudinal US shows the hernial sac containing gas-filled bowel ➡. This is a very useful sign to indicate a hernia.*

Bowel Wall in Hernial Sac

Bowel Gas in Hernial Sac

(Left) *Oblique longitudinal US shows the neck of a femoral hernia ➡ in the femoral canal lying inferior to the inguinal ligament ➡. The thickened hernial sac contains fluid ➡.* **(Right)** *During Valsalva, bowel passes through the femoral canal ➡ into the hernial sac, which helps confirm the presence of a femoral hernia. The femoral canal is narrow, and bowel may not reduce back into the peritoneal cavity (i.e., an incarcerated hernia). As expected, incarcerated hernias are more prone to strangulation.*

Femoral Hernia Before Valsalva

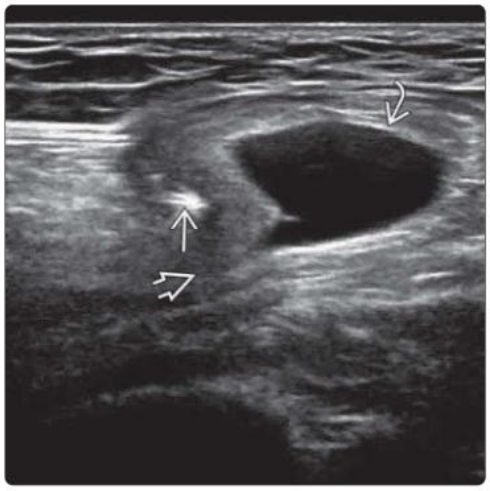

Femoral Hernia With Bowel During Valsalva

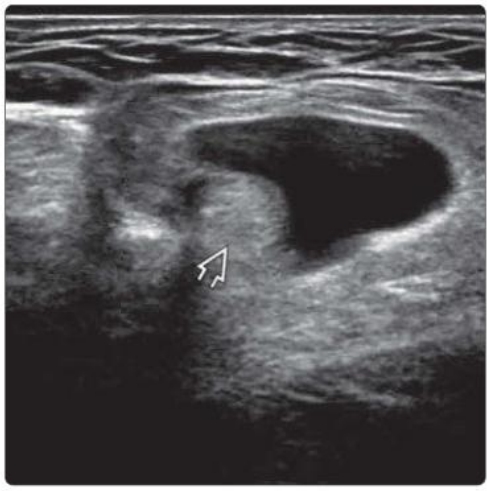

(Left) *Transverse US shows an echogenic mass due to mesentery ➡ in the scrotum from an indirect inguinal hernia. A normal testis ➡ is present alongside the hernial sac.* **(Right)** *Transverse color Doppler US shows a mixed hyperechoic and hypoechoic soft tissue mass containing scattered spots of arterial and venous-type vascularity ➡ reflecting the normal vascular pattern of the mesentery. This helps distinguish herniated mesenteric tissue from a lipoma.*

Mesentery in Scrotum

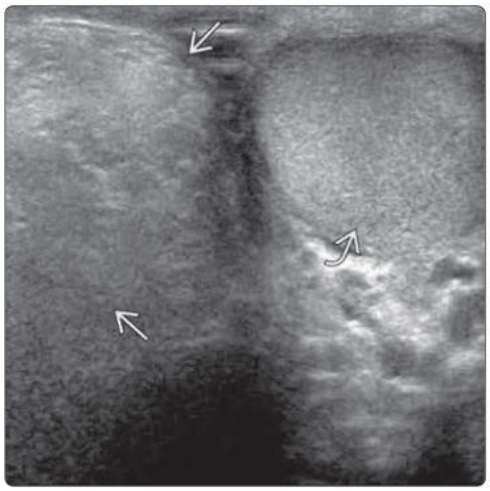

Vascularity Within Mesentery

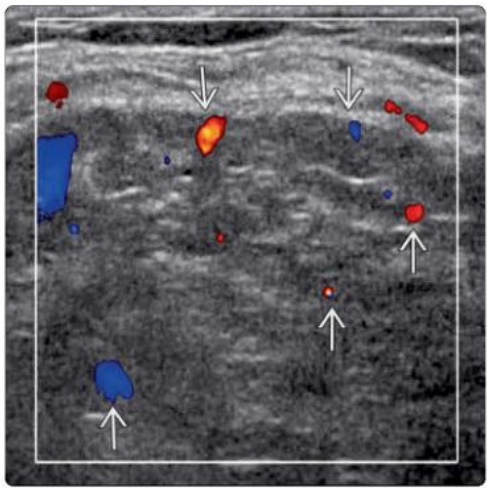

Indirect Inguinal Hernia: Step 1

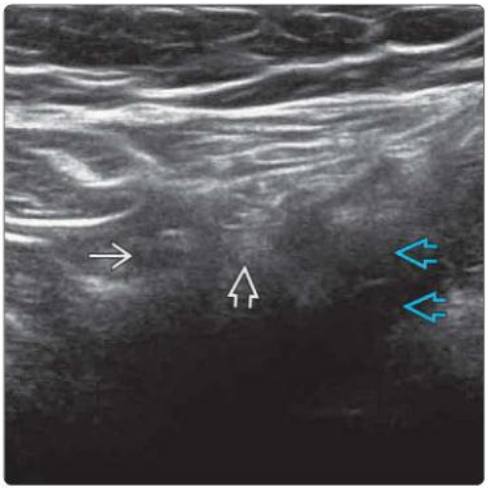

Indirect Inguinal Hernia: Step 2

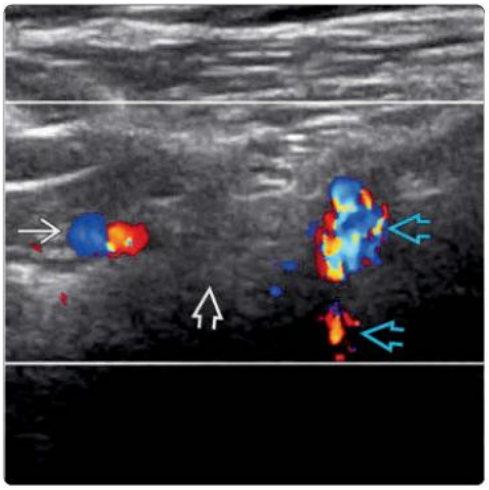

(Left) *Transverse US of a patient with left groin pain is shown. At rest, there is no hernia seen in the region of the deep inguinal ring. The DR is located lateral to the inferior epigastric vessels and medial to the external iliac vessels.* **(Right)** *Color Doppler US is useful to demonstrate the position of the DR of the inguinal canal, which lies between the inferior epigastric vessels and the external iliac vessels.*

Indirect Inguinal Hernia: Step 3

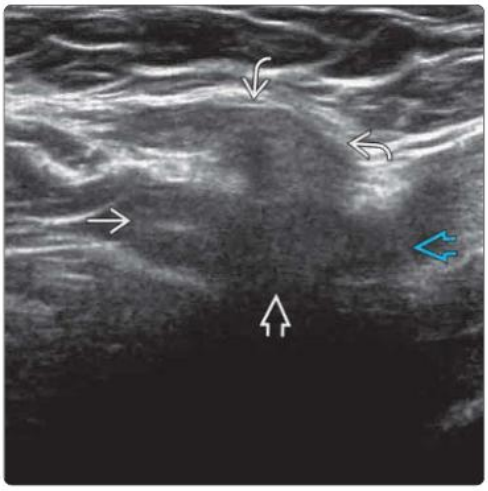

Indirect Inguinal Hernia: Step 4

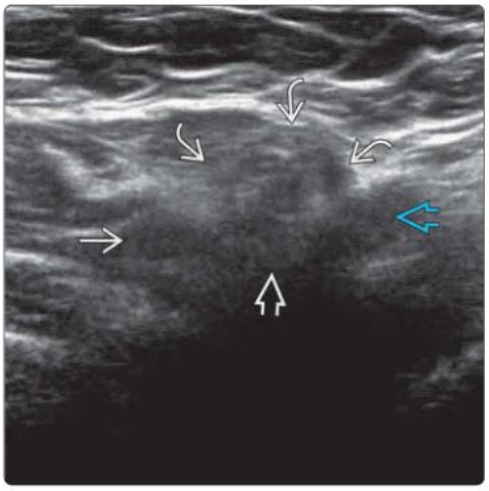

(Left) *Transverse US during Valsalva shows herniation of hypoechoic mesentery from the peritoneal cavity into the inguinal canal through the DR. The neck is located between the inferior epigastric vessels and the external iliac vessels.* **(Right)** *Corresponding US during Valsalva shows the change in configuration and size of the hernia sac. The DR between the inferior epigastric vessels and the external iliac vessels is shown.*

Indirect Inguinal Hernia: Step 5

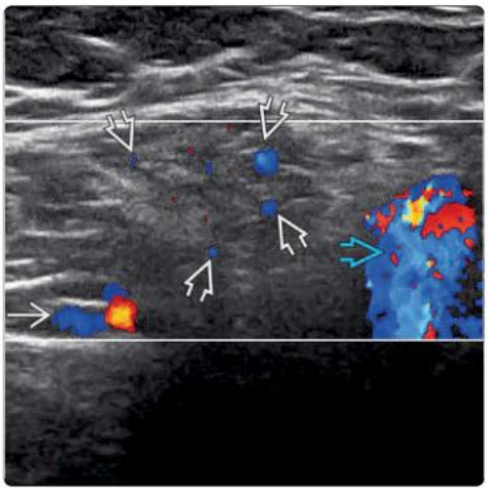

Indirect Inguinal Hernia: Step 6

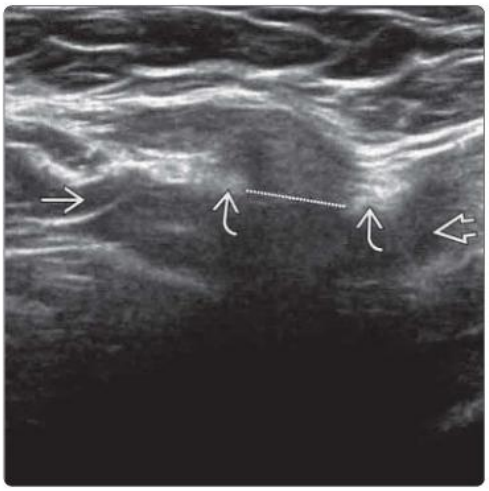

(Left) *Corresponding color Doppler US shows vascularity that is present within the hernial sac, which helps confirm mesentery within the sac. No gas or bowel wall is present. The inferior epigastric vessels and the external iliac vessels are demonstrated.* **(Right)** *The size of the fascial defect (broken line) between the medial and lateral borders of the fascia is measured to guide treatment. The inferior epigastric vessels and external iliac vessels are demonstrated.*

KEY FACTS

GENERAL CONSIDERATIONS

- US is very good for suspected hip effusion, synovitis, some adductor tendon pathology, & greater trochanteric pain
  - Can be supplemented by MR, particularly for deep gluteal pain & small tendon tears around hip
  - Also helpful to guide diagnostic & interventional procedures
- Full examination is preferable in most patients with poorly localized hip pain

ANTERIOR HIP

- Supine on examination couch with leg in neutral position
- Helpful to passively, internally or externally, rotate hip when assessing different structures
  - Anterior aspect of hip joint
  - Anterior superior iliac spine region
  - Rectus femoris tendon & insertion
  - Iliopsoas tendon
  - Dynamic examination for snapping iliopsoas tendon

MEDIAL HIP

- Hip abducted to variable degree & externally rotated with knee flexed (frog-leg position)
  - Adductor tendons & muscles

LATERAL HIP

- Lateral decubitus or oblique lateral decubitus
- Flexing & extending hip for suspected iliotibial band impingement
  - Gluteus minimus & medius tendons
  - Abductor tendons & muscles
  - Tensor fascia lata, iliotibial tract, & gluteal muscles

POSTERIOR HIP

- Patient prone with lower limb neutral position
- Low-frequency transducer may be required
  - Posterior thigh musculature just distal to ischial tuberosity; deep gluteal space proximal to ischial tuberosity; ischial tuberosity & hamstring tendon origins

(Left) *Clinical photograph shows the patient and probe position for examination of the anterior hip recess. The patient lies supine with the hip extended. Internal or external rotation of the hip during scanning of the anterior hip structures can be helpful.* **(Right)** *Oblique longitudinal US shows the anterior recess ➡ of the hip joint anterior to the neck ➡ and head ➡ of the proximal femur.*

Scan Position for Anterior Hip

Anterior Recess of Hip Joint

(Left) *Longitudinal US shows the capsular attachment ➡ to the rim of the acetabulum. The labrum ➡ is hypoechoic due to anisotropy. The femoral head of articular cartilage ➡ is clearly seen. Part of the rectus femoris tendon attachment ➡ is visible.* **(Right)** *Transverse US at the level of the femoral head shows the close relationship between the femoral head ➡, the acetabulum ➡, and the iliopsoas tendon ➡ and muscle ➡.*

Acetabular Attachment of Hip Capsule

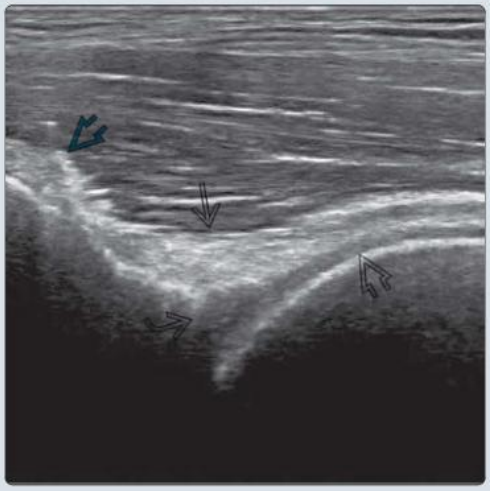

Femoral Head and Iliopsoas Tendon

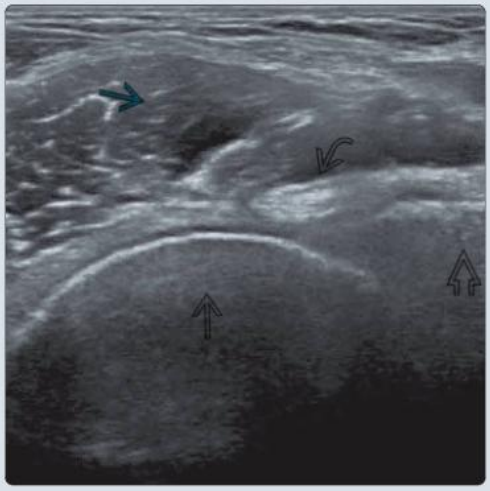

GENERAL CONSIDERATIONS

Clinical Indications for Hip US

- US is very useful investigation for most hip pathology; especially good for suspected hip effusion, synovitis, some adductor tendon pathology, & greater trochanteric pain
- US can be supplemented by MR, particularly for deep gluteal pain & small tendon tears around hip
- US also helpful to guide interventional procedures
- Full exam is preferable in most patients

TECHNIQUE: ANTERIOR HIP

Patient Position

- Supine on examination couch with leg extended; helpful to passively, internally or externally, rotate hip when assessing different structures

Specifically Examine

- **Anterior aspect of hip joint**
  - First, identify rounded cortex of femoral shaft in midthigh & trace in transverse plane proximally
  - At intertrochanteric region, where bone contour is seen to widen, rotate medial aspect of transducer upward to align longitudinally along femoral neck
  - Anterior joint capsule is seen extending from acetabulum to intertrochanteric line; superficial capsular fibers extend over proximal femoral shaft, while deep fibers reflect backward to head/neck junction
  - Each collagenous layer is seen as 2- to 4-mm thick echogenic band, while inner synovium is too thin to be seen
  - Normal thickness of anterior recess from outer margin capsule to bone is 6-8 mm
  - If no effusion, both capsular layers are opposed ± thin intervening hypoechoic line (stripe sign) representing anterior hip recess
  - Normal contour of anterior capsule is concave or flat rather than convex in outline
- **Acetabular labral junction**
  - Move transducer proximally along femoral neck to head/acetabular margin region
  - Anterior & superior labrum seen as echogenic triangular structure below echogenic acetabular rim
  - Passively rotating hip can help with delineation
- **Iliopsoas tendon**
  - Seen on transverse imaging over femoral head, located just anterior to hip capsule & deep to femoral neurovascular bundle
    - Tendon located on deep margin of iliopsoas muscle
    - Frog-leg lateral position best for viewing length of iliopsoas tendon & insertion → lesser trochanter
  - Normal iliopsoas bursa between tendon & anterior capsule cannot be seen
- **Dynamic examination for snapping iliopsoas tendon**
  - Transducer in oblique transverse plane just proximal to hip joint
  - Patient is asked to reproduce symptoms or else move hip from flexion-abduction to external rotation to neutral position during real-time scanning in transverse plane
  - Normally, iliopsoas tendon & muscle will move laterally in smooth clockwise fashion
  - Snap usually produced & felt as sudden flip of iliopsoas tendon around iliacus muscle
    - Iliacus muscle fibers become temporarily trapped between tendon & superior pubic ramus
  - Asymptomatic snapping is quite common finding on testing normal subjects
- **Rectus femoris tendon**
  - On transverse & longitudinal scanning proximal to hip joint, characteristic rectus femoris tendon with direct & indirect heads
    - Indirect head arises from supraacetabular ridge, while direct head arises from anterior inferior iliac spine
    - Indirect tendon joins lateral part of direct tendon, causing posterior acoustic shadowing deep to lateral aspect of rectus femoris tendon
  - Evaluate rectus femoris tendon from both medial & lateral sides to see both direct & indirect tendons
  - More distally, within proximal rectus femoris muscle, indirect tendon → central aponeurosis, while direct tendon → superficial aponeurosis
  - Rectus femoris tendon is C-shaped
- **Anterior superior iliac spine region**
  - Observe inguinal ligament, sartorius medially, & tensor fascia lata muscle laterally
  - On transverse scanning, proximal ends of these muscles can have pseudothyroid appearance
  - On longitudinal scanning, short tendons & attachments of these muscles are best seen
  - Observe lateral femoral cutaneous nerve deep to lateral aspect of inguinal ligament
  - Nerve moves from medial to lateral over iliacus, then between sartorius & tensor fascia lata
  - Sartorius muscle passes distally over femoral neurovascular bundle

TECHNIQUE: MEDIAL HIP

Patient Position

- Hip abducted to variable degree & externally rotated with knee flexed (frog-leg position)

Specifically Examine

- **Adductor tendons & muscles**
  - Scan transversely from pubic symphysis over pectineus muscle
  - Move transducer inferomedially on pectineus to see adductor muscles in short axis
    - Adductor longus (more superficial), adductor brevis, & adductor magnus (more deep) seen
  - Rotate transducer into long axis, maintaining it as parallel to adductor tendons as possible
  - Move transducer obliquely along inferior pubic ramus toward pubic bone & pubic symphysis
    - Observe common adductor tendon originating from pubic body & inferior pubic ramus
      - Adductor longus originates from pubic body just distal to pubic tubercle
      - Adductor brevis originates from medial aspect inferior pubic ramus
      - Adductor magnus originates from lateral aspect of inferior pubic ramus extending to ischial tuberosity

- Moving distally from origin, note 3 adductor muscles in long axis
  - Anterior & posterior obturator nerve branches lie between longus/brevis & brevis/magnus muscles, respectively
- Gracilis muscle arises just medial to adductor longus & descends more vertically in thigh

TECHNIQUE: LATERAL HIP

Patient Position

- Lateral decubitus or oblique lateral decubitus; flexing & extending hip for suspected iliotibial b& impingement

Specifically Examine

- **Gluteus minimus & medius tendons**
  - On transverse scanning, move transducer proximally along femoral cortex to firefighter helmet-shaped greater trochanter
  - Gluteus minimus tendon → anterior facet of greater trochanter
    - For longitudinal scanning, align transducer toward middle 1/3 of iliac crest along gluteus minimus tendon
      - Normal subgluteus minimus bursa not seen
  - Gluteus medius tendon → larger, triangular, lateral facet & smaller, flatter, posterosuperior facet of greater trochanter
    - For longitudinal scanning, align transducer toward posterior 1/3 of iliac crest along gluteus medius tendon; normal subgluteus medius bursa not seen
    - Move transducer proximally & posteriorly to view posterosuperior attachment
  - Rounded posterior facet of greater trochanter is bare
- **Tensor fascia lata, iliotibial tract, & gluteal muscles**
  - On transverse plane, identify tensor fascia lata & iliotibial band at anterior superior iliac spine region
    - Iliotibial band = focal thickening of fascia lata from posterior part of tensor fascia lata muscle overlying anterior part of gluteus maximus muscle
  - Fascia lata descends over anterior aspect of gluteus maximus, lateral aspect of gluteus medius muscle, & greater trochanter
    - Scanning transversely while slightly extending hip, observe normal smooth movement of iliotibial tract over trochanter
    - Normal trochanteric bursa at posterolateral aspect of greater trochanter is not seen
  - Also, on transverse scanning, identify gluteus minimus, medius, & maximus muscles
    - Anterior margins of gluteus minimus & medius merge so muscles are more clearly defined posteriorly
    - Anterior fibers of gluteus maximus muscle cover posterior aspect of gluteus medius tendon
    - Gluteus maximus passes over greater trochanter & inserts on posterior aspect of proximal femoral shaft

TECHNIQUE: POSTERIOR HIP & DEEP GLUTEAL SPACE

Patient Position

- Prone: Low-frequency transducer may be required
  - ± internally rotate hip to put short hip rotators on stretch
  - Firm downward transducer pressure usually required to examine tissues proximal to ischial tuberosity

Specifically Examine

- **Ischial tuberosity & hamstring tendon origins**
  - On transverse scanning, hamstring tendon origin area can be seen posterolaterally
  - Semimembranosus tendon lies deep & lateral
  - Semitendinosus/biceps femoris tendon lies superficially
  - Normal ischial tuberosity bursa is not seen
  - Sciatic nerve lies lateral to ischial tuberosity with posterior cutaneous nerve of thigh & inferior gluteal artery/nerve
- **Posterior thigh musculature just distal to ischial tuberosity**
  - Slowly scan in transverse plane down from ischial tuberosity
  - Identify semimembranosus tendon descending medially as large, thin, sheet-like, membranous aponeurosis
    - Tadpole-shaped membranous aponeurosis gives semimembranosus its name, lying deep to muscular portion of semitendinosus
    - No semimembranosus muscle fibers in proximal thigh
      - Muscle fibers arise from anterior aspect of aponeurosis more distally
  - Identify comma-shaped conjoint semitendinosus/biceps tendon lying more superficially
    - Semitendinosus muscle arises medially & slightly more proximally to that of biceps femoris, which arises laterally from conjoint tendon
    - Oblique central semitendinosus tendon is veil-like
  - Identify fatty triangle formed by conjoint tendon, semimembranosus aponeurosis, sciatic nerve with adductor magnus at base
  - Identify sciatic nerve lying deep to biceps femoris muscle in midline posterior thigh
  - 2 heads to biceps femoris muscle; 2nd belly seen in distal thigh arising from posterior aspect of femoral cortex & joining biceps laterally
- **Deep gluteal space proximal to ischial tuberosity**
  - Scan transversely between more distal end of ischial tuberosity & posterior facet of greater trochanter (ischiofemoral space)
    - Observe quadratus femoris muscle with sciatic nerve superficially
  - Scanning slowly in transverse plane more proximally, one can observe
    - Sciatic nerve deep to gluteus maximus
    - Posterior aspect of hip joint
    - Twinned gemelli muscles with tendon & short muscle belly & intervening obturator internus tendon
    - Sciatic nerve emerging from pelvis through greater sciatic notch just distal to piriformis muscle
  - On longitudinal scanning, long axis of sciatic nerve can be appreciated; moving probe proximally, sciatic nerve can be traced to greater sciatic foramen, where it emerges from pelvis; passes deep to gluteus maximus & superficial to short hip rotators

SELECTED REFERENCES

1. Gao G et al: Ultrasound had high accuracy in measuring hip joint capsule thickness. BMC Musculoskelet Disord. 25(1):101, 2024

Anterior Aspect of Hip Joint

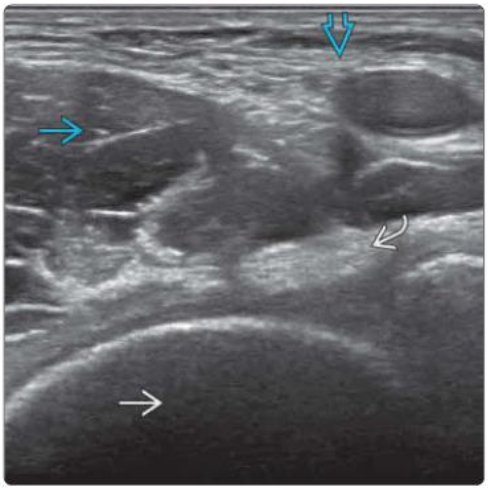

Femoral Nerve and Artery

(Left) *Transverse US at the level of the femoral head shows the close relationship between the femoral head ➡, the iliopsoas tendon ➡ and muscle ⇨, and the femoral neurovascular bundle ⇨.* **(Right)** *Transverse US shows how the femoral nerve ➡, which lies lateral to the femoral artery ➡, is indistinct and not as clearly outlined as most nerves. The femoral nerve divides into its many branches (pectineus, sartorius, quadriceps muscles as well as medial cutaneous and saphenous) 2-4 cm distal to the inguinal ligament.*

Rectus Femoris Tendon: Short Axis

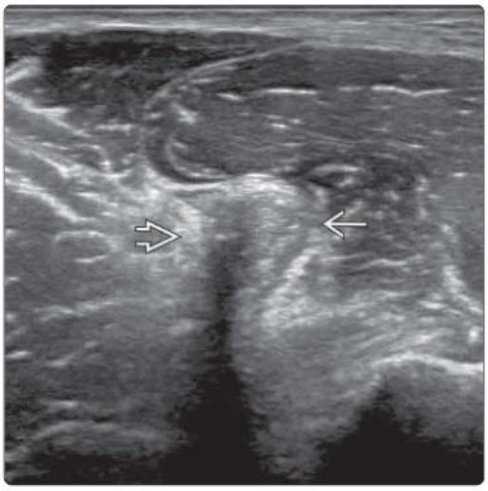

Direct Head of Rectus Femoris Tendon

(Left) *Transverse US shows the direct ➡ and reflected ➡ heads of the rectus femoris tendon. The reflected head, which lies laterally, is hypoechoic due to anisotropy.* **(Right)** *Longitudinal US shows the direct head of the rectus femoris tendon ➡ inserted into the anterior inferior iliac spine ➡. Scanning in a more oblique coronal plane allows one to reduce the effect of anisotropy from the reflected head.*

Indirect Head of Rectus Femoris Tendon

Superior Aspect of Hip Joint

(Left) *Longitudinal US shows the indirect head of the rectus femoris tendon ➡, which is hypoechoic due to fiber obliquity. These fibers are oblique to the scan plane, as they descend deeply to insert into the supraacetabular region.* **(Right)** *Longitudinal US just distal to the prior image shows the superior aspect of the hip joint with the acetabulum ➡ and acetabular labrum ➡ alongside the femoral head ➡.*

(Left) *Transverse US close to the anterior superior iliac spine shows the lateral cutaneous nerve of the thigh ⇨ between the inguinal ligament ⇨ and the iliacus muscle ⇨.* **(Right)** *Transverse US just distal to the prior image shows the lateral cutaneous nerve of the thigh ⇨ between the fascia lata ⇨ and the sartorius muscle ⇨.*

Lateral Cutaneous Nerve of Thigh

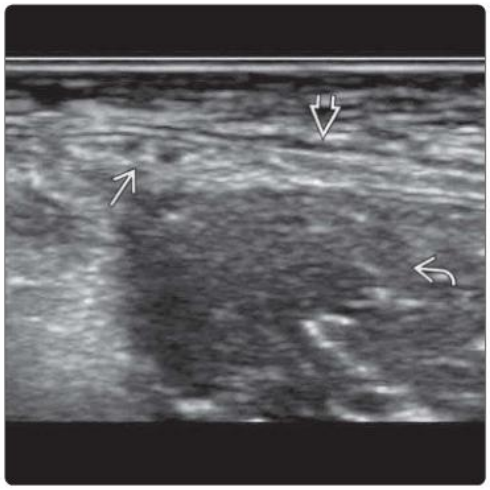

Lateral Cutaneous Nerve of Thigh

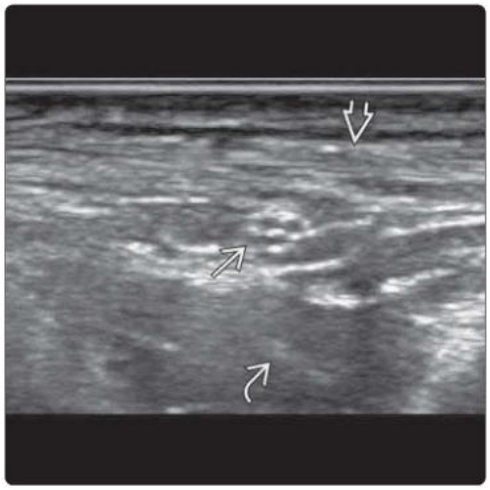

(Left) *Oblique longitudinal US shows a close relationship between the capsule overlying the femoral head ⇨ and the iliopsoas tendon ⇨.* **(Right)** *Oblique longitudinal US shows the iliopsoas tendon ⇨ insertion into the lesser tuberosity ⇨ of the proximal femur. The normal iliopsoas bursa between the tendon and the hip joint is not visible.*

Iliopsoas Tendon and Hip Joint

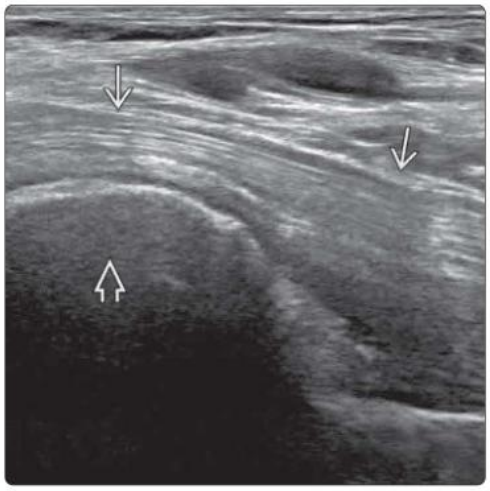

Iliopsoas Tendon Insertion

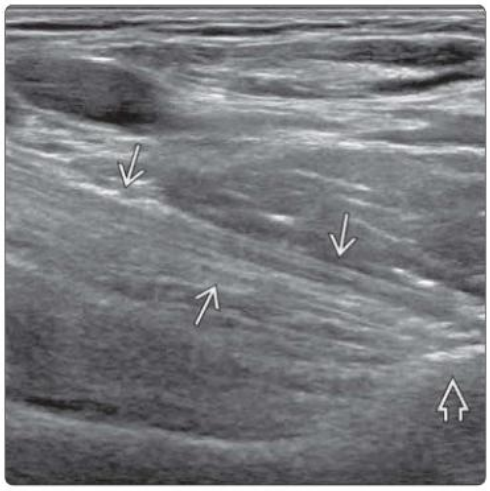

(Left) *Clinical photograph shows the patient and probe position for examination of the lateral hip. The patient lies in a decubitus position. Flexing and extending the limb under examination can be helpful to demonstrate iliotibial band impingement against the greater trochanter.* **(Right)** *Graphic shows facets of the greater trochanter of the proximal femur. The gluteus minimus is inserted onto the anterior facet ⇨, while the gluteus medius is inserted onto the lateral ⇨ and posterosuperior ⇨ facets. The posterior facet ⇨ is bare.*

Scan Position for Lateral Hip

Facets of Greater Trochanter

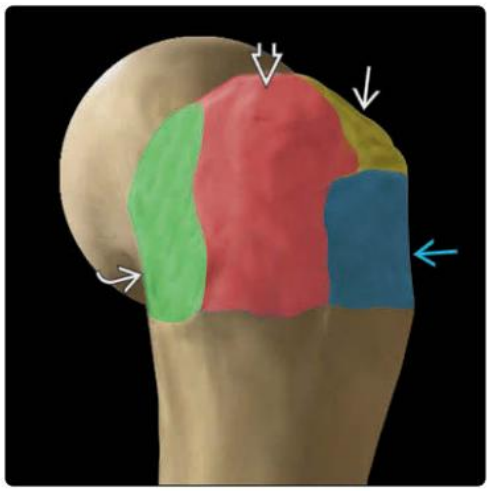

Facets of Greater Trochanter

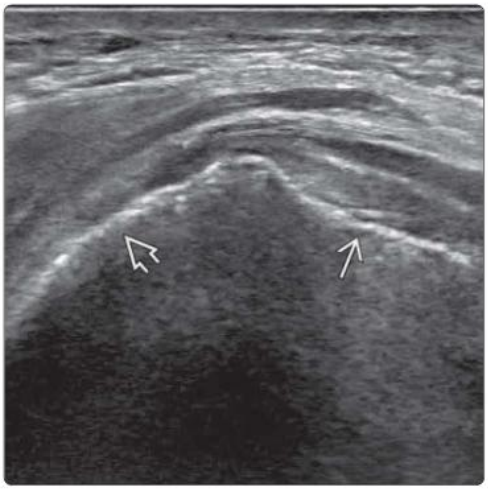

Gluteus Minimus Insertion

(Left) *Transverse US shows the firefighter helmet configuration of the anterior ➡ and lateral ➡ facets of the greater trochanter.* **(Right)** *Oblique longitudinal US shows the gluteus minimus musculotendinous junction ➡ and tendon insertion ➡ into the anterior facet of the greater trochanter.*

Gluteus Medius Insertion

Bare Posterior Facet

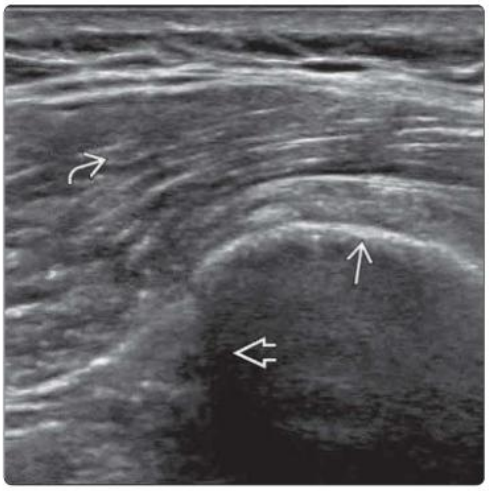

(Left) *Oblique longitudinal US shows gluteus medius musculotendinous junction ➡ and tendon insertion ➡ into the lateral facet of the greater trochanter.* **(Right)** *Transverse US shows the bare posterior facet of the greater trochanter ➡. The gluteus medius tendon inserted into the lateral facet ➡ is shown. This insertion is covered by the gluteus maximus muscle ➡.*

Gluteus Medius Insertion

Iliotibial Tract

(Left) *Longitudinal US shows the gluteus medius musculotendinous junction ➡ and tendon insertion ➡ into the posterosuperior facet ➡ of the greater trochanter. The gluteus medius has 2 tendinous insertions, a large one into the lateral facet and a smaller one into the posterosuperior facet.* **(Right)** *Transverse US at the lateral facet of the greater trochanter shows the thick iliotibial band ➡ overlying the greater trochanter ➡. The terms iliotibial tract and iliotibial band can be used synonymously.*

(Left) *Clinical photograph shows the scan position for the medial hip. The limb is placed in an abducted, externally rotated position. The adductor muscle is scanned in both transverse and longitudinal planes. This is also a good position for scanning the iliopsoas tendon.* **(Right)** *Transverse US shows the 3 adductor muscles lateral to the pectineus muscle. These are the adductor longus, adductor brevis, and adductor magnus from superficial to deep.*

Scan Position for Medial Hip

Pectineus and Adductor Muscles: Short Axis

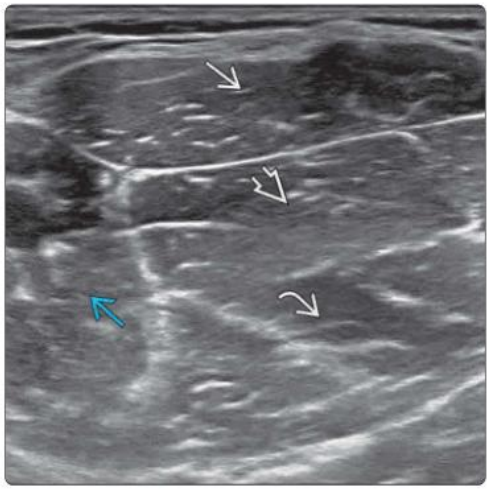

(Left) *Longitudinal US shows adductor muscles diverging from their origin on the pubic body and inferior pubic ramus.* **(Right)** *Longitudinal US shows the adductor muscles diverging from their origin. The anterior branch of the obturator nerve lies between the adductor longus and the adductor brevis, while the posterior branch lies between the adductor brevis and the adductor magnus.*

Adductor Muscle Origin: Long Axis

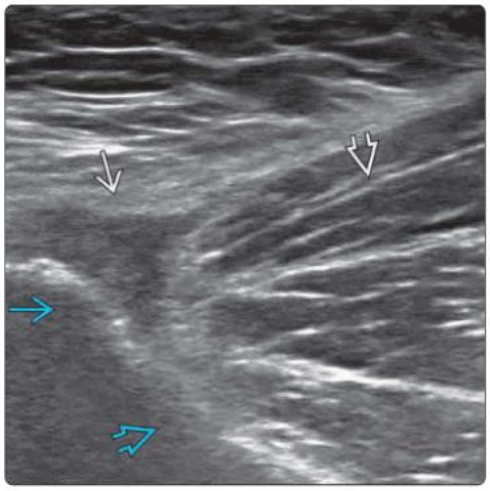

Adductor Muscles: Long Axis

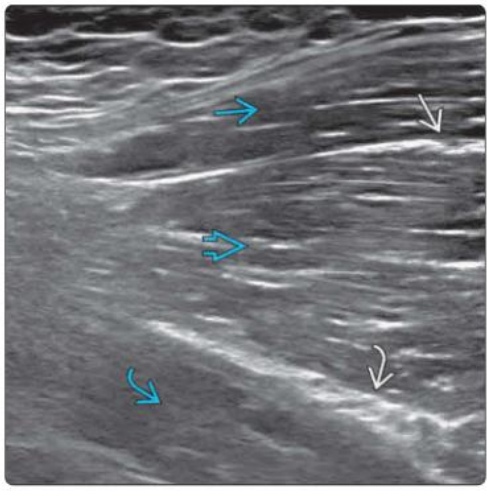

(Left) *Transverse US of the medial thigh shows the adductor longus, adductor brevis, and adductor magnus muscles. The gracilis muscle lies more superficially.* **(Right)** *Clinical photograph shows the patient and probe position for the posterior hip region. The patient lies prone. Especially in larger patients, deep pressure on the transducer is necessary to see the posterior hip structures more proximal to the ischial tuberosity.*

Adductor Muscles

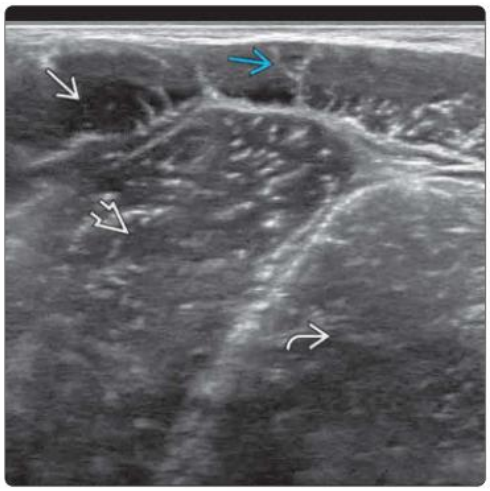

Scan Position for Posterior Hip

Sciatic Nerve

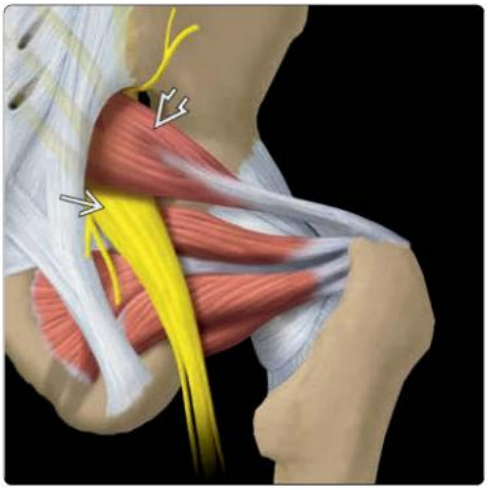

Sciatic Nerve

(Left) *Graphic shows deep gluteal region anatomy with the sciatic nerve ➡ exiting the pelvis below the piriformis muscle ➡. The sciatic nerve passes superficial to the short hip rotators (gemelli, obturator internus, and, more distally, quadratus femoris).* **(Right)** *Longitudinal US of the buttock region shows sciatic nerve ➡ emerging from sciatic foramen to descend the thigh. Gluteus maximus ➡ and the thick subcutaneous fat of the buttock ➡ lie superficially. The short rotators ➡ of the hip lie deep to the sciatic nerve.*

Deep Gluteal Region

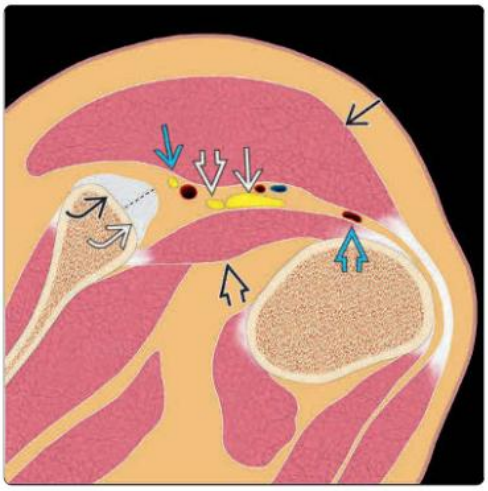

Ischiofemoral Space

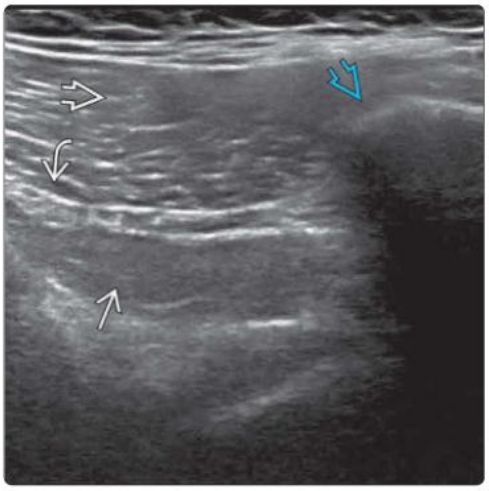

(Left) *Graphic shows deep gluteal anatomy with gluteus maximus ➡ and quadratus femoris muscles ➡, sciatic nerve ➡, posterior cutaneous nerve of the thigh ➡, inferior gluteal nerve and artery ➡, ascending circumflex femoral artery ➡, biceps-semitendinosus ➡, and semimembranosus ➡ ischial tuberosity attachment.* **(Right)** *Transverse US of the posterior thigh proximal to ischial tuberosity shows quadratus femoris ➡ & gluteus maximus muscles ➡ with intervening sciatic nerve ➡. Greater trochanter ➡ lies laterally.*

Ischial Tuberosity

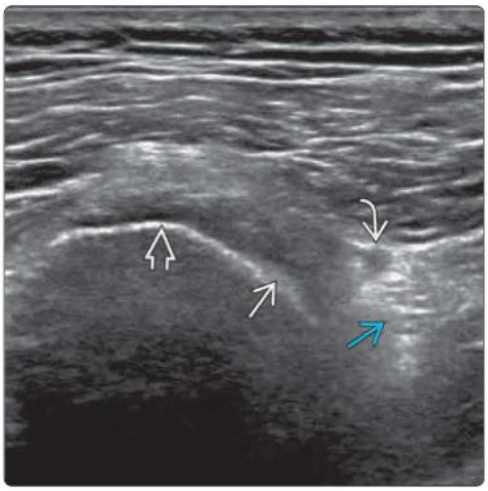

Proximal Thigh Musculature

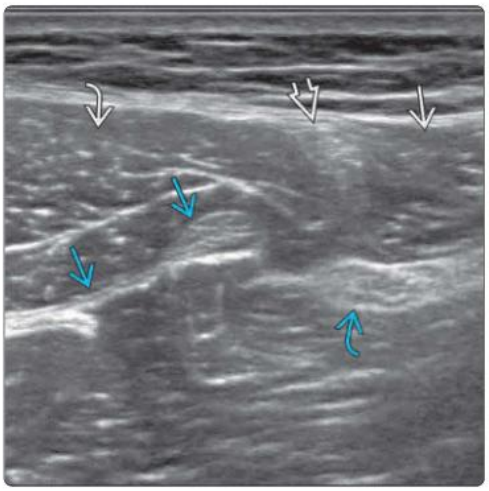

(Left) *Transverse US shows tendon attachment to ischial tuberosity. Conjoint semitendinous/biceps tendon ➡ attaches posteriorly, while semimembranosus tendon ➡ attaches laterally. Sciatic nerve ➡ and inferior gluteal artery ➡ are located lateral to tuberosity.* **(Right)** *Posterior aspect of the proximal thigh shows conjoint biceps/semitendinous tendon ➡ with biceps muscle ➡ laterally and semitendinous muscle ➡ medially. The sciatic nerve ➡ and semimembranosus tendon ➡ lie deep to these muscles.*

KEY FACTS

GENERAL CONSIDERATIONS

- Clinical indications for knee US
  - Knee effusion, synovitis, Baker cyst, medial collateral ligament (MCL) injury, parameniscal cyst, paraarticular ganglion, & quadriceps/patellar tendinosis/tear
- Less common specific indications
  - Pes anserinus & other bursitis, tendinosis/tear of other tendons besides patella & quadriceps tendons, gout, lateral collateral ligament injury, & peroneal nerve pathology

TECHNIQUE

- **Anterior knee**
  - Patient lying supine on examination table ± slight flexion
    - Anterior knee joint
    - Quadriceps tendon
    - Patellar bone & patellar tendon
    - Patellar retinacula
    - Anterior cruciate ligament
- **Medial knee**
  - Supine with knee externally rotated
    - MCL
    - Body of medial meniscus
    - Semimembranosus tendon
    - Pes anserinus tendons (semitendinosus, gracilis, & sartorius)
- **Lateral knee**
  - Lateral decubitus with knee extended
    - Distal iliotibial band
    - Lateral collateral ligament
    - Popliteus tendon
    - Biceps femoris tendon
- **Posterior knee**
  - Prone with knee extended
    - Gastrocnemius-semimembranosus bursa (Baker cyst)
    - Tibial & peroneal nerves
    - Posterior cruciate ligament

Scan Position for Anterior Knee

Quadriceps Tendon

(Left) *Clinical photograph shows scan position for the anterior knee, especially for patellar and quadriceps tendons. To assess fluid in patellar recesses, the knee is placed flat.* **(Right)** *Longitudinal US shows multilaminated quadriceps tendon ➡ inserting into superior pole of patella. Suprapatellar and prefemoral fat pads ➡ are visible as is trochlear cartilage ➡. Suprapatellar recess is not distended ➡. Most superficial lamina ➡ passes superficial to patella as the "prepatellar quadriceps continuation."*

Quadriceps Tendon: Short Axis

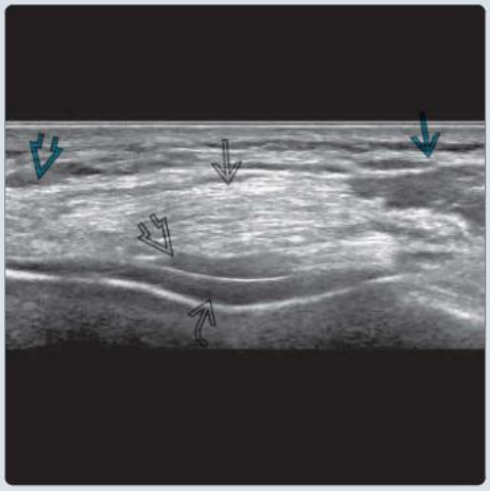

"Prepatellar Quadriceps Continuation"

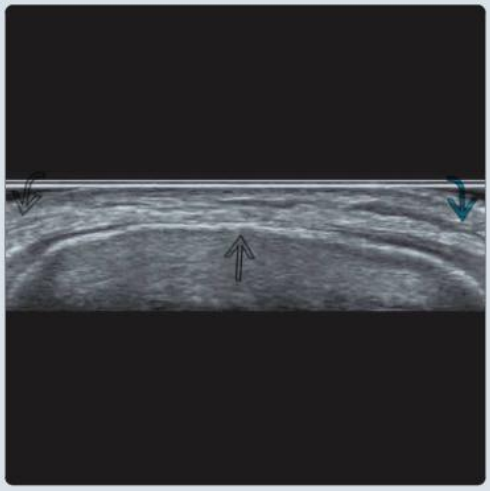

(Left) *Transverse US shows the quadriceps tendon ➡, suprapatellar recess containing a small amount of fluid ➡, and trochlear hyaline cartilage ➡. The vastus medialis extends more distally ➡ than the vastus lateralis ➡, which is tendinous at this level.* **(Right)** *Longitudinal US of the anterior aspect of the patella shows how superficial fibers of the quadriceps ➡ tendon proximally pass superficial to the patella ➡ as the "prepatellar quadriceps continuation" to connect with the superficial fibers of the patellar tendon ➡ distally.*

GENERAL CONSIDERATIONS

Clinical Indications for Knee US

- US is preferred investigation for all suspected extraarticular knee pathology as well as joint effusion & synovial proliferation
- Common specific indications are knee effusion, synovitis, Baker cyst, medial collateral ligament (MCL) injury, parameniscal cyst, paraarticular ganglion, & quadriceps/patellar tendinosis/tear
- Less common specific indications are pes anserinus & other bursitis, tendinosis/tear of other tendons besides patella & quadriceps tendons, lateral collateral ligament (LCL) injury, & peroneal nerve pathology
- Guides diagnostic & therapeutic intervention

TECHNIQUE: ANTERIOR KNEE

Patient Position

- Patient lying supine on examination table
  - Slight flexion (30°) helps minimize anisotropy of quadriceps & patellar tendons
    - More flexion (45-60°) is required to see anterior cruciate ligament (ACL)
    - Full flexion best for seeing femoral trochlear cartilage
  - Best to assess color flow in relaxed, extended position
  - Standing can accentuate meniscal extrusion & joint space narrowing
  - Standing or decubitus positions can help appreciate mobility of intraarticular bodies
  - Squatting may accentuate small parameniscal cysts of anterior horn lateral meniscus
  - Full extension of relaxed knee allows medial subluxation of patella to view medial retropatellar articular cartilage

Specifically Examine

- **Anterior knee joint**
  - Transverse scanning at medial & lateral aspects of patella to view medial & lateral patellar recess
    - Assess joint fluid & synovial thickening
      - Normal synovium is too thin to see clearly
  - Longitudinal scanning of suprapatellar region to view suprapatellar recess
    - Notice suprapatellar & prefemoral fat pads
      - Joint recess lies between these 2 pads
    - Nondistended suprapatellar recess is seen as thin, hypoechoic line
    - If distended, suprapatellar plica may be seen
  - Fluid tends to collect more in parapatellar recesses rather than suprapatellar recess
    - Mild fluid distension of 1 recess is normal, while fluid seen in ≥ 2 recesses indicates effusion
- **Quadriceps tendon**
  - Scan longitudinally & transversely
  - Quadriceps tendon is taut with knee slightly flexed & lax when knee is extended
    - Tendon has multilayered appearance (3-4 layers), though often only superficial layer is distinct
    - Rectus femoris → superficial layer
      - Extends over surface of patella as "prepatellar quadriceps continuation"
    - Vastus medialis & lateralis → intermediate layer
      - These 2 muscles also insert into superomedial & superolateral aspects of patella
      - Musculotendinous junction of vastus medialis lower than that of vastus lateralis
    - Vastus intermedius → deep layer
- **Patellar bone & patellar tendon**
  - Examine in longitudinal & transverse planes
  - Proximal & distal ends of patellar tendon expand slightly
  - More superficial fibers of patellar tendon are continuous "prepatellar quadriceps continuation"
  - Hoffa fat pad seen deep to patellar tendon
  - Below distal end of patellar tendon is deep infrapatellar bursa
    - Small amount of fluid in this bursa is normal
  - Normal prepatellar & superficial infrapatellar bursa cannot be seen
- **Patellar retinacula**
  - Scan in transverse plane over medial & lateral patellar recesses to see bilaminar patellar retinacula
  - Follow posteriorly to insertion into MCL medially & iliotibial band laterally
  - Medial patellofemoral ligament (MPFL) is most important medial stabilizer of patellofemoral joint
    - Contributes > 50% of medial patellar stability
    - Extends from superomedial aspect patella → Nomura point between medial epicondyle & adductor tubercle
    - Wraps over femoral attachment of MCL on way to Nomura point
    - Visible on US as 1- to 3-layered structure that fuses posteriorly
    - Patellar portion is thicker than tapering femoral portion
- **Femoral trochlear cartilage**
  - Knee fully flexed to see femoral trochlear cartilage in transverse & longitudinal planes
  - Knee extended, relaxed, & patella moved medially to show periphery of medial retropatellar cartilage
- **ACL**
  - Scanning longitudinally with knee flexed to 45-60°
  - Place transducer longitudinally below patella & rotate toward medial aspect lateral femoral condyle
  - Distal portion of ACL can be seen but is not routinely assessed with US

TECHNIQUE: MEDIAL KNEE

Patient Position

- Supine with knee externally rotated
  - Placing knee on firm pad can help valgus stretch for medial knee ligaments & joint space

Specifically Examine

- **MCL**
  - Examined in both longitudinal & transverse planes
  - 3-layered structure, but uppermost layer (deep fascia) is not visible on US
    - Superficial layer extends from medial femoral epicondyle → tibia 5 cm below medial joint line
      - 2-layered hyperechoic band that is most characteristically recognized as MCL on US
      - Posteriorly merges with posterior oblique ligament

        - Proximally, MPFL wraps over femoral attachment of MCL
    - Deep layer composes meniscofemoral & meniscotibial bands
        - Both bands are tightly attached to medial meniscal body but loosely attached to superficial layer of MCL
- **Body of medial meniscus**
    - Normal medial meniscus is separated from MCL by loose hypoechoic connective tissue, which is usually echo poor
        - Meniscal degeneration, deformation, & extrusion are accentuated on weight bearing
- **Semimembranosus tendon**
    - Scan in transverse plane over posteromedial knee to identify large semimembranosus tendon
    - Follow tendon distally to see direct arm inserting into shallow groove at posteromedial corner tibia
        - 3 other insertions of semimembranosus are anterior arm, capsular arm, & oblique arm
            - Anterior arm → medial tibia deep to MCL
            - Capsular arm → posterior oblique ligament
            - Oblique arm → oblique popliteal ligament
        - All arms can be seen on US but not routinely assessed
- **Pes anserinus tendons (semitendinosus, gracilis, & sartorius)**
    - Best scanned in transverse plane
    - Identify semitendinosus at posteromedial aspect knee
        - Seen as "cherry on pie" with semitendinosus tendon sitting atop semimembranosus muscle
    - Follow transversely to insertion at anteromedial aspect proximal tibia
    - Identify other 2 pes anserinus tendons in transverse plane & follow distally to insertion
    - Alternatively, follow MCL in longitudinal plane distally
        - At distal end of tibial MCL insertion, move transducer anteriorly to see pes anserinus tendons
    - Pes anserinus tendons are arranged linearly with fleshy sartorius anteriorly & semitendinosus posteriorly
        - Slender gracilis tendon lies between sartorius & semitendinosus tendons

TECHNIQUE: LATERAL KNEE

Patient Position

- Lateral decubitus with knee extended ± firm pad under knee to help varus stretch for lateral knee ligament & joint space
- Supine & internally rotated for anterolateral structures
- Prone & externally rotated for posterolateral structures

Specifically Examine

- **Distal iliotibial band**
    - Best examined mainly in longitudinal plane
    - Thin, tubular structure inserts into Gerdy tubercle anterolateral aspect proximal tibia
        - Iliotibial band fans out before insertion
    - Proximally, passes close to lateral femoral condyle
- **LCL**
    - Scan longitudinally with knee slightly flexed (30°), as this stretches ligament
    - Place transducer over fibular head & then rotate proximal end of transducer ~ 20° to align along LCL
        - LCL is thicker, more rounded than MCL & fans out at both femoral & fibular attachments
- **Popliteus tendon**
    - Located using longitudinal plane within popliteal sulcus deep & just anterior to femoral attachment LCL
    - Mild knee flexion can improve visibility of proximal end of popliteus tendon
- **Biceps femoris tendon**
    - Scan longitudinally posterolateral aspect of knee
    - Biceps femoris shares common insertion with LCL to posterolateral aspect of proximal fibula
        - Short & long heads of biceps femoris each have 2 tendon insertions (direct & anterior heads)
        - Direct heads of both tendons → fibular head

TECHNIQUE: POSTERIOR KNEE

Patient Position

- Prone with knee extended
- Flexion of knee may improve visibility of Baker cyst pedicle

Specifically Examine

- **Gastrocnemius-semimembranosus (Baker cyst)**
    - Identify medial margin of medial belly gastrocnemius in calf
        - Scan proximally along this medial margin in transverse plane to junction with semimembranosus tendon medially
        - Pedicle of Baker cyst, if present, will be located between these 2 structures
        - Anisotropy is common at gastrocnemius muscle-semimembranosus tendon interspace
            - Do not confuse this with small Baker cyst
- **Tibial & peroneal nerves**
    - Tibial nerve located superficial to popliteal artery & vein
        - Peroneal nerve branches off lateral side of tibial nerve, usually in distal thigh
    - Peroneal nerve best identified on transverse scanning, either arising from parent nerve or deep to distal part of biceps femoris muscle
        - Follow peroneal nerve transversely around fibular head where it divides into deep & superficial branches
- **Posterior cruciate ligament (PCL)**
    - Scan in oblique longitudinal plane with proximal end of transducer aligned 30° toward medial side
    - Distal 2/3 of PCL can be seen with US
        - Seen as thick, hypoechoic, cord-like structure inserted into posterior part of proximal tibia
- **Posterolateral corner structures**
    - Fabellofibular ligament
    - Popliteofibular ligament
    - Posterolateral capsule
    - All of these small structures can be seen but are not routinely assessed with US

SELECTED REFERENCES

1. Wu WT et al: Ultrasound imaging of the posterior lateral corner of the knee: a pictorial review of anatomy and pathologies. Insights Imaging. 15(1):39, 2024

Scan Position for Medial Patellar Recess

Lateral Patellar Recess

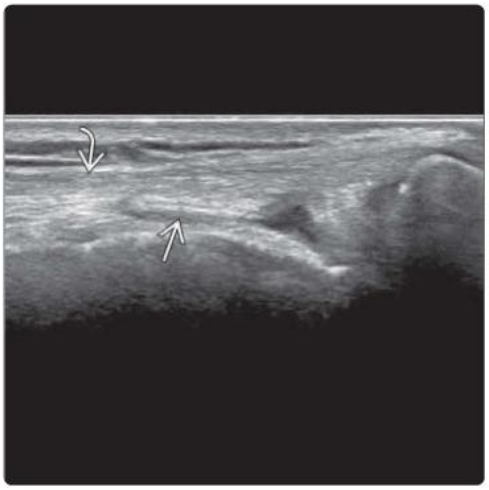

(Left) *Clinical photograph shows scan position for the medial patellar recess. The medial and lateral patellar recesses are best examined when the knee is extended or only slightly (10°) flexed.* **(Right)** *Transverse US shows the lateral patellar recess ➡ deep to the lateral retinaculum ➡. The slightly hypoechoic normal synovium is seen along with a very small amount of joint fluid. This is normal. The medial patellar recess will have a similar appearance.*

Medial Patellofemoral Ligament

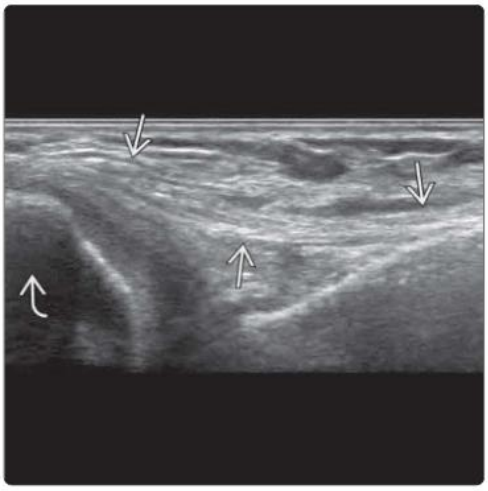

Patellar Tendon: Proximal Portion

(Left) *Transverse US shows the medial patellofemoral ligament (MPFL) ➡ extending from the proximal medial aspect of the patellar bone ➡ toward femoral attachment of the medial collateral ligament (MCL).* **(Right)** *Longitudinal US shows normal proximal patellar tendon. Superficial fibers extend over the anterior surface of the patella ➡, while deep fibers are hypoechoic ➡ due to anisotropy. Normal appearance and absence of hyperemia help distinguish this hypoechogenic area from tendinosis.*

Patellar Tendon: Distal Portion

Patellar Tendon: Short Axis

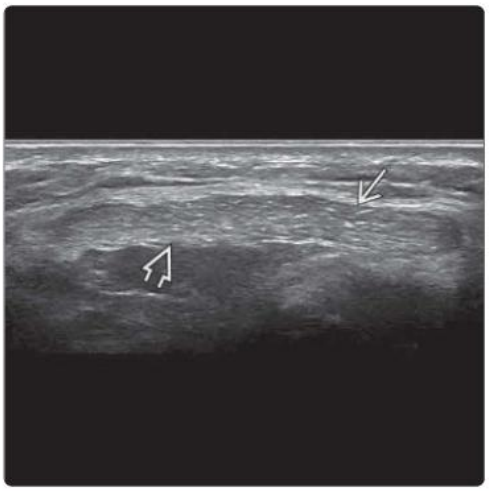

(Left) *Longitudinal US shows the distal part of the patellar tendon ➡ inserting into the anterior tibial tuberosity ➡. The patellar tendon does normally widen at this level.* **(Right)** *Transverse US shows the transverse section of the midportion of the patellar tendon ➡. The normal paratenon ➡ is seen as an echogenic layer anteriorly.*

(Left) *Transverse US shows normal femoral trochlea hyaline cartilage ⇨. The quadriceps tendon ⇨ lies close to the femoral trochlea.* **(Right)** *Longitudinal US obtained with the knee in full flexion shows the tibial portion of the anterior cruciate ligament (ACL) ⇨. The probe is angled toward the lateral femoral condyle. US only provides a limited view of the ACL. This is not assessed in routine clinical practice.*

Femoral Trochlear Articular Cartilage

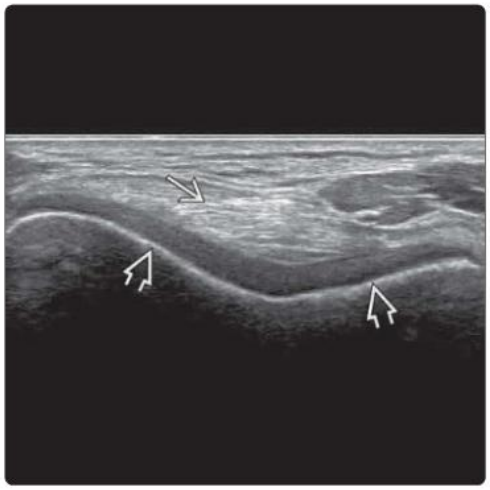

Anterior Cruciate Ligament

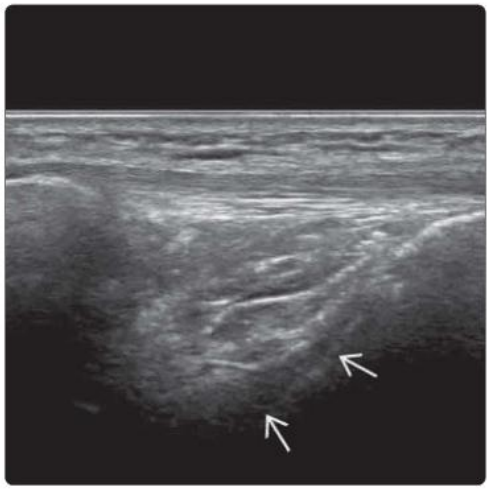

(Left) *Clinical photograph shows scan position for the medical knee, which is best examined in a decubitus position with the knee extended. From this position, rotate the knee posteriorly for anteromedial aspect and anteriorly for posteromedial corner.* **(Right)** *Longitudinal US shows the periphery of the body of the medial meniscus ⇨ deep to the MCL ⇨. Extrusion and deformation of the meniscus can be appreciated and accentuated by weight bearing.*

Scan Position for Medial Knee

Medial Collateral Ligament

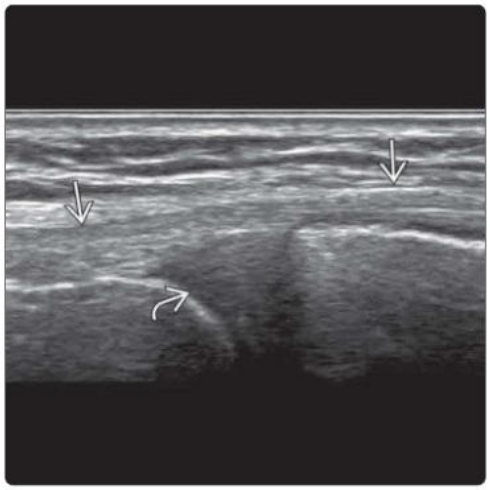

(Left) *Longitudinal US shows the femoral attachment ⇨ of the MCL. This is a main side of MCL tear, especially the anterior part of the insertion. The meniscofemoral and meniscotibial bands are seen ⇨ deep to the superficial component of the MCL ⇨.* **(Right)** *Transverse US shows the MPFL ⇨ passing superficial to the femoral attachment of the MCL ⇨. The posterior oblique ligament ⇨ is continuous with the posterior margin of the MCL attachment.*

Femoral Attachment of Medial Collateral Ligament

Femoral Attachment of Medial Collateral Ligament

Distal Semimembranous Tendon

Pes Anserinus Tendons

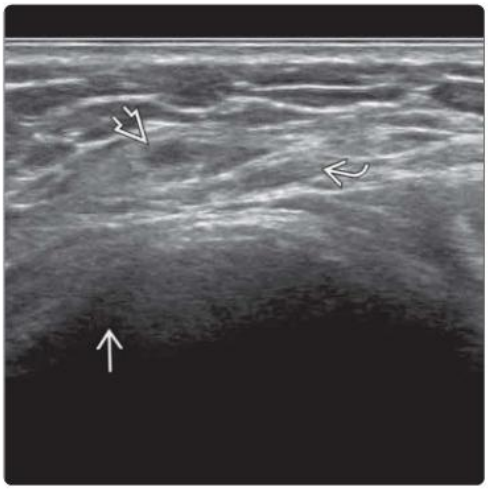

(Left) *Longitudinal US of posteromedial aspect knee shows the direct arm of the semimembranosus tendon ⇨ inserted into a shallow groove on the posteromedial aspect of the proximal tibia ⇨. The semimembranosus tendon also has anterior, capsular, and oblique arms.* **(Right)** *Transverse US of the posteromedial corner of the knee shows the gracilis ⇨ and sartorius ⇨ tendons. These pes anserinus tendons, together with the semitendinosus, insert into the anteromedial aspect of the proximal tibia ⇨.*

Scan Position for Lateral Knee

Iliotibial Band

(Left) *Clinical photograph shows scan position for the lateral knee, which is best examined in a decubitus position with the knee extended. From this position, rotate the knee posteriorly for the anterolateral aspect and anteriorly for the posterolateral corner.* **(Right)** *Longitudinal US shows a normal, thickened distal portion of the iliotibial band ⇨ inserting into the anterolateral aspect of the proximal tibia (Gerdy tubercle) ⇨.*

Iliotibial Band

Lateral Collateral Ligament: Fibular Attachment

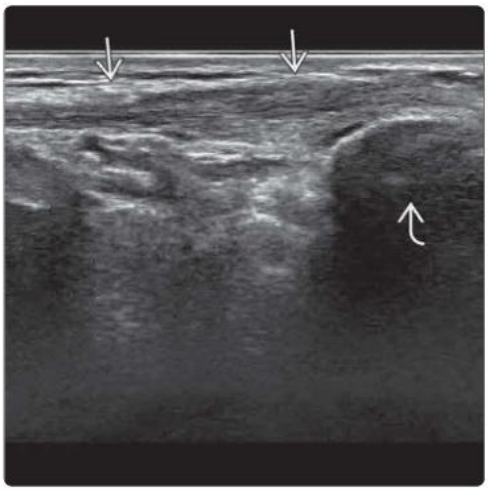

(Left) *Longitudinal US more proximal shows the iliotibial band ⇨ passing alongside the lateral aspect of the lateral femoral condyle ⇨. Friction between the iliotibial band the femoral condyle can lead to iliotibial band friction syndrome.* **(Right)** *Longitudinal US shows a normal, thickened distal portion of lateral collateral ligament (LCL) ⇨ attached to the proximal fibula ⇨. The proximal end of the transducer is angled ~ 20° anteriorly to align with the LCL.*

Lateral Collateral Ligament: Femoral Attachment

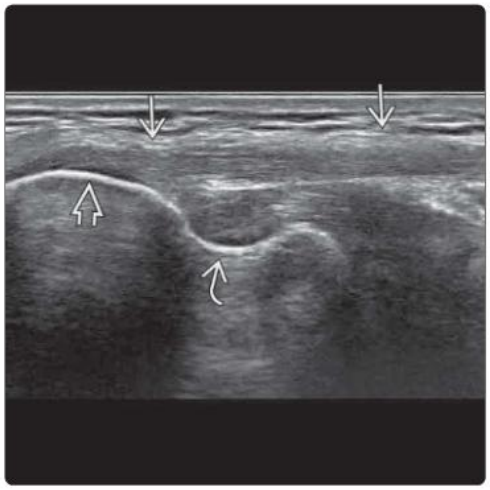

Popliteus Tendon

(Left) *Longitudinal US shows the proximal attachment of the LCL ➡ to the lateral aspect of the femoral condyle ➡ just proximal to the sulcus ➡ for the popliteus tendon attachment. The normal LCL fans out slightly at proximal and distal ends.* **(Right)** *Longitudinal US shows the proximal portion of the popliteus tendon ➡ attached to a groove ➡ in the lateral aspect of the femur just distal to the attachment of the LCL.*

Biceps Femoris Insertion

Scan Position for Posterior Knee

(Left) *Longitudinal US shows the broad attachment of the direct arm of the biceps femoris tendon ➡ to the posterolateral aspect of the proximal fibula ➡. This tendon is aligned vertically, as opposed to the LCL, which aligns toward the lateral femoral condyle.* **(Right)** *Clinical photograph shows scan position for the posterior knee. This is best examined with the patient lying prone and the knee extended.*

Gastrocnemius-Semimembranosus Recess

Tibial Nerve

(Left) *Transverse US of the posteromedial aspect of the knee shows the potential space ➡ between the medial belly of the gastrocnemius ➡ and the semimembranosus ➡ and semitendinosus ➡ tendons through which Baker cysts extend.* **(Right)** *Transverse US shows the tibial nerve ➡ superficial to the popliteal artery and vein ➡ at the proximal end of the popliteal fossa. The peroneal nerve ➡ has already arisen from the lateral side of the tibial nerve.*

Tibial Nerve

Peroneal Nerve

(Left) *Longitudinal US shows the tibial nerve ⇨ located posterior to the popliteal artery and vein ⇨. The vein is effaced from transducer pressure and is usually located either alongside the artery or between the artery and nerve.* **(Right)** *Transverse US shows the peroneal nerve ⇨ seen passing toward the fibular head alongside the biceps femoris muscle ⇨.*

Peroneal Nerve

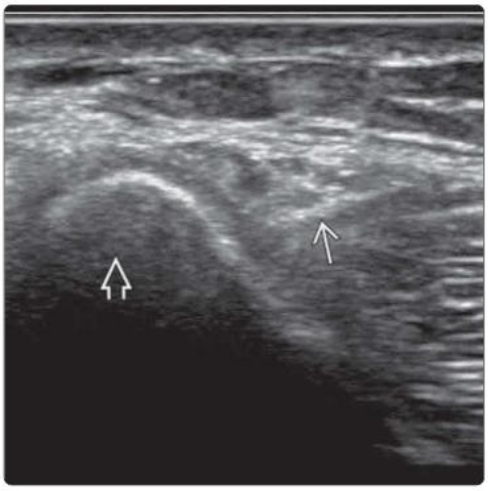

Peroneal Nerve

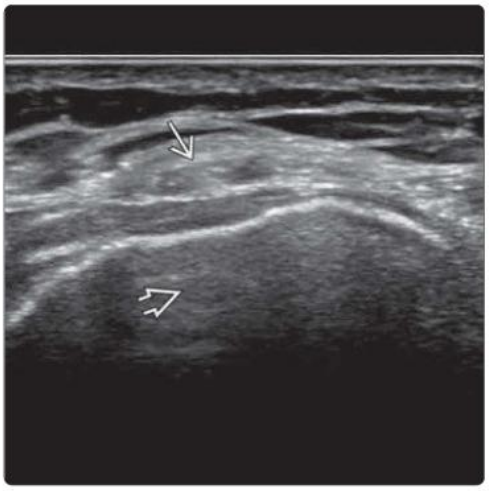

(Left) *US shows the peroneal nerve ⇨ just alongside the fibular head ⇨.* **(Right)** *Transverse US shows the peroneal nerve ⇨ passing posterior to the fibular head ⇨.*

Peroneal Nerve

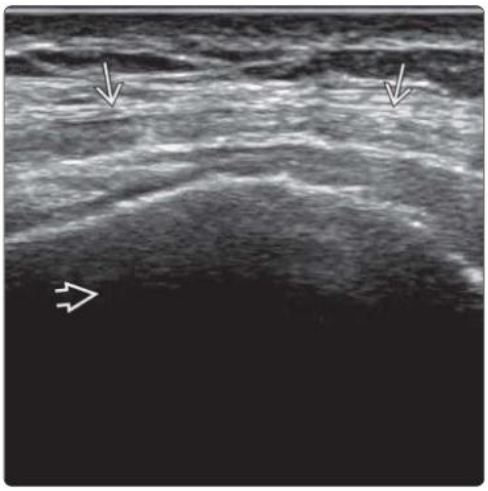

Posterior Cruciate Ligament

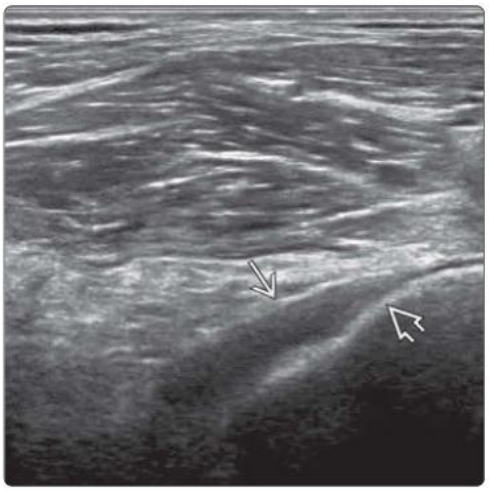

(Left) *Oblique longitudinal US shows the long axis of the peroneal nerve ⇨ passing posterior to the fibular head ⇨. The nerve will soon divide into its superficial and deep peroneal branches.* **(Right)** *Longitudinal US of the posterior knee shows the tibial portion of the posterior cruciate ligament ⇨, which is attached to the posterior aspect of the tibia ⇨ in the midline. To obtain this view, the proximal end of the probe is angled toward the inner aspect of the medial femoral condyle.*

KEY FACTS

GENERAL CONSIDERATIONS

- Common specific indications: Ligament tear, tendon disorders, & suspected joint infection & inflammation
- Less common specific indications: Suspected tarsal tunnel syndrome, impingement, & ganglia

TECHNIQUE

- **Anterior ankle**
  - Patient supine with knee flexed so that sole of foot is flat on examination couch
    - Anterior recess ankle joint
    - Anterior ankle tendons
    - Tibialis anterior tendon
    - Extensor digitorum longus tendon
    - Superior & inferior extensor retinacula
    - Deep peroneal nerve
- **Medial ankle**
  - Patient supine with hip abducted & knee flexed
    - Tibialis posterior tendon
    - Flexor digitorum tendon
    - Flexor hallucis longus tendon
    - Deltoid ligament
    - Tibial nerve & tarsal tunnel
- **Lateral ankle**
  - Rotate foot internally ± place firm pad under heel for examination of retromalleolar region
    - Anterior tibiofibular ligament
    - Anterior talofibular ligament
    - Calcaneofibular ligament
    - Peroneal tendons
    - Superficial peroneal nerve
- **Posterior ankle**
  - Patient prone with foot hanging over end of examination couch
    - Achilles tendon
    - Plantaris tendon
    - Sural nerve

Scan Position for Anterior Ankle

Anterior Ankle Recess

(Left) *Clinical photograph shows the patient position for scanning the anterior ankle. The patient lies on the examination couch with the knee flexed and the sole of the foot resting on the couch.* **(Right)** *Longitudinal US of the midline anterior aspect of the ankle joint shows the distal tibia, anterior capsule, intraarticular extrasynovial fat pad, and articular cartilage covering the talar dome. The anterior ankle joint should be scanned from medial to lateral.*

Tibialis Anterior and Extensor Hallucis Longus

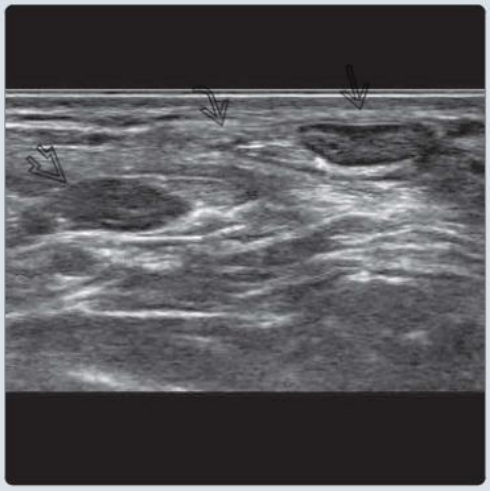

Extensor Digitorum Longus

(Left) *Transverse US just proximal to the ankle joint shows the tibialis anterior and extensor hallucis longus tendons lying deep to the superior band of the extensor retinaculum.* **(Right)** *Transverse US shows the extensor digitorum longus tendon at the level of the ankle joint just deep to the extensor retinaculum. The tendon has just divided into its digital slips. Note the proximity of the lateral aspect of the ankle to the skin. This makes the lateral ankle a preferred site for intraarticular injection.*

GENERAL CONSIDERATIONS

Clinical Indications for Ankle US

- Nearly all common conditions of ankle region are amiable to full assessment by US
- Common specific indications are ligament tear, tendon disorders, including Achilles tendon (AT), suspected joint infection or inflammation
- Less common specific indications are suspected tarsal tunnel syndrome, impingement, & ganglia

TECHNIQUE: ANTERIOR ANKLE

Patient Position

- Supine with knee flexed so that sole of foot is flat on examination couch

Specifically Examine

- **Anterior recess ankle joint**
  - Much more accessible than posterior recess & routinely examined
  - Absence of joint effusion makes significant intraarticular pathology very unlikely
  - Scan in longitudinal plane from most medial side to most lateral side
    - Capsule attached to tibia 10 mm proximal to articular margin & to talar body/neck junction distally
    - Extrasynovial anterior fat pad lies deep to capsule
    - Joint to skin distance is less lateral than medial; hence, lateral approach for injection is preferable
- **Anterior ankle tendons**
  - Mnemonic is "Tom [**t**ibialis anterior (TA)], Harry (extensor **h**allucis), & Dick (extensor **d**igitorum)" from medial → lateral
  - Anterior ankle tendons less frequently affected by disease or injury than other ankle tendons
  - Scan primarily in transverse section from distal leg to insertion
- **TA tendon**
  - Seen on anteromedial aspect of ankle to be ~ 2x as large as other extensor tendons; ovoid-shaped as opposed to more flattened shape of other extensor tendons
  - Proximally, TA tendon has tenosynovium, whereas, distally, it has paratenon
  - In 25% of patients, superior extensor retinaculum splits into 2 to form separate TA tunnel
    - TA passes deep to or within superior retinaculum but superficial to inferior retinaculum
  - Scan distal insertion of TA tendon in longitudinal plane with foot slightly everted
    - Inserts into dorsomedial aspect of medial cuneiform
- **Extensor hallucis longus tendon**
  - Seen as thin tendon that moves on passive flexion/extension of big toe
    - Inserts as aponeurotic sheath onto dorsal aspect of base of distal phalanx big toe
- **Extensor digitorum longus (EDL) tendon**
  - Seen on anterolateral aspect of ankle
    - Splints into 4 tendon slips after passing deep to extensor retinacula → middle & distal phalanges of toes
- **Superior & inferior extensor retinacula**
  - Seen as thin (< 1.5-mm), echogenic bands covering extensor tendons
  - Superior retinaculum is rectangular-shaped & located (6-9 mm) proximal to ankle joint
    - From distal fibula laterally to distal tibia medially
  - Inferior retinaculum seen just distal to ankle joint & is Y-shaped
    - Stem attached to lateral hindfoot → 2 limbs
      - Oblique superomedial limb → medial malleolus
      - Oblique inferomedial limb → cuneonavicular joint
- **Deep peroneal nerve (DPN)**
  - Seen on transverse scanning of tibial artery at ankle where nerve crosses from medial → lateral side of artery
    - Usually best seen on medial side of artery just proximal to ankle joint
    - DPN compression deep to inferior retinaculum termed anterior tarsal tunnel syndrome

TECHNIQUE: MEDIAL ANKLE

Patient Position

- Patient supine with hip abducted & knee flexed (frog-leg position)

Specifically Examine

- **Tibial nerve & tarsal tunnel**
  - Lies posterior & inferoposterior to medial malleolus bounded superficially by flexor retinaculum
  - Contains "Tom [**t**ibialis posterior (TP)], Dick [flexor **d**igitorum (FD)], & a very nervous (**a**rtery, **v**ein, tibial **n**erve) Harry [flexor **h**allucis longus (FHL)]"
  - Tibial nerve lies alongside posterior tibial artery & veins between FD & FHL
  - Compression of tibial nerve within confines of tarsal tunnel leads to tarsal tunnel syndrome
  - Small medial calcaneal nerve arises from tibial nerve or lateral plantar nerve proximal to, within, or distal to tarsal tunnel
    - Highly variable in position & number & difficult to see
  - In 80% of patients, tibial nerve divides in tarsal tunnel into medial & lateral plantar nerves
    - Inferior calcaneal nerve is 1st branch of lateral plantar nerve (supplies abductor digiti minimi muscle; compression mimics plantar fasciitis, Baxter neuropathy)
- **TP tendon**
  - Scan primarily in transverse plane from supramalleolar region to insertion
  - Inspect supra-, retro-, infra-, & premalleolar segments, keeping transducer at right angles to tendon
  - TP tendon lies in shallow groove behind medial malleolus, which acts as pulley
  - Covered by thick flexor retinaculum with hyaline cartilage more deeply (pulley enthesis)
  - Normally, TP is ~ 2x size of FD tendon
  - Small TP tendon sheath effusion is normal
  - Insertional area best seen on longitudinal scanning
    - Just before insertion, TP widens & angles deeply, making it prone to anisotropy
    - Plantar flexion of foot can increase visibility of insertional fibers

- Superomedial calcaneonavicular ligament (CNL) component of spring ligament between talus & distal TP tendon
  - Extends from sustentaculum tali → navicular bone
  - Normally < 4 mm thick
  - "Gliding layer" of loose areolar tissue superficial to & articular fibrocartilage deep to CNL
- Accessory navicular bone is common finding & strongly associated with pes planus
- 3 types of accessory navicular bone
  - Small accessory bone not directly attached to navicular bone
  - Large accessory bone with synchondrotic attachment to navicular bone
  - Large accessory bone with osseous fusion to navicular bone
- TP tendon partially attaches to all 3 types
- Cornuate configuration with elongated medial pole of navicular bone is also common finding

- **FD tendon**
  - Located posterolateral to TP & usually not affected by tendinosis; hence, FD used as reference for TP tendon size; passes superficial to sustentaculum tali
- **FHL tendon**
  - Scan longitudinally at posterior ankle deep & medial to AT
  - Scan transversely at posterior ankle to see FHL passing between medial & lateral posterior processes of talus
  - Scan in coronal plane inframalleolar region to see FHL deep to sustentaculum tali
    - Passive flexion & extension of big toe can increase FHL visibility
  - As FHL tendon sheath commonly communicates with ankle, FHL tendon sheath effusions are common
- **Deltoid ligament**
  - Deep (anterior & posterior tibiotalar) & superficial (tibionavicular, tibiospring, tibiocalcaneal) components
  - Scan in longitudinal plane with proximal end of transducer on medial malleolus ± foot dorsiflexion to tense ligament
  - Superficial component seen as thinner, vertical band from medial malleolus → sustentaculum tali, spring ligament, & navicular bone
  - Deep component seen as triangular, striated, echogenic tissue with wide portion attached to talus
    - Anisotropy at talar aspect due to fiber obliquely is normal finding

TECHNIQUE: LATERAL ANKLE

Patient Position

- Rotate foot internally ± place firm pad under heel for examination of retromalleolar region

Specifically Examine

- **Anterior tibiofibular ligament**
  - Scan at distal end of tibia in oblique transverse plane
  - Align transducer along line extending from distal end of lateral malleolus to supramalleolar area of medial malleolus
    - Seen as thin, striated band connecting tibia & fibula; wider at tibial attachment
- **Anterior talofibular ligament (ATFL)**: Place transducer on tip on lateral malleolus & scan transversely or slightly downward along length of ATFL
  - ATFL seen as linear, striated band, 2 mm thick, between fibular & talus with anterolateral gutter deep to ligament; small artery & vein superficial to ATFL
- **Calcaneofibular ligament (CFL)**
  - Seen deep on transverse scanning of peroneal tendon
  - Place transducer along line from anterior tip of lateral malleolus to posteroinferior corner of heel
  - Dorsiflexion tenses CFL & elevates peroneal tendons
  - Angle transducer to reduce anisotropy at fibular insertion
- **Peroneal tendons**
  - Scan in transverse plane from supramalleolar region → midfoot
  - In retromalleolar region, peroneal brevis tendon seen deep to peroneus longus tendon
    - Peroneus brevis tendon is < 1/2 size of peroneal longus & is more oblong in shape
  - Note retinaculum & fibrocartilaginous anchor attached to posterolateral corner fibula; ± dorsiflex & invert ankle to see if peroneal tendons sublux (external or internal)
  - When following tendons around lateral malleolus in transverse plane, follow 1 tendon at a time
  - Peroneal tubercle (should be < 5 mm) may separate tendons at lateral part of calcaneum
  - Peroneus brevis → 5th metatarsal base
  - Peroneal longus → cuboid groove → medial cuneiform/1st metatarsal base; ± os peroneum (20% of patients) within tendon just proximal to groove
- **Superficial peroneal nerve**: Located alongside lateral intermuscular septum
  - Emerges at interspace between peroneus muscles & EDL muscle
  - Pierces crural fascia on anterolateral aspect of leg 9 cm (6-12 cm) proximal to fibular tip; can be stretched by fascia, giving rise to lateral ankle pain

TECHNIQUE: POSTERIOR ANKLE

Patient Position

- Prone with foot hanging over end of examination couch

Specifically Examine

- **AT**: Scanned in longitudinal & transverse planes from musculotendinous junction to calcaneal insertion; should be < 7 mm thick
  - Surrounded by paratenon rather than complete synovial sheath; Kager fat pad & retrocalcaneal bursa lie deeply
  - Inserts into posterior calcaneal tuberosity across 1-cm length with thin entheseal fibrocartilage between tendon & bone
- **Plantaris tendon**: Scan transversely on medial aspect of AT to see small, hypoechoic, oval-shaped plantaris tendon
  - Proximally, seen deep to medial belly of gastrocnemius
  - Distally, usually blends with AT
- **Sural nerve**: Scan transversely between AT & peroneal tendons; sural nerve seen just medial or lateral to short saphenous vein, which acts as marker for this nerve
  - Passes behind lateral malleolus deep to peroneal tendons

Tibialis Anterior Tendon Insertion

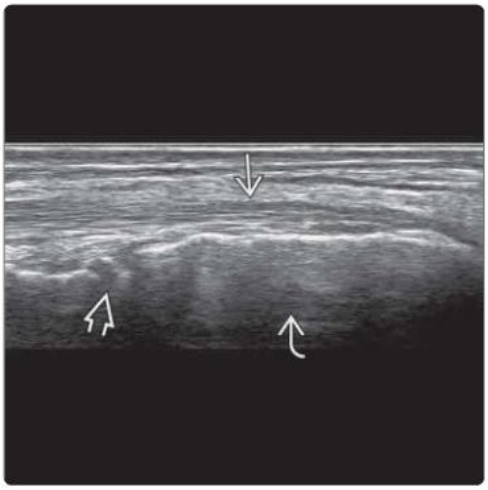

Deep Peroneal Nerve

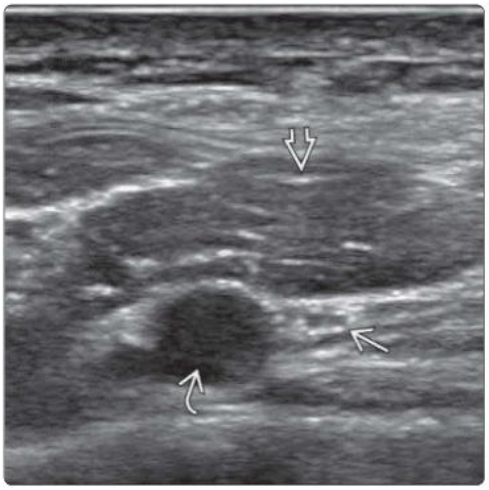

(Left) *Longitudinal US at the dorsomedial aspect of the midfoot shows the tibialis anterior tendon ⇨ inserted into the medial cuneiform ⇨. The navicular-cuneiform articulation ⇨ is also shown.* **(Right)** *Transverse US just proximal to the ankle joint shows the deep peroneal nerve ⇨ just medial to the anterior tibial artery ⇨ and deep to the extensor hallucis longus muscle ⇨. Slightly more distal to this location, the nerve passes to the lateral aspect of the anterior tibial artery.*

Anterior Tibiofibular Ligament

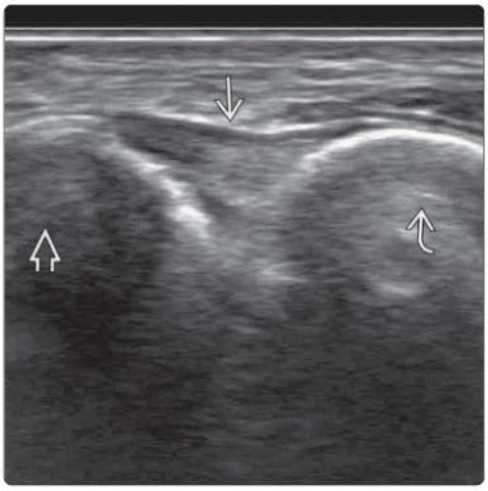

Anterior Talofibular Ligament

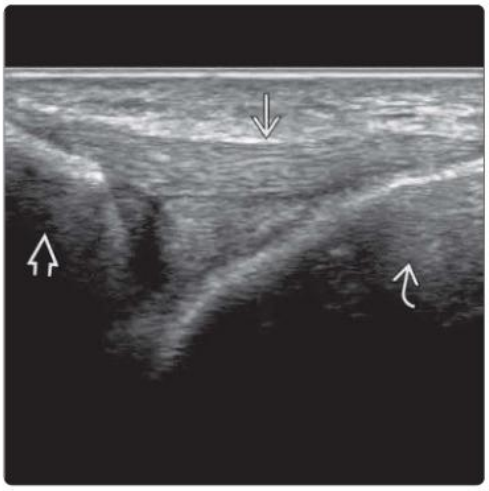

(Left) *Transverse oblique US immediately proximal to the ankle joint, with the medial side of the transducer angled ~ 45° proximally, shows the triangular-shaped anterior tibiofibular ligament ⇨ between the tibia ⇨ and fibula ⇨. The anterior tibiofibular ligament is wider at its tibial attachment.* **(Right)** *Transverse US at the level of the fibular tip ⇨ shows the anterior talofibular ligament ⇨ extending between the fibular tip and the talus ⇨.*

Scan Position for Lateral Ankle

Peroneal Tendons in Retromalleolar Area

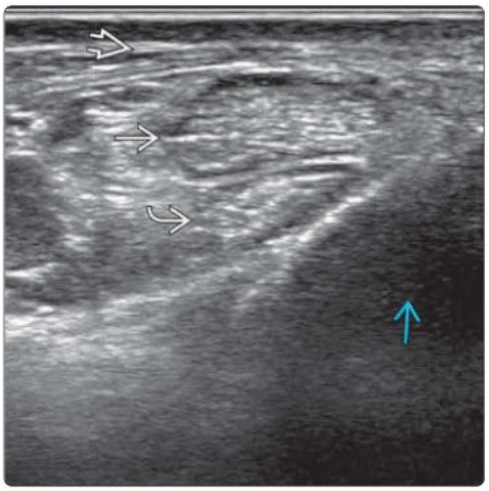

(Left) *Clinical photograph shows the position used for examination of the lateral ankle region. The heel can be placed in a firm pad. This allows easier transducer access to the retromalleolar region. Alternatively, the heel can be placed at the edge of the examination couch.* **(Right)** *Transverse US shows the peroneus longus ⇨ and brevis ⇨ tendons covered by the superior peroneal retinaculum ⇨ posterior to the distal fibula ⇨.*

(Left) *Transverse US at the more distal retromalleolar region shows the peroneus longus ➡ and peroneus brevis ➡ tendons posterior to the fibular tip ➡ and overlying the calcaneofibular ligament ➡ close to its fibular attachment.* **(Right)** *Transverse US shows the peroneus longus ➡ and brevis tendons ➡ overlying the lateral aspect of the calcaneum ➡ at the inframalleolar region.*

Peroneal Tendons in Retromalleolar Region

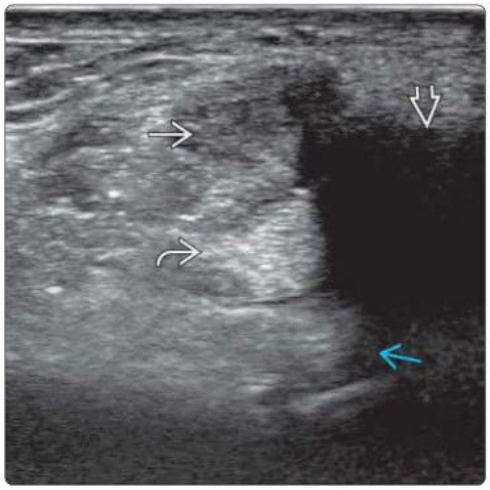

Peroneal Tendons in Inframalleolar Region

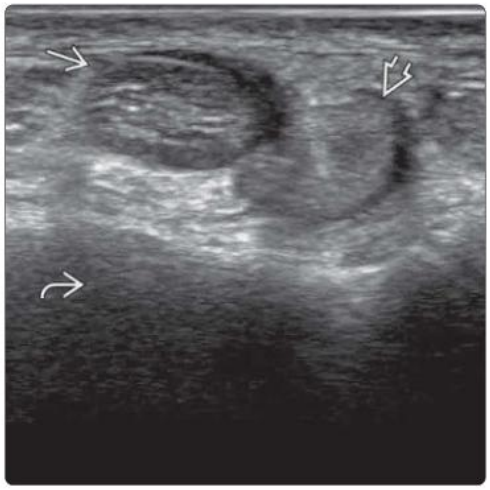

(Left) *Longitudinal US at the posteroinferior aspect of the fibular tip shows the distal part of the calcaneofibular ligament ➡ lying deep to the peroneal tendons ➡ and inserting into the lateral aspect of the calcaneum ➡.* **(Right)** *Longitudinal US along the proximal part of the calcaneofibular ligament ➡ shows the ligament below the peroneal tendons ➡. The fibular attachment ➡ is difficult to see due to acoustic shadowing. Integrity can be tested by dorsiflexing the ankle. Posterior talocalcaneal articulation ➡ is shown.*

Calcaneofibular Ligament

Calcaneofibular Ligament

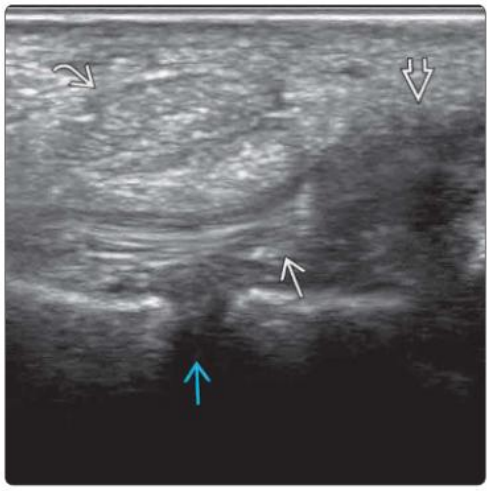

(Left) *Transverse US at mid- to lower leg laterally shows the superficial peroneal nerve ➡ emerging through the crural fascia at the interspace between the peroneal brevis ➡ and extensor digitorum longus ➡ muscles. The nerve can be injured indirectly at this location, giving rise to lateral ankle pain.* **(Right)** *Clinical photograph shows the patient position for scanning the medial ankle. The patient lies on the examination couch with the hip adducted, knee flexed, and the side of the ankle and foot resting on the couch (frog-leg position).*

Superficial Peroneal Nerve

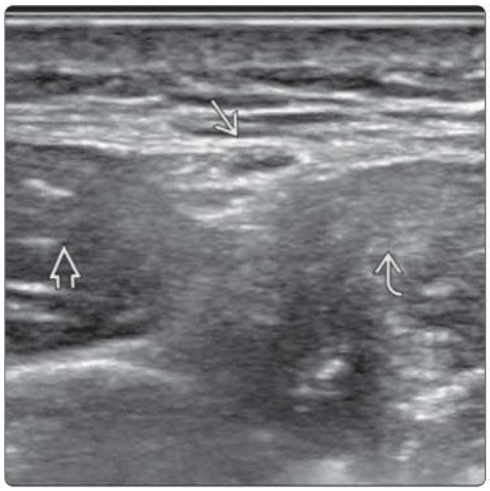

Scan Position for Medial Ankle

Tarsal Tunnel

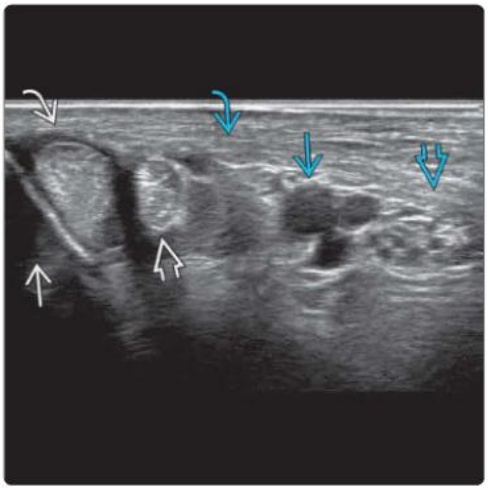

Retromalleolar Tibialis Posterior

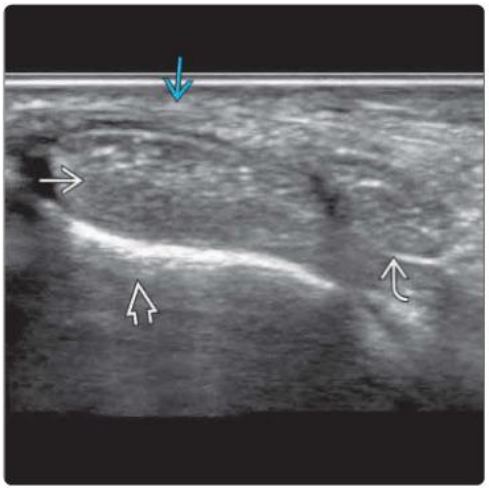

(Left) *Transverse US posterior to the medial malleolus shows the posterior tibialis tendon, flexor digitorum longus, posterior tibial artery and veins, and tibial nerve deep to the flexor retinaculum.* **(Right)** *Transverse US at the medial retromalleolar region shows the posterior tibialis and flexor digitorum longus tendons covered by the flexor retinaculum.*

Superomedial Fibers of Calcaneofibular Ligament

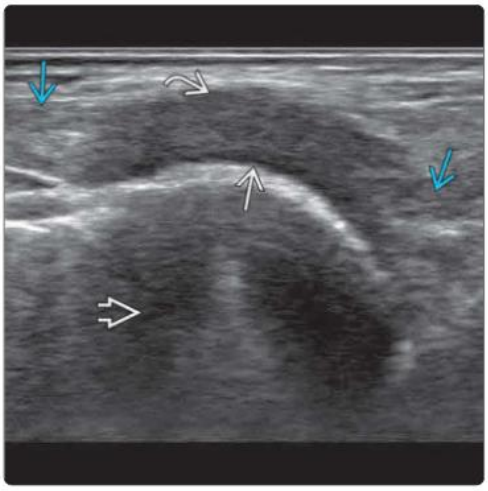

Tibialis Posterior Insertion

(Left) *Longitudinal US along superomedial fibers of the calcaneonavicular ligament, lying medial to talar head and just dorsal and deep to the tibialis posterior tendon, is shown. There is a thin layer of fibrocartilage between the fibers and bone. Fibers running to the tibia proximally and the navicular bone distally can be appreciated.* **(Right)** *Longitudinal US along the posterior tibialis tendon shows fibers inserting into the medial pole of the navicular bone. The tendon also inserts deeply into the cuneiform bones.*

Tibiospring Ligament

Tibiotalar Ligament

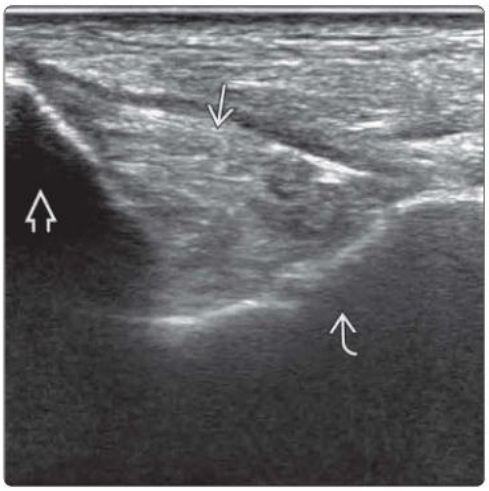

(Left) *Longitudinal US shows the tibiospring ligament extending from the medial malleolus to the superomedial fibers of the spring ligament.* **(Right)** *Longitudinal US shows the triangular-shaped posterior tibiotalar fibers extending between the medial malleolus and the talus.*

(Left) *Clinical photograph shows the scan position for the posterior ankle region. The patient's foot is dorsiflexed on the couch. Alternatively, the foot can hang freely over the end of the couch.* **(Right)** *Longitudinal US shows the musculotendinous junction of the Achilles tendon. The soleus muscle ➡ is attached to the undersurface of the Achilles tendon ➡. The gastrocnemius muscle is attached much more proximally on the dorsal surface. Kager fat pad ➡ and flexor hallucis longus (FHL) muscle ➡ lie deep to the Achilles tendon.*

Scan Position for Posterior Ankle

Longitudinal Musculotendinous Junction of Achilles Tendon

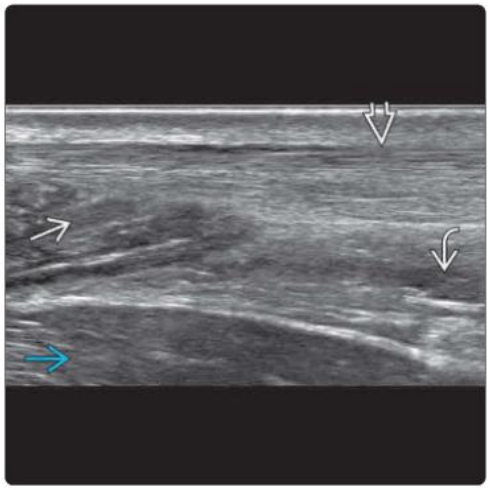

(Left) *Longitudinal US shows the Achilles tendon ➡ insertion to the posterior aspect of the calcaneum. There is hypoechoic entheseal fibrocartilage ➡ at the interface between the tendon and bone. Mild retrocalcaneal bursa distention ➡ is normal.* **(Right)** *Transverse US shows the Achilles tendon ➡ at the musculotendinous junction. The soleus muscle ➡ lies deep to the Achilles tendon.*

Longitudinal Achilles Tendon Insertion

Transverse Achilles Tendon: Proximal Aspect

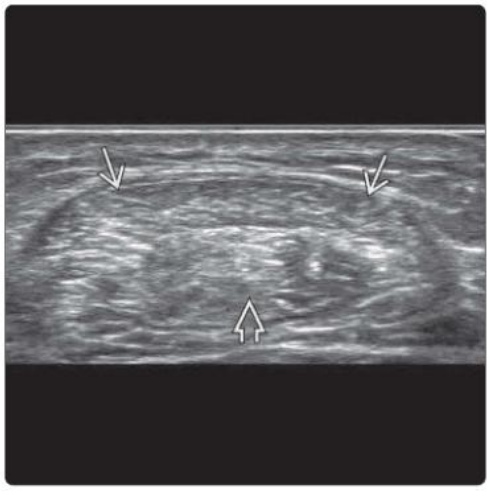

(Left) *Transverse US shows the midportion of the Achilles tendon ➡. The normal echogenic, nondistended paratenon ➡ is barely visible. Kager fat pad ➡ lies deep to the Achilles tendon.* **(Right)** *Transverse US shows the Achilles tendon at the calcaneal insertion. The Achilles tendon ➡ broadens out toward its insertion on the posterior aspect of the calcaneum. Copious gel should be applied to the sides of the transducer to reduce air artifact.*

Transverse Midportion of Achilles Tendon

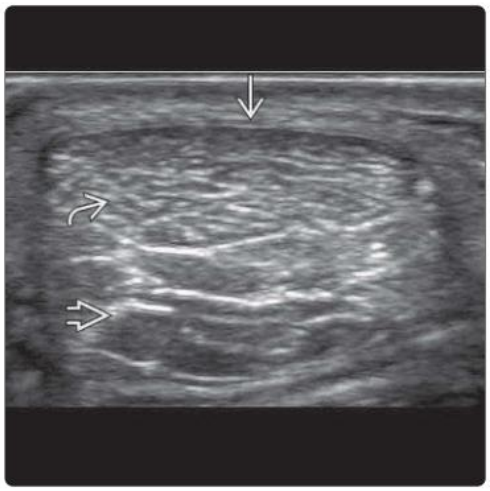

Transverse Achilles Tendon Insertion

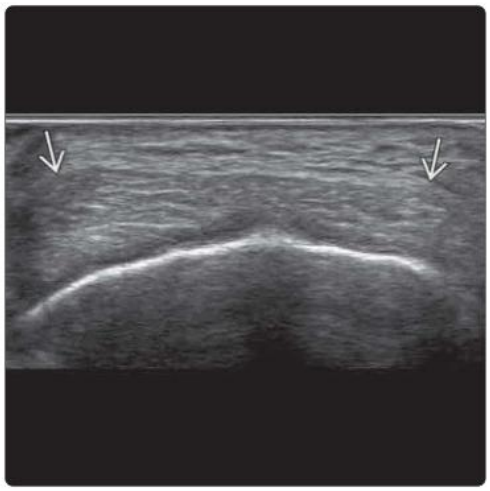

Plantaris Tendon: Midleg

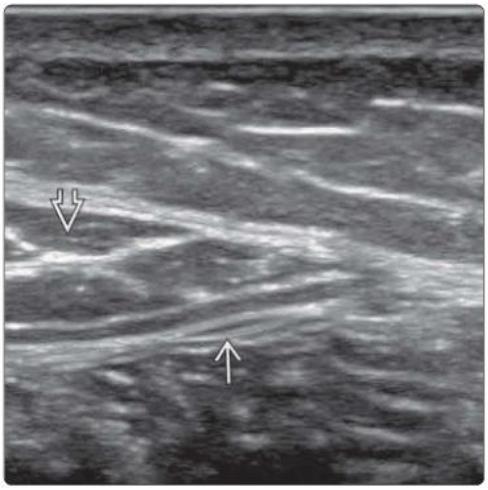

Plantaris Tendon: Distal Leg

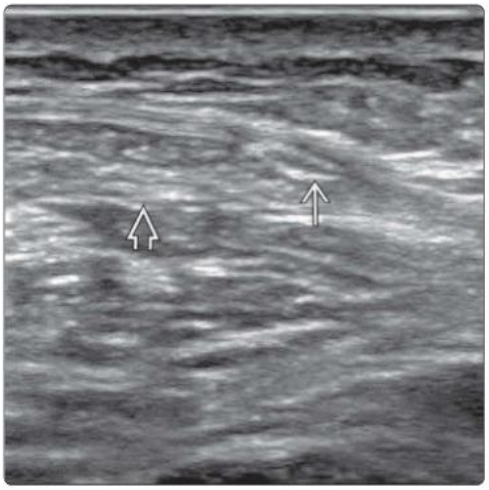

(Left) *Transverse US shows the plantaris tendon ➡ deep to the medial belly of the gastrocnemius muscle ➡. The plantaris tendon is best scanned proximally and distally in a transverse plane.* **(Right)** *Transverse US shows the plantaris tendon ➡ on the medial side of Achilles tendon ➡. Distally, the plantaris tendon is inserted into either the Achilles tendon or the medial aspect of the calcaneum.*

Posterior Ankle Recess

Flexor Hallucis Longus

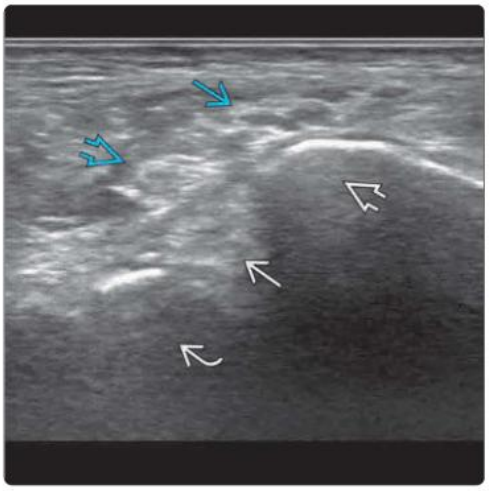

(Left) *Longitudinal US shows posterior recess of the ankle joint ➡ located between the posterior aspect of the distal tibia ➡ and talus ➡. Visibility of this recess can be improved by ankle dorsiflexion.* **(Right)** *Transverse US of the posteromedial aspect of the ankle shows FHL ➡ between lateral ➡ and medial ➡ tubercles of the posterior talus. FHL is closely applied to the ankle joint with its tendon sometimes in direct communication with the posterior recesses. The tibial nerve ➡ and posterior tibial vessels ➡ lie posteriorly.*

Neural Anatomy of Ankle Level

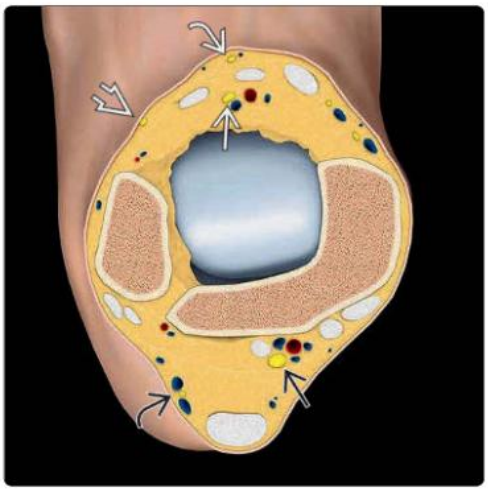

Sural Nerve

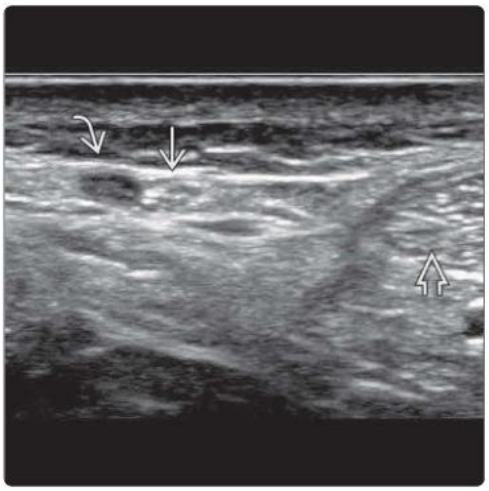

(Left) *Transverse graphic at the level of the ankle joint shows the position of the deep peroneal nerve ➡, medial dorsal cutaneous nerve ➡, intermediate dorsal cutaneous nerve ➡, tibial nerve ➡, and sural nerve ➡.* **(Right)** *Transverse US at the midportion of the Achilles tendon ➡ shows the sural nerve ➡ lying alongside the short saphenous vein ➡. The sural nerve may lie medial or lateral to the vein. The vein is located between the Achilles tendon and the peroneal muscles/tendons.*

KEY FACTS

GENERAL CONSIDERATIONS

- Common specific indications: Suspected plantar fasciitis and fibroma, Morton neuroma, ganglia, osteoarthritis, gout, and other joint disorders
- Less common specific indications: Suspected ligament injury, muscle swelling, plantar fascial tear, plantar plate injury, stress fracture

TECHNIQUE

- **Dorsal foot**
  - Patient position: Supine with knee flexed and ankle plantar flexed so that sole of foot flat on examination couch
  - Bones and joints of foot
  - Subtalar joints
    - Anterior and posterior subtalar joints, which do not communicate
    - 4 different US approaches to subtalar joints
  - 1st metatarsophalangeal (MTP) joint
    - Most frequently symptomatic foot joint
  - Calcaneocuboid ligament
  - Dorsal talonavicular ligament
    - Along with calcaneocuboid ligament, helps support midtarsal joint
  - Lisfranc ligament
    - Dorsal component readily evaluated with US
  - Extensor tendons
  - Muscles
- **Plantar foot**
  - Patient position: Prone with foot dorsiflexed and toes resting on examination couch
  - Plantar fascia: Medial, central, and lateral bands
  - Plantar muscles
  - Flexor tendons
  - Toe web spaces
  - Hallucal-sesamoid complex 1st MTP joint
    - Readily evaluated with US

Scan Position for Dorsum of Foot

Dorsal Foot Bones

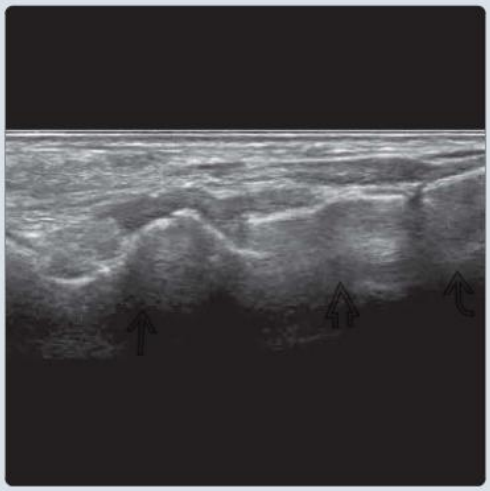

(Left) *Clinical photograph shows the probe and patient position for the dorsum of the foot.* **(Right)** *Longitudinal US shows the bones of the forefoot and midfoot with the talus ➡, navicular ➡, and medical cuneiform ➡. The location and shape of the foot bones make them quite readily recognizable.*

Dorsal Foot Bones

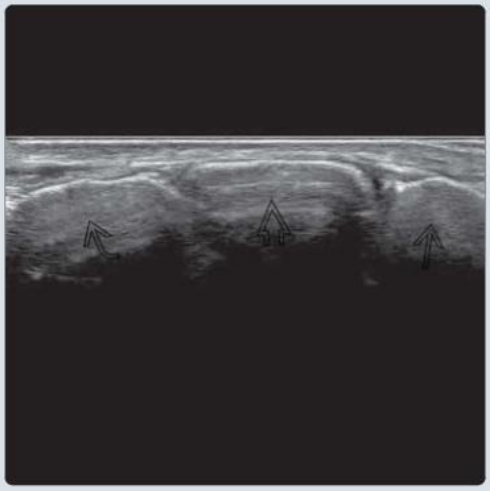

Dorsal Foot Soft Tissues

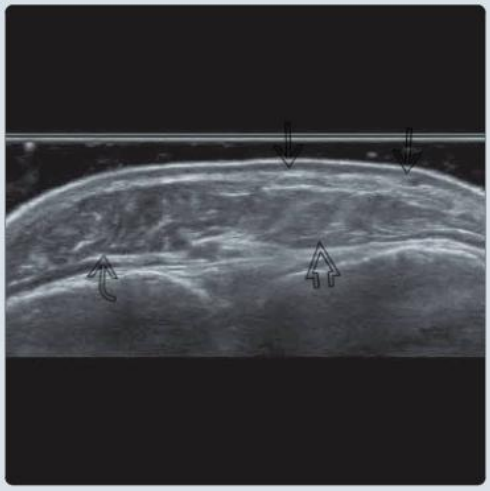

(Left) *Longitudinal US in the medial aspect of the tarsus shows the base of the 1st metatarsal ➡, medial cuneiform ➡, and navicular ➡ bones.* **(Right)** *Transverse US of the diverging extensor digitorum tendon slips ➡ overlying the extensor hallucis brevis ➡ and extensor digitorum brevis ➡ muscles is shown.*

GENERAL CONSIDERATIONS

Clinical Indications for Foot US

- While closely integrated with ankle pathology, many foot conditions can be fully evaluated with US
- Common specific indications: Suspected plantar fasciitis and fibroma, Morton neuroma, ganglia, osteoarthritis, gout, and other joint disorders
- Less common specific indications: Suspected ligament injury, muscle swelling, plantar fascial tear, plantar plate injury, stress fracture

TECHNIQUE: DORSAL FOOT

Patient Position

- Supine with knee flexed and sole resting on examination couch

Specifically Examine Bones and Joints

- Easily recognizable bones or bone areas are talar head and neck, navicular bone, and metatarsal bases
- **Subtalar joints**
  - Comprise anterior (ASTJ) and posterior (PSTJ) subtalar joint, which do no communicate with each other
    - ASTJ does communicate with talonavicular joint ("talocalcaneonavicular joint")
      - ASTJ seen on US from medial approach
    - PSTJ does communicate with posterior recess of ankle joint
      - PSTJ seen on US from posteromedial, posterolateral, and lateral approaches
- **1st metatarsophalangeal joint**
  - Evaluated from both dorsal and plantar aspects, primarily in longitudinal plane
  - Passive flexion and extension can help in assessment
  - On plantar aspect, assess plantar plate, paired sesamoid bones, and intervening flexor hallucis longus (FHL)
    - Sesamoid bones with intervening ligament and plantar plate may be bipartite, hypoplastic, or aplastic
    - Bipartite sesamoid is overall larger than expected sesamoid size with smooth bony margins
    - Both sesamoids are located within tendons of medial and lateral heads of flexor hallucis brevis muscle

Specifically Examine Ligaments

- **Calcaneocuboid ligament**
  - Evident on lateral side of calcaneocuboid articulation
    - Smaller calcaneonavicular ligament also arises at this calcaneal location
- **Dorsal talonavicular ligament**
  - Along with calcaneocuboid ligament, helps support Chopart joint (midtarsal joint)
    - Injured in up to 20% of ankle sprains
- **Lisfranc ligament**
  - 3 components: Dorsal, interosseous (strongest), and plantar
  - Interosseous and plantar components are difficult to see
    - Plantar component is Y-shaped with medial cuneiform stem → 2nd and 3rd metatarsal bases
- **Extensor tendons**
  - Tibialis anterior → dorsomedial medial cuneiform
  - Extensor hallucis longus → base of distal phalanx hallux
  - Extensor digitorum longus → base of middle and distal phalanges of lesser digits
- **Dorsal muscles**
  - Extensor hallucis brevis and extensor digitorum brevis muscles are inseparable on transverse scanning of dorsocentral midfoot
    - Lie deep to extensor digitorum tendons

TECHNIQUE: PLANTAR FOOT

Patient Position

- Patient prone with knee slightly flexed and ankle dorsiflexed with toes on examination couch

Specifically Examine

- **Plantar fascia**
  - Assessed in both longitudinal (primarily) and transverse planes
  - Composed of medial, central, and lateral bands
    - Medial band not present in hindfoot
    - Central band is largest and extends from medial calcaneal tuberosity to metatarsal heads
      - < 4.3 mm thick at leading edge of calcaneum
    - Lateral band extends from calcaneum to 5th metatarsal base
- **Plantar muscles**
  - 4 muscle layers are identified on both transverse and longitudinal scanning
  - Infrequently diseased and usually assessed with MR
  - 1st layer: Flexor digitorum brevis located deep to plantar fascia with abductor hallucis and abductor digiti minimi on either side
  - 2nd layer: Quadratus plantae and lumbrical muscles
    - Quadratus plantae extends from calcaneum to flexor digitorum longus (FDL) tendon
    - Lumbricals arise from flexor digitorum tendon slips
  - 3rd layer: Peroneus longus tendon traverses plantar aspect of foot from cuboid groove to medial cuneiform and 1st metatarsal base
    - More distally, flexor hallucis brevis and adductor hallucis medially and flexor digiti minima laterally
  - 4th layer: Interossei and muscles on dorsum of foot
- **Flexor tendons**
  - On longitudinal scanning on medial aspect of hindfoot, identify sustentaculum tali
  - FDL passes superficial to this bony landmark while FHL passes deep to it
  - FDL and FHL can be traced on transverse scanning to where they cross over in midfoot (knot of Henry)
    - FDL crosses more superficially and receives insertion of quadratus plantae just beyond this point
    - FHL passes between sesamoid bones of 1st metatarsophalangeal joint
- **Toe web spaces**
  - Best if scanned in neutral position with heel on examination couch
  - Can be assessed from either plantar or dorsal approach
    - Apply finger pressure from either dorsal or plantar side to bring tissues of interest closer to transducer
  - Transverse metatarsal ligament is difficult to see

(Left) *Longitudinal US shows the dorsal talonavicular ligament between the distal part of the talus and the proximal part of the navicular bone.* **(Right)** *Longitudinal US shows the calcaneocuboid ligament between the distal part of the calcaneum and the proximal part of the cuboid bone. The calcaneonavicular ligament (not shown) arises from the same part of the calcaneum, extending medially toward the navicular bone.*

Talonavicular Ligament

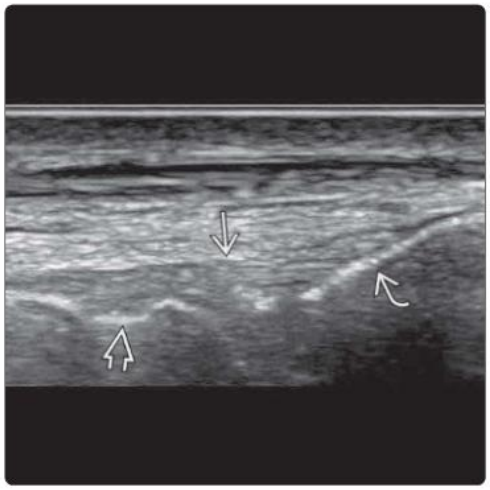

Calcaneocuboid Ligament

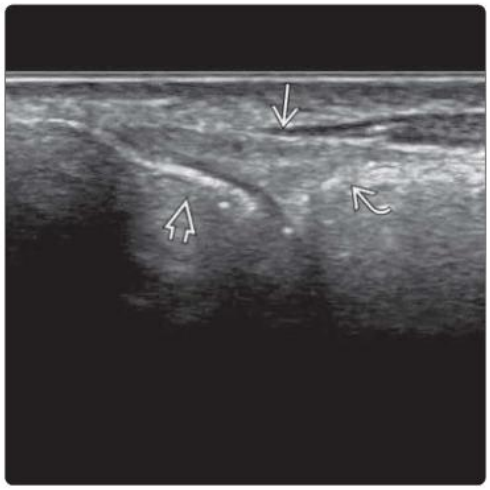

(Left) *Transverse US of the midfoot shows the dorsal component of the Lisfranc ligament, extending between the medial cuneiform and the base of the 2nd metatarsal bone. This strong ligament is aligned almost transversely.* **(Right)** *Transverse US of the midfoot shows the flexor digitorum tendon crossing the flexor hallucis longus tendon. Medial plantar nerve is also visible deep to the abductor hallucis longus muscle.*

Lisfranc Ligament

Knot of Henry

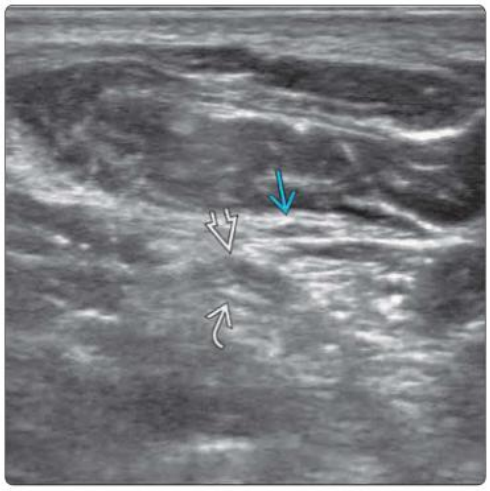

(Left) *Clinical photograph shows the scan position for the anterior subtalar joint. The orientation is from the medial malleolus to the superomedial fibers of the spring ligament. Varus strain on the midfoot can help accentuate the anterior subtalar joint.* **(Right)** *Oblique transverse US shows the talus and the sustentaculum tali with the intervening anterior subtalar joint. Overlying this area are the superomedial fibers of the spring ligament and the tibialis posterior tendon.*

Scan Position for Anterior Subtalar Joint

Anterior Subtalar Joint

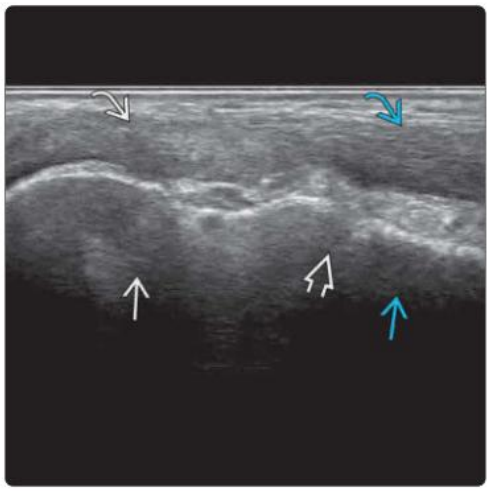

Scan Position (1) for Posterior Subtalar Joint

Lateral View of Posterior Subtalar Joint

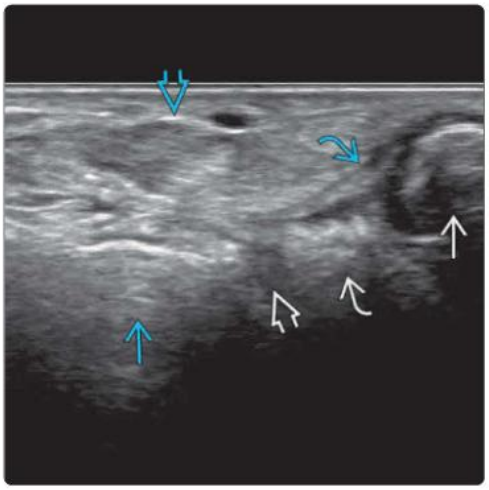

(Left) *Clinical photograph shows the foot and probe position for the posterior subtalar joint (PSTJ), lateral approach. The foot is placed on a pad to aid valgus strain. The orientation of the probe is from the anterior aspect of the lateral malleolus to the midcalcaneal region.* **(Right)** *Longitudinal US shows the lateral view of the PSTJ. The lateral malleolus, talus, and calcaneum are seen. Overlying this joint are the peroneal tendons and part of the calcaneofibular ligament.*

Scan Position (2) for Posterior Subtalar Joint

Posteromedial View of Posterior Subtalar Joint

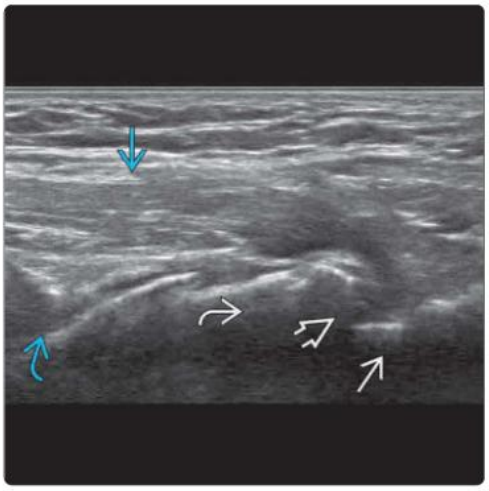

(Left) *Clinical photograph shows foot and probe position for the PSTJ, posteromedial view. The probe is oriented along the flexor hallucis longus tendon at the medial border of the Achilles tendon. The lower part of the probe is moved medially to view the PSTJ.* **(Right)** *Longitudinal US shows posteromedial aspect of the PSTJ. PSTJ lies between the posterior process of talus and calcaneum. Overlying this joint is the flexor hallucis longus tendon. PSTJ space is widened by dorsiflexion and foot eversion. Ankle joint is shown.*

Scan Position (3) for Posterior Subtalar Joint

Posterolateral View of Posterior Subtalar Joint

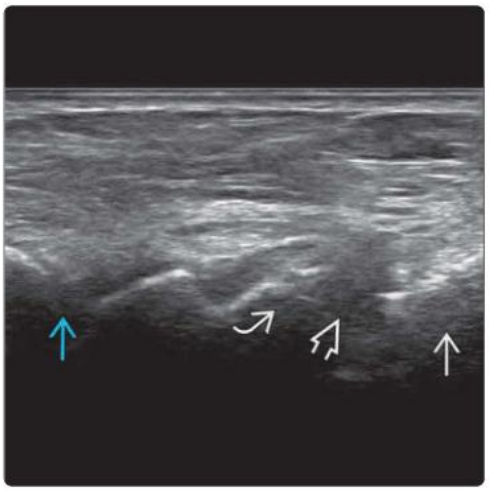

(Left) *Clinical photograph shows the foot and probe position for the PSTJ, posterolateral view. The probe is oriented along the lateral border of the Achilles tendon, and the lower part of the probe is angled medially over the PSTJ.* **(Right)** *Longitudinal US shows the posterolateral view of the PSTJ. The joint lies between the posterior process of the talus and the calcaneum. PSTJ space can be widened by dorsiflexion and foot inversion. Posterior recess of the ankle is also shown.*

(Left) *Clinical photograph shows the scan position for examination of the plantar foot. An advantage of this position is that toe flexion causes stretching, and possibly aids visibility of structures, such as the plantar fascia.* **(Right)** *Longitudinal US shows the plantar fascia insertion into the anteromedial aspect of the medial calcaneal tuberosity ➡. Plantar fascia thickness ➡ should be measured at the leading edge of the calcaneum. Superficially, the heel fat pad ➡ is seen.*

Scan Position for Plantar Foot

Plantar Fascia Insertion

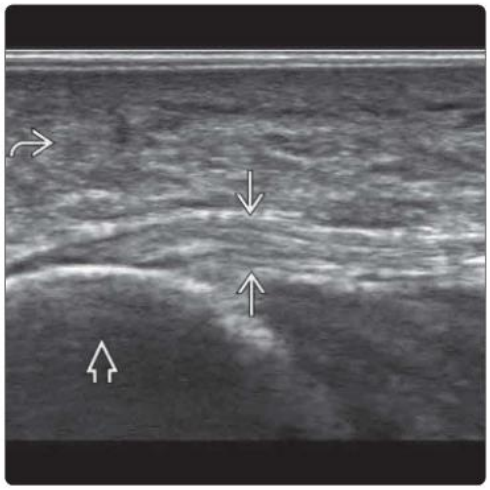

(Left) *Longitudinal US shows the central band of the plantar fascia ➡ at the midfoot. The flexor digitorum brevis muscle ➡ lies deep to the proximal end of the central band of the plantar fascia. Abductor digiti minimi lies deep to the proximal end of the lateral band of the plantar fascia (not shown).* **(Right)** *Longitudinal US shows the lateral band of the plantar fascia ➡ inserting into the inferior aspect of the base of the 5th metatarsal bone ➡.*

Plantar Fascia Midfoot

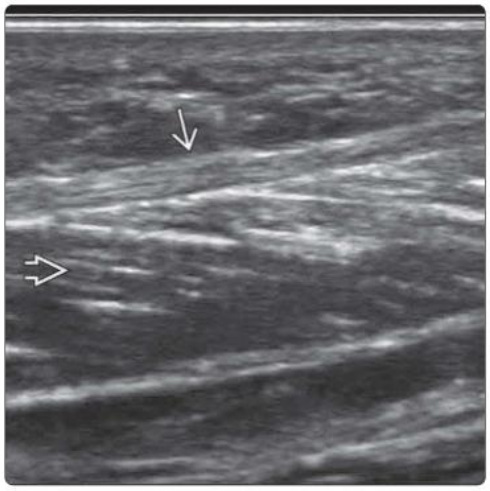

Lateral Band of Plantar Fascia

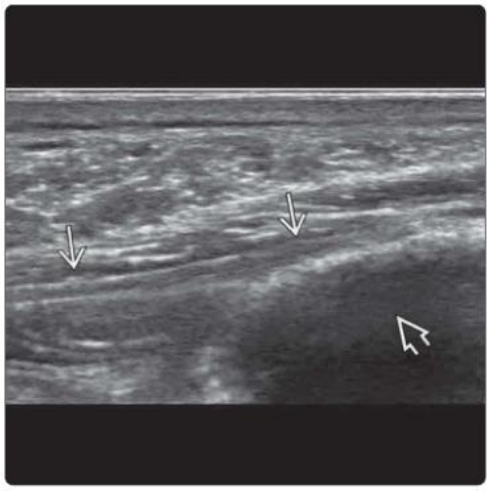

(Left) *Longitudinal US shows the peroneus brevis tendon ➡ insertion into the lateral aspect of the base of the 5th metatarsal bone ➡.* **(Right)** *Longitudinal US shows the peroneus longus tendon ➡ on the lateral aspect of the midfoot. The peroneus longus passes along the cuboid ➡ to the cuboid groove ➡ and then along the 3rd layer of the plantar foot muscles to insert into the medial cuneiform and 1st metatarsal base. In 20% of patients, there is an os peroneum located within the peroneus longus tendon just proximal to the groove.*

Peroneus Brevis Tendon Insertion

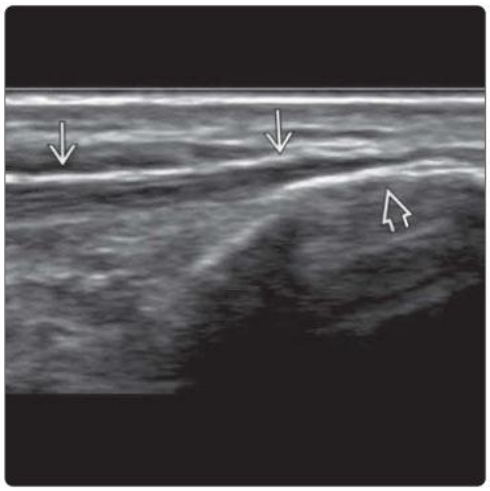

Peroneus Longus Tendon

1st Metatarsophalangeal Joint

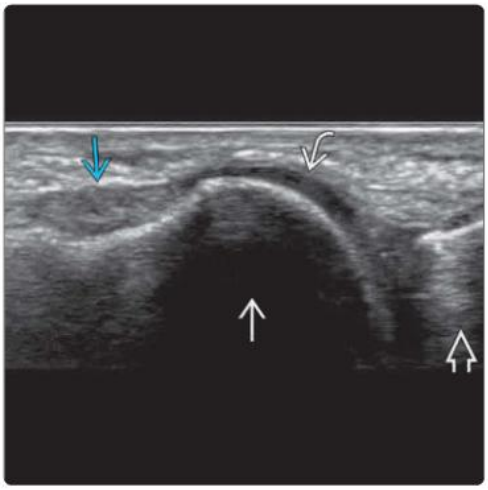

Extensor Hallucis Longus Insertion

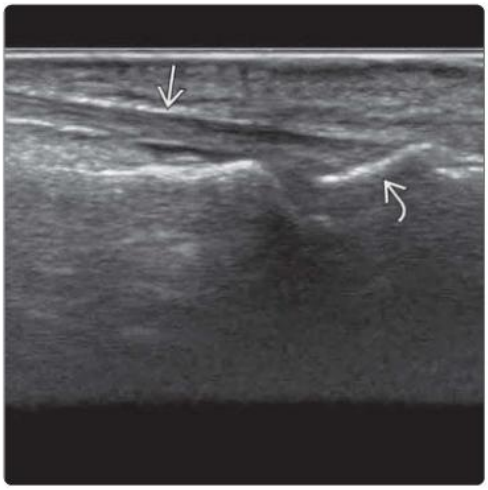

(Left) *Longitudinal US shows the 1st metatarsophalangeal (MTP) joint with a rounded metatarsal head and rather flat base of proximal phalanx. The hyaline cartilage of the metatarsal head is visible along with the dorsal joint recess. This degree of joint distention is normal.* **(Right)** *Longitudinal US shows the normal extensor hallucis longus (EHL) tendon insertion to base of distal phalanx of toe. Variability in position and number of the EHL insertion exists, which may have etiologic bearing on hallux valgus.*

Flexor Hallucis Longus

Hallucal-Sesamoid Complex: Short Axis

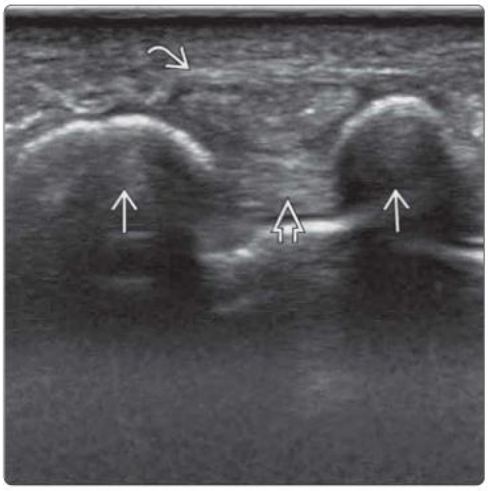

(Left) *Longitudinal US shows flexor hallucis longus tendon overlying the plantar plate of the 1st MTP joint. The plantar plate, overlying the metatarsal head, is firmly adherent to the base of the proximal phalanx.* **(Right)** *Transverse US in the plantar aspect of the 1st MTP joint shows the paired sesamoid bones, larger on the medial side. The plantar plate lies deeply between these bones with the flexor hallucis longus tendon more superficially. The intersesamoid ligament is indistinguishable from the plantar plate.*

Hallucal-Sesamoid Complex: Long Axis

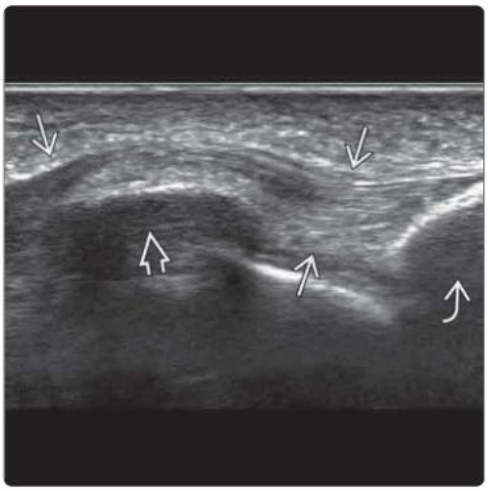

Scan Position for Interdigital Web Space

(Left) *Longitudinal US of the base of the 1st MTP joint shows the medial sesamoid embedded in the medial head of the flexor hallucis brevis tendon, which is inserted to the base of the proximal phalanx.* **(Right)** *Clinical photograph shows the scan position for examining the interdigital web space. The transducer is placed on the plantar surface with finger pressure applied to the dorsal surface. Conversely, the transducer can be placed dorsally with plantar finger pressure.*

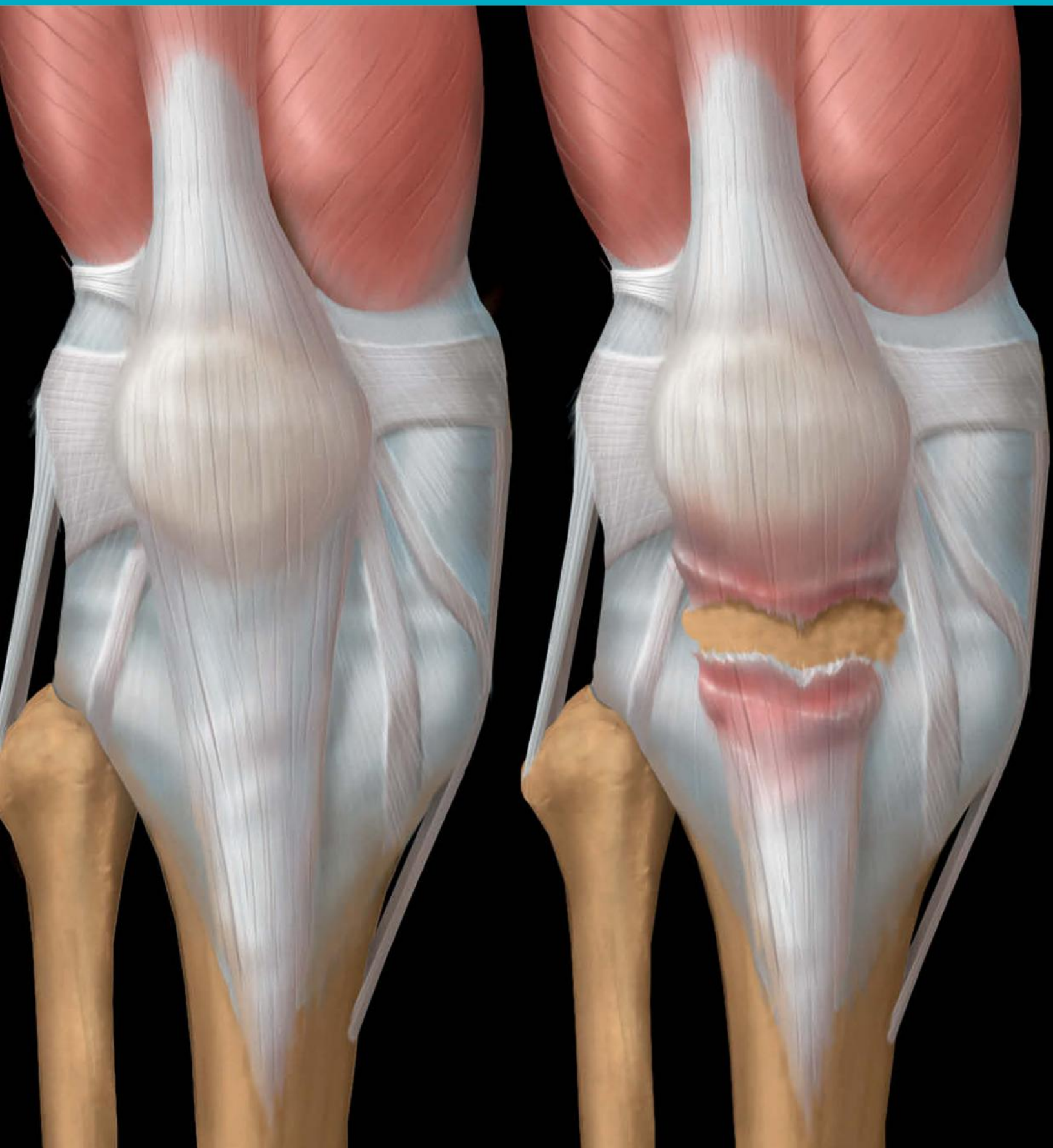

PART III
SECTION 1

Tendon Disorders

Rotator Cuff/Biceps Tendinosis	434
Rotator Cuff/Biceps Tendon Tear	446
Nonrotator Cuff Tendinosis	454
Nonrotator Cuff Tendon Tears	464
Tenosynovitis	476
Elbow Epicondylitis	486

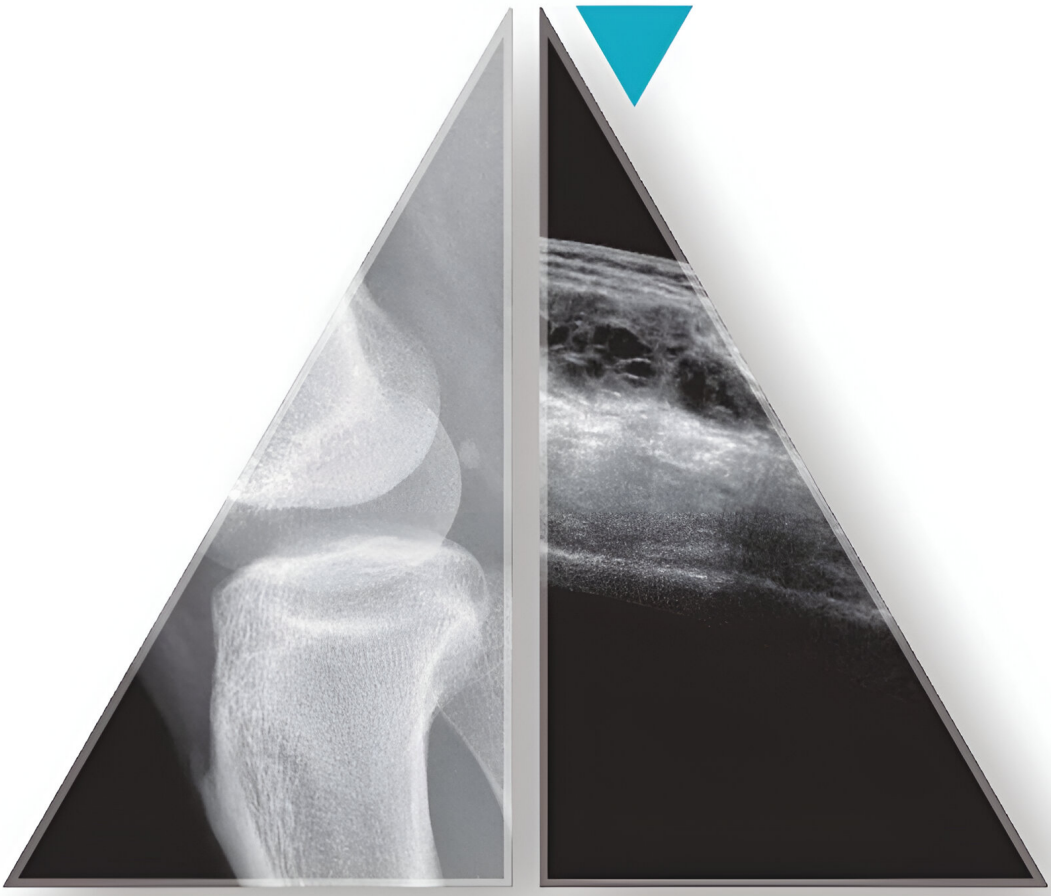

KEY FACTS

TERMINOLOGY

- Collagenous degeneration of rotator cuff ± biceps tendons with proteoglycan deposition

IMAGING

- Supraspinatus > subscapularis, biceps, & infraspinatus > teres minor
- Subclinical tendinosis very common & usually bilateral
  - Do not rely on asymptomatic contralateral side as normal internal reference
- US better than MR for assessing tendinosis, as tendon detail, such as fibrillar pattern, is better appreciated
- Thickened tendon with diffuse hypoechogenicity & indistinct fibrillar pattern
  - Grade as mild, moderate, or severe
- ± cortical irregularity of tendon insertional area
- Tendon hyperemia unusual in rotator cuff tendinosis
- Strong association between tendinosis severity & tendon tear
  - The more severe the tendinosis, the greater the likelihood of tendon tear
- Focal hypoechoic area of proteoglycan accumulation within tendinosis can mimic intrasubstance tear
  - Tears are more linear, more hypoechoic, & sharper in outline ± associated tendon volume loss
- Calcific tendinosis: Formative, latent (resting), & resorptive phases
  - Focal echogenic area within rotator cuff tendon with acoustic shadowing
  - Surrounding tendon hyperemia in resorptive phase
- Biceps tendinosis often accompanies rotator cuff tendinosis
  - Junctional segment ("genu") at proximal end of bicipital groove is most common site of biceps tendinosis

TOP DIFFERENTIAL DIAGNOSES

- Artifact from anisotropy or rotator cable
- Intrasubstance tendon tear

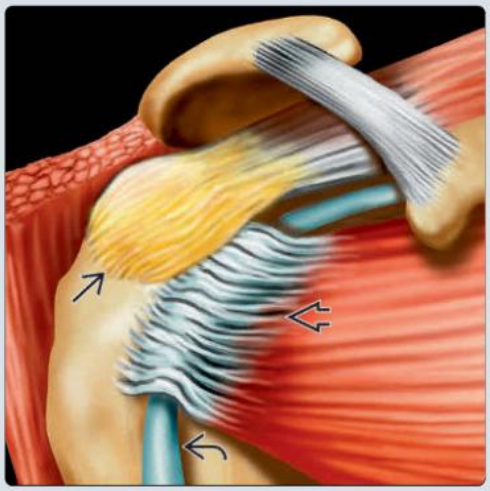

(Left) *Oblique graphic shows a diffusely thickened supraspinatus tendon ⇨ indicative of tendinosis. A normal subscapularis tendon ⇨ & biceps tendon ⇨ are also shown.* **(Right)** *Longitudinal US shows a diffusely thickened & hypoechoic supraspinatus tendon ⇨ indicative of moderate to severe tendinosis. A barely discernible fibrillary pattern ⇨ is present. Note the hypoechoic area ⇨ close to the insertion due to a combination of anisotropy & rotator cable effects.*

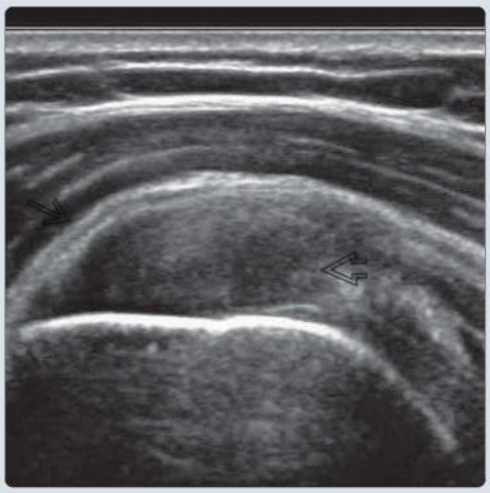

(Left) *Longitudinal US shows a diffusely thickened & hypoechoic supraspinatus tendon ⇨. Poorly demarcated, hypoechoic areas ⇨ with loss of distinct fibrillary structure are seen, features indicative of severe supraspinatus tendinosis.* **(Right)** *Longitudinal US shows severe tendinosis of the long head of the biceps tendon ⇨ at the proximal end of the bicipital groove (or "genu") between the horizontal & vertical components. The more distal tendon is relatively normal ⇨. Tendinosis usually occurs at the genu area.*

TERMINOLOGY

Synonyms

- Rotator cuff tendinopathy
- Calcific tendinitis

Definitions

- Collagenous degeneration of rotator cuff ± biceps tendons with proteoglycan deposition

IMAGING

General Features

- Best diagnostic clue
  - Thickened tendon with diffuse hypoechogenicity & indistinct fibrillar pattern
- Location
  - Supraspinatus > subscapularis, biceps, & infraspinatus > teres minor
  - Slight predominance in dominant shoulder
- Morphology
  - Thickened, inhomogeneous tendon ± surface fraying
    - Tendon torn or partially torn in advanced cases with fluid entering defect
    - Strong association between tendinosis severity & likelihood of tendon tear

Radiographic Findings

- Radiography
  - Acromion with flat undersurface, anteriorly hooked acromion, anterior or lateral downsloping acromion, os acromiale
  - Acromioclavicular joint osteophytes, acromial spurs
  - Surface irregularity, sclerosis, or subcortical cysts of tendon insertion ("footprint")
  - Tendon calcification in calcific tendinosis

MR Findings

- T1WI
  - Thickened tendon with intermediate signal intensity
- T2WI
  - Tendon hyperintensity on fluid-sensitive sequences

Ultrasonographic Findings

- Thickened, hypoechoic tendon with patchy & linear areas of more pronounced hypoechogenicity
  - Graded as mild, moderate, or severe based on degree of thickening, hypoechogenicity, & loss of normal fibrillar pattern
    - Measurement of tendon thickness is generally not helpful, as there are no distinct landmarks, & thickness is dependent on patient size
  - Focal hypoechoic areas of proteoglycan deposition can mimic intrasubstance tears
    - Tears are more linear, more hypoechoic/ anechoic, & sharper in outline ± tendon volume loss
  - Nonintrasubstance tears identified by changes in tendon contour, retraction, fluid gap & loss of volume
- Cortical irregularity at tendon insertional area occurs with more severe degrees of tendinosis
- Tendinosis generally can affect all rotator cuff tendons to some degree, with supraspinatus most commonly affected
  - Occasionally, only single tendon affected
  - Biceps tendinosis usually accompanies rotator cuff tendinosis
    - Normal biceps tendon has oblong cross-sectional contour at proximal end of bicipital groove ("genu" or junctional segment), which is usual site of biceps tendinosis
    - Biceps tendon becomes thickened, more rounded, & more indistinct with ↑ severity of tendinosis
- Likelihood of tendon tear increases as degree of tendinosis increases
  - Tendinosis & tendon tears usually occur in same areas
  - Tears uncommonly occur in normal tendons
  - Likelihood of successful repair reduces as tendinosis severity increases
- Tendon hyperemia very uncommon in rotator cuff tendinosis as compared to tendinosis in other sites
  - Except in calcific tendinitis, where tendon hyperemia can be florid
- Subclinical tendinosis of similar severity is often present on opposite asymptomatic side
  - Be wary of using opposite asymptomatic side as internal reference of normality
- **Calcific tendinosis**
  - Formative, latent (resting), & resorptive phases
    - Focal, echogenic mass within rotator cuff tendon with acoustic shadowing
      - Variable size & multiplicity
      - During formative & resorptive stages, calcification can be less echogenic with less acoustic shadowing
      - Tendon hyperemia may be seen in resorptive phase due to intense inflammation & vascularization of tissue around calcium deposit
  - Small tendon tears may show echogenicity akin to calcific tendinitis
    - Tear-related echogenicity tends to be small, thin, & streaky without postacoustic shadow

Imaging Recommendations

- Best imaging tool
  - US is better than MR for assessing tendinosis, as tendon detail, such as fibrillar pattern, is better appreciated
    - Patients prefer US
- Protocol advice
  - Systematically examine tendons, taut & nontaut, in longitudinal & transverse planes with patient in sitting position
  - Arm rotated into different positions to optimize visibility of each tendon in turn
  - Important to always grade severity of tendinosis as mild, moderate, or severe for each tendon individually
    - Can also use intermediate grading, such as "mild to moderate" or "moderate to severe"

DIFFERENTIAL DIAGNOSIS

Intrasubstance Tendon Tear

- Focal areas of proteoglycan deposition may mimic intrasubstance tears & vice versa
  - Tears are more hypoechoic/anechoic, more sharply defined, & more linear ± contour flattening or retraction of tendon

Anisotropy

- Tendon appears hypoechoic when US beam is not perpendicular to tendon fibers
- Realign transducer to eliminate anisotropic effect

Rotator Cable

- Band-like tendinous thickening at medial aspect of rotator crescent
- Running perpendicular to & below supraspinatus & infraspinatus tendons
- Strengthens rotator cuff tendons
- More prevalent on US with background tendinosis
- Cable can be preferentially spared when remaining tendon shows tendinosis
  - Uncommonly, reverse may happen

PATHOLOGY

General Features

- Etiology
  - Combination of intrinsic, extrinsic, biomechanical, & genetic factors
    - Intrinsic theory: Overuse, degeneration, & microtears
    - Extrinsic theory: Secondary to repeated impingement, steroid injections
    - Biomechanical: Eccentric tensile overload of rotator cuff tendons
- Genetics
  - Familial predisposition

Staging, Grading, & Classification

- Grade arbitrarily into mild, moderate, or severe, depending on degree of thickening, hypoechogenicity, & loss of normal fibrillar pattern
  - Severity of tendinosis affects likelihood for tear & surgical outcome

Gross Pathologic & Surgical Features

- Thickened, grayish or yellow-brown tendon rather than normal white color

Microscopic Features

- Collagen degeneration & disruption without inflammatory cell infiltrate
  - Normal architectural arrangement of collagen is impaired
  - ↓ in type I collagen, ↑ in weaker type III collagen
  - Tenocyte apoptosis (cell death) in some areas
  - ↑ tenocyte number with more rounded nuclei
  - ↑ extracellular proteoglycan ground substance with high concentration of glycosaminoglycans
- **Calcific tendinosis**
  - Deposition of hydroxyapatite crystals into matrix vesicles
    - These vesicles coalesce to form foci of calcification
      - Chalk-like during formative & latent phases
      - Paste-like during resorptive phase

CLINICAL ISSUES

Presentation

- Most common signs/symptoms
  - Often subclinical; usually bilateral in older patients
  - Slowly progressive, poorly localized shoulder pain with decreased range of motion
  - Relationship between pain & severity of tendinosis is unclear
    - Tendinosis per se probably does not induce pain
      - Normal tendon does not contain neurons
      - High prevalence of asymptomatic tendinosis
    - Pain most likely related to associated bursitis ± bone change or impingement
  - **Calcific tendinosis**
    - Resorptive phase is characterized by severe pain & limitation of movement
    - Crystal shedding into bursa, joint, or bone → pain
- Clinical profile
  - In young athletes, precipitating factor, such as overhead sporting activity or os acromiale, is usually present
  - In older athletes or older nonathletic population, onset is more insidious ± structural abnormality

Demographics

- Age
  - Uncommon < 30 years; gradually increasing prevalence & severity with increasing age
- Sex
  - Slight female predominance

Treatment

- Physiotherapy
- Corticosteroids & long-acting local anesthetic injection to subacromial-subdeltoid bursa
  - Multiple steroid injections best avoided as may accelerate tendon degeneration
- Subacromial decompression
- **Calcific tendinosis**
  - Usually self limiting
  - US-guided steroid injection
  - US-guided needling, lavage, & aspiration ("barbotage")
    - 1- or 2-needle technique
    - Warm saline (42 °C) lavage seems better at calcium dissolution than room temperature saline
      - Decreases procedure time & likelihood of postprocedural bursitis
  - Extracorporeal shock wave therapy

DIAGNOSTIC CHECKLIST

Consider

- Small tear if no abnormality on 1st inspection in patient with tendinosis & sudden deterioration in symptoms
- Small, avulsive-type tear at leading tendon edge
- Tears are very common in more severe degrees of tendinosis, particularly intrasubstance tears
  - Intrasubstance tears are almost integral part of severe tendinosis; expect to see them
- Always grade tendinosis, & when tendinosis present, grade each tendon separately

SELECTED REFERENCES

1. Saran S et al: Imaging of calcific tendinopathy: natural history, migration patterns, pitfalls, and management: a review. Br J Radiol. 97(1158):1099-111, 2024

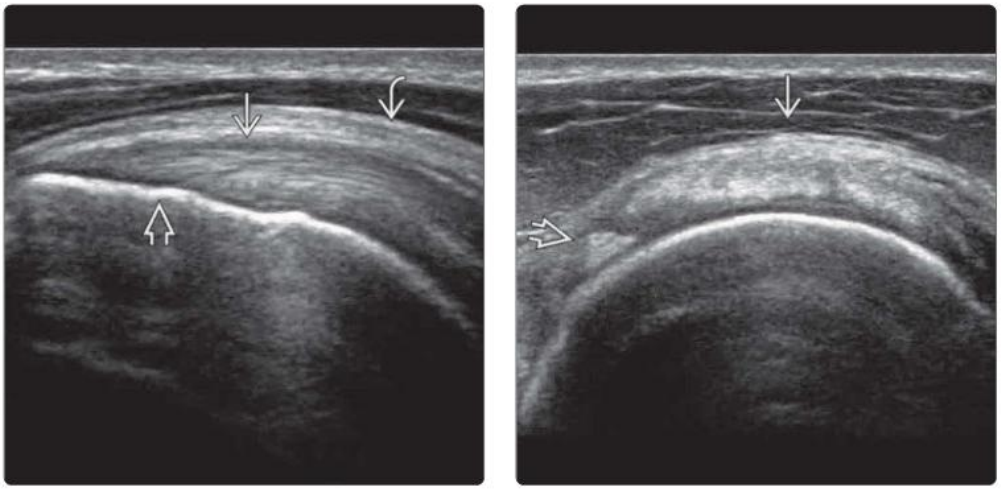

(Left) *Longitudinal US shows a normal, hyperechoic supraspinatus tendon ➡ of normal size with a distinct fibrillary pattern. Note the smooth insertional area on the greater tuberosity of the humerus ➡. The peribursal fat ➡ deep to the deltoid muscle is also shown.* **(Right)** *Transverse US in the same patient shows the normal, hyperechoic supraspinatus tendon ➡ in transverse section. Note the long head biceps tendon ➡ within the rotator interval.*

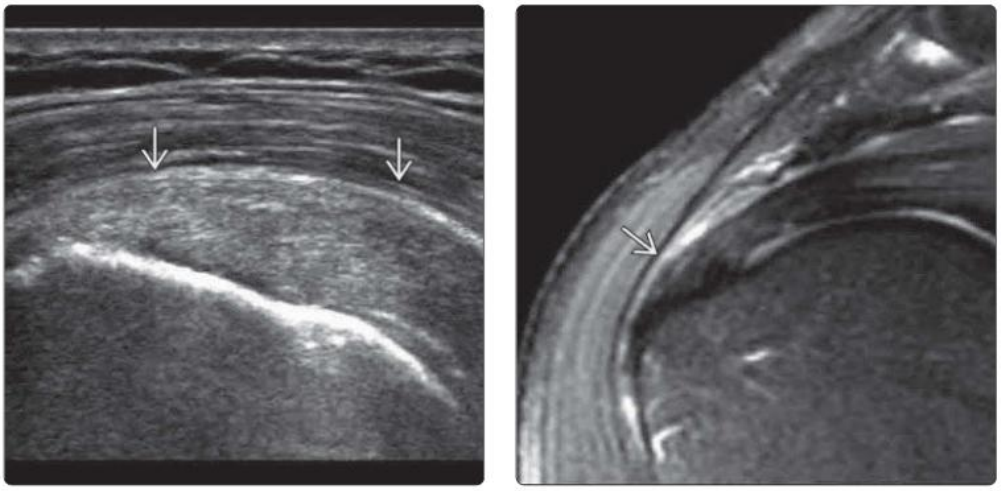

(Left) *Longitudinal US shows mild supraspinatus tendinosis. The tendon ➡ is mildly thickened & hypoechoic. Most of the hyperechoic fibers can still be identified.* **(Right)** *Oblique coronal T2 SPIR MR shows mild supraspinatus tendinosis with mild tendon hyperintensity ➡ over & above that due to magic angle effect & mild tendon thickening. The fibrillar pattern of the tendon is better visualized by US than MR.*

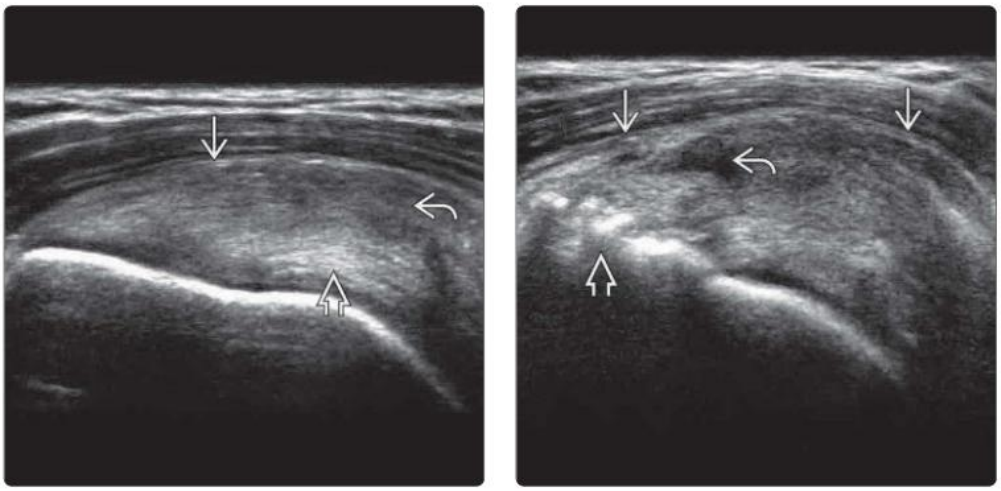

(Left) *Transverse US shows moderate supraspinatus tendinosis. The tendon ➡ is more thickened and heterogeneous. There are ill-defined areas of hypoechogenicity ➡ interspersed with areas of preserved fibrillar pattern ➡.* **(Right)** *Longitudinal US shows a markedly thickened & hypoechoic supraspinatus tendon ➡ due to severe tendinosis. The normal fibrillar pattern is largely absent. There is also severe cortical irregularity at the insertional area ➡, & there are small intrasubstance tears ➡.*

(Left) *Frontal radiograph of the shoulder shows a subacromial hyperostotic spur* ➡ *that narrows the subacromial space, predisposing to tendon impingement & tendinosis. Note the mild cortical irregularity & hyperostosis of the greater tuberosity* ➡ *as a feature of tendinosis.* **(Right)** *Longitudinal US in the same patient shows mild supraspinatus tendinosis* ➡. *The hypoechoic area* ➡ *is due to a different orientation between rotator cable fibers* ➡ *& remaining fibers.*

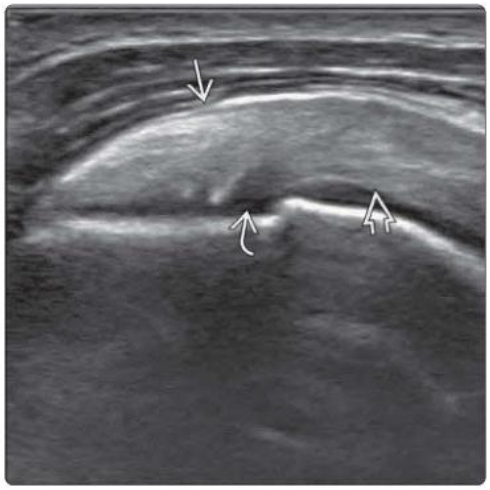

(Left) *Longitudinal US shows mild tendinosis of main supraspinatus fibers* ➡ *& no tendinosis of cable fibers* ➡. *The supraspinatus tendon distal to the cable is known as the crescent* ➡. **(Right)** *Graphic shows fiber condensation of the rotator cable* ➡, *which extends perpendicular & deep to supraspinatus* ➡ *& infraspinatus* ➡ *tendons. The semicircular area between rotator cable & tendon insertion is the rotator crescent* ➡. *The position of the biceps tendon* ➡ *is shown.*

(Left) *Longitudinal US shows mild supraspinatus tendinosis. The tendon* ➡ *is mildly and diffusely thickened. Its normal hyperechogenicity and fibrillar pattern are largely preserved. It is important to grade tendinosis as mild, moderate, or severe.* **(Right)** *Transverse US in the same patient shows minimal distension of the subacromial subdeltoid bursa* ➡ *associated with supraspinatus tendinosis* ➡.

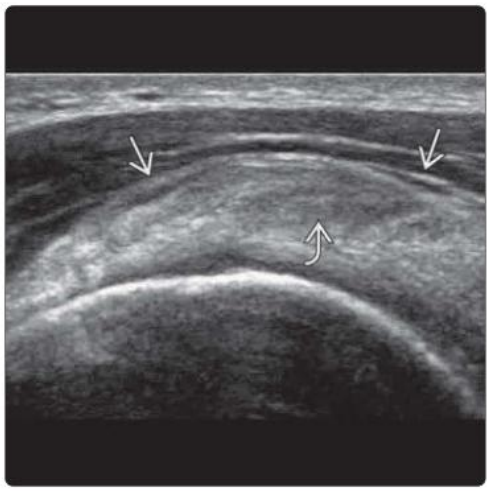

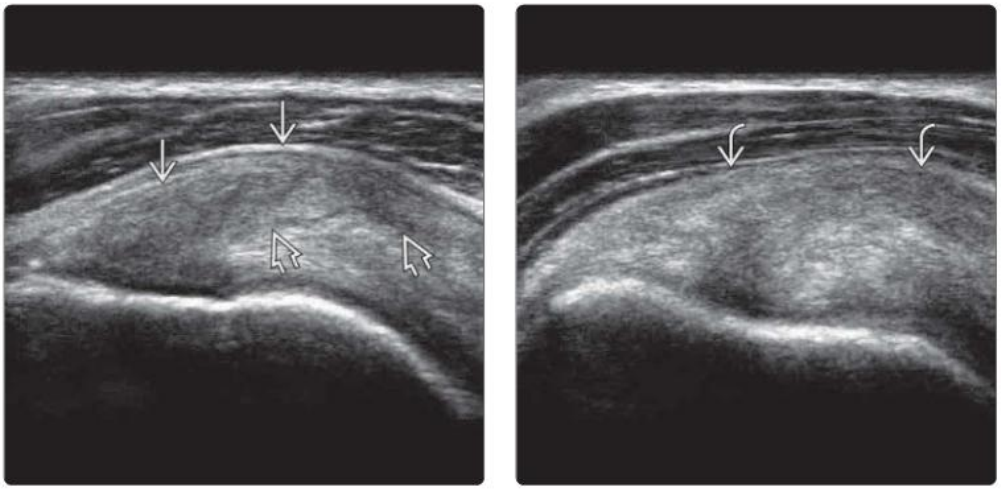

(Left) *Longitudinal US shows moderate supraspinatus tendinosis. The tendon is thickened, and the fibrillar structure is distinct with ill-defined, hypoechoic areas. One should use all 3 criteria to grade the severity of tendinosis.* **(Right)** *Transverse US in the same patient with moderate supraspinatus tendinosis shows mild bursal surface fibers fraying. This is a common feature in more severe degrees of tendinosis.*

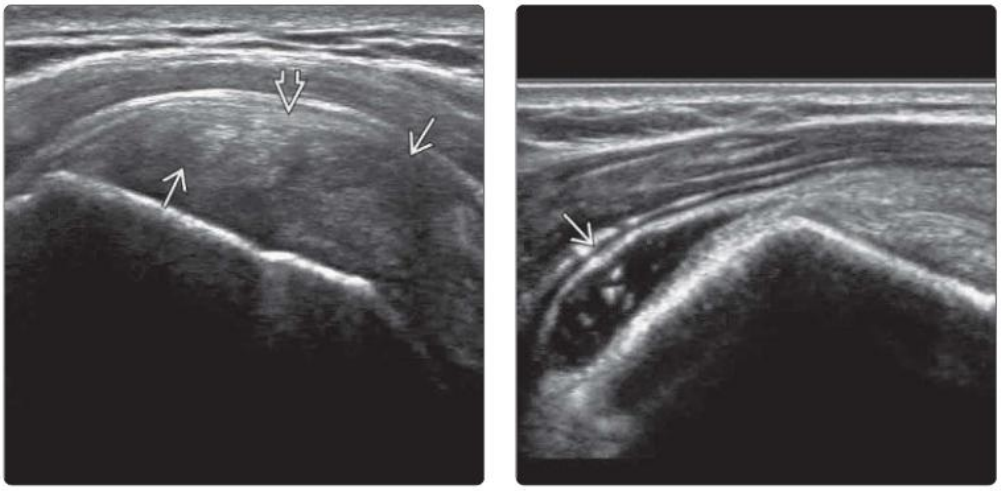

(Left) *Longitudinal US shows severe supraspinatus tendinosis with the tendon being markedly thickened & hypoechoic with loss of normal fibrillar pattern throughout most of the tendon, except for some of the bursal fibers.* **(Right)** *Longitudinal US in the same patient at a slightly more lateral portion shows mild distension of the subacromial-subdeltoid bursa, indicative of mild bursitis. In this situation, one should search carefully for a surface or rim-rent tendon tear.*

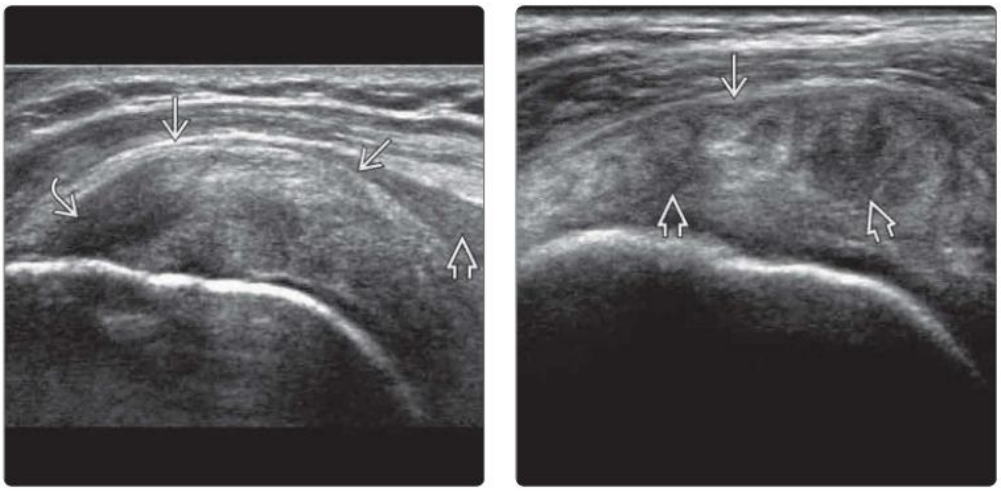

(Left) *Longitudinal US shows moderate supraspinatus tendinosis. Note the hypoechoic anisotropic effect. There is distension of the subacromial-subdeltoid bursa with echogenic fluid probably due to proteinaceous content.* **(Right)** *Longitudinal US shows severe supraspinatus tendinosis. The tendon is more thickened and heterogeneous. There are indistinct areas of hypoechogenicity due to proteoglycan accumulation.*

(Left) *Transverse US in the same patient shows diffuse thickening & heterogeneous echogenicity of the supraspinatus tendon associated with mild bursal surface fraying & mild subacromial-subdeltoid bursitis.* **(Right)** *Sagittal T2 FS MR shows moderate supraspinatus tendinosis within moderate tendon thickening & hyperintensity. Moderate fluid distension in the subacromial-subdeltoid bursa is present. Note the normal subscapularis, infraspinatus, & biceps tendons.*

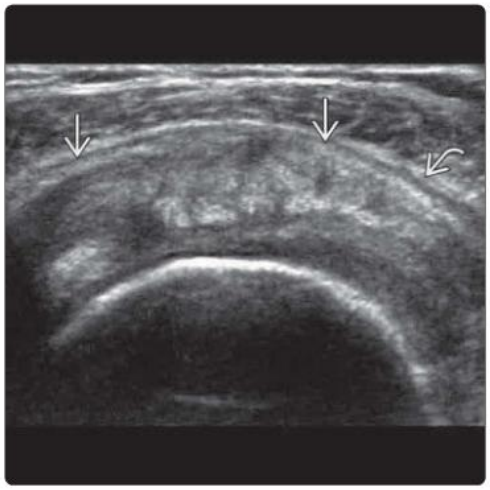

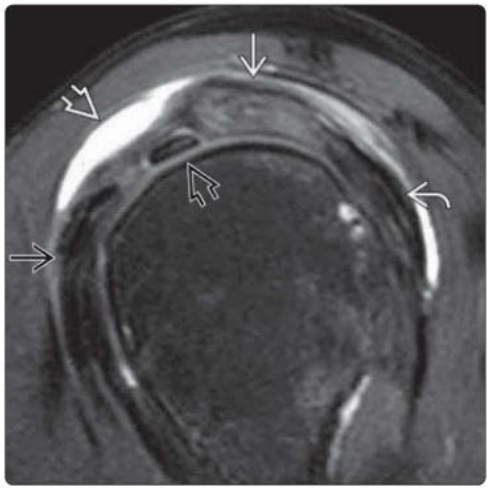

(Left) *Longitudinal US shows severe supraspinatus tendinosis with a well-demarcated, linear, hypoechoic intrasubstance tear. The other more globular, hypoechoic area within the tendon is a feature of tendinosis.* **(Right)** *Longitudinal US shows a partial-thickness, bursal-surface tear of the supraspinatus tendon at the insertional area. The tear is sharply demarcated against the background of moderate tendinosis. Note the cortical irregularity at the greater tuberosity.*

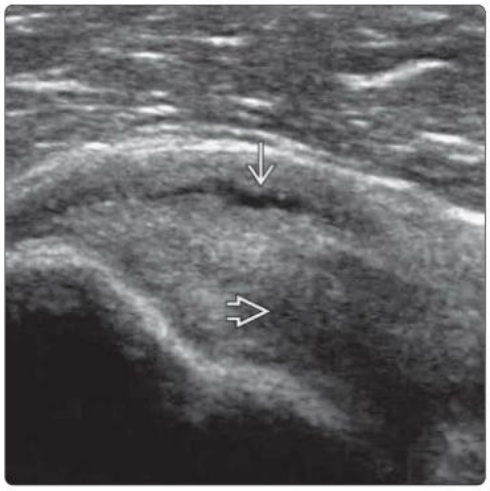

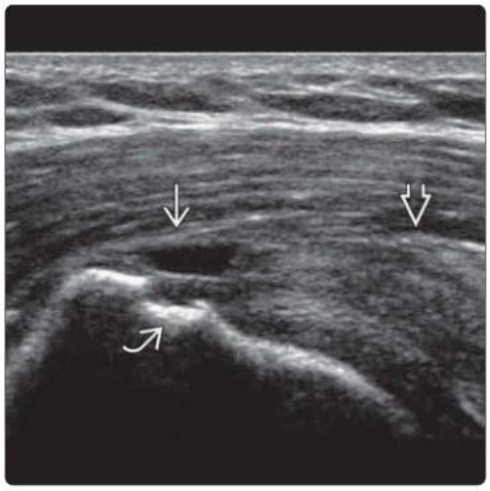

(Left) *Longitudinal US of the supraspinatus tendon shows moderate tendinosis with thickening & loss of fibrillar pattern. There is a small, anechoic, articular-surface tear just proximal to the footprint.* **(Right)** *Transverse US in the same patient shows a full-thickness partial tear of the midfibers supraspinatus tendon. Note severe thickening due to tendinosis of the anterior & posterior fibers. There is a strong relationship between severity of tendinosis & tendon tear.*

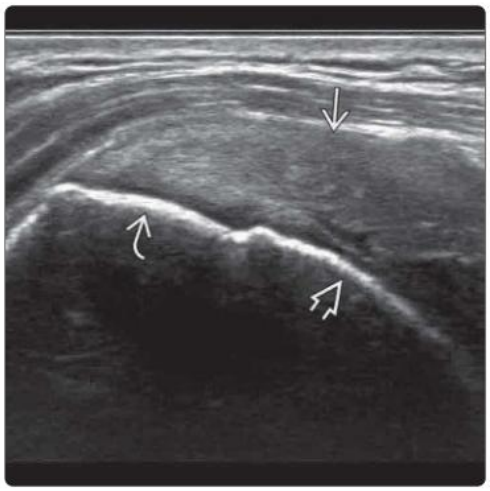

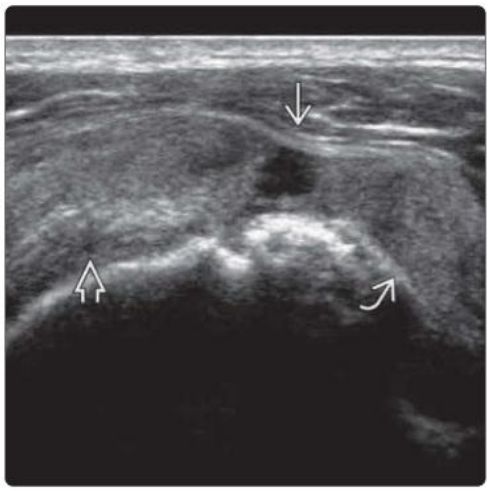

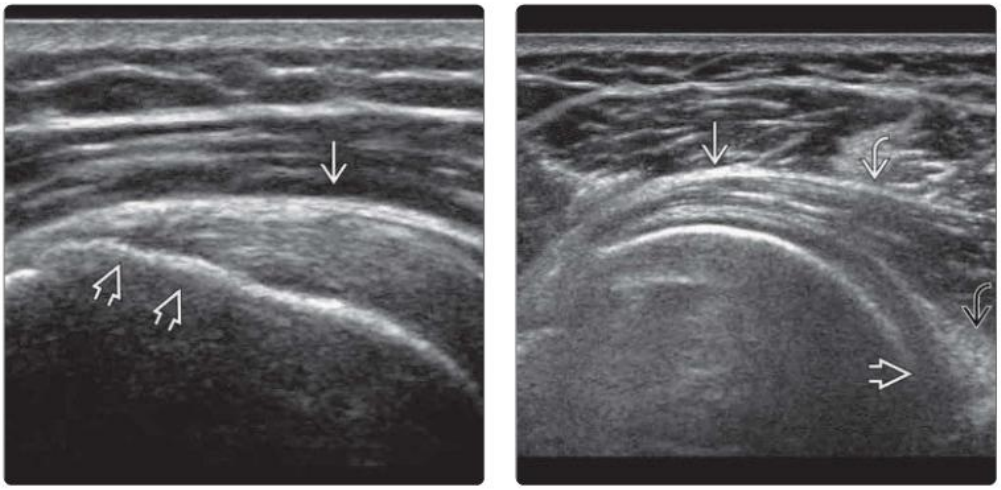

(Left) *Longitudinal US shows a normal infraspinatus tendon ⇨ inserting into the middle facet of the greater tuberosity ⇨. The infraspinatus, supraspinatus, & teres minor are inseparable at insertion.* **(Right)** *Longitudinal US shows the normal infraspinatus tendon ⇨ at a slightly more proximal level. In this position, the myotendinous junction ⇨ as well as the posterior glenohumeral joint ⇨ are seen. Note the normal posterior glenoid labrum ⇨.*

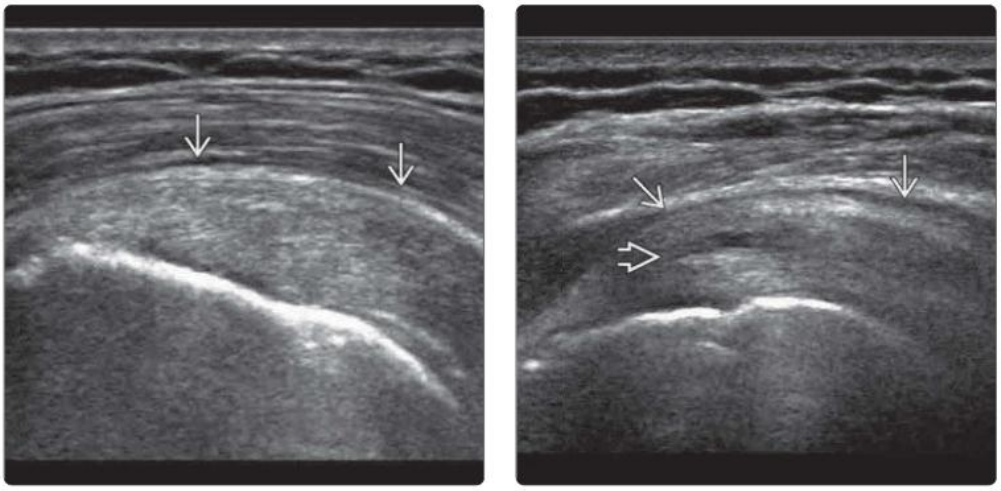

(Left) *Longitudinal US shows mild thickening & hypoechogenicity of the infraspinatus tendon ⇨, indicative of mild tendinosis.* **(Right)** *Longitudinal US shows moderate infraspinatus tendinosis. The tendon ⇨ is moderately thickened & hypoechoic. There is an intrasubstance tear ⇨ without extension to either the bursal or articular surface present.*

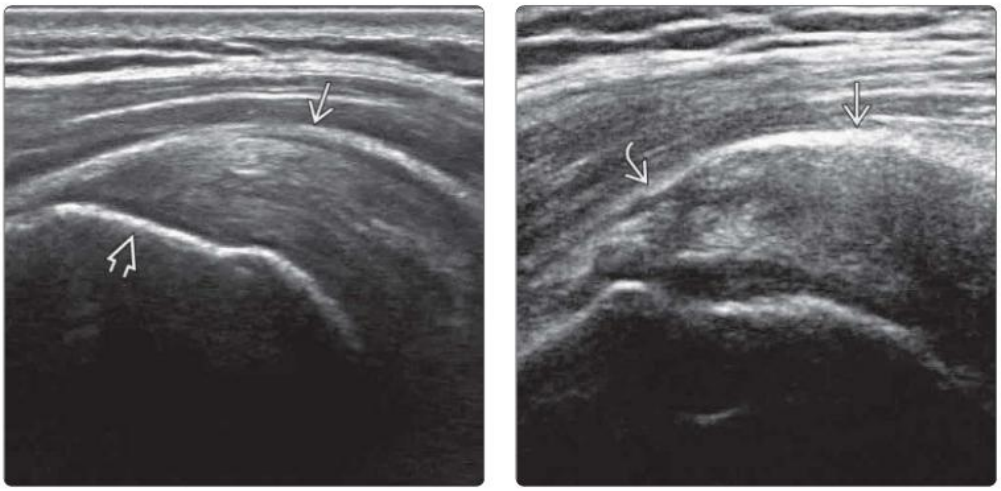

(Left) *Transverse US shows moderate to severe infraspinatus tendinosis ⇨ with thickening, hypoechogenicity, & reduced fibrillar pattern. The smooth tendon contour is preserved, & the insertional area ⇨ is normal. There is no discrete tear.* **(Right)** *Longitudinal US shows severe infraspinatus tendinosis with a diffusely thickened & hypoechoic infraspinatus tendon ⇨. In contrast to the previous case, there is a medium-sized, irregular bursal surface tear ⇨ near the insertion.*

(Left) *Longitudinal US shows a normal subscapularis tendon ➡ inserting onto the lesser tuberosity ⇨ of the humerus. The tendon is normal in size with distinct hyperechoic fibers.* **(Right)** *Transverse US shows normal appearances of the subscapularis tendon ⇨ in the transverse section. The distinctive bundle heterogeneity is due to the juxtaposition of hyperechoic tendon bundles ➡ with hypoechoic muscle ⇨.*

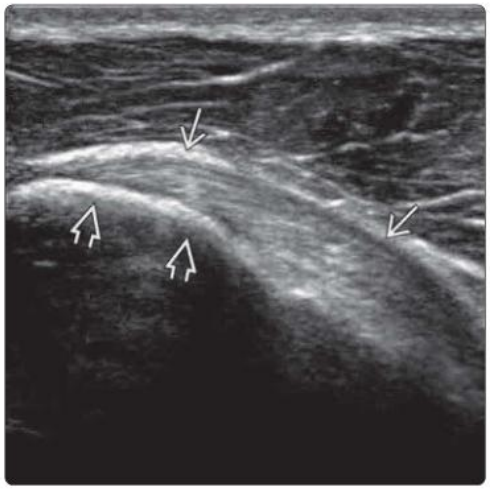

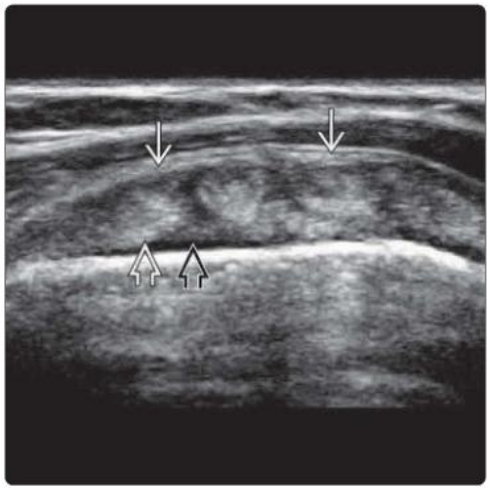

(Left) *Longitudinal US shows mild to moderate subscapularis tendinosis ➡ associated with mild fluid distension within the subcoracoid recess ⇨.* **(Right)** *Transverse US in the same patient shows the superior subscapularis fibers ➡ are thickened to a greater degree than the mid ⇨ & inferior ⇨ fibers. Tendinosis preferentially affects the superior subscapularis fibers.*

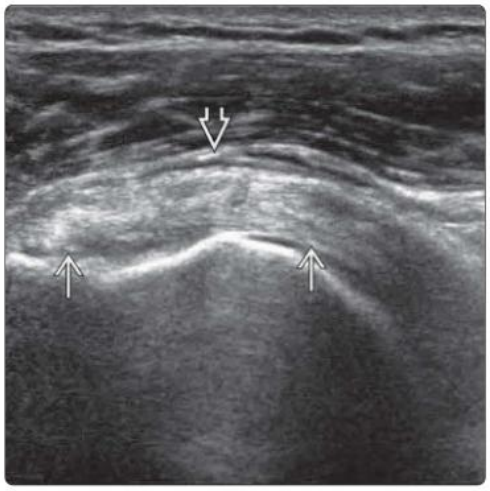

(Left) *Longitudinal US shows moderate to severe subscapularis tendinosis ➡.* **(Right)** *Transverse US in the same patient shows diffuse thickening of the superior, mid, & inferior subscapularis tendon fibers ➡. Distinction between the tendon fibers & muscle fibers is diminished as the severity of tendinosis increases. The appearances are those of moderate to severe tendinosis.*

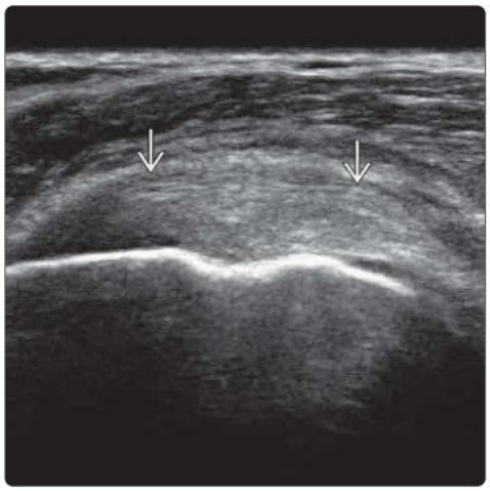

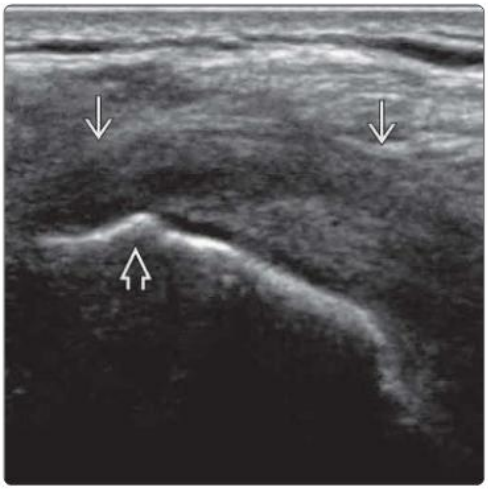

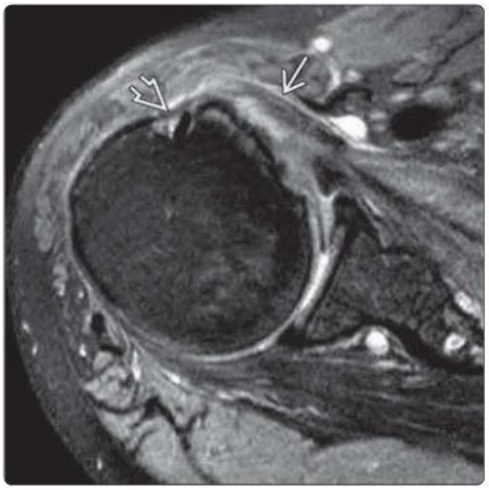

(Left) *Longitudinal US shows severe subscapularis tendinosis with a severely thickened & diffusely hypoechoic subscapularis tendon associated with mild cortical irregularity of the lesser tuberosity.* **(Right)** *Axial PD FSE FS MR in the same patient shows severe subscapularis tendinosis with hyperintense signal within the thickened tendon. Note the normal long head of the biceps tendon within the bicipital groove.*

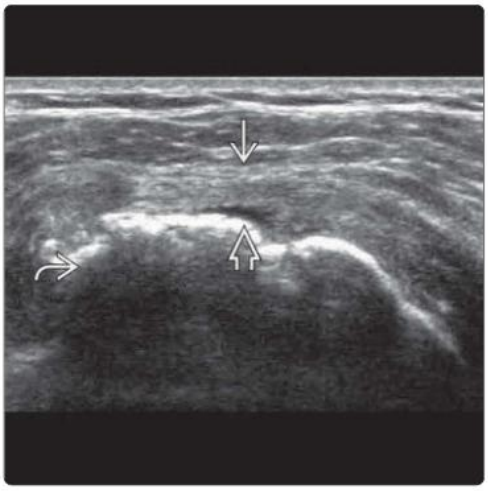

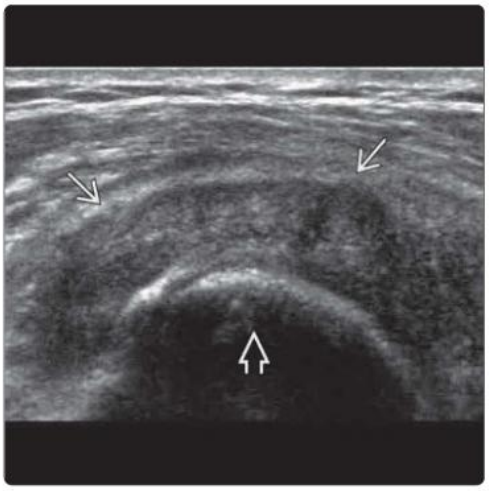

(Left) *Longitudinal US shows severe cortical irregularity of the lesser tuberosity. There is subscapularis tendinosis associated with articular surface avulsive-type tear near the insertion. Note flattening of the tendon surface contour due to the tendon tear.* **(Right)** *Transverse US of the same subscapularis tendon proximal to the tear shows severe background tendinosis with diffuse thickening & hypoechogenicity. Note the lesser tuberosity.*

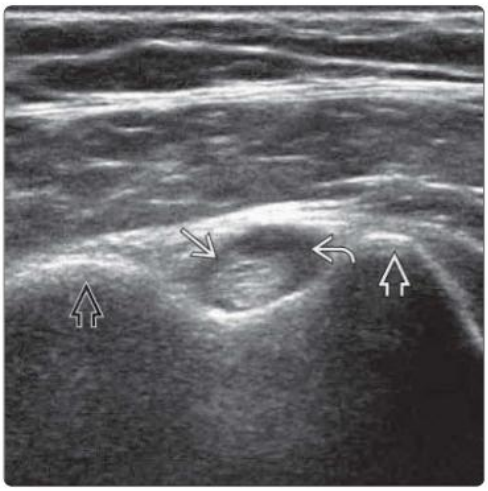

(Left) *Transverse US shows a normal biceps tendon within the bicipital groove. There is a small amount of fluid within the biceps tendon sheath. Note the medial & lateral lips of the bicipital groove.* **(Right)** *Longitudinal US in the same patient shows the normal long head of the biceps tendon. As the biceps tendon sheath communicates with the glenohumeral joint, fluid in one compartment mirrors that in the other compartment.*

(Left) *Transverse US shows the normal oblong configuration of the long head of the biceps tendon ⇨ at the uppermost portion of the bicipital groove ⇨.* **(Right)** *Transverse US shows mild tendinosis of the long head of the biceps tendon ⇨ with mild tendon swelling leading to a slightly ovoid, cross-sectional contour. Tendinosis of the biceps long head most commonly affects the tendon at the uppermost portion of the bicipital groove.*

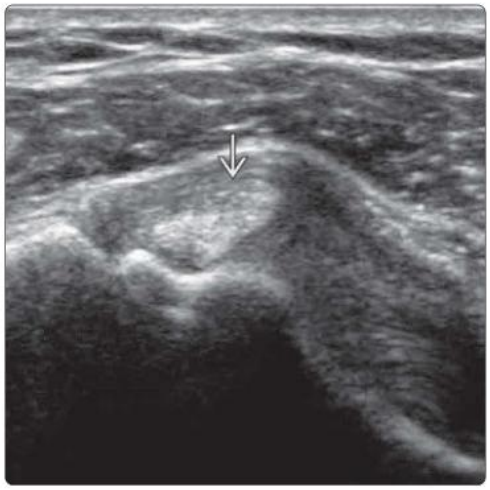

(Left) *Transverse US shows moderate biceps tendinosis ⇨. The tendon is more hypoechoic and more thickened than normal. The appearances are those of moderate biceps tendinosis.* **(Right)** *Transverse US shows severe biceps tendinosis ⇨ at the upper end of the bicipital groove. The tendon is moderately swollen & heterogeneous in echotexture with several longitudinal splits. Longitudinal split tears extending for ~ 1 cm are common in severe biceps tendinosis.*

(Left) *Transverse US shows severe junctional biceps tendinosis ⇨ with severe tendon thickening & loss of internal echotexture. The tendon is indistinct with moderate peritendinous soft tissue thickening.* **(Right)** *Longitudinal US in the same patient shows the severe tendinosis affecting the junctional (genu) ⇨ and intraarticular ⇨ segments of the long head of the biceps tendon. The biceps tendon more distally in the bicipital groove is normal with preserved size and fibrillar pattern ⇨.*

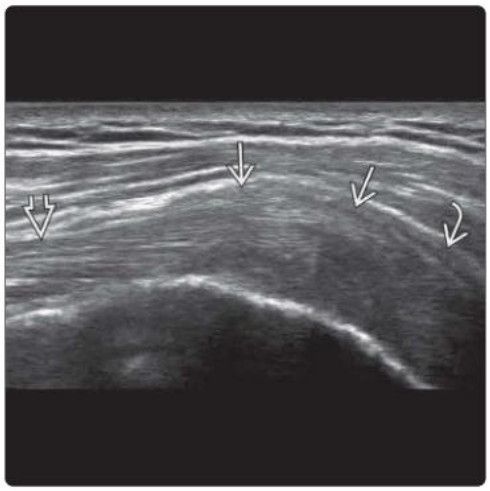

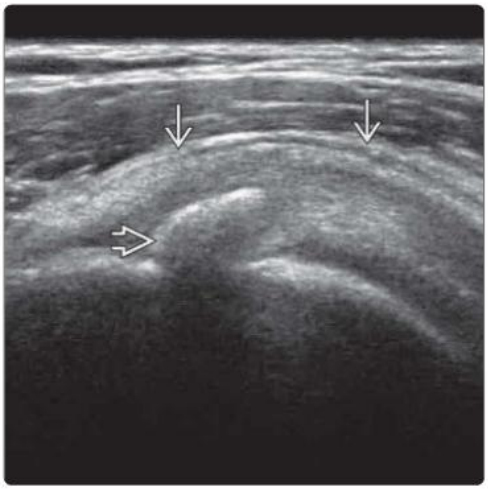

(Left) *Longitudinal US shows a medium-sized area of calcific deposition ⇨ with posterior acoustic shadowing at the supraspinatus insertional area. There is mild background tendinosis ⇨. This can be summarized as mild supraspinatus tendinosis with a medium-sized area of calcific deposition.* **(Right)** *Frontal radiograph in the same patient shows the calcific focus ⇨ close to the greater tuberosity ⇨. US is more sensitive than radiography at depicting calcific deposition within tendons.*

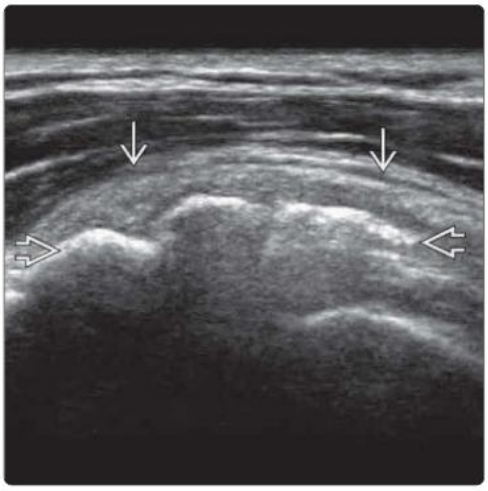

(Left) *Longitudinal US shows mild supraspinatus tendinosis ⇨ with large, clump-like areas of calcification deposition ⇨ within the tendon substance. This can be summarized as mild supraspinatus tendinosis with severe calcific deposition.* **(Right)** *Longitudinal US shows a small, poorly defined area of faint calcification ⇨ within the supraspinatus tendon. Only mild background tendinosis is present. This can be summarized as mild calcific tendinosis with minimal calcific deposition.*

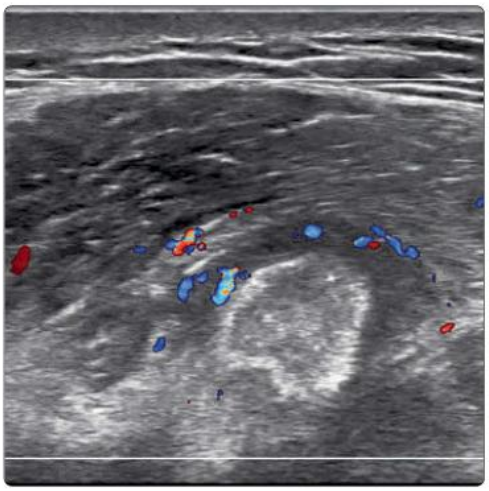

(Left) *Longitudinal US shows severe thickening of the subscapularis tendon ⇨ with a large area of paste-like calcium deposition ⇨ within the tendon substance. There is also an edematous rim surrounding this area ⇨.* **(Right)** *Transverse color Doppler US in the same patient shows moderate hyperemia in the tendon substance and adjacent soft tissue indicative of an inflammatory response associated with the resorptive phase of calcific tendinosis.*

KEY FACTS

TERMINOLOGY

- Partial-thickness, full-thickness, or complete rotator cuff ± biceps tendon tear

IMAGING

- US & MR have comparable accuracy for rotator cuff & biceps tendon tear detection
- Supraspinatus tendon tears most commonly close to or at insertional area (footprint), especially anterior fibers
  - Most tears are avulsive-type from footprint
  - Pay particular attention to anterior leading edge
- Isolated infraspinatus & subscapularis tears less common
  - Infraspinatus: Anterior insertion most common (associated with posterior supraspinatus tendon tear)
  - Subscapularis: Superior insertion most common (associated with biceps ± supraspinatus tendon tear)
- Tears common with moderate to severe tendinosis
- Biceps tendon tears: Either longitudinal split tears or complete transverse tears
  - Most occur at upper bicipital groove ("genu" of tendon)

DIAGNOSTIC CHECKLIST

- Discontinuity of tendon & gap filled with anechoic fluid
  - Focal flattening or concavity of tendon surface
- Nonvisualization of tendon in retracted complete tear
  - ± cartilage interface sign ± superior migration of humeral head in supraspinatus tendon tear
- For partial-thickness tear, determine site, width, & length
  - e.g., for supraspinatus: Anterior/middle/posterior fibers
- For partial-thickness tear, also note % of depth of tear relative to tendon thickness
  - Note whether bursal-sided, articular-sided, or intrasubstance
- Grade severity of tendinosis (mild, moderate, or severe)
- Recognition of intrasubstance tear can be more challenging in moderate to severe tendinosis
  - Intrasubstance tear: Linear, irregular, sharp, hypoechoic area ± volume loss ± fluid motion

(Left) *Longitudinal US shows a full-thickness tear of the supraspinatus tendon midfibers. The gap is filled with anechoic fluid with fibers retracted medially. Note the cortical irregularity of the insertional area.* **(Right)** *Transverse US of the same patient shows the full-thickness tear of the supraspinatus tendon midfibers. Anterior fibers and posterior fibers remain intact. Note the loss of volume with bursal surface contour depression.*

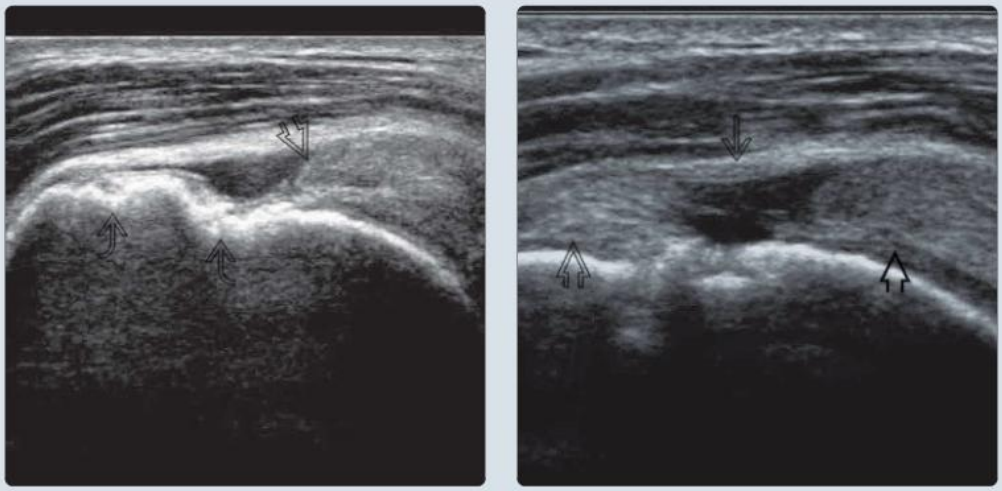

(Left) *Longitudinal US shows a near full-thickness partial tear of the supraspinatus tendon. The gap is filled with anechoic fluid. There are a few intact fibers close to the articular surface with moderate supraspinatus tendinosis.* **(Right)** *Longitudinal US shows an irregular intrasubstance tear within the supraspinatus tendon midfibers. The tear does not extend to the bursal or articular surface.*

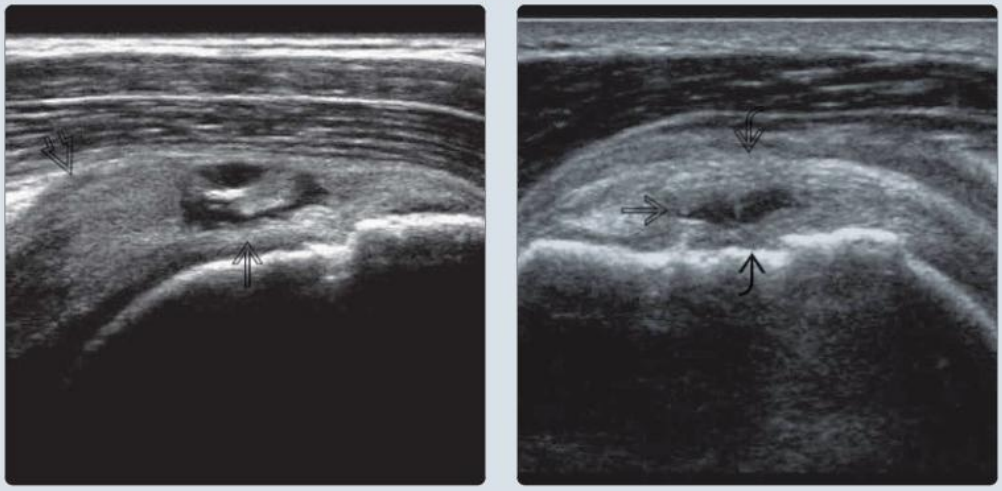

TERMINOLOGY

Definitions

- Complete tear: All fibers of tendon are torn
- Partial tear: Some fibers of tendon are torn
  - Full-thickness tear: Tear involves only part of tendon (e.g., anterior, mid-, or posterior supraspinatus fibers)
  - Partial-thickness tear: Tear involves only part of tendon depth (e.g., bursal, intrasubstance, articular side)
    - Intrasubstance tear does not extend to bursal or articular surface (not seen at arthroscopy)
- Massive tear: Complete supraspinatus & infraspinatus tear

IMAGING

General Features

- Best diagnostic clue
  - Discontinuity of tendon or tendon torn from its insertional area
- Location
  - Supraspinatus most common site of cuff tendon tear
    - Anterior fibers most commonly torn, particularly leading edge
    - Tear may extend posteriorly to infraspinatus or anteriorly to biceps pulley & subscapularis
      - Biceps pulley & transverse ligament tear → medial subluxation biceps tendon
  - Infraspinatus tears most common at anterior insertion
    - Supraspinatus & infraspinatus merge at insertion; not easy to distinguish posterior supraspinatus fibers from anterior infraspinatus fibers
    - Max supraspinatus tendon width (i.e., anteroposterior dimension) at footprint is 25 mm
      - Infraspinatus tendon likely involved if supraspinatus tear extends > 25 mm posterior to biceps tendon
    - Max infraspinatus tendon width at footprint is 28 mm
  - Subscapularis tears most common at superior insertion
    - ± adjacent biceps or supraspinatus tendinosis & tear
    - Important to detect on imaging, as may be concealed arthroscopically ("hidden lesion")
  - Long head biceps tendon tear most upper at uppermost bicipital groove
  - Isolated infraspinatus & subscapularis tears uncommon
  - Teres minor tendon tears very rare
- Types
  - Most cuff tears are avulsive-type (i.e., tendon stripped from insertional area)
  - Some are attrition-type → bursal-side thinning & fraying

Radiographic Findings

- Radiography
  - Features of chronic tendinosis at bony insertion: Cortical irregularity, subcortical sclerosis/cysts
  - In complete supraspinatus tear: Superior migration of humeral head, acromial "acetabularization"
  - Acromial osteophytic spur or hook, laterally downsloping acromion, acromioclavicular osteoarthritis (OA)
  - Rotator cuff arthropathy
    - Large rotator cuff tear → limited dynamic stabilization → glenohumeral decentering → accelerated OA

MR Findings

- T1WI
  - Structural abnormalities predisposing to tear (better seen on MR than US)
    - Acromial osteophytic spurs or hook, thickened coracoacromial ligament, acromioclavicular joint OA
  - Rotator cuff muscle atrophy/fatty infiltration
- T2WI FS
  - Fluid-filling complete or incomplete gap in tendon
    - ± subacromial bursal fluid (better seen on MR than US)
  - MR arthrography most sensitive for articular-surface tears

Ultrasonographic Findings

- Discontinuity or gap within tendon filled with clear anechoic or hypoechoic fluid (primary sign)
  - Gap filled with blood may appear iso- or hypoechoic
  - Most tears are avulsive-type, retracted from footprint
  - Attritional-type appears as flattened, concave, undulated or frayed bursal tendon contour
  - ± gas locules with comet-tail artifacts in acute tear
  - ± small echobright streaks without postacoustic shadow, surrounding by fluid (common in rim-rent tears)
- Intrasubstance tear: Linear, irregular, sharp anechoic or hypoechoic area within tendon substance
- Complete tear with retraction: Nonvisualization of tendon
  - Cartilage interface sign with clear visualization of humeral head cartilage
  - Superiorly migrated humeral head in massive tear
- Background tendinosis usually present
- Fluid within subacromial-subdeltoid bursa
  - Can be large with full-thickness tendon tears
- Cortical irregularity ± cystic change at bony footprint
- Muscle atrophy in chronic tears
- Biceps tendon tears: Either longitudinal split tears or complete transverse tears
  - Most tears preferentially affect uppermost part of bicipital groove, where tendinosis is most common
  - Complete tears seen as empty bicipital groove
    - Collapsed tendon sheath ± synovial hypertrophy may mimic attenuated biceps tendon
    - Retracted long head biceps muscle belly in arm may mimic soft tissue mass
  - Supraspinatus aponeurosis may mimic split tear

Imaging Recommendations

- Best imaging tool
  - US
    - Comparable accuracy to MR for detecting rotator cuff or biceps tendon tears
- Protocol advice
  - Systematic examination
    - Scrutinize supraspinatus tendon anterior leading edge, particularly if unexplained bursal fluid
    - Make sure all insertional area is covered with tendon
  - For partial tears: Note site as well as anteroposterior & mediolateral dimensions of tear
    - Note % of depth of partial-thickness tear relative to tendon thickness
      - Note whether bursal-, articular-sided, or intrasubstance

  - For supraspinatus & infraspinatus, note whether anterior, middle, or posterior fibers torn
  - For subscapularis, note whether superior, middle, or inferior fibers torn
  - Note whether tear located at insertion or proximal to insertion
  - Biceps tears: Extraarticular, junctional "genu" or intraarticular
- Be wary of diagnosing supraspinatus or infraspinatus musculotendinous junction tears with US
- Grade tendinosis severity as mild, moderate, or severe
  - Difficult in acute tear, as tendon is often swollen
- Recognition of intrasubstance tear is more difficult in moderate to severe tendinosis
  - Intrasubstance tear: Linear, irregular, sharp, anechoic or hypoechoic area ± volume loss, fluid motion
  - Small intrasubstance tears are expected feature of severe tendinosis
- Assess supraspinatus & infraspinatus muscle atrophy at scapula
  - ↓ volume, ↑ echogenicity (should be = trapezius or teres minor)
  - Also compare with central tendon echogenicity
- For biceps tendon, scrutinize uppermost part of bicipital groove
  - Grade biceps tendinosis as mild, moderate, or severe
  - If empty bicipital groove, check for
    - Medial biceps subluxation & subscapularis tear
    - Retracted tendon & long head muscle belly ± fatty change at mid to upper arm (complete tear)

DIFFERENTIAL DIAGNOSIS

Bursitis

- Fluid distension of subacromial-subdeltoid bursa
- Fluid first accumulates under & adjacent to acromion, lateral aspect of upper arm, & medial to coracoid process

Rotator Cuff & Biceps Tendinosis

- Usually coexist
- Thickened tendon, lost fibrillar pattern, & ↓ echogenicity

Calcific Tendinitis

- Calcium hydroxyapatite deposition
  - Echogenic foci within tendon ± acoustic shadowing

Rotator Cable

- Band-like fibrous thickening at medial rotator crescent
- Runs perpendicular & deep to supraspinatus & infraspinatus tendons

PATHOLOGY

General Features

- Etiology
  - Rare in patients < 40 years of age
  - Partial- or full-thickness rotator cuff tear in 60% of symptomatic patients > 60 years of age
    - Often spontaneous on background of tendinosis
  - Tears in normal tendons usually due to severe trauma
- Associated abnormalities
  - Subacromial impingement
  - Superior labrum anterior to posterior tears (SLAP)
  - Posterosuperior internal impingement
  - Rotator cuff arthropathy
  - Adhesive capsulitis

Gross Pathologic & Surgical Features

- Thickened, indurated torn tendon edges
- Hemorrhage in interstitial tears
- Associated subacromial-subdeltoid bursitis

Microscopic Features

- Collagen degeneration without inflammatory cells

CLINICAL ISSUES

Presentation

- Most common signs/symptoms
  - Pain & impingement
    - Insidious onset of pain in adults with impingement syndrome
    - Persistence of pain following acute trauma
    - Pain during descent of abducted arm ("painful arc")
    - Partial tears are more painful than full-thickness tears
  - Weakness/limited range of motion
    - Supraspinatus tear: Abduction ± forward flexion
    - Infraspinatus tear: Weak external rotation
- Clinical profile
  - Patient > 40 years-old with impingement; athletes may present younger

Natural History & Prognosis

- Many tears progress from partial to full in < 2 years
- Many symptomatic tears can become asymptomatic
- Smaller tears may heal

Treatment

- Autologous blood injection for partial tears
  - Physiotherapy for minor partial tears
- Arthroscopic debridement, suture anchoring, & subacromial decompression for larger tears
  - Muscle atrophy can improve with successful repair

DIAGNOSTIC CHECKLIST

Consider

- Small supraspinatus surface tear or leading edge tear if unexplained bursal fluid seen
  - Scrutinize tendon contour & anterior edge at footprint

Image Interpretation Pearls

- Systematic examination for secondary signs
  - e.g., footprint cortical irregularity, bursal fluid, flattened tendon contour (flagging peribursal fat sign)
- Be aware of mimics
  - e.g., collapsed biceps tendon sheath mimicking intact attenuated tendon; prominent supraspinatus aponeurosis mimicking split biceps tendon tear
- Suspected tears should be confirmed in 2 planes

SELECTED REFERENCES

1. Sahu AK et al: Role of ultrasound and MRI in the evaluation of postoperative rotator cuff. J Ultrason. 23(95):e188-201, 2023

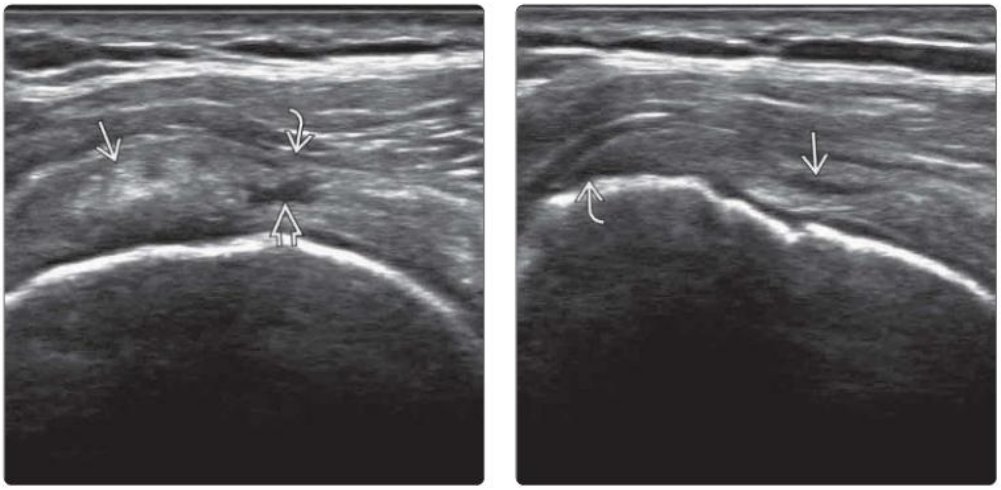

(Left) *Transverse US shows mild supraspinatus tendinosis ➡ with a small, well-defined, irregular hypoechoic area ➡ in the midfibers due to an intrasubstance tear. Note the moderate associated bursal surface contour dipping ➡.* **(Right)** *Longitudinal US of the same intrasubstance supraspinatus tear ➡ shows the tear to be proximal to the footprint. All rotator cuff tendon tears should be confirmed and measured in 2 planes. The hypoechoic area ➡ near the greater tuberosity is due to anisotropy.*

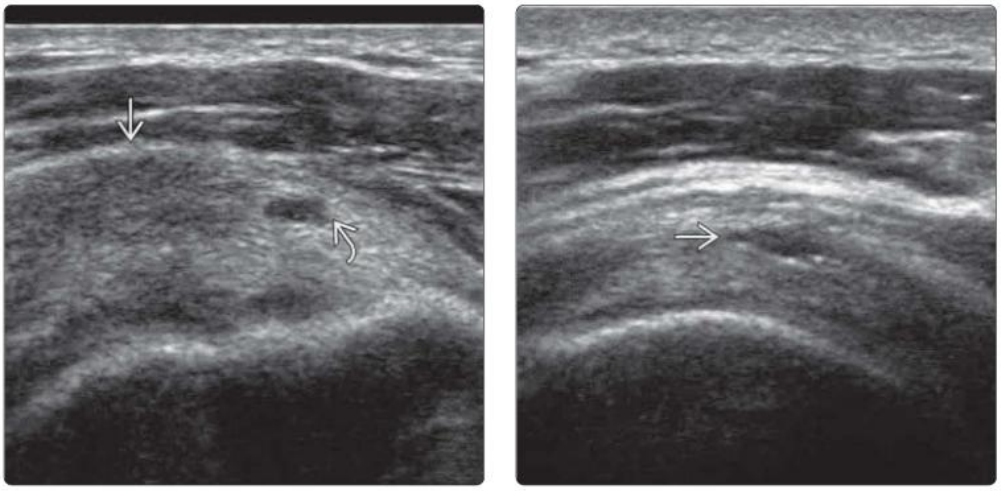

(Left) *Longitudinal US shows moderate to severe supraspinatus tendinosis ➡. There is a more discrete, small, partial-thickness intrasubstance tear ➡. The normal fibrillar echotexture of the supraspinatus tendon is lost.* **(Right)** *Longitudinal US shows a partial intrasubstance tear ➡ involving 25% of the infraspinatus tendon thickness close to the myotendinous junction. This tear does not extend to either the bursal or articular surfaces and would not be seen on arthroscopy.*

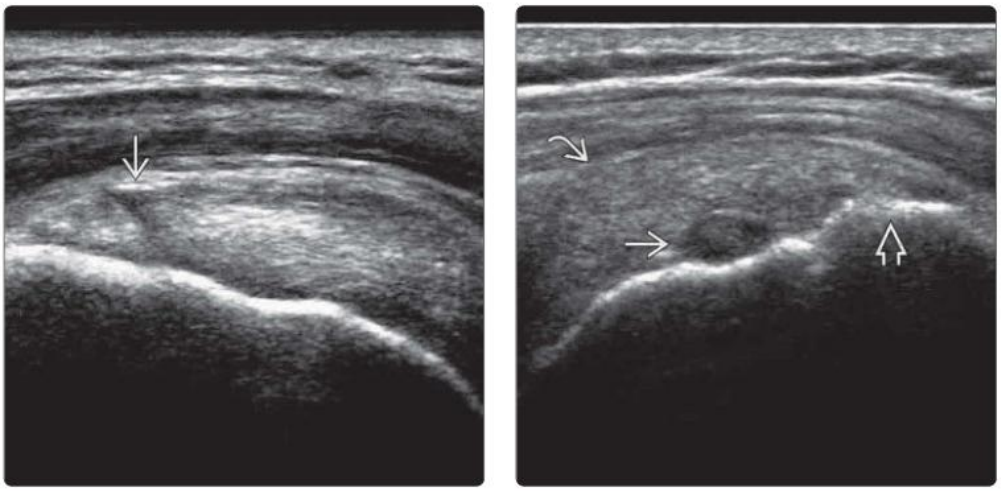

(Left) *Longitudinal US shows a well-defined, hypoechoic, bursal surface tear ➡ overlying the insertional area of the supraspinatus tendon. No bursal fluid is present.* **(Right)** *Longitudinal US shows a small, well-defined, hypoechoic partial-thickness tear ➡ at the articular surface of the supraspinatus tendon. Note the mild supraspinatus tendinosis ➡ and cortical irregularity at the greater tuberosity ➡.*

(Left) *Longitudinal US shows a full-thickness avulsive-type tear ➡ of the supraspinatus tendon with anechoic fluid filling the torn gap. The fibers have stripped from the footprint ➡ with mild retraction.* **(Right)** *Transverse US shows the same partial supraspinatus tear ➡ to involve the anterior fibers of the supraspinatus tendon and wider at the articular margin ➡ than the bursal margin ➡. Both the maximum length (mediolateral) and width (anteroposterior) of the tear should be measured.*

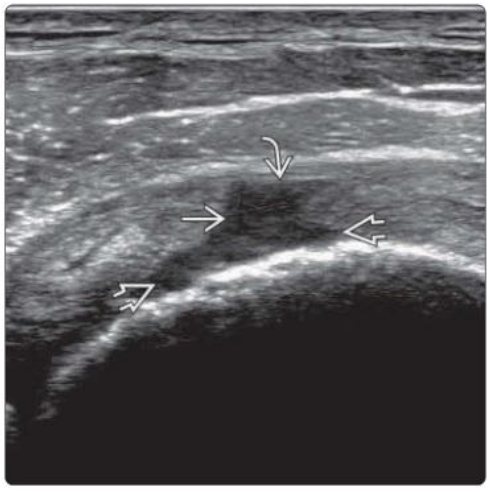

(Left) *Longitudinal US shows a full-thickness tear of the midfibers of the supraspinatus tendon. The torn fibers ➡ are retracted medially from the footprint, which is now bare and irregular ➡. The retraction gap is filled with fluid ➡.* **(Right)** *Longitudinal US shows a complete chronic tear of the supraspinatus tendon just proximal to the footprint ➡ with a bare humeral head ➡. Some residual fibers remain attached to the footprint ➡.*

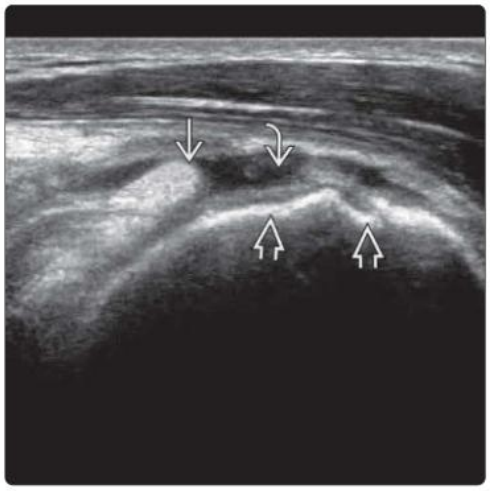

(Left) *Longitudinal US shows a full-thickness tear ➡ of the mid and posterior fibers of the supraspinatus tendon. The retraction gap is filled with fluid and echogenic foci. The humeral head cartilage ➡ underneath the tendon gap is clearly visualized. Note the intact anterior fibers ➡.* **(Right)** *Transverse US of the same patient shows a bare area in the middle facet ➡ of the greater tuberosity due to a full-thickness tear of the mid and posterior fibers. There is moderate tendinosis of the anterior insertional fibers at the superior facet ➡.*

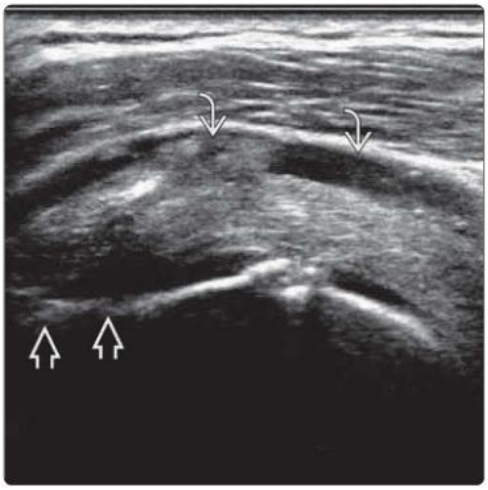

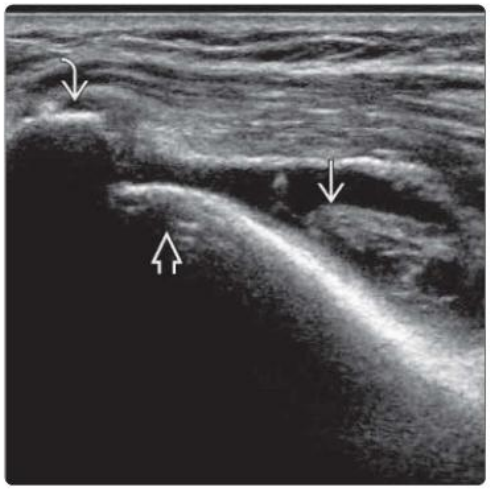

(Left) *Longitudinal US shows moderate supraspinatus tendinosis with a complete avulsive-type tear from the insertional area. There is moderate subacromial-subdeltoid bursal distension containing some echogenic material, consistent with hemorrhage.* **(Right)** *Longitudinal US shows a complete tear of the supraspinatus tendon. The torn tendon end is retracted proximally. The humeral head has superiorly migrated and now lies just deep to acromion.*

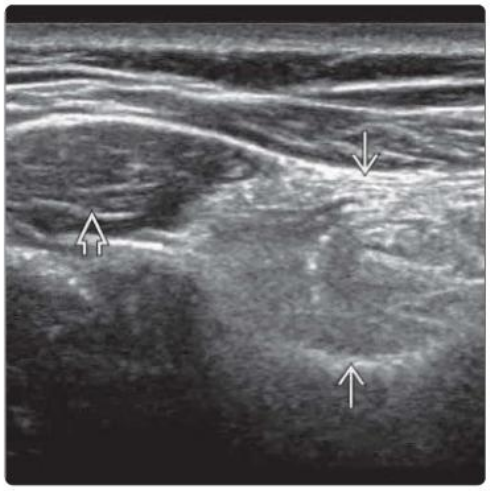

(Left) *Clinical photograph of a patient with rotator cuff tear shows muscle wasting at supraspinatus and infraspinatus muscle areas. Muscle atrophy is more readily appreciated in thin patients.* **(Right)** *Longitudinal US shows fatty atrophy of the infraspinatus muscle in a patient with a massive rotator cuff tear. The hyperechoic infraspinatus muscle has a depressed contour due to volume loss compared to the normal teres minor muscle.*

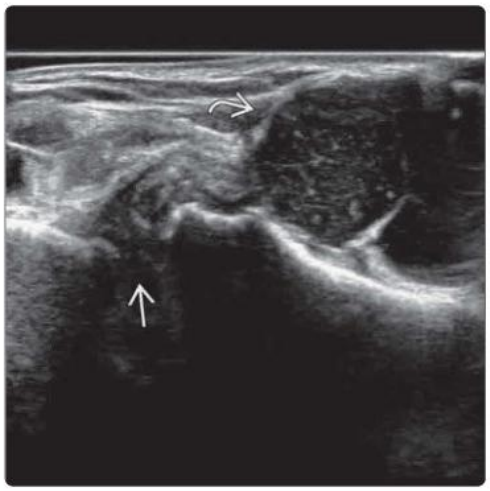

(Left) *Clinical photograph shows a middle-aged man with insidious onset of cystic shoulder swelling.* **(Right)** *Transverse US in the same patient shows a large ganglion cyst overlying the lateral end of the clavicle. This ganglion has arisen as a result of a complete supraspinatus tear, with superior migration of the humeral head, acromioclavicular (AC) capsular attrition, and leakage of glenohumeral fluid through the AC joint to the ganglion. This is characteristic of rotator cuff arthropathy and the "geyser phenomenon."*

(Left) *Transverse US shows a large, partial-thickness tear ➡ of the midfibers of the subscapularis tendon extending to the superficial margin of the tendon ➡.* **(Right)** *Longitudinal US shows an avulsive-type tear of the subscapularis tendon from the insertional area ➡ on the medial lip of the bicipital groove. The tendon fibers are retracted medially ➡ with fluid filling the retraction gap.*

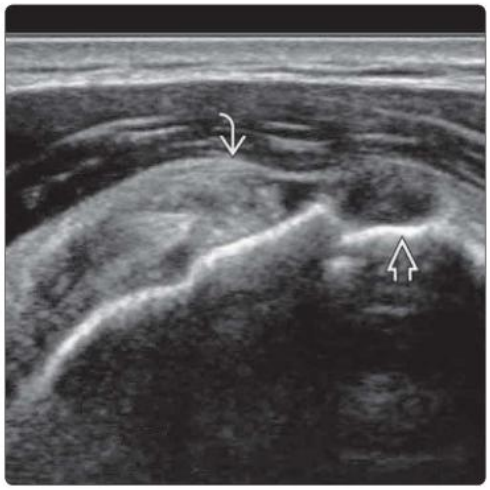

(Left) *Transverse US shows a longitudinal split tear ➡ in the subscapularis tendon ➡ involving the biceps pulley. The biceps long head tendon ➡ is medially subluxed and located at the superior aspect of the lesser tuberosity ➡ rather than within the bicipital groove ➡.* **(Right)** *Transverse US in the same patient at a slightly more cephalad location shows the medial subluxation of the thickened biceps long head tendon ➡ into the subscapularis tendon substance ➡.*

(Left) *Transverse US shows moderate biceps tendinosis with mild synovial proliferation within the surrounding tendon sheath ➡. There is a wide intrasubstance tear ➡ within the deeper aspect of the biceps tendon.* **(Right)** *Longitudinal US in the same patient shows moderate biceps tendinosis ➡ near the proximal end of the bicipital groove with an irregular, longitudinal, split-like tear ➡ of the deeper fibers. Nearly all partial-thickness biceps tendon tears are longitudinal split tears.*

(Left) *Clinical photograph shows a roundish swelling of the upper arm ⇨, which was more pronounced with attempted contraction, compatible with Popeye sign of complete rupture of long head biceps tendon (LHBT).* **(Right)** *Transverse US in the same patient shows absent LHBT in the bicipital groove due to complete tear. There is a residual thickened tendon sheath ⇨, which can mimic an intact tendon. Note the adjacent cortical irregularity ⇨ of the bicipital groove, which can precipitate tendon attrition.*

(Left) *Transverse US in the same patient more distally at the midhumerus level shows the distally retracted, torn LHBT stump ⇨.* **(Right)** *Longitudinal US shows a retracted myotendinous junction ⇨ of the long head of the biceps due to a complete tendon tear. The tendon sheath ⇨ located proximally seems to contain blood.*

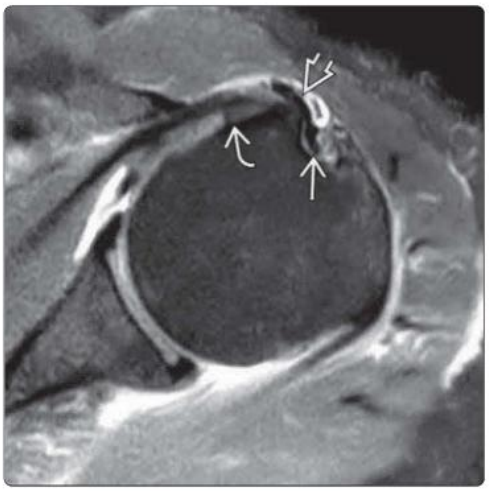

(Left) *Transverse US at the bicipital groove shows an apparent intact LHBT ⇨, which was in fact a mimic from a displaced prominent supraspinatus aponeurosis. The actual LHBT is medially subluxed ⇨ with a split tear ⇨. Prominent supraspinatus aponeurosis or residual tendon sheath may mimic intact LHBT.* **(Right)** *Axial T2 FS MR in the same patient shows the medially subluxed LHBT ⇨ and displaced supraspinatus aponeurosis within the bicipital groove mimicking an intact LHBT ⇨. Note subscapularis tendinosis ⇨.*

KEY FACTS

TERMINOLOGY

- Tendinosis: Degenerative disease of tendon with variable degree of peritendinitis

IMAGING

- Some tendons (common extensor tendon origin, 1st extensor compartment wrist, Achilles, patellar, posterior tibialis) are particularly susceptible to tendinopathy
- Focal, diffuse, or nodular tendon enlargement with hypoechogenicity & loss of normal fibrillar pattern
- Hyperemia correlates with activity of tendinopathic process
- Tendinosis predisposes to tendon tears, which are uncommon in normal tendons
- Partial tears are seen as sharp, linear, hypoechoic defects within area of tendinosis
  - Usually split tears
  - Should not be confused with dilated vascular channels within hyperemic tendon
- Variable peritendinitis: Swelling, edema, & hyperemia of tissues around tendon
  - Peritendinitis is important feature to assess, as it will respond to antiinflammatory medication
- Additional secondary signs
  - Tendon calcification
  - Tendon sheath effusion
  - Cortical erosion or hyperostosis at insertional area
  - Bursitis

DIAGNOSTIC CHECKLIST

- Grade level of tendinosis & peritendinitis as mild, moderate, or severe
  - Inspect tendon substance & edges for small tendon tears
- Routinely examine with color Doppler imaging
  - Use minimal transducer pressure for superficial tendons
- Be careful about using contralateral asymptomatic side, as normal reference as subclinical tendinosis is common

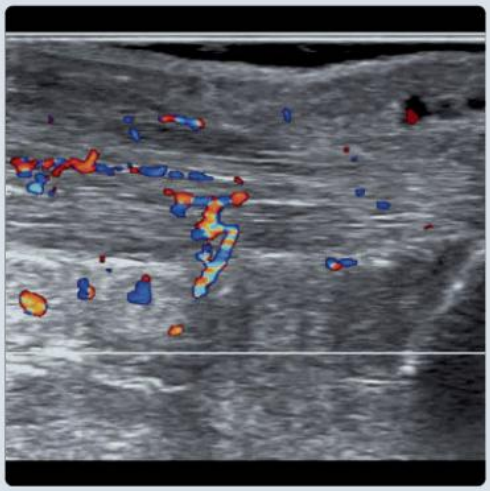

(Left) *Longitudinal US of the mid-Achilles tendon shows severe diffuse thickening with mild thickening of the paratenon ⇨, consistent with severe tendinopathy. There are several foci of calcification ⇨ within the tendon.* **(Right)** *Longitudinal color Doppler US of the Achilles tendon shows marked hyperemia in the thickened midportion of the tendon. Dystrophic calcification tends to be seen more in insertional, rather than noninsertional, tendinosis.*

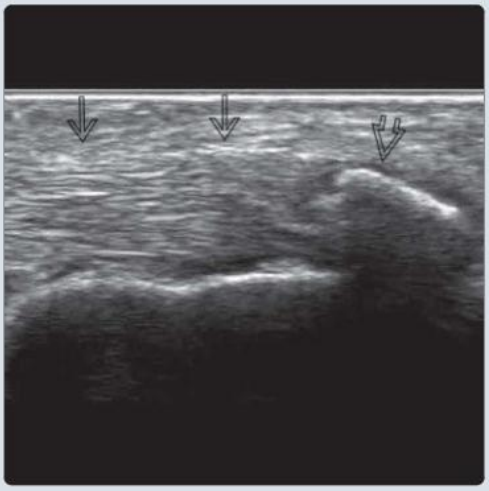

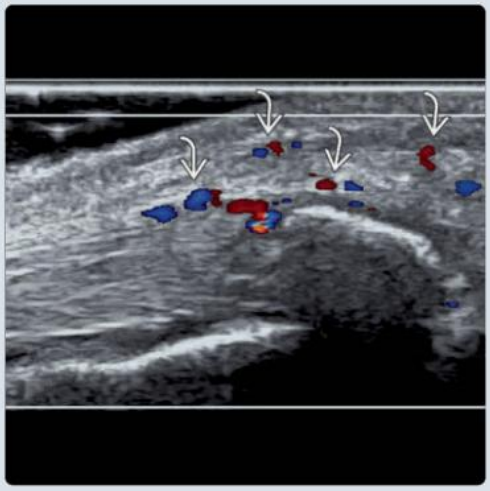

(Left) *Longitudinal US of a 55-year-old man with posterior heel pain 2 months following a football game shows a mildly thickened with otherwise normal-appearing Achilles tendon ⇨ and a prominent posterior calcaneal spur ⇨.* **(Right)** *Longitudinal color Doppler US in the same area with minimal transducer pressure shows moderate peritendinosis and superficial tendinous hyperemia ⇨ indicating moderate peritendinitis with mild active tendinosis. Color flow imaging is helpful in detecting active tendinosis.*

TERMINOLOGY

Synonyms

- Tendinitis

Definitions

- Disease of tendon with variable degree of peritendinitis
  - Peritendinitis is inflammation of soft tissues surrounding tendon
- Collagenous tendon degeneration with proteoglycan deposition

IMAGING

General Features

- Best diagnostic clue
  - Focal, diffuse, or nodular tendon enlargement with loss of normal fibrillar echotexture
- Location
  - Some tendons are more susceptible to tendinosis
    - Achilles: Calcaneal insertion > midportion of tendon
    - Patellar: Proximal > distal; deep > superficial
    - Posterior tibialis: Insertion > retro- or inframalleolar segments
    - Common extensor > common flexor tendon origin at elbow
    - Gluteus minimus & medius insertion at greater trochanter insertion > gluteus maximus
    - Ischial attachment (origin) of hamstring tendons
  - Susceptible areas
    - Tendon insertion or areas where tendons curve (e.g., genu of biceps tendon at cephalad end of bicipital groove)
- Morphology
  - Normal appearance
    - Fibrillar pattern, homogeneous isoechoic appearance
    - Anterior convexity of middle 1/3 of Achilles tendon
  - Measurements vary along different parts of tendon
    - Normal cross-sectional area of Achilles tendon
      - 0.54 ± 0.11 cm^2 at musculotendinous junction; 0.54 ± 0.12 cm^2 at midlevel; 0.74 ± 0.15 cm^2 at calcaneal insertion
    - Normal size of posterior tibialis tendon
      - ~ 2x size of flexor digitorum longus tendon
      - < 0.16 cm^2 at retromalleolar; < 0.18 cm^2 at inframalleolar; < 0.27 cm^2 at insertion
  - Paired tendons can have different diameter
    - Peroneus longus tendon normally slightly larger than peroneus brevis tendon

Ultrasonographic Findings

- Increased tendon thickening with hypoechogenicity & variable loss of normal fibrillar pattern
  - Cross-sectional area of tendon measured at specific locations
    - Useful for follow-up rather than diagnosis; tendon morphology slower to change
- Proteoglycan accumulation: Focal hypoechoic area bulging tendon margins
- Hyperemia within or around tendon is common feature
  - Level of hyperemia correlates with disease activity
    - Hyperemia not seen in rotator cuff tendinosis
- Intrasubstance partial tear seen as sharp, linear hypoechoic defect within area of tendinosis
  - Occurs with moderate to severe degrees of tendinosis; usually runs longitudinally in tendon ("split tear")
  - May be difficult to distinguish from areas of focal proteoglycan deposition
    - Tear is discrete, linear, sharper, & more hypoechoic
  - Dilated vascular channels within hyperemic tendon may mimic tear
- Secondary signs of tendinosis common in moderate to severe tendinosis
  - Tendon sheath effusion, if tenosynovium present
  - Dystrophic calcification within tendinosis, more common with insertional tendinosis
  - Reactive cortical irregularity or hyperostosis of insertional area
  - Adjacent bursitis (Achilles)
  - Paratenonitis (Achilles, patella)
- Secondary signs may be seen in normal asymptomatic subjects
  - Focal calcification of Achilles tendon (21% of normal subjects)
  - Fluid in retrocalcaneal bursa (35% of normal subjects)
  - Calcaneal bony contour abnormality (63% of normal subjects)
- Variable peritendinitis of surrounding soft tissues
  - Swelling, edema, & hyperemia on color Doppler imaging
  - Grade as mild, moderate, or severe
  - Peritendinitis important feature to note, as it will respond to antiinflammatory medication
  - Tendinosis per se is not inflammatory disease
- Elastography
  - Potentially useful in early tendinosis before grayscale features become apparent

Radiographic Findings

- Radiography
  - Sclerosis, cortical irregularity, hyperostosis of insertional tendinosis
  - Intratendinous dystrophic calcification
  - Accessory navicular bone associated with posterior tibialis tendinosis

MR Findings

- Increased T1, T2, PD signal within enlarged tendon
- Hyperintense inflammatory fluid around tendon
- Partial tears discrete hyperintensity on T2 FS
- Reactive marrow change seen at enthesis

Imaging Recommendations

- Best imaging tool
  - US, as nearly all tendons are readily accessible
- Protocol advice
  - Examine both symptomatic & contralateral side
    - Be careful about using asymptomatic contralateral side as normal standard, as subclinical tendinosis is common
    - Always evaluate severity & location of peritendinitis
  - Use minimal transducer pressure to avoid blanching color Doppler signal

- Grade severity of tendinosis as mild, moderate, or severe
- Anisotropy can be used to differentiate tendon from surrounding fat
- Anisotropy can mimic tendinosis, so toggle transducer to make anisotropy disappear

DIFFERENTIAL DIAGNOSIS

Xanthoma

- Affects Achilles > patellar tendon
- Affected areas tend to be more focal & less hyperemic than tendinosis; dystrophic calcification more common
- Features of severe hypercholesterolemia
  - ± thickening of extensor tendon hoods over metacarpophalangeal joints

Tenosynovitis

- Disease of tendon sheath
  - Only affects tendons with complete synovial sheath
- Tenosynovial inflammation, rather than tendon thickening, is predominant
- Often tenosynovitis & tendinosis coexist

PATHOLOGY

General Features

- Etiology
  - Repetitive overuse → microtrauma with collagen bundle microfracture & incomplete healing
  - Achilles: Hypovascular watershed zone 2-6 cm proximal to calcaneal insertion
    - Eccentric loading of fatigued muscle-tendon unit or overtraining
    - Runners susceptible to acceleration (sprinting) & deceleration (eccentric contraction) injuries
  - Posterior tibialis: Flatfoot & accessory navicular bone ± cornuate configuration navicular bone
    - Reactive thickening superior calcaneonavicular fibers of spring ligament on US
  - Patellar tendon: Running & jumping
    - Microtrauma between patellar bone tip & central deep fibers of adjacent patellar tendon
- Relevant anatomy
  - Achilles & patellar tendons have incomplete synovial sheath
- Posterior tibialis inserts into accessory navicular bone (when present), medial pole of navicular bone, & cuneiform bones
  - Cornuate navicular is elongated medial pole of navicular bone

Gross Pathologic & Surgical Features

- Tendon is gray instead of glistening white
- Nodular thickening, calcification ± partial tendon tear
- Inflamed tissues around tendon

Microscopic Features

- Features of failed healing response
  - Noninflammatory intratendinous collagen degeneration
  - Fiber degeneration (fibrinoid, mucoid) & thinning with partial tears
  - Hypercellularity with scattered vascular ingrowth
  - Increased interfibrillar glycosaminoglycans (chondroitin sulfate)
- Inflammation of peritendinous tissues

CLINICAL ISSUES

Presentation

- Most common signs/symptoms
  - Pain with stretching of tendon
- Other signs/symptoms
  - Tendinosis is often visible on US with minimal or no symptoms (subclinical presentation)
    - Subclinical disease is common on contralateral side in patients with unilateral symptoms
- Clinical profile
  - Chronic dull to sharp pain at onset of exercise
    - Gradually subsides with more exercise & returns following cessation of exercise

Demographics

- Age
  - Young to middle-aged adults (most common), young athletes, & older sedentary populations
- Epidemiology
  - Usually associated with either physical or physiologic overuse

Natural History & Prognosis

- Severe features seen on US bode for chronic relapsing & remitting symptomatology
- Mild features seen on US bode for favorable outcome
- Tendinosis predisposes to tendon tears
  - Tears uncommon in normal tendons
  - Risk of tendon tear increases with increasing severity of tendinosis

Treatment

- Conservative
  - Rest & immobilization
  - Controlled, slow stretching exercise
  - Antiinflammatory medication if peritendinitis
- Nonconservative
  - US-guided dry needling, autologous blood injection (ABI), platelet-rich plasma (PRP) injection, barbotage, sclerotherapy
    - Dry needling is as effective as PRP & ABI for treating tendinosis
  - US-guided steroid injection for peritendinitis
  - Debridement for focal proteoglycan accumulation
  - Suturing of large tears

DIAGNOSTIC CHECKLIST

Consider

- Grade tendinosis & peritendinitis as mild, moderate, or severe with help of color Doppler imaging
- Look for secondary features & tendon tears
- Measurement of tendon caliber is useful for follow-up

SELECTED REFERENCES

1. Delbello F et al: Calcific tendinopathy atypically located outside the rotator cuff: a systematic review. Curr Med Imaging. 20:e100423215585, 2024
2. Sharif F et al: Does the ultrasound imaging predict lower limb tendinopathy in athletes: a systematic review. BMC Med Imaging. 23(1):217, 2023

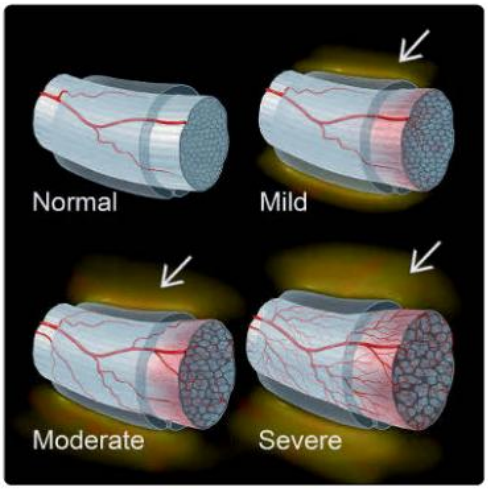

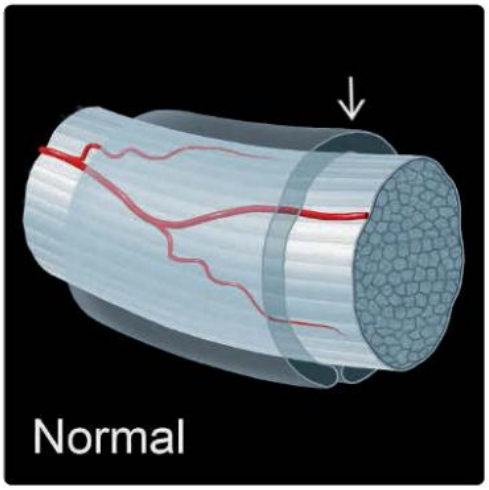

(Left) *Graphic shows grades of tendinosis. The severity of tendinosis and degree of surrounding peritendinitis ➡ should be independently graded. The more severe the tendinosis, the greater the risk of tendon tear. The more severe the peritendinitis, the greater the clinical response to antiinflammatory medication.* **(Right)** *Graphic shows a normal tendon structure with a tendon sheath ➡. Most tendons do not have a tendon sheath.*

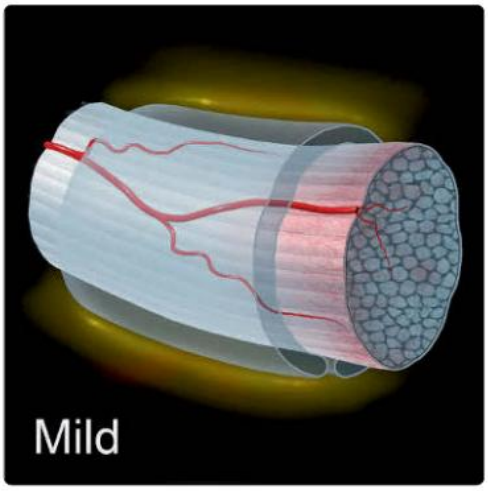

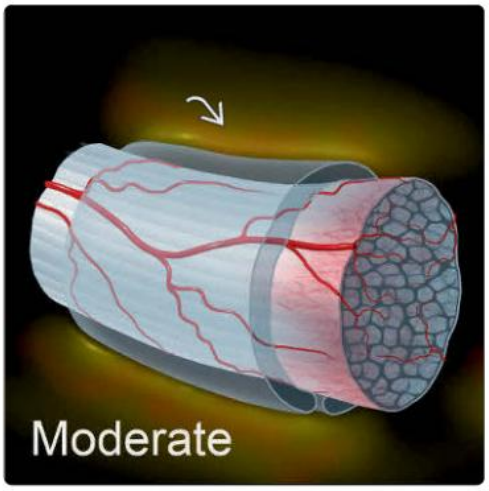

(Left) *Graphic shows mild tendinosis with mild tendon swelling (due to proteoglycan accumulation) and tendon hyperemia. Intrinsic vascularity is generally not a feature of normal tendons.* **(Right)** *Moderate tendinosis with more swollen tendon, proteoglycan deposition, and hyperemia is shown. Although tendinosis and peritendinitis ➡ (seen as peritendinous edema and hyperemia) severity are broadly interrelated, both features should be independently graded as mild, moderate, or severe.*

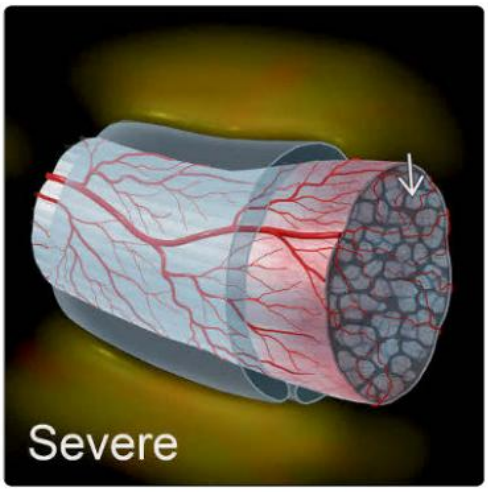

(Left) *Graphic shows severe tendinosis with severe tendon swelling and hyperemia ➡ (manifested on US as tendon swelling, tendon hypoechogenicity, loss of fibrillar pattern, and tendon hyperemia). Mild tenosynovial swelling is a commonly seen feature of peritendinitis and, as such, is disguisable from primary tenosynovitis in which the tendon is usually normal.* **(Right)** *Longitudinal US of the palmaris longus tendon shows how tendinosis is often localized to that segment of tendon ➡ under the most physical stress.*

(Left) *Transverse US in the same patient shows moderate severity palmaris longus tendinosis ⇨ with tendon thickening, hypoechogenicity, and loss of fibrillar pattern. The adjacent median nerve ⇨ is mildly indented.* **(Right)** *Transverse color Doppler US shows moderate peritendinous ⇨ and mild tendon hyperemia ⇨ reflecting active disease. Overall appearances indicate moderate severity palmaris longus tendinosis with moderate peritendinitis.*

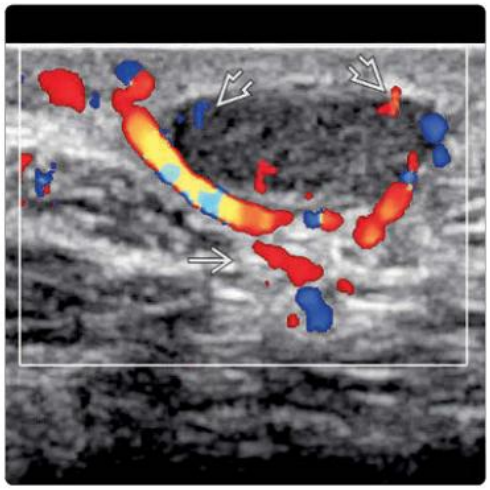

(Left) *Clinical photograph shows severe swelling of the Achilles tendon region ⇨. There was moderate localized tenderness.* **(Right)** *Transverse US shows a severely thickened Achilles tendon with mildly thickened paratenon ⇨. Small curvilinear hypoechoic areas ⇨ may represent partial tears or prominent intratendinous vessels. These can be differentiated with color Doppler imaging. Small intrasubstance tears are an expected feature of severe tendinosis.*

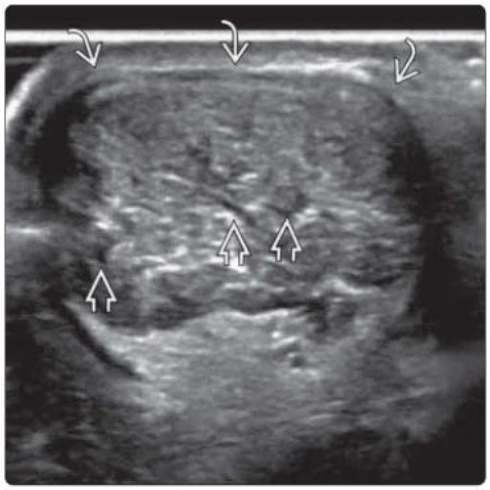

(Left) *Longitudinal US of the midportion of the Achilles tendon in the same patient shows severe diffuse thickening ⇨ due to severe Achilles tendinopathy. Small linear hypoechoic areas ⇨ are due to small tears (common in severe tendinosis).* **(Right)** *Longitudinal color Doppler US of the same area shows severe intratendinous and peritendinous hyperemia indicating active tendinosis. Color flow is best assessed with the tendon relaxed, the transducer still, and with minimal or no transducer pressure.*

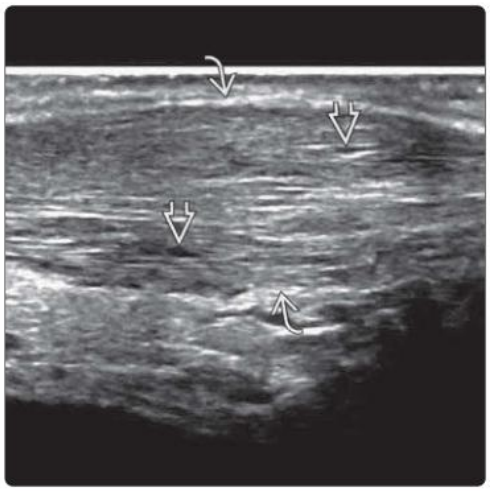

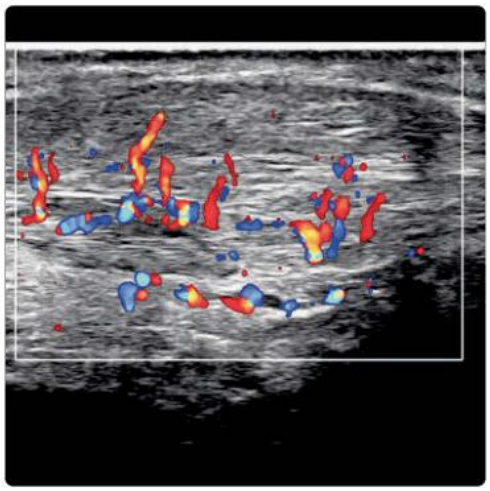

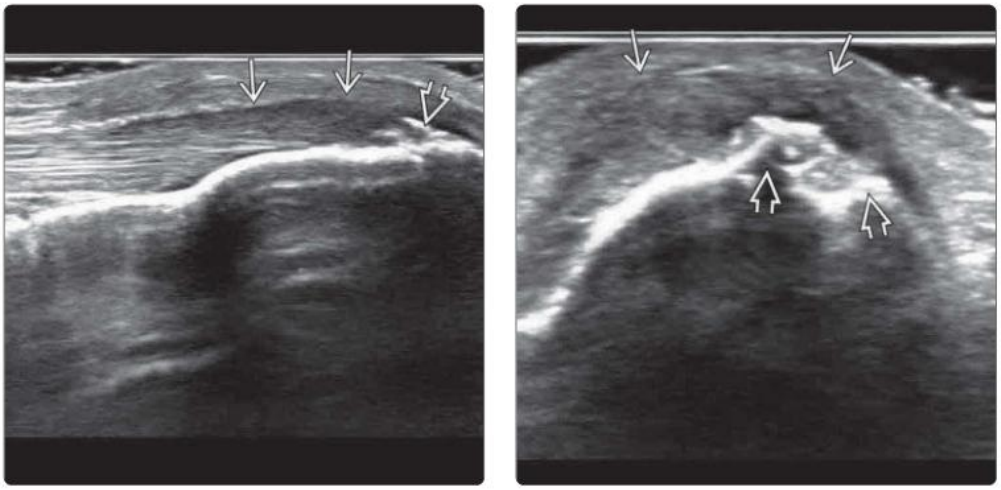

(Left) *Longitudinal US of a patellar tendon shows moderate insertional tendinosis with moderate tendon thickening at the tibial insertion and loss of the fibrillar pattern ⇨. There is associated mild insertional cortical irregularity ⇨.* **(Right)** *Transverse US of the same area shows the heterogeneous hypoechoic appearance of the tendon fibers at the insertion ⇨ with typical insertional cortical irregularity ⇨.*

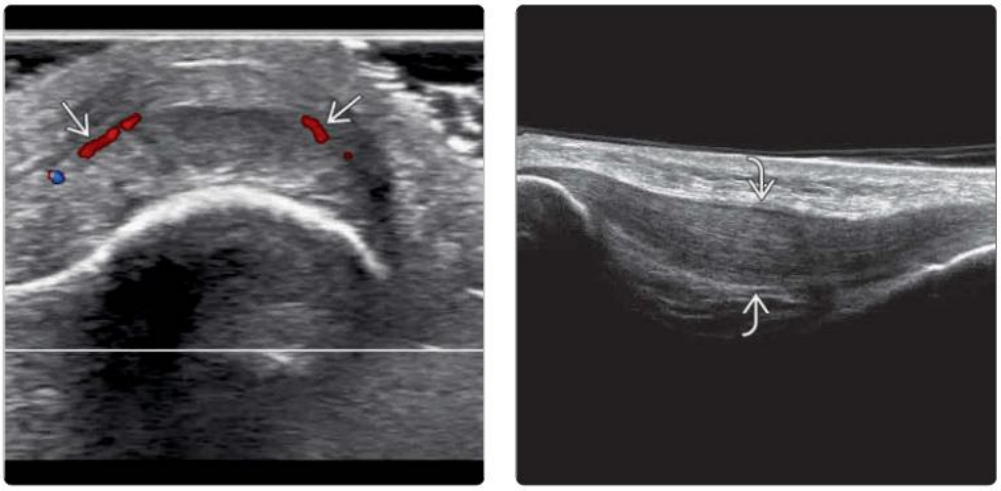

(Left) *Transverse color Doppler US of the same patellar tendon shows moderate intratendinous hyperemia ⇨, consistent with an active reparative response within the area of tendinosis.* **(Right)** *Longitudinal panoramic US of the patellar tendon shows diffuse thickening, particularly of the midportion ⇨. The whole tendon is more hypoechoic than normal.*

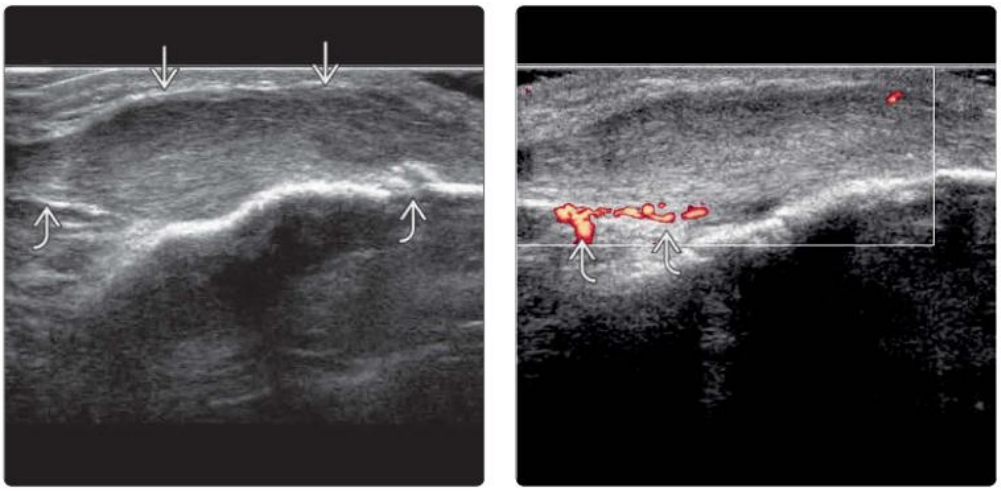

(Left) *Longitudinal US of a patellar tendon close to the tibial insertion shows severe focal thickening with hypoechogenicity and loss of the fibrillar pattern ⇨, consistent with severe tendinosis. Mild cortical irregularity ⇨ is present.* **(Right)** *Longitudinal power Doppler US of the same area shows peritendinous hyperemia ⇨ due to inflammation and a reparative response.*

(Left) *Longitudinal color Doppler US of a quadriceps tendon shows mild thickening at the patellar insertion. Mild intrasubstance dystrophic calcification is present. There is no significant hyperemia present, which favors quiescent disease.* **(Right)** *Sagittal PD MR of the knee in the same patient shows a moderately thickened quadriceps tendon with minimal tendon hyperintensity corresponding to the US findings of quadriceps tendinosis.*

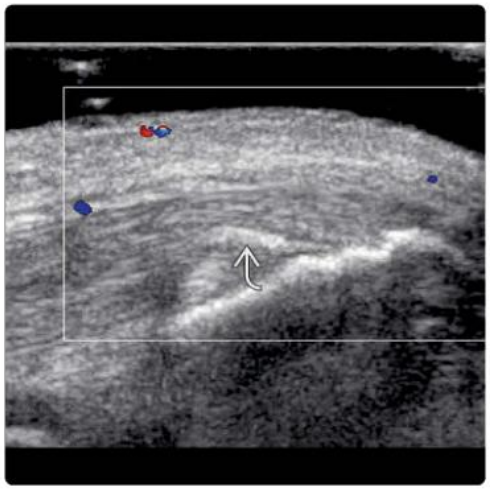

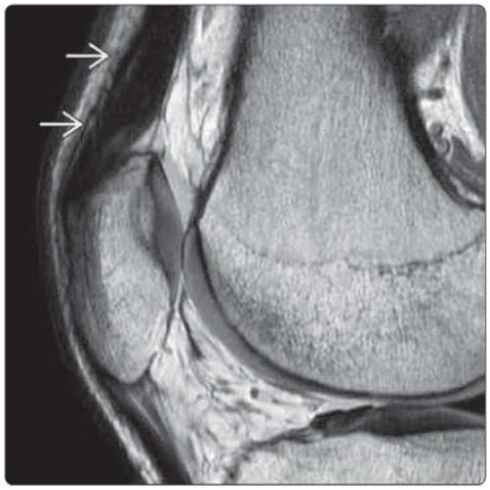

(Left) *Longitudinal US of quadriceps tendon shows moderate tendon thickening with severe intratendinous dystrophic calcification. Clinical symptoms help distinguish this tendinosis with dystrophic calcification from calcific tendinitis.* **(Right)** *Transverse US in the same patient shows several calcified areas within the thickened quadriceps tendon. This is severe dystrophic calcification with tendinosis rather than calcific tendinitis. The latter is much more painful, tender, and inflamed, particularly in the resorptive phase.*

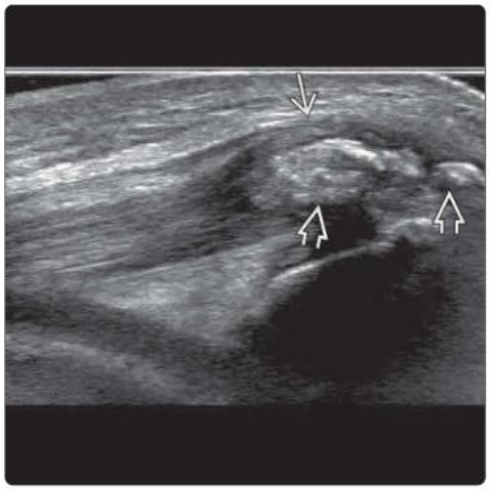

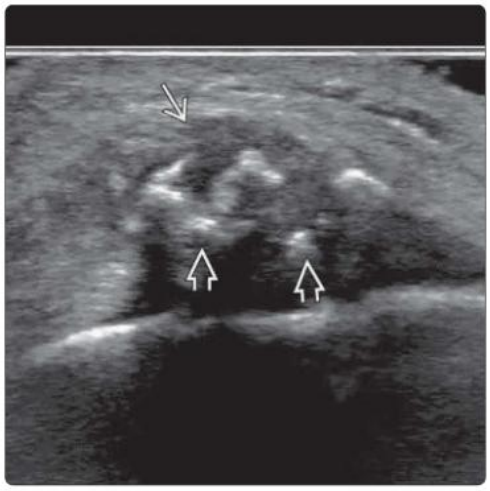

(Left) *Peroneus longus tendon is swollen with heterogeneous loss of fibrillar pattern and irregular echotexture due to microtears. The adjacent peroneus brevis tendon is normal.* **(Right)** *Transverse color Doppler US of the same area shows severe peritendinous and tendon hyperemia indicating severe active tendinosis, reflecting disease activity.*

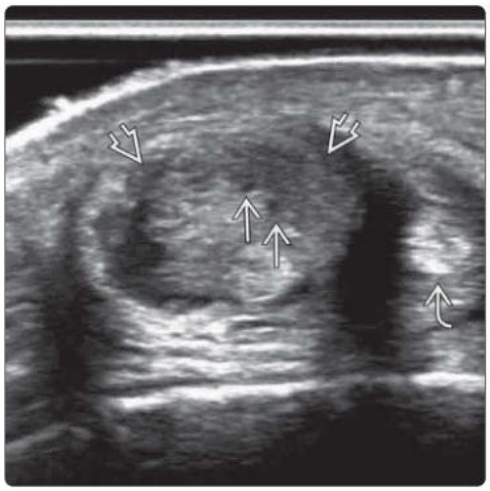

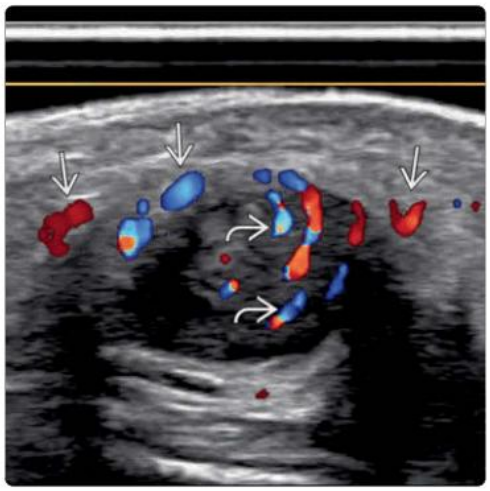

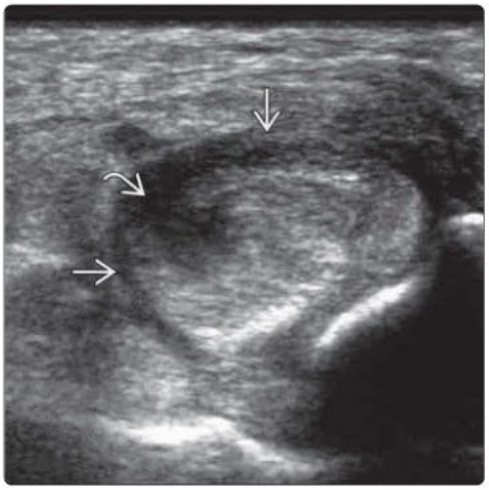

(Left) *Clinical photograph shows a patient who had flat foot and pain for 1 year. There is collapse of the longitudinal arches with moderate heel valgus deformity. Abnormal stresses are placed on the medical side of the ankle and foot.* **(Right)** *Transverse US of the retromalleolar tibialis posterior tendon in the same patient shows severe tendinosis with a thickened heterogeneous tendon ➡. The hypoechoic area ➡ within the tendon with an ill-defined margin is most likely due to proteoglycan accumulation rather than anisotropy.*

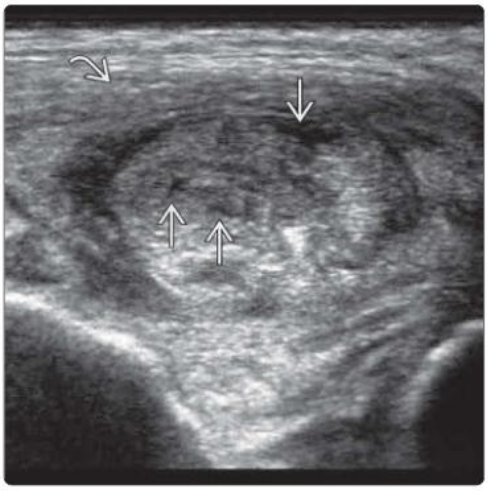

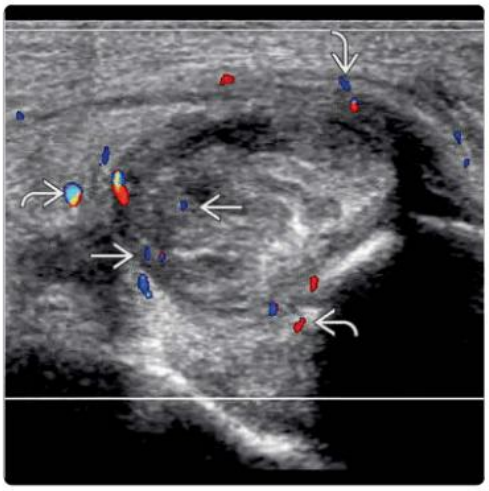

(Left) *Transverse US of the same tibialis posterior tendon at the inframalleolar level shows severe tendinosis with several small hypoechoic areas ➡, consistent with small intrasubstance tears. There is moderate thickening of the overlying flexor retinaculum ➡.* **(Right)** *Transverse color Doppler US of the same area shows moderate intratendinous ➡ and peritendinous hyperemia ➡, consistent with moderate disease activity and moderate peritendinitis.*

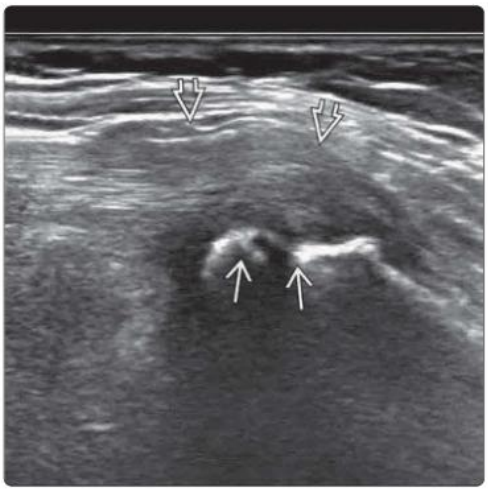

(Left) *Longitudinal US of the distal semimembranosus tendon shows moderate thickening and bulging at the tibial insertion ➡ associated with mild cortical irregularity of the proximal tibia ➡. No hyperemia was evident (not shown). These features indicate low-grade chronic tendinosis.* **(Right)** *Transverse US of the same area shows tendon thickening and hypoechogenicity ➡. The medial gastrocnemius muscle ➡ and semitendinosus tendon ➡ laterally are normal.*

(Left) *Longitudinal US of the elbow shows a normal common extensor tendon origin (CETO) ⇨ at the lateral epicondyle ⇨. The tendon is not thickened and has a normal fibrillar pattern with no calcification or tear. The tendons course over the radiohumeral articulation ⇨.* **(Right)** *Longitudinal US of the contralateral abnormal CETO shows severe heterogeneous echogenic tendon thickening ⇨ with an intrasubstance partial tear of the midfibers filled with fluid ⇨.*

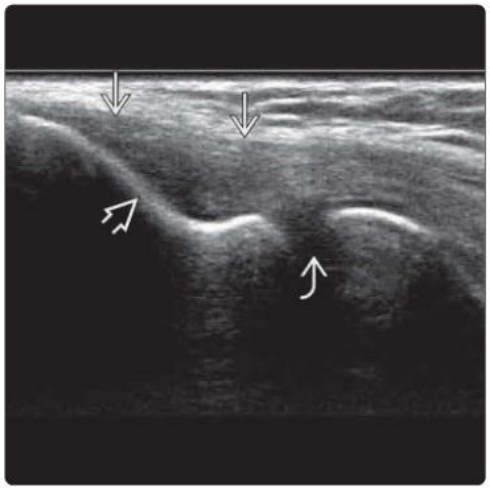

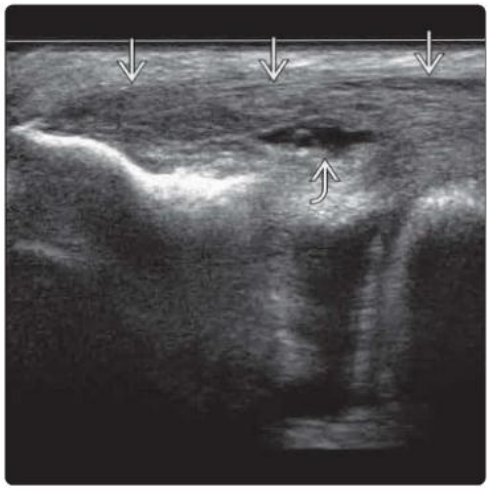

(Left) *Longitudinal color Doppler US of the same area shows severe hyperemia within the thickened tendon, consistent with severe disease activity.* **(Right)** *Transverse color Doppler US shows a severely thickened CETO with several small echogenic foci due to dystrophic calcification ⇨. Small discrete tears are present at the insertion ⇨. Minimal hyperemia is present.*

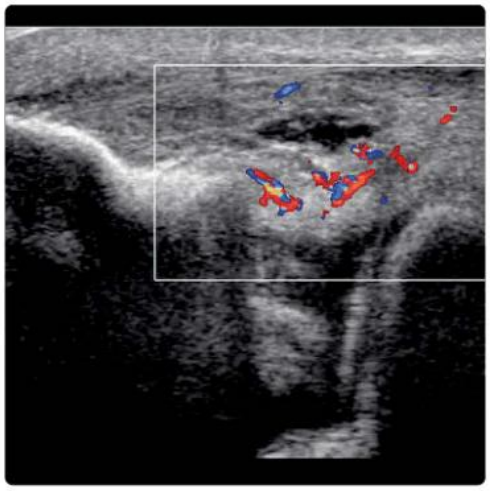

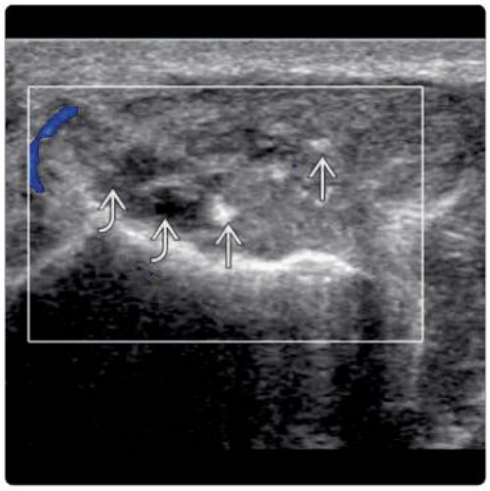

(Left) *Longitudinal US of common flexor tendon origin (CFTO) shows moderate tendon thickening ⇨ and hypoechogenicity with a small area of dystrophic calcification ⇨. Dystrophic calcification is quite common in insertional tendinosis of the Achilles and quadriceps tendons and, to a lesser degree, the CFTO.* **(Right)** *Moderate thickening with decreased fibrillar pattern of the extensor carpi ulnaris ⇨ is indicative of tendinosis with severe thickening of the extensor retinaculum ⇨. A microtear is present within the tendon ⇨.*

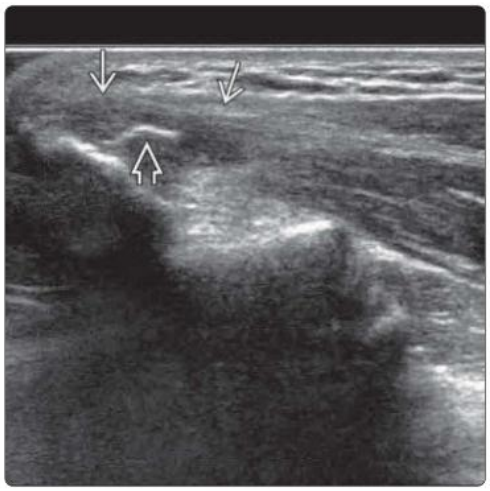

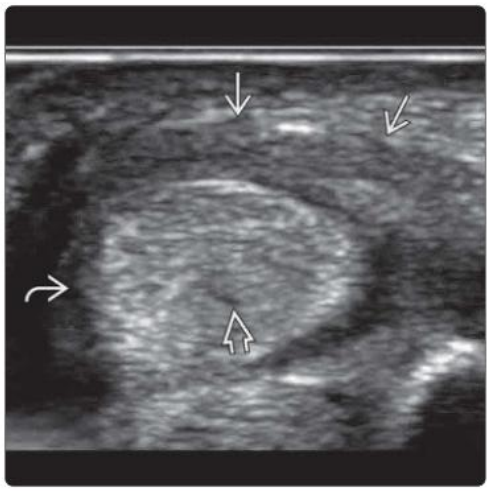

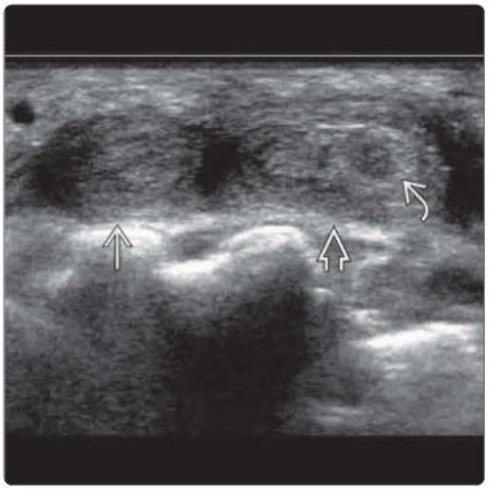

(Left) *Clinical photograph shows a patient with dorsal hand pain and swelling. Note the swelling of the extensor digitorum (ED) tendons to the middle and index fingers ➡.* **(Right)** *Transverse US of ED tendons to index ➡ and middle ➡ fingers in the same patient shows marked swelling with loss of the fibrillar pattern. The focal hypoechoic area ➡ within the tendon is consistent with myxoid accumulation.*

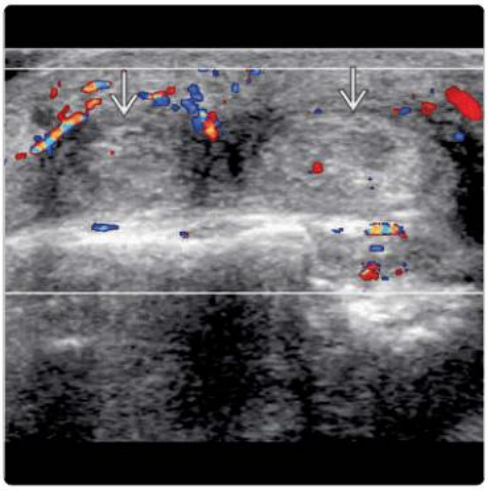

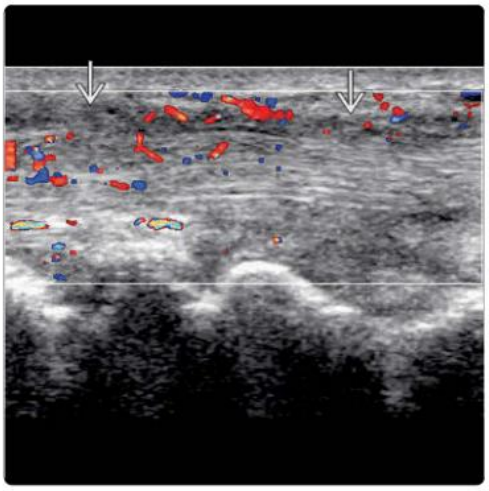

(Left) *Transverse color Doppler US in the same patient shows moderate hyperemia around the thickened ED tendons ➡, consistent with moderate peritendinitis. The tendon sheath is not present at this level.* **(Right)** *Longitudinal color Doppler US of the same area shows ED tendon ➡ thickening with intratendinous hyperemia, consistent with moderate disease activity.*

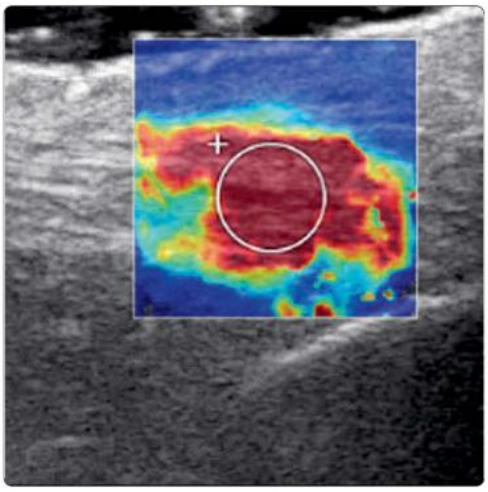

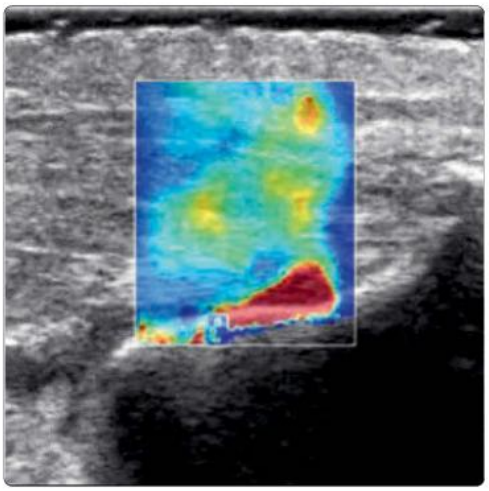

(Left) *Longitudinal elastography shows the normal stiff appearance of the Achilles tendon at its insertion, as indicated by the red color. The elasticity spectrum varies between red (hard tissue) and blue (soft tissue). The normal tendon is red in color.* **(Right)** *Longitudinal US elastography shows softening of the Achilles tendon at its insertion, as indicated by the blue coloring, compatible with severe tendinosis.*

KEY FACTS

TERMINOLOGY

- Tendon tear = discontinuity either within tendon substance or at attachment
  - Partial thickness, full thickness, or complete

IMAGING

- Tendon tears occur in tendon areas prone to tendinosis
  - Tendinosis is strong prerequisite to tendon tear
  - The more severe the tendinosis, the greater the likelihood of tendon tear
  - Tendon tears uncommon in normal tendons, except in severe trauma
- US allows recognition of tendon tears with high accuracy
  - For small tendons, examine first in transverse plane
    - Swollen tendon ends make tear more conspicuous
    - Look for abrupt loss of tendon on transverse scanning
  - For larger tendons, examine first in longitudinal plane
  - Passive tendon movement can help in identifying tear
- Gap within tendon is either filled with blood, serous fluid, or edematous fat ± gas
- Tendon swelling following acute tear limits assessment of preexisting tendinosis
- Collapsed tenosynovial sheath can mimic attenuated tendon
- US is accurate at detecting retear & defining cause of limited movement following repair
  - Limited movement may be due to adhesions
  - Tendon swelling can remain for years following repair

DIAGNOSTIC CHECKLIST

- Compare with contralateral side
- Follow tendon from musculotendinous junction to insertion
- Minimize anisotropy, which can mimic tendon tears
- Try to ascertain degree of preexisting tendinosis
- Measure retraction gap
- Mark torn tendon ends on skin

(Left) *Clinical photograph shows both heels hanging freely over the edge of a bed with the patient lying prone. There is loss of plantar flexion on the affected left side with swelling ⇨ of the Achilles region.* **(Right)** *Longitudinal US of the same patient shows a complete tear of the proximal 1/3 of the Achilles tendon ⇨. The proximal ⇨ and distal ⇨ stumps are retracted. The soleus muscle deep to the tear ⇨ is normal.*

(Left) *Longitudinal US of distal leg shows a complete tear in the proximal 1/3 of the Achilles tendon with hematoma ⇨ partially filling the retraction gap. Note the swollen proximal ⇨ and distal ⇨ tendon ends.* **(Right)** *Longitudinal US shows a complete Achilles tendon tear ⇨ just distal to the musculotendinous junction. This is the most common site of an Achilles tendon tear. The proximal ⇨ and distal ⇨ tendon ends are retracted. The plantaris tendon ⇨ is intact.*

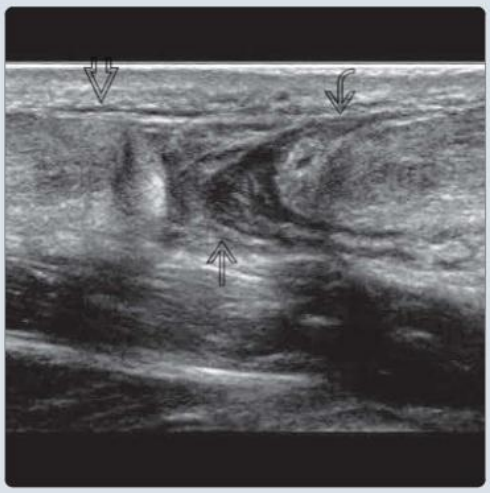

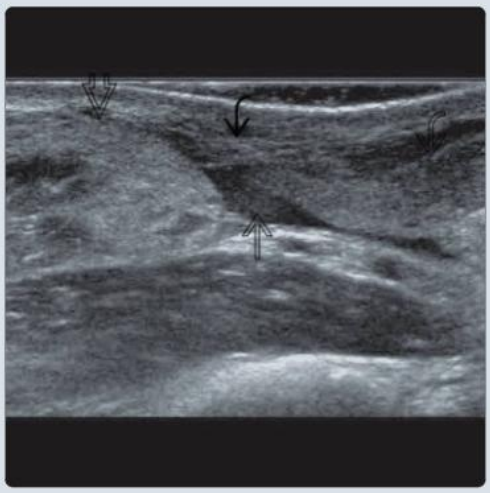

TERMINOLOGY

Synonyms

- Tendon rupture, tendon tear, tendon sprain, tendon strain
  - Tendon sprain & strain are more clinical rather than imaging terms used to describe partial-thickness tendon tear

Definitions

- Tendon tear = discontinuity within tendon substance or at attachment
  - Partial-thickness tear: Some tendon fibers are torn, but this tear does not involve full tendon thickness
  - Full-thickness tear: Some tendon fibers are torn with this tear involving full tendon thickness
  - Complete tear: All of tendon fibers are torn
  - High-grade partial tear: Partial tendon tear involving > 50% of tendon fibers

IMAGING

General Features

- Best diagnostic clue
  - Fluid-filled gap in tendon
  - Discontinuity of tendon fibers
- Location
  - In most patients, occurrence & location of tendon tears closely mirrors that of tendinosis
    - Tendinosis is strong prerequisite of tendon tear
    - Tendon areas prone to tendinosis are also those prone to tendon tears
      - Biceps tendon at proximal end ("genu") of bicipital groove
      - Common extensor tendon origin at lateral epicondyle
      - Extensor pollicis longus tendon at level of Lister tubercle
      - Extensor carpi ulnaris just distal to ulnar head
      - Hamstring tendons at ischial tuberosity
      - Adductor tendons at pelvic attachment
      - Gluteus medius/minimus tendons at greater trochanter
      - Quadriceps tendon at patellar insertion
      - Patellar tendon at patellar origin
      - Achilles tendon close to musculotendinous junction & at calcaneal insertion
      - Posterior tibialis tendon around medial malleolus or near insertion
      - Peroneal tendons around lateral malleolus, peroneal tubercle, or os peroneum (peroneus longus)
      - Tibialis anterior tendon close to insertion
- Morphology
  - Some tendons preferentially tear transversely
    - Adductor, quadriceps, patellar, Achilles, tibialis anterior, & wrist extensors & flexors
    - Generally, larger tendons tend to tear transversely
  - Some tendons preferentially tear longitudinally
    - Hamstrings, posterior tibialis, peroneal tendons, & biceps
    - Generally, smaller tendons tend to tear either longitudinally or transversely

Ultrasonographic Findings

- Fluid-filled gap within tendon
  - Acutely, tendon retraction gap may be filled with blood, serous fluid, fat ± gas locules, making tendon ends difficult to see
  - Irregular tendon ends
- Often swollen tendon ends
  - Swollen tendon ends increase visibility of small tendon tears
- Collapsed tendon sheath may mimic intact attenuated tendon
  - Seen with smaller tendons (i.e., finger flexors, extensor pollicis longus, biceps)
- Partial tear
  - Focal discontinuity of tendon, not involving all tendon fibers
  - Lack of tendon retraction
- Partial intrasubstance tear
  - Tear seen as linear, sharp, & hypoechoic area within tendon
  - Focal areas of proteoglycan accumulation in severe tendinosis can mimic partial tendon tear
    - Proteoglycan accumulation is more rounded, more irregular, & less hypoechoic
- Postrupture tendon swelling
  - Helps in identifying tendon tear, as it makes tendon ends more conspicuous
  - Can limit evaluation of presence & severity of preexisting tendinosis
    - Intratendinous calcification & hyperemia are good clues to preexisting tendinosis
    - Examining contralateral tendon helpful, as tendinosis is often bilateral
- Some tendon tears, especially those occurring spontaneously due to tendinosis, may present late
  - Partial gap in reparative hypoechoic granulation tissue may be seen in chronic tears
  - Mild hyperemia of granulation tissue
- Tendon subluxation may lead to restricted tendon movement without tear
- Limitation in tendon movement following repair may be due to tendon adhesion & not retear
  - US is accurate at detecting retear or identifying cause of limited tendon movement
    - Suture material seen traversing tendon gap with retear
- Tendon remains swollen & hyperemic long after tendon integrity & strength have returned
  - Rehabilitation schedule best guided by clinical assessment rather than serial US examination

MR Findings

- T1WI
  - Assess tendon enlargement + retraction
- T2WI
  - Disruption with discontinuity ± wavy retracted tendon
  - Enlarged tendon may be seen for many years post surgery

Imaging Recommendations

- Best imaging tool
  - US allows recognition of tendon tears with high accuracy & precision
- Protocol advice
  - Start by examining unaffected side to become familiar with normal appearance
  - For small tendons, examine first in transverse plane along length of tendon
    - Examine tendon slowly from distal → proximal, looking for any gap in tendon
    - Look for swollen tendon end & then sudden loss of tendon on continual transverse scanning
  - Continually realign transducer to avoid anisotropy
  - Passive movement of affected tendon can help identify tendon ends
  - If bicipital groove or extensor carpi ulnaris groove is empty, check that tendon has not subluxed
  - For Achilles tendon examination, examine patient prone with foot dorsiflexed
    - Measure distance of tear to musculotendinous junction & insertion at posterior superior calcaneal tuberosity
    - ± examine in full plantar flexion to determine tendon end apposition with plantar flexion, if conservative treatment being considered
  - Mark retracted tendon ends on skin to aid surgical repair

DIFFERENTIAL DIAGNOSIS

Scarred Tissue

- May limit normal tendon excursion during passive movement

Tendinosis With Peritendinitis

- Small intrasubstance tears are inherent part of severe tendinosis
  - Microtears may be too small to resolve

PATHOLOGY

General Features

- Etiology
  - Trauma
    - No underlying tendinosis
  - Middle-aged patients tear large or medium-sized tendons during modest to high exertion
    - Typically, torn tendon has minimal or mild tendinosis
  - Older adult patients tear medium-sized or small tendons spontaneously or with minimal exertion
    - Typically, torn tendon has moderate to severe tendinosis
  - Other common etiologic factors
    - Inflammatory arthropathy
      - Commonly affects extensor carpi ulnaris & extensor tendons of 4th & 5th fingers
      - Due to chronic friction from subluxed ulnar head ± chronic tenosynovitis
    - Malaligned fracture, particularly distal radial fracture ± fixation plate
      - Usually affects flexor carpi radialis, flexor pollicis longus, & long index finger flexor tendons
    - Chronic joint deformity &, possibly, repeated steroid injection

Gross Pathologic & Surgical Features

- Quadriceps tendon
  - Composed of 3 lamina: Superficial (from rectus femoris), intermediate (vastus lateralis & medialis), & deep (vastus intermedius)
  - Partial tears usually involve superficial ± intermediate lamina

Microscopic Features

- Degeneration with decreased collagen cross linking
  - Loss of viscoelasticity & increased stiffness

CLINICAL ISSUES

Presentation

- Most common signs/symptoms
  - Acute onset of pain ± swelling during exertion
  - Loss of tendon function
- Clinical profile
  - Trauma
  - Exertional activity in young/middle-aged patients
  - Nonexertional activity in older adult patients
  - Squeezing calf muscles produces plantar flexion if Achilles tendon intact (Thompson test)

Demographics

- Age
  - Uncommon before 30 years
- Sex
  - M:F = 5:1

Natural History & Prognosis

- Achilles tendon
  - Nonsurgical rerupture rate: 20%
  - Surgical rerupture rate: 2%

Treatment

- Complete Achilles tendon tear
  - Cast immobilization
    - Used in acute tears when US shows good approximation of tendon ends with plantar flexion
  - Surgical repair is usually required
    - Usually end-to-end anastomosis
- Other tendons: Surgical repair

DIAGNOSTIC CHECKLIST

Image Interpretation Pearls

- Examine contralateral side for comparison
- Minimize anisotropic effect
- Utilize passive or active tendon movement during US examination
- Check for degree of preexisting tendinosis
- Measure retraction gap
- Mark torn ends of tendon on skin

SELECTED REFERENCES

1. Fenech M et al: Ultrasound assessment of acute Achilles tendon rupture and measurement of the tendon gap. Australas J Ultrasound Med. 27(2):106-19, 2024

(Left) *Longitudinal US of an acute full-thickness Achilles tendon tear shows a gap filled with echogenic edematous fat ⇨. The swollen proximal ⇨ and distal ⇨ ends of the tendon are shown. The retraction gap can be filled with hematoma, gas, fat, or reparative tissue.* **(Right)** *Clinical photograph shows proximal and distal ends of the tendon tear marked on the skin. The shallow, rounded skin depressions ⇨ are made with an upturned marker pen cap before the gel is removed. Tendon ends are then marked with a felt pen.*

(Left) *Longitudinal US shows tendinosis and fusiform thickening of the midsegment of the Achilles tendon ⇨. A small longitudinal intrasubstance partial tear is present within the central portion of the tendon ⇨.* **(Right)** *Transverse US at the same location shows the intrasubstance tear ⇨ of the Achilles tendon. Complete tears of the Achilles tendon are much more common than partial tears.*

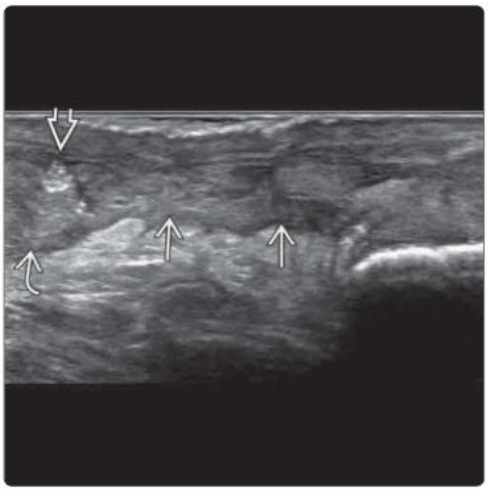

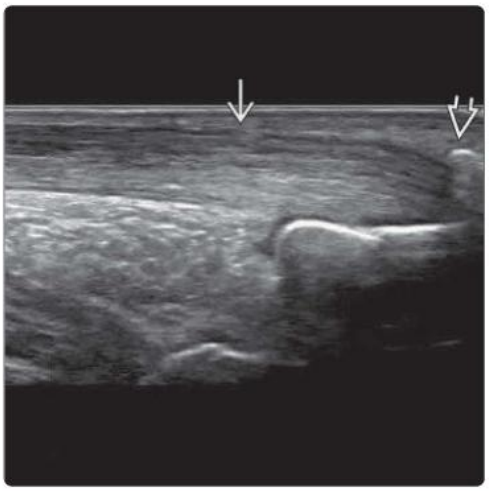

(Left) *Longitudinal US shows an acute complete tear of the distal end of Achilles tendon. The gap is filled with echogenic hematoma ⇨. The proximal end ⇨ is swollen with small flecks of calcification ⇨, suggestive of preexisting chronic tendinosis.* **(Right)** *Longitudinal US of contralateral Achilles tendon for comparison is shown. There is mild tendon swelling ⇨ with a large dorsal calcaneal osteophytic spur ⇨, indicative of mild insertional tendinosis.*

(Left) *Longitudinal US of Achilles tendon shows a complete avulsive tear from the calcaneal insertion. The fracture fragment is retracted proximally at the distal end of the retracted tendon. The retraction gap is filled with hemorrhage.* **(Right)** *Transverse US of the same area shows the avulsion fracture fragments within the distal end of the Achilles tendon, which is severely swollen due to acute tear.*

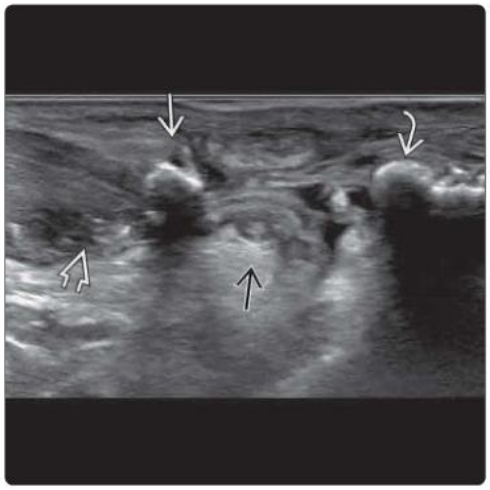

(Left) *Longitudinal US of medial calf shows a large myofascial and myotendinous junction tear of the medial gastrocnemius muscle belly. The gap is filled with hypoechoic hematoma tracking along the myofascial plane at the mid- to lower calf region.* **(Right)** *Transverse US of the same area shows a myofascial tear filled up with hematoma located between the medial head of the gastrocnemius muscle and the soleus muscle.*

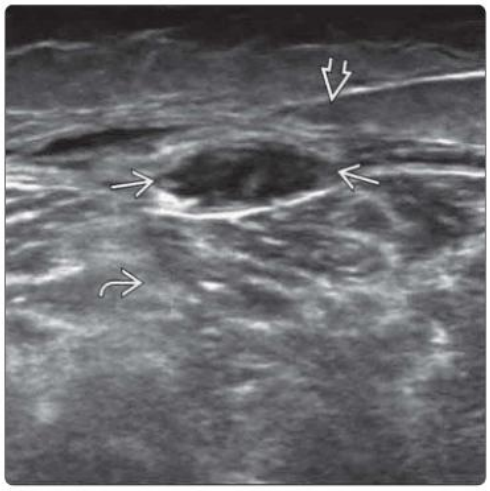

(Left) *Longitudinal US shows an acute tear of the adductor longus tendon close to the inferior pubic ramus attachment. The tendon fibers are retracted distally. The gap is partially filled with hematoma.* **(Right)** *Longitudinal US of the same patient close to the pubic tubercle shows a torn tendon with cortical irregularity of the insertional area. Tendon fibers are displaced distally.*

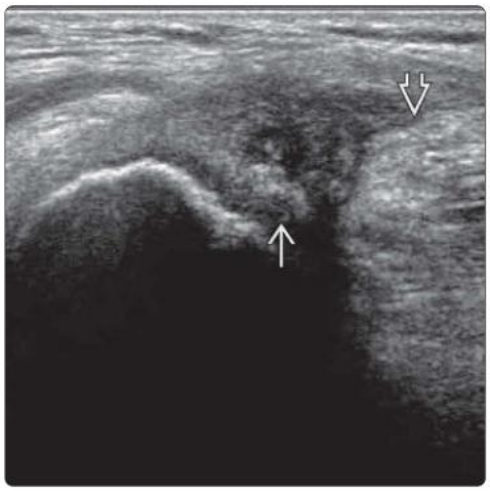

(Left) *Longitudinal extended field-of-view US shows a myotendinous junction plantaris tendon tear ➡ at the proximal calf. The gap is filled with hematoma. The mid and distal parts of the plantaris tendon ➡ are intact. This is an unusual location for plantaris tear, as most occur distally.* **(Right)** *Transverse US of the same area shows hematoma located between the gastrocnemius ➡ and soleus ➡ muscles. This ruptured plantaris tendon could be misdiagnosed as a myofascial gastrocnemius tear.*

(Left) *Clinical photograph shows a mass ➡ on the posteromedial aspect of the distal thigh. The mass had been present for several years. It moves more distally and becomes more apparent with muscle contraction and almost disappeared with muscle relaxation.* **(Right)** *Longitudinal US of the same area shows an incomplete rupture of the semimembranosus tendon from its proximal insertion and retraction to the midthigh region. There is a fibrotic mass ➡ at the site of the retracted torn tendon.*

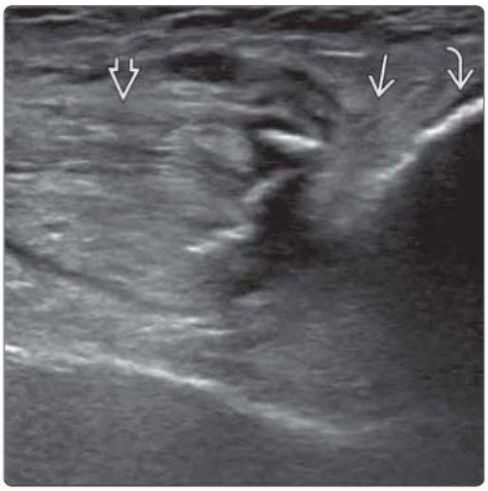

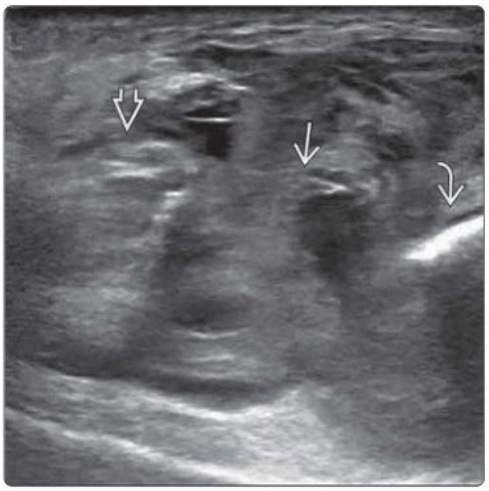

(Left) *Longitudinal US of distal thigh shows a complete quadriceps tendon tear from superior pole of patella ➡. The proximal tendon end ➡ has retracted with an avulsed bone fragment at its distal end. The tendon gap is filled up with hemorrhagic fluid ➡.* **(Right)** *Longitudinal US of the same patient also shows a complete contralateral quadriceps tendon tear from superior pole of patella ➡. The proximal tendon end ➡ is swollen. The gap is filled with hemorrhage ➡, compatible with bilateral quadriceps tendon tear.*

(Left) *Graphic shows a patellar tendon tear just distal to the patella, which is also stabilized by the medial and lateral patellofemoral ligaments. The less functionally relevant lateral and medial patellotibial ligaments, as well as the patellomeniscal ligament, are also shown.* **(Right)** *Longitudinal extended field-of-view US of the knee shows a complete tear (avulsion) of the patellar tendon from the inferior pole of the patella. The tendon gap is filled with blood, serous fluid, and fat.*

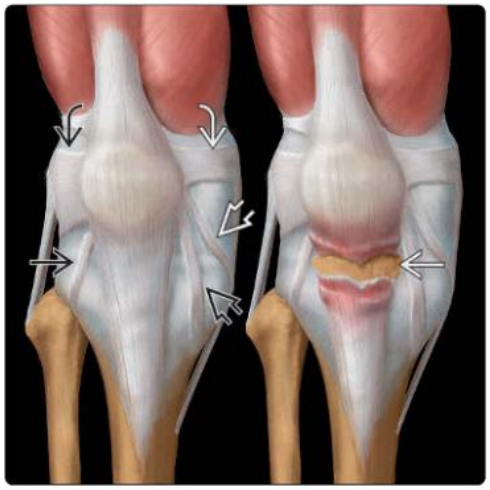

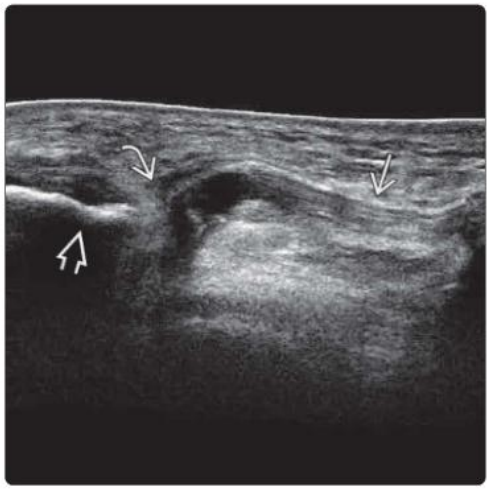

(Left) *Lateral radiograph in a patient with acute knee trauma shows a high-riding patella ("patella alta") with a small osseous fragment, which seems to be attached to the patellar tendon, suggestive of a complete patellar tendon tear.* **(Right)** *Longitudinal US in the same patient shows a complete avulsion of the patellar tendon from the patellar bone. The small osseous fragment attached to the avulsed patellar tendon end is seen. The tendon retraction gap is filled with blood, serous fluid, and fat.*

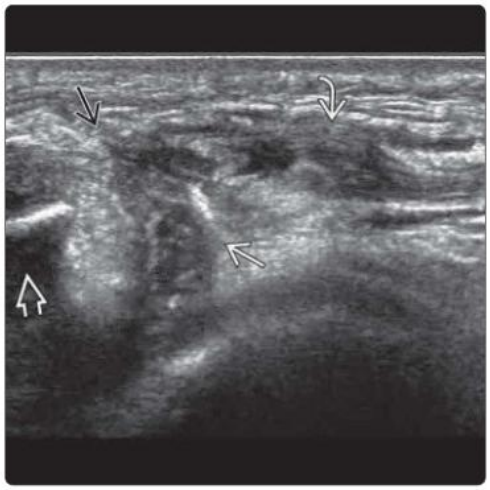

(Left) *Longitudinal US shows a chronic, deep-seated, intrasubstance semimembranosus tendon tear. The superficial fibers are intact. The tear is sharp, irregular, and hypoechoic and likely to be filled with organizing hematoma and fibrotic tissue. Note the medial femoral condyle.* **(Right)** *Longitudinal US of the contralateral semimembranosus tendon in the same patient shows a normal tendon fibrillar pattern coursing over the medial femoral condyle.*

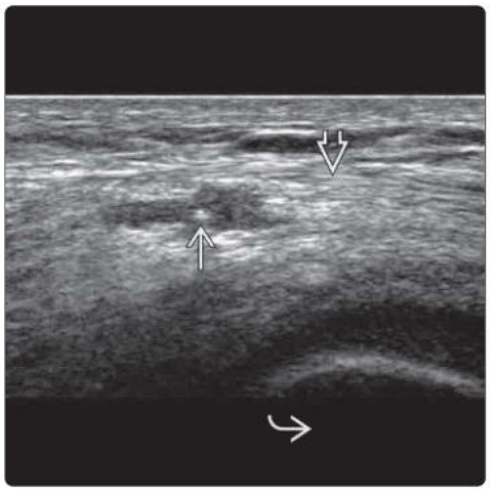

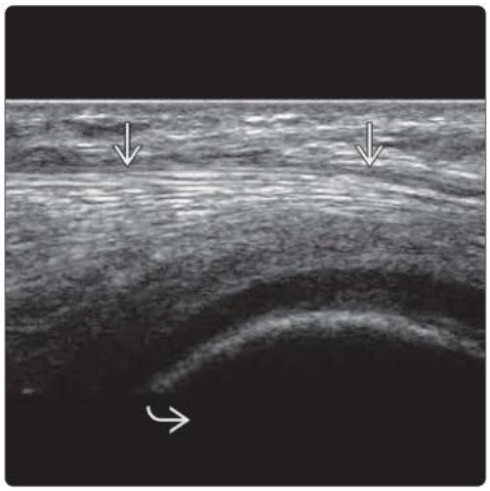

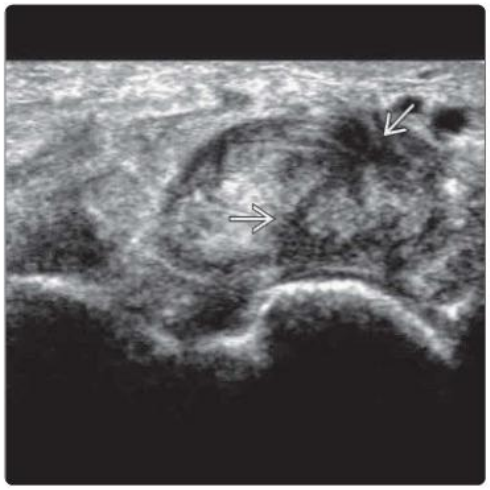

(Left) *Clinical photograph shows quite severe pes planus with loss of the medial longitudinal arch with heel valgus deformity.* **(Right)** *Transverse US of the medial retromalleolar region shows severe posterior tibialis tendinosis with several irregular, linear, hypoechoic areas within the tendon substance, consistent with multiple longitudinal split tears. Longitudinal split tears, which typically extend over 2-3 cm, are quite common in moderate to severe tendinosis of the tendons around the ankle.*

(Left) *Transverse US of the inframalleolar region shows several small, linear, hypoechoic split tears in the posterior tibialis tendon. Moderate background tendinosis is present. Note the thickened flexor retinaculum. The normal deltoid ligament is present deep to the tendon.* **(Right)** *Transverse US of medial inframalleolar region shows several hypoechoic split tears in the posterior tibialis and flexor digitorum tendons. There are several calcified foci due to tendinosis with a small tendon sheath effusion.*

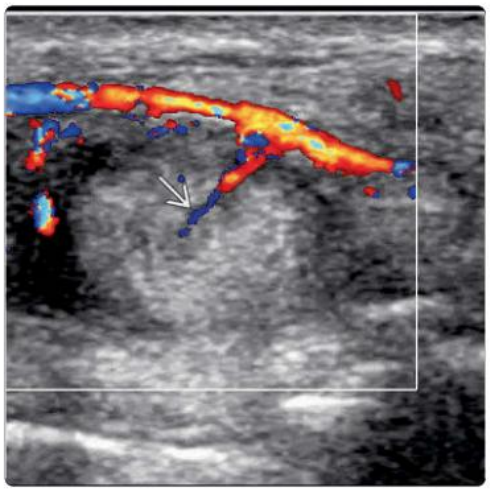

(Left) *Transverse US of the posterior tibialis tendon shows a linear, discrete, hypoechoic line extending from the surface to the center of the tendon, suspicious for a partial-thickness tear.* **(Right)** *Transverse color Doppler US of the corresponding region shows the linear, discrete, hypoechoic line, representing a vascular channel. This may be due to vascularized granulation tissue with a healing tear. Always check any suspected partial tears with color Doppler US.*

(Left) *Transverse US of the lateral inframalleolar region shows a normal peroneus longus and a moderately attenuated peroneus brevis tendon.* **(Right)** *Transverse US just proximal to the previous image shows absence of the peroneus brevis tendon due to a complete tear. The peroneus longus tendon is unchanged. Tears in the small tendons around the ankle and wrist are best appreciated first on transverse scanning along the tendon length.*

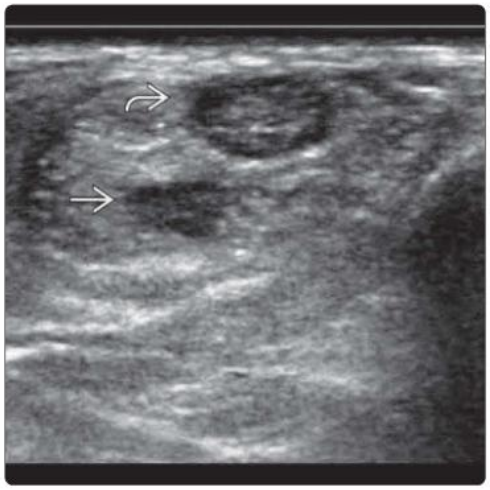

(Left) *Longitudinal US in the lateral retromalleolar area of the same complete tear of the peroneus brevis tendon shows proximal retraction of the swollen tendon end to the supramalleolar region. The peroneus longus tendon is intact.* **(Right)** *Transverse US of the lateral inframalleolar region at region of peroneal tubercle shows several full-thickness longitudinal (split) tears within the peroneus longus tendon. There is mild peroneus brevis tendinosis with a small tendon sheath effusion, though no tendon tear.*

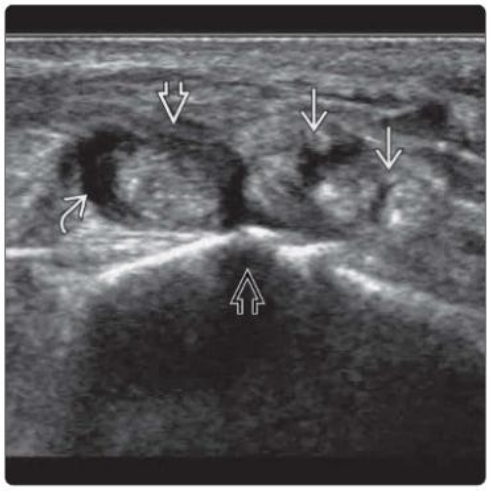

(Left) *Clinical photograph of a patient with foot trauma and impaired big toe dorsiflexion shows the location of the distal and proximal stumps of the torn extensor hallucis longus drawn on the skin. Skin marking following US examination is helpful for surgical exploration and repair.* **(Right)** *Longitudinal US in the same patient shows a complete tear of the extensor hallucis longus with proximal retraction to the level of the navicular bone. There is hematoma filling the tendon gap overlying the 1st metatarsal shaft.*

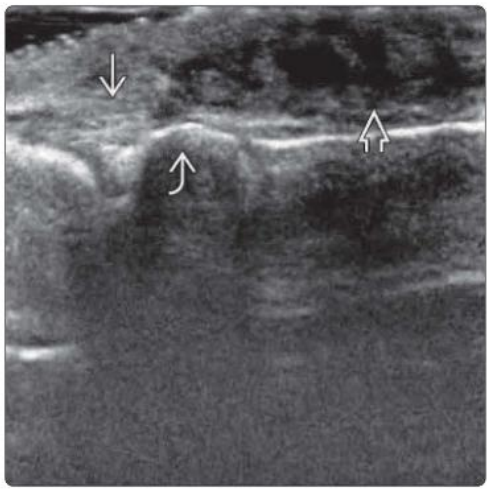

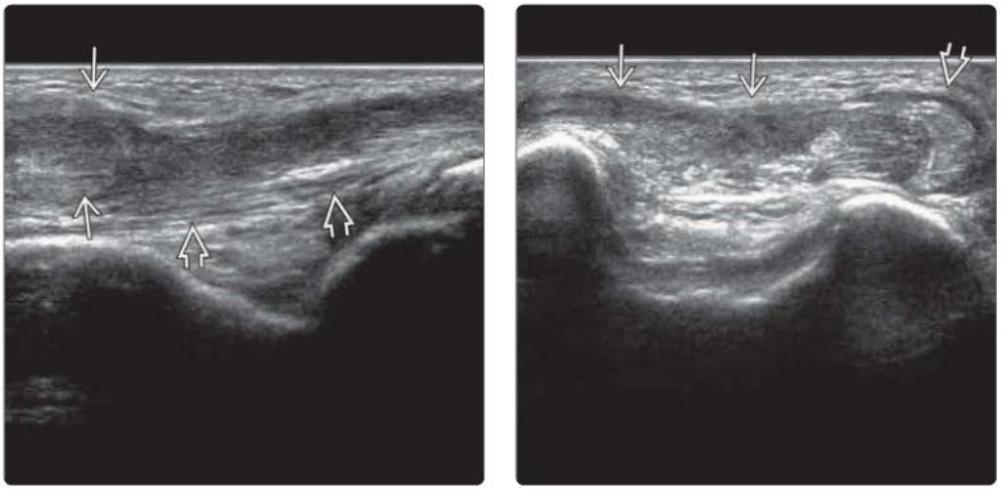

(Left) *Longitudinal US of triceps tendon shows a high-grade partial tear at the distal myotendinous junction ➡. The deep fibers ⇨ are still in continuity. The proximal end of the torn tendon has retracted proximally forming a "pseudomass," corresponding to a clinically palpable mass.* **(Right)** *Transverse US of the same area shows a tendon tear of the more superficially located lateral and long head fibers ➡. The fibers of the medial head ⇨ of the triceps are relatively spared.*

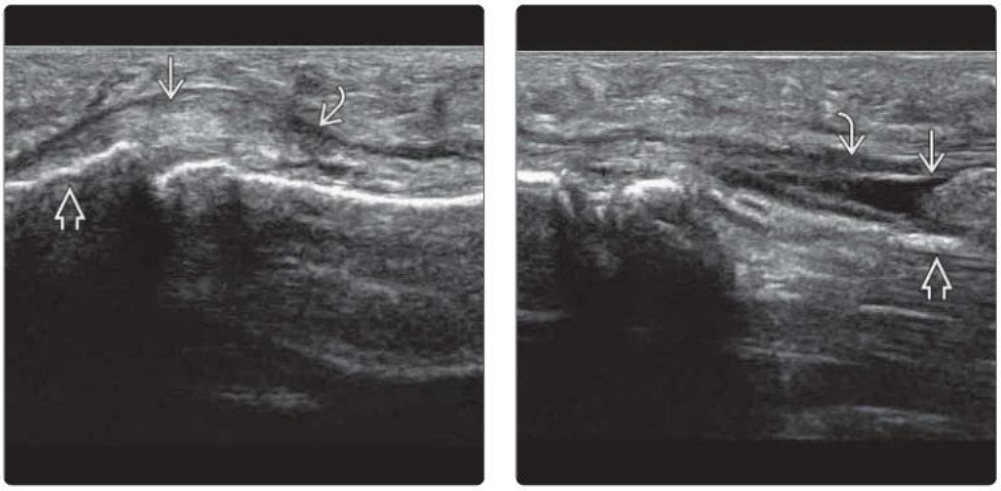

(Left) *Longitudinal US shows a complete tear ⇨ of the flexor pollicis longus tendon following direct trauma to the thumb. A swollen distal tendon stump ⇨ is inserted into the base of the distal phalanx ⇨.* **(Right)** *The end of the proximal stump ⇨ of the same tendon is retracted to the proximal 1/3 of the middle phalanx ⇨. The partially collapsed tendon sheath ⇨ should not be misdiagnosed as intact tendon fibers.*

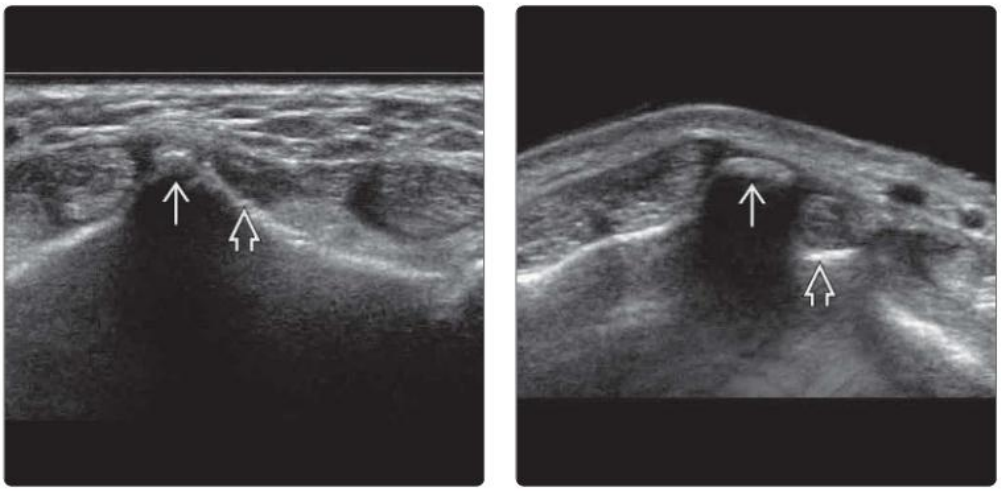

(Left) *Transverse US in a patient with limited thumb movement shows absence of the extensor pollicis longus (EPL) tendon at the distal radius level ⇨. The tendon is normally located just ulnar to Lister tubercle ⇨.* **(Right)** *Transverse US of the contralateral wrist shows a normal EPL tendon ⇨ readily identified adjacent to the Lister tubercle ⇨. This is the most common site of EPL tendon rupture. Lister tubercle acts as a fulcrum for EPL tendon action.*

(Left) *Clinical photograph shows the sites of the retracted proximal ⇨ and distal ⇨ ends of the torn EPL tendon marked on the patient's skin.* **(Right)** *Transverse PD MR shows a wrist with a complete tear of the EPL tendon. EPL tendon tears typically occur alongside the Lister tubercle, deep to the extensor retinaculum. The small, hypointense dot ⇨ represents the collapsed EPL tendon sheath. The torn, swollen EPL tendon ends (not shown) were more visible proximally and distally.*

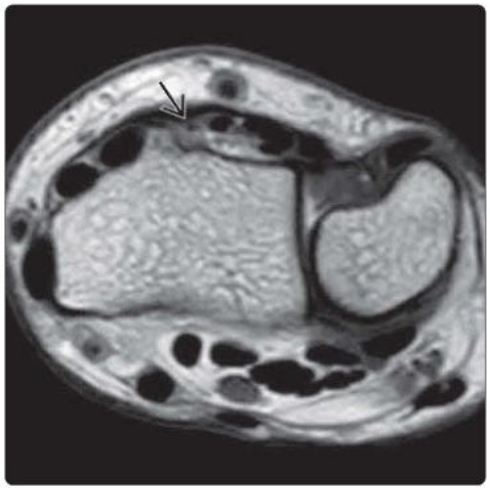

(Left) *Clinical photograph of a patient presenting with pain and swelling ⇨ over the radial side of both hands is shown.* **(Right)** *Longitudinal US of the left extensor pollicis brevis in the same patient shows a small intrasubstance focal split tear with intratendinous cyst formation ⇨.*

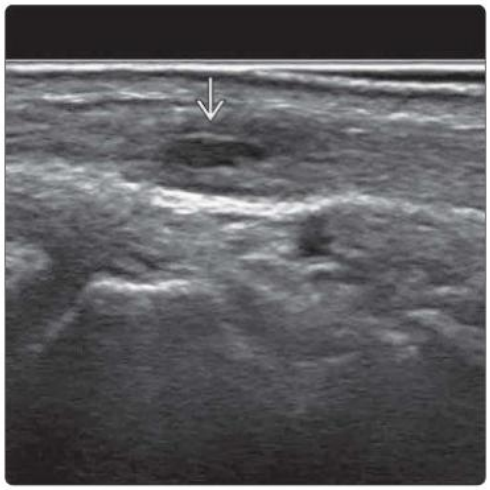

(Left) *Longitudinal US of the contralateral extensor pollicis brevis tendon in the same patient shows a larger intrasubstance focal split tear with intratendinous cyst formation ⇨.* **(Right)** *Transverse US of the same patient shows a bilobed intratendinous cyst secondary to focal intrasubstance split tear ⇨. The normal intact tendon fibers ⇨ are displaced peripherally.*

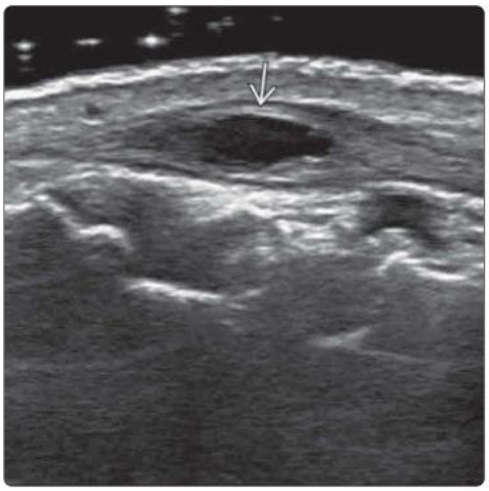

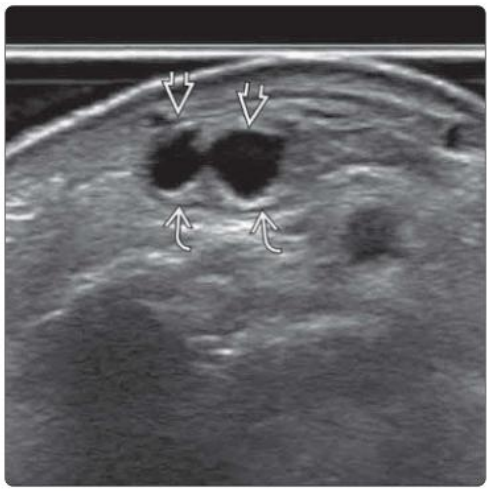

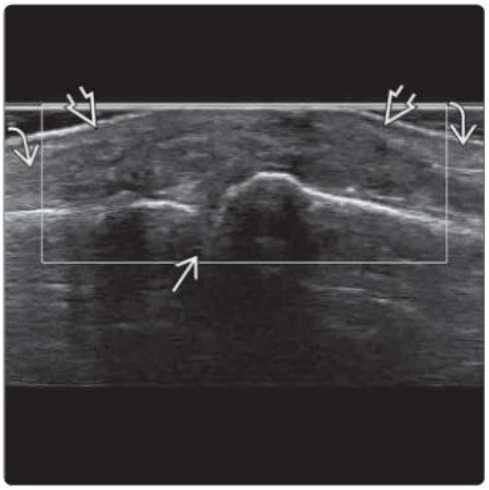

(Left) *Clinical photograph shows the thumb of a 64-year-old man 4 months following repair ➡ of completely torn EPL and brevis tendons to the thumb. There was restricted thumb movement with pain on the dorsoradial aspect of the wrist.* **(Right)** *Longitudinal US at the metacarpophalangeal joint ➡ level in the same patient shows a fibrotic-type mass ➡ surrounding the indistinct extensor tendon hood ➡ of the thumb. No hyperemia is present. Limited movement of the extensor tendons is present on passive flexion/extension.*

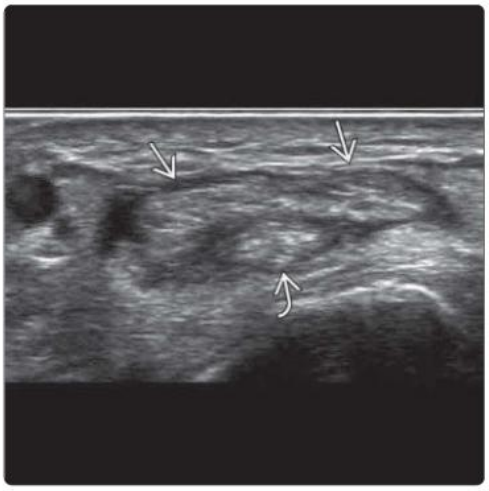

(Left) *Transverse US at the same level as previous image shows the disrupted, irregular extensor tendon ➡ on the dorsum of the metacarpal shaft ➡. There is moderate surrounding fibrotic-type tissue ➡ in the region of the sagittal bands. These are fairly typical appearances following extensor tendon repair.* **(Right)** *Transverse US more proximally on the dorsoradial aspect of wrist shows that the EPL tendon ➡ is located deep to, rather than superficial to, the 2nd extensor compartment tendons ➡, consequent on previous tear or repair.*

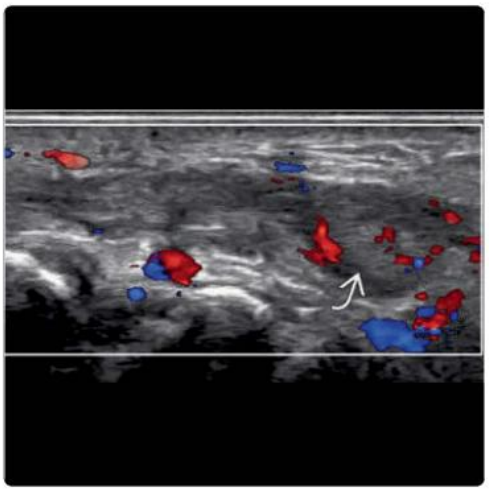

(Left) *Transverse US of the same patient shows mild tendinosis of the malpositioned EPL tendon ➡ on the radial side of the 2nd extensor compartment tendons ➡.* **(Right)** *Transverse US at this location shows moderate hyperemia around the malpositioned EPL ➡ just radial to the 2nd extensor compartment tendons. This localized tendinosis of the EPL was most likely due to malpositioning and was also the most likely the cause of postoperative dorsoradial wrist pain.*

KEY FACTS

IMAGING

- Only affects tendons encased by synovium
- Distention of tenosynovium (tendon sheath) due to fluid or synovitis with variable tendon swelling
- **Acute exudative tenosynovitis**
  - Usually due to acute infection or gout
  - Fluid accumulation within sheath with little or no synovial proliferation
  - Fluid may have speckled, echogenic appearance due to aggregates of debris, pus, or crystals
- **Acute nonexudative tenosynovitis**
  - Usually due to infection, inflammatory disease, or gout
  - Synovial proliferation within sheath predominates over fluid accumulation
- **Chronic active tenosynovitis**
  - Synovial proliferation with hyperemia within tendon sheath
- **Chronic inactive tenosynovitis**
  - Clear fluid accumulation ± mildly thickened sheath
  - Hyperemia mostly around, rather than within, tendon sheath
- **Stenosing tenosynovitis**
  - Hypertrophy of retinaculum or pulley component of tendon osseofibrous tunnel
  - Restricts tendon movement (trigger finger & de Quervain disease)

DIAGNOSTIC CHECKLIST

- Tenosynovitis: Disease of tendon sheath with minimal tendon involvement
- Tendinosis: Disease of tendon with variable degree of peritendinitis
- Use color Doppler to distinguish tenosynovial inflammation from tenosynovial effusion
- Use minimal transducer pressure to avoid effacing tendon sheath effusion or vascularity

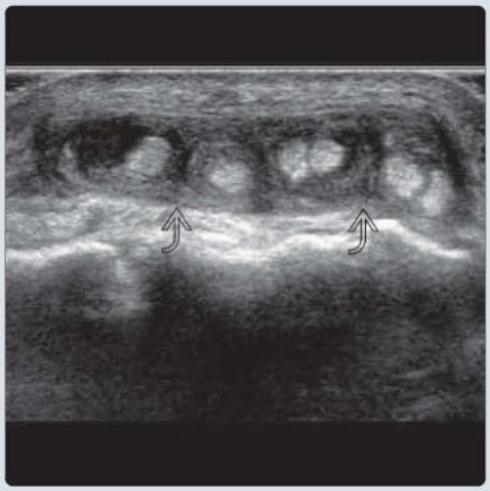

(Left) *Clinical photograph shows severe swelling of the dorsum of wrist in a patient with a 2-week history of increasing wrist pain.* **(Right)** *Transverse US at the metacarpal level shows a severely thickened tendon sheath around the extensor digitorum communis tendon. Synovial proliferation is present. The extensor digitorum tendons are only mildly swollen.*

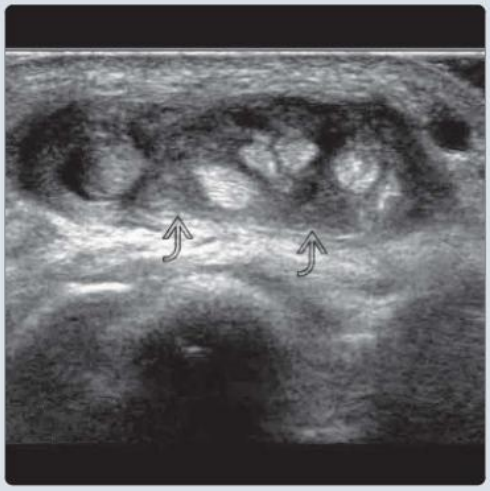

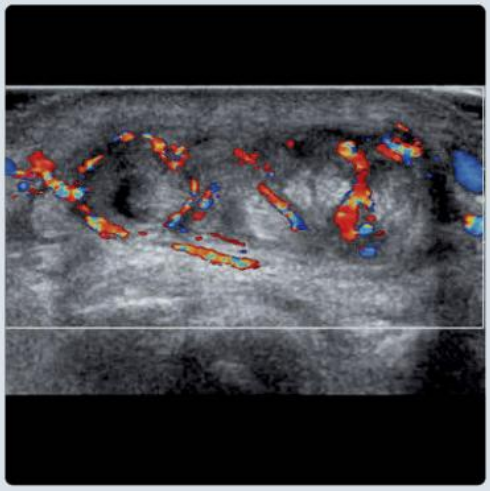

(Left) *Transverse US of the same patient at the level of the proximal carpal row shows even more severe distention of the extensor digitorum communis tendon sheath with thickened proliferative synovium.* **(Right)** *Transverse color Doppler US of the extensor digitorum communis tendon sheath of the same patient shows severe hyperemia of the thickened synovium, consistent with chronic active tenosynovitis.*

TERMINOLOGY

Synonyms

- Tendinitis or tendonitis are arbitrary terms best avoided

IMAGING

General Features

- Best diagnostic clue
  - Inflammation of tendon sheath (tenosynovium)
  - Thickening of tendon sheath (tenosynovial proliferation)
  - Exudate or fluid within tendon sheath forms halo around tendon
- Location
  - Only affects tendons encased by synovial sheath
  - Wrist extensors > wrist flexors > finger flexors > ankle tendons
    - Tenosynovitis cannot occur if no tendon sheath present, e.g.,
      - Flexor carpi ulnaris tendon has no tendon sheath
      - Extensor digitorum tendons have no tendon sheath on dorsum of fingers
- Morphology
  - Distention of tendon sheath with mild tendon swelling
  - Variable tendon sheath distention & content, depending on cause, severity, duration

Radiographic Findings

- Radiography
  - Signs of underlying cause
    - Calcific aggregates in gouty tophi or calcium pyrophosphate dihydrate deposition
    - Erosive or septic arthropathy
    - Radiopaque foreign body

MR Findings

- T2WI
  - Fluid signal within distended synovial sheath
  - Villonodular synovial proliferation
- T1WI C+ FS
  - Contrast enhancement helps differentiate tenosynovial proliferation from tendon sheath fluid

Ultrasonographic Findings

- Depends on chronicity of tenosynovitis
- **Acute exudative tenosynovitis**
  - Usually due to infection or gout
    - Fluid accumulation within tendon sheath with little or no synovial proliferation
      - Forms hypoechoic halo around tendon
    - Fluid may have speckled echogenic appearance due to aggregates of debris or pus
      - Echogenic comet-tail artifacts due to gouty crystal aggregates tend to be larger than those due to inflammatory aggregates in infected tenosynovial fluid
    - Hyperemia around, but not within, tendon sheath
    - Infection may spread from tendon sheath into peritendinous tissues
    - ± foreign body within tendon sheath
- **Acute proliferative tenosynovitis**
  - Due to rheumatologic disease, gout, or infection
    - Distention of tendon sheath with minimal or no tendon swelling
    - Synovial proliferation within sheath predominates over fluid accumulation
    - Hyperemia predominantly around, rather than within, tendon sheath
- **Chronic active tenosynovitis**
  - Due to rheumatologic disease, gout, or infection
  - Markedly thickened tendon sheath due to synovial proliferation rather than fluid
    - Synovial proliferation particularly prevalent in tuberculous tenosynovitis
    - Probe pressure can differentiate fluid from tenosynovial thickening
      - Fluid can be effaced, but tenosynovial thickening is not fully compressible
      - Intrasheath hyperemia confirms tenosynovial proliferation rather than fluid
  - Established hyperemia both within & around tendon sheath
  - ± tendon rupture
    - Chronic inflammation weakens tendon
- **Chronic inactive tenosynovitis**
  - Either synovial proliferation or clear fluid accumulation within mildly thickened sheath
    - Adhesions can lead to entrapped tenosynovial fluid with marked distention
    - Multiple "rice bodies" (small, fibrinous nodules) may uncommonly develop in chronic inflammation (e.g., tuberculosis or rheumatoid arthritis)
  - No significant hyperemia either around or within tendon sheath
- **Stenosing tenosynovitis**
  - Describes tendon disorders associated with hypertrophy of fibrous component of tendinous osseofibrous tunnel
  - Tenosynovitis terminology is contentious, as this entity is more related to tendinosis rather than tenosynovitis
  - Hypertrophy of flexor pulley (trigger finger) or 1st extensor retinaculum (de Quervain disease)
    - For trigger finger, A1 pulley is thickened more frequently than A2 pulley; any finger may be affected
  - Thickening (> 0.5 mm) of pulley or retinaculum
    - Normal thickness of pulley or retinaculum ≤ 0.5 mm
  - ± hyperemia of retinaculum or thickened tendon
  - Occasional tendon sheath effusion
  - Restriction of tendon movement on dynamic imaging

Imaging Recommendations

- Best imaging tool
  - US: Accurate at revealing presence & extent of tenosynovitis
    - Facilitates fine-needle aspiration (for culture, crystals) or biopsy to determine cause
    - US-guided steroid injection treatment
- Protocol advice
  - Examine full length of tendon or group of tendons in transverse plane
  - Use minimal transducer pressure to avoid effacing tendon sheath effusion or vascularity
  - Always include evaluation with color Doppler

  - Determines activity; distinguish synovial proliferation from fluid & confirm disease chronicity
  - Examine nearby joints for synovitis or effusion
  - Look for fluid leakage outside tendon sheath
  - In stenosing tenosynovitis, measure thickness of retinaculum or pulley
    - Measure retinacular or pulley thickness at 10- or 2-o'clock positions
    - Perform dynamic assessment to see if tendon movement restricted beneath pulley or retinaculum

DIFFERENTIAL DIAGNOSIS

Tendinosis

- Disease of tendon with variable degree of peritendinitis
- Tendon swelling, disruption of fibrillar echotexture, & intratendinous hyperemia predominate
  - Tendon sheath swelling is less than in tenosynovitis
- Intratendinous neovascularization is not usual feature of tenosynovitis
- Distinction between tenosynovitis & tendinosis not always clear-cut; mixed patterns may exist

Paratendinous Ganglion

- Fluid located eccentrically to tendon

Severe Edema or Cellulitis

- Mild secondary tendon sheath swelling can occur with severe cellulitis or edema in absence of actual tenosynovitis

PATHOLOGY

General Features

- Etiology
  - Overuse, infection (acute or chronic), inflammatory arthropathy, crystal deposition
  - Often no specific cause is found
- Relevant anatomy: Wrist flexor tendons
  - Flexor tendon sheaths of thumb & little finger communicate via radial & ulnar bursae on volar aspect of wrist
  - In 50% of cases, radial & ulnar bursae communicate via intermediate bursa
- Relevant anatomy: Wrist extensor compartments
  - 6 discrete extensor tendon sheaths that do not communicate
  - Extensor tendon expansions on dorsum of fingers do not have tendon sheaths
  - Septum separates 1st extensor compartment tendons in 25% of cases

Gross Pathologic & Surgical Features

- Inflammation of tendon sheath
- Thickening of tendon retinaculum or pulley

Microscopic Features

- Inflammatory cells infiltrate tenosynovium

CLINICAL ISSUES

Presentation

- Most common signs/symptoms
  - Pain, swelling, & tenderness of affected tendons
  - Limitation of movement
- Other signs/symptoms
  - Crepitus, tendon triggering
  - Surrounding cellulitis

Demographics

- Age
  - Most common in middle-aged to older adults
- Sex
  - Inflammatory tenosynovitis, de Quervain tenosynovitis, & repetitive strain injury have female predominance
- Epidemiology
  - Rheumatologic disease, e.g., rheumatoid arthritis, systemic lupus erythematosus
  - Metabolic disease, e.g., gout, pseudogout
  - Repetitive strain injury
  - Infective tenosynovitis more common in immunosuppressed patients & patients prone to penetrating injury
  - Stenosing tenosynovitis of 1st extensor compartment is common post partum ("baby wrist"), & trigger finger more common in diabetes patients

Natural History & Prognosis

- Majority (80%) improve with conservative treatment
  - If infective, may need surgical drainage

Treatment

- Noninfective tenosynovitis & chronic infective tenosynovitis
  - Rest, splinting, physiotherapy
    - Antiinflammatory medication ± US-guided steroid injection
    - ± appropriate antibiotics, if infective
    - Synovectomy for failed conservative treatment
- Acute exudative tenosynovitis
  - Surgical drainage, elevation, antibiotics
- Stenosing tenosynovitis
  - US-guided steroid injection between tendon sheath & pulley or retinaculum
  - US-guided release

DIAGNOSTIC CHECKLIST

Consider

- Tendinosis rather than tenosynovitis if tendon is predominantly swollen with intratendinous hyperemia
- Tenosynovitis cannot occur if no tendon sheath

Image Interpretation Pearls

- Use color Doppler to distinguish synovial inflammation from synovial effusion
- Excessive transducer pressure may displace small amount of tendon sheath fluid
- Compare with contralateral side

SELECTED REFERENCES

1. Flores DV et al: Diagnostic and interventional US of the wrist and hand: quadrant-based approach. Radiographics. 43(8):e230046, 2023
2. Sahbudin I et al: The value of ultrasound-defined tenosynovitis and synovitis in the prediction of persistent arthritis. Rheumatology (Oxford). 62(3):1057-68, 2023
3. Gitto S et al: Sonography of non-neoplastic disorders of the hand and wrist tendons. J Ultrasound Med. 37(1):51-68, 2018

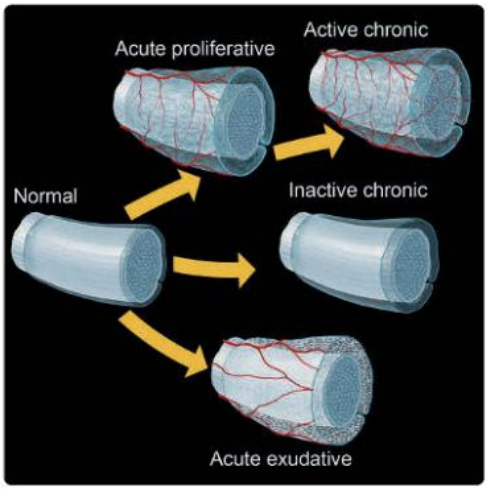

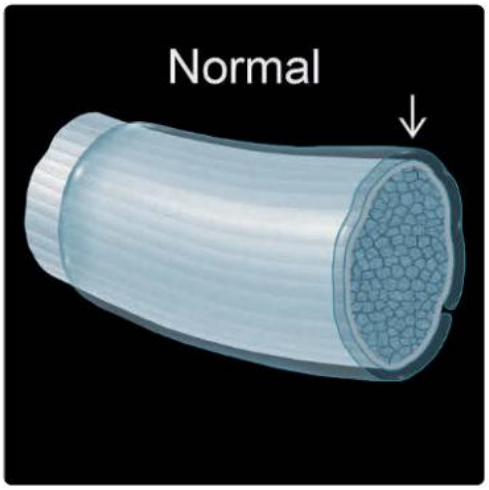

(Left) *Graphic shows different types of tenosynovitis. Tenosynovitis is a disease of the tendon sheath. Unlike tendinosis, which can affect any tendon, tenosynovitis can only affect those tendons with a tendon sheath.* **(Right)** *Graphic shows normal tendon sheath ➡ for comparative purposes. Most, but not all, of the tendons of the wrist/hand & ankle/foot have a tendon sheath. The long head of biceps has a tendon sheath. The patellar & Achilles tendons have a paratenon.*

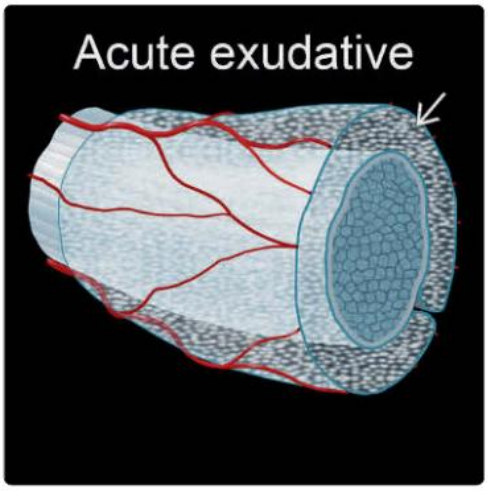

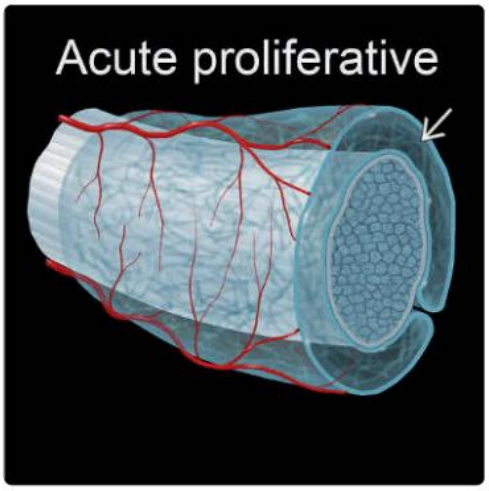

(Left) *Graphic shows acute exudative tenosynovitis ➡, usually secondary to bacterial infection/penetrating trauma & rapidly progressive. Purulent exudate can be aspirated. Hyperemia occurs around, rather than within, the tendon sheath.* **(Right)** *Graphic shows acute proliferative tenosynovitis. This is a proliferative process & usually due to repetitive trauma or a systemic inflammatory disorder. Tendon swelling occurs due to synovial proliferation ➡ with a mild exudate. Hyperemia is limited to the sheath surface.*

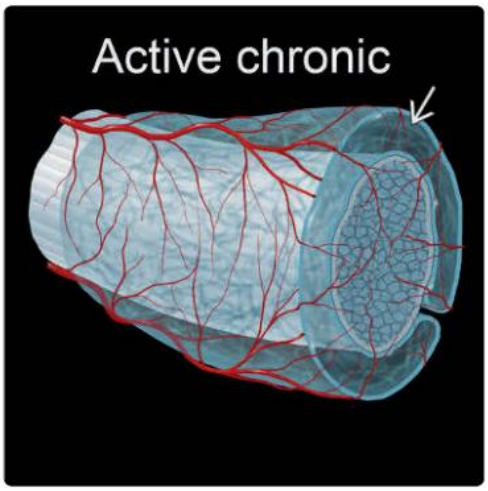

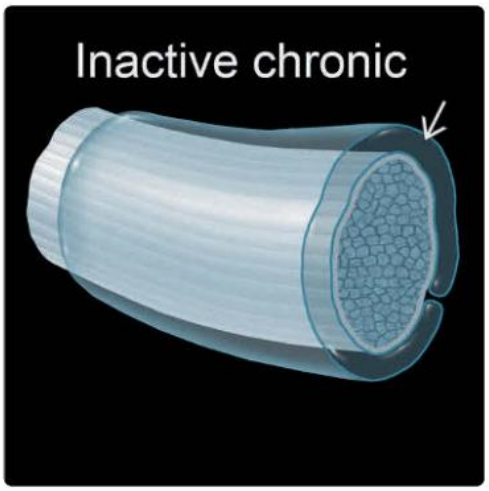

(Left) *Graphic shows active chronic tenosynovitis. Mature hyperemic synovial proliferation ➡ fills the distended tendon sheath. Hyperemia may extend into the tendon, which may be slightly enlarged due to edema. Otherwise, the tendon is normal in appearance.* **(Right)** *Graphic shows inactive chronic tenosynovitis. The tendon sheath is distended with serous fluid ➡. This distention may be severe & localized due to tendon sheath adhesions. Little or no hyperemia is present.*

(Left) *Transverse US of the dorsal wrist in a patient with a 2-month history of wrist swelling shows moderately severe synovial thickening* ➡ *with no visible tendon sheath effusion, suggestive of chronic tenosynovitis. Note mild swelling of the extensor digitorum tendons.* **(Right)** *Longitudinal color Doppler US of the ring finger extensor tendon shows synovial thickening extending along the dorsum of the hand with severe hyperemia, consistent with chronic active tenosynovitis.*

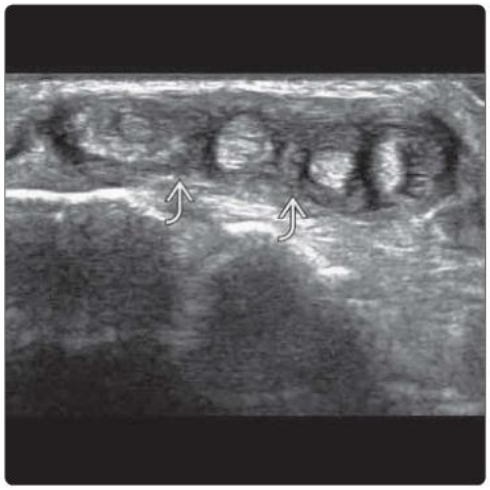

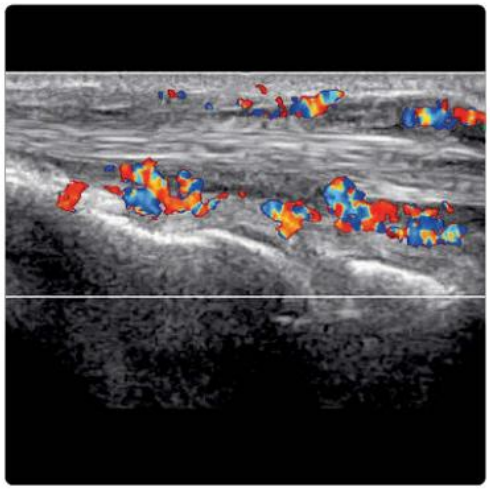

(Left) *Transverse US of the extensor digitorum communis in a patient with known gout & progressive wrist swelling for 3 months shows severe synovial thickening* ➡ *surrounding the mildly swollen tendons, indicative of chronic active tenosynovitis.* **(Right)** *Transverse color Doppler US at the same level shows severe peritendinous hyperemia, suggestive of active chronic tenosynovitis.*

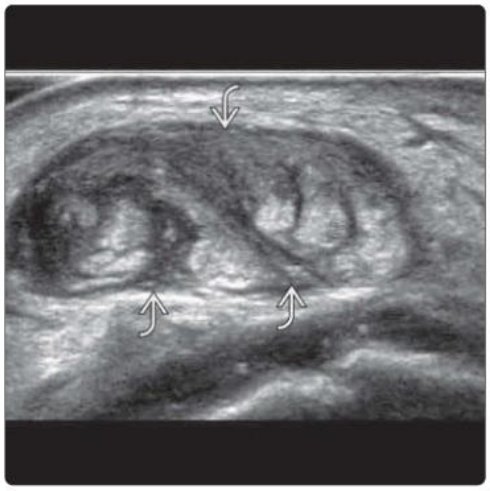

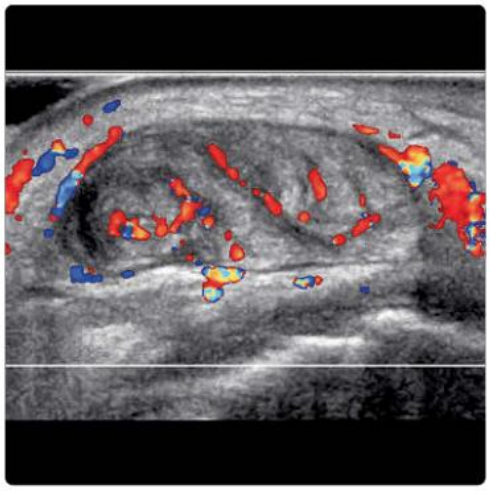

(Left) *Clinical photograph of a patient with known gout shows marked swelling on the dorsum of the wrist with erythema.* **(Right)** *Longitudinal US of the same wrist shows marked distention of the common extensor digitorum tendon sheath. Small, echogenic speckles* ➡ *within the thickened tenosynovium are consistent with crystal aggregates. These features are compatible with a gouty tenosynovitis.*

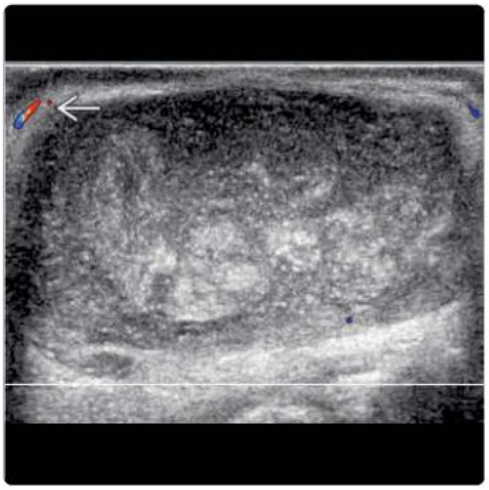

(Left) *Transverse US of the same wrist shows echogenic crystal aggregates ➡, some of which are quite large within the thickened tenosynovium & difficult to separate from the mildly swollen tendons ➡ on this static image.* **(Right)** *Transverse US of the same wrist shows minimal hyperemia ➡ surrounding the extensor tendon sheath, suggestive of chronic inactive tenosynovitis.*

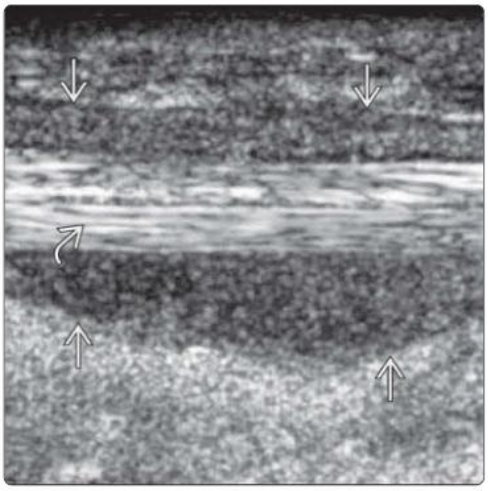

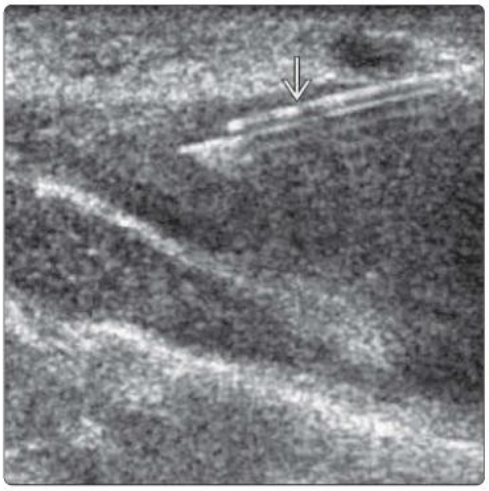

(Left) *Longitudinal US shows acute exudative flexor tenosynovitis of the middle finger with distention of the flexor digitorum tendon sheath ➡ by fluid containing many small, echogenic aggregates, which tend to be less echogenic than those seen in gout. The flexor tendons ➡ are slightly swollen.* **(Right)** *Longitudinal US of the same distended tendon sheath shows needle during needle aspiration ➡ of purulent tendon sheath fluid. This tendon sheath aspirate grew Staphylococcus aureus.*

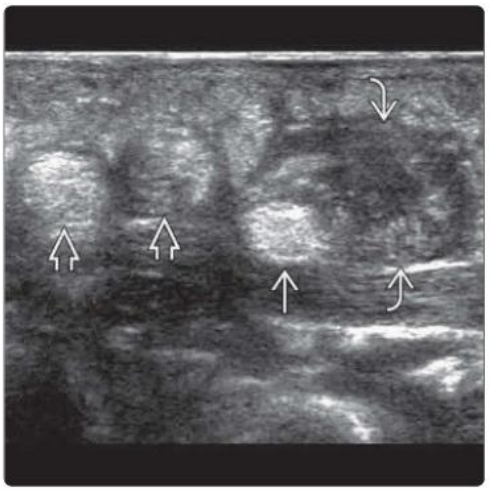

(Left) *Clinical photograph of a palm shows swelling & redness localized to the radial aspect of the palm ⇨. US was requested to rule out deep abscess.* **(Right)** *Transverse US of the palm of the same patient shows thickened tenosynovium ➡ with hyperemia (not shown) eccentrically surrounding the index finger flexor tendon ➡ with moderate soft tissue swelling & edema, consistent with chronic active tenosynovitis. The remaining flexor tendons ➡ are not affected.*

(Left) *Transverse US shows moderate hypoechoic tenosynovial proliferation ⇨ of the extensor digitorum communis tendon sheath on the dorsum of the wrist following a dog bite. The extensor digitorum tendons ⇨ are only minimally swollen.* **(Right)** *Color Doppler US revealed marked tenosynovial hyperemia. Features are consistent with chronic active proliferative tenosynovitis. Intrasheath hyperemia on color Doppler imaging helps distinguish synovial proliferation from synovial fluid.*

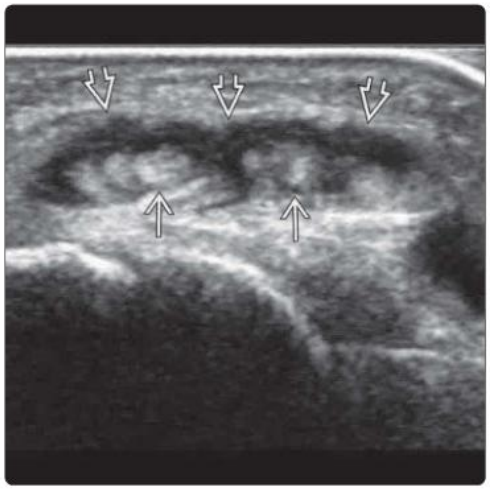

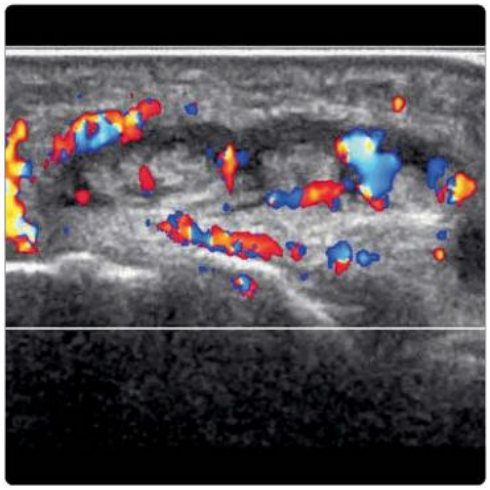

(Left) *Clinical photograph shows moderate swelling ⇨ of the middle finger. Limited movement was present.* **(Right)** *Longitudinal US of the same finger shows tenosynovitis of the flexor digitorum tendon with a mildly thickened tendon sheath ⇨ encasing the tendon. The tendon is mildly to moderately thickened.*

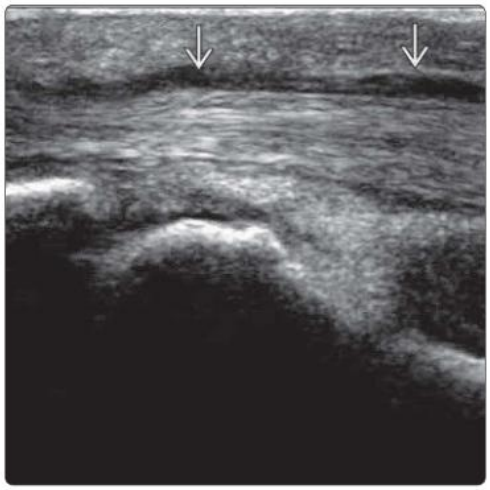

(Left) *Transverse color Doppler US of the same patient shows tendon sheath thickening ⇨ encasing the flexor tendons with moderate tenosynovial hyperemia, suggestive of active inflammation.* **(Right)** *Transverse US in a diabetic patient with group B streptococcal septicemia shows severe distention ⇨ of the extensor hallucis longus (EHL) tendon sheath. The EHL tendon ⇨ is mildly swollen & of normal echogenicity.*

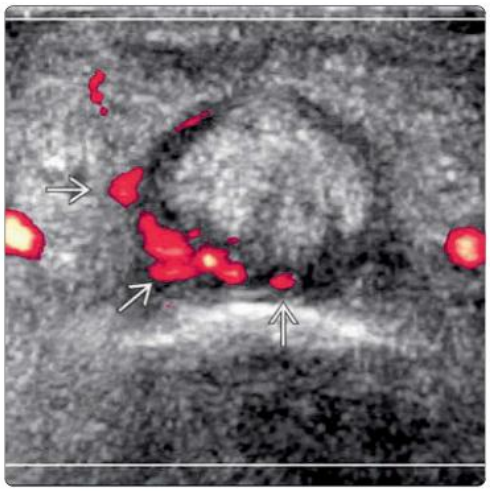

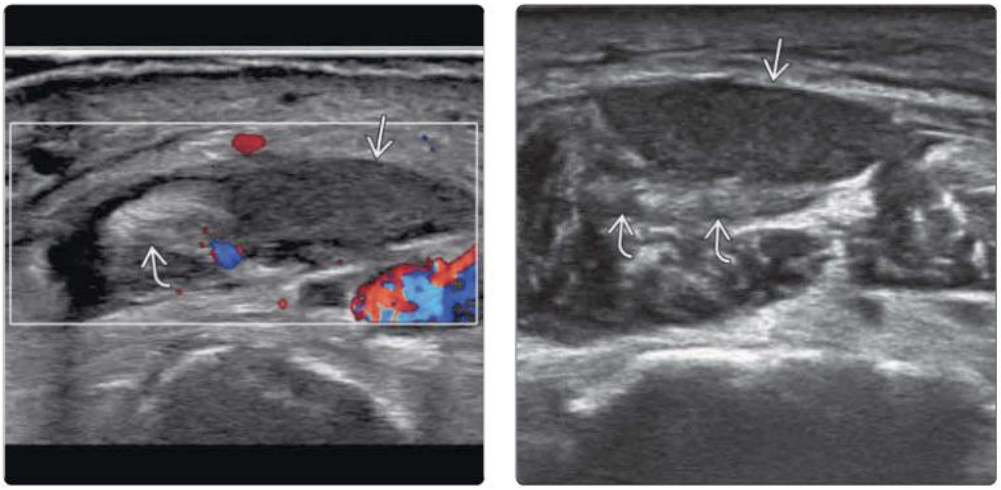

(Left) *Transverse color Doppler US shows no hypervascularity of the distended EHL tenosynovium ➡, suggesting pus collection rather than tenosynovial proliferation. The EHL tendon ➡ is mildly swollen.* **(Right)** *Transverse US of the same patient shows severe tenosynovial distention ➡ of the extensor digitorum of the foot. Color Doppler US shows no significant hyperemia (not shown). The extensor digitorum tendons ➡ are mildly swollen & of normal echogenicity.*

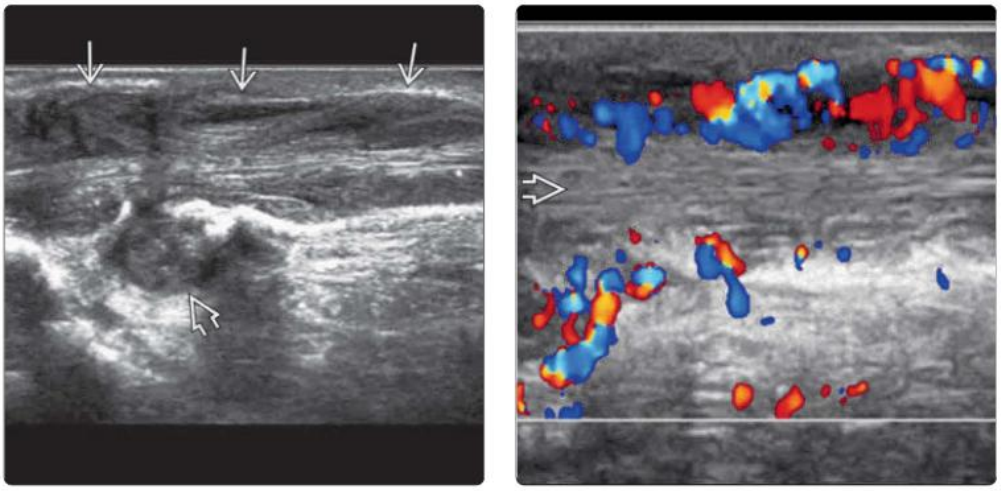

(Left) *Longitudinal US shows severe tenosynovial proliferation ➡ of the extensor carpi ulnaris (ECU) at the wrist in a patient with systemic lupus erythematosus (SLE). This is associated with medium-sized erosion of the ulnar head ➡ filled with proliferative granulation tissue (pannus).* **(Right)** *Color Doppler US in the same patient reveals marked tenosynovial hyperemia. The ECU tendon ➡ is mildly swollen & of normal echogenicity. There is chronic active ECU tenosynovitis due to SLE.*

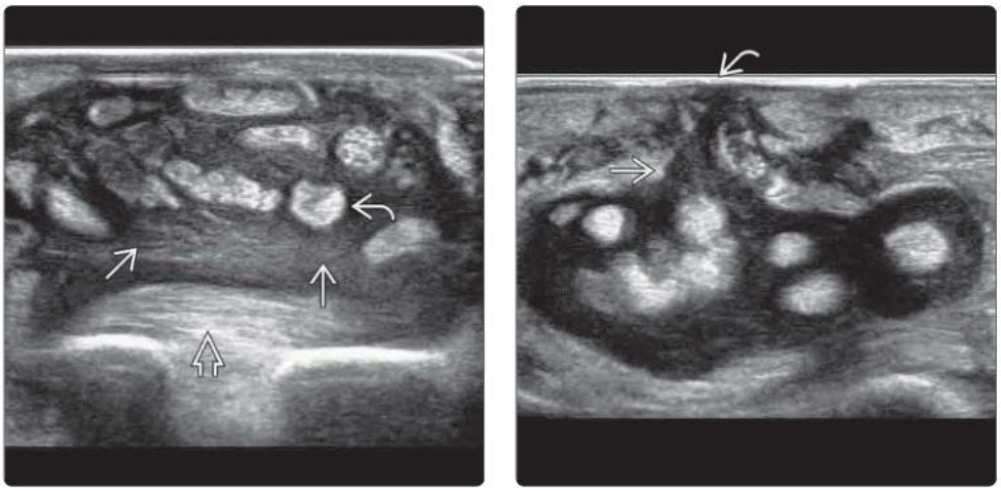

(Left) *Transverse US shows severe tenosynovial proliferation ➡ of the wrist flexor tendons in a patient with known tuberculous (TB) tenosynovitis. Color Doppler imaging (not shown) revealed marked tenosynovial hyperemia. The tendons ➡ are mildly swollen & of normal echogenicity. Pronator quadratus muscle ➡ is normal.* **(Right)** *Transverse US of the same wrist at the more distal level shows inflamed tenosynovium extending along a recent surgical incision tract ➡ toward the skin ➡.*

(Left) *Transverse US of the same patient shows TB tenosynovitis of the 1st extensor compartment. Both the extensor pollicis brevis ➡ & abductor pollicis longus ➡ tendons have split longitudinally with interdigitation of inflamed synovium.* **(Right)** *Transverse color Doppler US of the same area shows severe tenosynovial hyperemia. The main radial artery ➡, passing deep to the 1st extensor compartment tendons & the superficial palmar branch of the radial artery ➡, is shown.*

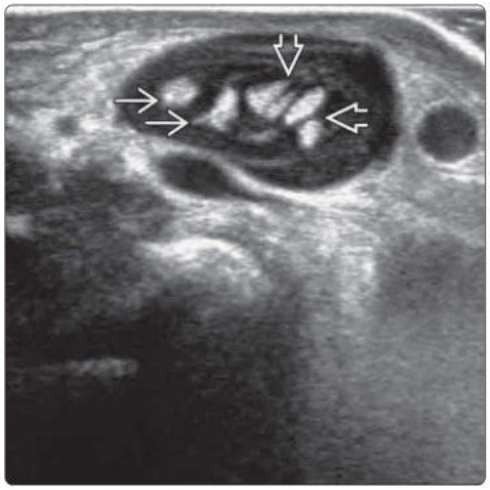

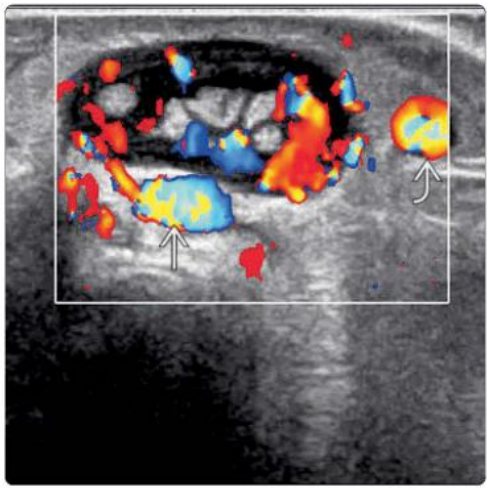

(Left) *Clinical photograph shows severe swelling ➡ of the 1st extensor compartment tendons on the left side with moderate ➡ swelling on the right side.* **(Right)** *Transverse US of the left 1st extensor compartment shows a thickened inseparable abductor pollicis longus & extensor pollicis brevis tendons ➡. The overlying extensor retinaculum ➡ is severely thickened. These features are compatible with de Quervain disease.*

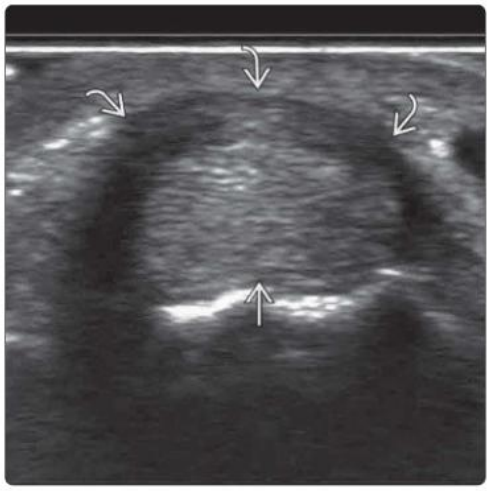

(Left) *Transverse US at the same level shows a cross-sectional area measurement using a continuous trace (dotted lines) of the 1st extensor compartment tendons. This measurement is helpful in monitoring treatment response, as is retinacular thickness.* **(Right)** *Longitudinal US of the same patient shows severe thickening of 1st extensor compartment retinaculum ➡. Underlying abductor pollicis longus tendon is moderately indented. Severe restriction of passive tendon movement on dynamic testing was present.*

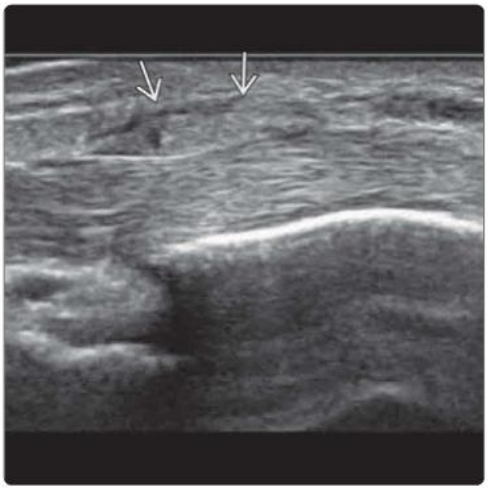

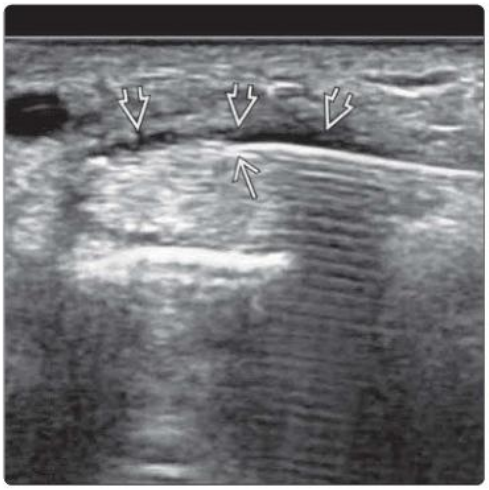

(Left) *Longitudinal US shows severe thickening of the 1st extensor compartment retinaculum ⇨. The underlying abductor pollicis longus tendon is moderately indented. There was severe restriction of passive tendon movement on dynamic testing.* **(Right)** *Transverse US during injection of steroid between the tendon sheath & the retinaculum is shown. The needle tip ⇨ is located at the interface between the tendon & the retinaculum with a thin rim of injected fluid ⇨.*

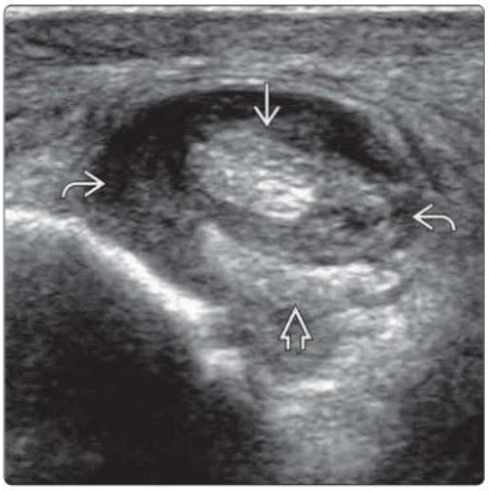

(Left) *Clinical photograph shows lateral retromalleolar ankle swelling with a thickened tubular structure ⇨ in line with the peroneal tendons.* **(Right)** *Transverse US of the supramalleolar common peroneus tendon sheath shows severe synovial proliferation ⇨ surrounding the mildly swollen peroneus longus ⇨ & peroneus brevis ⇨ tendons. Color Doppler imaging (not shown) revealed diffuse tenosynovial hyperemia indicating chronic active tenosynovitis & no tendon sheath effusion.*

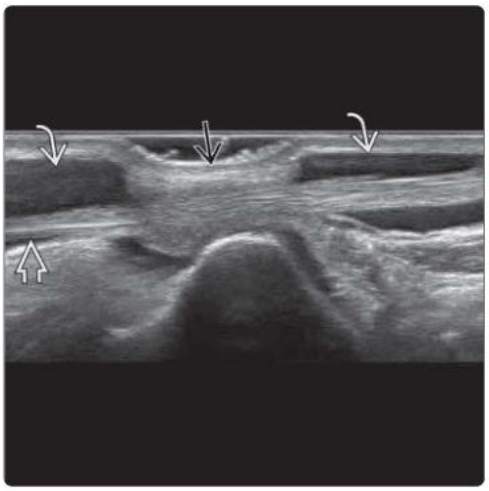

(Left) *Clinical photograph of a 44-year-old woman with bilobulated, nonpainful swelling ⇨ of the anterolateral aspect of ankle for 3 years is shown.* **(Right)** *Longitudinal US of the same area shows a clear tendon sheath effusion ⇨ surrounding the normal extensor digitorum tendon ⇨, leading to the clinically apparent swelling. No hyperemia was present (not shown), consistent with chronic inactive tenosynovitis. Inferior extensor retinaculum ⇨ prevents tendon sheath distention in midportion.*

KEY FACTS

TERMINOLOGY

- Tennis elbow (lateral epicondylitis), golfer's elbow (medial epicondylitis)

IMAGING

- Thickening, hypoechogenicity, fibrillar disruption ± hyperemia of common extensor tendon origin (CETO) or common flexor tendon origin (CFTO)
  - Grade tendinosis severity (minimal, mild, moderate, severe); relates to likelihood of tear/long-term prognosis
  - Independently grade level of hyperemia (minimal, mild, moderate, severe); relates to disease activity
- Hypoechoic, roundish areas with internal echoes within tendon indicative of focal proteoglycan deposition
- Sharp, linear, hypoechoic areas within tendon indicative of intrasubstance tendon tear
- Deeper, anechoic areas at bony attachment indicative of avulsive-type tendon tears
- CETO tendinosis: Usually first affects extensor carpi radialis brevis, followed by anterior fibers of extensor digitorum communis
- CFTO tendinosis: Usually first affects flexor carpi radialis, pronator teres, & palmaris longus tendons

TOP DIFFERENTIAL DIAGNOSES

- Radial or cubital tunnel syndromes

CLINICAL ISSUES

- Lateral epicondylitis most common cause of elbow pain
  - 10x more common than medial epicondylitis

DIAGNOSTIC CHECKLIST

- Severe pain or exacerbation is usually due to tendon tear
- Concomitant ligament injury likely if tear involves inferior 1/3 of CETO or CFTO
- Look to deep margin of tendon for small tendon tears
- 1/6 patients with typical epicondylitis symptoms have no abnormality on US

(Left) *Graphic shows moderate-severity common extensor tendon origin (CETO) tendinosis with a small avulsive-type tear in the midtendon area. Normal radial collateral ligament is noted.* **(Right)** *Longitudinal US shows mild CETO tendinosis with mild hypoechogenicity, mild loss of the normal fibrillar pattern, and cortical irregularity. There is a medium-sized avulsive-type tear of the deep fibers. This tear also involves the radial collateral ligament, which is located at the deeper 1/3 of the CETO.*

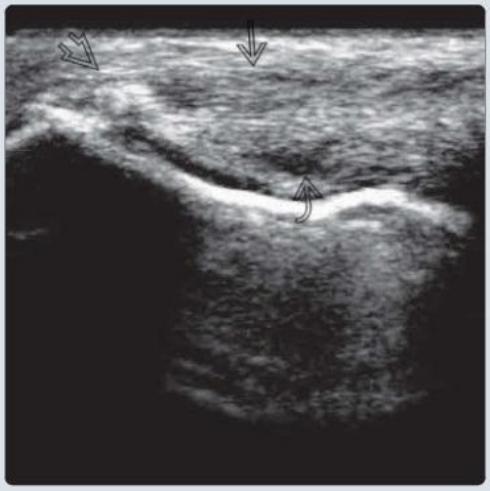

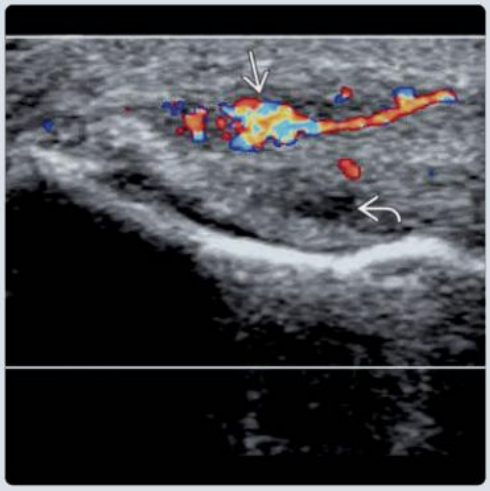

(Left) *Longitudinal US shows moderate CETO tendinosis. There is a small, deep-seated intrasubstance tear, which most likely also involves the radial collateral ligament. Early dystrophic tendon calcification is present. It is important to grade tendinosis severity as minimal, mild, moderate, or severe, as this relates to the likelihood of tear.* **(Right)** *Longitudinal color Doppler US in the same patient shows mild hyperemia indicative of active disease. The small tear is again shown.*

TERMINOLOGY

Abbreviations

- Tendinosis of common extensor tendon origin (CETO) (lateral epicondylitis)
- Tendinosis of common flexor tendon origin (CFTO) (medial epicondylitis)

Synonyms

- Tennis elbow: Lateral epicondylitis, lateral epicondylalgia
- Golfer's elbow: Medial epicondylitis, medial epicondylalgia, medial tennis elbow, flexor-pronator sprain

IMAGING

General Features

- Best diagnostic clue
  - Similar appearances irrespective of whether common extensor or flexor tendon origin is affected
    - Features of tendinosis
      - Hypoechogenicity, thickening, loss of normal fibrillar structure, calcification, cortical irregularity, hyperemia
      - Severity of tendinosis strongly associated with likelihood of tendon tear
- Location
  - CETO
    - Attached to lateral aspect of lateral epicondyle
    - Tendinosis usually first affects extensor carpi radialis brevis (ECRB) tendon, followed by anterior fibers of extensor digitorum communis (EDC) tendon
      - Anterior & deeper components most affected
    - ± tear of underlying radial collateral ligament
  - CFTO
    - Attached to anterior aspect of medial epicondyle & anterior joint capsule
      - CFTO tendon component shorter than that of CETO
    - Tendinosis usually first affects flexor carpi radialis (FCR), pronator teres (PT), & palmaris longus (PL)
    - Runs anterior-superficial & parallel to ulnar collateral ligament
- Size
  - Varies from tendon thickening → intrasubstance tear → to complete avulsion
- Morphology
  - Diffuse tendon thickening → tear
    - Small tears tend to be linear & intrasubstance type, while large tears tend to be avulsive type

Radiographic Findings

- Radiography
  - Cortical irregularity & hyperostosis of CETO/ CFTO
  - Dystrophic calcification within common tendon origin
  - Soft tissue swelling at common tendon origin

MR Findings

- T1WI
  - Thickening & increased T1, T2 signal intensity within common extensor/flexor tendon origin at lateral/medial epicondyle respectively
- T2WI FS
  - Thickening & increased signal intensity of common extensor/ flexor tendon origin
    - Peritendinitis is feature of moderate to severe tendinosis
    - Fluid-cleft indicates tear
    - Insertional subcortical bone marrow edema uncommon

Ultrasonographic Findings

- Tendinosis (> 90% of symptomatic patients)
  - Thickened, hypoechogenic tendon with surface bowing & disruption of normal fibrillar pattern
    - Tendon hypoechogenicity usually affects deeper aspects of tendon initially, spreading to more superficial aspects as disease progresses
    - Ill-defined, hypoechoic areas are indicative of focal proteoglycan accumulation
    - Increased cross-sectional area (CSA) & thickness of tendon
    - For lateral epicondylitis
      - Thickness & CSA measured at plateau of lateral epicondyle
      - Normal CETO thickness < 5 mm at plateau
      - Useful baseline measure for follow-up
      - Tendon size not used as strict diagnostic criterion
- Tendon hyperemia (60% of symptomatic patients)
  - Normal tendons do not display intrinsic vascularity
- Tendon tears (20% of symptomatic patients)
  - Sharp, linear, anechoic/hypoechoic areas within tendon indicative of intrasubstance tendon tears
    - Fluid within tear sometimes compressible
    - Cortical-based anechoic areas indicative of avulsive-type tears
- Secondary signs of tendinosis (% of symptomatic patients)
  - Dystrophic calcification within tendon substance (30%)
  - Cortical irregularity at insertion (20%)
  - Calcific enthesophytes at insertional area (45%)
- Collateral ligament can be torn in conjunction with deeper tendon tears, particularly with CETO tears
- 1/6 patients with typical epicondylitis symptoms have no abnormality on US
- Shear wave or strain elastography can be helpful
  - Strain ratio of < 0.5, stiffness of < 17kPa, & shear wave velocity of < 2.3m/s have high sensitivity & specificity for lateral epicondylitis

Imaging Recommendations

- Best imaging tool
  - US
- Protocol advice
  - Examination with shoulder elbow flexed 70°; elbow internally rotated for lateral epicondylitis, externally rotated for medial epicondylitis
    - Examine with transducer aligned both parallel to & at right angles to long axis of tendons
  - Always include evaluation with color Doppler & compare with contralateral side
    - Grade vascularity subjectively as absent, minimal, mild, moderate, or severe
    - Use copious acoustic gel & minimal transducer pressure

- Level of hyperemia good guide to disease activity
  - Superb microvascular imaging & other vascularity enhancement techniques will optimize assessment
- Check integrity of collateral ligaments
- Measure tendon CSA & thickness at flat lateral aspect of lateral epicondyle (plateau) for lateral epicondylitis
  - Always examine ulnar nerve in medial epicondylitis
- Consider MR if US does not explain symptoms

DIFFERENTIAL DIAGNOSIS

Radial or Cubital Tunnel Syndromes

- Compression of radial or ulnar nerves near lateral or medial epicondyles, respectively
- May be concurrent with epicondylitis

Hypertrophy of Radiohumeral Synovial Flange (Plica)

- Synovial fold projecting into posterolateral elbow joint
- May occur with repetitive pronation & supination

Collateral Ligament Injury

- Usually, has prior moderate to severe trauma

PATHOLOGY

General Features

- Etiology
  - Trauma or overload injury, typically after minor & often unrecognized injury
- Relevant anatomy: CETO
  - ECRB, EDC, extensor digiti minimi (EDM), & extensor carpi ulnaris (ECU) (humeral head) arise inseparably from lateral epicondyle
    - ECRB, EDC, & EDM have common origin from superior & posterosuperior aspect of lateral epicondyle
    - ECU arises from posteroinferior aspect of lateral epicondyle & lies deep to EDC & EDM tendons
  - ECRL arises from distal 1/3 supracondylar ridge
  - Radial collateral ligament lies deep to extensor tendons & runs slightly anteriorly, while extensor tendons run slightly posteriorly
    - EDC is located at superficial 1/3 CETO
    - ECRB located at middle 1/3 CETO
    - Radial collateral ligament located at deep 1/3 CETO
- Relevant anatomy: CFTO
  - PT, FCR, flexor digitorum superficialis (FDS), PL, & flexor carpi ulnaris (FCU) all arise from medial epicondyle
    - FDS lies deep to FCR, PL, & FCU

Staging, Grading, & Classification

- Classify tendinosis as mild, moderate, or severe, depending on overall severity of tendinosis

Gross Pathologic & Surgical Features

- Tendinosis with tendon thickening ± macroscopic partial tear or full-thickness tear

Microscopic Features

- Degenerate, noninflammatory condition (thus, "epicondylosis" is more appropriate term), though peritendinitis is feature of tendinosis
- Collagen disorganization, increased fibroblastic activity, neovascularization, extracellular matrix accumulation
  - Tendon tears heal with reparative granulation tissue
  - Maturation of fibrous tissue to scar-like tendon tissue
- Pathology is similar for both medial & lateral epicondylitis

CLINICAL ISSUES

Presentation

- Most common signs/symptoms
  - Adult patient with lateral or medial elbow pain
    - Pain aggravated by exercise, gradually lessens with rest over several days
    - Lateral epicondylitis pain aggravated by forced wrist extension; medial epicondylitis pain aggravated by forced wrist flexion
    - Local tenderness at tendon origin

Demographics

- Age
  - Peak incidence: 40-50 years
- Epidemiology
  - Population prevalence: ~ 3%
  - Lateral epicondylitis 10x more common than medial epicondylitis
    - Most patients with tennis elbow do not play tennis
    - In golfers, tennis elbow is more common

Natural History & Prognosis

- Usually self-limiting; 1/3 will improve by 3 months, 1/2 by 6 months, 3/4 by 1 year
  - Chronic symptoms or relapse more likely if established tendinosis on US

Treatment

- Conservative
  - Most patients respond to rest ± bracing
    - ± physiotherapy, exercise, stretching, Kinesio taping
    - ± NSAIDs (oral or topical)
  - Dry needling (fenestration)
    - Local anesthetic to tendon surface
    - 20-30 to-&-fro movements of needle within tendon to stimulate healing & promote bleeding within tendon
      - Bleeding facilitates healing, as blood contains mesenchymal stem cells
    - ± followed by 2-3 mL of PRP injection
    - Followed by icing, rest, & physiotherapy
  - Botulinum toxin injection to forearm extensor muscles (60 units)
    - Potentially useful for chronic treatment-resistant lateral epicondylitis
    - Seems to be effective for up to 4 months
  - Steroid injection treats peritendinitis with good early response, though poor long-term outcome
    - Potential deleterious effect on tendon integrity
  - Extracorporeal shock wave therapy (ESWT)
  - Electrotherapy (US, laser therapy, etc.)
- Surgical
  - Anchoring of tendon insertion or tendon release of ECRB

SELECTED REFERENCES

1. Tobaly D et al: Assessing the treatment response of lateral elbow tendinopathy using time-dependent ultrasonography, Doppler imaging, and elastography. Insights Imaging. 15(1):113, 2024

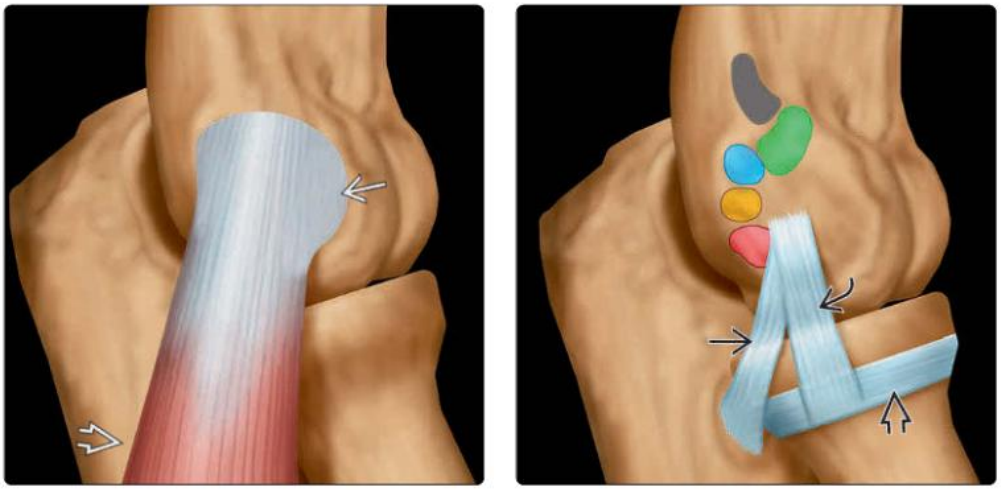

(Left) *Graphic shows the common extensor tendon attachment ⇨, other than ECRL, onto the lateral epicondyle and the extensor muscles ⇨ orientated slightly posteriorly.* **(Right)** *Graphic shows approximate origins of common extensor tendons on lateral epicondyle (gray = ECRL; green = ECRB; blue = extensor digitorum; yellow = EDM; red = ECU). ECRL arises from the distal 1/3 of the supracondylar ridge. Radial collateral ligament ⇨, lateral ulnar collateral ligament ⇨, and annular ligament ⇨ are noted.*

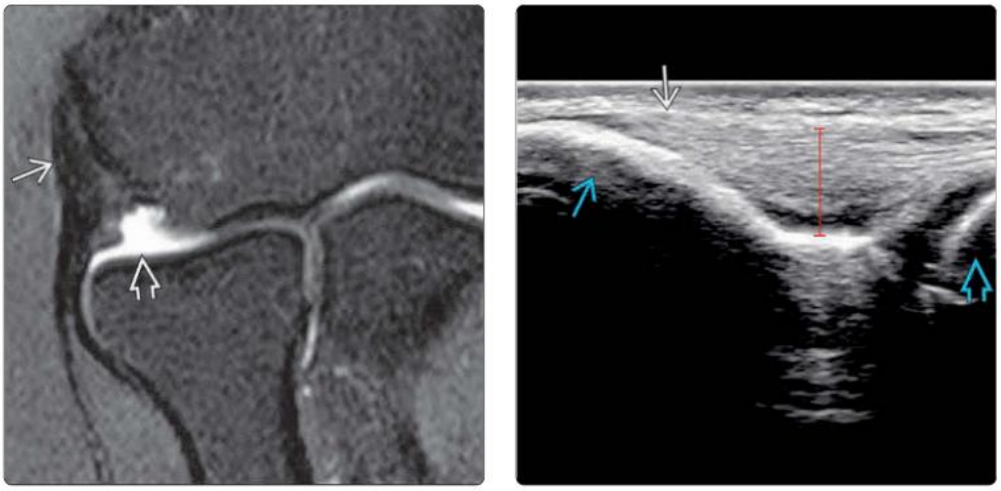

(Left) *Coronal T2 FS MR shows the normal CETO ⇨ at the lateral epicondyle. There is no abnormal hyperintense signal or fiber tear. A small amount of physiologic joint fluid is present at the radiocapitellar articulation ⇨.* **(Right)** *Longitudinal US shows the normal CETO ⇨ at the lateral humeral epicondyle ⇨. There is no abnormal thickening, bulging, or tear, and the fibrillar pattern of the tendon is preserved. Normal tendon thickness at the plateau level is < 5 mm. The bony origin is smooth. Radial head ⇨ is noted.*

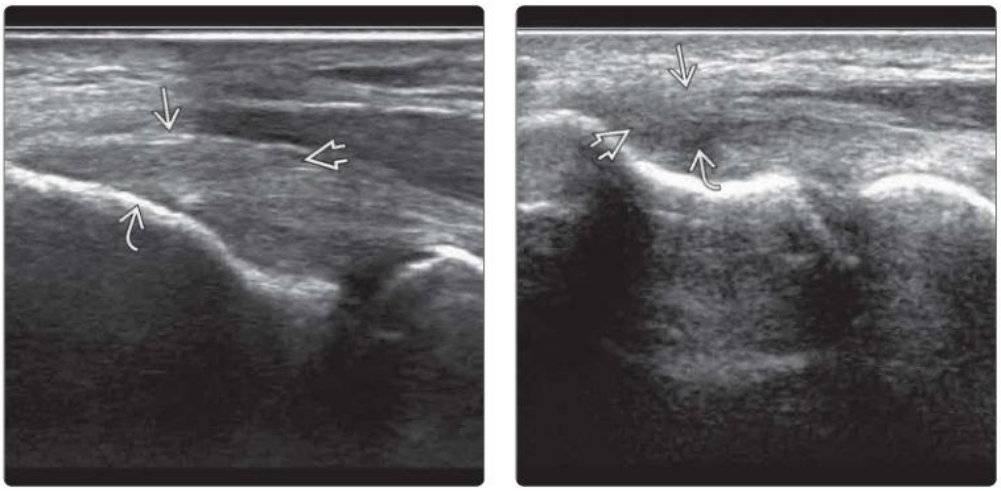

(Left) *Longitudinal US shows mild CETO tendinosis ⇨ with subtle loss of fibrillar pattern ⇨ and mild superficial convexity, indicative of mild tendinosis. Note the smooth bony origin ⇨.* **(Right)** *Longitudinal US shows mild CETO tendinosis with thickening ⇨ and mild loss of fibrillar pattern ⇨. Compared to the previous example, there is a more conspicuous, ill-defined hypoechoic focus ⇨ within the CETO substance due to proteoglycan accumulation rather than an intrasubstance tear.*

(Left) *Longitudinal US shows mild CETO tendinosis with mildly bulging of the superficial fibers* ⇨ *and mild lateral epicondylar hyperostosis* ⇨*. No intrasubstance hypoechogenicity or discrete tear is evident.* **(Right)** *Color Doppler longitudinal US of the same area shows minimal tendon hyperemia helping to firm up a diagnosis of mild CETO tendinosis with minimal disease activity.*

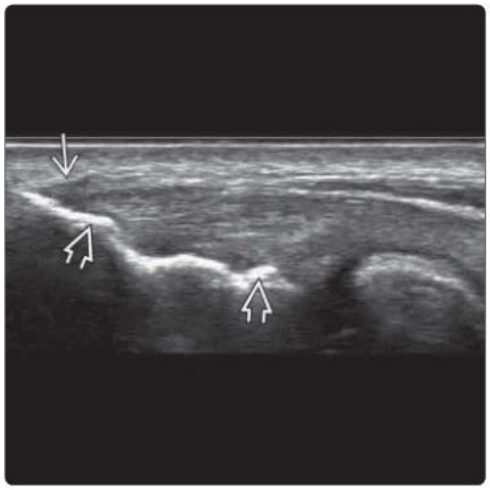

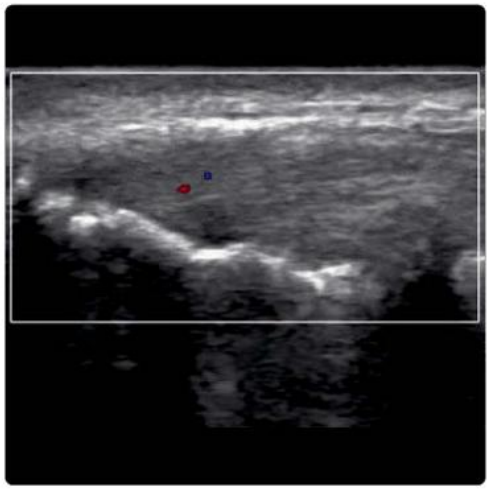

(Left) *Longitudinal US of contralateral CETO in the same patient shows more pronounced tendinosis with more thickening* ⇨*, hypoechogenicity, loss of fibrillar pattern* ⇨*, and moderate cortical irregularity* ⇨*.* **(Right)** *Color Doppler longitudinal US of the same elbow shows more pronounced (moderate) hyperemia compared to the contralateral side. Use minimal pressure while scanning to avoid effacing the underlying vascularity.*

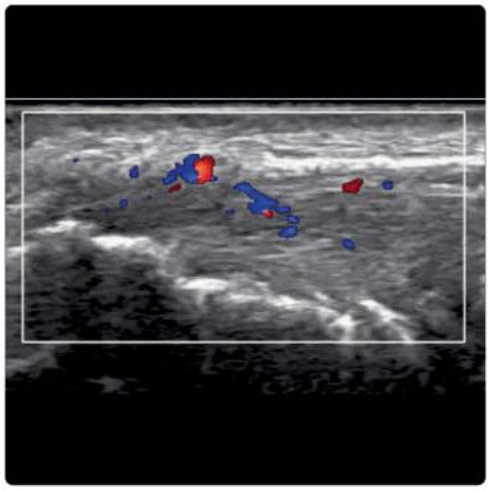

(Left) *Transverse US of the same patient's right (top) and left (bottom) CETO show enlarged cross-sectional areas indicative of tendinosis. This is measured at the plateau region of the epicondyle where the bony surface appears flat. Transverse scanning should be routine, as tendon enlargement may not be conspicuous on longitudinal plane.* **(Right)** *Longitudinal US shows severe CETO tendinosis evident by marked thickening* ⇨ *and loss of fibrillar pattern* ⇨ *with severe superficial bulging* ⇨*.*

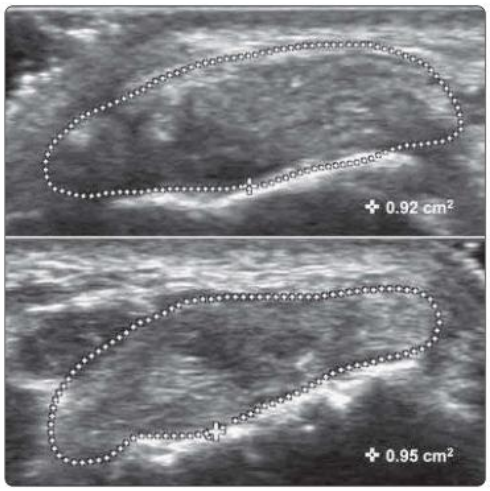

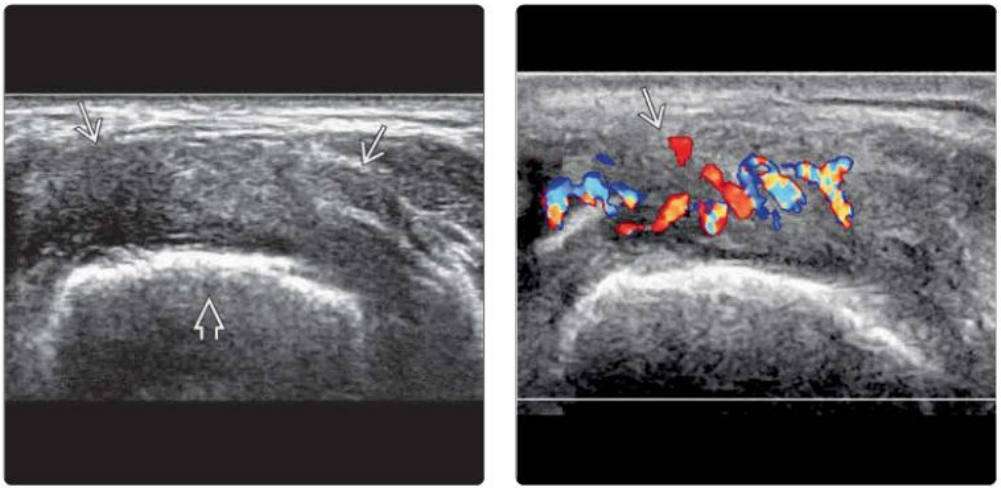

(Left) *Transverse US shows moderate thickening of the CETO ➔ overlying the lateral humeral condyle ➔. No tear is present.* **(Right)** *Transverse color Doppler US of the same area shows moderate to severe hyperemia ➔, indicative of moderate to severe disease activity. Disease activity does not invariably accompany macroscopic tendon tear and vice versa.*

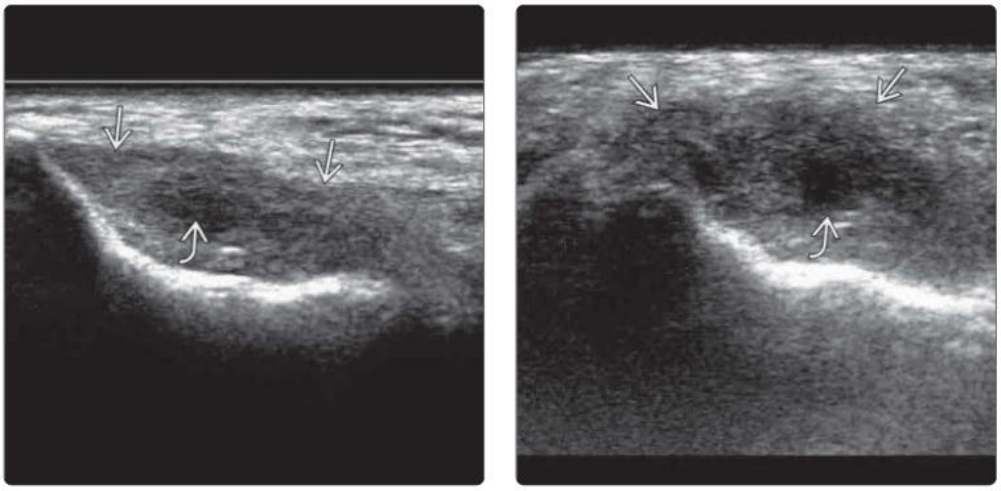

(Left) *Longitudinal US shows moderate CETO tendinosis ➔ with tendon thickening and hypoechogenicity associated with a probable small intrasubstance tear ➔. Differentiation between focal severe proteoglycan (mucoid) accumulation and tear can be challenging, as both entities can appear similar and often coexist.* **(Right)** *Oblique longitudinal US in the same patient shows moderate CETO tendinosis ➔ with a slightly more discrete intrasubstance tendon tear ➔.*

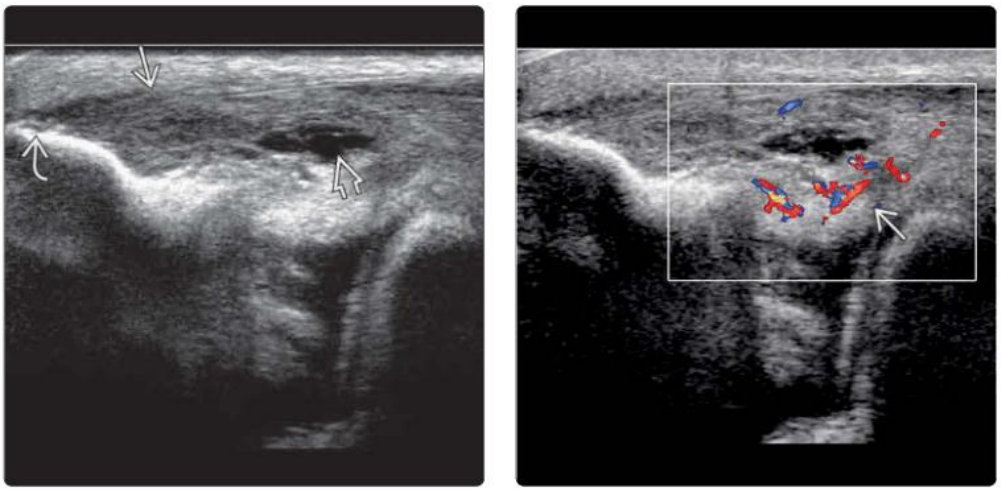

(Left) *Longitudinal US shows moderate CETO tendinosis with thickening and hypoechogenicity of the CETO ➔ at the lateral epicondyle. There is a medium-sized intrasubstance tendon tear ➔ with a more discrete, anechoic appearance than the prior example. Minimal insertional cortical hyperostosis ➔ is present.* **(Right)** *Longitudinal color Doppler US of the same area shows mild to moderate hyperemia ➔, indicative of active disease.*

(Left) *Longitudinal US shows moderate tendinosis of the CETO ➡ with dystrophic intratendinous calcification ➡.* **(Right)** *Coronal T2 FS MR in the same patient shows abnormal thickening and hyperintensity ➡ of the CETO, indicative of moderate tendinosis. There is a small intrasubstance tear ➡ present. Unlike insertional tendinosis at other sites, bone marrow edema is not a common feature of CETO tendinosis.*

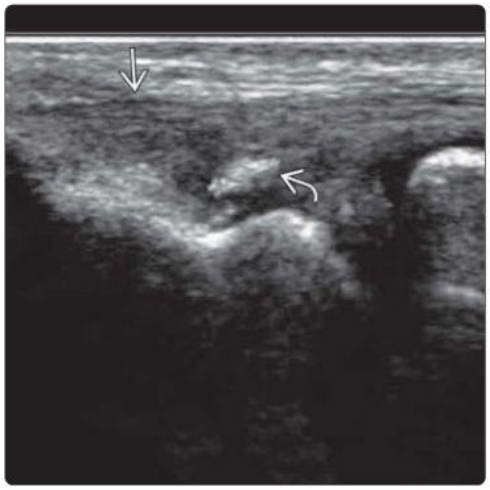

(Left) *Longitudinal US shows severe CETO ➡ with tendon thickening, hypoechogenicity, and loss of the normal fibrillar pattern. No tear is present.* **(Right)** *Transverse US of the same area shows severe CETO tendinosis ➡ with dystrophic intratendinous calcification ➡. Mild surface irregularity of the lateral epicondyle ➡ is present.*

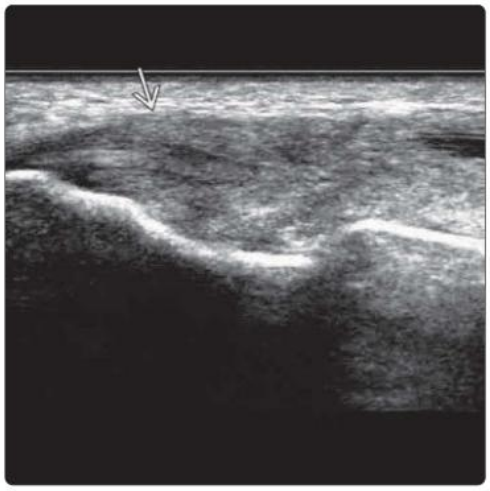

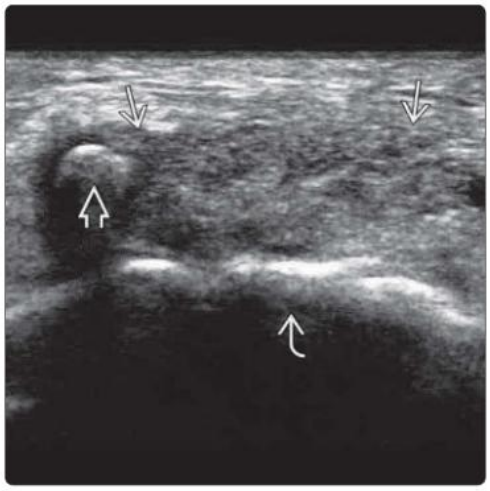

(Left) *Axial T1 MR in the same patient shows the thickened CETO, which is isointense ➡ to adjacent muscle.* **(Right)** *Coronal T2 FS MR in the same patient shows severe CETO tendinosis ➡ with diffuse hyperintensity. No tear is present. Only that portion of the CETO close to the bone is affected. There is very little reactive bone change.*

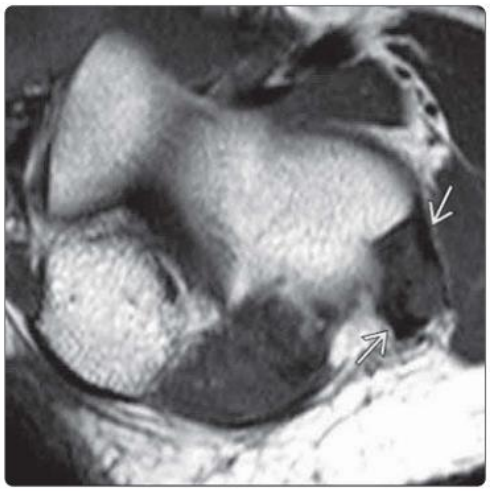

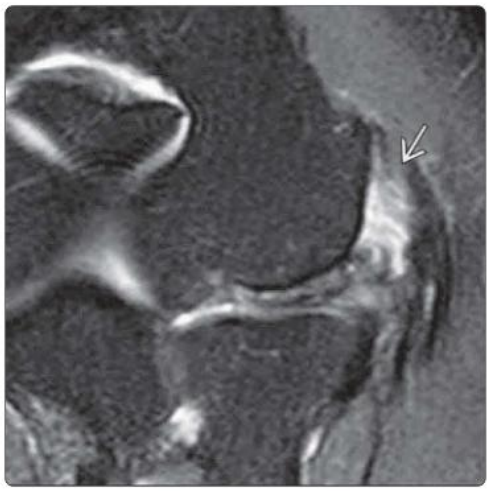

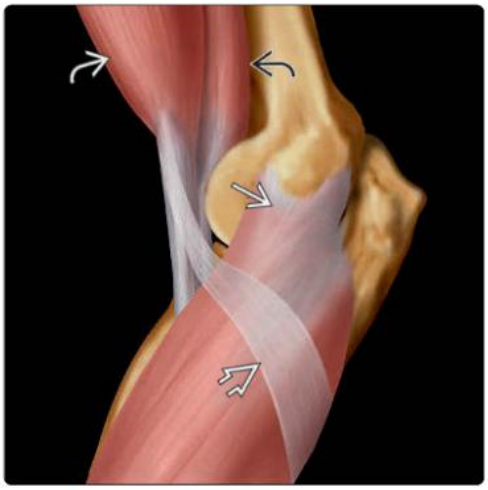

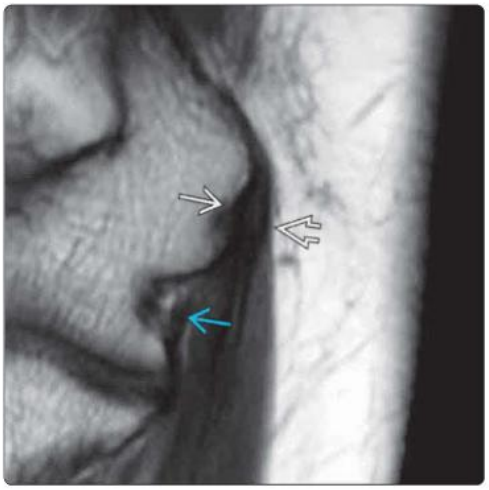

(Left) *Graphic shows the attachment of common flexor tendons to the medial epicondyle. Note the bicipital aponeurosis, biceps muscle, and brachialis muscle.* **(Right)** *Coronal T1 MR shows the normal common flexor tendon origin (CFTO) at the medial epicondyle. The tendon is hypointense and inserted over a broader area than the CETO on the lateral side. Note the flat superficial contour and smooth bony origin. The ulnar collateral ligament is noted.*

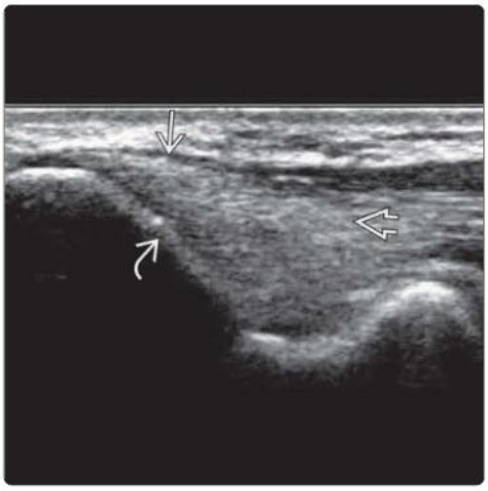

(Left) *Longitudinal US shows the normal CFTO at the medial epicondyle. Note the preserved fibrillar pattern, largely flat superficial contour, and smooth bony origin.* **(Right)** *Longitudinal US shows mild CFTO tendinosis with hypoechogenicity, mild thickening, and a bulging superficial contour. No tear is present.*

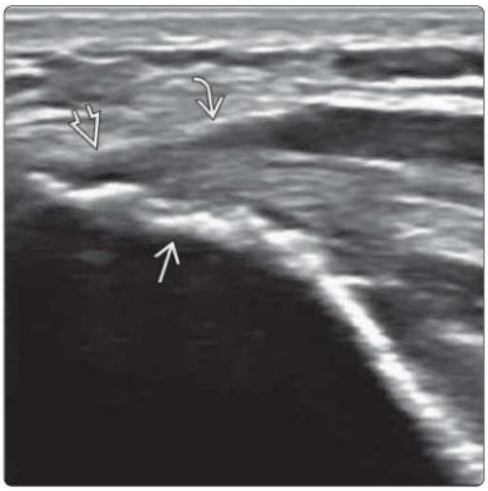

(Left) *Longitudinal US shows mild CFTO tendinosis with moderate bony irregularity of the medial epicondyle and mild tendon thickening. There is a very small avulsive-type tear at the proximal origin.* **(Right)** *Longitudinal US shows mild CFTO tendinosis with mild tendon thickening, an indistinct fibrillar appearance, and a small centrally located avulsive-type tear. No cortical irregularity is present.*

PART III
SECTION 2

Soft Tissue, Bone, and Joint Injury

Fat Injury	496
Muscle Infarction	504
Muscle Injury	508
Hematoma/Seroma	518
Ligament Injury	526
Bone Fracture	534

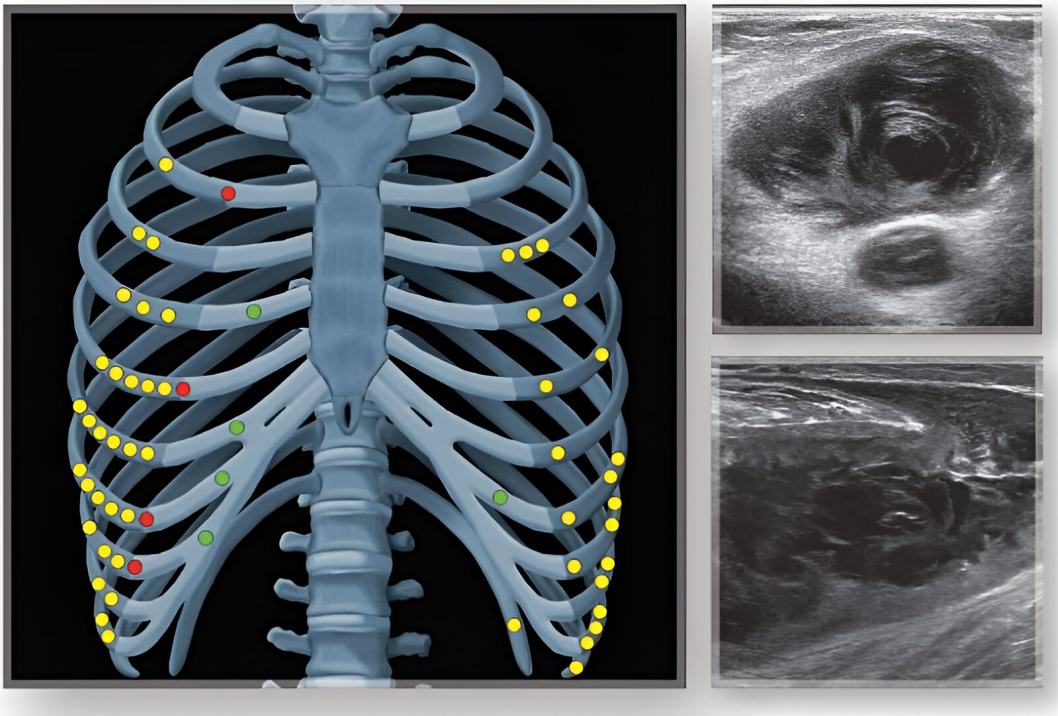

KEY FACTS

TERMINOLOGY

- Focal inflammation ± necrosis ± atrophy of subcutaneous fat

IMAGING

- Variable appearances depending on chronicity of lesion
- Trauma may be mild & not recalled
- Earlier stages (< 1 year)
  - Localized mild swelling & increased echogenicity of subcutaneous fat
  - Loss of normal subcutaneous fat striation
  - Irregular poorly defined margins without discrete mass
  - Hypoechoic stranding extending into surrounding fat
  - ± fluid accumulation within affected fat (liquefaction)
  - ± calcification of affected fat
    - US very sensitive at depicting early calcification
  - ± hypoechoic pseudocapsule
  - Usually mild or no hyperemia
- Investing fascia & muscle are usually normal
- Later stages (> 1 year)
  - Area of fat necrosis becomes better defined & more hypoechoic
  - Loss of volume of affected area
- US allows definitive diagnosis in most cases
  - US is better at depicting associated calcification than MR
- Morel-Lavallée lesion
  - Compressible hypoechoic or anechoic collection between subcutaneous fat & investing fascia
  - Most commonly occurs in anterolateral thigh
- Mobile, echogenic fat globules in cystic nodular area of fat necrosis & Morel-Lavallée lesion

TOP DIFFERENTIAL DIAGNOSES

- Subcutaneous lipoma
- Subcutaneous panniculitis
- Superficial thrombophlebitis
- Fibroma
- Seroma

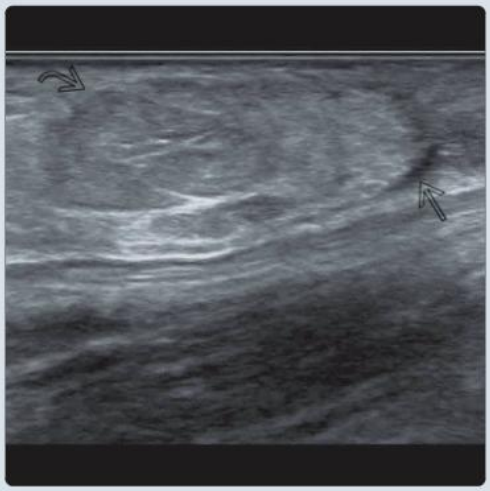

(Left) *Transverse US of the lateral thigh region in a patient with recent trauma shows a quite well-defined area of subcutaneous edema due to fat injury that is hyperechoic to adjacent normal subcutaneous fat. Note the mirror image artifact deep to the investing fascia.* **(Right)** *Longitudinal US of the lateral thigh in a patient with a mildly tender mass for 3 months following blunt trauma shows a localized area of swollen subcutaneous fat associated with a hypoechoic pseudocapsule, compatible with fat necrosis.*

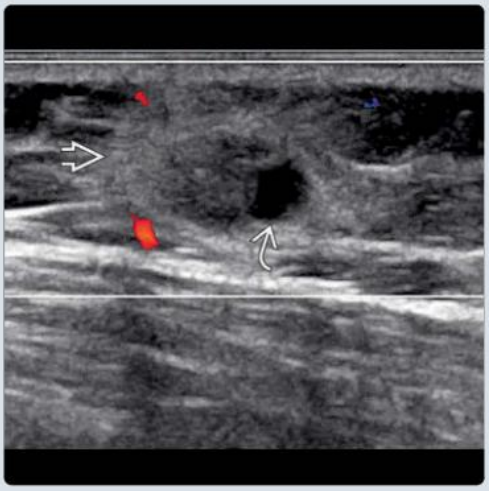

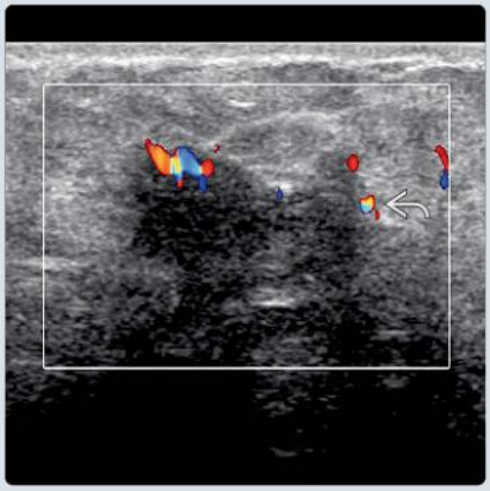

(Left) *Longitudinal color Doppler US shows a focal subcutaneous fat necrosis in the anterior abdominal wall. It shows a cystic area with mild peripheral subcutaneous fat edema and hyperemia. The degree of hyperemia in noninfected fat necrosis is usually absent or mild.* **(Right)** *Longitudinal color Doppler US shows a well-defined, irregular, and hypoechoic lesion due to chronic subcutaneous fat necrosis. There is mild, marginal hyperemia indicative of perilesional repair.*

TERMINOLOGY

Definitions

- Focal inflammation ± necrosis ± atrophy of subcutaneous fat
- Morel-Lavallée lesion: Shear injury leading to separation of subcutaneous tissue from underlying investing fascia creating potential space filled with blood, lymph, or other breakdown products

IMAGING

General Features

- Best diagnostic clue
  - Localized altered echogenicity & thickness of subcutaneous fat with loss of normal fat lobulation
- Location
  - Subcutaneous fat usually over bony protuberances
    - Mainly affects gluteal region or proximal thighs
- Size
  - From a few mm to 10 cm
  - Commonly full depth of subcutaneous tissue is affected
- Morphology
  - Focal swelling of subcutaneous tissues progressing to induration & atrophy

Radiographic Findings

- Focal swelling or atrophy of subcutaneous soft tissue
- Subcutaneous calcification
- Subcutaneous gas locules after high-pressure trauma

MR Findings

- T1WI
  - Focal hyperintense subcutaneous fat swelling
  - Spiculated areas of linear hypointensity within subcutaneous fat due to reactive fibrosis
    - ± pseudocapsule
  - Focal atrophy of subcutaneous fat
  - Usually investing fascia & muscle are normal
- T2WI FS
  - Focal hyperintense subcutaneous fat swelling with surrounding edema
    - ± nodular areas of subcutaneous hypointensity due to calcification
    - ± larger hyperintense areas within subcutaneous fat due to fluid
- T1WI C+ FS
  - Minimal or no intrinsic contrast enhancement
  - Enhancement of pseudocapsule & surrounding edema

Ultrasonographic Findings

- **Traumatic fat necrosis**
  - Appearances vary depending on chronicity of lesion
  - Earlier stages (within 1 year)
    - Localized swelling & increased echogenicity of edematous subcutaneous fat
      - Poor definition of subcutaneous fat lobulation
      - Irregularly defined margins without discrete mass
      - Lobulation of subcutaneous fat that becomes better defined & more hypoechoic with increasing chronicity
      - ± pseudocapsule, which is usually hypoechoic though may be hyperechoic
    - ± fluid accumulation within affected fat
      - Linear fluid collections located superficial to investing fascia
      - Larger, more rounded fluid collections in areas with more abundant subcutaneous fat (e.g., buttock)
      - mobile echogenic fat nodules in nodular cystic fat necrosis
    - ± calcification of affected subcutaneous fat
      - Seen in subacute or chronic stage of fat necrosis
      - Varies from mild, speckled calcification to dense calcification
      - Increasing calcification with increasing lesion chronicity
      - Shadowing artifact may impede full depiction of necrotic area
      - Aggregations of fibrosis without calcification in chronic lesions can cast less severe shadowing artifact
      - US more sensitive than radiographs in depicting mild calcification
    - Hyperemia usually mild or absent
      - Moderate or severe hyperemia suggests secondary infection
  - Later stages
    - Subcutaneous fat necrosis becomes better defined & more hypoechoic with increasing chronicity
      - Subcutaneous fat atrophy may occur with depression of skin surface
  - Usually normal fascia & muscle deep to affected area
    - May rarely show disruption if severe trauma
- **Morel-Lavallée lesion**
  - Uncommon lesion
  - Compressible hypoechoic or anechoic collection between subcutaneous fat & investing fascia
    - Characteristic location at interface between fascia & subcutaneous fat
    - Most commonly occurs in anterolateral thigh
  - Acute/subacute: More heterogeneous & irregular
    - ± echogenic, nondependent fat globules within fluid collection
    - ± signs of secondary infection
  - Chronic: More homogeneous & well defined
    - Partial or complete fibrous capsule

Imaging Recommendations

- Best imaging tool
  - US provides definitive diagnosis in most cases with ready comparison of contralateral side
    - Better at depicting associated calcification than MR
    - MR is better at defining extent of edematous subcutaneous tissue
- Protocol advice
  - Minimal transducer pressure to avoid effacement of subcutaneous fat
  - Ample acoustic gel to fill any skin depression
  - Compare with adjacent normal subcutaneous fat on ipsilateral side or normal subcutaneous fat on contralateral side
  - Use color Doppler to assess vascularity

- Extended FOV imaging can improve perception of localized subcutaneous fat atrophy & show full length of Morel-Lavallée lesion

DIFFERENTIAL DIAGNOSIS

Subcutaneous Lipoma

- Discrete, nontender, subcutaneous lipomatous mass
- Fine linear striations parallel to long axis of mass
- Atypical lipoma & angiolipoma mimic fat necrosis

Subcutaneous Panniculitis

- Localized subcutaneous inflammation with edema & hyperemia
  - Erythema nodosum = septal panniculitis
- More common in shin regions & in children
- Many causes of panniculitis
  - Infection
    - *Streptococcus*, tuberculosis, rheumatic fever
  - Systemic inflammatory disorder
    - Polyarteritis nodosa, systemic lupus erythematosus, sarcoidosis, dermatomyositis, morphea, Takayasu arteritis, necrotizing vasculitis
  - Myeloproliferative disorder
    - Lymphoma, leukemia
  - Pancreatic disease
    - Pancreatitis (50%) or pancreatic carcinoma (50%)
    - May precede recognition of pancreatitis in 50%
  - Drug hypersensitivity
  - Weber-Christian disease: Rare inflammatory panniculitis
    - Fever, arthralgia, anemia, leucopenia, deranged liver function, subcutaneous panniculitis

Superficial Thrombophlebitis

- Localized swelling wall of subcutaneous vein
- ± perivenous edema ± intraluminal thrombosis

Fibroma

- Localized tumoral collection of collagen with sparse number of fibroblasts
- Well-defined to irregular hypoechoic mass
- Absent or mild vascularity

Seroma

- Localized collection of fluid often near surgical site
- Variable content & wall thickness depending on chronicity

PATHOLOGY

General Features

- Etiology
  - Following trauma
    - ~ 50% of patients report prior trauma
      - Trauma is likely cause, even when patients cannot recall antecedent trauma
    - Shearing stress of subcutaneous fat; investing fascia interface with disruption of perforating blood vessels & creation of potential spaces in Morel-Lavallée lesion
  - Following panniculitis

Gross Pathologic & Surgical Features

- Vary due to evolutionary nature of lesion
- Lobular thickening of subcutaneous fat surrounded by fibrous septa
- Later stages may show more dense fibrosis & atrophy of subcutaneous fat

Microscopic Features

- No need to biopsy majority of cases
- Inflammatory infiltrate predominantly involving subcutaneous septa (septal panniculitis) or lobules (lobular panniculitis) ± vasculitis
- Aggregates of foamy phagocytic macrophages
- Reactive fibrous tissue with areas of fat necrosis
- Cytology of cystic aspirate may reveal anuclear fat cells (vacuolated fat cells or "ghost" cells)

CLINICAL ISSUES

Presentation

- Most common signs/symptoms
  - 50% recall trauma (days, weeks, or months)
  - Evolving lesion over weeks or months
  - Tender subcutaneous swelling
    - Progressing to induration & later atrophy
- Other signs/symptoms
  - Pain & tenderness in 50%
  - May be asymptomatic & may present de novo as focal skin depression

Demographics

- Age
  - Young to middle age
- Sex
  - No sex predilection

Natural History & Prognosis

- Resolves over weeks or months with induration ± atrophy
- Indurated subcutaneous tissue either returns to normal, remains slightly indurated, or undergoes progressive fat atrophy leading to focal skin depression

Treatment

- Often no specific treatment
- ± antiinflammatory medication, if lesions are painful
- Percutaneous draining for Morel-Lavallée lesion
  - Usually recurs following percutaneous aspiration
  - Surgical drainage & sclerodesis for chronic lesion

DIAGNOSTIC CHECKLIST

Consider

- Pancreatic disease in patients presenting with unexplained panniculitis or fat necrosis

Image Interpretation Pearls

- Ill-defined, localized echogenicity of subcutaneous fat clinically evolving over weeks or months is usually due to either fat injury or panniculitis

SELECTED REFERENCES

1. Kim M et al: Nodular cystic fat necrosis: a distinctive rare soft-tissue mass. Skeletal Radiol. 53(3):583-8, 2024

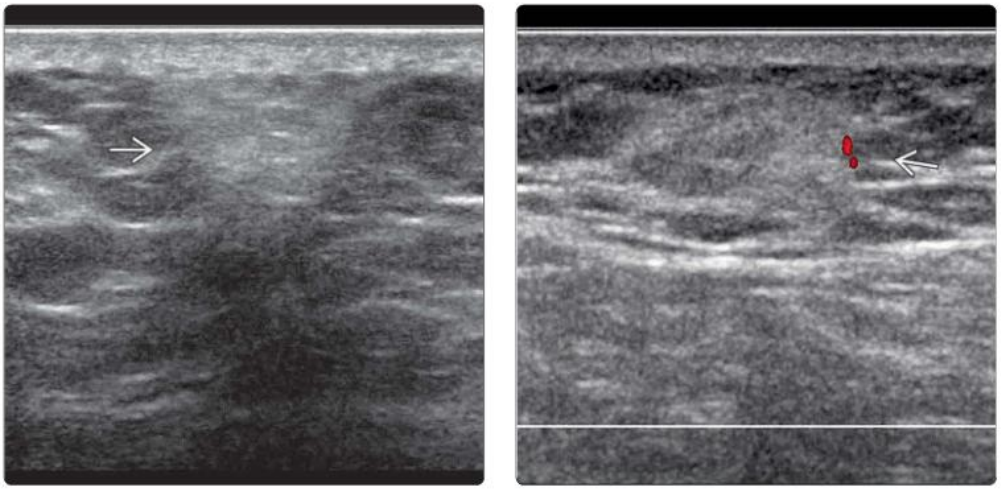

(Left) *Transverse US in a patient with blunt buttock injury 4 months earlier shows a small area of subcutaneous fat necrosis in the upper buttock region. Slight loss of volume is present. There is no liquefaction or calcification.* **(Right)** *Color Doppler US of the same lesion shows minimal peripheral hyperemia. Minimal marginal hyperemia is typical of fat necrosis.*

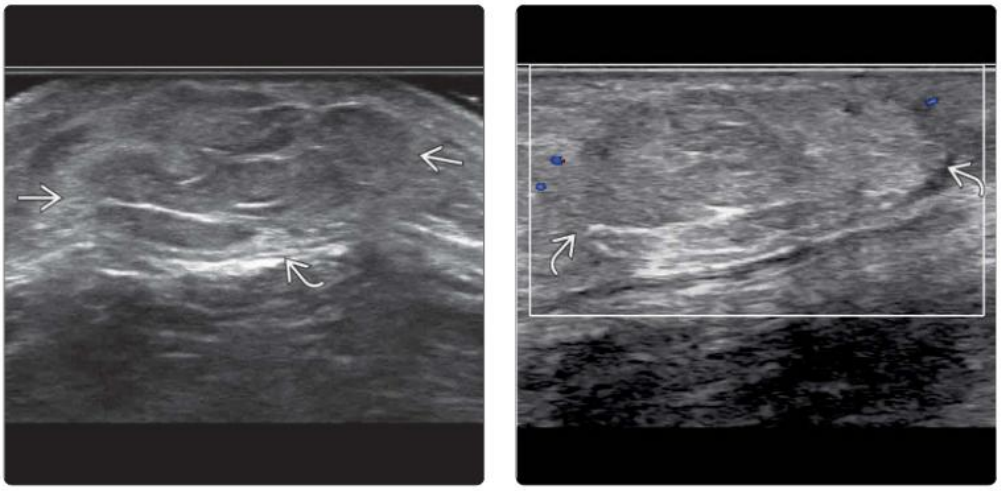

(Left) *Transverse US of the distal thigh in a patient with a mobile mass shows a localized area of subcutaneous fat swelling that mildly indents on the investing fascia. The adjacent subcutaneous fat is edematous.* **(Right)** *Longitudinal US of the same lesion shows a hypoechoic halo surrounding the lesion, representing the fibrotic pseudocapsule. There is no intrinsic vascularity within the area of fat necrosis, but mild peripheral vascularity is present.*

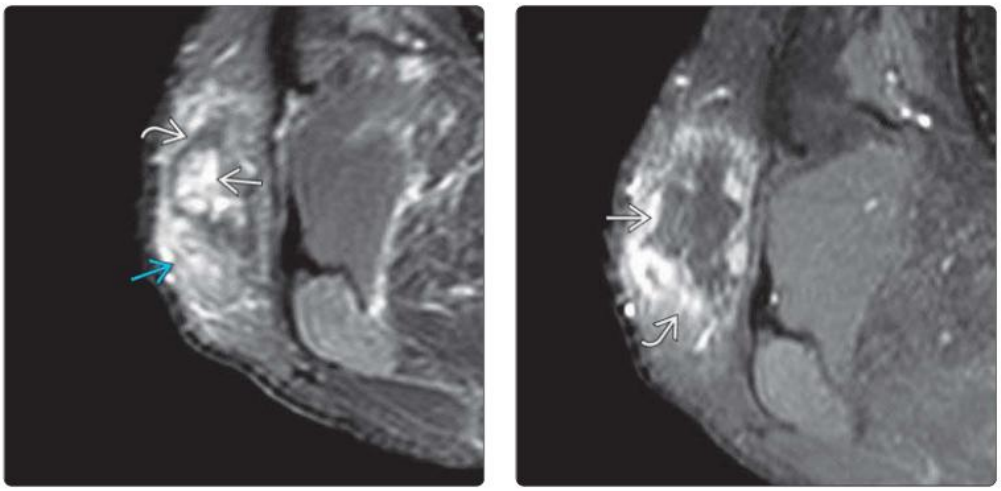

(Left) *Axial T2 FS MR of the same lesion shows thickening of the subcutaneous fat tissue with a T2-hypointense rim surrounding the area of fat necrosis. Note edema within the area of fat necrosis and in the adjacent subcutaneous fat.* **(Right)** *Axial T1 C+ FS MR of the same lesion shows mild to moderate enhancement of the pseudocapsule and adjacent subcutaneous fat. This is due to perilesional inflammation and not infection. The central component of the fat necrosis is nonenhancing.*

(Left) *Transverse US in a patient with a slowly enlarging posttraumatic mass in the abdominal wall shows a heterogeneous subcutaneous mass composed of an ill-defined peripheral hyperechoic component and a discrete central hypoechoic component. Areas of subcutaneous fat necrosis become better defined and more hypoechoic with increasing chronicity. Note the posterior shadowing due to dense fibrosis.* **(Right)** *Axial T1 MR of the same lesion shows a spiculated area of subcutaneous fat necrosis.*

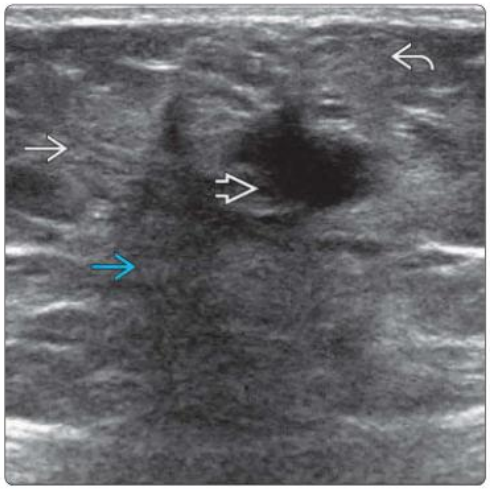

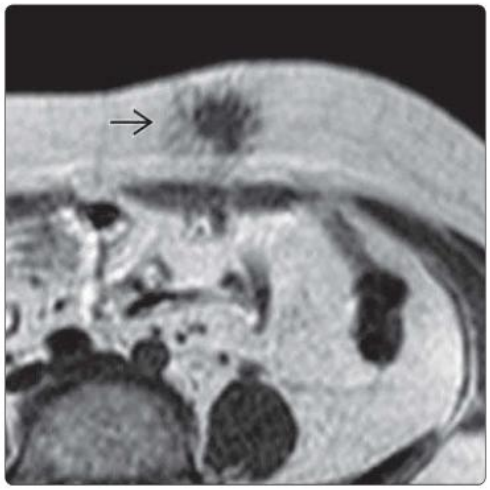

(Left) *Transverse US in a patient with a 1-cm calf mass shows an area of fat necrosis comprised of a central hypoechoic component, calcific foci, and an ill-defined peripheral hyperechoic component. Note the posterior shadowing due to both the calcification and fibrosis.* **(Right)** *Transverse US in the same patent shows another area of fat necrosis that is similar in appearance but with no calcific component. US is more sensitive in detecting early calcification than MR.*

(Left) *Longitudinal US shows a heterogeneous subcutaneous mass in the anterior abdominal wall. The mass comprises an ill-defined peripheral hyperechoic component, a central hypoechoic fat lobule, and a small cystic area.* **(Right)** *Transverse color Doppler US shows a well-defined, cystic area of subcutaneous necrosis with a pseudocapsule, mild posterior acoustic enhancement, and mild marginal hyperemia. This is a mature lesion with no surrounding inflammation.*

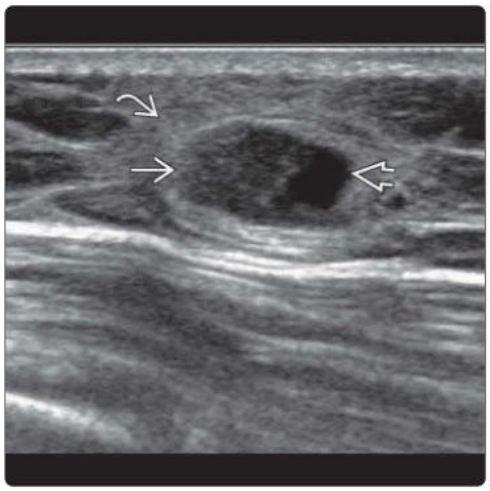

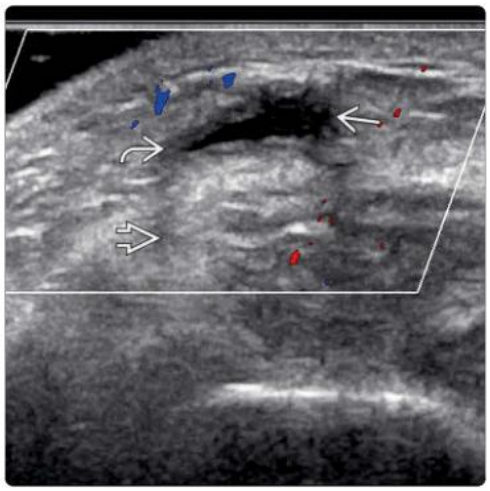

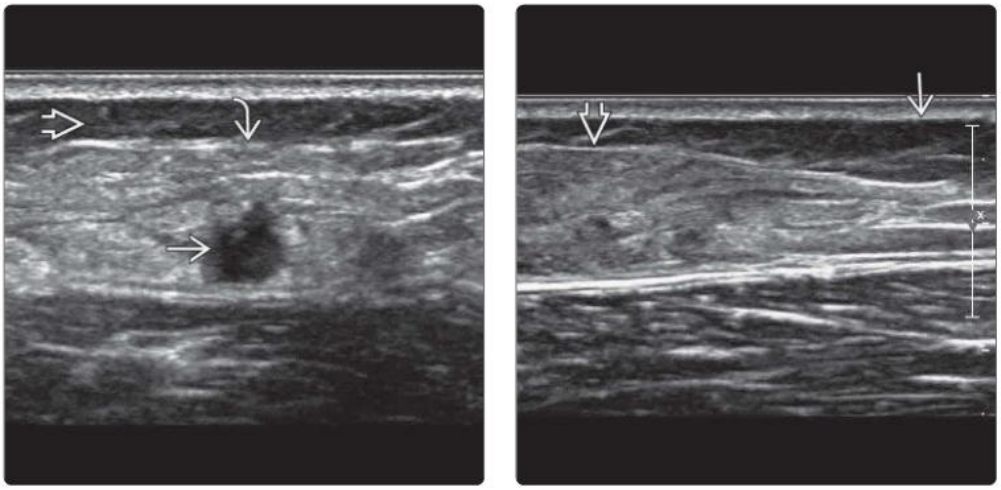

(Left) *Transverse US of the calf in a patient with prior local blunt trauma shows ill-defined hyperechoic subcutaneous fat with a small irregular hypoechoic area. Note the relatively normal superficial subcutaneous fat.* **(Right)** *Longitudinal US in the same patient at a slightly more caudal location shows the clear distinction between normal hypoechoic subcutaneous fat and the posttraumatic hyperechoic edematous injured subcutaneous fat.*

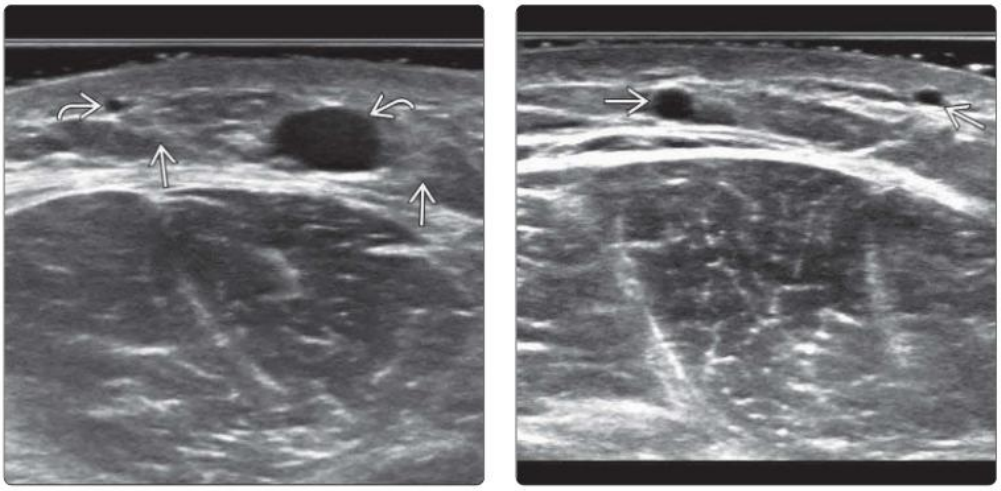

(Left) *Transverse US in a patient with painful soft tissue induration of the anterior thigh shows focal atrophy of the subcutaneous fat with increased echogenicity and a few small cystic areas.* **(Right)** *Transverse US in the same patient at a slightly more medial location shows more cystic spaces. The patient had an ipsilateral foot injury a few months prior but could not recall a direct trauma to the thigh. Overall appearances are still most compatible with posttraumatic cystic fat necrosis.*

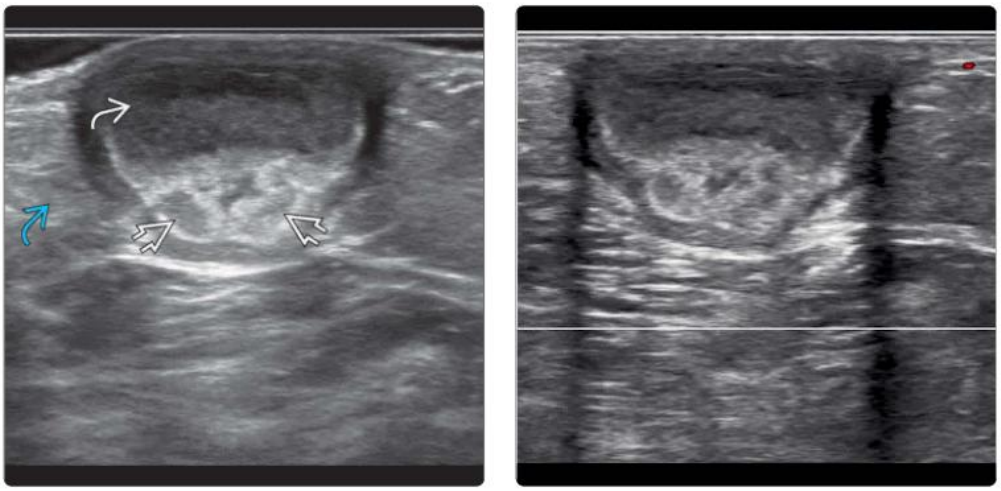

(Left) *Transverse US of the forearm in a patient with Castleman disease and breast cancer shows a thick-walled cystic subcutaneous mass with internal fluid-fluid level and echogenic fat lobules. There is mild edema of the adjacent subcutaneous fat.* **(Right)** *Transverse color Doppler US of the same lesion shows no intrinsic vascularity. The main differential diagnoses were cystic fat necrosis, hematoma, and chronic abscess. The lesion was biopsied to exclude malignancy. Histology revealed fat necrosis.*

(Left) *Transverse US in a patient with recent history of crush injury to the calf shows an area of subcutaneous fat liquefaction ➡ secondary to subcutaneous fat necrosis. The subcutaneous fat is hyperechoic ➡ and swollen due to subcutaneous fat edema.* **(Right)** *Longitudinal US of the same lesion shows how the full depth of subcutaneous fat is affected. Mild edema is also present in the medial belly of the gastrocnemius ➡ just deep to the investing fascia ➡.*

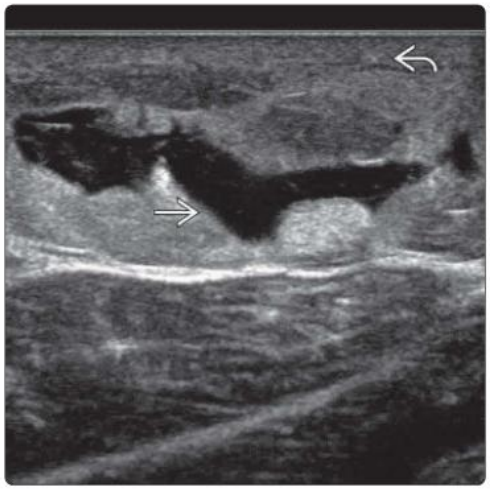

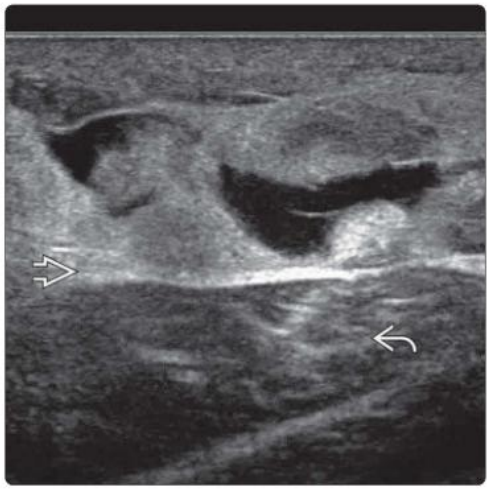

(Left) *Clinical photograph of a patient with previous history of buttock trauma shows severe focal contour depression ➡ in the buttock region.* **(Right)** *Extended field-of-view US in the same patient shows a focal area of severe subcutaneous fat atrophy ➡. There is severe thinning of the subcutaneous fat compared to the adjacent normal subcutaneous fat ➡. The underlying ischial tuberosity ➡ is normal.*

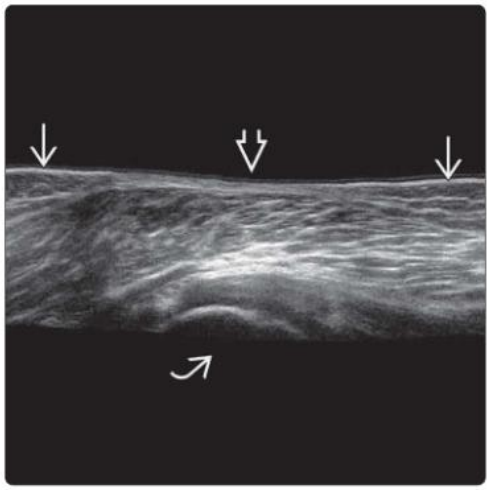

(Left) *Clinical photograph of 71-year-old man who developed a lateral calf nodule ➡ soon after total knee replacement (TKR) 8 months prior is shown. The nodule had remained largely unchanged since initial onset.* **(Right)** *Longitudinal US of the same calf nodule shows a well-defined, multilobulated, mildly expanded area of partially calcified deep subcutaneous fat ➡, compatible with fat necrosis, most likely due to surgical stirrups applied during TKR. Mild marginal hyperemia was present (not shown).*

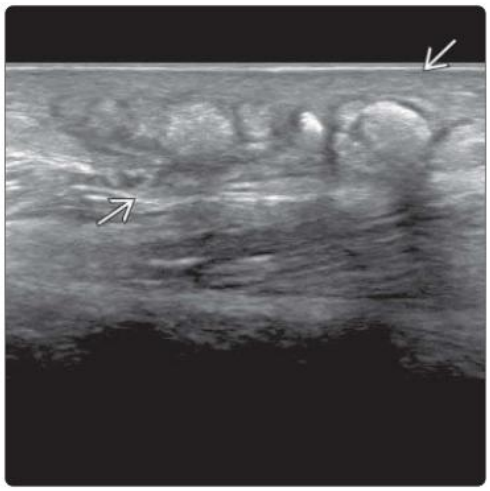

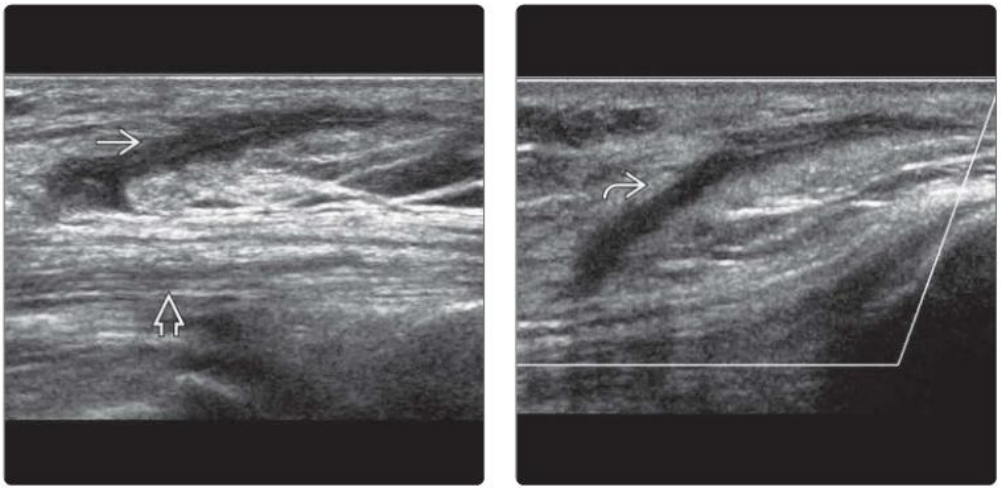

(Left) *Longitudinal US in a patient with subacute trauma to knee shows a cleavage-type injury ➡ of the subcutaneous fat in the suprapatellar region. The quadriceps tendon is normal ➡.* **(Right)** *Longitudinal color Doppler US of the same lesion shows no hyperemia. The linear hypoechoic cleavage space ➡ is filled with fluid. This midsubcutaneous cleavage injury is different from a typical Morel-Lavallée lesion, in which subcutaneous fat separates from the investing fascia.*

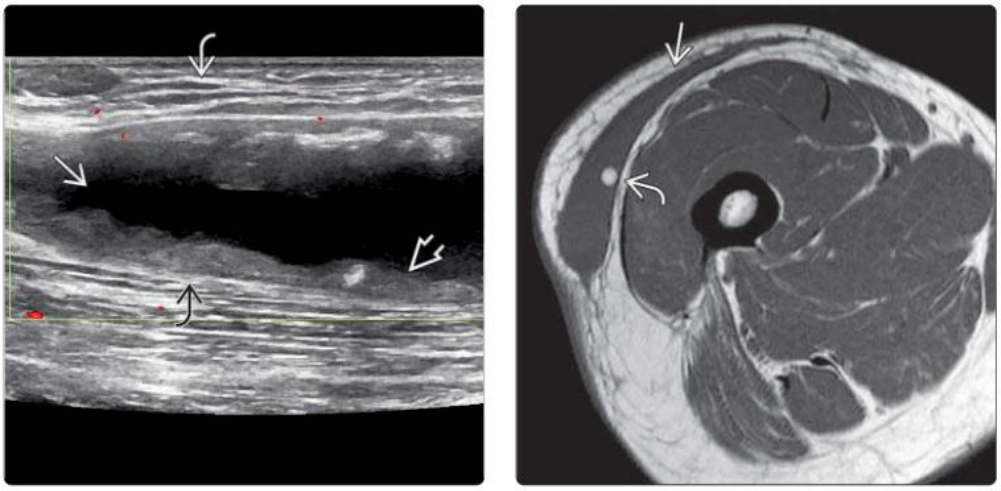

(Left) *Longitudinal color Doppler US of the thigh several weeks after injury shows a Morel-Lavallée lesion with an elongated fluid collection ➡ lying between the investing fascia ⇨ and the subcutaneous fat ➡. The fluid collection has a thick irregular rim of hypoechoic traumatized fat ➡. (Courtesy P. Robinson, MD.)* **(Right)** *Axial T1 MR in a patient with lateral thigh swelling, clinically suspected of sarcoma, shows an elongated subcutaneous fluid collection ➡ with a small fat lobule ➡ characteristic of a Morel-Lavallée lesion.*

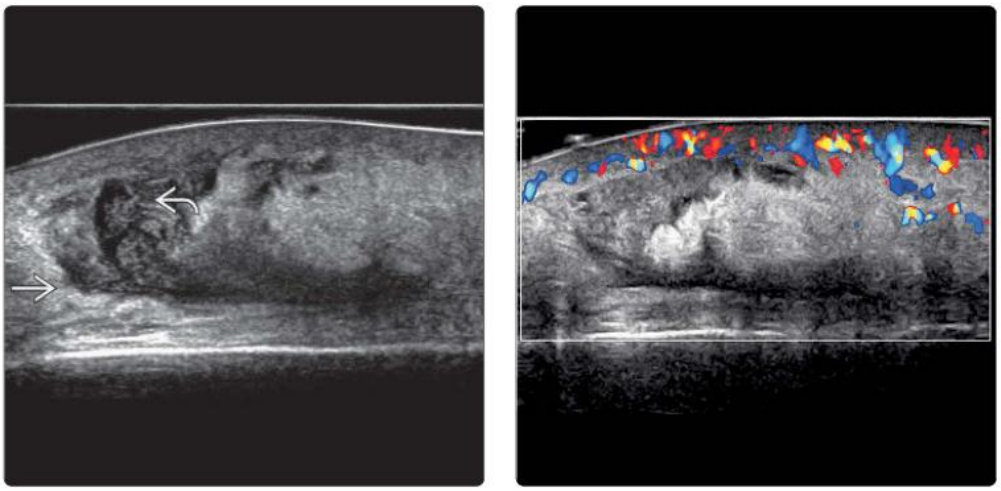

(Left) *Longitudinal US of the shin region in a patient with blunt trauma to this area, who subsequently developed progressive erythema and swelling, shows a large subcutaneous mass ➡ with marked surrounding edema. There are hypoechoic areas ➡ within the affected area, but no discrete liquefaction is present.* **(Right)** *Longitudinal color Doppler US of the same lesion shows moderate to severe hyperemia, consistent with an infected area of subcutaneous fat necrosis.*

KEY FACTS

TERMINOLOGY

- Diabetic muscle infarction, diabetic myonecrosis, aseptic myonecrosis, ischemic myonecrosis

IMAGING

- Predilection for involvement of larger muscles in lower limb
  - Thigh (60%) > leg (40%)
  - Thigh: Anterior > posterior > medial compartment
  - Leg: Posterior > anterior = lateral compartment
  - Usually involves several muscles rather than single muscle
  - Bilateral muscle involvement uncommon (10%)
- Focal, ill-defined swelling & hypoechogenicity of affected muscle
  - Effacement & disruption of affected muscular architecture
- ± subfascial fluid
- ± gas within infarcted area
- ± hemorrhage within infarcted area (best seen on MR)
- Subcutaneous tissue edema overlying infarcted area
- Mass-like area appears during reparative phase
  - Muscle echotexture broadly recognizable within mass-like area
- Initially infarcted area iso- or hypovascular relative to surrounding muscle
  - Becomes mildly hypervascular relative to surrounding muscle during reparative phase
- Biopsy for histologic confirmation is usually not necessary

CLINICAL ISSUES

- Sudden onset of severe localized muscle pain with swelling of affected muscle
- Preexisting advanced diabetes
  - 20% of patients with muscle infarction die within 2 years due to other diabetic complications
- Settles in 5-8 weeks with conservative treatment
- Muscle infarction may also occur in patients with chronic renal failure or severe angiopathy, though no diabetes

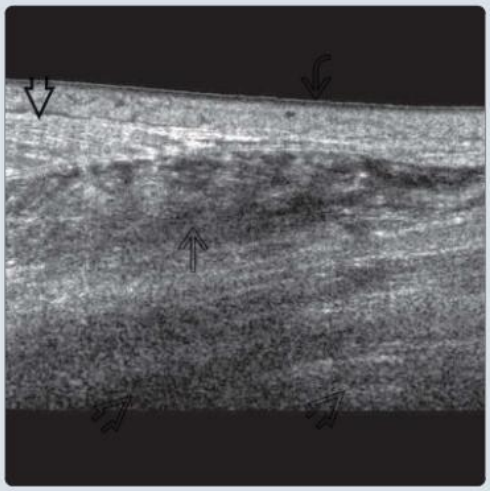

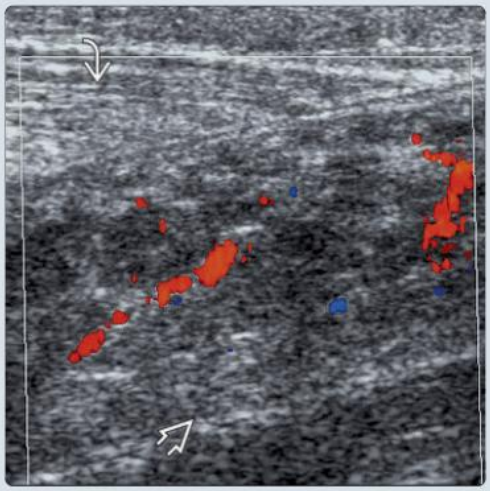

(Left) *Longitudinal US of a diabetic patient shows a swollen soleus muscle ⇨ with a more hypoechoic area superficially ⇨, indicative of diabetic muscle infarction. There is mild subcutaneous edema ⇨. Note the relatively normal gastrocnemius muscle ⇨.* **(Right)** *Longitudinal color Doppler US in the same patient shows moderate hyperemia of the affected soleus muscle ⇨. The gastrocnemius muscle is not hyperemic ⇨.*

(Left) *Axial T2 FS MR in the same patient shows moderate to severe edema of the soleus muscle ⇨ and lateral gastrocnemius belly ⇨. Note mild subcutaneous edema with a small subfascial fluid collection ⇨. The appearances are compatible with diabetic myonecrosis.* **(Right)** *Transverse T1 MR in a diabetic patient shows an ill-defined, hyperintense area ⇨ within the mildly swollen lateral gastrocnemius belly due to muscle infarction with hemorrhage.*

TERMINOLOGY

Synonyms

- Diabetic muscle infarction, diabetic myonecrosis, aseptic myonecrosis, ischemic myonecrosis

Definitions

- Muscle infarction leading to muscle cell death

IMAGING

General Features

- Best diagnostic clue
  - Focal muscle edema in susceptible diabetic patient
- Location
  - Deep within affected muscle
  - Usually involves several muscles rather than single muscle
  - Particularly larger muscles of lower limb
  - Thigh (60%) > leg (40%)
    - Thigh: Anterior compartment (100%), posterior compartment (65%), medial compartment (55%)
    - Leg: Posterior compartment (90%), anterior compartment (20%), lateral compartment (20%)
  - Gluteal muscle also commonly affected
  - Upper limb & abdominal muscle uncommonly affected
  - Bilateral muscle involvement uncommon (10%)
- Size
  - Variable, though typically 3-5 cm
- Morphology
  - Initially, affected muscle swollen
  - Later, firm muscle mass may develop at affected site

Radiographic Findings

- Radiography
  - Arterial calcification as feature of diabetic arteriopathy, renal disease, or atherosclerosis

MR Findings

- T1WI
  - Swollen, isointense affected muscle
  - ± focal hyperintensity within affected muscle due to hemorrhage (40%)
    - Hemorrhage better seen on MR than US
- T2WI FS
  - Focally edematous muscle
    - Degree of edema more pronounced on MR than US
    - ± discrete mass at site of infarction
    - ± subfascial fluid collection (60-100%)
  - Subcutaneous edema (100%)
- T1WI C+
  - Diffuse or rim-enhancement pattern
    - Not beneficial in predicting outcome
  - Most diagnostic information available from noncontrast examination

Ultrasonographic Findings

- Grayscale ultrasound
  - Focal, ill-defined swelling & hypoechogenicity of affected muscle
  - Effacement & disruption of affected muscular architecture if severe
    - Intrinsic muscle architecture remains apparent in milder cases
  - ± subfascial fluid superficial to infarcted muscle area
    - Can be gravity dependent, so less readily appreciated on US than MR
  - ± gas within infarcted area, seen as echogenic foci with reverberation artifact
  - Subcutaneous tissue edema overlying infarcted area
    - Varies according to extent, severity, & duration of infarction
    - Degree of subcutaneous edema may provide clue to duration of infarction
  - Infarcted area may resolve or evolve into medium-sized, discrete, well-marginated, hypoechoic mass
    - Mass appears during reparative phase; not feature of acute phase
    - Echotexture of muscle broadly preserved within mass-like area
    - Mass slowly resolves, tending to become better defined & firmer with time
  - Calcification is not a feature
- Color Doppler
  - Initially, affected area is iso- or hypovascular relative to surrounding muscle
    - Becomes mildly hypervascular relative to surrounding muscle after 2-3 weeks
  - Can exclude deep venous thrombosis

Imaging Recommendations

- Best imaging tool
  - US to help confirm diagnosis of diabetic muscle infarction & exclude likely differential diagnoses
- Protocol advice
  - Perform early examination followed by serial examinations at intervals of 3-4 weeks for 9-12 weeks to observe changing nature of lesion
  - Routinely compare vascularity of affected muscle with contralateral unaffected muscle
  - Biopsy for histologic confirmation is usually not necessary
    - Indicated only for atypical presentation, equivocal findings, or if not settling as expected over time
    - Aspiration of fluid for culture may be helpful if secondary infection is suspected

DIFFERENTIAL DIAGNOSIS

Muscle Abscess/Infective Phlegmon

- Severe pain & tenderness ± fever
- Predominant central hypoechoic/anechoic component
- Deteriorates & becomes more liquefied with time
- Purulent fluid on aspiration

Infective or Inflammatory Myositis

- Severe pain & tenderness ± fever
- Diffuse muscle edema & hyperemia
- Progresses rather than regresses with time

Deep Venous Thrombosis

- Noncompressibility of affected vein
- Visible thrombus within vein
- Poor phasicity on spectral analysis

Compartment Syndrome

- Muscle ischemia caused by ↑ intracompartmental pressure, often from trauma
  - Most commonly affects anterior compartment of leg
- 5 P's: Pain > paresthesia > pallor > pulselessness > paralysis
- Majority do not progress to infarction if compartmental (fascial) release performed promptly
- Dystrophic calcification rarely develop in chronic subclinical compartment syndrome ("calcific myonecrosis")

PATHOLOGY

General Features

- Etiology
  - Probably caused by microvascular occlusion due to arteriosclerosis obliterans, thrombus, or embolus
  - Hypoxia: Reperfusion injury & hypercoagulable state may also be contributory
- Associated abnormalities
  - Longstanding, insulin-dependent diabetes
  - Poor control of glycemia
  - Presence of microvascular diabetic complications (neuropathy, retinopathy, nephropathy)

Gross Pathologic & Surgical Features

- Swollen, nonhemorrhagic, pale-looking muscle

Microscopic Features

- Muscle necrosis (myonecrosis) & edema
  - Phagocytosis of necrotic muscle fibers
- Acute or chronic inflammatory infiltrate
  - Greater if secondary infection
- Granulation tissue repair with fibrosis
- Small arteries of infarcted area may have thickened, hyalinized walls & be occluded with fibrin clot or calcium fragments

CLINICAL ISSUES

Presentation

- Most common signs/symptoms
  - Sudden severe localized muscle pain & swelling
  - Preexisting advanced diabetes
- Other signs/symptoms
  - Often delay between onset of symptoms & presentation (average 4 weeks)
  - Resolution of swelling with appearance of painful palpable mass (33%) over 3 weeks
  - Fever (10%)
  - Secondary infection of affected muscle
- Clinical profile
  - Mean duration of diabetes prior to diabetic muscle infarction is 15 years
    - Insulin-dependent diabetics (30%), noninsulin-dependent diabetics (30%), noninsulin-dependent diabetics on insulin regime (30%)
  - Accompanying diabetic complications common
    - Nephropathy (70%), retinopathy (60%), neuropathy (60%), peripheral vascular disease (10%), hypertension (10%)
  - Laboratory tests inconclusive
    - Elevated creatine kinase (50%)
      - Particularly if obtained soon after onset of symptoms
      - Will normalize in ~ 1 week
    - Elevated white cell count (10%)
    - Elevated C-reactive protein (50%)
    - Elevated erythrocyte sedimentation rate (50%)
  - Muscle infarction may also occur in patients with chronic renal failure or severe angiopathy, though no diabetes

Demographics

- Age
  - Range: 19-81 years (mean: 42 years)
    - Insulin-dependent diabetics affected at younger age than noninsulin-dependent diabetics
- Sex
  - Slightly more common in diabetic women (60%)
- Epidemiology
  - Diabetes mellitus affects 5% of population
  - Muscle infarction uncommon complication of diabetes

Natural History & Prognosis

- Settles in ~ 5-8 weeks with conservative treatment
- ~ 1/3 of patients have 2nd episode of muscle infarction
  - Most commonly involves different muscle (85%) rather than same muscle (15%)
- Diabetic muscle infarction poor prognostic sign
  - 20% of patients die within 2 years due to other diabetic complications

Treatment

- Conservative
  - Bed rest & non-weight bearing
    - Leg elevation
  - Analgesia ± specific drug treatment
    - Nonsteroidal antiinflammatory agents
    - Antiplatelet therapy if hypercoagulable state
    - Steroids if antiphospholipid antibodies present
  - Stringent metabolic control of diabetes
  - Gradual resumption of activity as pain resolves
- Complications
  - Biopsy may induce bleeding into infarcted area
  - Secondary infection of infarcted muscle (uncommon)

DIAGNOSTIC CHECKLIST

Consider

- Diabetic muscle infarction in any patient with known diabetic complication presenting with muscle pain

Image Interpretation Pearls

- Diagnosis based on recognition of typical US findings in at-risk patients
- Serial examination showing evolving US changes will allow definitive diagnosis without need for percutaneous biopsy

SELECTED REFERENCES

1. Davidson AL et al: Practical review on the contemporary diagnosis and management of compartment syndrome. Plast Reconstr Surg Glob Open. 12(3):e5637, 2024
2. Broski SM et al: Muscle: ischemia, infarction, and compartment syndrome. Semin Musculoskelet Radiol. 21(4):443-58, 2017
3. Baker JC et al. Diabetic musculoskeletal complications and their imaging mimics. Radiographics. 1959-74; 32(7), 2012

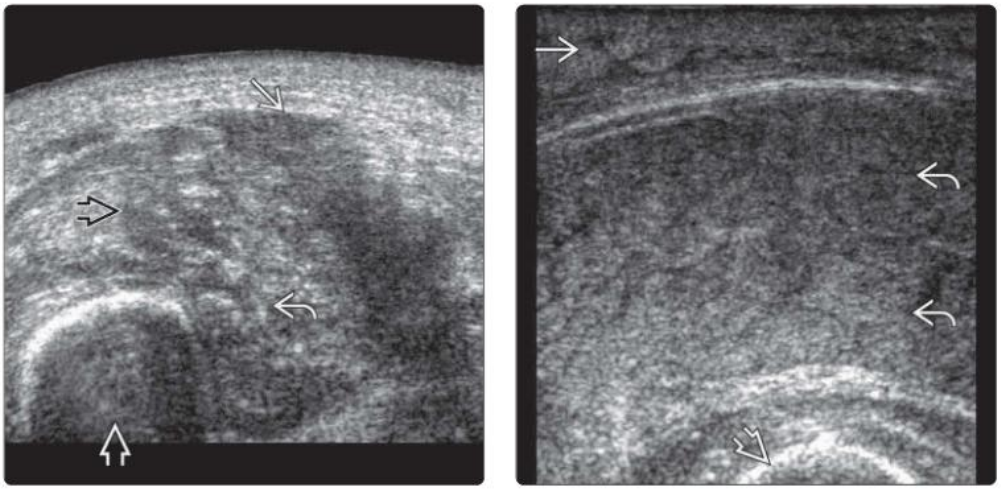

(Left) *Transverse US in a diabetic patient shows a well-defined, swollen, hypoechoic area ⇨ of vastus lateralis muscle infarction. The small echogenic foci ⇨ are possibly due to gas. There is a more hypoechoic edematous area laterally ⇨. The femoral shaft is normal ⇨.* **(Right)** *Transverse US in a diabetic patient shows a diffusely swollen vastus intermedius muscle ⇨ with subcutaneous edema ⇨, consistent with recent muscle infarction. The femoral shaft ⇨ is shown.*

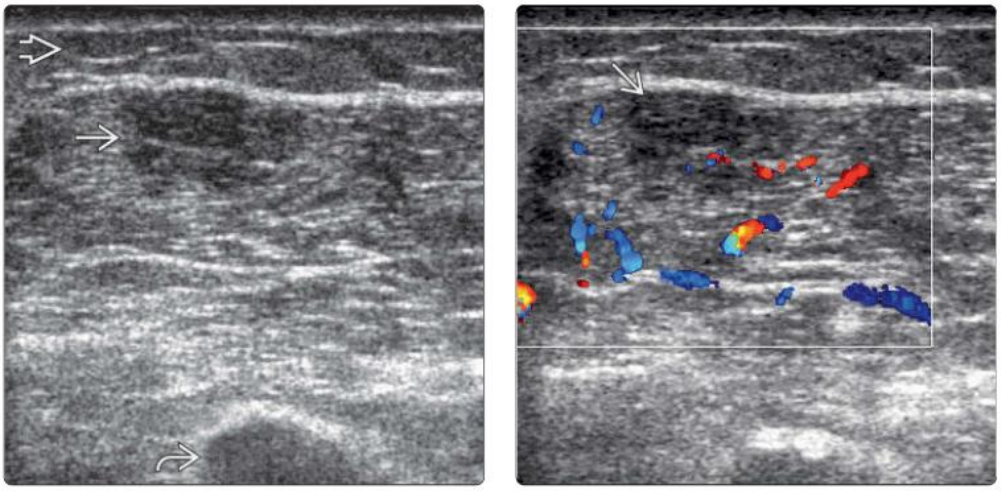

(Left) *Transverse US in a diabetic patient shows a well-defined, hypoechoic area ⇨ with broadly preserved background muscle architecture due to resolving biceps brachii muscle infarction. There is no subcutaneous edema ⇨. The humeral shaft is normal ⇨.* **(Right)** *Transverse color Doppler US at the same location (same patient) shows moderate hyperemia around the infarcted hypoechoic area ⇨. In a typical patient, these appearances require no additional imaging.*

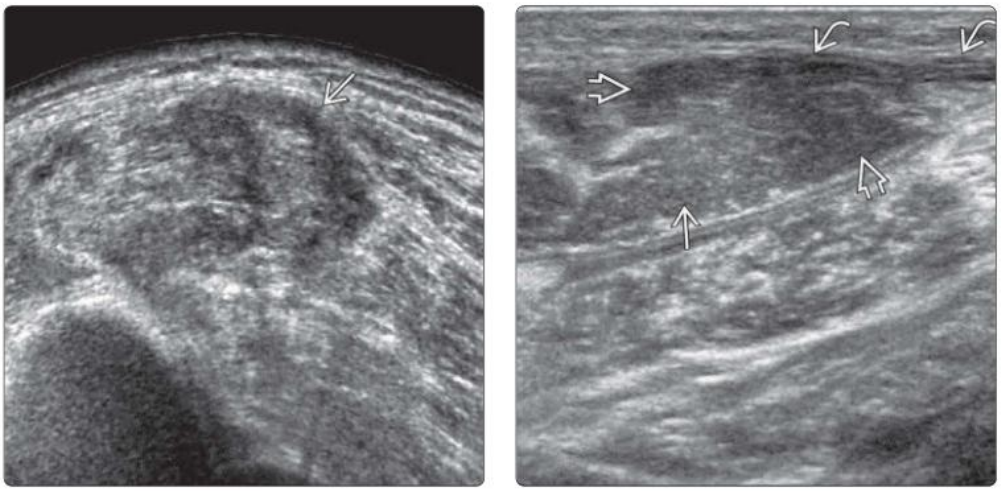

(Left) *Transverse US in a diabetic patient shows a well-defined, hypoechoic area ⇨ due to peroneal muscle infarction. The muscle architecture can still be appreciated within the infarcted area, indicating no discrete mass present.* **(Right)** *Transverse US in a diabetic patient shows ill-defined hypoechoic areas ⇨ in mildly swollen lateral gastrocnemius muscle belly ⇨ with a small amount of overlying subfascial fluid ⇨. In the right clinical context, these US features are compatible with resolving diabetic myonecrosis.*

KEY FACTS

TERMINOLOGY

- **Contusion**: Direct blunt compressive trauma to muscle without definable tear
- **Tear**: Discontinuity of muscle fibers typically at myofascial or myotendinous junction
- **Delayed-onset muscle soreness (DOMS)**: Overuse → muscle edema without definable tear
  - Pain peaking 1-3 days after overuse
- **Hernia**: Focal protrusion of part of muscle through fascial defect

IMAGING

- **Muscle contusion**
  - Ill-defined hyperechogenicity of muscle or muscles
  - No discrete muscle tear (fiber discontinuity)
- **Muscle tear**
  - Discontinuity ± retraction of muscle fibers
  - Tear filled with hematoma or fluid
  - ± mild muscle edema or hemorrhage
  - Estimate percentage of muscle fibers torn
  - Grade 1: < 5% of muscle fibers torn
  - Grade 2: 5-99% of muscle fibers torn
  - Grade 3: 100% of muscle fibers torn
- **Muscle hematoma**
  - Typically associated with grade 2 or 3 tears
  - Appearance varies with duration of hematoma, severity, & location
- **DOMS**
  - Affected muscle may be normal or diffusely hyperechoic due to diffuse muscle edema
- **Muscle hernia**
  - Focal protrusion of muscle through fascial defect
  - Accentuated by muscle contraction or exercise

CLINICAL ISSUES

- Most muscle injuries improve with conservative treatment
- Injury grade correlates well with return-to-play (RTP) time
- Functional recovery precedes structural recovery

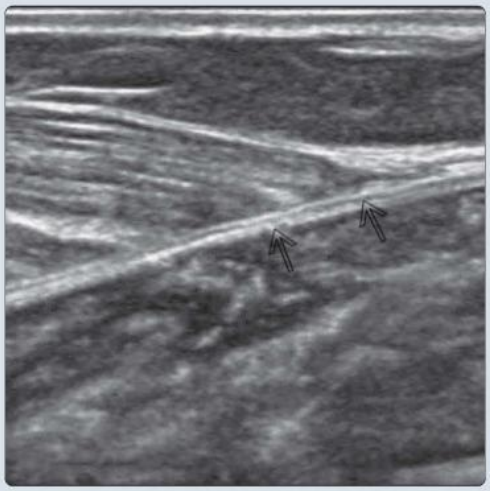

(Left) *Longitudinal US of an unaffected leg shows normal sharp angulation of the myotendinous and myofascial junction ⇨ at the distal end of the medial belly of the gastrocnemius muscle. This is the most common site of calf muscle tear.* **(Right)** *Clinical photograph shows a patient with a recent calf muscle tear. There is moderate calf swelling and bruising ⇨ with more intense, gravity-related bruising at the ankle region ⇨.*

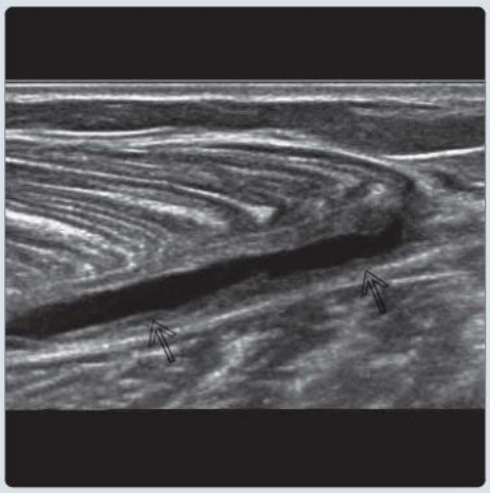

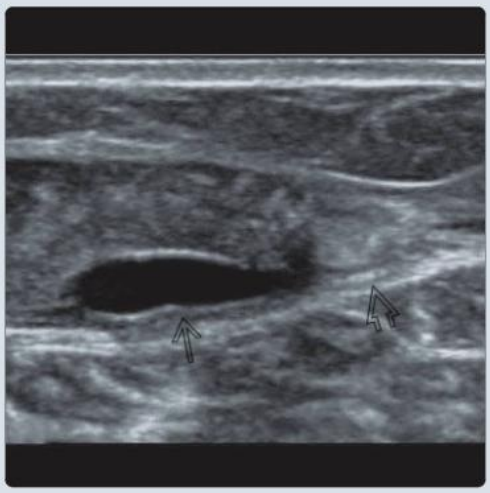

(Left) *Longitudinal US of a symptomatic leg shows a myofascial junction tear ⇨ at the distal end of the medial belly of the gastrocnemius muscle. The medium-severity tear is filled with fluid. No muscle retraction is present.* **(Right)** *Transverse US of the same area shows the moderate-severity myofascial tear ⇨. Overall, ~ 15% of the cross-sectional area (CSA) of the muscle insertion is torn. The plantaris tendon ⇨ is normal.*

TERMINOLOGY

Synonyms

- Muscle tear, muscle contusion, muscle hematoma, muscle strain, "pulled muscle," "tennis leg," delayed-onset muscle soreness (DOMS), muscle hernia

Definitions

- Tear: Discontinuity of muscle fibers typically at myofascial or myotendinous junction
- Contusion: Direct blunt compressive trauma to muscle without definable tear
- DOMS: Overuse → muscle edema without definable tear
- Hernia: Focal protrusion of part of muscle through fascia

IMAGING

General Features

- Best diagnostic clue
  - Muscle tear; hypoechoic area within muscle or at myotendinous/myofascial junction
- Location
  - Usually affects lower limb muscles (gastrocnemius > rectus femoris, adductor longus, biceps femoris, semimembranosus, semitendinosus, & soleus muscles)
  - Typically at myofascial junction within muscle or myotendinous junction
    - These are weak areas at interface between tissues of different elastic property
- Morphology
  - Muscle fiber discontinuity with hemorrhage & edema

MR Findings

- T1WI
  - Muscle tears
    - Low to intermediate signal intensity hemorrhage
    - ± hyperintense subacute hemorrhage
    - Peripheral hypointense hemosiderin
    - Loss of normal muscle striations ± retracted belly
  - DOMS
    - Muscle swelling of intermediate signal intensity
  - Muscle hernia
    - Focal defect in investing fascia ± muscle protrusion
- T2WI
  - Muscle tear
    - Hyperintense edema in affected muscle
    - Inhomogeneous signal intensity mass in midsubstance tears due to hemorrhage & edema
    - Perimuscular hyperintense fluid
  - DOMS
    - Diffuse homogeneous hyperintensity

Ultrasonographic Findings

- **Muscle contusion**
  - Direct (extrinsic) injury
  - Ill-defined hyperechogenicity of muscle(s) due to edema ± hemorrhage
  - No discrete muscle tear (fiber discontinuity)
  - Hyperemia during reparative phase
- **Muscle tear**
  - Usually indirect (intrinsic) injury
    - Typically at myofascial or myotendinous junction
  - Grade 1 injury (Peetrons 2002, US-based)
    - Either no visible tear or small tear involving few muscle fibers (< 5% of muscle fibers torn)
    - Muscle either normal or shows focal or diffuse hyperechogenicity
  - Grade 2 injury
    - Partial (5-99%) muscle fibers torn
    - Discontinuity (tear) ± retraction of muscle fibers
      - Tear filled with hematoma or fluid
  - Grade 3 injury
    - Complete tear of muscle at myotendinous junction usually with retraction
- **Healing muscle tear**
  - Bridging scar tissue or regenerated muscle at site of tear
  - Clearer definition of injured area
  - Localized hyperemia, disappears when healing complete
- **Muscle hematoma**
  - Typically associated with grade 2 or 3 tears
  - Appearance varies with duration, severity & location of hematoma
  - First 48 hours, hypoechoic → more hyperechoic as hematoma solidifies ± acoustic enhancement
  - After 72 hours, hematoma can start to liquefy
    - Anechoic areas, starting centrally in hematoma
  - Marginal hyperemia during reparative phase (reparative fibrovascular granulation tissue)
    - Peripheral granulation tissue usually hyperechoic & hyperemic
    - Granulation tissue is more hyperechoic than fresh hematoma
  - Chronic → myositis ossificans
    - Hyperechoic rim with variable acoustic shadowing
    - Identifiable on US ~ 2 weeks earlier than XR
- **DOMS**
  - Affected muscle may be normal or, if severe, diffusely hyperechoic due to diffuse muscle edema
  - No discernible muscle tear
- **Muscle hernia**
  - Focal protrusion of muscle fibers through fascial defect
  - Accentuated by muscle contraction or exercise

Imaging Recommendations

- Best imaging tool
  - Most muscle tears are accessible on US
    - MR preferable in pelvitrochanteric muscles, adductor or hamstring insertions as less accessible with US
  - MR probably has edge over US in classifying & grading muscle tears
- Protocol advice
  - Examine with muscle at rest & compare with contralateral side
  - Examine all tears in 2 planes
  - Measure dimensions of tear & estimate percentage of muscle or myotendinous junction torn
    - US during muscle contraction can help accentuate muscle retraction
  - Gastrocnemius muscle tear: Look closely at distal end of myotendinous junction medial belly
    - Check for integrity of plantaris tendon
      - Seen medial to Achilles tendon & deep to medial belly gastrocnemius muscle

- Muscle hernia: Reexamine after exercise if hernia is not apparent on initial examination
  - Most commonly involves tibialis anterior muscle

DIFFERENTIAL DIAGNOSIS

Tendon Tear

- Quadriceps, patellar, or Achilles tendon

Ruptured Baker Cyst

- May mimic medial gastrocnemius tear with acute calf pain & swelling
- Fluid along fascial planes > > edema in muscles
- "Speech bubble" configuration with neck between semimembranosus tendon & medial gastrocnemius head

Soft Tissue Tumor

- May mimic muscle tear with palpable mass
- Healing muscle tears have recognizable background muscle architecture & less mass effect
- Peripheral hyperemia of healing tear as opposed to central hyperemia of tumor

PATHOLOGY

General Features

- Muscle tear
  - Extrinsic tear: Direct external trauma
    - Commonly affects rectus femoris
  - Intrinsic tear: Forced contraction of elongated muscle
    - Usually located at myofascial junction
    - Most common type of muscle injury
- DOMS: Reversible structural damage at cellular level due to unaccustomed severe repetitive exertion

Staging, Grading, & Classification

- Several other grading/classification systems (MR based)
  - **British Athletics Muscle Injury Classification (2014)**
    - Grade 0a: Focal muscle pain with normal MR
    - Grade 0b: Generalized muscle pain with MR being normal or showing muscle edema
    - Grades 1-3: High STIR signal at site of injury, subclassified into a) myofascial, b) myotendinous/muscle, & c) tendinous
      - Grade 1: < 10% cross section or longitudinal length < 5 cm with < 1 cm fibre disruption
      - Grade 2: 10-50% cross section or longitudinal length 5-15 cm with < 5 cm fibre disruption
      - Grade 3: > 50% cross section or longitudinal length > 15 cm with > 5 cm fibre disruption
    - Grade 4: Complete tear
  - **Olympic Park Grading System for Calf Injury (2018)**
    - Grade 0: Muscle edema adjacent to intact connective tissue (tendon/aponeurosis/epimysium)
    - Grade 1: Myofibril detachment from connective tissue
    - Grade 2: Connective tissue signal change, delamination or partial tear
    - Grade 3: Connective tissue failure/retraction

CLINICAL ISSUES

Presentation

- Most common signs/symptoms
  - Tear & hematoma: Sudden onset of limb pain at time of exertion; "pop" sensation
    - Localized swelling & tenderness ± discrete mass
    - Complete rupture: Palpable defect with retracted mass
  - DOMS: Swelling & pain beginning 1-2 days after exercise, peaking at 3 days & resolving by day 7
  - Muscle hernia: Chronic pinpoint pain & tenderness
    - Usually has well-developed musculature

Demographics

- Age
  - Young to middle-aged athlete
    - In children, apophyseal fractures predominate
    - In older patients, tendon tears predominate
- Epidemiology
  - Muscle injury: 30% of sports-related injuries
  - Risk factors
    - Eccentric contraction force
    - Muscles that cross > 1 joint
    - Muscles that comprise mainly type II fibers

Natural History & Prognosis

- Most muscle injuries improve with conservative treatment
- Injury grade correlates well with return-to-play (RTP) time
- Longitudinal extent of tear considered prognostic indicator for RTP time
- Shorter recovery time for lower-grade injuries; 6-8 weeks or longer recovery time for higher-grade injuries
- Shorter RTP time for myofascial injury than tendon injury
- Hamstring tears, rectus femoris central tendon tears & retears at site of previous tear tend to take longer to heal
- Functional recovery precedes structural recovery

Treatment

- Conservative
  - Rest, ice, compression, elevation
  - Physical therapy: Stretching & exercises
  - Nonsteroidal antiinflammatory drugs
  - Gradual increase in activity
- Surgery
  - Decompression for compartment syndrome
  - Hematoma evacuation
  - Suturing of some complete muscle tears
  - Repair of investing fascia defect (if muscle hernia)
  - ± resection of fibrotic mass

DIAGNOSTIC CHECKLIST

Consider

- Muscle hernia in any muscular patient with pinpoint muscle pain & tenderness

Image Interpretation Pearls

- Pay particular attention to distal myofascial junction of medial head of gastrocnemius for small tears

SELECTED REFERENCES

1. Heiss R et al: Imaging of muscle injuries in soccer. Skeletal Radiol. ePub, 2023
2. Ossola C et al: Role of ultrasound and magnetic resonance imaging in the prognosis and classification of muscle injuries in professional football players: correlation between imaging and return to sport time. Radiol Med. 126(11):1460-7, 2021

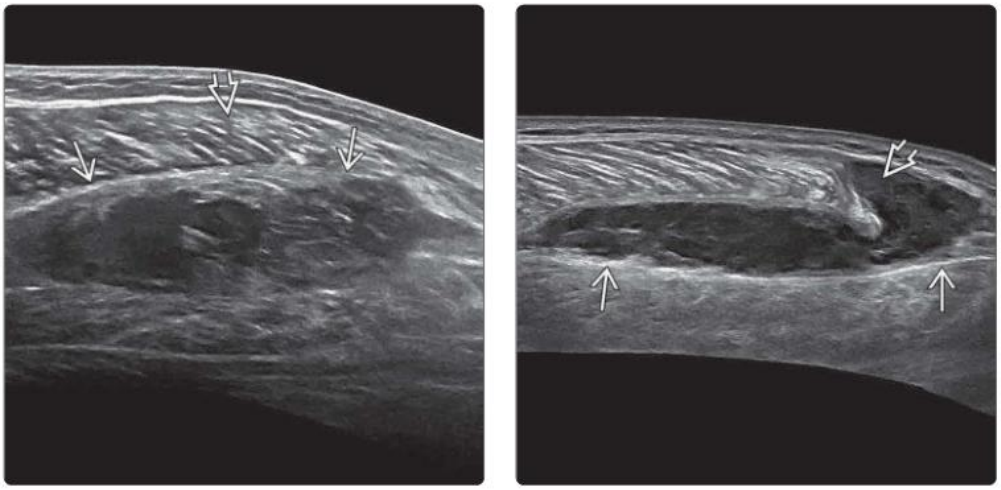

(Left) *Longitudinal US shows a myofascial tear ⇨ at the distal end of the medial gastrocnemius muscle ⇨. The tear is filled with hematoma. No muscle retraction is present.* **(Right)** *Longitudinal extended FOV US shows the full extent of large myofascial and myotendinous junction tear of the medial belly of the gastrocnemius muscle ⇨, which is also filled with hematoma. Overall, ~ 70% of the CSA of the insertion of the medial belly of gastrocnemius muscle is torn with moderate muscle retraction ⇨.*

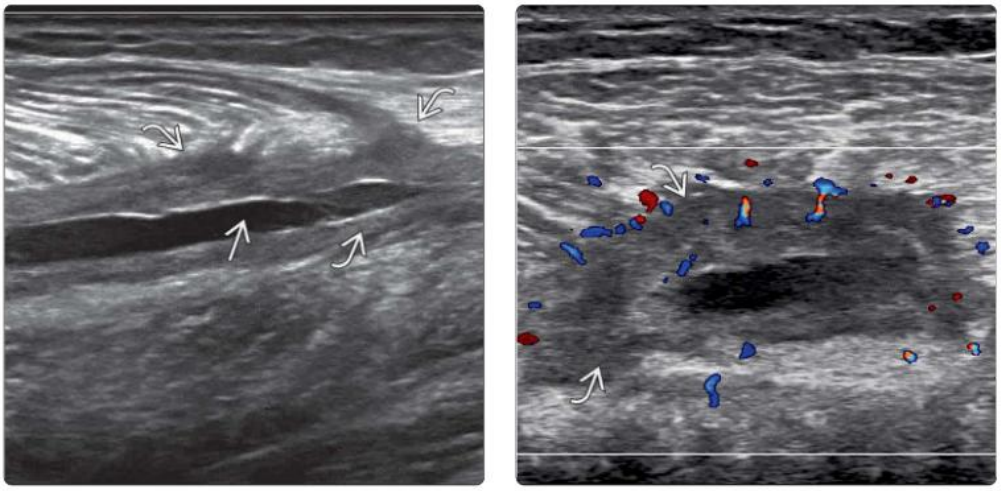

(Left) *Longitudinal US shows a healing medial gastrocnemius myofascial tear ⇨ with granulation tissue formation ⇨. This will eventually form fibrosis and bridge the tear.* **(Right)** *Transverse color Doppler US of the same healing gastrocnemius myofascial tear shows hyperaemia in the granulation tissue ⇨. Features of healing tear can persist for many months following injury and do not necessarily prevent return to play.*

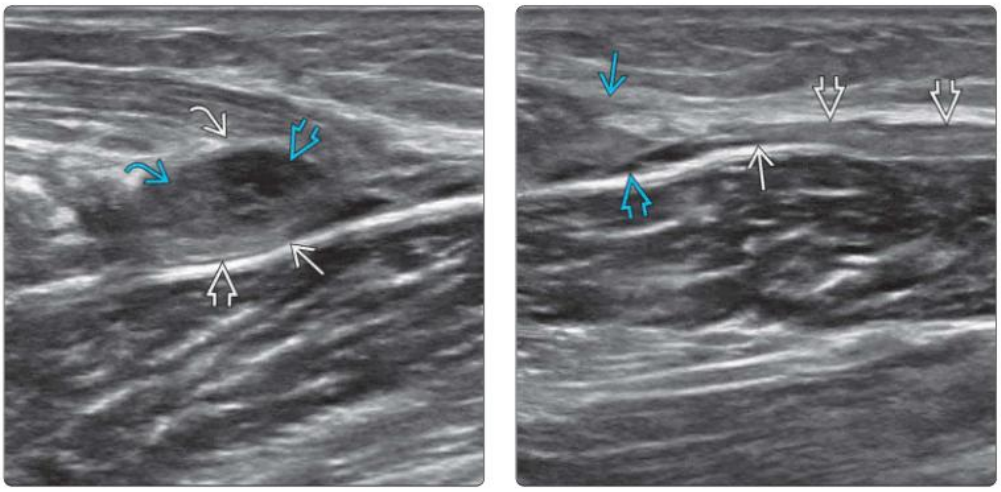

(Left) *Longitudinal US shows a medial gastrocnemius myofascial tear ⇨ filled with echogenic hematoma ⇨ and fluid ⇨. The subjacent plantaris tendon ⇨ is torn with a retracted proximal stump ⇨.* **(Right)** *Longitudinal US further distally along the calf in the same patient shows the distal stump ⇨ of the plantaris tendon ⇨ distal to the level of the medial gastrocnemius myotendinous junction ⇨. A small amount of fluid fills the gap ⇨ between the proximal and distal stumps of the torn plantaris tendon.*

(Left) *Transverse US in a patient with recent blunt trauma to the shin shows a medium-sized area of muscle contusion* ➡ *with echogenic hemorrhage and edema at the proximal aspect of the tibialis anterior muscle. No discrete muscle tear is evident.* **(Right)** *Transverse color Doppler US of the same area shows mild hyperemia. This is a grade 1 muscle injury.*

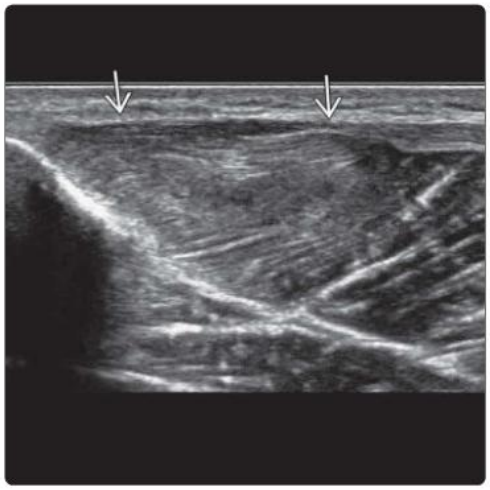

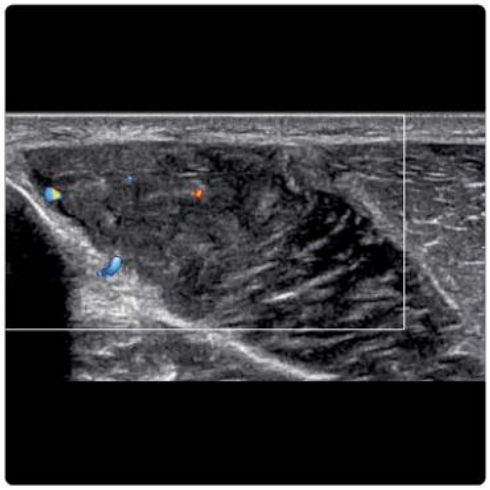

(Left) *Longitudinal US in a patient with recent blunt trauma to lateral hip region shows a medium-sized area of muscle contusion* ➡ *with edema at the deeper part of the gluteus maximus muscle overlying the posterior edge of the greater trochanter* ➡. **(Right)** *There is a small tear* ➡ *within the contused area of the muscle. No hypervascularity is present (not shown). This is consistent with a grade 1 muscle tear.*

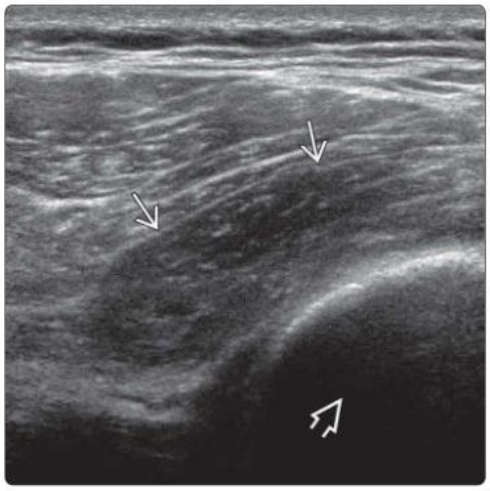

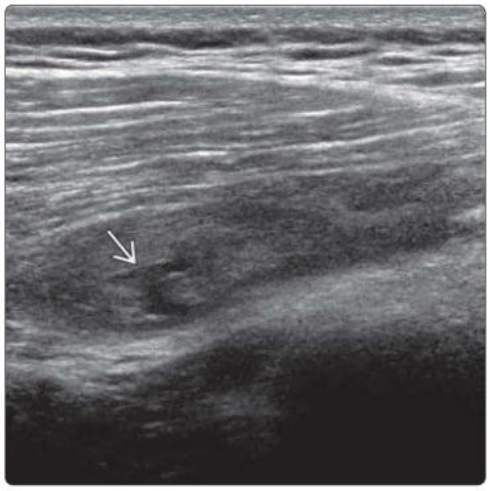

(Left) *Transverse US in an older patient with blunt thigh trauma and bruising shows a small hematoma* ➡ *in the proximal medial portion of the tensor fascia lata muscle* ➡ *at the anterolateral aspect of the upper thigh. There is adjacent muscle fiber discontinuity due to a small grade 1 muscle tear* ➡. **(Right)** *Transverse US close to the same location shows a partial tear* ➡ *involving only ~ 5% of the tensor fascia lata muscle cross-sectional area (CSA).*

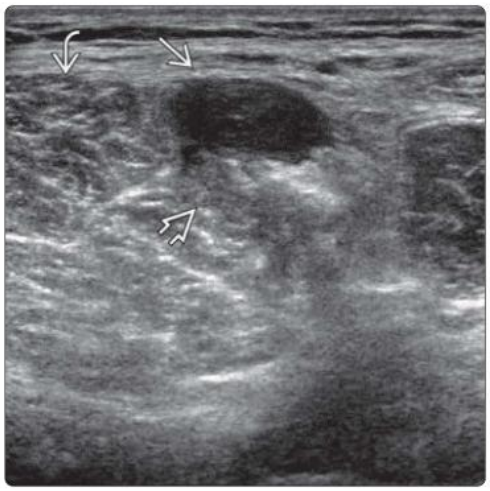

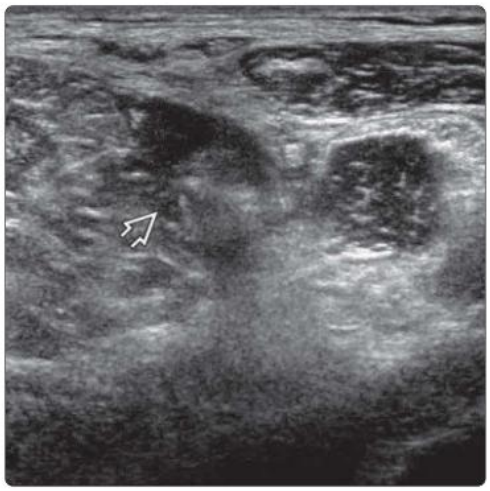

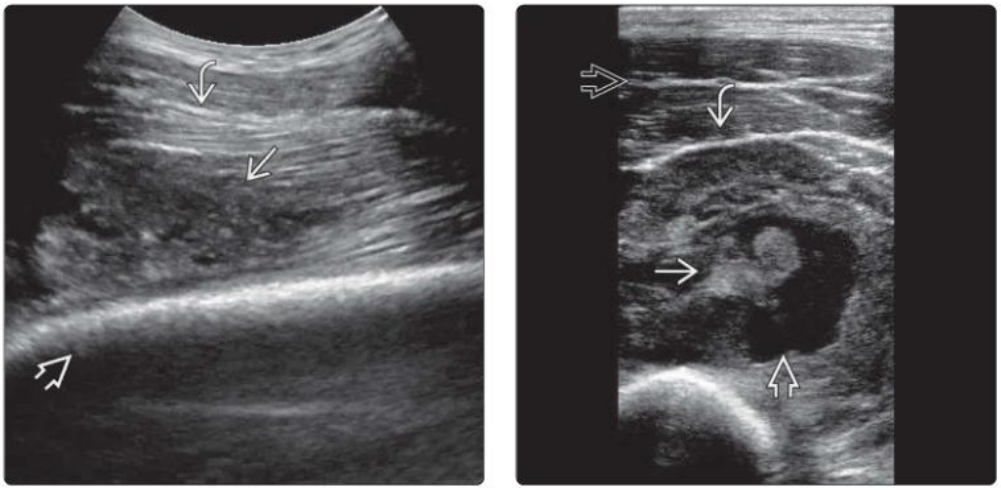

(Left) *Longitudinal US in a patient with recent leg trauma shows a severe tear ⇨ at the upper to midportion of the vastus intermedius muscle ⇨. This grade 2 tear occupied ~ 70% of the muscle cross-sectional area. The femoral shaft ⇨ is normal.* **(Right)** *Transverse US of the same area shows torn ⇨ vastus intermedius muscle fibers ⇨ with a large intramuscular hematoma ⇨. The overlying rectus femoris muscle ⇨ is normal.*

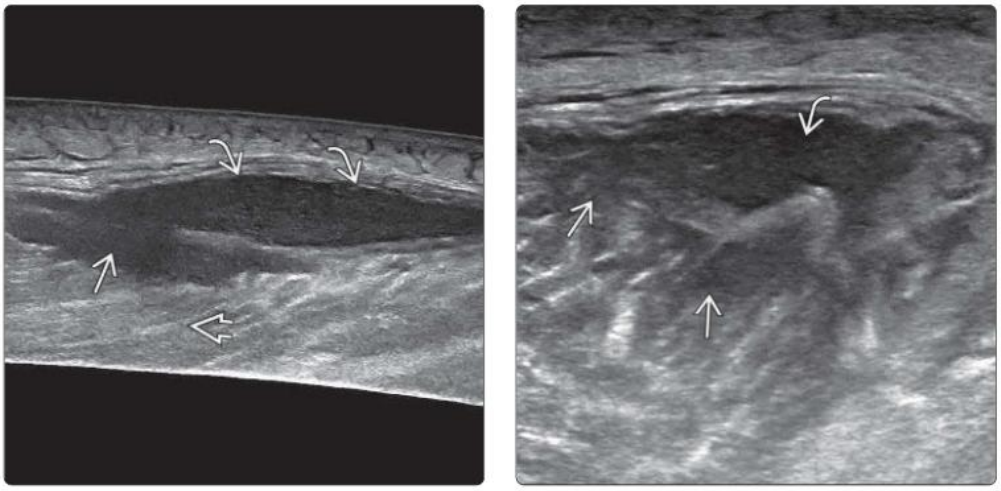

(Left) *Longitudinal extended FOV US of the posterolateral thigh shows a muscle tear ⇨ of the biceps femoris long head ⇨ after being hit by a heavy trolley. The tear extends inferiorly as a myofascial tear ⇨, filled with a hematoma.* **(Right)** *Transverse US shows irregularity of the muscle fibers ⇨ of the biceps femoris long head, corresponding to the tear. The tear involves ~ 40% of the CSA of the muscle, consistent with a grade 2 tear. The tear is filled with echogenic blood ⇨.*

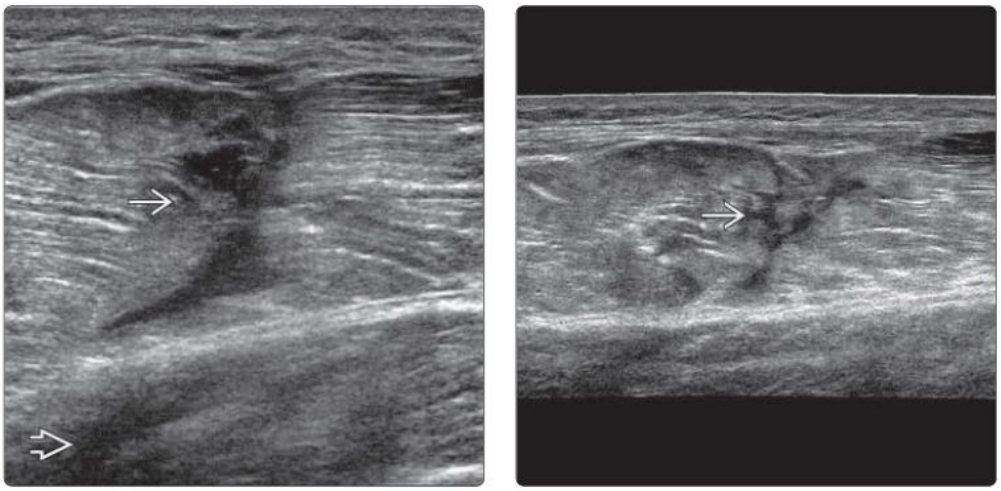

(Left) *Longitudinal US of the thigh in a patient recently kicked by a horse shows a full-thickness tear ⇨ in the vastus lateralis muscle of the distal thigh. Overall, 90% of the fibers were torn, consistent with a severe grade 2 tear. The tear was associated with a surrounding hematoma and a moderate-sized knee joint effusion (not shown). The adjacent vastus intermedius muscle ⇨ is normal.* **(Right)** *Longitudinal extended FOV US shows the same full-thickness tear ⇨ of the vastus lateralis muscle. There is no muscle retraction.*

(Left) *Longitudinal extended FOV US shows severe retraction of the rectus femoris muscle due to a complete (grade 3) tear at the quadriceps tendon junction. The underlying vastus muscles were not torn.* **(Right)** *Longitudinal US in the same patient shows a clapper bell configuration of the completely torn, retracted rectus femoris muscle. The underlying vastus intermedius muscle is not torn.*

(Left) *Transverse US of the same rectus femoris muscle tear shows an amorphous appearance of a torn rectus femoris muscle around the central muscle tendon compared to the adjacent normal vastus muscle.* **(Right)** *Sagittal CT of the knee in a patient after fall injury for suspected occult patella fracture shows a large hematoma of the suprapatellar region along the quadriceps myotendinous junction and tendon. The patella is normal with no fracture.*

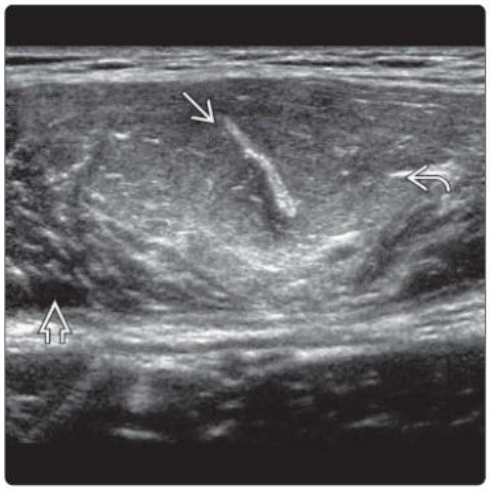

(Left) *Longitudinal US more proximally than previous CT shows a myofascial tear of the rectus femoris muscle with irregularity of the superficial muscle fibers and epimysium disruption.* **(Right)** *Longitudinal extended FOV US more distally of suprapatellar region shows a large hematoma filling the rectus femoris myofascial tear, with hematoma tracking down to the suprapatellar region, corresponding to CT findings. The deep fibers of the quadriceps tendon are intact, and the patella is normal.*

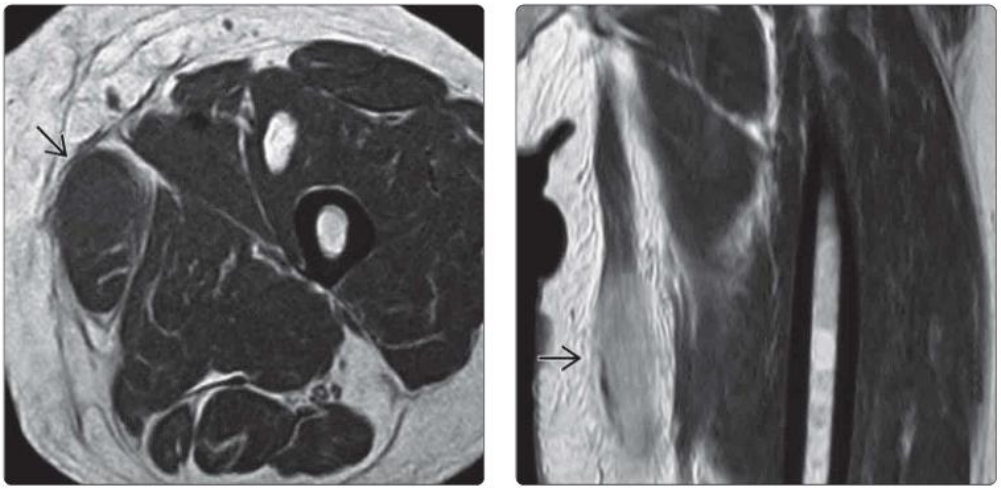

(Left) *Axial T1 MR in a middle-aged patient with vague thigh trauma 2 months earlier shows localized isointense swelling ⇨ in the anterior aspect of the gracilis muscle. The remaining thigh musculature is normal.* **(Right)** *Coronal T2 MR of the same lesion shows diffuse muscle edema and swelling within the middle 1/3 of the gracilis muscle ⇨.*

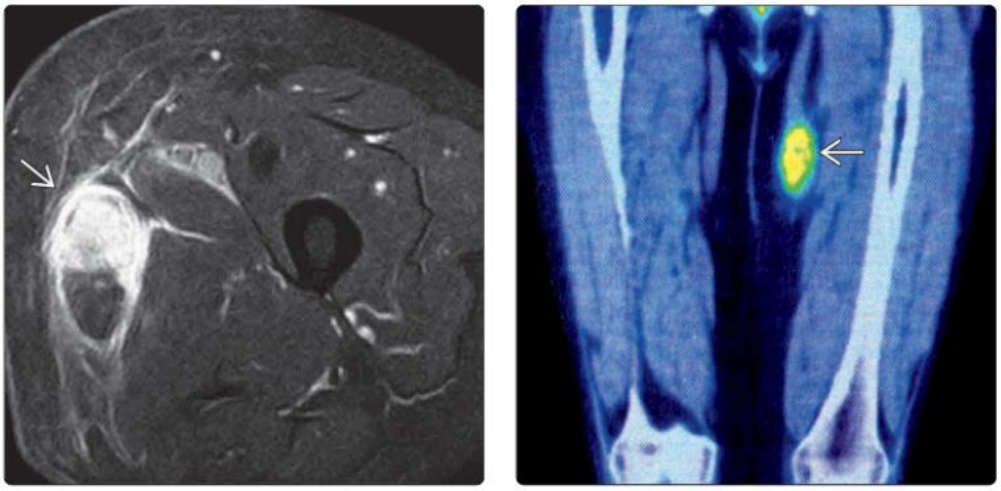

(Left) *Axial T1 C+ FS MR of the same lesion shows intense contrast enhancement ➡ in and around the affected area of the gracilis muscle.* **(Right)** *Coronal reconstructed FDG PET/CT of the same lesion shows increased metabolic activity (standardized uptake value 4.4) in the swollen gracilis muscle area ➡. Based on the MR and PET/CT appearances, this was reported as a soft tissue sarcoma, and a US-guided biopsy was advised.*

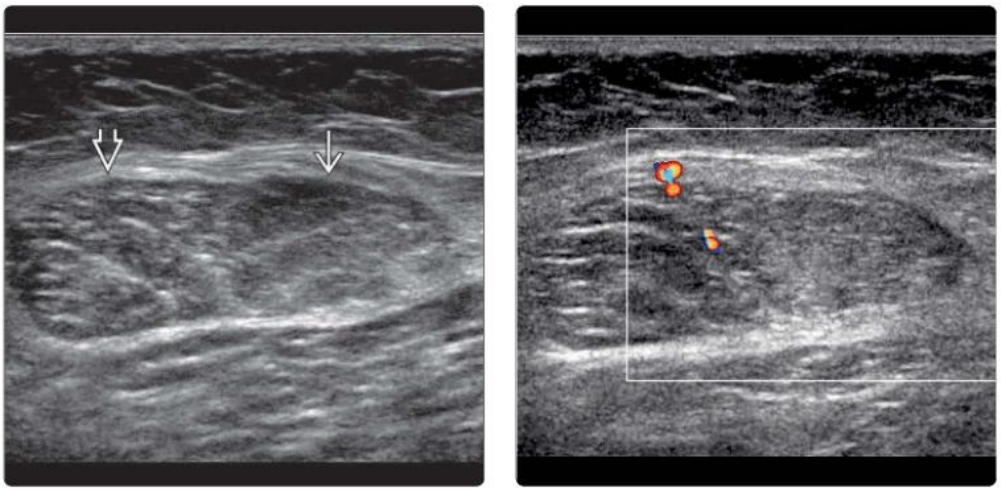

(Left) *Transverse US of the same lesion shows moderate swelling confined to the anterior part ➡ of the gracilis muscle ⇨. The background muscle architecture is preserved. This favored a healing muscle tear with no evidence of tumor.* **(Right)** *Transverse color Doppler US of the same lesion shows mild perilesional hyperemia. In view of the MR and PET findings, a US-guided biopsy for histology was performed, which confirmed a healing muscle tear. US is helpful when other imaging is ambiguous.*

(Left) *Transverse US of the distal thigh shows a healing partial tear ➡ of the long head of the biceps femoris muscle ➡ just proximal to the myotendinous junction. This involves 30% of the CSA of the long head. There is fibrosis and granulation tissue filling the tear.* **(Right)** *Longitudinal US of the posterior midthigh shows a healing tear ➡ of the semimembranosus muscle. No calcification or muscle retraction is present. There was mild marginal hyperemia. The time since injury also helps in differentiating fibrosis from hematoma.*

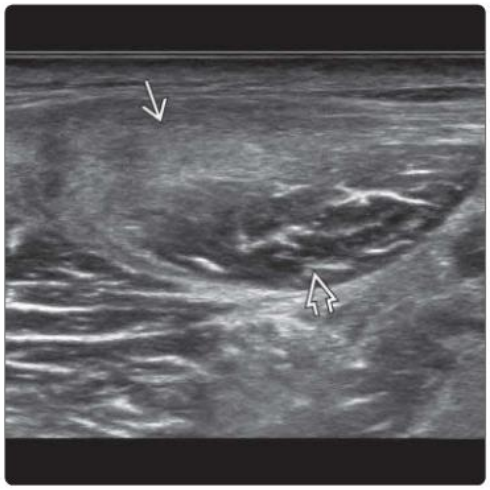

(Left) *Transverse US of the thigh in a patient 4 weeks after severe blunt thigh trauma shows a partially calcified ➡ hematoma ➡ deep in the rectus femoris muscle and alongside the femoral shaft ⇄.* **(Right)** *Lateral radiograph in the same patient shows the partially ossified hematoma ➡ surrounding the proximal femoral shaft, consistent with posttraumatic myositis ossificans (MO).*

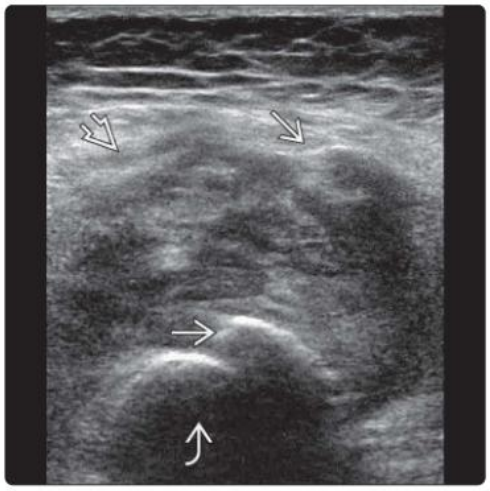

(Left) *Transverse US of the thigh in a patient 10 weeks after blunt thigh trauma shows myositis ossificans ➡ with an oval-shaped, hypoechoic mass within the slightly edematous, hyperechoic vastus lateralis muscle ➡ alongside the femoral shaft ⇄. There is quite mature peripheral ossification ⇄ present.* **(Right)** *Color Doppler US of the same area shows mild marginal hyperemia. Maturation of MO can be followed with US.*

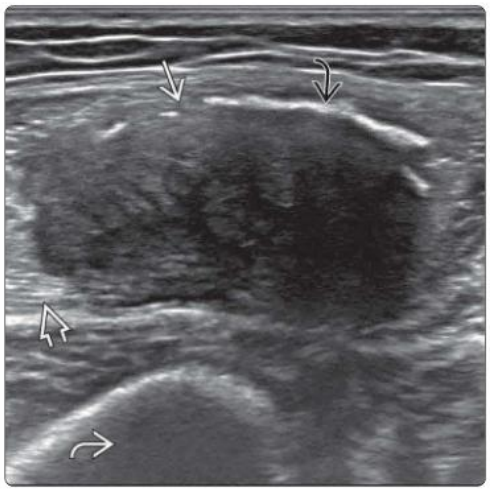

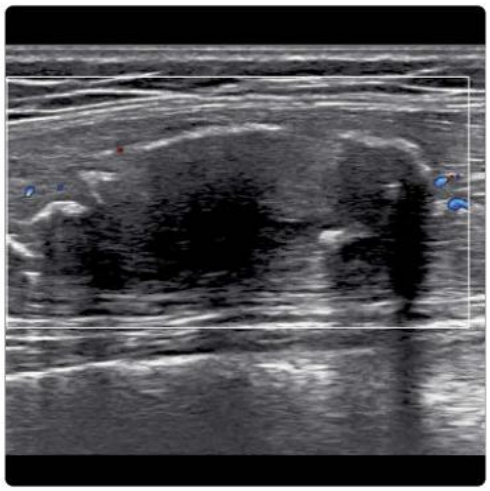

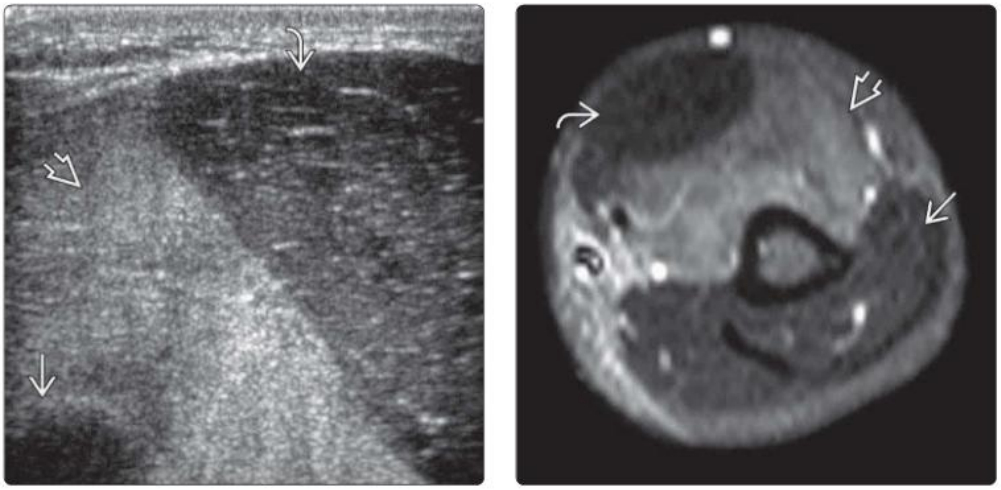

(Left) *Transverse US in a patient with unaccustomed overuse rowing injury and pain onset 1 day later shows severe edema of the brachialis muscle ⇨ consistent with delayed-onset muscle soreness (DOMS). The overlying biceps muscle ⇨ and the humeral shaft ⇨ are normal.* **(Right)** *Axial T2 FS MR in the same patient shows severe edema of the brachialis muscle ⇨, consistent with DOMS, which is a cellular-related muscle injury. The biceps ⇨ and triceps muscles ⇨ are normal.*

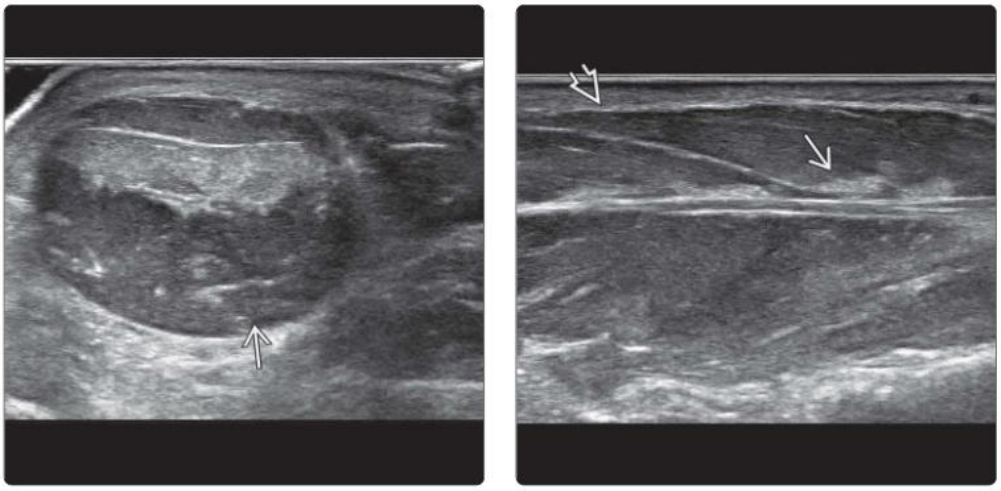

(Left) *Transverse US in a patient with pes planus and severe overuse trekking injury to the foot 1 day prior shows severe diffuse swelling of the abductor hallucis longus muscle ⇨, which is swollen to 3x the normal size. Moderate diffuse muscle hyperemia was present. The appearances are due to DOMS.* **(Right)** *Longitudinal US of the same area shows how muscle architecture is maintained ⇨. The echogenic area ⇨ alongside the swollen central tendon is due to intense muscle edema ± hemorrhage.*

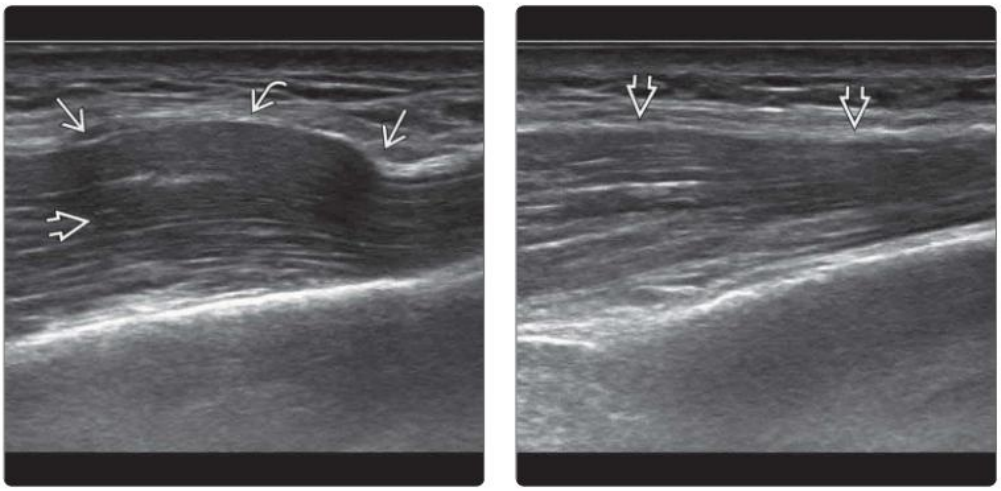

(Left) *Longitudinal US over the lower shin shows focal bulging ⇨ of the extensor digitorum longus muscle ⇨, corresponding to a clinically palpated swelling. The bulging exacerbated on dorsiflexion of the toes. This is due to an underlying fascial deficiency ⇨ with resultant muscle herniation.* **(Right)** *Longitudinal US of the same site shows spontaneous reduction of the extensor digitorum longus muscle ⇨ herniation at rest. The fascial defect and muscle herniation are both not obvious when the muscle is relaxed.*

KEY FACTS

IMAGING

- Hematoma: Acute
  - Quite well-defined heterogeneous mass ± echogenic pseudosolid appearance
  - Multilaminated whorled appearance
  - Anechoic cystic areas
  - Echogenic foci due to gas locules
  - Surrounding soft tissue edema
  - Mild surrounding hyperemia
  - No internal hyperemia
  - Underlying cause of hematoma, such as muscle tear or vascular malformation, may be apparent
- Hematoma: Subacute & chronic
  - More well-defined margin ± distinct capsule
  - Reduces in size on serial examination
  - Hypoechoic fluid areas due to separation of serum from cellular elements in process of liquefaction
  - Mild marginal hyperemia on color Doppler imaging
  - ± more central hyperemia if of long duration
- Organizing hematoma
  - Encapsulated, increasing size due to recurrent bleeding, intrinsic hyperemia
  - May simulate soft tissue tumor
  - May need biopsy to distinguish
- Seroma
  - Often close to site of surgery (chest wall, abdomen, groin)
  - Echo-poor or anechoic with strong posterior acoustic enhancement
  - Usually no wall or barely discernible wall
- Lymphocele
  - Close to site of vascular surgery
  - Very similar US appearances to seroma
- Best imaging tool: Serial follow-up helpful to confirm hematoma & to check for underlying cause
- Protocol advice: Relate to clinical setting

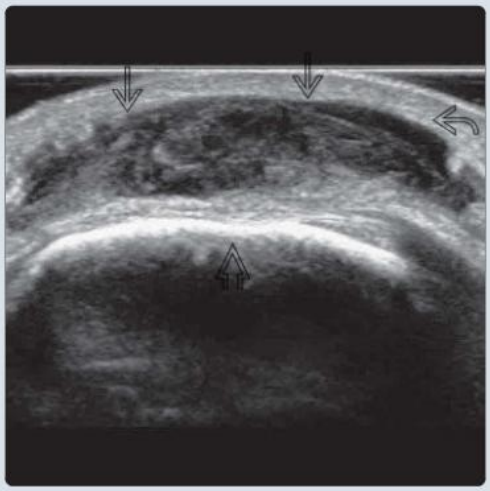

(Left) *Clinical photograph shows a patient with an acute knee injury associated with prepatellar soft tissue swelling, abrasions, and bruises.* **(Right)** *Transverse US in the same patient shows a medium-sized acute subcutaneous hematoma ⇨ anterior to the patella ⇨. The hematoma shows a heterogeneous, hypoechoic, pseudosolid appearance. A more fluid component is present at the superficial aspect of the hematoma ⇨.*

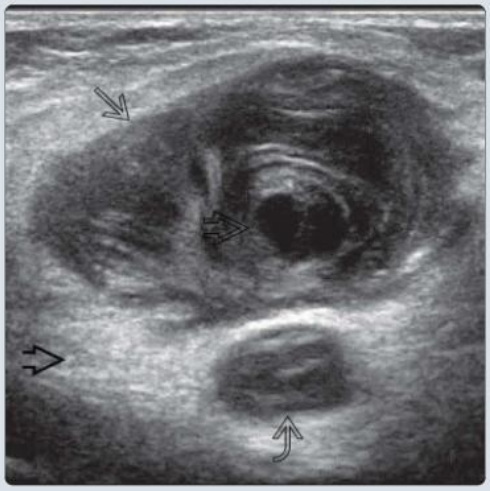

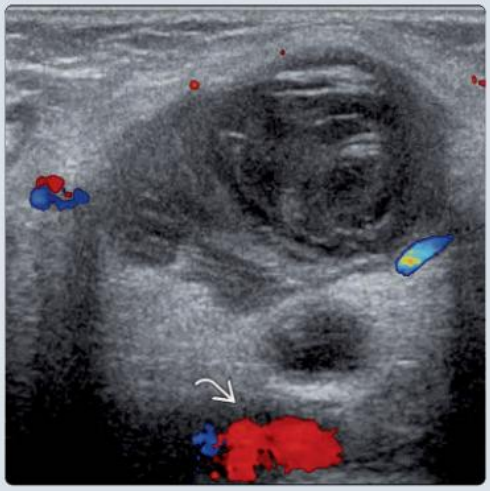

(Left) *Transverse US of groin 2 days after arterial puncture shows well-defined, oval-shaped hematoma ⇨ with typical multilaminated whorled appearance, posterior enhancement, & central anechoic ⇨ fluid component. Posteriorly, a smaller hematoma ⇨ & moderate degree of surrounding edema ⇨ is present.* **(Right)** *Transverse color Doppler US shows no vascularity within the mass, suggesting hematoma rather than pseudoaneurysm. The femoral artery is located posteriorly ⇨.*

TERMINOLOGY

Definitions

- Hematoma: Focal collection of blood lying outside of blood vessel & no communication
- Seroma: Serous fluid collection within soft tissues
- Lymphocele: Collection of lymphatic fluid due to leakage from lymphatics

IMAGING

General Features

- Best diagnostic clue
  - Hematoma: Largely solid-looking echogenic mass with small cystic areas & no intrinsic hyperemia
    - Often history of trauma/bleeding tendency/on anticoagulant
  - Seroma: Anechoic fluid collection ± internal debris; minimal or no wall hyperemia
    - Nearby surgery
  - Lymphocele: Anechoic fluid collection; no internal debris; no wall hyperemia
    - Nearby vascular surgery
    - Difficult to distinguish seroma from lymphocele
- Location
  - Usually at site of trauma or surgery
- Size
  - Variable but usually large in buttock or thigh

Radiographic Findings

- Radiography
  - Mildly hyperdense soft tissue opacity & swelling
    - ± calcification in old hematoma

MR Findings

- T1WI & T2WI
  - Hematoma
    - Acute: Isointense on T1WI; variable hyper- to hypointense on T2WI
    - Subacute/chronic: Hyperintense on T1WI & T2WI
    - T2* GRE: Hemosiderin deposition with susceptibility blooming artifact
  - Seroma/lymphocele
    - Fluid-like collection near site of surgery

Ultrasonographic Findings

- Internal echogenicity depends on degree of blood coagulation, liquefaction, & organization
- Hematoma
  - Appearances depend on chronicity
  - Acute: Fairly well-defined heterogeneous mass in subcutaneous or muscle layer
    - Echogenic pseudosolid appearance
    - Multilaminated whorled appearance
    - Anechoic cystic components
    - Echogenic foci due to gas locules
    - Surrounding soft tissue edema
    - Usually no surrounding hyperemia in hyperacute stage; develops over few days; no intrinsic hyperemia
    - Mild acoustic enhancement
    - Underlying cause of hematoma, such as muscle tear or vascular malformation, may be apparent
  - Subacute & chronic: Well defined, variable echogenicity depending on liquefaction & degree of reparative organization
    - More well-defined margin ± distinct capsule
    - Reduces in size on serial examination
    - Hypoechoic fluid areas due to separation of serum from cellular elements during liquefaction process
    - Mild marginal hyperemia ± more central hyperemia if hematoma of long duration; may remain avascular
    - ± marginal calcification
    - Acoustic enhancement if liquefaction; acoustic shadowing if calcification or fibrosis
    - Underlying cause may become more apparent
  - Organizing hematoma
    - May simulate soft tissue mass; may require biopsy for confirmation
    - Encapsulated, increasing in size due to recurrent internal bleeding, internal hyperemia
    - Neovascularization, although present, may not be shown on color Doppler imaging due to small size of neovascular vessels
  - Hemophiliac pseudotumor
    - Organizing hematoma of hemophilia; affecting 1-2% of all hemophiliacs
    - Thick-walled hematoma with internal vascularity
    - Can grow due to repeated bleeding
    - Mass effect with bone scalloping
    - Usually in soft tissues but can be subperiosteal or intraosseous
  - Rectus sheath hematoma
    - Above arcuate line
      - Ovoid in shape with long axis superoinferior
      - Localized to one rectus muscle, does not cross midline
      - Expansile in appearance, mimicking soft tissue tumor
    - Below arcuate line
      - No linea alba, so can cross midline; pad-like with transverse long axis
- Seroma
  - Often close to site of surgery (chest wall, abdomen, groin)
  - US appearances vary with chronicity & content of seroma
  - Echo-poor with strong posterior acoustic enhancement
  - Acute or subacute seroma
    - Usually anechoic because of sterile fluid content
    - Usually no wall or barely discernible wall
    - No adjacent soft tissue edema or hyperemia
    - No internal echogenic component unless complicated by hemorrhage
    - US-guided aspiration yields clear or pale straw-colored fluid
  - Chronic seroma
    - Increasing echogenicity of content ± fibrous septa
    - Increasing wall thickness & mild hyperemia
    - Difficult to distinguish from chronic liquefied hematoma
- Lymphocele
  - Close to site of vascular surgery
  - Very similar US appearances to seroma

  - Etiology of seroma & lymphocele is different
  - US-guided aspiration yields clear or pale straw-colored fluid
    - Laboratory analysis yields slight increase in lymphocyte count
    - Chylous fluid (↑ triglyceride & protein count) is feature of high retroperitoneal & thoracic lymphoceles only

Imaging Recommendations

- Best imaging tool
  - US can make distinction between hematoma & seroma/lymphocele
  - Serial follow-up helpful to confirm hematoma & to check for underlying cause
    - MR may provide additional help in assessing underlying injury or vascular malformation
  - Percutaneous aspiration can help distinguish seroma/lymphocele & low-grade infection (e.g., fungal infection)
    - Increased lymphocyte count in lymphocele
- Protocol advice
  - Correlate closely with clinical setting
  - Always include evaluation with color Doppler
  - Check for signs of any infection
    - Aspirate if doubt exists as to infection

DIFFERENTIAL DIAGNOSIS

Soft Tissue Mass/Sarcoma

- Predominantly solid in appearance
- Usually more internal vascularity
- Enlarging clinically or on serial examination
- No trauma or surgical history

Low-Grade Abscess

- Thicker walls ± internal septation
- Internal debris with variable amount of internal echoes ± gas locules

Aneurysm

- Doppler spectral analysis shows arterial flow communicating with adjacent artery (pseudoaneurysm)

PATHOLOGY

General Features

- Etiology
  - Hematoma: Blood leakage from vasculature
    - Spontaneous hematoma
      - Underlying bleeding tendency (e.g., hemophilia, anticoagulant therapy, aspirin)
      - Unrecognized self trauma, such as severe coughing or sneezing
      - Rectus sheath hematoma due to inferior epigastric vessel constriction during physical exertion
  - Seroma: Serous exudate from serous membrane
    - Generally occurs following surgery to chest, abdomen, or groin

Gross Pathologic & Surgical Features

- Hematoma: Weeks later, more progressive hemolysis & liquefaction
  - Chronic hematoma can have multilaminated concentric appearance due to repeated bleeding
  - Months later, hematoma completely resolves
- Organizing hematoma
  - Central mass of blood, wall of granulation tissue, & dense, fibrous tissue at periphery
  - Expanding nature due to irritant effects of blood products, causing repeated exudation ± bleeding from capillaries

CLINICAL ISSUES

Presentation

- Most common signs/symptoms
  - Localized swelling
  - History of trauma & surgery
  - Hematoma: Bruising or bluish discoloration of skin
- Other signs/symptoms
  - Tenderness, redness, & increased warmth
  - Abnormal clotting profile & thrombocytopenia, if bleeding tendency

Demographics

- Age
  - More common in older patients due to impaired coagulation (hematoma) & increasing likelihood of surgery (seroma/lymphocele)
- Sex
  - Any sex, though rectus sheath hematoma is more common in female patients due to weaker rectus muscles

Natural History & Prognosis

- Hematoma & seroma/lymphocele usually resolve gradually over 2-6 months

Treatment

- Hematoma
  - Rest, ice, compression, & elevation ± analgesia
  - Intravenous fluid resuscitation/blood transfusion
  - Correction of coagulopathy (e.g., stop anticoagulant, infusion of fresh frozen plasma, platelet concentrates)
  - Aspiration if liquefied
  - Embolization of rectus sheath hematoma
- Seroma/lymphocele
  - US-guided aspiration or drainage
  - Pressure bandaging

DIAGNOSTIC CHECKLIST

Consider

- Infection if adjacent soft tissue hyperemia & edema

Image Interpretation Pearls

- Relate to clinical history/on anticoagulant
- Always evaluate with color Doppler imaging to rule out pseudoaneurysm

SELECTED REFERENCES

1. Amaravathi U et al: The Morel-Lavallée lesion. J Emerg Med. 64(1):67-9, 2023
2. Annison DR et al: Identification and triage of a Morel-Lavallée lesion using point of care ultrasound. Ultrasound. 30(1):85-9, 2022

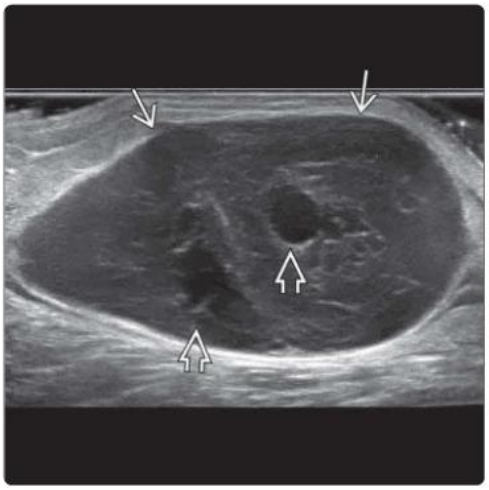

(Left) *Clinical photograph shows a patient with chronic swelling ➡ for more than 3 months over the medial side of the calf after hitting on hard object.* **(Right)** *Transverse US in the same patient shows a large, well-defined hematoma ➡ within the subcutaneous tissues in contact with the investing fascia. Small anechoic cystic areas ➡ due to liquefaction are noted inside. No hyperaemia is evident. Overall appearances favor a chronic, partially liquefied hematoma.*

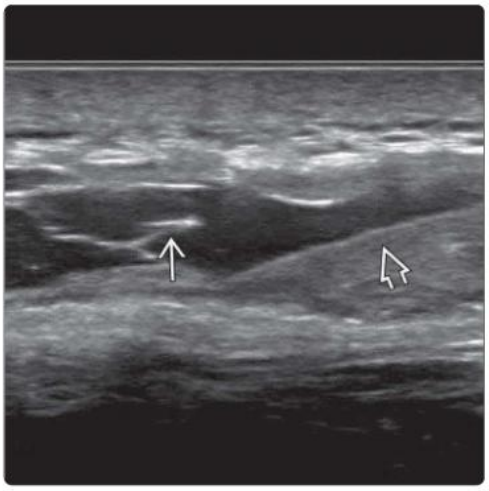

(Left) *Transverse US of the gluteus muscle in a patient who fell 3 weeks earlier shows a large, partially solid, partially cystic mass ➡ with fluid-fluid levels and multilamellated whorling pattern within the gluteal muscle, consistent with hematoma.* **(Right)** *Longitudinal US shows a subcutaneous cystic mass overlying the L1-L3 vertebrae and spinous processes after surgery. There is no intraspinal extension. Note internal septation ➡ and fluid-fluid level ➡, compatible with postoperative seroma.*

(Left) *Clinical photograph shows a patient with spontaneous painful swelling of the iliac crest region ➡, which had been increasing for 6 months with no history of trauma.* **(Right)** *Transverse US in the same patient shows a largely solid mass in the subcutaneous tissue above the iliac crest. The lesion is well encapsulated with no calcification. Small, hypoechoic areas are present ➡. This is highly suspicious of an expanding hematoma, which was confirmed by percutaneous biopsy.*

(Left) *Longitudinal US shows the calf in a patient with spontaneous swelling. Note the large, well-defined, oval-shaped mass with multilaminated whorled appearance and mild posterior enhancement, consistent with hematoma. Small liquefied areas ⇨ are seen. No discrete tear or vascular malformation is seen.* **(Right)** *Color Doppler US of the same mass shows increased vascularity ⇨ eccentrically within the mass, suggestive of underlying vascular anomaly. Note the surrounding edema ⇨.*

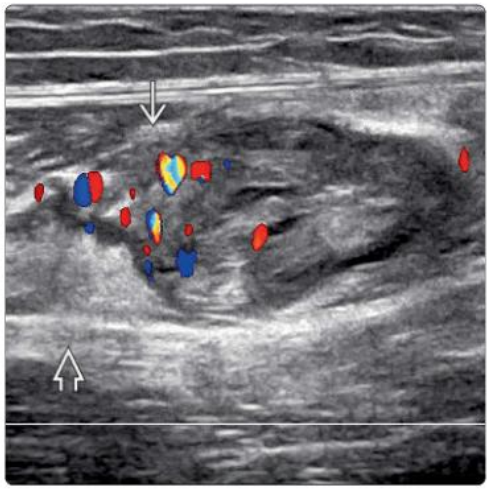

(Left) *Transverse US of the calf 3 days following blunt trauma shows a large hematoma within the soleus muscle belly. Layering ⇨ is present within the more liquefied portions.* **(Right)** *Transverse US of the medial aspect of the knee shows a large subcutaneous cystic collection with fluid-fluid levels. This hematoma is composed of an echogenic blood clot ⇨, a clear liquefied serous component ⇨, and a more dependent cellular component ⇨.*

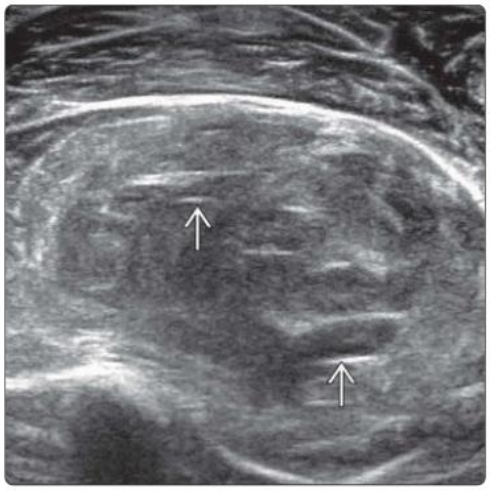

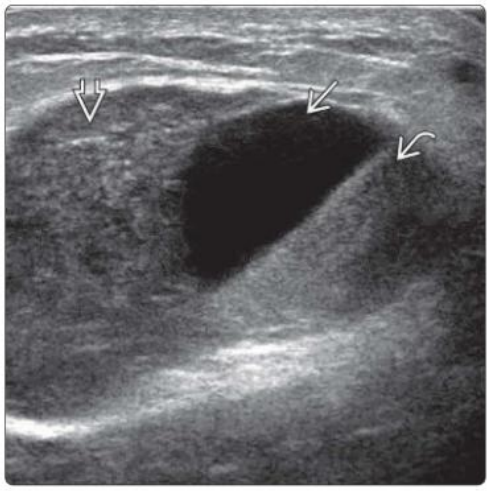

(Left) *Transverse US shows a heterogeneous hematoma within the coracobrachialis muscle ⇨. Another medium-sized hematoma is seen within the short head of biceps muscle ⇨. Partial liquefaction is present ⇨.* **(Right)** *Transverse US shows a large cystic mass ⇨ in the subcutaneous tissues of the groin region after hernia surgery. Low-level echoes ⇨ are present within the collection. There was no demonstrable perilesional hyperemia seen. Features are compatible with lymphocele (biopsy proven).*

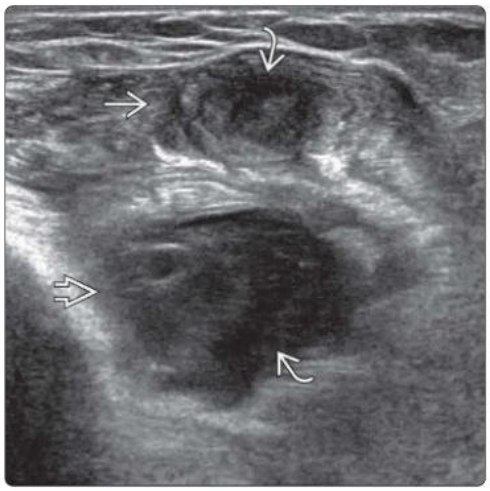

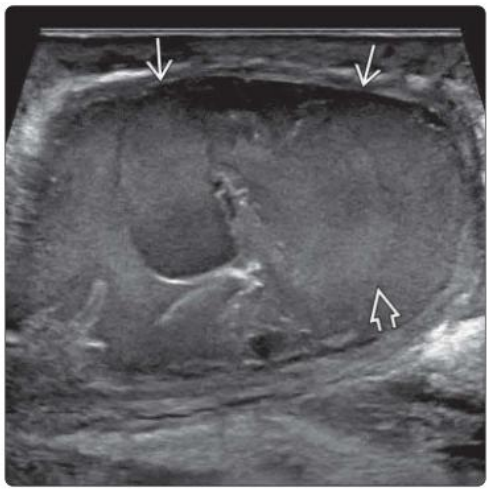

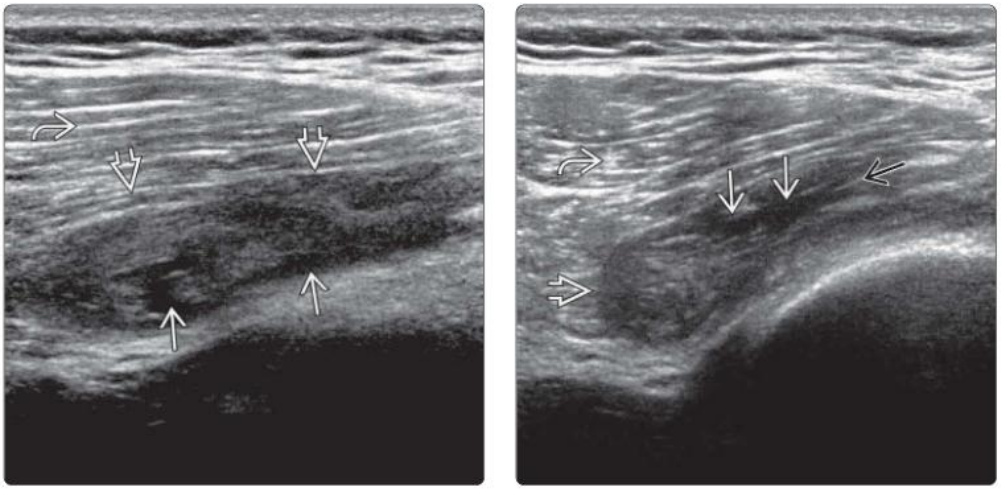

(Left) *Longitudinal US of the gluteus region shows a relatively well-defined hypoechoic mass ⇨ at the deep gluteus maximus muscle ⇨ with small anechoic areas ⇨ suggestive of liquefaction of hematoma, consistent with muscle contusion.* **(Right)** *Transverse US of the same location shows muscle contusion with hemorrhage ⇨ in the gluteus maximus muscle ⇨ with small anechoic areas ⇨. Of note, small intact muscle fibers are seen ⇨.*

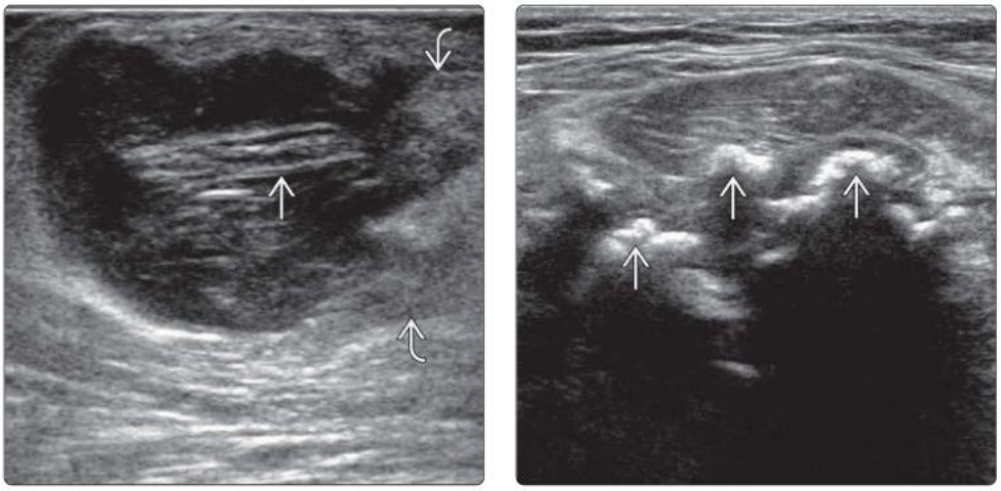

(Left) *Longitudinal US of the calf in an anticoagulated patient with spontaneous swelling shows a medium-sized hematoma with fibrinous-type layering ⇨ confined to the subcutaneous tissues. Moderate surrounding soft tissue edema ⇨ is present.* **(Right)** *Transverse US of the thigh following a road traffic accident several months prior shows a large, heavily calcified mass with peripheral calcification ⇨ obscuring more posterior detail. CT confirmed a large calcified hematoma.*

(Left) *Clinical photograph of an older patient who presented with painful swelling ⇨ of the medial aspect of the proximal thigh is shown. Clinically, an epidermoid cyst was suspected.* **(Right)** *Transverse color Doppler US in the same patient shows a large, well-defined, multiseptated cystic subcutaneous mass ⇨ with peripheral hyperemia, consistent with organizing hematoma. Following aspiration, which yielded old blood, the mass settled and did not recur.*

(Left) *Longitudinal US shows a large hematoma between the medial belly of the gastrocnemius and the soleus muscle. This hematoma was due to a myofascial tear between the soleus and the gastrocnemius muscles. The hematoma is partially liquefied.* **(Right)** *Longitudinal color Doppler US of the same location shows mild increased peripheral vascularity of the hematoma. Such peripheral vascularity is a common feature of hematoma.*

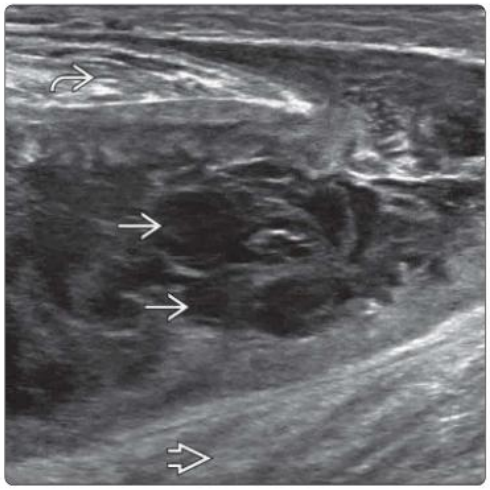

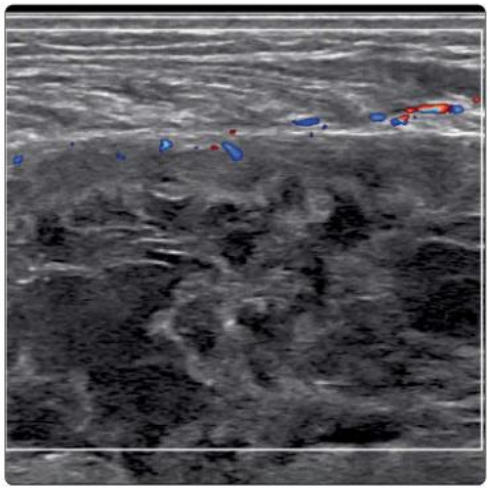

(Left) *Longitudinal US shows a myofascial tear between the soleus and the gastrocnemius muscle. Hypoechoic organized hematoma with internal septations is present within the gap. No cystic component to indicate liquefaction is present.* **(Right)** *Transverse US of the same location shows the hypoechoic organized hematoma within the gap of the myofascial tear between the soleus and the gastrocnemius muscle.*

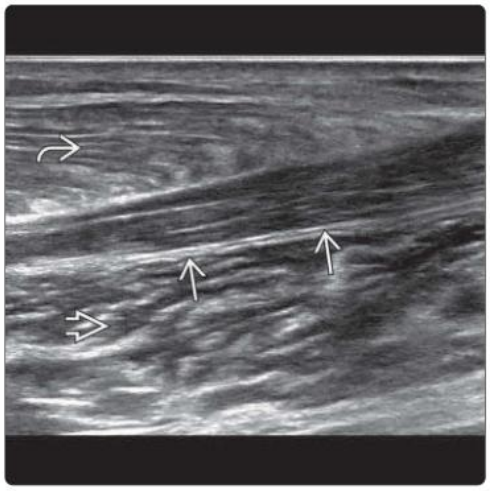

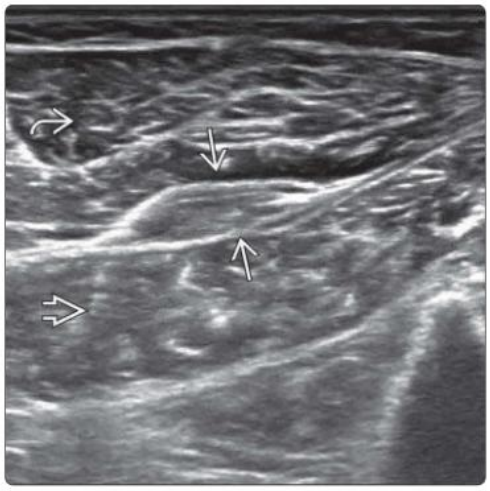

(Left) *Clinical photograph shows groin swelling at the site of a scar due to inguinal hernia repair 2 months prior.* **(Right)** *Longitudinal oblique US in the same patient shows an oval-shaped, well-defined collection within the inguinal canal. The mass contains predominantly cystic components with multiple thin internal septations and small areas of more solid material. Features are compatible with chronic seroma.*

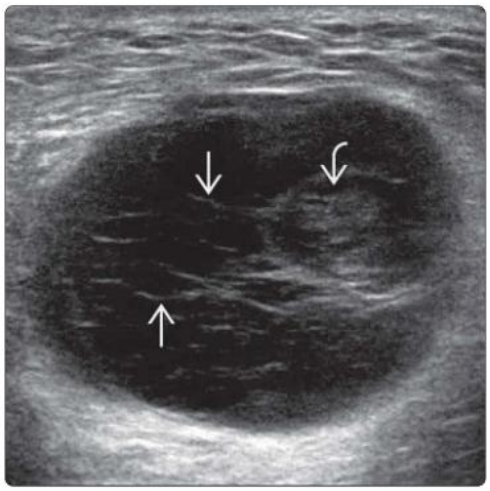

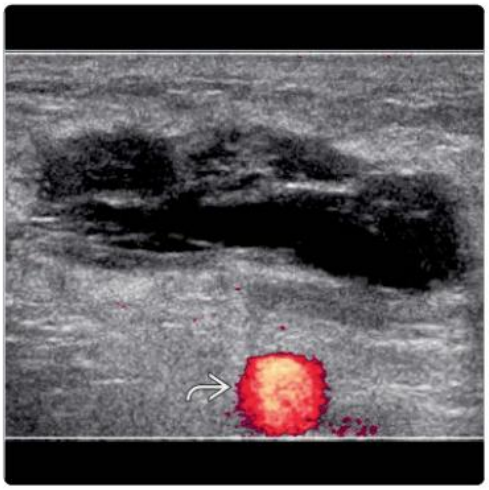

(Left) *Transverse US of the groin in a patient following hernial surgery shows a thick-walled seroma ➡ containing anechoic fluid just anterior to the surgical mesh ➡.* **(Right)** *Transverse color Doppler US of the same seroma more proximally shows no vascularity within the lesion or in the adjacent soft tissues. The femoral artery ➡ is normal.*

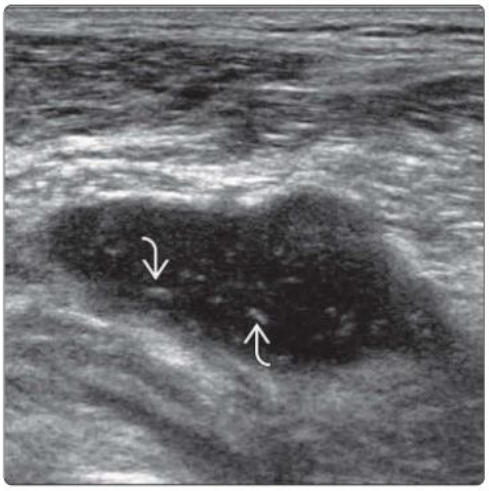

(Left) *Panoramic transverse US shows a large seroma within the anterior abdominal wall. The seroma lies between the subcutaneous fat ➡, the surgical wound ➡, and the underlying surgical mesh ⇨.* **(Right)** *Transverse US of the medial aspect of the popliteal fossa 3 months after knee operation shows a well-defined cystic lesion with small, echogenic foci ➡ and no discernible wall. Appearances are consistent with lymphocele or seroma.*

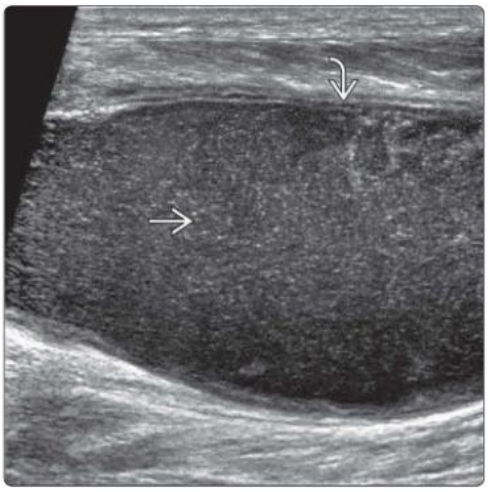

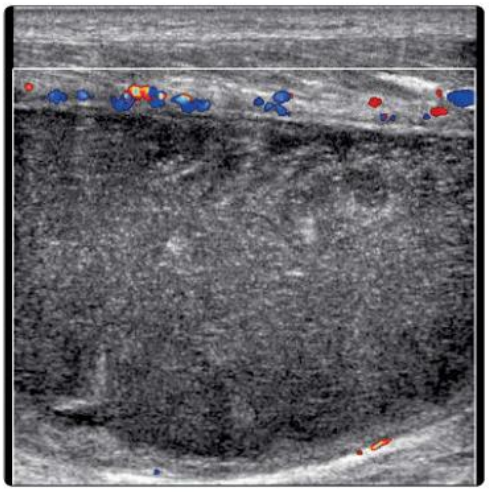

(Left) *Longitudinal US of the calf in a patient with end-stage renal failure shows multiple echogenic speckles ➡ and a well-defined wall ➡, consistent with abscess rather than seroma, lymphocele, or liquefied hematoma. Aspiration yielded purulent fluid.* **(Right)** *Longitudinal color Doppler US of the same lesion shows mild peripheral hyperemia. The size of intrinsic echogenic speckles is indicative of abscess rather than seroma, lymphocele, or liquefied hematoma.*

KEY FACTS

TERMINOLOGY

- Ligament tear: Tear or avulsion of ligament fibers
- Ligament sprain: Partial tear without visible ligament discontinuity

IMAGING

- Ligament tears have similar appearances irrespective of ligament location
- Assess noninjured contralateral side
- Align transducer along long axis of ligament
- Adjust transducer alignment to minimize anisotropy
- Acute stage
  - Diffuse or localized ligament swelling
  - Tear can be partial or full thickness
  - Ligament retraction or discontinuity if complete
  - Widening of ligament tear or joint space when stressed
- Chronic stage: 4 possible sequelae exist
  - Diffusely thickened continuous ligament
    - Can remain for many years following injury
    - Most common sequel of ligament tear
  - Diffusely thickened discontinuous ligament
  - Ligament is continuous but attenuated
    - Ligament laxity with joint space widening during stress
  - Absent ligament
    - No ligament visible due to attrition or resorption of ligament fibers

PATHOLOGY

- Grade 1: Mild partial ligament tear
- Grade 2: Moderate to severe partial ligament tear
- Grade 3: Complete ligament tear or avulsion

CLINICAL ISSUES

- Usually does not require surgical intervention
  - Most partial & some complete ligament tears heal spontaneously
- Ligament tears can lead to joint instability or impingement

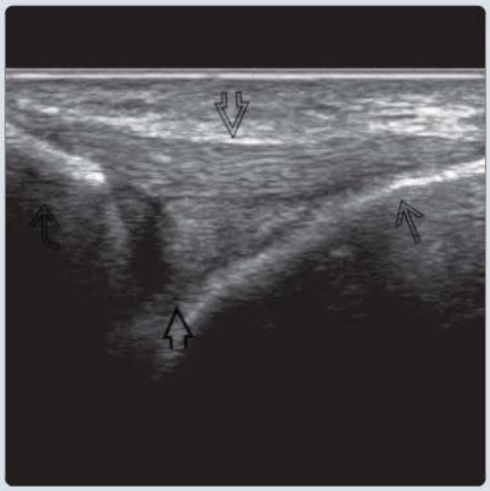

(Left) *Clinical photograph shows probe orientation for examining the anterior talofibular ligament (ATFL). The ankle is slightly plantar flexed, and the probe orientation is transverse.* **(Right)** *Transverse US of the anterolateral ankle shows normal intact ATFL ⇨ coursing between the fibula ⇨ and the talus ⇨. Note how the ligament is echogenic and taut with continuity of fibers. The anterolateral recess ⇨ of the ankle is deep to the ligament.*

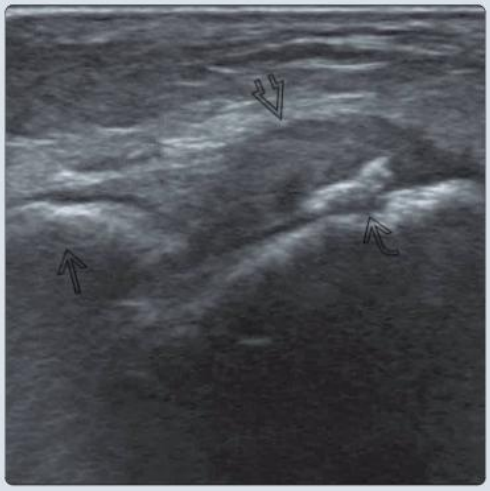

(Left) *Transverse US of the lateral ankle region shows a severe tear of the ATFL ⇨ with severe swelling of the fibers in between the talus ⇨ and the fibula ⇨. No ligament discontinuity is evident.* **(Right)** *Longitudinal US of ankle shows a severe tear of the ATFL ⇨ which is moderately swollen and associated a small talar avulsion fracture ⇨. No ligament discontinuity is present. The fibular tip ⇨ is normal.*

TERMINOLOGY

Synonyms

- Skiers or gamekeeper's thumb: Tear of ulnar collateral ligament (UCL) thumb
- Stener lesion: Proximal retraction of UCL, which overlies adductor aponeurosis
- Ligament sprain
  - Spain is incomplete tear, usually used when no ligament discontinuity evident
  - Partial tear used when ligament discontinuity evident

Definitions

- Ligament: Fibrous band that connects 2 bones helping to stabilize intervening joint
- Ligament tear: Tear or avulsion of ligament fibers
- Avulsion: Some or all ligament fibers are torn away (avulsed) from their bony attachment
  - ± attached avulsed fragment of bone (avulsion fracture)
- Ligament sprain: Partial ligament tear (usually intrasubstance)

IMAGING

General Features

- Best diagnostic clue
  - Swollen ligament following trauma
  - Discontinuity of ligament fibers
- Location
  - Some ligaments are more susceptible to tear
    - Ankle
      - Anterior talofibular ligament (ATFL), calcaneofibular ligament (CFL), anterior tibiofibular ligament (ATibFL)
      - ATFL ligament tears before CFL; ATibFL tear is "high ankle sprain" & associated with deltoid ligament tear
      - Deltoid ligament: Anterior deep fibers most prone to tear
    - Knee
      - Medial collateral ligament (MCL): Anterior fibers femoral attachment
      - Lateral collateral ligament (LCL): Anywhere along length of ligament
    - Thumb
      - UCL metacarpophalangeal (MCP) joint: Particularly phalangeal attachment
    - Elbow
      - Radial collateral ligament: Particularly humeral attachment
- Morphology
  - Normal
    - Normal fibrillar pattern
    - No edema, normal thickness, & taut
  - Partial tear
    - Variable edema & swelling
    - Loss of fibrillar pattern ± partial discontinuity
    - ± laxity on stress testing
  - Complete tear
    - Discontinuity of fibers
    - Avulsion of bony attachment

Radiographic Findings

- Soft tissue swelling ± joint effusion
  - ± avulsion fracture at ligament insertional area
  - ± diastasis of opposing bone margins

Ultrasonographic Findings

- Ligament injuries have same appearance irrespective of where ligament is located
- Acute stage
  - Diffuse or localized ligament swelling
  - ± ligament fiber discontinuity with hypoechoic gap at site of tear filled up with fluid or hematoma
    - Grade as mild, moderate, severe partial or full thickness tear
    - Note avulsion fracture, if present
  - Ligament retraction if complete tear
    - ± wavy, displaced ligament
    - Widening of ligament tear or joint space when ligament is stressed
  - Surrounding soft tissue edema & hemorrhage
  - Surrounding soft tissue hyperemia on color Doppler
  - Variable size joint effusion
- Chronic stage: 4 possible sequelae of ligament tear exist
  - Diffusely thickened continuous ligament
    - Most common sequel of ligament tear, which can remain unchanged for many years
    - Disorganized reparative tissue undergoing gradual remodeling
    - Even completely torn ligaments can regain full continuity with healing
    - ± ligament calcification
    - Pellegrini-Stieda: Calcification at proximal attachment of MCL
      - May be associated with adductor magnus tendon avulsion
  - Diffusely thickened discontinuous ligament
    - Uncommon sequel
    - Stener lesion: Yo-yo sign due to retracted stump of torn ligament lying superficial to adductor aponeurosis
  - Diffusely attenuated ligament
    - Ligament is continuous but reduced in caliber compared to normal ligament
    - Repeated partial tear with fiber resorption
    - Ligament laxity with widening of joint space during stress maneuver
  - Absent ligament
    - No ligament visible
    - Torn fibers undergo attrition or resorption during repair process
- Associated findings
  - Ankle ligament injury: Osteochondral injury talar dome
  - MCL tear of knee: Meniscal & cruciate ligament injury
  - LCL tear of knee: Posterolateral corner injury
- Chronic stress
  - Ligaments can thicken with chronic repetitive stress, such as superomedial fibers spring ligament with pes planus

MR Findings

- Acute: Edema & thickening ± some fiber loss

- Chronic: Thickening or attenuation of fibers
- Complete: Fiber discontinuity ± hematoma filling gap

Imaging Recommendations

- Best imaging tool
  - US to assess ligament injury
    - MR for associated injuries & for visualizing tears in ligaments with limited US access
- Protocol advice
  - Assess noninjured contralateral side
  - Align transducer along long axis of ligament
  - Adjust transducer alignment to minimize anisotropy
  - ± stretch ligament to maximize visibility of tear & determine joint laxity

DIFFERENTIAL DIAGNOSIS

Anisotropic Artifact

- US beam should be oriented perpendicular to ligament to prevent artifact
- Ligaments are best examined under stretch

Traction Apophysitis

- Apophysitis, epicondylitis, or avulsion fracture of medial humeral condyle ("little league elbow syndrome")
- More common in adolescents

PATHOLOGY

General Features

- Etiology
  - Trauma with undue stretching of ligament
  - Epidemiology
    - Most frequent musculoskeletal injury
    - Ankle sprain is most common injury in college athletes
      - 85% of ankle ligament tears occur laterally, 15% medially

Staging, Grading, & Classification

- General
  - Grade 1: Mild partial tear/sprain
    - Ligament swollen with no visible ligament discontinuity or avulsion
  - Grade 2: Moderate to severe partial tear/sprain
    - Ligament severely swollen ± discontinuity of some fibers
  - Grade 3: Complete ligament tear or avulsion

Gross Pathologic & Surgical Features

- Inflammatory phase: Bleeding → platelet-rich fibrin clot → growth factors → repair stimulation
  - Acute inflammation begins immediately after injury & lasts for ~ 72 hours
- Proliferative phase: Fibroblasts → disorganized scar tissue filling ligament gap → progressive remodeling
  - Lasts 4-6 weeks
- Reparative phase: Progressive collagen maturation
  - Lasts months → years

Microscopic Features

- Normal histology
  - Ligament is composed of 2/3 water, 1/3 solid tissue; solid component is mainly (85%) type I collagen
  - Ligaments consist of bundles of collagen fibers aligned parallel along course of ligament
    - Collagen fibers are crosslinked &, if not under tension, undulate along long axis of ligament
    - Fibroblasts & proteoglycans reside in extracellular matrix between collagen fibers
- Remodeled ligament tissue remains morphologically, biochemically, & functionally inferior to normal ligament
  - Normal ligament (type I ligament 85%); healed ligament mainly composed of type III collagen
  - Remodeled fibers are smaller with less crosslinking
    - Ligaments only regain 40-80% of original stiffness & strength, but elasticity recovers to 90%

CLINICAL ISSUES

Presentation

- Most common signs/symptoms
  - Joint pain, especially with apprehension testing
- Other signs/symptoms
  - Pain & swelling after traumatic event & instability

Natural History & Prognosis

- Complications
  - Chronic instability → chondral injury or premature osteoarthritis
  - Impingement due to hyperplastic scar tissue
  - Dystrophic calcification

Treatment

- Conservative
  - Rest, ice, compression, elevation
  - Controlled exercise regimen
    - Remobilization improves ligament remodeling
  - Prolotherapy (i.e., proliferative therapy)
    - US-guided injection of platelet-rich plasma (PRP) to torn ligament
      - Enhances fibroblastic & capillary proliferation
      - No proven clinical benefit of PRP treatment for ligament injury
- Surgical
  - Selected complete tear
    - Many complete tears will heal with conservative treatment
    - Stener lesion: Emergent surgery for better recovery
  - Ligament fixation to bone

DIAGNOSTIC CHECKLIST

Image Interpretation Pearls

- Examine contralateral noninjured side for comparison
- Adjust transducer alignment to minimize anisotropy
- Perform, if possible, dynamic assessment with stress maneuver
- Grade ligament tear as mild, moderate, severe partial or complete tear
- Assess presence of & severity of ligament discontinuity

SELECTED REFERENCES

1. Bordalo M et al: High-resolution ultrasound of the foot and ankle. Foot Ankle Clin. 28(3):697-708, 2023

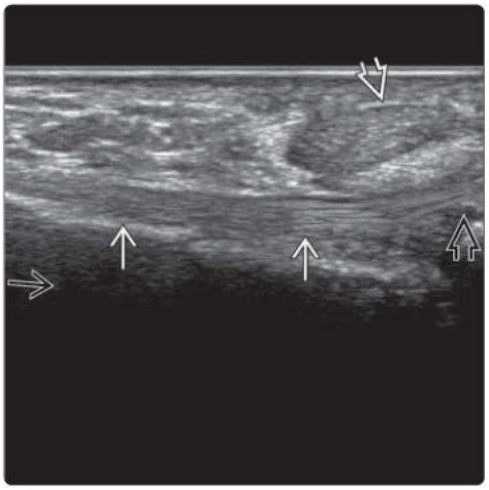

(Left) *Clinical photo shows probe orientation for examining the calcaneofibular ligament (CFL). Ligament visibility can sometimes be improved by dorsiflexing the ankle.* **(Right)** *Longitudinal US in the same patient shows the normal CFL ➡ coursing between the fibular tip ⇨ and the calcaneum ⇨ deep to the peroneal tendons ➡.*

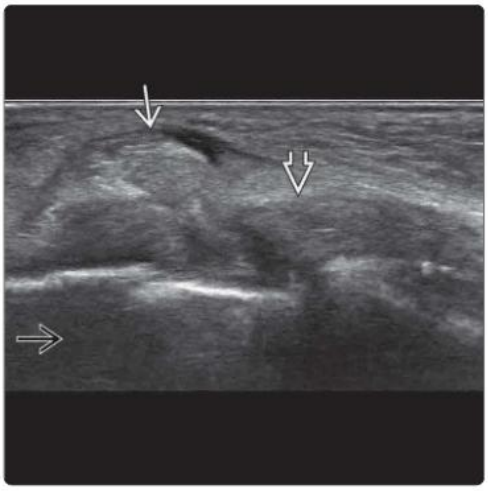

(Left) *Longitudinal US of the ankle shows a severe CFL tear with a severely thickened, hypoechoic ligament ➡ overlying the calcaneum ⇨. The peroneal tendons ➡ are located superficial to the calcaneum. In complete tears they can almost abut the calcaneum due to loss of the CFL sling effect.* **(Right)** *Axial PD FSE MR of the ankle in a patient with an injury 2 weeks prior shows a severely swollen CFL ➡ and the peroneal tendons ⇨ close to the calcaneum ➡, consistent with complete (grade 3) CFL tear.*

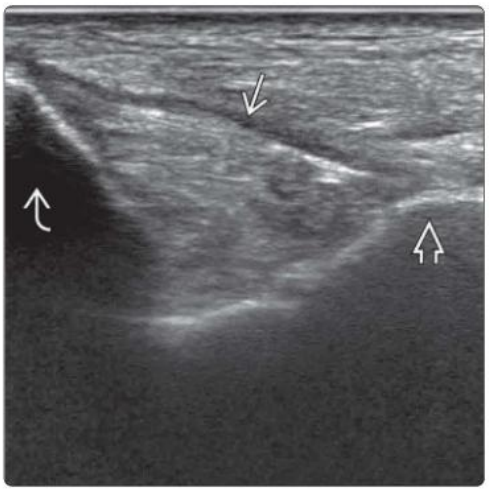

(Left) *Clinical photograph shows the probe orientation for assessing the deltoid ligament. The proximal end of the probe is on the medial malleolus while the distal end sweeps anterior to posterior to view different components of the deltoid ligament.* **(Right)** *Longitudinal US shows the normal fan-shaped deltoid ligament ➡ between the medial malleolus ➡ and the talus ➡. The 5 different components of the deltoid ligament are not separable on US.*

(Left) *Transverse US of the medial inframalleolar region 1 day after injury shows a severe tear of the deltoid ligament with a hypoechoic, severely thickened deltoid ligament located deep to the tibialis posterior tendon.* **(Right)** *Longitudinal oblique US of the medial ankle at the malleolar level shows severe, hypoechoic thickening of the deep and superficial fibers of the deltoid ligament. The tibialis posterior tendon overlying the ligament is normal.*

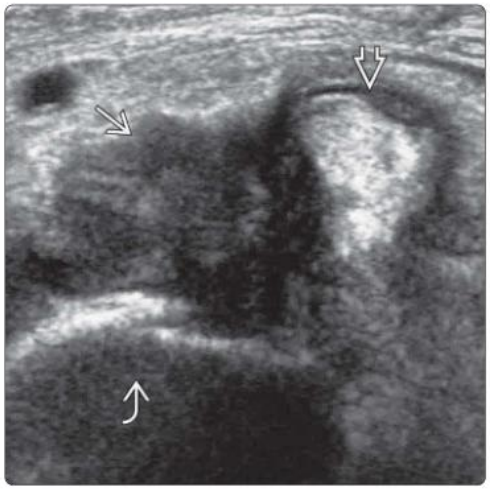

(Left) *Axial PD FSE MR of the tibiofibular articulation shows a normal anterior tibiofibular ligament (ATibFL) with intact low-signal fibers connecting the anterolateral margin of the tibia to the fibula. The normal posterior tibiofibular ligament with intact low-signal fibers is also seen connecting the posterior tibia and fibula.* **(Right)** *Clinical photograph shows the transducer position for examining the ATibFL.*

(Left) *Longitudinal US of a normal subject shows intact ATibFL with normal fibrillar structure coursing between the tibia and fibula. The ligament is normally wider at the tibial end.* **(Right)** *Transverse US of the anterior lower leg shows complete tear of the ATibFL coursing between the tibia and fibula with the gap filling up with fluid. There is no widening of the tibiofibular distance.*

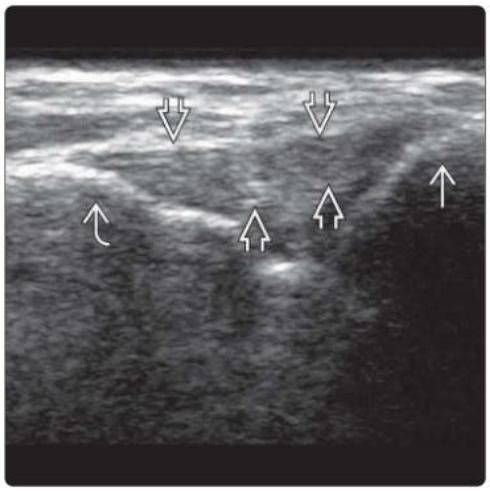

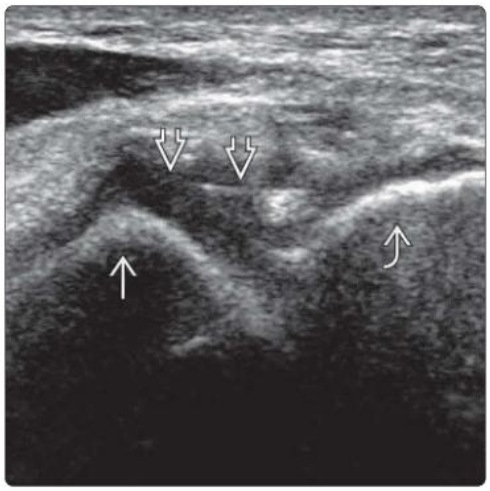

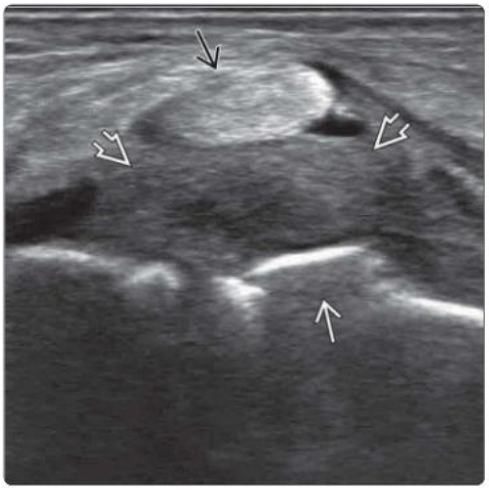

(Left) *Clinical photograph of a standing foot shows pes planus with flattening of the medial longitudinal arch.* **(Right)** *Longitudinal oblique US of the medial foot in a patient with pes planus shows moderate (6.1 mm; normal < 5 mm) reactive-type thickening of the superomedial fibers of the spring ligament. These fibers are located between the posterior tibialis tendon and the talar head. The ligament thickens from chronic stress on the medial longitudinal arch.*

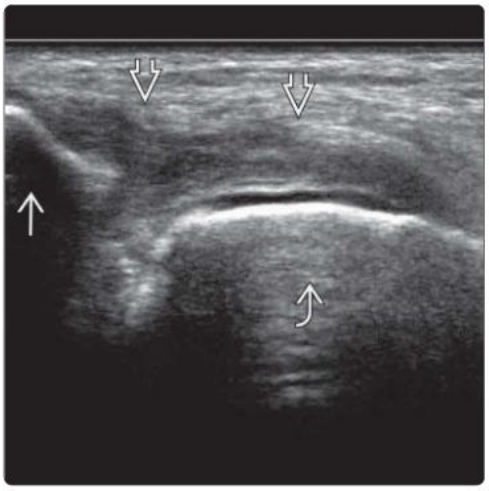

(Left) *Clinical photograph shows lateral ankle swelling with a dependent bruise at the inframalleolar region 2 weeks following an inversion injury. Clinically, this is consistent with an ATFL tear.* **(Right)** *Longitudinal US in the same patient shows a severely thickened, hypoechoic ATFL with fiber continuity between the distal fibula and talus, compatible with severe (grade 2) partial tear of the ATFL.*

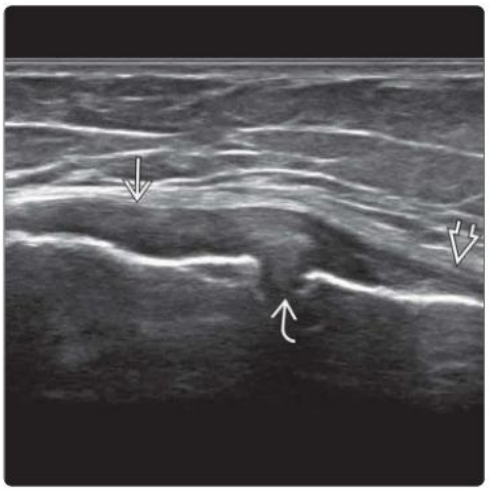

(Left) *Coronal T2 FS MR shows a severe tear of the anterior fibers medial collateral ligament (MCL) with partial periosteal stripping of adductor magnus insertion.* **(Right)** *Longitudinal US shows moderate-severity partial MCL tear with diffuse hypoechoic fiber thickening at the femoral attachment and loss of normal fibrillar echotexture. The distal MCL fibers are normal. There is mild medial meniscal extrusion.*

(Left) *Longitudinal US of the lateral ankle region shows a partially healed partial tear of the ATFL ➡ with a thickened, hypoechoic ATFL on the fibular side and loss of normal fibrillar structure. A small avulsed osseous fragment is present ⇨ from the fibula tip ⇨ and not from the talar attachment ⇨.* **(Right)** *Longitudinal US shows normal UCL of thumb ➡ between the metacarpus ⇨ and the proximal phalanx ⇨. The normal UCL is thick. The thin adductor aponeurosis is seen superficially extending to the dorsum of proximal phalanx.*

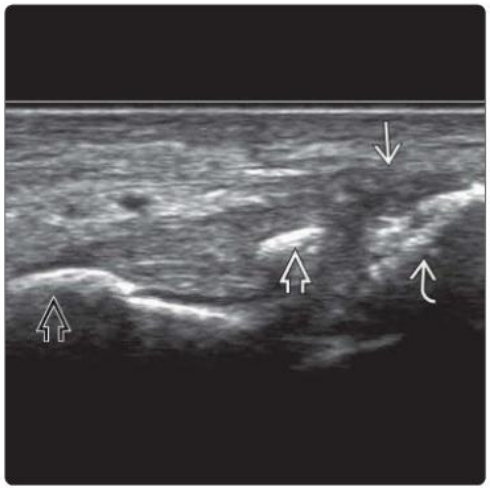

(Left) *Longitudinal US shows a severe sprain of the UCL of thumb ➡, which is diffusely thickened extending between metacarpus ⇨ and proximal phalanx ⇨. There is no Stener lesion.* **(Right)** *Longitudinal oblique US of the UCL of the thumb shows a chronic Stener lesion with proximal retraction of the torn UCL ➡ and a thickened adductor aponeurosis ➡.*

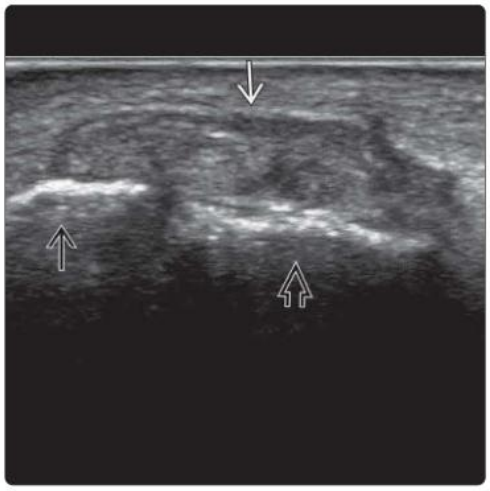

(Left) *Longitudinal oblique US in the same patient shows the joint space ➡ between the metacarpal head ➡ and the base of the proximal phalanx ⇨ without valgus stress maneuver.* **(Right)** *Longitudinal oblique US shows the joint space ➡ between the metacarpal head ➡ and the base of the proximal phalanx ⇨ has increased during valgus stress maneuver. Features are compatible with joint laxity due to UCL injury.*

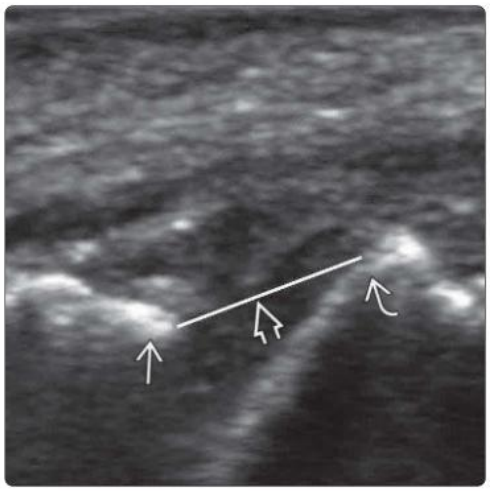

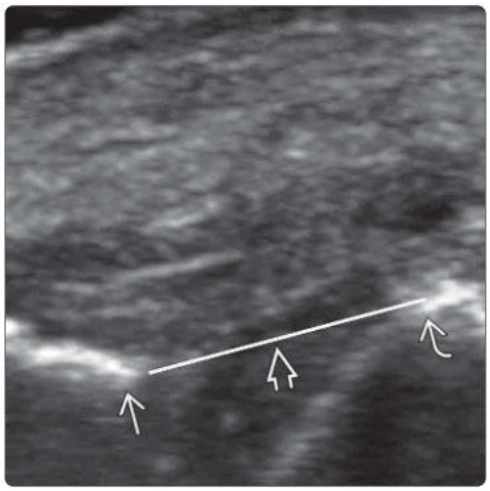

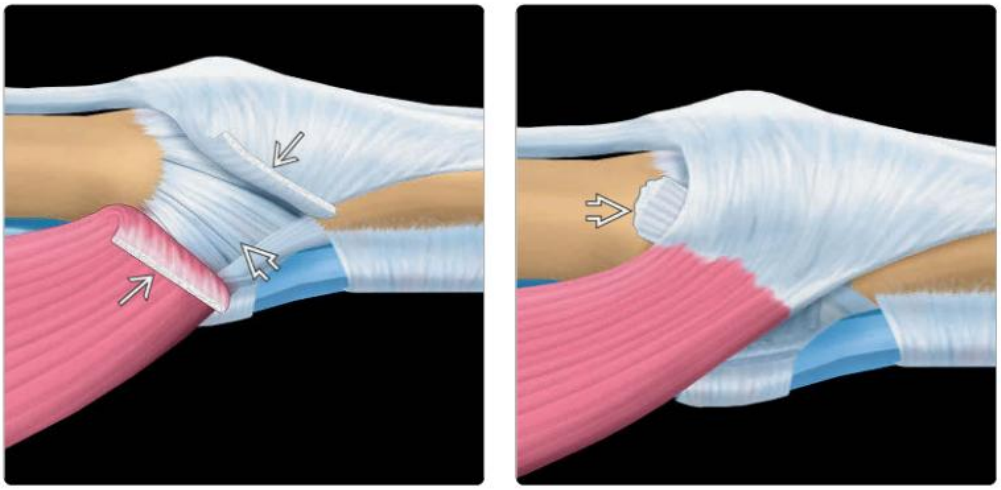

(Left) *Graphic shows the ulnar aspect of the metacarpophalangeal (MCP) joint of the thumb and a reflected adductor aponeurosis ➡ with the UCL ➡ beneath.* **(Right)** *Graphic shows the ulnar aspect of the MCP joint of the thumb. When a complete tear of the UCL occurs, the proximal end of the ligament may retract back ➡ over the adductor aponeurosis. This is referred to as a Stener lesion.*

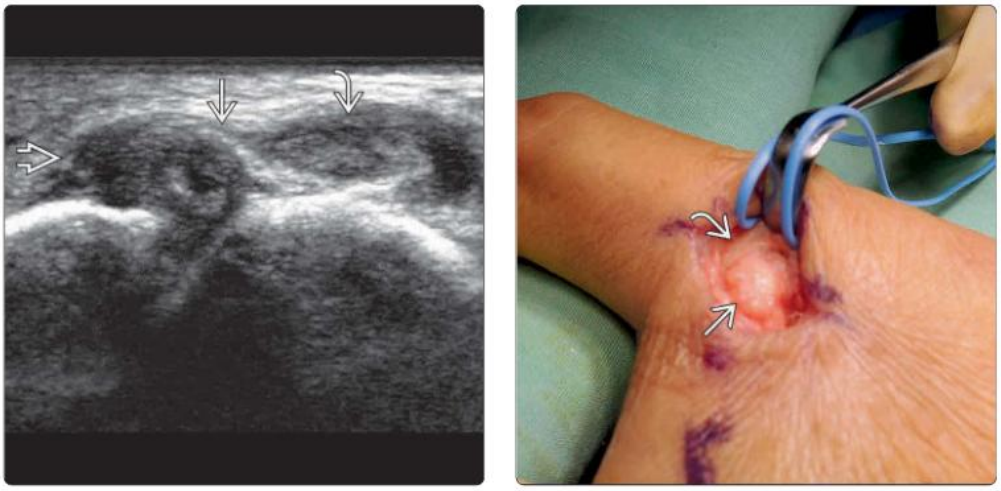

(Left) *Longitudinal US of the ulnar aspect of the MCP joint of the thumb shows a swollen, irregular, and hypoechoic torn distal end of the UCL ➡. The swollen proximal end of the UCL ➡ is displaced proximal to the adductor aponeurosis ➡.* **(Right)** *Intraoperative photograph of the same patient shows a Stener lesion with the torn and retracted UCL ➡ located proximal and slightly superficial to the adductor aponeurosis ➡.*

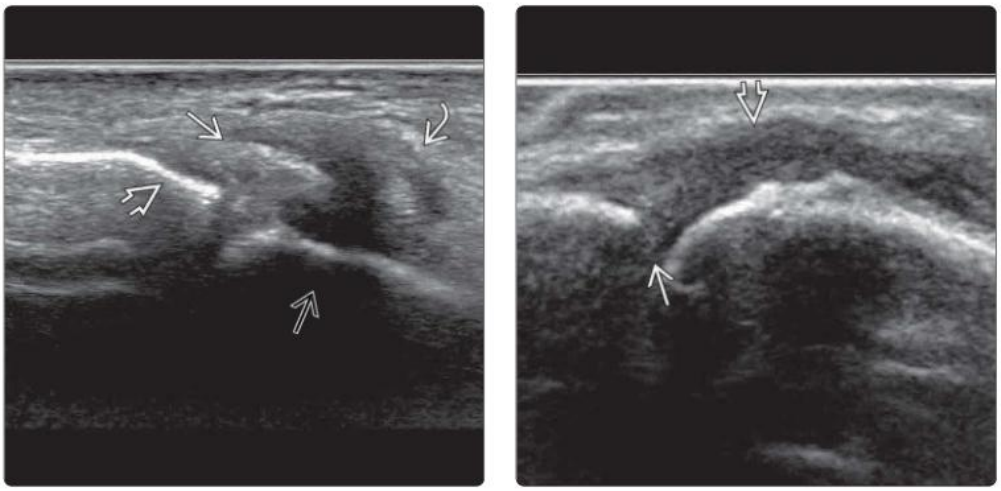

(Left) *Longitudinal US of the thumb 1 week following an abduction injury shows the swollen ulnar collateral ligament ➡ is torn from the proximal phalanx ➡ and retracted proximally proximal to the adductor aponeurosis ➡. This is a Stener lesion. There is no metacarpal bone ➡ or phalangeal fracture.* **(Right)** *Longitudinal US of the radial side of the proximal interphalangeal joint of the little finger ➡ shows a severely thickened, hypoechoic radial collateral ligament ➡, compatible with a high-grade partial tear.*

KEY FACTS

TERMINOLOGY

- Fracture (fx): Traumatic discontinuity of bone usually involving both cortical & trabecular bone
- Stress fx: Fx occurring in normal bone due to excessive repetitive submaximal loading
- Insufficiency fx: Fx occurring in diffusely weakened bone subjected to normal loading
- Pathologic fx: Fx occurring in focally weakened bone subjected to normal loading

IMAGING

- Standard radiographs will **not** show
  - 85% of rib, 50% of nasal bone, 15% of scaphoid fxs
  - 25% of pediatric elbow, 100% of chondral fxs
- Fx
  - Focal cortical disruption with soft tissue edema, hematoma, or callus ± reverberation artifact at fx line
  - → fx edge resorption with hypoechoic osteoid deposition across fx line
  - → progressive callus mineralization
- Stress fx
  - Thickened hyperechoic periosteum at symptomatic site
  - Visible on US before radiographs
  - Hyperemic thickened periosteal rim on color Doppler imaging
- Insufficiency fx
  - US insensitive to detection in early stage
  - Focal cortical hyperostosis or exuberant callus in later stages
- Pathologic fx
  - Often wider fx line ± cortical irregularity extending beyond fx margins
  - ± visible tumor protruding from fx gap
  - US helpful to guide biopsy
- Chondral fx
  - Focal disruption of hypoechoic cartilage
  - ± juxtachondral soft tissue edema or hematoma

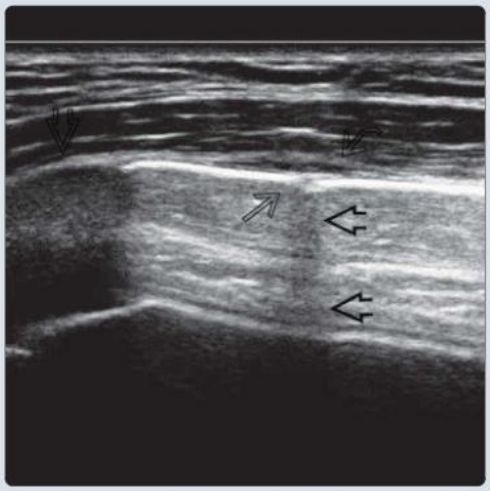

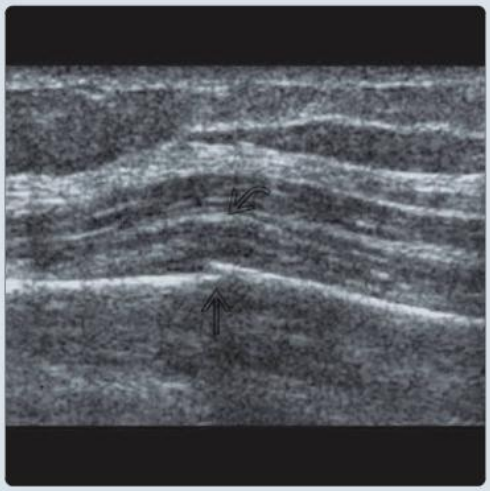

(Left) *Transverse US shows an acute undisplaced fracture on the anterior aspect of the rib with focal discontinuity of the cortex ⇨, minimal soft tissue swelling ⇨, and posterior reverberation ⇨ (chimney phenomenon). The costochondral junction and hypoechoic costal cartilage are also shown ⇨. Radiograph was normal.* **(Right)** *Transverse US shows a mildly angulated acute fracture ⇨ in the anterior axillary line with mild overlying soft tissue swelling ⇨. Radiograph was normal.*

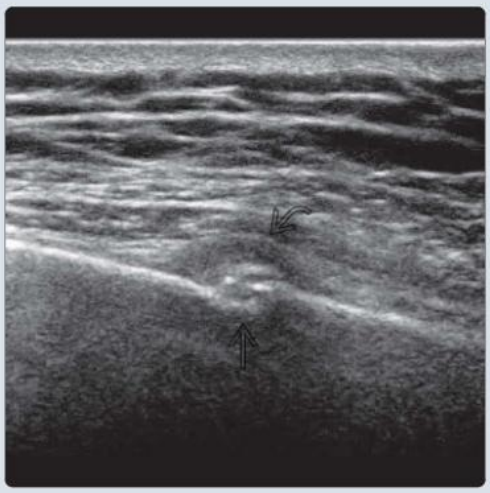

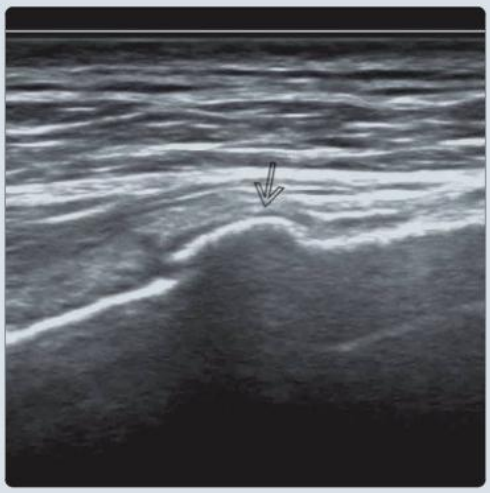

(Left) *Transverse US shows a healing fracture in the midaxillary line ⇨. There is hypoechoic callus surrounding the fracture ⇨ with echogenic mineralization more deeply. This stage of fracture healing may no longer be painful.* **(Right)** *Longitudinal US shows a healed fracture at a lateral rib with a smooth, well-formed, and mineralized callus ⇨. There is no adjacent soft tissue swelling or hyperemia.*

TERMINOLOGY

Definitions

- Fracture (fx): Traumatic discontinuity of bone usually involving both cortical & trabecular bone
- Trabecular micro-fx: Fx limited to trabecular component of bone without clear fx line
  - Diffuse bone marrow edema on MR imaging but no discrete fx line
- Stress fx: Fx occurring in normal bone due to excessive repetitive submaximal loading
- Stress reaction of bone: Trabecular micro-fx occurring in normal bone due to repetitive excessive submaximal loading
- Insufficiency fx: Fx occurring in diffusely weakened bone subjected to normal loading
  - Usually due to osteoporosis; other causes include renal osteodystrophy & chronic bisphosphonate therapy
- Pathologic fx: Fx occurring in focally weakened bone subjected to normal loading
  - Usually due to metastatic infiltration or primary bone tumor; infection & radiation are other causes

IMAGING

General Features

- Best diagnostic clue
  - Acute: Focal disruption of bone cortex with juxtacortical soft tissue edema/hemorrhage
  - Subacute/chronic: Cortical step/irregularity ± periosteal thickening ± callus formation
- Location
  - Most common in ribs, distal radius, scaphoid, metacarpals, phalanges, metacarpals, nasal bones, skull, & vertebral bodies

Radiographic Findings

- 1st-line method of fx assessment
  - Shows majority of fx to good effect
  - Limited depiction of some fxs
  - Standard radiographs will not show
    - 85% of rib fxs, 50% of nasal bone fxs, 15% of scaphoid fxs
    - 25% of pediatric elbow fxs, 100% of chondral fxs
    - < 5% of proximal femoral & distal radial fxs in osteopenic patients

MR Findings

- Gold standard for fx detection
  - Detects both cortical & trabecular component of fx as well as stress reaction with high sensitivity, specificity, & negative predictive value

Ultrasonographic Findings

- Fx
  - Focal cortical disruption with adjacent soft tissue edema, hematoma, or callus
    - ± reverberation artifact (chimney phenomenon) or shadowing artifact at fx site
    - Effusion, hemarthrosis, or lipohemarthrosis if intracapsular surface extension is present
  - Later, fx edge resorption occurs with hypoechoic osteoid deposition across fx line
  - → progressive callus mineralization
  - → complete callus mineralization → smooth bump on cortical contour
- Stress fx
  - Thickened rim of hyperechoic periosteum at symptomatic site
    - Visible on US before radiographs
  - Hyperemia of thickened periosteum on color Doppler imaging
  - → increasing echogenicity of periosteal thickening due to progressive mineralization of callus
- Pathologic fx
  - Often wider fx line ± cortical irregularity extending beyond fx margins
  - ± visible tumor protruding from fx gap
- Insufficiency fx
  - Periosteal thickening & hyperemia with adjacent soft tissue edema
  - ± focal cortical irregularity or disruption
  - Overall sensitivity of US for early insufficiency fx is low
    - Propagates from trabecular bone & is therefore not visible on US at early stage
    - MR is most sensitive
- Chondral fx
  - Focal disruption of hypoechoic cartilage
  - ± juxtachondral soft tissue edema or hematoma
    - Heals by fibrocartilaginous repair
    - No callus formation

Imaging Recommendations

- Best imaging tool
  - Radiography ± US for selected fx detection
  - Increasingly, US is advocated as best initial investigation for suspected rib, sternal, nasal bone, & skull fxs
  - With suitable training, US can detect or exclude fxs in these areas with high (> 90%) sensitivity & specificity
    - US can be used as standalone investigation or as supplement to radiography
    - Allows real-time corroboration with site of symptoms
  - US assessment of fx is severely limited in
    - Retroscapular area of rib cage & spine
    - Intraarticular areas, carpus, or tarsus
    - Reduced transducer access due to open wound, severe abrasion, or external fixation
    - Gas or severe trauma to soft tissues impairing acoustic transmission
    - Assessment of any trabecular fx
    - Unconscious or uncooperative patient
      - Cannot localize painful area
    - Complex fx as overall fx perception is limited
  - In addition to fx detection, US can also
    - Check alignment of fx post reduction
      - More time efficient compared to repeating radiographs
    - Guide "hematoma block" of local anesthetic
      - Significantly decreased need for systemic analgesics in immediate post-fx period
    - Check for neurovascular injury in at-risk fx

        - e.g., displaced pediatric supracondylar fx (Gartland types II-IV)
        - 15% risk of neurovascular complication, up to 90% vascular injury risk in type IV
        - Brachial artery (kinking, spasm, thrombosis, laceration) & median nerve most at risk
- Protocol advice
    - Focus examination on area of maximum pain & tenderness
    - Align transducer with long axis of bone
    - Check for cortical as well as juxtacortical signs of fx
    - Determine location, displacement, angulation, comminution, & alignment of fx as well as integrity of adjacent cortex
        - Check juxtacortical soft tissues for edema, hematoma, presence & maturity of callus
    - ± finger palpation test to ensure US abnormality corresponds to point of maximum pain
    - Check for fx-related complications
    - For rib fx
        - Ask patient to point to most painful area & start examination at this site
            - Either in decubitus, supine, or prone position
        - Align transducer along long axis of rib
        - Then examine this rib from costosternal junction to costovertebral junction
        - Repeat procedure for all ribs in painful area
        - If rib fx detected, mark site on skin with bleb of US gel
            - Place transducer in oblique longitudinal plane over 12th rib & count ribs backward toward bleb of gel
            - In addition to rib number, report whether rib fx is located in midscapular line; posterior, mid-, or anterior axillary line; or midclavicular line
        - Only weak correlation exists between degree of rib fx displacement/alignment & time to clinical healing
        - Check for pneumothorax
            - Align transducer within intercostal space parallel to ribs at least dependent portion of affected hemithorax
            - Look for absence of gliding sign (lung gliding at pleural interface on real-time scanning)
            - Look for absence of moving comet-tail artifacts at lung surface (on real-time scanning)
            - US is as sensitive as radiography for pneumothorax detection
        - Check for pleural effusion or hemothorax at most dependent portion of affected hemithorax
        - ± brachial plexus injury in upper rib fx
            - C8 & T1 roots most common injury, though least well seen on US
            - Check for presence of pseudomeningocele
    - For nasal bone fx
        - Examine longitudinal & transverse planes midline of nasal bones, right & left lateral nasal bones
            - Evaluate osseous & cartilaginous components
            - Ideally, use "hockey stick" transducer
            - US more sensitive than radiography, though slightly less than CT, for nasal bone fx
            - US cannot evaluate nasal septum
        - Consider CT if nasal bone fx is depressed on US

DIFFERENTIAL DIAGNOSIS

Physiologic Cortical Irregularity or Physis

- No adjacent soft tissue edema, hematoma, callus or pain

Bone-Allograft or Bone-Prosthetic Junction

- No adjacent soft tissue edema, hematoma, or callus

PATHOLOGY

Staging, Grading, & Classification

- Hematoma at fx site with inflammatory response
    - Production & release of proinflammatory cytokines
    - Peaks at 24 hours; completes after 7 days
    - Local & systemic recruitment of mesenchymal stem cells
    - Fibrin-rich granulation tissue forms & replaces hematoma in & around fx site
- Elevation & stimulation of periosteum → intramembranous ossification at subperiosteal site (hard callus) → bridging woven bone
- Endochondral formation within granulation tissue (soft callus) → progressive endochondral ossification of callus
- Bone remodeling → original lamellar structure & external shape

CLINICAL ISSUES

Presentation

- Most common signs/symptoms
    - Acute localized pain & tenderness after trauma
- Other signs/symptoms
    - Swelling, hematoma, ecchymosis, limited motion
    - Stress fx: Pain induced by exercise & relieved by rest
        - History of abrupt increase in mechanical stress (exercise, severe cough)

Natural History & Prognosis

- Severe pain for ~ 1 week; symptom free in 6-8 weeks

Treatment

- Initially, rest, ice, compression, & elevation
- ± fx reduction, ± cast immobilization
- Functional casting or brace
- External or internal metallic fixation

DIAGNOSTIC CHECKLIST

Consider

- Using US to detect fx in those known sites where accuracy of radiography is limited
- Careful assessment of bone should be integral part of any MSK-US examination, especially in posttraumatic patients

Image Interpretation Pearls

- Localized cortical discontinuity at tender spot with adjacent soft tissue injury or reparative change

SELECTED REFERENCES

1. Calvisi SL et al: Sonographic diagnosis of radiographically undetectable Bennet fracture. J Ultrasound. ePub, 2024
2. Cocco G et al: Ultrasound imaging of bone fractures. Insights Imaging. 13(1):189, 2022

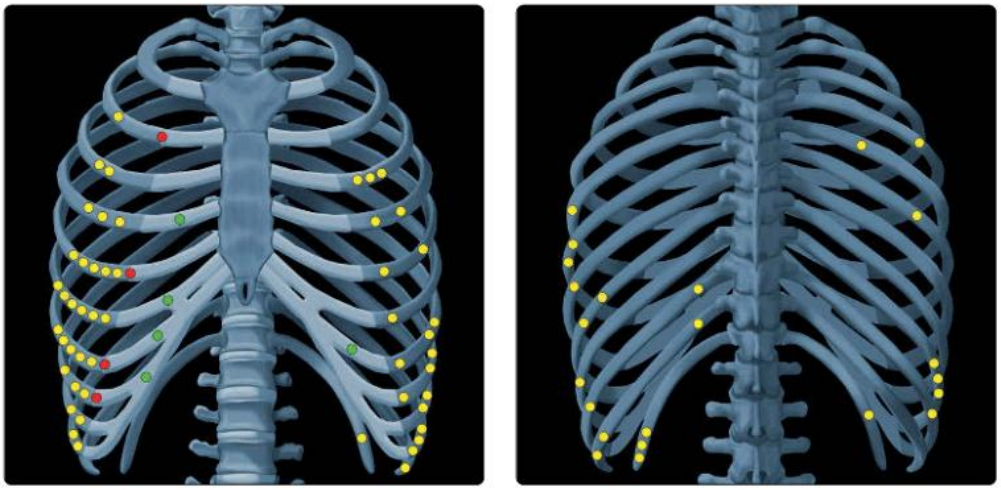

(Left) *Graphic of the anterior chest wall shows the common locations of rib fractures (yellow dots), costochondral junction fractures (red dots), and costal cartilage fractures (green dots).* **(Right)** *Graphic of the posterior chest wall shows the common locations of rib fractures (yellow dots). Note that most chest wall fractures occur anteriorly (preferentially affecting the lower ribs) and are more common on the right side anteriorly and on the left side posteriorly.*

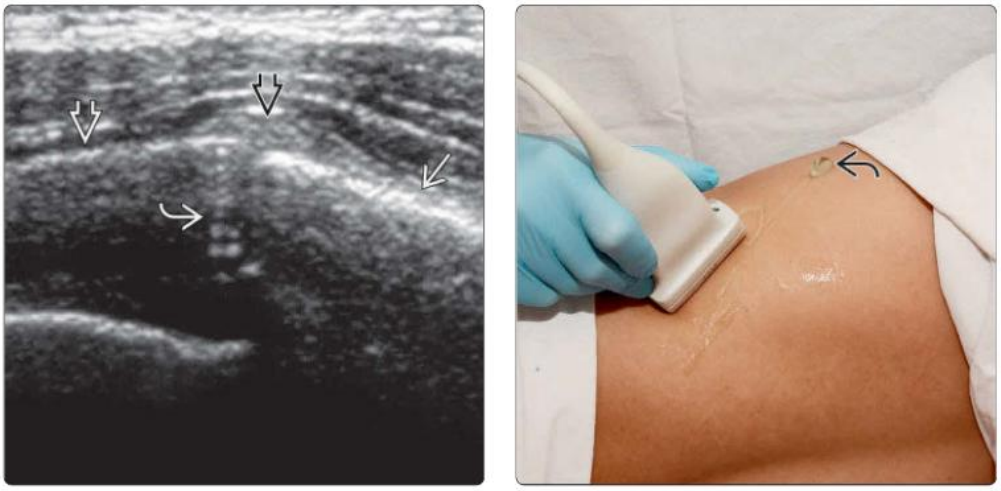

(Left) *Transverse US shows an acute, undisplaced costochondral junction fracture with mild soft tissue swelling ⇨ anterior to the junction between the osseous ➡ and chondral ➡ portions of the rib. Note reverberation artifact ⇨ at the fracture site (chimney phenomenon).* **(Right)** *Clinical photograph shows how to determine which rib is fractured. Mark fracture site with gel ⇨. Place transducer transversely over the 12th rib, and move it upward to the fracture site while counting ribs as the transducer passes over them.*

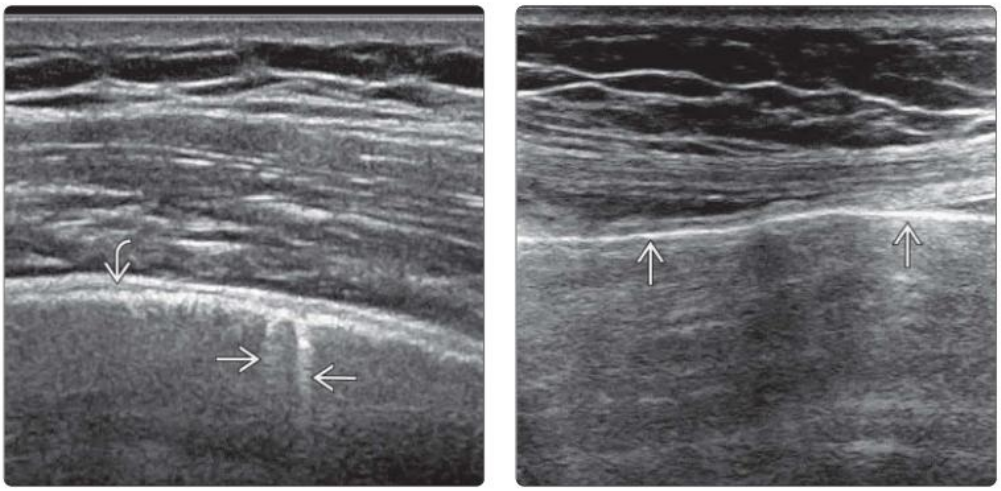

(Left) *Transverse US of a normal lung through the intercostal window shows normal, thick, irregular echogenic pleural interface ⇨ with reverberation artifacts ➡, which moves to and fro on dynamic view.* **(Right)** *Transverse US shows pneumothorax with a thin, sharp echogenic line on the parietal pleural surface ➡ and absent reverberation artifact. On dynamic view, the expected pleural gliding is lost, enabling clear recognition of pneumothorax.*

(Left) *Longitudinal US of an active rower shows a stress fracture at the anterior aspect of the right 6th rib. There is subtle hyperechoic juxtacortical hyperostosis* ⇨ *and hypoechoic soft tissue swelling* ⇨. **(Right)** *Transverse color Doppler US of the right 6th rib* ⇨ *at the same location shows a hypoechoic rim of juxtacortical soft tissue swelling with moderate hyperemia* ⇨. *The normal 5th rib* ⇨ *is shown.*

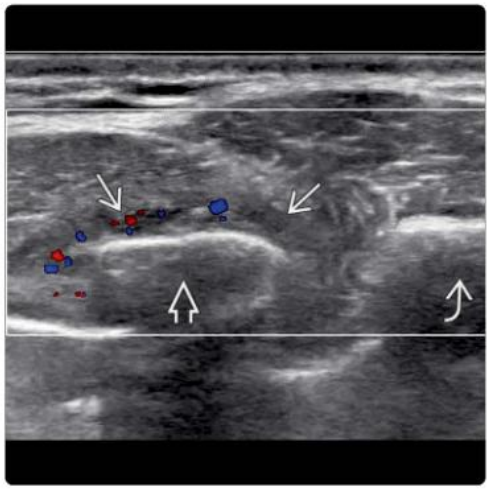

(Left) *Longitudinal US in a patient with anterior chest pain following a fall shows an angulated fracture* ⇨ *of the sternal body with mild associated soft tissue swelling* ⇨. *Radiograph was normal.* **(Right)** *Sagittal T1 MR confirms a mildly angulated, mildly displaced transverse fracture* ⇨ *of the sternal body. Many sternal fractures are not visible on radiographs when compared with MR. US will allow correct identification or exclusion of most sternal fractures.*

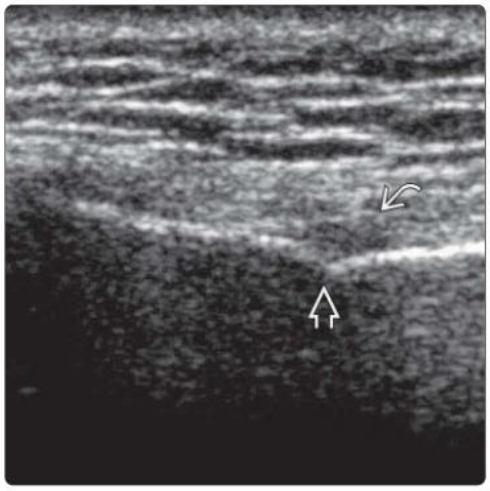

(Left) *Transverse US of the humeral head posteriorly shows a moderate-sized cortical depression* ⇨ *consistent with a Hill-Sachs fracture, which was not known prior to US examination.* **(Right)** *Radiograph of the same patient confirms a Hill-Sachs fracture* ⇨. *The patient subsequently recalled a fall and shoulder injury a long time ago but never sought medical attention or underwent imaging.*

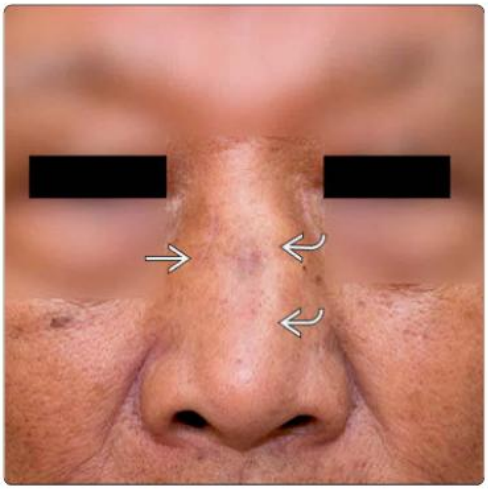

(Left) *Clinical photograph shows depressed fracture of the nose ➡ and apparent left septal deviation ➡. US is almost as sensitive as CT for detecting both lateral nasal wall and midline nasal bone fractures.* **(Right)** *Longitudinal midline US of the same patient shows a very comminuted, midline nasal fracture involving both the osseous ➡ and cartilaginous ➡ components. US, unlike CT, cannot assess the nasal septum.*

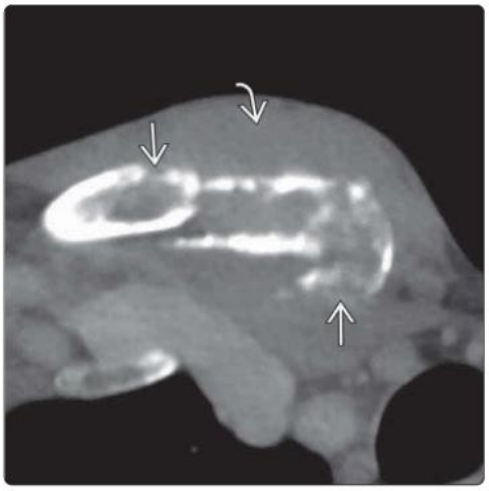

(Left) *Longitudinal US of the clavicle in a patient with increasing swelling and pain for 6 months shows a fracture with a cortical step ➡, irregularity ➡, impaction ➡, and a medium-sized extraosseous mass ➡ with mild hyperemia (not shown).* **(Right)** *Axial oblique CT of the same patient shows a pathologic fracture, cortical destruction ➡, and extraosseous mass ➡. US-guided biopsy yielded Propionibacterium with no malignancy. A diagnosis of atypical osteomyelitis was made.*

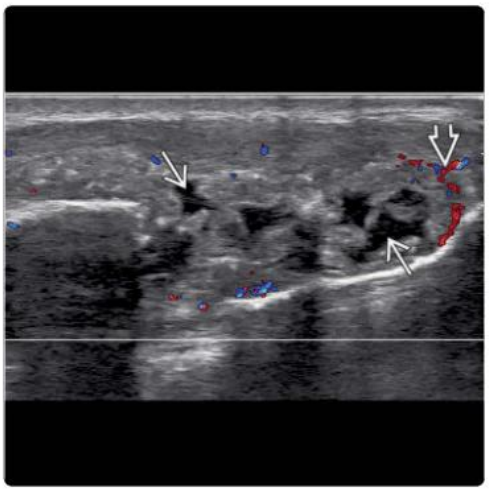

(Left) *CT of a patient with prior radiotherapy around the clavicular region shows a pathologic clavicular fracture with rounded ends ➡ and a large, intervening, low-density mass ➡ with a smooth calcific rim ➡. Diagnosis possibilities were a radiation-induced sarcoma or osteolysis from a nonunited insufficiency fracture.* **(Right)** *Color Doppler US at the same site shows cystic areas ➡ with mild perilesional vascularity ➡, favoring insufficiency fracture, which was confirmed by US-guided biopsy.*

(Left) *Lateral knee radiograph in a young patient with chronic renal failure and renal osteodystrophy shows a faint periosteal avulsion fracture ➡ from the superior pole of the patella. There is radiographic evidence of hyperparathyroidism.* **(Right)** *Longitudinal US of the same patient shows the quadriceps tendon ➡ attached to the thin periosteal sleeve avulsion fracture ➡, which is slightly separated from the superior patella pole ➡. This type of fracture is more common in children and in patients with metabolic bone disease.*

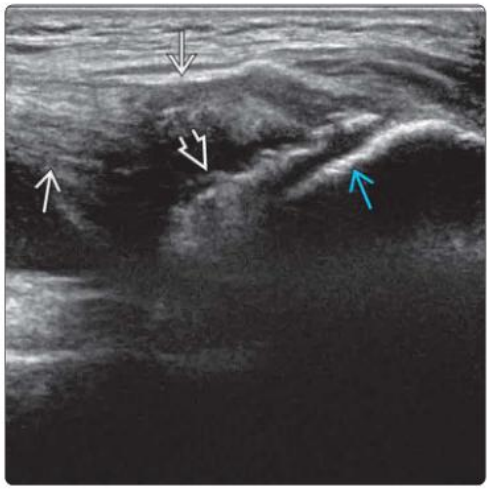

(Left) *Longitudinal color Doppler US of the same patient shows moderate hyperemia ➡ of the fracture site.* **(Right)** *Sagittal reformat CT of the same patient shows a periosteal sleeve fracture ➡, which is attached to the quadriceps tendon ➡ avulsed from the superior patellar pole. This type of fracture can also occur at the inferior patellar pole. Note arterial calcification ➡ in this young patient due to chronic renal failure.*

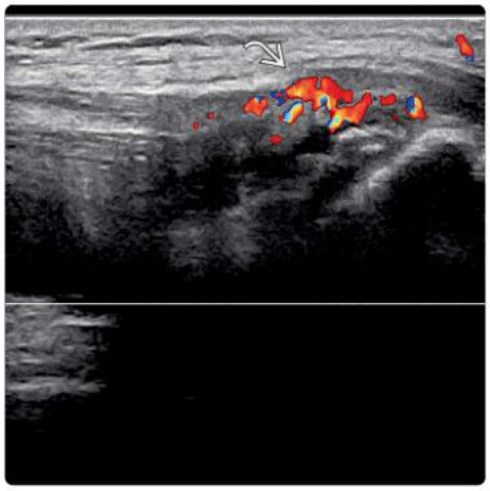

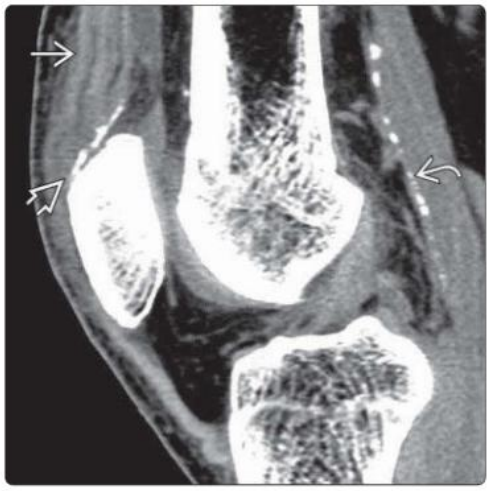

(Left) *Lateral radiograph of the knee in a 12-year-old boy with acute hemarthrosis following a fall is shown. There is a very faint opacity at the inferior pole of the patella ➡. The radiograph was reported as showing a high-riding patella but no fracture.* **(Right)** *Longitudinal US shows an extensive periosteal sleeve avulsion ➡ extending from the mid- to inferior patella ➡ with an attached patellar tendon ➡.*

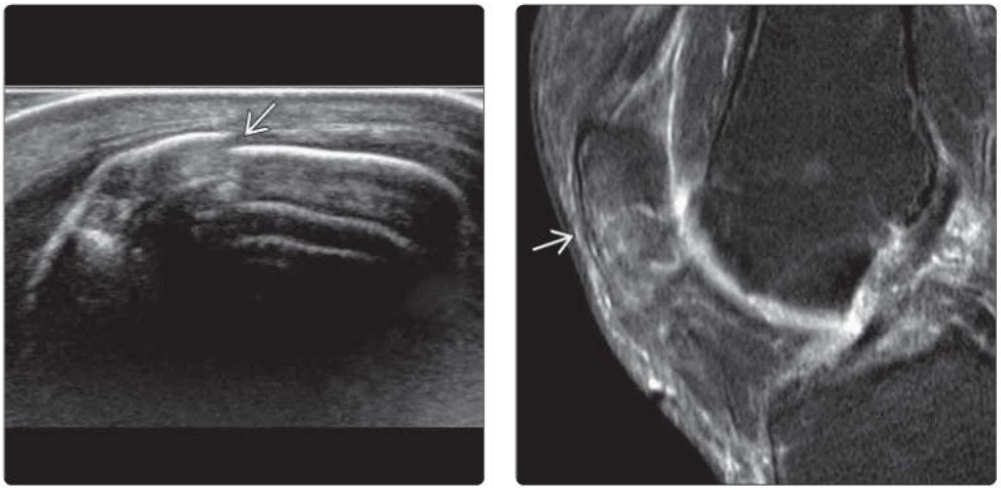

(Left) *Longitudinal US in a 66-year-old woman with knee pain following a fall shows a minimally displaced fracture of the patella ➡, which was not apparent on radiographs (not shown).* **(Right)** *Sagittal T2 FS MR of the same knee confirms the patellar fracture ➡ with a hyperintense thin fracture line and mild patellar bone marrow edema (image slightly degraded by mild movement artifact). Radiographically occult patellar fractures are not uncommonly found on US.*

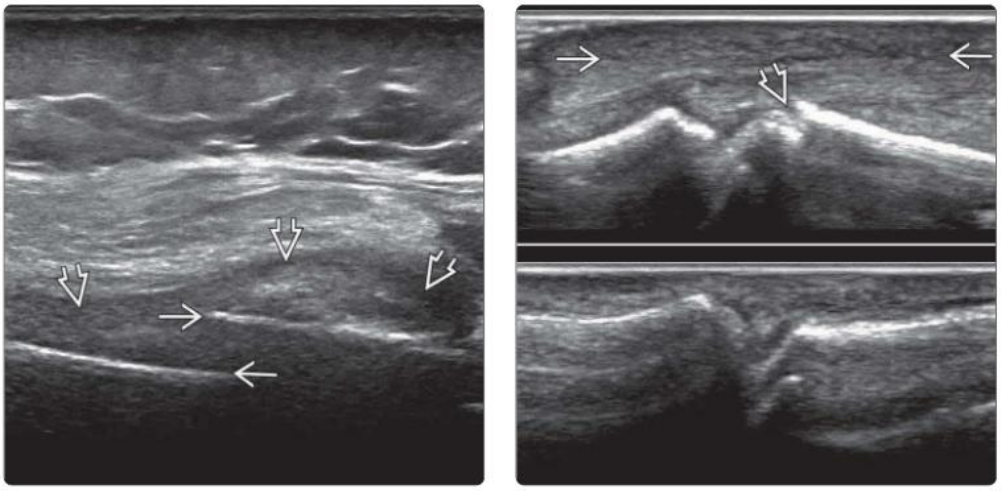

(Left) *Longitudinal US of distal femoral fracture with a cortical step ➡, and a fairly smooth adjacent soft tissue mass ➡ without vascularity (not shown), compatible with a hematoma is shown.* **(Right)** *Longitudinal US dorsal aspect of injured left (top) and normal right (bottom) middle finger at DIP is shown. Note mild soft tissue swelling ➡ and fracture of the injured proximal phalangeal head ➡, which was occult radiographically but confirmed on CT. Mild flexion can improve fracture conspicuity.*

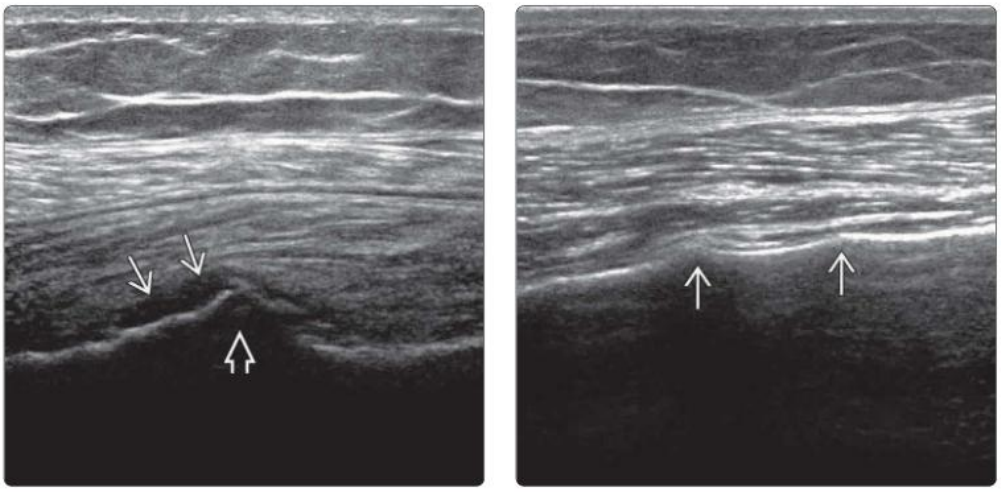

(Left) *Longitudinal US of lateral aspect of the proximal femoral shaft in an older adult patient with thigh pain shows an osseous spike ➡ with a thin, hypoechoic rim ➡ due to unossified callus. This is consistent with an insufficiency fracture, associated with chronic bisphosphonate therapy and atypical subtrochanteric fracture.* **(Right)** *Longitudinal US of another older adult patient shows 2 similar, though smaller, fractures ➡. These fractures should be further assessed by radiography ± CT or MR.*

(Left) *Transverse US shows an echogenic rim of thickened periosteum around the 2nd metatarsal shaft. This is consistent with a stress fracture. The normal 3rd metatarsal shaft is also shown for comparison.* **(Right)** *Longitudinal color Doppler US of the same patient shows mild hyperemia around the thickened periosteum. Normal nonthickened periosteum is not visible on US. US is more sensitive than radiography at detecting early metatarsal stress fracture.*

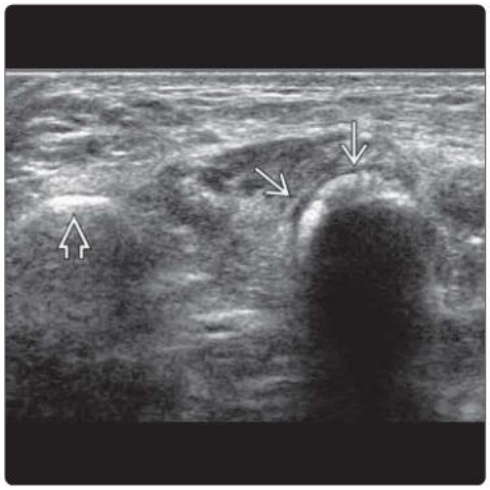

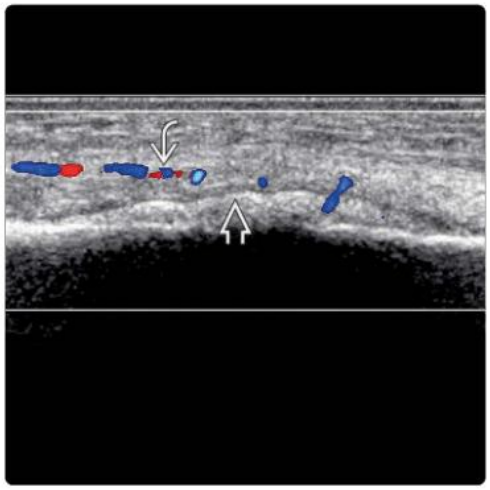

(Left) *Dorsoplantar radiograph of the foot in the same patient performed at the same time as US examination shows no radiographic evidence of a stress fracture, particularly in the 2nd metatarsal shaft.* **(Right)** *Dorsoplantar radiograph of the same foot 2 months later shows unequivocal focal cortical thickening in the 2nd metatarsal shaft, consistent with a stress fracture. No other imaging was obtained.*

(Left) *Longitudinal US of the 2nd metatarsal of a patient with resolved midfoot pain from a few months prior is shown. In contrast to the previous cases of stress fracture, this case shows long, smooth cortical bump along diaphysis without callus, soft tissue, or hyperemia (not shown), suggestive of an old, healed stress reaction.* **(Right)** *Dorsoplantar radiograph of the same patient shows corresponding smooth, circumferential periosteal thickening with a small cortical defect at the proximomedial aspect.*

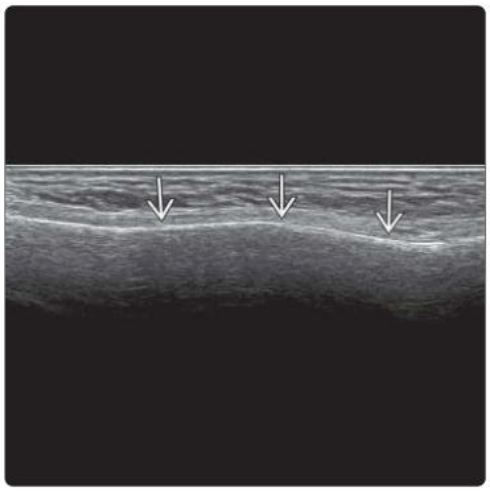

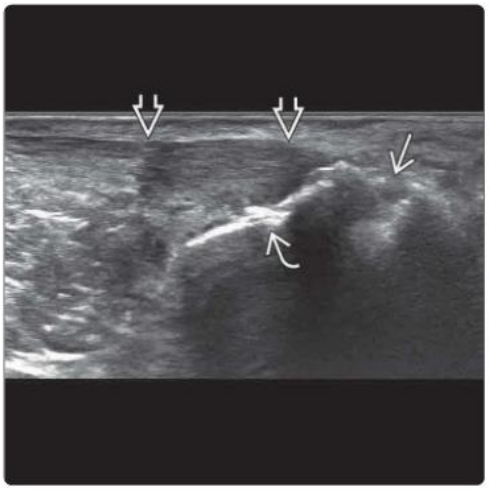

(Left) *Clinical photograph of a middle-aged patient with a football injury shows local swelling and ecchymosis ⇨ of the posterior heel. No clinically palpable gap of the Achilles tendon was apparent.* **(Right)** *Longitudinal US of the same patient shows an apparent intact Achilles tendon ⇨; however, there is a small cortical gap ⇨ and surrounding irregularity ⇨ at the posterosuperior calcaneal bony attachment, suggestive of an avulsion fracture.*

(Left) *Lateral radiograph of the same patient confirms a small, mildly superiorly displaced avulsion fracture of the Achilles calcaneal insertion ⇨ with a small fracture gap ⇨, closely correlating to the US findings.* **(Right)** *Frontal radiograph shows a mildly displaced transverse pathologic fracture ⇨ of the midhumeral shaft in a patient with no known primary tumor.*

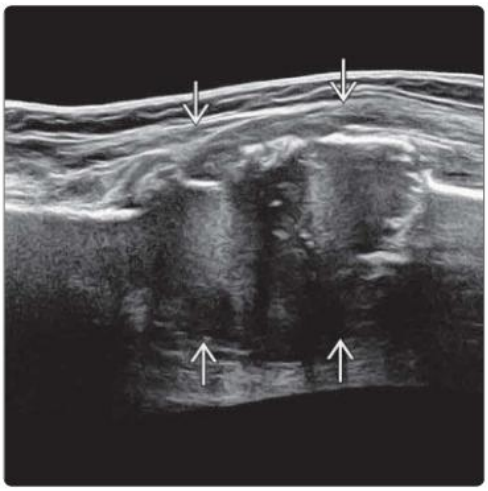

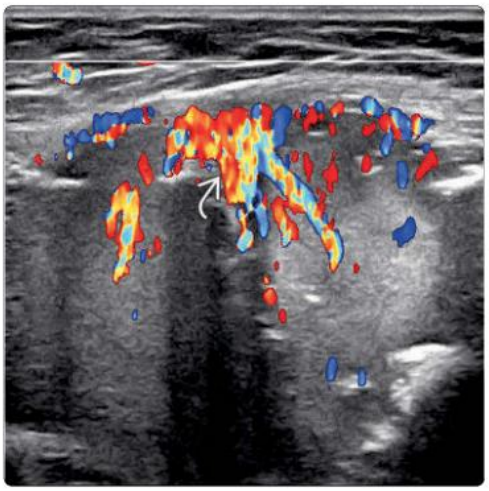

(Left) *Extended field-of-view US in the same patient shows a large, pathologic-type fracture in the midshaft of the humerus with irregular cortical osteolysis and mild osseous expansion ⇨.* **(Right)** *Transverse color Doppler US of the same tumor shows marked intralesional hyperemia ⇨, confirming the presence of a viable tumor rather than a hematoma. Biopsy confirmed metastatic adenocarcinoma, most likely of lung origin.*

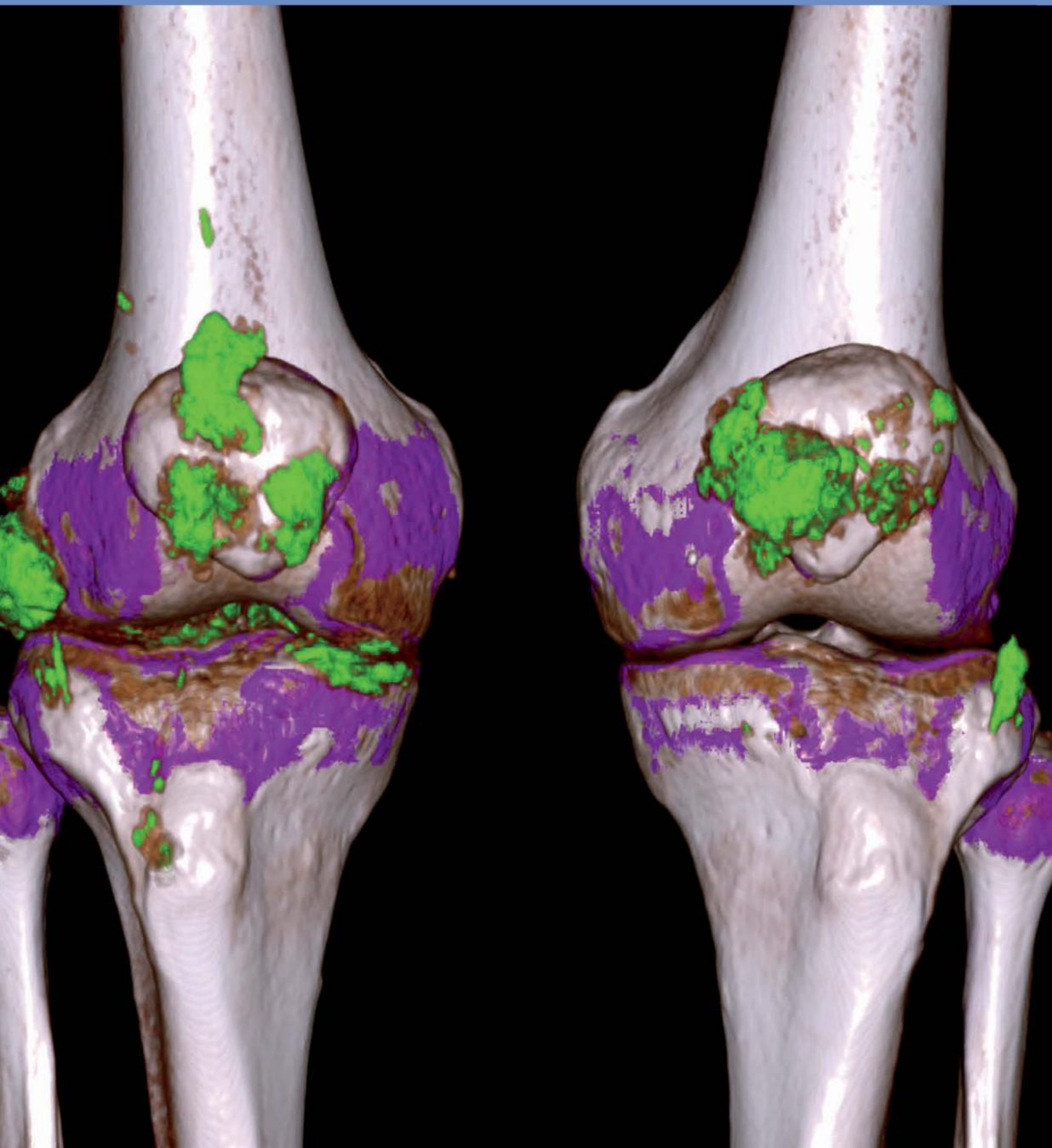

PART III
SECTION 3

Arthropathies

Osteoarthritis	546
Inflammatory Arthritis	554
Gout and Pseudogout	564
Developmental Hip Dysplasia	572

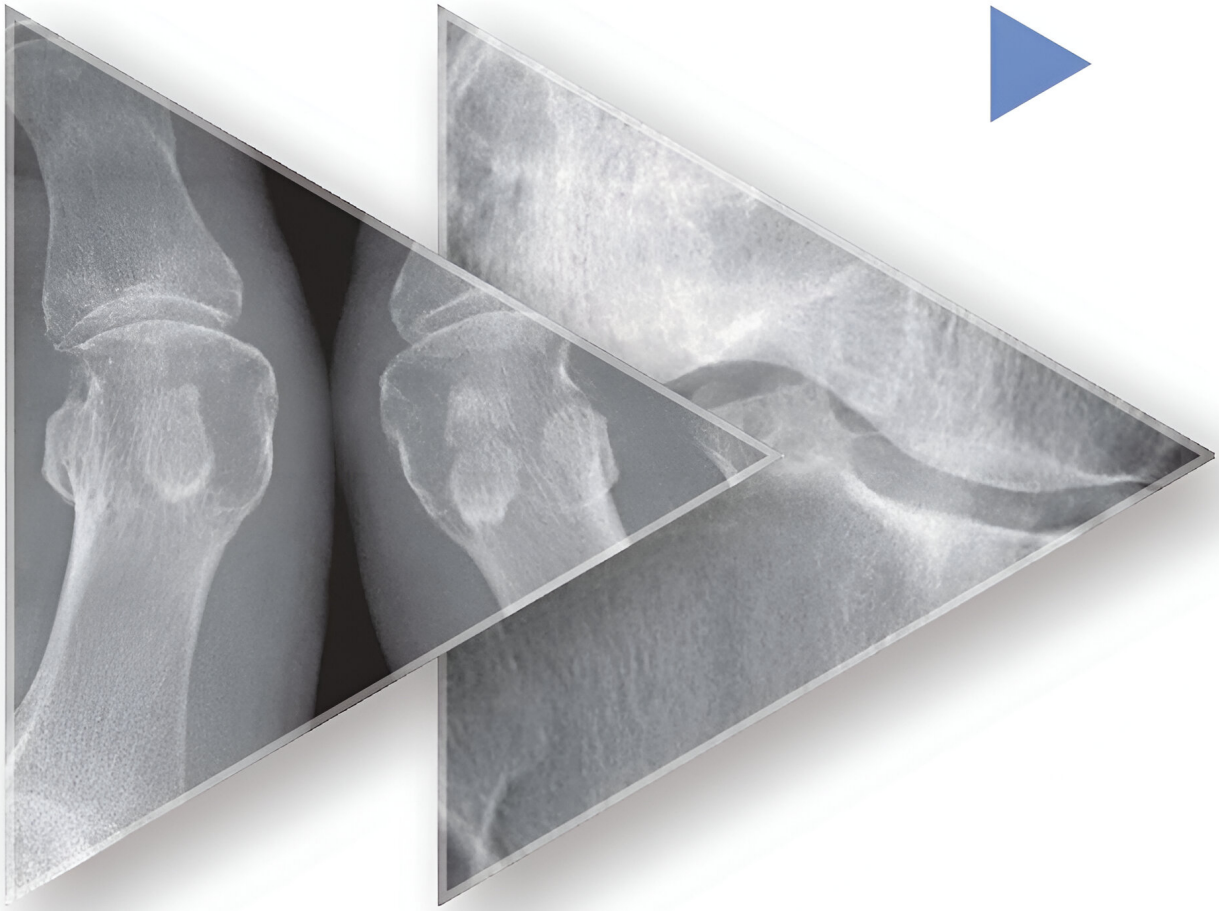

KEY FACTS

TERMINOLOGY

- Osteoarthrosis, osteoarthropathy, degenerative joint disease

IMAGING

- Joint space narrowing, marginal osteophytosis, capsular swelling, synovitis, & effusion are US signs of OA
- Most commonly affects knee, hip, finger, 1st carpometacarpal, triscaphe, wrist, acromioclavicular & tarsal joints
- US is increasingly used to determine inflammatory component of OA & differentiate OA from crystal deposition disease or inflammatory arthropathy
- Inflammatory element of OA is characterized by
  - Capsular swelling
  - Joint effusion
  - Synovial proliferation
  - Synovial & pericapsular hyperemia
  - Edema of periarticular soft tissues

CLINICAL ISSUES

- Only modest correlation between US severity of OA & clinical symptoms

DIAGNOSTIC CHECKLIST

- US is best for assessing degree of synovitis
  - Size of effusion, degree of synovial proliferation, & level of hyperemia to gauge inflammatory component of OA
  - Presence of echogenic comet-tail artifacts as indicator of crystal arthropathy
  - Joint aspiration to check for crystals or infection
- Useful for guiding needle placement for joint aspiration, therapeutic injection, or synovial biopsy
- Degree of inflammatory component helps differentiate inflammatory-type OA from inflammatory arthropathy
  - Less pronounced in OA & commensurate with severity of underlying OA
  - Inflammatory arthropathy associated with more pronounced synovial proliferation ± active synovitis

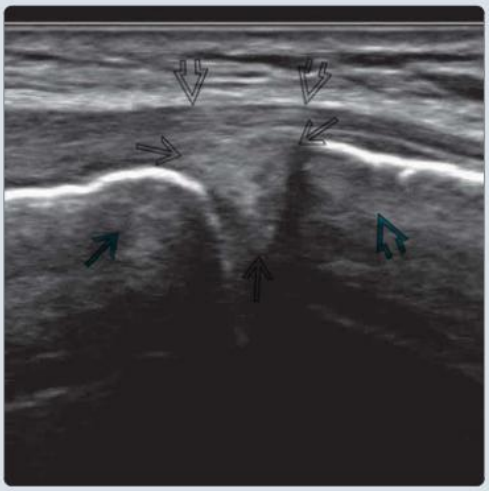

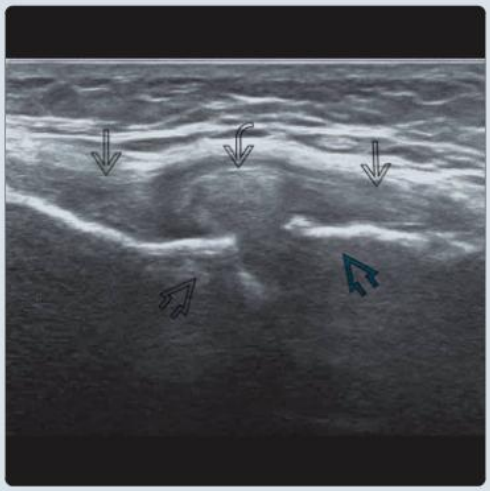

(Left) *Longitudinal US of a normal medial tibiofemoral joint line is shown. Note the lack of osteophytes, preserved triangular and nonextruded medial meniscus, and normal nondisplaced medial collateral ligament (MCL) (femur, tibia).* **(Right)** *Longitudinal US of the medial knee joint shows severe extrusion of the meniscal body displacing the MCL superficially. There is moderate to severe joint space narrowing between the medial femoral and tibial condyles. Note relative lack of osteophytosis.*

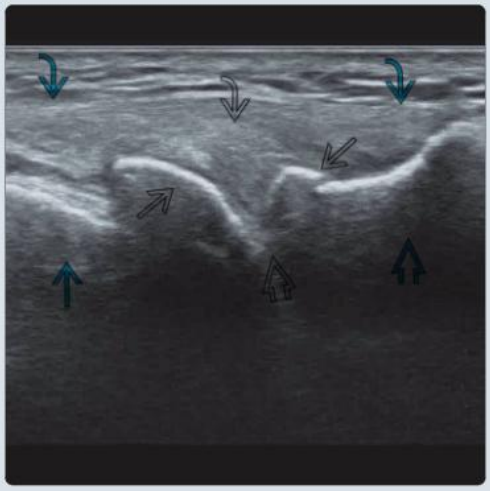

(Left) *Longitudinal US of the medial knee joint shows another extruded meniscal body. In contrast to the previous case, there is severe marginal osteophytosis and joint space narrowing. The body is the best visualized portion of the meniscus by US.* **(Right)** *Longitudinal US of the lateral tibiofemoral joint line shows moderate osteoarthritis (OA) with moderate marginal osteophytes, moderate meniscal extrusion, and moderate to severe joint space narrowing. Note femur, tibia, and iliotibial band.*

TERMINOLOGY

Abbreviations

- Osteoarthritis (OA)

Definitions

- Degenerative disease with thinning of articular cartilage & associated bone change, soft tissue change, positional change, & inflammation
  - Bone change: Osteophytosis, cortical irregularity, subchondral reactive changes (edema, cyst formation, sclerosis, attenuation)
  - Soft tissue change: Usually mild synovial proliferation, capsular swelling, joint effusion
  - Positional change: Joint subluxation ± misalignment
  - Inflammation: Variable degree of inflammation present
- Secondary: Accelerated OA due to existing joint disorder

IMAGING

General Features

- Best diagnostic clue
  - Articular cartilage thinning accompanied by marginal osteophytosis, subchondral sclerosis, cyst formation ± inflammatory component
- Location
  - Most commonly affects knee, hip, finger, 1st carpometacarpal, triscaphe articulation, wrist, acromioclavicular & tarsal joints
  - May affect only localized area or whole of joint

Radiographic Findings

- Radiography is primary screening modality for OA
  - Joint space narrowing (JSN), subchondral sclerosis/cysts, osteophytes
  - Malalignment (e.g., mild subluxation → severe genu varum)
  - Focal cartilage loss may have no JSN radiographically
  - Consider load bearing for more representative assessment

MR Findings

- T1WI
  - Cartilage thinning, subchondral sclero-cystic change, marrow fat signal extending into osteophytes
- Fluid sensitive
  - Subchondral edema
  - Joint effusion ± intraarticular debris
  - Reactive-type synovitis, usually mild
  - Periarticular edema

Ultrasonographic Findings

- Increasingly used to determine inflammatory component of OA & differentiate OA from crystal or inflammatory arthropathy
  - Radiography can determine presence of OA, but US can reveal inflammatory component
  - One can also detect OA when US performed for other suspected pathology
- JSN, marginal osteophytosis, capsular swelling, synovitis, & effusion
  - Focal cartilage thinning or defects cannot be fully evaluated with US
  - JSN of some joints (e.g., patellofemoral) may not be readily appreciable
- Joint effusion
  - May be anechoic if simple, or slightly echogenic if longstanding or with debris
  - US can detect radiographically occult intraarticular debris
  - Central aspects of joint not fully visualized with US
  - Medial & lateral patellar recesses of knee usually distend prior to suprapatellar recess
- Inflammatory element is characterized by
  - Capsular swelling
  - Joint effusion
  - Synovial proliferation (synovial thickening & fronds)
    - Important sign of OA inflammatory component
    - Mild synovial proliferation is common finding in OA
  - Pericapsular & synovial hyperemia on color Doppler
    - Not very sensitive sign in OA
    - Color Doppler imaging is often negative, even with inflammatory component present in OA
      - Due to low-grade inflammation generally associated with OA
    - Capsular-synovial hyperemia is difficult to depict in deeper joints, such as hip, shoulder, & even knee
  - Echogenic foci due to proteinaceous aggregates, debris, or crystals
    - Calcium pyrophosphate deposition (CPPD) common accompaniment of moderate to severe OA
  - Edema of periarticular tissues (MR better than US)
- Clinical picture, radiographic findings, & degree of inflammatory component helps differentiate inflammatory-type OA from inflammatory arthropathy
  - Inflammatory arthropathy has more pronounced synovial proliferation & inflammation
    - ± erosions & other clinical/radiographic features of inflammatory arthropathy
- Joint subluxation can be exaggerated on US as dependent on transducer angulation & alignment
- Medial meniscal extrusion is common feature in moderate to severe medial femorotibial OA
- Associated Baker cysts, parameniscal cysts, or ganglia identified by US with high level of accuracy
  - Inflammatory component, crystal aggregates, & synovial debris can extend into Baker cysts & ganglia
- US-guided joint aspiration is helpful to exclude infective, inflammatory arthropathy or crystal deposition disease
  - < 1,000-WBC/μL synovial fluid is indicative of OA (normally ~ 200 WBC/μL)
  - > 5,000-WBC/μL synovial fluid is indicative of acute inflammatory or infective arthropathy
  - Specimen for crystal identification should be sent fresh, as alcohol will dissolve crystals

Imaging Recommendations

- Best imaging tool
  - US for assessing degree of synovitis & guiding intraarticular needle placement
  - MR for assessing chondral & subchondral damage
- Protocol advice
  - Examine joints in systematic fashion
  - Use varying degree of flexion or internal/external rotation to maximize cartilage visibility

- Use minimal transducer pressure to avoid effacing effusions & blanching color Doppler signal
- Assess JSN & marginal osteophytosis as well as medial meniscal extrusion (knee)
- Assess degree of synovial effusion & echogenicity, degree of synovial proliferation, & hyperemia
- Assess degree of capsular swelling, periarticular edema, bursa, & cysts
- Can semiquantitatively grade synovial hyperemia on color Doppler imaging
  - Grade 0: No flow
  - Grade 1: Up to 3 color signals
  - Grade 2: > 3 color signals, but < 50% of synovial area shows color signal
  - Grade 3: > 50% of synovial area shows color signal
- Circumferential collagen bundle damage → impaired ability to resist hoop strain (circumferential stress) → meniscal extrusion
- Can measure degree of medial meniscal extrusion in supine & standing positions
  - Degree of extrusion beyond line joining outer margins of femoral & tibial condyles (excluding osteophytes)
    - Normal < 2 mm, increasing to < 3 mm on standing
    - OA often > 4 mm, increasing to > 5 mm on standing

DIFFERENTIAL DIAGNOSIS

Inflammatory Arthritis

- Signs of symmetrical disease ± positive serologic markers
- Degree of synovitis is more than expected for degree of OA present ± presence of erosions

Crystal Deposition Disease

- Echogenic foci within synovial fluid, synovium, articular cartilage, tendon, ligament, or menisci
- Otherwise similar to acute OA exacerbation
  - ± discrete hard or soft tophi
  - US-guided aspiration for crystals

Focal Chondral Injury

- Best assessed with MR

PATHOLOGY

General Features

- Etiology
  - Common risk factors are age, sex, prior joint injury, obesity, genetic predisposition, congenital dysplasia, & mechanical factors, such as malalignment
  - Primary & secondary OA may be different diseases with common final pathway
  - Secondary OA often explained by overload paradigm ("wear & tear")
  - Primary OA does not always reconcile with overload paradigm, e.g., common in sedentary individuals
    - Diminished synovial clearance of normal joint enzymes
    - Closed, positive feedback loop modulates joint enzymatic level & activity
  - Meniscal degeneration & extrusion has etiologic role in knee OA

Staging, Grading, & Classification

- Kellgren and Lawrence system for OA (radiography)
  - 0: None
  - I: Doubtful: Doubtful JSN possible osteophytic lipping
  - II: Minimal: Definite osteophytes, possible JSN
  - III: Moderate: Multiple moderate osteophytes, definite JSN, some sclerosis, possible bone end deformity
  - IV: Severe: Large osteophytes, marked JSN, severe sclerosis, definite bone end deformity

CLINICAL ISSUES

Presentation

- Most common signs/symptoms
  - Pain aggravated by movement & joint swelling
  - Only modest correlation between US severity of OA & clinical symptoms
- Clinical profile
  - Catching, locking, or grinding in older patient

Demographics

- Age
  - Typically older patients (> 50 years)
- Sex
  - Female predominance; accelerated joint degeneration occurs after menopause

Natural History & Prognosis

- Progressive, debilitating disease

Treatment

- Conservative
  - Minimize overloading, e.g., weight loss
  - Muscle strengthening
  - Pain management by oral/ topical analgesics or NSAIDs
  - Glucosamine & chondroitin by oral supplements
  - Intraarticular aspiration ± injection
    - Steroid
    - Viscosupplementation (e.g., hyaluronic acid)
    - US modest at predicting clinical response
      - In general, more severe arthropathy on US, less sustained clinical response
- Surgical
  - Arthroscopy (debridement)
  - Resurfacing procedure (hip or knee)
  - Tibial osteotomy to redistribute weight-bearing load
  - Prosthetic joint replacement

DIAGNOSTIC CHECKLIST

Consider

- Size of effusion, degree of synovial proliferation, & level of hyperemia to gauge inflammatory component of OA
- Presence of crystals/ tophi in crystal arthropathy
- Joint aspiration or synovial biopsy to exclude infection or crystals

SELECTED REFERENCES

1. Chalian M et al: What is new in osteoarthritis imaging? Radiol Clin North Am. 62(5):739-53, 2024
2. Nevalainen MT et al: The ultrasound assessment of osteoarthritis: the current status. Skeletal Radiol. 52(11):2271-82, 2023

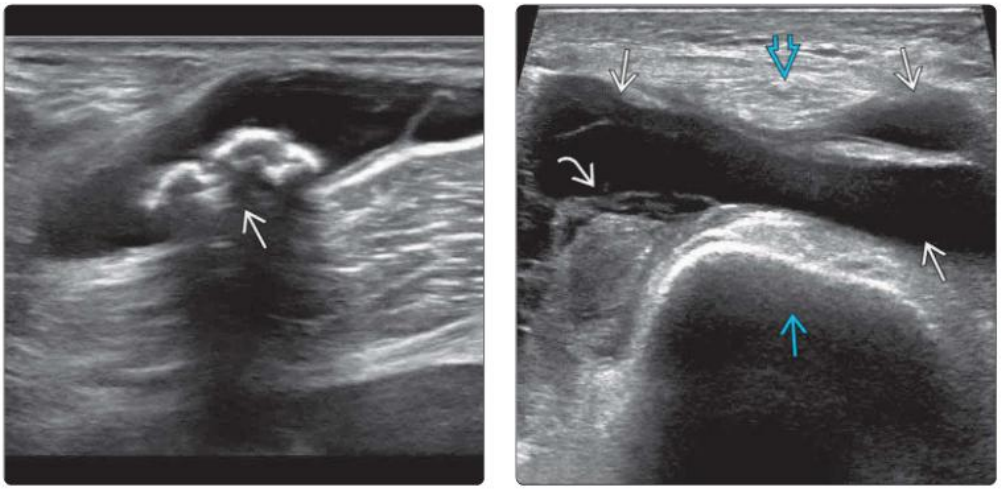

(Left) *Longitudinal US of a patient with severe knee OA shows a calcified body within Baker cyst, which is most likely due to a growing osseous fragment or osteochondral fragment from the knee joint. The same pathology is often seen in Baker cyst as in the knee joint.* **(Right)** *Transverse US of the suprapatellar knee in a patient with moderate OA shows a large joint effusion with mild synovial proliferation. Note femur and quadriceps tendon.*

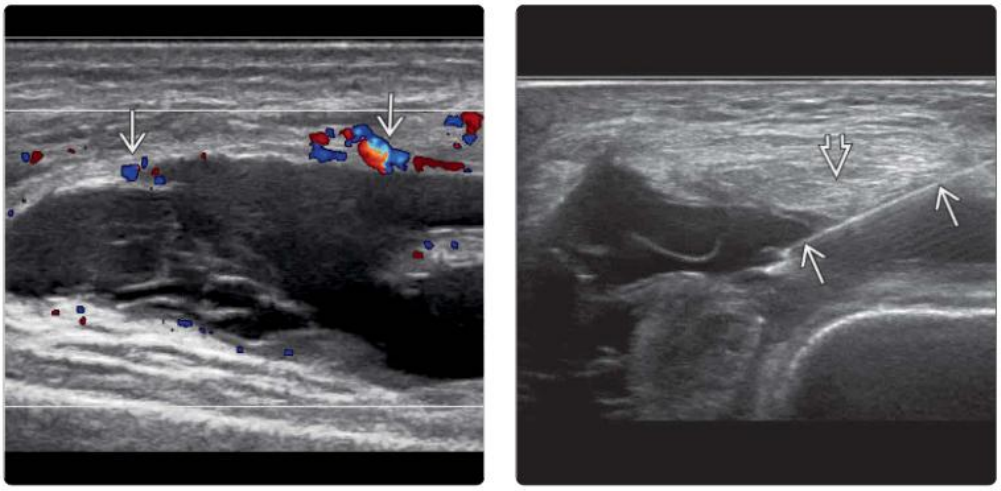

(Left) *Color Doppler US of the same patient shows moderate capsular hyperemia indicating active synovitis. US is useful in determining whether knee swelling is due to effusion or synovial proliferation and whether there is active inflammation.* **(Right)** *Transverse US of the same patient during joint aspiration is shown. The needle is inserted at the anteromedial suprapatellar region and advanced under the quadriceps tendon.*

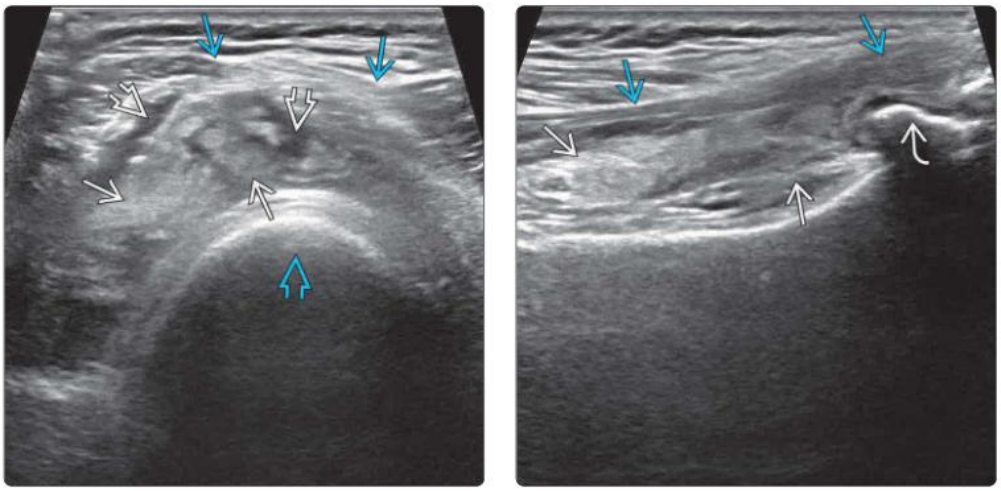

(Left) *Transverse US of the suprapatellar region in a patient with knee OA and increasing swelling is shown. In contrast to the previous cases, this US clearly depicts extensive synovial proliferation as the main cause for swelling with only minimal effusion (femur, quadriceps expansion).* **(Right)** *Longitudinal US of the same patient shows the craniocaudal extent of severe synovial proliferation with minimal effusion. Note the large superior trochlear osteophyte and quadriceps tendon.*

(Left) *Clinical photograph shows swelling (Bouchard node) and mild flexion deformity of the middle finger proximal interphalangeal (PIP) joint (PIPJ). Heberden nodes are similar nodes at the distal interphalangeal (DIP) joint (DIPJ).* **(Right)** *Longitudinal US of the same patient's middle finger dorsal PIPJ shows moderate marginal osteophytes along the head of the proximal phalanx and base of the middle phalanx with mild synovial thickening but without joint effusion.*

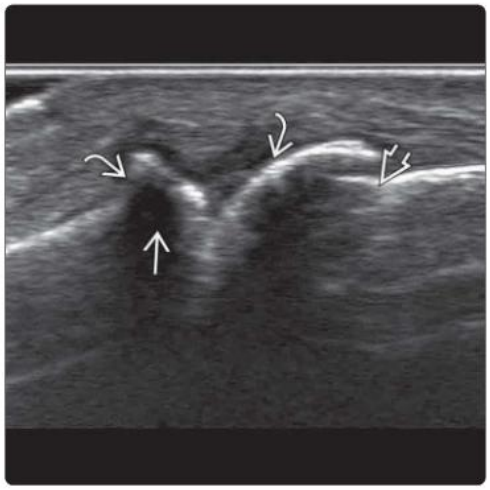

(Left) *Longitudinal US of the same middle finger PIPJ, but now at the volar aspect, again shows moderate marginal osteophytes and slightly more pronounced synovial thickening. Flexor digitorum tendon passing over the joint is preserved.* **(Right)** *Longitudinal US of the same patient's middle finger dorsal DIPJ showing much less pronounced OA changes with only minimal osteophytic lipping.*

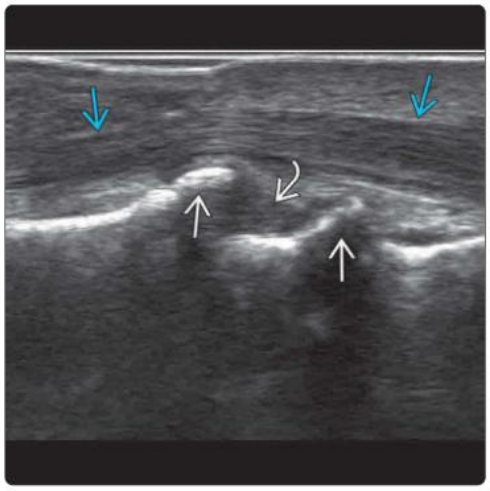

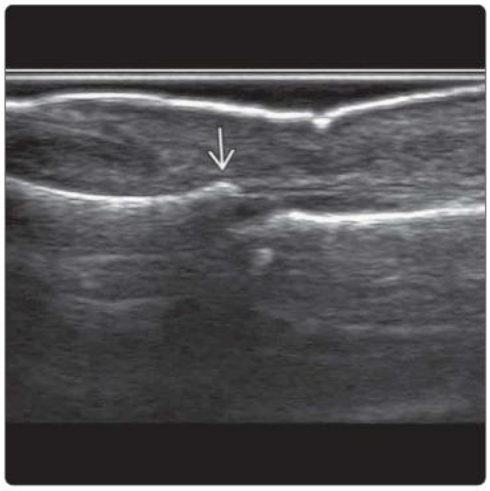

(Left) *Longitudinal US of the volar aspect of the thumb base is shown: 1st metacarpal base, trapezium, scaphoid, radius. There is severe 1st carpometacarpal joint (CMCJ) OA with large trapezium osteophyte, cortical irregularity, and synovial thickening.* **(Right)** *Longitudinal US of the volar aspect of the thumb CMCJ shows severe OA with prominent osteophytosis. Note 1st metacarpal and trapezium.*

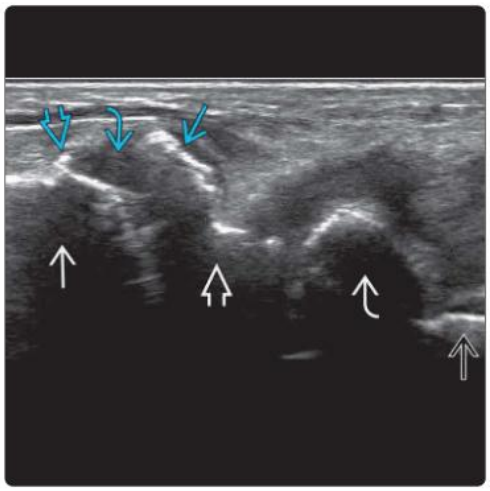

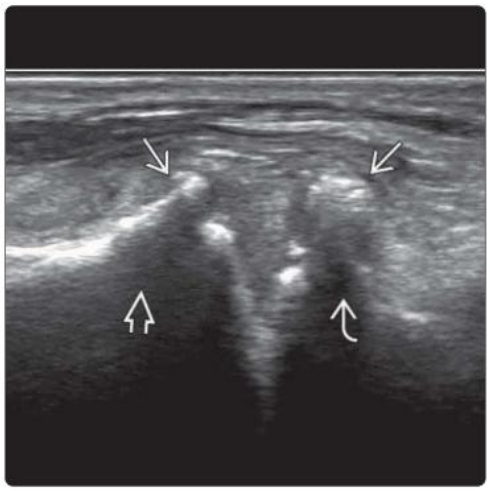

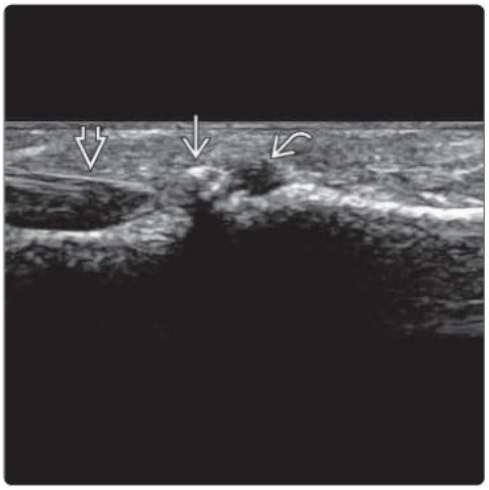

(Left) *Clinical photograph shows swelling (Heberden node) and mild flexion deformity of the DIPJ. Bouchard nodes are similar nodes at the PIPJ.* **(Right)** *Longitudinal US of the same case shows prominent marginal osteophytosis of the dorsal DIPJ with mild capsular swelling. Finger flexion may help to better show the dorsal DIPJ joint space and articular surfaces. The nail overlies the distal phalanx.*

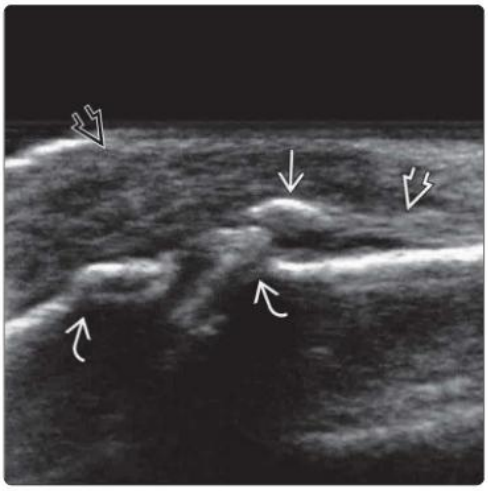

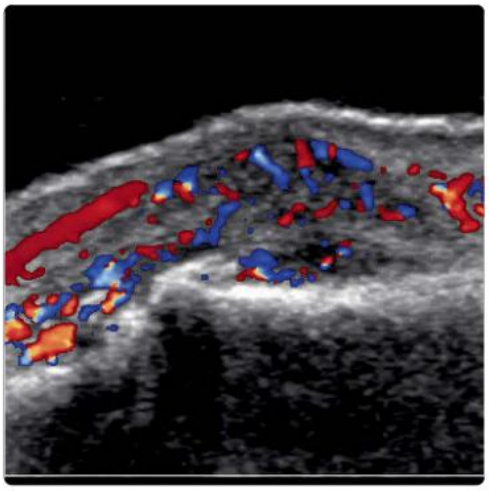

(Left) *Longitudinal US of a patient with recent trauma to the finger shows moderate PIPJ OA with prominent dorsal osteophytosis and a small avulsion fracture, which is attached to the extensor expansion. There is marked dorsal swelling.* **(Right)** *Color Doppler US shows marked periarticular hyperemia dorsally. Osteoarthritic osteophytes can fracture with resultant periarticular inflammation.*

(Left) *Longitudinal US of the acromioclavicular joint shows mild OA with osteophytic lipping, mild capsular thickening, and a few tiny echogenic intraarticular debris.* **(Right)** *Longitudinal color Doppler US of another acromioclavicular joint shows severe capsular swelling with moderate hyperemia, consistent with acute-on-chronic, inflammatory-type OA. Effusion within the acromioclavicular joint is rarely seen, making it more difficult to separate the capsule from the synovium.*

(Left) *Clinical photograph shows moderate swelling of the right sternoclavicular joint (SCJ). Its superficial location means any disfiguration will be readily apparent clinically. This joint is very accessible to US.* **(Right)** *Transverse color Doppler US of the same SCJ shows severe capsular thickening with mild hyperemia, without erosive component. Distinction from an inflammatory arthropathy is best made on clinical and serologic grounds, as CT or MR are often unhelpful in this context (clavicle, manubrium).*

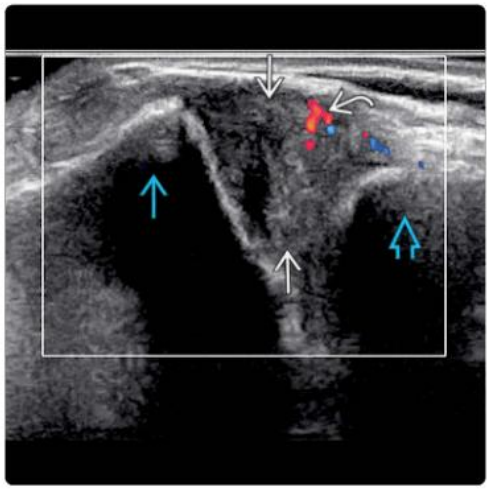

(Left) *Transverse US shows moderate right and mild left SCJ capsular thickening. Such dual-screen layout is useful for direct contralateral comparison in cases with subtler changes.* **(Right)** *Clinical photograph of a patient presenting with long history of gradual increasing swelling at the dorsal midfoot region.*

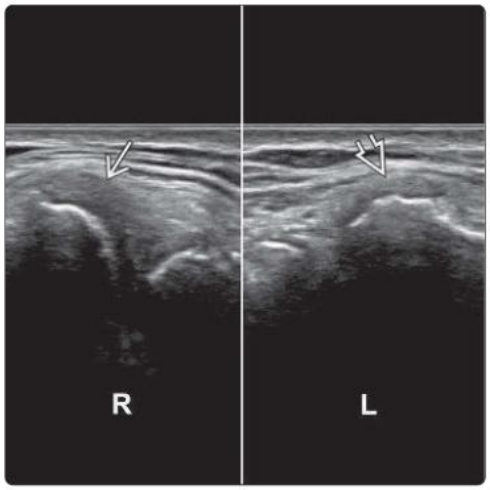

(Left) *Longitudinal US of the same patient reveals prominent osteophytes at the 1st tarsometatarsal joint (TMTJ) as the main cause of dorsal foot swelling with a small joint effusion and mild capsular thickening. Note talus, navicular, medial cuneiform, 1st metatarsal base.* **(Right)** *Color Doppler US of the same patient shows moderate capsular and pericapsular hyperemia around the 1st TMTJ consistent with active inflammation. Note medial cuneiform, 1st metatarsal base.*

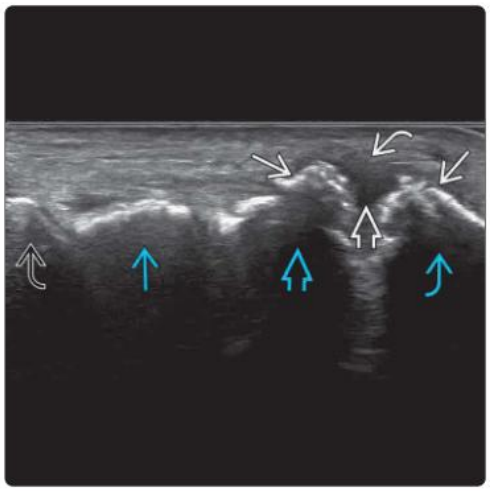

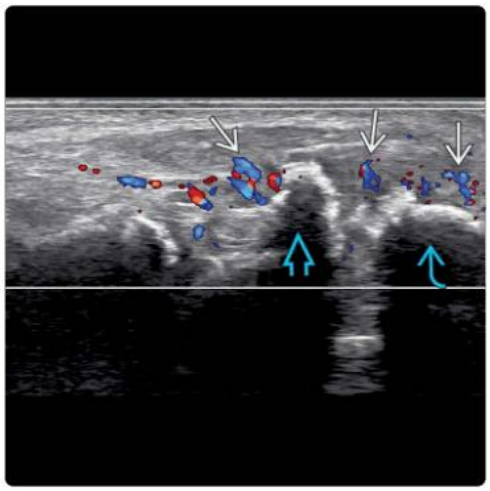

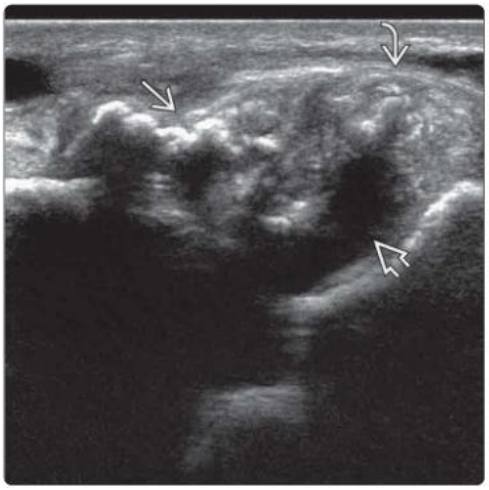

(Left) *Clinical photograph of a diabetic patient with progressive ankle swelling shows severe deformity.* **(Right)** *Longitudinal US in the same patient shows severe ankle arthropathy with chronic synovial thickening, osseous fragmentation, debris, and a small effusion. Possibilities include either a diabetic neuroarthropathy or, less likely, a tuberculous arthropathy. US-guided synovial biopsy revealed acute-on-chronic inflammation but no evidence of infection.*

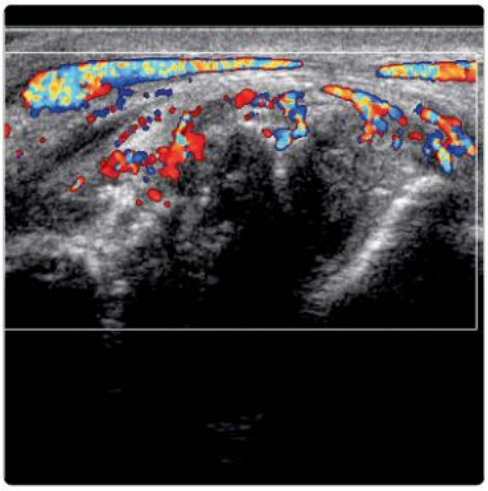

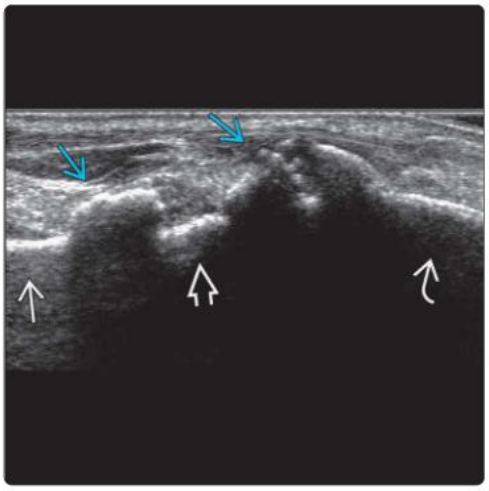

(Left) *Longitudinal color Doppler US in the same patient shows moderate periarticular hyperemia. The appearances are consistent with subacute exacerbation of diabetic neuroarthropathy.* **(Right)** *Longitudinal US in a patient with lateral foot pain shows severe hypertrophic-type OA with large marginal osteophytes at the effaced calcaneum/cuboid joint proximally and the cuboid/5th metatarsal base joint distally. There is little surrounding inflammation.*

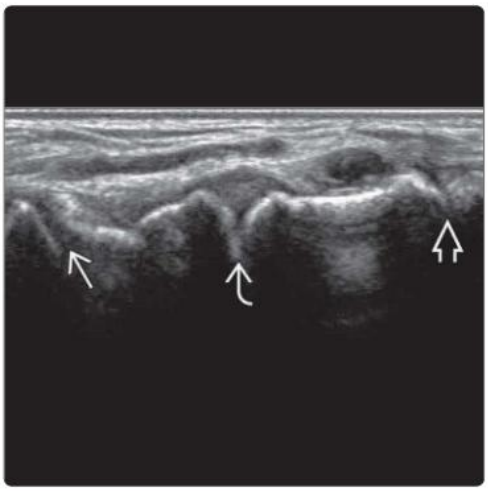

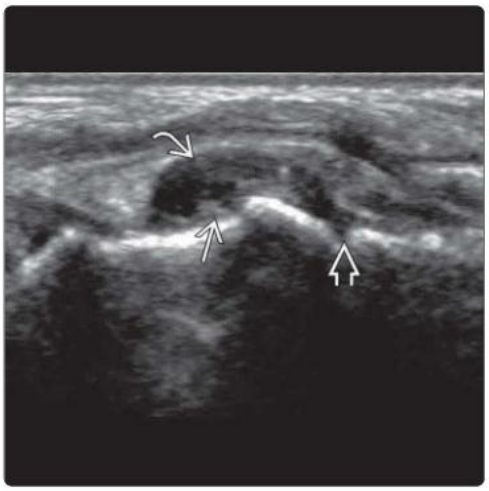

(Left) *Longitudinal US in a patient with medial midfoot pain shows overall mild to moderate OA with joint space narrowing, capsular swelling, and marginal osteophytosis at the talonavicular, navicular-cuneiform, and 2nd TMT articulations.* **(Right)** *Longitudinal US of the same patient shows a medium-sized paraarticular ganglion of the 2nd TMTJ dorsally. Synovial proliferation is present within this paraarticular ganglion.*

KEY FACTS

TERMINOLOGY

- Systemic autoimmune inflammatory disorders of synovium with secondary involvement of articular surface & bone
- Spondyloarthritis associated with enthesitis

IMAGING

- Mono- to oligo- to polyarthropathy
- Thickened hyperemic synovium
  - Can affect any synovial-lined joint or tendon sheath
  - Wrist joint > small joints of hand & feet
- **Effusion**
  - Sensitive though nonspecific indicator of synovitis
- **Thickened synovium (pannus)**
  - Most common finding in inflammatory arthropathy
  - Hypoechoic > hyperechoic
  - Synovial proliferation & hyperemia = active inflammation
  - US 10x more sensitive than clinical examination at detecting early synovitis
- **Marginal bony erosion**
  - Affects bare areas
  - Juxtaarticular cortical defects ± adjacent synovitis
  - US detects 6x more MCP joint erosions than radiography
  - 30% false-positive rate for US detection of erosions
- **Cartilage loss**
  - US good but best assessed with radiography or MR
- **Periarticular soft tissue changes**
  - Tenosynovitis, nerve entrapment, bursitis, rheumatoid nodules, & peripheral enthesopathy
- **Color Doppler**
  - Allows activity of synovitis to be assessed
  - Active synovitis shows high flow; inactive synovitis = low/absent flow

SCANNING TIPS

- Minimal probe pressure during color Doppler to avoid masking synovial hyperemia
- Utilize probe and joint positioning to maximize cartilage visualization

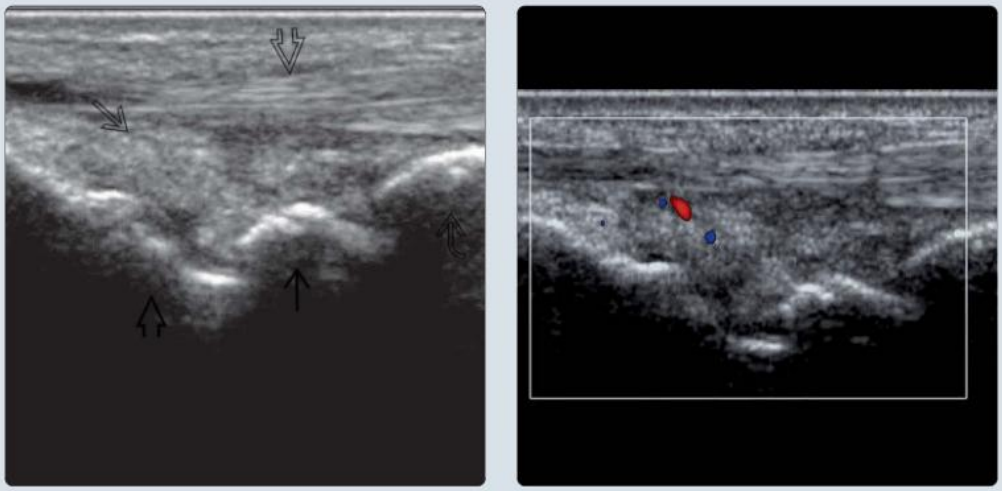

(Left) *Longitudinal US shows moderate hyperechoic synovial proliferation ⇨ on the dorsum of the carpus deep to the extensor tendons ⇨. The distal end of the radius ⇨, the lunate ⇨, and the capitate ⇨ are shown.* **(Right)** *Longitudinal color Doppler US of the same area shows mild synovial hyperemia. This is indicative of low-level synovial inflammatory activity.*

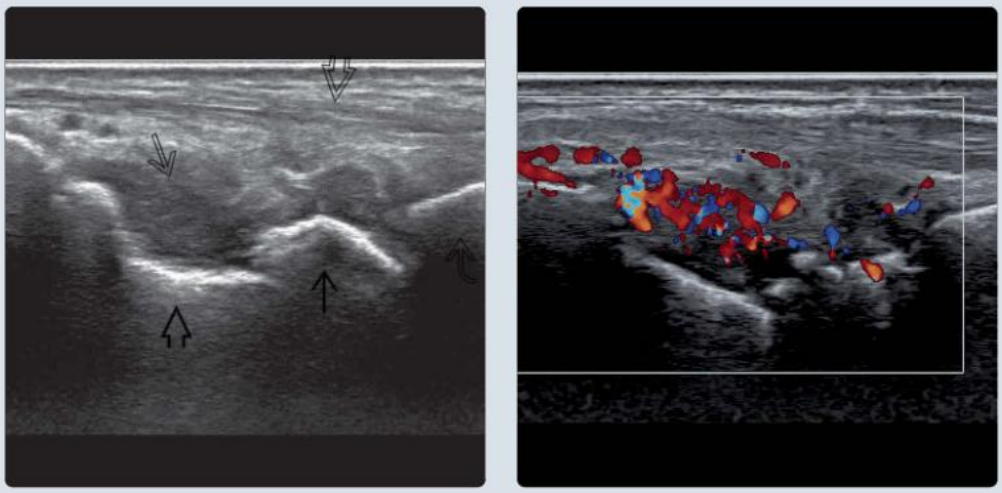

(Left) *Longitudinal US shows quite severe, largely hypoechoic synovial proliferation ⇨ on the dorsum of the carpus deep to the extensor tendons ⇨. The distal end of the radius ⇨, the lunate ⇨, and the capitate ⇨ are shown. Hypoechoic synovium is more edematous than hyperechoic synovium.* **(Right)** *Longitudinal color Doppler US of the same area shows severe synovial hyperemia. This is indicative of high-level synovial inflammatory activity.*

TERMINOLOGY

Synonyms

- Rheumatoid arthritis (RA), juvenile inflammatory arthropathy, systemic lupus erythematosus (SLE), psoriatic arthropathy, spondyloarthroarthritis (SpA)

Definitions

- Systemic autoimmune inflammatory disorders primarily affecting either synovium or enthesis with secondary involvement of articular surface & bone

IMAGING

General Features

- Best diagnostic clue
  - Thickened, hyperemic synovium & tenosynovium ± erosions ± joint space narrowing
  - Hyperostosis, cortical irregularity, soft tissue thickening, & hyperemia at entheses in SpA
- Location
  - Any synovial-lined joint, tendon sheath, or enthesis
  - Wrist > carpometacarpal, metacarpophalangeal (MCP), metatarsophalangeal (MTP), & interphalangeal joints
  - Elbow, shoulder, hip, knee, ankle, intertarsal joints
- Size
  - Multiple (polyarthropathy) > few (oligoarthropathy) > single (monoarthropathy) joints involved
- Morphology
  - Synovial proliferation → osteitis → erosions
  - Synovial proliferation → cartilage damage → joint space narrowing → deformity & subluxation → ankylosis
  - Enthesitis → osteitis → entheseal cortical resorption & hyperostosis

Radiographic Findings

- Radiography
  - Usually normal in early stages of disease
  - Soft tissue swelling, juxtaarticular osteopenia, joint space narrowing, bone erosion
    - Pattern and distribution of disease offers more clue to diagnosis than individual radiographic signs
  - Joint obliteration & ankylosis, particularly of carpus
  - Arthritis mutilans & joint deformity ("swan neck," "boutonniere") less common nowadays with advent of disease-modifying therapy

MR Findings

- T1WI
  - More sensitive at depicting early bony erosions against background of hyperintense fatty marrow
  - Hypertrophied, hypointense synovium
- T2WI FS
  - Fluid & edematous tissue (synovium, erosions, osteitis, paraarticular soft tissues)
  - Effusions & pannus are both hyperintense & usually not readily distinguishable
  - Joint space narrowing, erosions, osteitis can be graded semiquantitatively (RAMRIS score)
- T1WI C+
  - Effusion fluid will not enhance, whereas pannus will enhance vigorously
  - Contrast enhancement is necessary to appreciate activity of synovitis
    - Synovial volume & degree of synovial perfusion can be accurately quantified

Ultrasonographic Findings

- **Effusion**
  - Sensitive, though nonspecific, indicator of synovitis
- **Synovial proliferation (pannus)**
  - Most common US finding in inflammatory arthritis
  - Normal synovium is not visible on US
  - Thickened synovium often hypoechoic but may be iso- or hyperechoic
    - The greater the water content, the more hypoechoic the synovium
  - Various types of synovial proliferation: Diffuse, frond-like, lobulated, or nodular
    - May resemble hypoechoic or echogenic synovial fluid
    - Joint fluid is normally anechoic
  - US is 10x more sensitive than clinical examination at detecting early MTP joint synovitis
- **Marginal bony erosions**
  - Focal, slightly irregular cortical defect ± containing hyperemic pannus
  - 6x more MCP erosions are detected with US than radiography
  - 30% false-positive rate for US detection of erosions
- **Cartilage loss**
  - US good but best assessed with radiography or MR
- **Periarticular soft tissue changes**
  - Tenosynovitis, nerve entrapment, bursitis, rheumatoid nodules, & peripheral enthesopathy all well seen with US
- **Synovial vascularity**
  - Allows level of synovial activity to be assessed
    - Active synovitis → high flow
    - Inactive synovitis → low/absent flow
    - Grade synovial hyperemia semiquantitatively as absent, mild, moderate, or severe
    - Spectral analysis: Active synovitis associated with ↓ resistive index but not routinely acquired
  - Color Doppler helpful in distinguishing synovial proliferation from joint fluid

Imaging Recommendations

- Best imaging tool
  - US as most peripheral joints are accessible, multiple joints can be examined during same examination, & diagnostic/therapeutic intervention possible
    - US useful for peripheral SpA but less so for central SpA, including sacroiliitis
- Protocol advice
  - Joints best examined in long axis, tendons in short axis
  - Systematic examination of each symptomatic joint
    - Dorsal aspects of wrists & small joints of hands & feet are usually most informative
  - If multiple joints symptomatic, examine wrists & 3 most symptomatic other joints
    - If no joint symptoms, examine wrists & 2nd MCP joint of dominant hand for subclinical disease
  - Erosions usually associated with surface cortical irregularity & adjacent pannus

  - Helps distinguish normal osseous indentation from erosion ± compare with opposite side
  - Use minimal transducer pressure when examining superficial joints, especially on color Doppler, to avoid masking underlying hyperemia
  - Utilize US probe & joint movement to maximize chondral visualization (e.g., flex MCP joint for dorsal metacarpal head)
  - Main question: Is degree of synovitis present more than expected for degree of underlying joint disorder?
    - If yes, consider inflammatory arthritis or crystal arthritis (with crystal aggregates usually visible in latter)
- Grading
  - Grade disease severity semiquantitatively from 0 (none) to 3 (severe) based on combination of synovial proliferation & color Doppler vascularity

DIFFERENTIAL DIAGNOSIS

Osteoarthritis

- Joint space narrowing with marginal osteophytosis & absence of erosions
  - Synovial proliferation & hyperemia not as pronounced as in inflammatory arthritis
- Inflammatory erosive osteoarthritis is characterized by small joint involvement, erosions, & synovial proliferation similar to other inflammatory arthritides
  - Clinical course, radiography, & laboratory tests helpful to distinguish

Septic Arthritis

- Often indistinguishable from inflammatory monoarthropathy
- Joint aspiration is required

Crystal Deposition Disease

- Very similar to acute inflammatory mono- or oligoarthropathy
- ± echogenic foci within joint fluid, synovium, or articular cartilage due to crystal aggregates
- Joint aspiration ± dual-energy CT helpful to identify crystals

PATHOLOGY

Gross Pathologic & Surgical Features

- RA is primarily disease of synovial inflammation
- Bilateral, symmetrical joint involvement
- Synovial proliferation (pannus) → erosion at bare area between articular cartilage & capsule
- Chronic synovitis → capsular, ligamentous laxity, & tendon attrition/rupture
  - Laxity of radioulnar & ulnocarpal ligaments
  - → dorsal subluxation ulna head → extensor carpi ulnaris tendinosis, attrition & tear (caput ulnae syndrome)

Microscopic Features

- Synovial inflammation
  - Synovial hyperplasia with inflammatory infiltrate
  - Synovial membrane exudes fibrinous exudate
- Rheumatoid factor (RF)
  - Serum IgM antibody present in 70% of RA patients
  - The higher the titer, the greater the likelihood of RA
    - RF titer ≥ 1:40 = 28% likelihood of RA; RF titer ≥ 1:640 = 99% likelihood of RA
  - High RF ± high anticitrullinated protein (ACCP) antibody titer
    - Associated with more severe disease

CLINICAL ISSUES

Presentation

- Consider following features of RA
  - Number of large or small joints affected
  - RF & ACCP positivity
  - C-reactive protein (CRP) & ESR levels
  - Symptom duration: Early RA (ERA) defined as symptom duration < 2 years
    - ERA more responsive to treatment

Demographics

- Age
  - 25-60 years most common
  - Peak incidence: 40-60 years
- Sex
  - M:F = 1:3
- Epidemiology
  - RA prevalence = 1% of population

Natural History & Prognosis

- Chronic disease with relapse-remission pattern → progressive joint destruction
- Complications
  - Progressive joint disease with secondary osteoarthritis → functional impairment
  - Tendon attrition & rupture
  - Median & ulnar nerve entrapment
  - Rheumatoid nodules at pressure sites
  - Avascular necrosis
  - Pulmonary (granuloma, fibrosis, pleuritis), ocular (episcleritis), stromal (Sjögren syndrome), & renal
  - Lymphadenopathy, splenomegaly (Felty syndrome)

Treatment

- Conservative
  - Nonsteroidal antiinflammatory agents
  - Corticosteroid (systemic or intraarticular)
  - Disease-modifying agents (DMARDs)
    - Methotrexate, hydroxychloroquine, sulfasalazine
  - Biological agents (e.g., etanercept, infliximab)
- Surgical
  - Synovectomy & tenosynovectomy
  - Tendon repair
  - Arthroplasty or arthrodesis

DIAGNOSTIC CHECKLIST

Image Interpretation Pearls

- Use color Doppler to determine synovial activity
- Aspirate joint fluid if septic arthritis or crystal deposition disease suspected

SELECTED REFERENCES

1. Bonfiglioli KR et al: Ultrasonographic insights into peripheral psoriatic arthritis: updates in diagnosis and monitoring. J Pers Med. 14(6), 2024

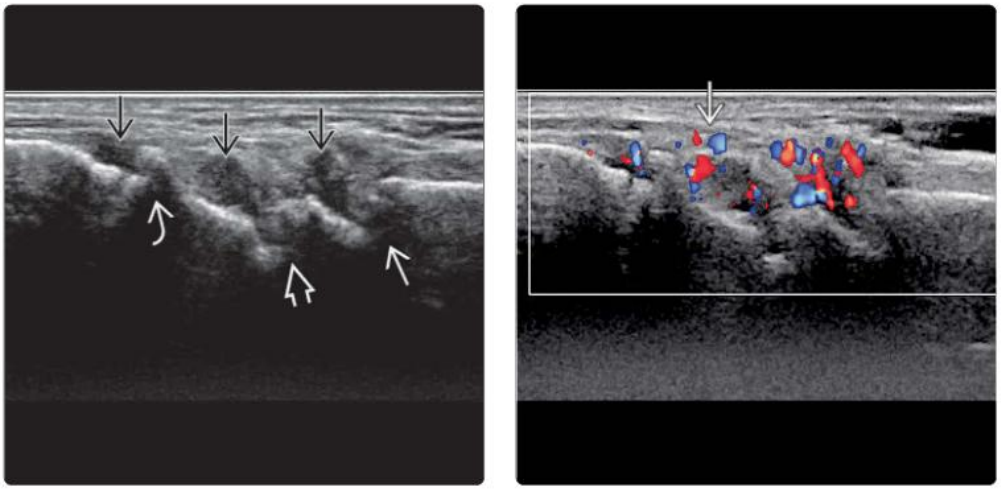

(Left) *Longitudinal US in a patient with rheumatoid arthritis (RA) shows apparent radiolunate ⇨ and lunocapitate ⇨ joint widening secondary to erosion and synovial proliferation ⇨. In contrast, the carpometacarpal articulation shows joint space narrowing ⇨ due to cartilage loss without erosion.* **(Right)** *Longitudinal color Doppler US of the same area shows moderate synovial hyperemia ⇨, indicative of moderately inflamed synovitis.*

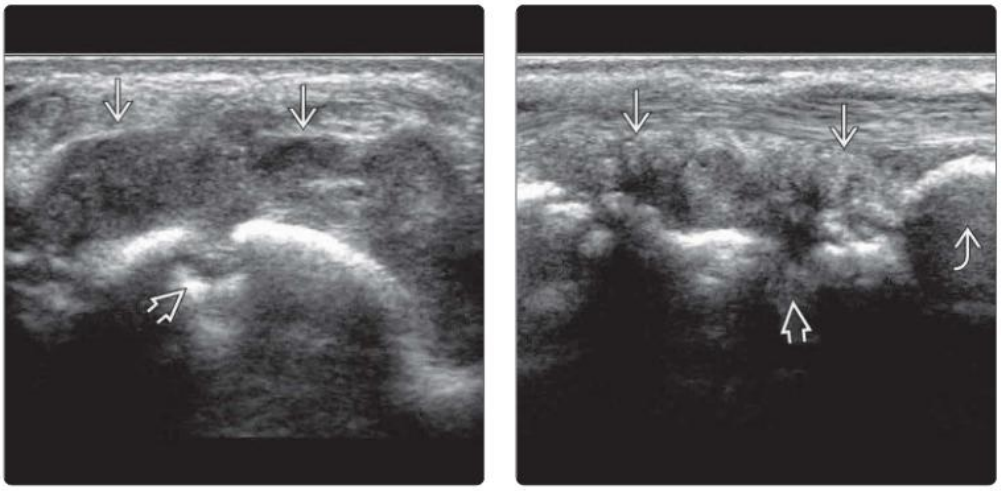

(Left) *Transverse US in a patient with chronic RA and carpal fusion shows severe synovial proliferation ⇨ on the dorsum of the wrist joint with a moderate-sized discrete bony erosion ⇨ on the dorsal aspect of the fused scapholunate joint.* **(Right)** *Longitudinal US of the same area shows moderate synovial proliferation ⇨ on the dorsal aspect of a largely ankylosed carpus. The midcarpal articulation is still not fused ⇨. The ulnar head is mildly subluxed ⇨.*

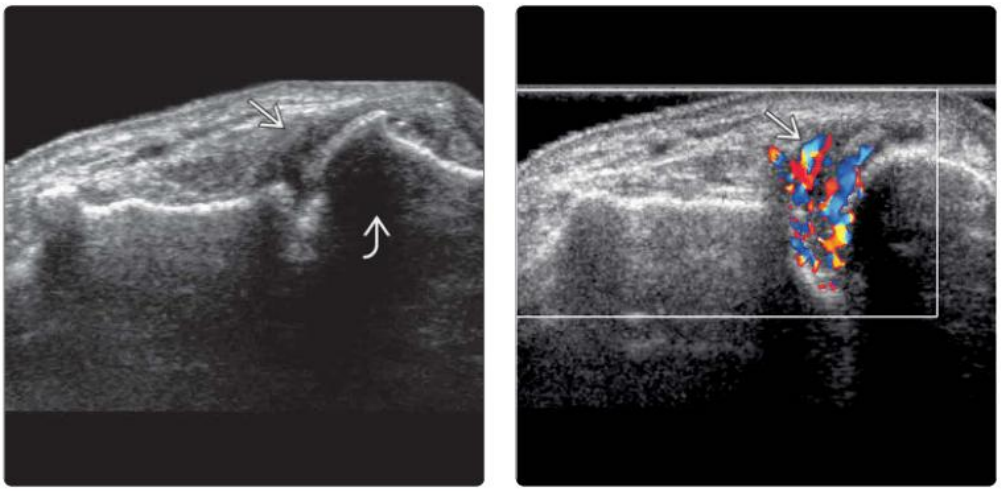

(Left) *Transverse US shows moderate synovial proliferation of the dorsal aspect of the distal radioulnar joint ⇨ in a patient with RA. There is moderate dorsal subluxation of the ulnar head ⇨.* **(Right)** *Transverse color Doppler US of the same area shows severe synovial hyperemia ⇨, indicative of active synovitis. Assessing the degree of synovial vascularity is the best way to gauge synovial activity.*

(Left) *Transverse color Doppler US of a patient with juvenile inflammatory arthritis (JIA) shows moderate synovial thickening ➡ and hyperemia of the dorsal aspect of the distal radioulnar joint (DRUJ) ➡. The DRUJ is one of the commonly affected joints in JIA.* **(Right)** *Axial T1 C+ FS MR in the same patient shows the full extent of DRUJ synovitis ➡. MR enables a more encompassing disease overview, including intraarticular extent, while US offers excellent assessment of focal disease activity.*

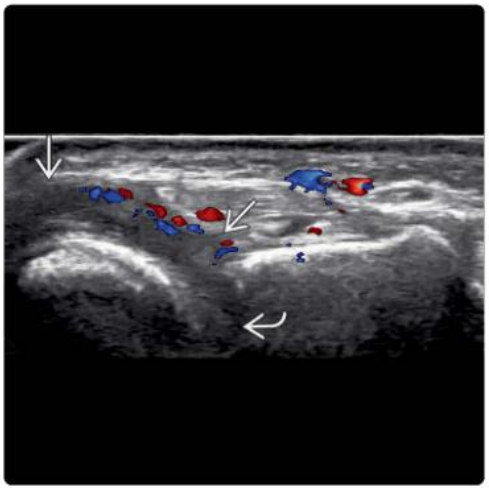

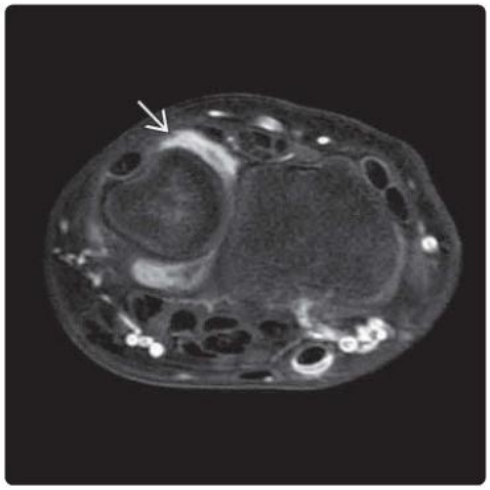

(Left) *Longitudinal US in a patient with end-stage RA shows severe arthropathy with a largely fused carpus ➡. There is outpouching of both thickened synovium ➡ and synovial fluid ➡ dorsally. The thickened synovium shows villous proliferation.* **(Right)** *Transverse color Doppler US in a patient with RA shows moderate active flexor tenosynovitis at the volar wrist, evident by tendon sheath thickening ➡ and hyperemia. Tenosynovitis is a common finding in inflammatory arthropathy. Median nerve ➡ is normal.*

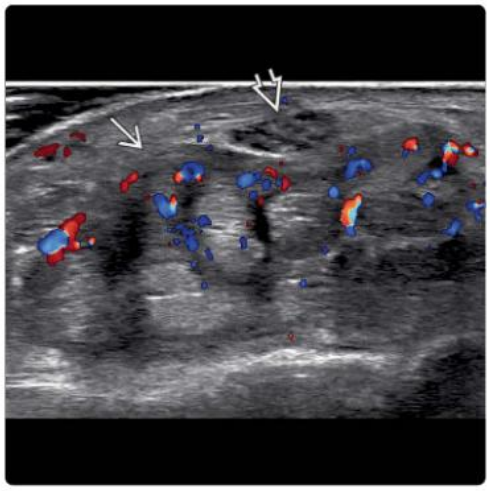

(Left) *Longitudinal US shows moderate synovial proliferation ➡, hyperemia ➡, & effusion ➡ at the dorsal 2nd metacarpophalangeal (MCP) joint, indicating moderate disease. The dorsal aspect of the metacarpal neck ➡ often shows focal cortical depression, which should not be mistaken for erosion.* **(Right)** *Longitudinal US shows mild synovial proliferation ➡ on the dorsum of the middle finger distal interphalangeal joint in a patient with RA. Middle phalanx head is eroded ➡, & joint space is irregular & narrowed ➡.*

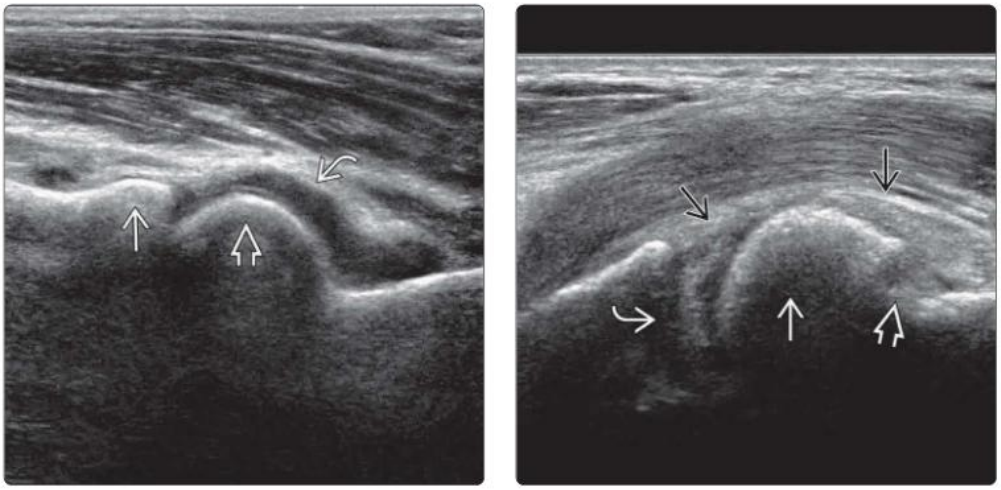

(Left) *Longitudinal US in a patient with early RA shows mild synovial proliferation with moderate effusion ⇨ of the elbow joint. There is no erosive change of either the capitellum ⇨ or the radial head ⇨.* **(Right)** *Longitudinal US in a patient with longstanding RA shows moderate synovial proliferation ⇨ on the anterior aspect of the elbow joint with a moderate-sized, discrete erosion ⇨ at the proximal end of the capitellum ⇨. The radial head ⇨ is shown.*

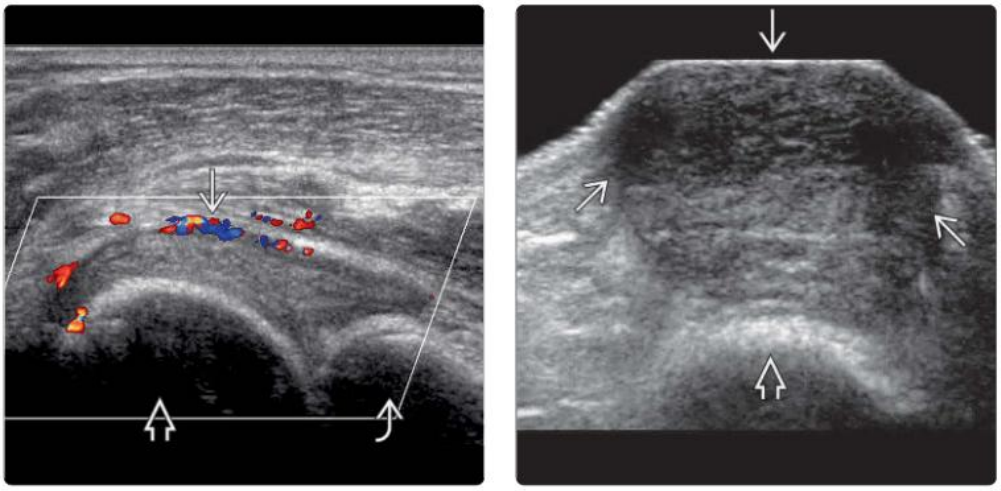

(Left) *Transverse color Doppler US in an RA patient shows moderate synovial proliferation ⇨ of the posterior glenohumeral joint with moderate synovial hyperemia. Color Doppler signal detection is less sensitive for the deeper joints. No humeral head ⇨ or glenoid ⇨ erosion is present.* **(Right)** *Transverse US shows a rheumatoid nodule ⇨ over the olecranon process ⇨ with typical hypoechoic, rounded appearance and subcutaneous location. Mild hyperemia was present on color Doppler imaging.*

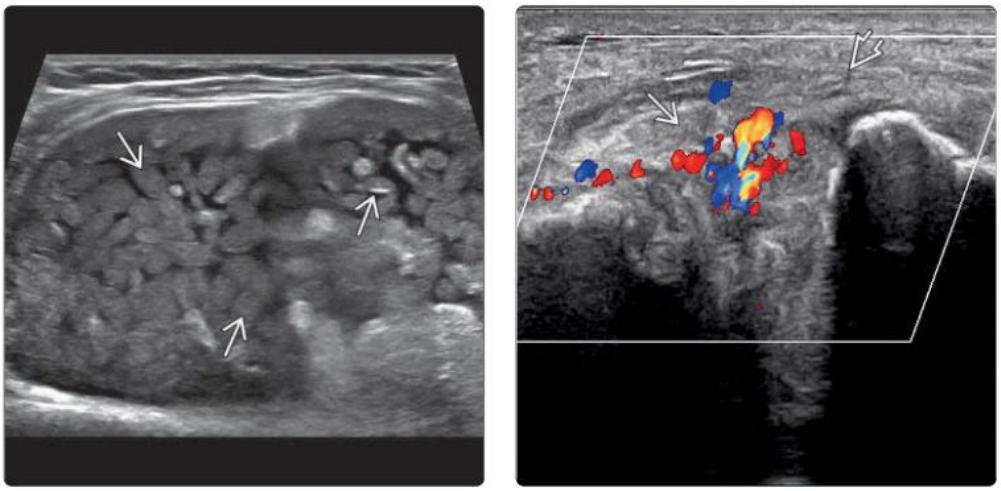

(Left) *Transverse US in an RA patient shows a severely distended subacromial-subdeltoid bursa packed with fairly uniformly shaped and sized rice bodies ⇨. Rice bodies are proteinaceous aggregates and a feature of chronic RA.* **(Right)** *Transverse color Doppler US in an RA patient with right sternoclavicular joint swelling shows moderate synovial hyperemia ⇨ indicative of moderately active synovitis. The periarticular soft tissues are moderately edematous ⇨.*

(Left) *Longitudinal US in a patient with systemic lupus erythematosus shows a moderate-sized inflammatory hip joint effusion* ⇨ *with mild synovial proliferation* ⇨*. Aspiration yielded straw-colored, nonpurulent fluid, which had an increased white cell count but was negative on Gram stain and sterile on culture.* **(Right)** *Longitudinal US in a patient with chronic RA and recent hip pain shows moderate synovial proliferation* ⇨*. There is proximal femoral avascular necrosis with femoral head collapse* ⇨*.*

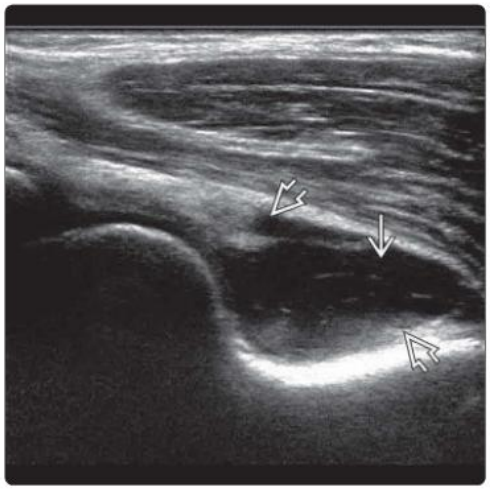

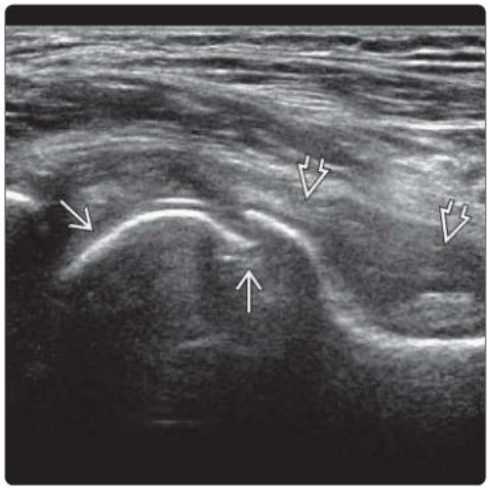

(Left) *Transverse US of the lateral patellar recess in a patient with RA shows mild, frond-like synovial proliferation* ⇨*, which can be readily distinguished from joint fluid* ⇨*. This degree of synovial proliferation can be seen in moderate to severe osteoarthritis.* **(Right)** *Transverse US of the lateral patellar recess in a patient with RA shows more severe, frond-like synovial proliferation* ⇨*. This level of synovial proliferation would be uncommon in osteoarthritis unless accompanied by crystal or debris deposition.*

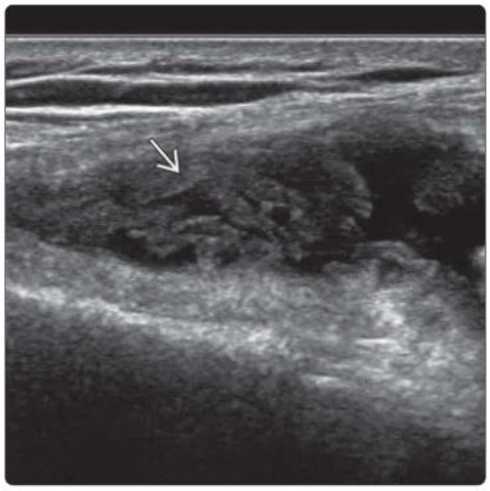

(Left) *Transverse US of the lateral patellar recess in a patient with RA shows more severe, lobulated, hyperechoic synovial proliferation* ⇨*, which is readily distinguished from joint fluid* ⇨*.* **(Right)** *Longitudinal US of the suprapatellar pouch shows nodular-like synovial proliferation* ⇨*. There is no known significance to the type of proliferation present (i.e., smooth, frond-like, lobular, or nodular) in RA.*

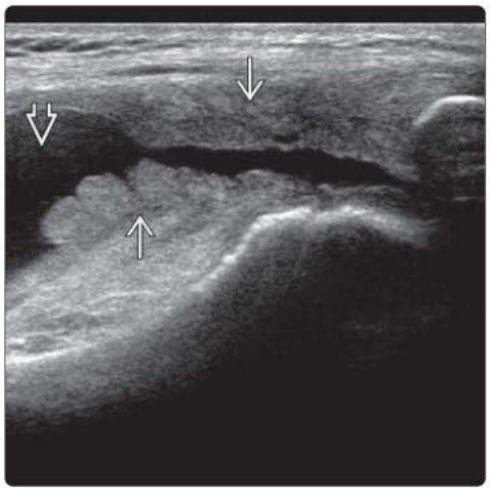

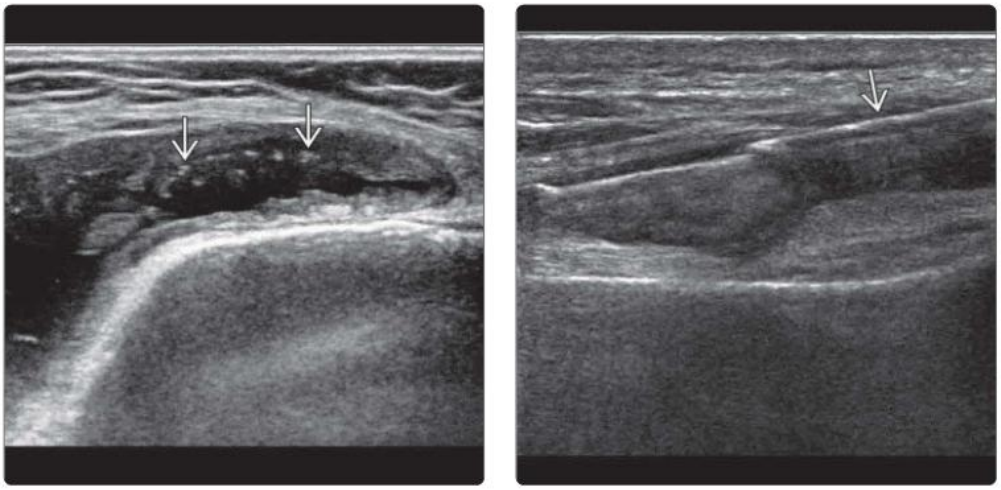

(Left) *Transverse US in a patient with RA shows moderately thickened synovium in the medial patellar recess with several small surface echogenic foci ⇨, most likely due to fibrin aggregates rather the crystal aggregates.* **(Right)** *Transverse US shows the lateral patellar recess in a patient with RA during synovial biopsy ⇨. Both synovial fluid analysis and synovial biopsy are useful at excluding crystal arthritis or septic arthritis in patients with suspected inflammatory arthropathy.*

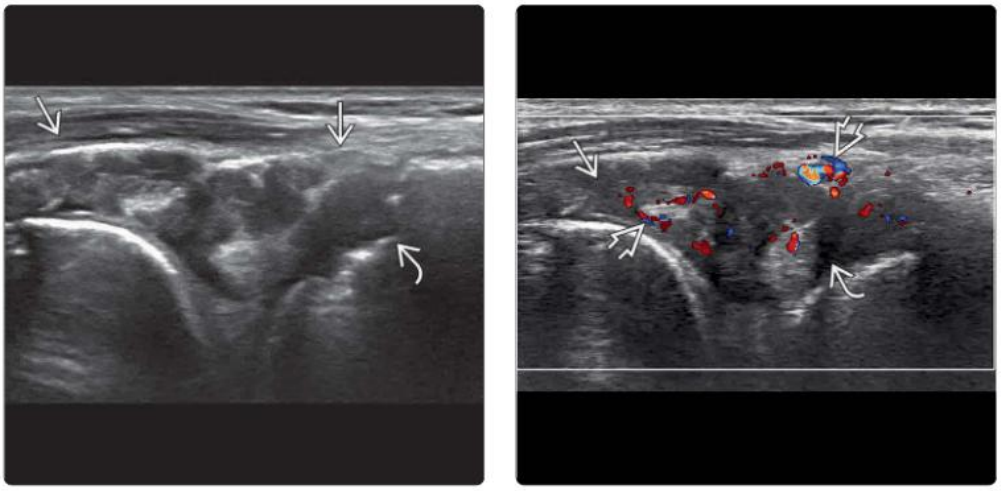

(Left) *Longitudinal US of an RA patient shows moderate synovial proliferation ⇨ along the lateral tibiofemoral joint line with a moderate-sized periarticular cortical erosion of the lateral tibial condyle ⇨.* **(Right)** *Longitudinal color Doppler US in the same patient shows moderate disease activity at the lateral knee evident by moderate synovial hypertrophy ⇨ /hyperemia ⇨ and small effusion ⇨.*

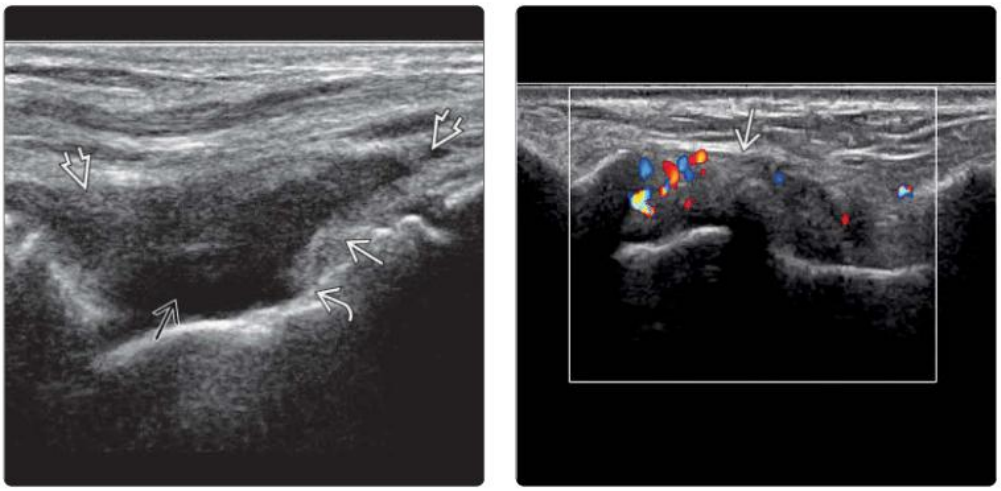

(Left) *Longitudinal US shows moderate ankle joint capsular distension ⇨ due to a combination of synovial proliferation ⇨ and joint fluid ⇨. The ankle joint capsule is attached distally to the talar neck ⇨.* **(Right)** *Longitudinal color Doppler US in a patient with RA shows moderate ankle joint capsular distension due to synovial proliferation ⇨. There is no appreciable joint fluid present. Moderate synovial hyperemia is present.*

(Left) *Longitudinal US in a patient with RA shows moderate anterior ankle involvement with joint effusion ➡, synovial hypertrophy ➡, and bony erosion of the talar neck ➡. There is also moderate extensor hallucis longus tenosynovitis ⇨. (Right) Transverse US of the same area shows the true extent of extensor hallucis and digitorum tenosynovitis ➡, which was severely hyperemic on color Doppler US (not shown). Ankle joint effusion ➡ and synovitis ➡ are shown.*

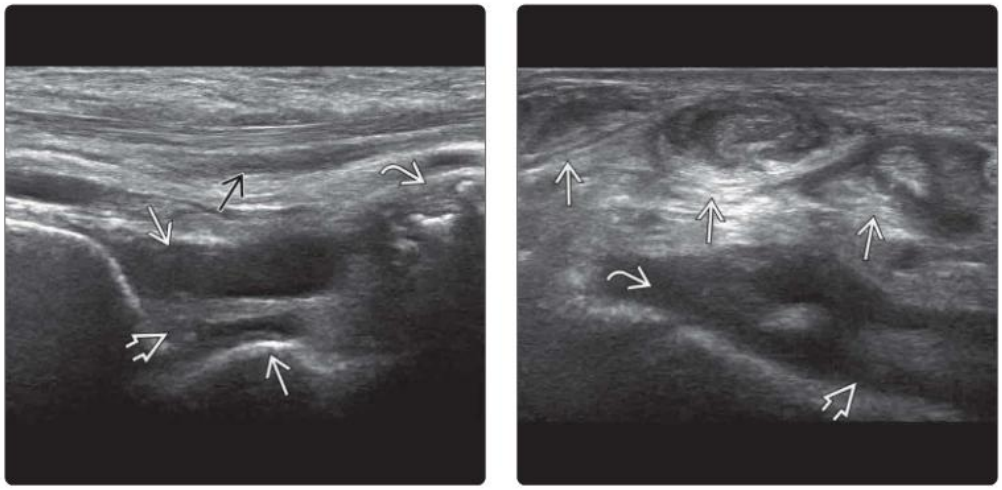

(Left) *Transverse US in a patient with RA-related tenosynovitis ➡ shows needle aspiration of the extensor digitorum tendon sheath ➡ to help exclude an infective or gouty tenosynovitis. This is helpful only in a minority of patients with tenosynovitis.* **(Right)** *Longitudinal color Doppler US in a patient with moderately active RA shows mild synovial hyperemia though moderate synovial proliferation and effusion with joint distension ➡ on the dorsum of the hyperextended 2nd metatarsophalangeal joint ➡.*

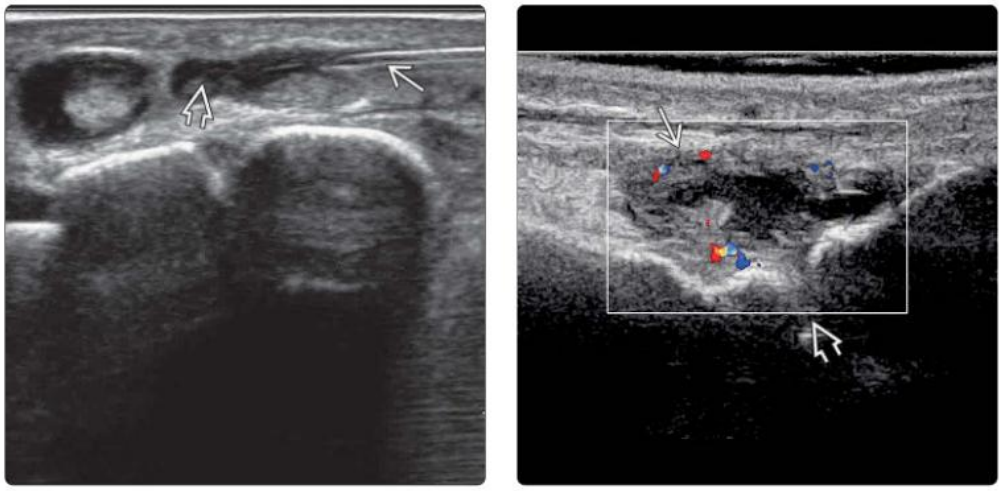

(Left) *Longitudinal US in a patient with suspected RA shows severe synovial proliferation ➡ on the dorsum of the 2nd tarsometatarsal joint ➡. Small, echogenic foci ➡ are embedded in the thickened synovium.* **(Right)** *Longitudinal color Doppler US of the same joint shows severe synovial hyperemia. US-guided synovial biopsy (not shown) helped exclude joint infection and crystal arthropathy.*

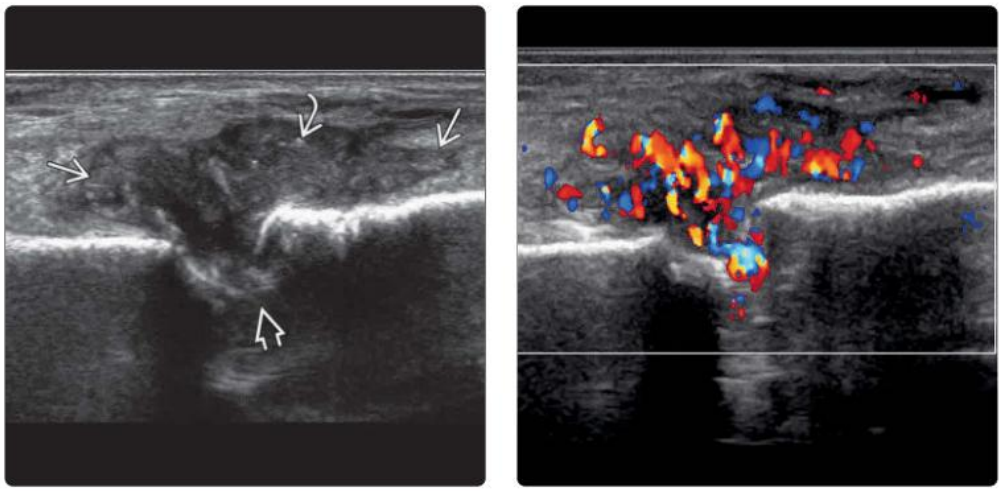

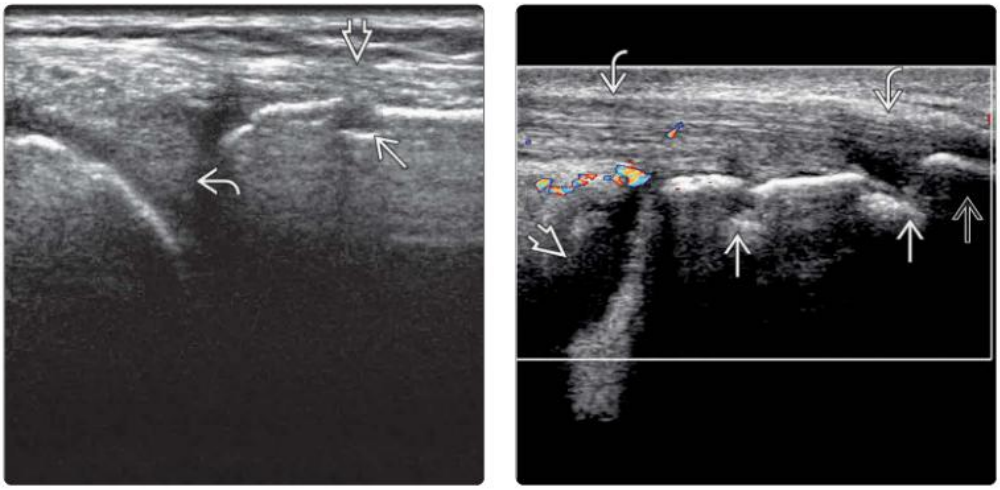

(Left) *Longitudinal US of the medial aspect of the knee joint in a patient with peripheral spondyloarthritis (SpA) shows a medium-sized periarticular entheseal erosion ➡ deep to the normal medial collateral ligament ➡. Medial meniscus ➡ is normal.* **(Right)** *Longitudinal color Doppler US of the same area shows medium-sized entheseal erosions ➡ deep to the Achilles tendon ➡. There is mild hyperemia with a mildly distended retro-Achilles bursa ➡. Mild enthesophytosis ➡ with cortical hyperostosis is present.*

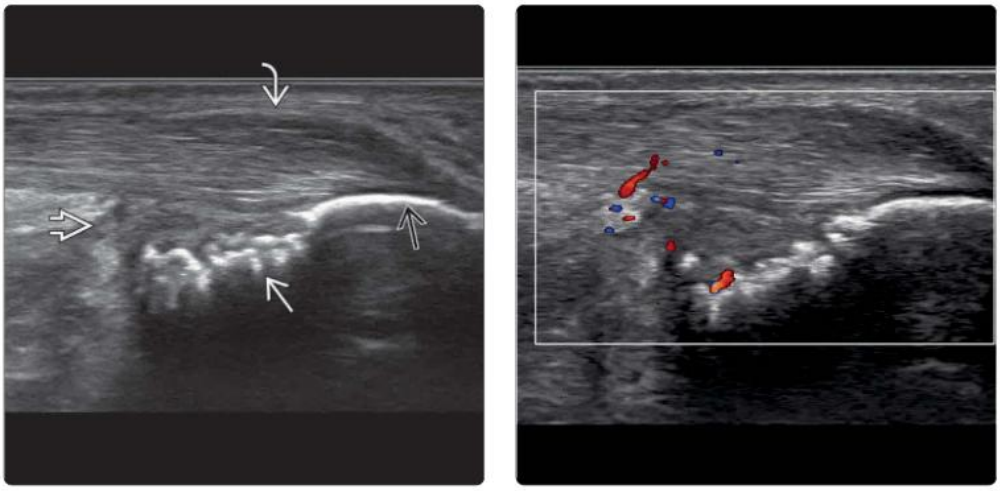

(Left) *Longitudinal US of the posterior heel in a patient with peripheral SpA shows severe irregular cortical erosion ➡ deep to the mildly distended retrocalcaneal bursa ➡. The Achilles tendon is slightly thickened ➡, while the calcaneal tendon insertion ➡ is normal.* **(Right)** *Longitudinal color Doppler US of the same area shows mild marginal hyperemia of the retrocalcaneal bursal area. The retrocalcaneal bursa is an integral part of the Achilles tendon enthesis organ and, in this case, is the main affected area.*

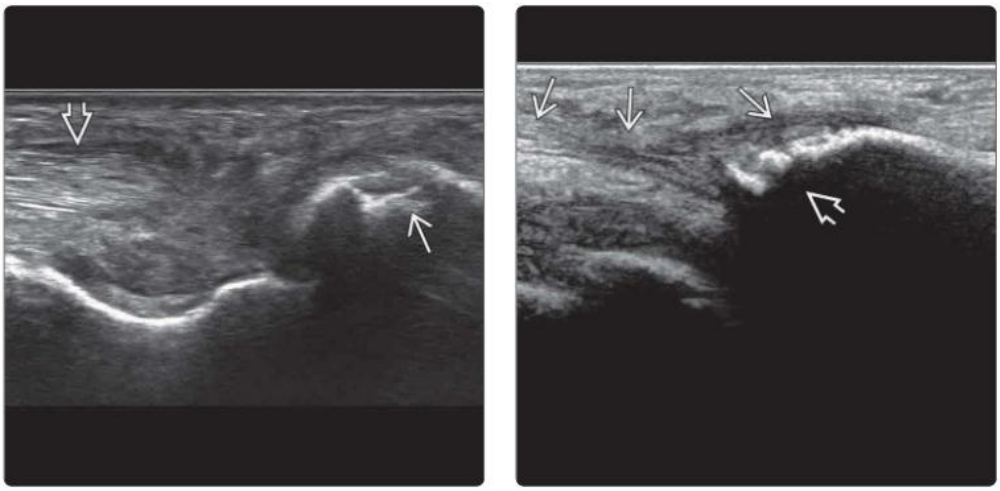

(Left) *Longitudinal US in the same patient shows a quite large entheseal erosion ➡ on the medial pole of the navicular bone. This area comprises part of the insertional area of the posterior tibialis tendon ➡.* **(Right)** *Longitudinal US in a patient with peripheral SpA shows moderate thickening ➡ of the lateral band plantar fascia at its insertion into the 5th metatarsal base. Moderate cortical irregularity and hyperostosis (enthesophytosis) of the 5th metatarsal base are present ➡.*

KEY FACTS

TERMINOLOGY

- Inflammatory arthropathy due to deposition of urate (gout) or calcium pyrophosphate dihydrate (CPPD) (pseudogout) crystal

IMAGING

- US usually sufficient for diagnosis without joint aspiration
- **Tophi**: Soft tophi (hyperechoic, no acoustic shadowing) → hard tophi (hyperechoic, intense acoustic shadowing)
  - Quite well-defined, irregular margins with variable hypoechoic halo ("wet clumps of sugar")
  - Multiple grouped tophi are common
- **Tendons & ligaments**
  - Probably most frequent site of gouty crystal deposition
  - Microdeposits with small, hyperechoic foci → large, hyperechoic foci with intense acoustic shadowing
- **Synovial fluid & synovium**
  - Hyperechoic foci or cloudy areas in synovial fluid or synovium
  - Fine punctuate echogenicity ("urate sand")
  - Large echogenic aggregates (snowstorm appearance)
  - Pseudogout: Fewer echogenic foci in synovial fluid
- **Hyaline (articular) cartilage**
  - Gout: Thin echogenic band on surface of cartilage ("urate icing" or double-contour sign)
    - Most sensitive sign for diagnosis of gouty arthritis
  - Pseudogout: Thin echogenic band in midzone of cartilage (CPPD deposition); hyaline cartilage zonal distribution has high disease specificity
- **Fibrocartilage**
  - Pseudogout: Punctuate echogenic foci within hypoechoic fibrocartilaginous disc (wrist) or menisci (knee) due to CPPD deposition

DIAGNOSTIC CHECKLIST

- US: Include synovial fluid, synovium, cartilage, bone, tendons, ligaments, & tophi
- Joint aspiration: Send fresh specimen

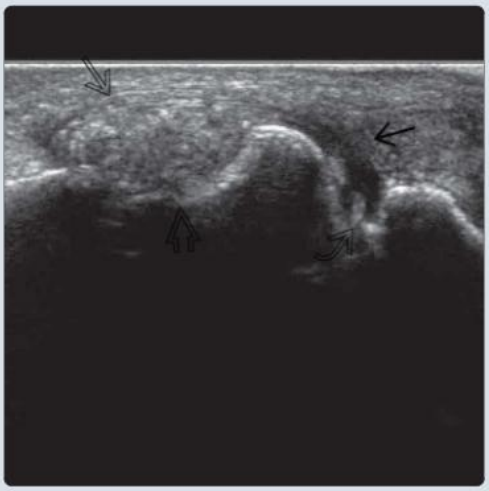

(Left) *Longitudinal US shows a typical 1st metatarsophalangeal joint (MTPJ) gouty arthritis. The soft tophus ➡ causes marginal erosion ➡ of the metatarsal head. A small joint effusion ⇨ is present in the MTPJ with echogenic gouty crystal aggregates ➡.* **(Right)** *Anteroposterior radiograph in the same patient shows soft tissue swelling ➡ and marginal erosions ➡. The tophi are largely noncalcified and not clearly seen.*

(Left) *Axial NECT in the same patient shows hyperdense calcified tophi ➡. CT is more sensitive than radiography at revealing gouty tophi. There are marginal erosions ➡ deep to the tophi.* **(Right)** *Axial T1 MR in the same patient shows the isointense (to muscle) tophi ➡ and marginal erosions ⇨. Dual-energy CT (if available) is better than MR or US at quantifying gouty tophi volume for monitoring response to treatment.*

TERMINOLOGY

Synonyms

- Gouty arthropathy, calcium pyrophosphate dihydrate (CPPD) arthropathy, crystal arthropathy, metabolic arthritis, tophaceous gout, podagra, gouty tophi

Definitions

- Inflammatory arthropathy due to urate (gout) or CPPD (pseudogout) crystal deposition

IMAGING

General Features

- Best diagnostic clue
  - Echogenic foci (crystal aggregates) in joint or soft tissues
- Location
  - Gout: 1st metatarsophalangeal (MTP) joint (podagra) (50%) > ankle > midfoot > knee > wrist
    - Helix of ear, olecranon bursa, tendons (especially patellar & triceps), knee & ankle ligaments
  - Pseudogout: Any joint, especially knee, wrist, scapho-trapezium-triquetral joints
    - Extrachondral involvement (synovium, tendons, ligaments, soft tissues) less common than in gout
    - Common accompaniment of moderate to severe osteoarthritis
- Size
  - Gouty tophi range from few mm to 5 cm
- Morphology
  - Monoarticular swelling → deforming polyarthropathy
    - Tophi lead to hard, discrete nodules in subcutaneous, paraarticular, & other tissues

Radiographic Findings

- Gout: Eccentric soft tissue hyperdense swelling ± calcific tophi
  - Asymmetric arthropathy
    - Absence of osteopenia
    - Joint space preserved until late
    - Marginal erosions with overhanging edges & thin sclerotic edge
- Pseudogout: Chondrocalcinosis in both hyaline & fibrocartilage (e.g., meniscus, triangular fibrocartilage complex); generally symmetric

CT Findings

- Dual-energy CT (DECT): Highly specific for gout tophi
  - Need gouty crystal accumulation before visible on DECT
  - Can differentiate & automatically quantify total crystal volume

MR Findings

- T1WI
  - Tophi: Well-defined masses, isointense to muscle
- T2WI
  - Tophi: Low to high signal intensity
    - Variable intensity reflects amount of urate deposition, edema, & maturity of granulation tissue
- T1WI C+
  - Tophi: Honeycomb-like heterogeneous to near-homogeneous enhancement
    - Honeycomb appearance due to avascular urate surrounded by vascularized granulation tissue

Ultrasonographic Findings

- **Tophi**
  - Soft tophi (hyperechoic without acoustic shadowing) → hard tophi (hyperechoic with intense acoustic shadowing)
  - Quite well-defined, irregular margins with variable hypoechoic halo ("wet clump of sugar")
  - Multiple grouped tophi are common
- **Tendons/ligaments**
  - Probably most frequent site of crystal deposition in gout
  - Ranges from microdeposits with small, hyperechoic foci to large, hyperechoic foci with intense acoustic shadowing
    - Fibrillar pattern is disrupted, tendon is stretched & displaced
    - Acoustic shadowing with larger (> 5-mm) masses
    - Hypervascularity in active disease
    - ± tendon rupture (uncommon)
- **Synovial fluid**
  - Gout: Variable appearance of joint fluid
    - Hyperechoic aggregates in synovial fluid
      - Fine punctuate echogenicity ("urate sand")
      - Large echogenic aggregates (snowstorm appearance)
  - Pseudogout: Fewer echogenic aggregates in joint fluid
- **Hyaline (articular) cartilage**
  - Gout: Thin echogenic band on surface of cartilage ("urate icing" or double-contour sign)
    - Most sensitive sign for diagnosis of gouty arthritis
  - Pseudogout: Thin echogenic band in midzone of cartilage (CPPD deposition)
    - No acoustic shadowing
- **Fibrocartilage**
  - Pseudogout: Punctuate echogenic foci within hypoechoic fibrocartilaginous disc (wrist) or menisci (knee) due to CPPD deposition
- **Bone**
  - Marginal erosions
    - Invariably associated with overlying tophus
- **Subcutaneous tissue**
  - Gouty lobular-type panniculitis, particularly of lower extremities

Imaging Recommendations

- Best imaging tool
  - US is best 1st-line investigation for gout & is usually sufficient for diagnosis without joint aspiration
    - More accurate than clinical examination or radiography at detecting gout
    - Small, nonconglomerate crystal aggregates detected by US will be negative on DECT
  - 1st/2nd MTP joint, ankle, knee, wrist, patellar/triceps tendons are all common sites of involvement
    - Screening 1st MTP joints & either knees or ankles is comparable to screening all areas
    - At knee, earliest changes are often seen in popliteal groove
- Protocol advice

- Assess all aspects of joint (cartilage, fluid, synovium) & periarticular structures (ligaments, tendons, bone)
- ± synovial fluid aspiration for analysis by polarizing light microscopy (sensitivity: 84%; specificity: 100%)
  - Only small amount of fluid is required for analysis
  - Send fresh specimen (since crystals are dissolved by water, alcohol, or formalin)
  - Urate crystals: Needle-like, negatively birefringent
  - CPPD crystals: Rod-like, positively birefringent
- Urate & CPPD crystals may coexist
- Also send fluid for Gram stain, culture, & cell count

DIFFERENTIAL DIAGNOSIS

Rheumatoid Nodule

- Hypoechoic, well-defined ± hyperemia
  - No echogenic foci
  - Typical location (over bony prominences)

Rheumatoid Arthritis

- Symmetric polyarthropathy; bony erosions are usually smaller
- Proteinaceous aggregates in synovial fluid of inflammatory arthropathy are less echogenic than crystal aggregates
- Absence of crystals on synovial fluid analysis

Septic Arthritis

- Distinction from acute gout can be difficult
  - Septic arthritis & crystal arthropathy may coexist
  - Synovial fluid analysis is helpful

PATHOLOGY

General Features

- Etiology
  - Genetic
  - Diet ("disease of kings")
  - Diabetes, thiazide diuretics, renal impairment
- Associated abnormalities
  - Hypertension, diabetes mellitus, metabolic syndrome, abdominal obesity, hyperlipidemia
  - Renal stones (1,000x ↑ incidence)
    - Pure uric acid stones (80%) or mixed stones (20%)
- Uric acid = end product of purine catabolism
  - ↓ excretion of uric acid in urine (90% cases)
  - ↑ production of uric acid (10% cases)
- Clinical gout only develops in some hyperuricemic patients
  - US is helpful to diagnose subclinical gouty arthritis in hyperuricemic individuals
- Urate solubility is affected by concentration, cold, pH, tissue composition, & turnover
  - Uric acid preferentially deposits in synovium, around joints, tendons, ligaments
- Urate crystals are coated with apolipoprotein E or B
  - Protein coating may stop crystals from triggering inflammation
  - Immunoglobulins bind to bare areas on crystals & initiate phagocytosis by neutrophils
  - Exposure of bare areas on crystals (flux in uric acid level or trauma) may trigger acute inflammation

Gross Pathologic & Surgical Features

- Tophi; multilobulated locules with white, chalky material

Microscopic Features

- Multicentric urate crystals surrounded by vascularized granulation tissue & inflammatory infiltrate

CLINICAL ISSUES

Presentation

- Most common signs/symptoms
  - Acute monarticular arthritis (90%)
    - Severe inflammation reaching peak in 8-12 hours
  - Arthritis usually precedes development of tophi
    - Tophi slowly enlarge over years
- Other signs/symptoms
  - Tendinitis, tenosynovitis, or enthesitis (mainly in gout)

Demographics

- Age
  - Peak onset = 30-50 years (males), 50-70 years (females)
  - Earlier with renal insufficiency or genetic predisposition
- Sex
  - Gout: M:F = 9:1
    - Estrogen is mildly uricosuric
    - Gout is more common in postmenopausal women
  - Pseudogout: M:F = 1.5:1.0
- Epidemiology
  - 1% of general population

Natural History & Prognosis

- Acute attack resolves spontaneously in < 2 weeks
  - Joint is normal between attacks (early disease)
  - → polyarticular involvement with attacks becoming less intense, more frequent, & lasting longer
  - → chronic polyarthropathy
  - If serum urate levels are kept below 6 mg/dL, ↓ in crystal deposition can be seen on US
- Gouty nephropathy

Treatment

- Limiting acute attack
  - Rest & nonsteroidal antiinflammatory agents
- Prevention or reversal of crystal deposition
  - Diet modification & weight reduction
  - Drug therapy: Allopurinol, probenecid, or colchicine
- Surgery
  - Excision of tophi (cosmetic, chronically discharging)

DIAGNOSTIC CHECKLIST

Consider

- US should include assessment of synovial fluid, articular cartilage, bone, tendons, ligaments, & soft tissue tophi
  - Distinction between gout & pseudogout rests on site of crystal deposition, synovial fluid analysis ± DECT
- Joint aspiration: Send fresh specimen (since crystals dissolved by water, alcohol, or formalin)

SELECTED REFERENCES

1. Knudsen PA et al: Invariant dynamics in a united-atom model of an ionic liquid. J Chem Phys. 160(3):034503, 2024

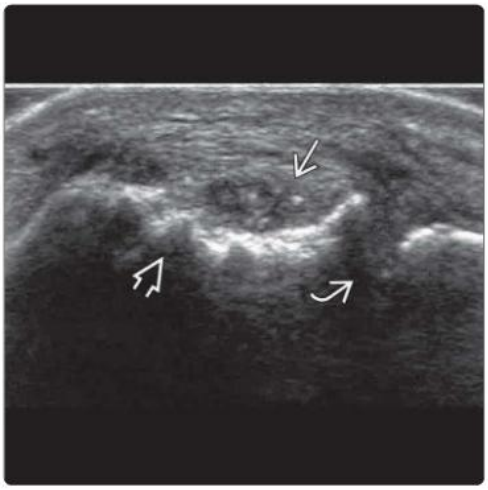

(Left) *Longitudinal US shows a soft tophus near the 1st MTPJ with marginal erosion of the metatarsal head. A small MTPJ effusion is present with tiny echogenic "urate sand" within the synovial fluid.* **(Right)** *Anteroposterior radiograph in the same patient shows soft tissue swelling and marginal erosions of both MTPJs. Symptoms were only present on the right side.*

(Left) *Oblique US of the knee shows a large, soft gouty tophus on the lateral aspect of the distal femur. The internal structure of the tophus as well as the bone can be fully appreciated, as there is no acoustic shadowing.* **(Right)** *Longitudinal US of Achilles insertion and posterior aspect of calcaneum shows a fairly soft gouty tophus within the subcutaneous calcaneal bursa. In contrast to the previous case, the deeper structures are at places obscured by posterior acoustic shadowing.*

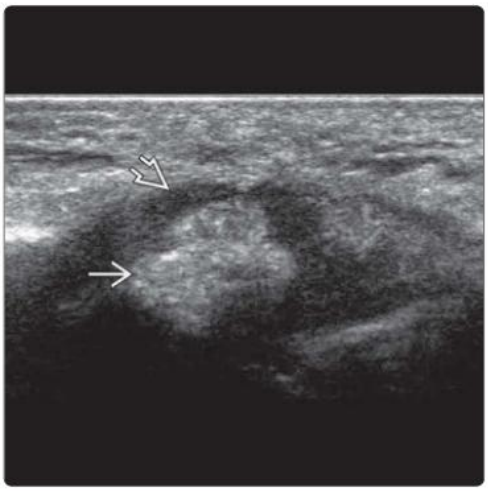

(Left) *Transverse US, volar aspect of the wrist, shows a moderately hard, gouty tophus just proximal to the tunnel inlet. There is a hyperechoic central area with a quite well-defined hypoechoic rim of granulation tissue resembling a lump of wet sugar.* **(Right)** *Longitudinal US shows a hard, gouty tophus overlying the anterior tibial tuberosity with dense acoustic shadowing. Neither the internal composition of the tophus nor the structures deep to the tophus can be appreciated. The tibial shaft is shown.*

(Left) *Longitudinal US of the dorsal wrist shows a large, lobulated, echogenic tophus containing more discrete and intensely echogenic foci, consistent with crystal aggregates.* **(Right)** *Longitudinal US of the posterior elbow shows lumps of echogenic gouty tophi within the triceps tendon insertion. Associated marked gouty olecranon bursitis contains a mixture of anechoic effusion, urate sand, and larger, discrete crystal aggregates.*

(Left) *Clinical photograph of a patient with gout shows redness and swelling at the dorsal left wrist.* **(Right)** *Longitudinal US of this swelling in the same patient shows a bulky soft tissue tophus superficial to the wrist extensor tendons and also chronic radiocarpal synovitis. Note the echogenic crystal deposits within the tophus and joint and cortical erosions of the lunate.*

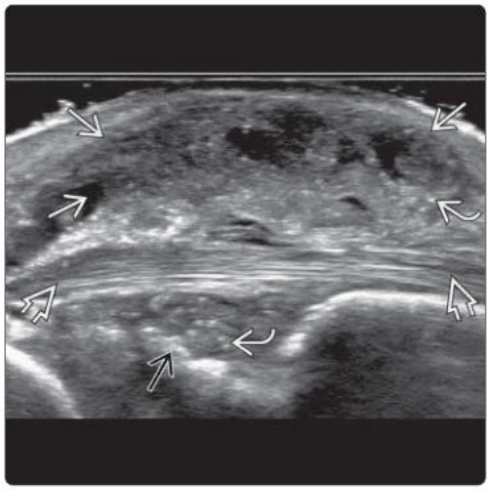

(Left) *Transverse US shows severe gouty wrist flexor tenosynovitis. The tendon sheath is severely distended with fine echogenic fluid (snowstorm appearance). The tendons are poorly defined, suggestive of intratendinous urate deposition.* **(Right)** *Transverse US of the ankle shows anterior tibialis gouty tenosynovitis. There are crystal aggregates within the tendon sheath as well as fine echogenic crystal aggregates within the tendon.*

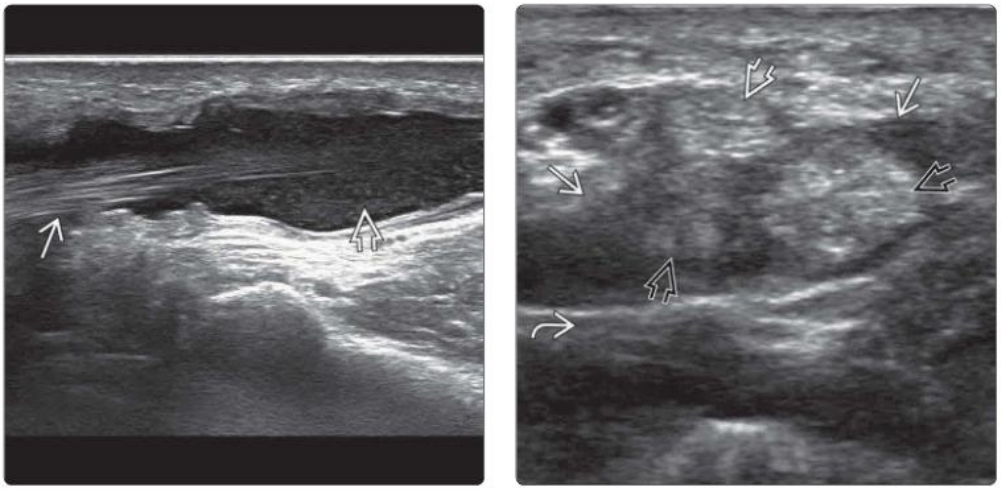

(Left) *Longitudinal US of the wrist shows gouty tenosynovitis of the flexor carpi radialis tendon ➡ sheath with tendon sheath effusion containing "urate sand" ➡ that is quite specific for gout. There is no tendon involvement.* **(Right)** *Longitudinal US of the hand shows severe gouty flexor digiti minimi tenosynovitis. The tendon sheath ➡ is distended with fluid and large crystal aggregates ➡. The flexor tendon ➡ and metacarpal bone ➡ are normal.*

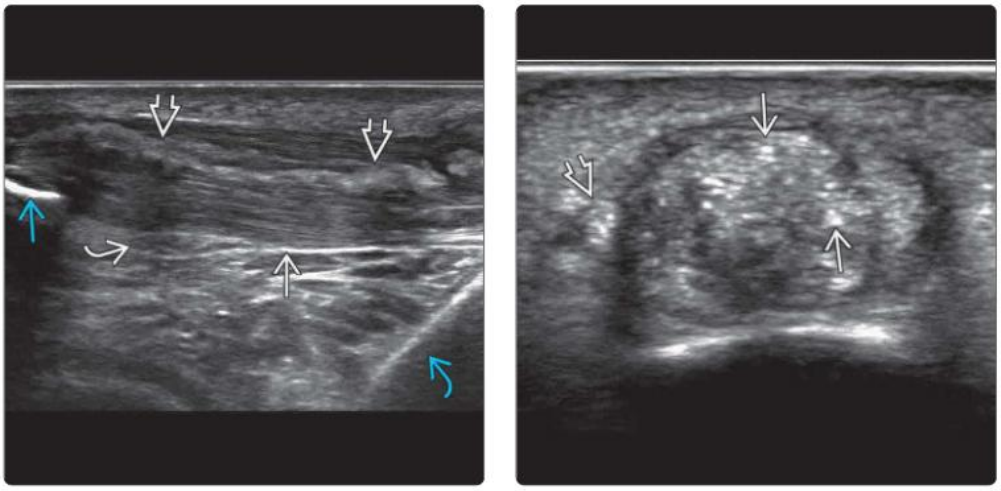

(Left) *Longitudinal US of the patellar tendon ➡ shows moderate tendon thickening with intratendinous sheet-like echogenicity ➡ and mild postacoustic shadowing ➡ due to gouty deposition. The patella ➡ and tibia ➡ are normal.* **(Right)** *Transverse US of the little finger flexor tendon shows severe gouty tendinopathy. In contrast to the previous image, the echogenic intratendinous crystal depositions ➡ are finer and more scattered. There are also crystal deposits within the tendon sheath ➡.*

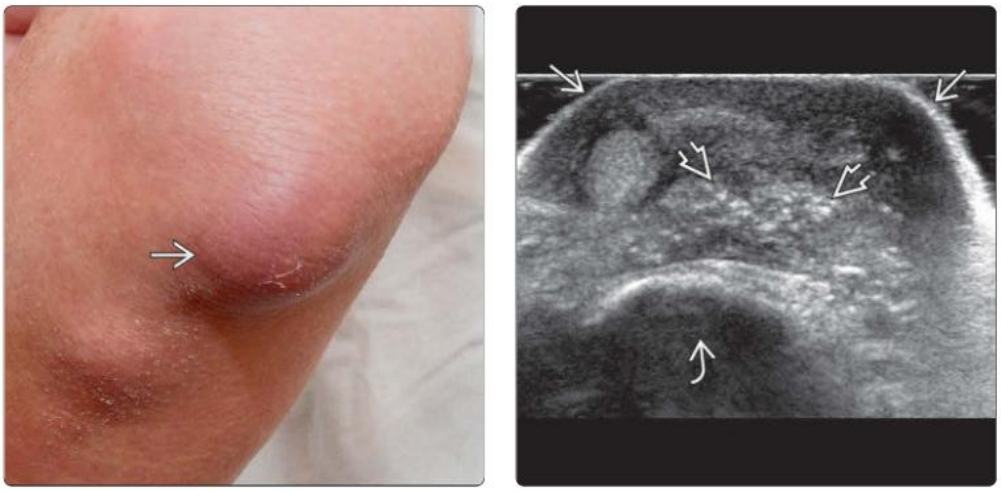

(Left) *Clinical photograph of the posterior elbow in a patient with known gout shows swelling and redness ➡, consistent with olecranon bursitis.* **(Right)** *Transverse US of the same location as the previous image shows gouty olecranon bursitis ➡ superficial to the olecranon ➡. The poorly defined bursa is distended with finely echogenic fluid (snowstorm appearance) ➡. Olecranon bursitis often appears quite solid irrespective of etiology and can masquerade as a soft tissue mass.*

(Left) *Transverse US of the elbow shows a large joint effusion with a few fine, mildly echogenic foci and occasional coarser echogenic foci, suggestive of crystal deposition with minimal synovial proliferation. Crystal arthritis may occasionally contain only a few visible crystal aggregates.* **(Right)** *Longitudinal color Doppler US of the dorsal 3rd metacarpophalangeal joint shows severe acute-on-chronic gouty synovitis with synovial proliferation, small echogenic gouty deposits, and severe hyperemia.*

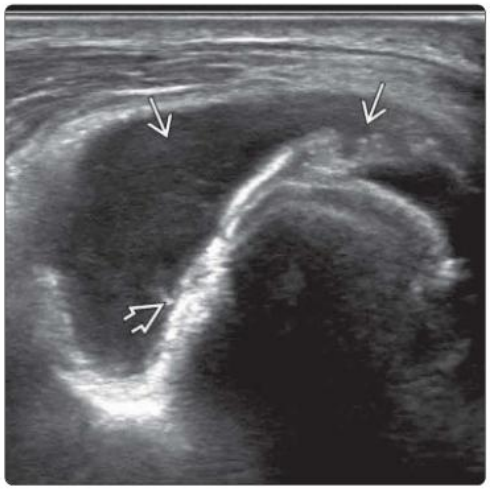

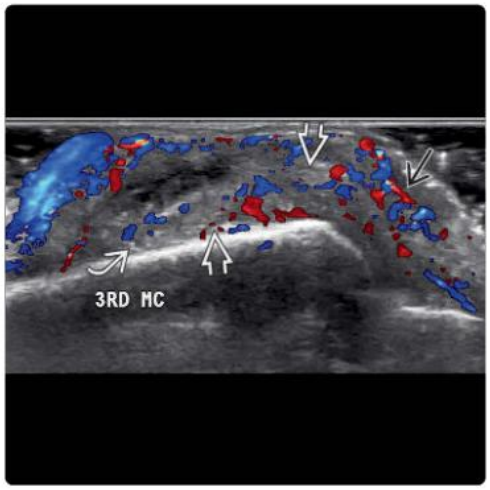

(Left) *Dual-energy CT (DECT) 3D-rendered image shows multiple urate deposits (green) in both knees (e.g., popliteal groove, prepatellar bursae, and meniscus). Automatic total urate volumes were 11.9 cm² and 3.4 cm², respectively.* **(Right)** *Longitudinal US of the dorsoulnar wrist shows gouty arthritis with small, echogenic foci in the joint (snowstorm appearance) and a thick urate deposit on the articular disc surface. The ulnar head and extensor carpi ulnaris tendon are normal.*

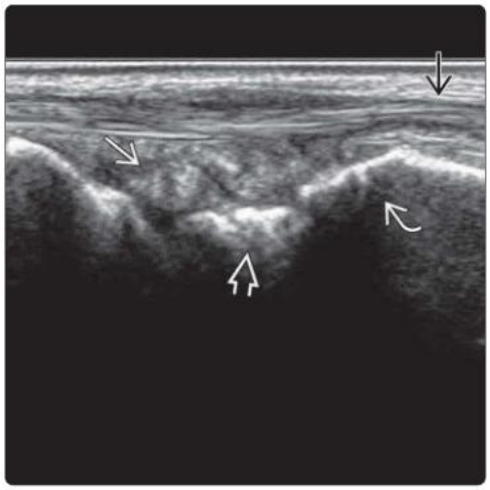

(Left) *Longitudinal US of the anterior elbow in a patient with acute gout shows "urate icing" or double-contour sign on the surface of capitellum cartilage due to crystal deposition, a specific sign for gouty arthropathy. Crystal deposition is also seen in the thickened synovium.* **(Right)** *Transverse US of the femoral trochlea shows an echogenic band within the midzone of articular cartilage due to CPPD deposition. This pattern of crystal deposition is quite specific for CPPD disease. This image was obtained with the knee flexed.*

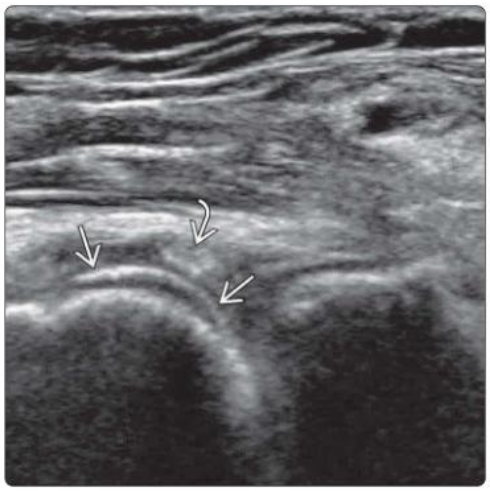

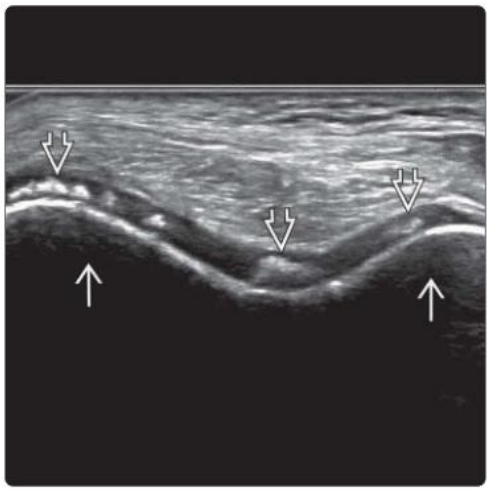

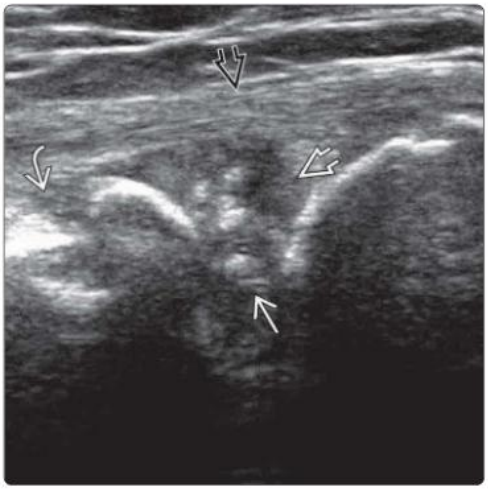

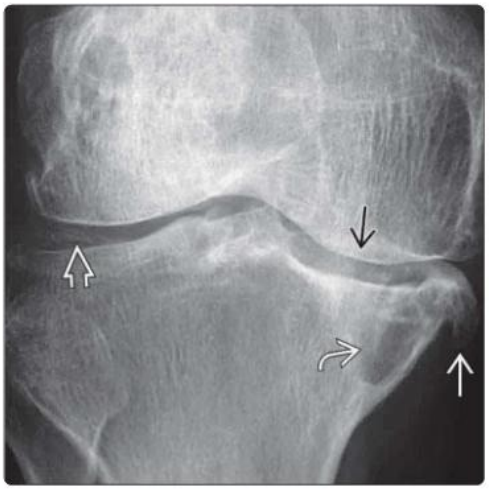

(Left) *Longitudinal US of the knee shows echogenic foci ➡, due to CPPD deposition, within the lateral meniscus ➡. The lateral collateral ligament ⇨ is normal. There is a marginal bony erosion ➡.* **(Right)** *Anteroposterior radiograph in the same patient shows chondrocalcinosis of the lateral meniscus ➡. There is also quite severe osteoarthritis with marginal osteophytosis ➡, joint space narrowing ⇨, and a large subchondral cyst ➡.*

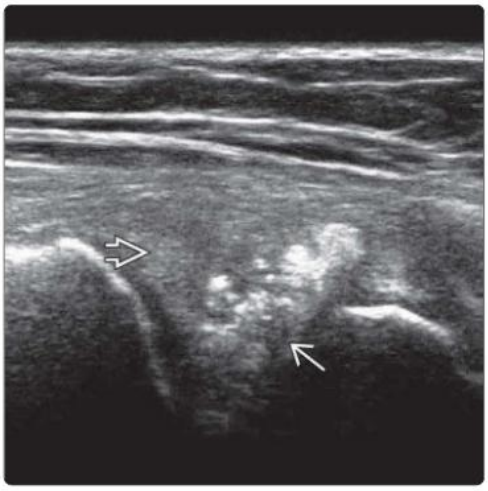

(Left) *Longitudinal US of the medial aspect of the knee shows echogenic foci ➡ due to CPPD deposition within the medial meniscus ➡.* **(Right)** *Anteroposterior radiograph in the same patient shows moderate chondrocalcinosis of both the medial and lateral menisci ➡. Calcium pyrophosphate crystals deposit centrally in the menisci, while urate crystals deposit initially on the surface of the menisci.*

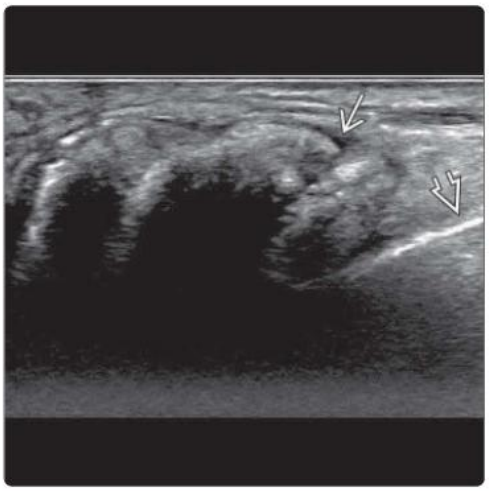

(Left) *Sagittal CT reconstruction of the 1st MTPJ region shows large, well-marginated bony erosions ➡ and a heavily calcified soft tissue mass ➡, consistent with chronic tophaceous gout. Percutaneous biopsy is not needed in this context.* **(Right)** *Longitudinal US of the same area (same patient) shows a hard tophus ➡ obscuring the MTPJ distal to the 1st metatarsal shaft ➡. Underlying erosions are not visible. Combining US with radiography or CT is helpful in assessing gouty arthritis.*

KEY FACTS

IMAGING

- Shallow acetabulum ± subluxation of femoral head
- US is useful before 6 months of age
- Normal hip
  - Capsular laxity: > 50% bony coverage femoral head at rest with < 50% bony coverage on stress examination or normal movement
- Subluxation: < 50% bony coverage at rest
- Dislocation: Femoral head lies completely outside bony acetabulum at rest
- Modified Graf staging
  - Type Ia = mature hip, angular bony promontory, α ≥ 60°, β < 55°
  - Type Ib = mature hip, roundish bony promontory, α ≥ 60°, β < 55°
  - Type IIa = physiologic immaturity < 3 months, α = 50-59°, β = 55-77°
  - Type IIb = immaturity > 3 months, α = 50-59°, β = 55-77°
  - Type IIc = critical hip, subluxation, α = 43-49°, β > 77°
  - Type III = dislocated hip, α < 43°
  - Type IV = dislocated hip, inverted labrum, α < 43°
- Roundish anterior acetabular rim can be physiologic & more often seen in immature hips
- Obtain single image showing deepest part of acetabulum, triradiate cartilage, center of femoral head, straight iliac contour

TOP DIFFERENTIAL DIAGNOSES

- Physiologically immature hip in neonate or premature baby

DIAGNOSTIC CHECKLIST

- Key to diagnosis rests on obtaining correct coronal (longitudinal) view
- Be clear with respect to definitions of capsular laxity, subluxation, & dislocation
  - Useful to have these definitions written on templated US report
- If in doubt, repeat US in 2-4 weeks

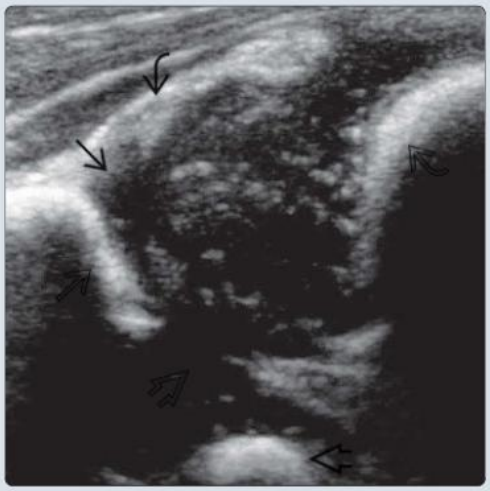

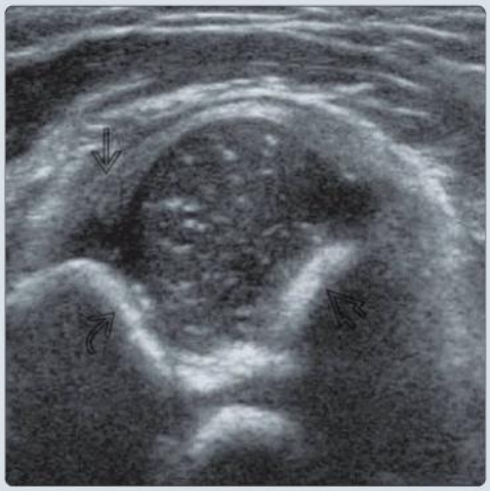

(Left) *Longitudinal coronal US shows a standard view of a normal hip. This view includes the osseous acetabular roof ➡, cartilaginous acetabular roof ⇨, acetabular labrum ⇨, triradiate cartilage ➡, ischium ⇨, and ossified femoral metaphysis ⇨.* **(Right)** *Transverse US of a normal hip shows the femoral head well centered within the acetabulum (ice cream cone view). The anterior pillar of acetabulum ⇨, acetabular labrum ➡, femoral metaphysis ⇨, and gluteal muscle are shown.*

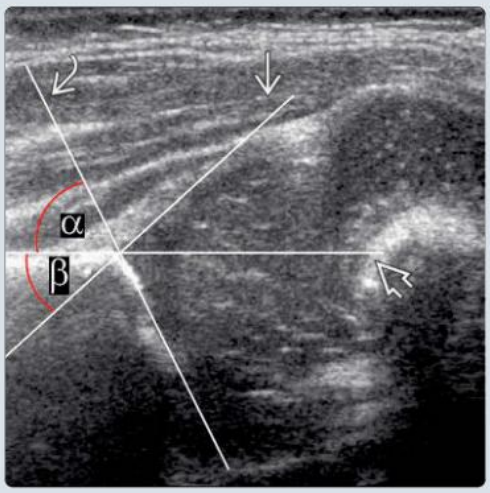

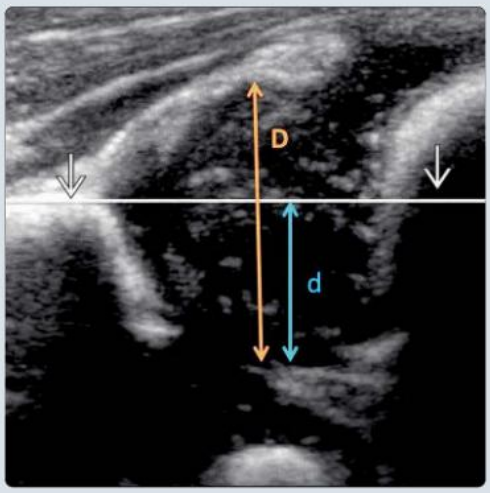

(Left) *Longitudinal coronal US shows a standard view of a normal hip. Note the tangential lines along the ilium ➡, acetabular roof ⇨, cartilaginous roof ➡, and the α and β angles formed by the intersection of these lines.* **(Right)** *Longitudinal US shows a standard coronal view of a normal hip with a well-covered femoral head. The portion of the femoral head diameter (d) covered by bone acetabulum (D) is > 50% (d/D > 50%). Note the iliac line ➡.*

TERMINOLOGY

Abbreviations

- Developmental dysplasia of hip (DDH)

Synonyms

- Congenital dysplasia of hip (CDH) (less appropriate)

Definitions

- Underdevelopment of acetabular component of hip joint

IMAGING

General Features

- Best diagnostic clue
  - Shallow acetabulum ± subluxation of femoral head
- Morphology
  - Ranges from shallow acetabulum to complete dislocation with false acetabulum ("pseudoacetabulum")
    - Secondary hypoplasia of femoral head

Ultrasonographic Findings

- Both morphology (coronal & transverse views) & dynamic evaluation
- Morphology: Graf technique
  - Coronal ("egg in spoon") view
    - Obtained from lateral approach with hip & knee in slight (~ 20°) flexion; infant in decubitus (or supine) position
    - Align transducer 10-15° obliquely (usually posteriorly) from coronal plane to obtain straight iliac line
    - Obtain single image showing deepest part of acetabulum, triradiate cartilage, center of femoral head, straight iliac contour
      - Position too anterior → false-positive result; too posterior → false-negative result
    - Normal hip
      - Sharp edge to ossified acetabular roof (promontory)
      - Roundish anterior acetabular rim can be physiologic & often seen in immature hips
  - Transverse ("ice cream cone") view
    - Shows femoral head overlying triradiate cartilage
  - 3 lines drawn on coronal view to assess acetabular morphology
    - Iliac line: Line along straight contour of ilium
    - Acetabular roof line: Line along osseous acetabular roof
      - From promontory to triradiate cartilage
    - Cartilage roof line: Line from promontory to tip of labrum
  - α angle: Intersection between iliac line & acetabular roof line
    - α angle is acetabular angle
    - Reflects steepness of acetabular roof
      - The greater the angle, the more mature the hip
      - The smaller the angle, the more dysplastic the hip
  - β angle: Intersection between iliac line & cartilage roof line
    - Represents elevation of acetabular labrum
    - Greater β angle means greater displacement of femoral head & less coverage of cartilaginous roof
    - β angle is less critical than α angle
  - Modified Graf staging
    - Type Ia = mature hip, angular bony promontory, α ≥ 60°, β < 55°
    - Type Ib = mature hip, roundish bony promontory, α ≥ 60°, β < 55°
    - Type IIa = physiologic immaturity < 3 months, α = 50-59°, β = 55-77°
    - Type IIb = delayed ossification = immaturity > 3 months, α = 50-59°, β = 55-77°
    - Type IIc = very deficient acetabulum = subluxation, α = 43-49°, β > 77°
    - Type III = dislocated hip, α < 43°
    - Type IV = severe dysplasia = dislocated hip, inverted labrum, α < 43°
- Dynamic testing: Apply Barlow maneuver (i.e., posterior force on adducted & flexed hip)
  - Tries to displace femoral head from acetabulum during real-time imaging
  - Lack of relaxation by infant can limit acquisition of optimal stress view → false-negative examination
  - Counterforce applied to back of infant
  - Acetabular bony coverage
    - Portion of femoral head contained within bony acetabulum
    - Center of femoral head relative to iliac straight line
    - Capsular laxity: ≥ 50% bony coverage of femoral head at rest, < 50% bony coverage on stress examination or active movement
    - Subluxation: < 50% bony coverage at rest
      - Some centers define subluxation as < 33% bony coverage & 33-50% as indeterminate
    - Dislocation: Femoral head lies completely outside bony acetabulum at rest
- Normal hip
  - Should have ≥ 53% of femoral head covered by bony acetabulum (bony coverage); normal α angle

Radiographic Findings

- Radiography
  - Hip dysplasia associated with relatively shallow acetabulum with slanting roof & relatively small superolaterally placed femoral head
  - Hilgenreiner line links tops of both triradiate cartilages
    - Femoral metaphysis should lie below Hilgenreiner line
  - Perkin line is perpendicular to Hilgenreiner line through lateral margin of bony acetabulum
    - Femoral capital epiphysis should lie within inner lower quadrant of intersection between Perkin & Hilgenreiner lines
  - Acetabular index is angle between acetabular roof & Hilgenreiner line
    - 30-32° in newborn; ↓ in older children

MR Findings

- T2WI
  - Inverted limbus of acetabular roof is best seen on coronal images
    - Hypertrophy of hypointense ligamentum teres & fibrofatty pulvinar

Imaging Recommendations

- Best imaging tool
  - US is useful up to 6 months of age
  - Limited at 6-9 months & not useful thereafter
    - Obscured by femoral capital ossification centers
- Protocol advice
  - 0-3 months: Linear transducer ≥ 10 MHz
    - In big infant, it is better to use 7.5 MHz in order to see ischium (bone landmarks are more important)
  - Lateral decubitus (or supine) position with standard orthogonal views
    - Hip & knee in slightly flexed position
  - Ensure that definitions of capsular laxity, subluxation, & dislocation are clear to those interpreting US result
    - Useful to have these definitions written on templated US report
  - Useful to continue screening hip during active movement even if child is restless

DIFFERENTIAL DIAGNOSIS

Physiologic Immature Hip

- In neonate or premature baby

PATHOLOGY

General Features

- Etiology
  - Laxity of joint capsule
  - Inadequate contact between acetabulum & femoral head
- Relevant anatomy
  - Osseous acetabulum formed by portions of ilium, ischium, & pubis
    - These osseous elements unite at triradiate cartilage (growth cartilage)
  - Echogenic fibrocartilage at edge of cartilaginous roof is true acetabular labrum
  - Ossification center of femoral head appears on US before it appears radiographically (6th-8th week)

Gross Pathologic & Surgical Features

- Hourglass-shaped joint capsule
- Femoral head flattened medially
- Thickened tight transverse ligament

CLINICAL ISSUES

Presentation

- Most common signs/symptoms
  - Palpable clunk during Ortolani & Barlow maneuvers
- Clinical profile
  - Barlow maneuver (same maneuver used in US technique)
    - Hip is flexed to 90° & gently adducted while thigh is pushed posteriorly
    - "Clunk" is felt as femoral head dislocates
  - Ortolani maneuver
    - Hip is flexed to 90° & gently abducted while thigh is lifted anteriorly
    - "Clunk" is felt as dislocated femoral head reduces

Demographics

- Age
  - Newborns
- Sex
  - M:F = 1:4
  - Left hip is 3x more commonly affected than right hip
- Epidemiology
  - Dysplasia: 0.8% of newborns (0.3% boys, 1.4% girls)
- Risk factors
  - Positive family history, breech presentation, oligohydramnios, torticollis, foot deformity
    - 3% of breech births; 8% of girls with breech birth have DDH

Natural History & Prognosis

- Prognosis
  - Physiologic hip joint laxity of newborn without acetabular dysplasia resolves spontaneously
  - Early treatment of DDH: Excellent result with Pavlik harness or splint
    - Acetabulum particularly amenable to remodeling during first 10 postnatal weeks
    - Contact between femoral head & acetabulum is necessary for normal acetabular development
  - Delayed treatment of DDH: Irreversible dysplasia
    - Hip muscle tightness; joint space fills with fibrofatty tissue; ligamentum teres & joint capsule redundant
    - Acetabulum cannot be remodeled
- Limited range of movement, adductor spasm
- Limb shortening & secondary hip osteoarthritis or pseudoacetabulum

Treatment

- Conservative
  - Pavlik harness ± closed reduction (if dislocated)
- Surgical for dislocation or subluxation failing to respond to conservative treatment
  - Open reduction + spica cast
  - Adductor tenotomy + release of iliopsoas
  - Varus (derotational) vs. reconstructive osteotomy

DIAGNOSTIC CHECKLIST

Consider

- On US examination, incorrect orientation can make deep hip appear shallow
  - Not possible to make shallow hip appear deep

Image Interpretation Pearls

- Key to diagnosis rests on obtaining correct coronal (longitudinal) view
- Identify landmarks: Osseous promontory, triradiate cartilage, tip of labrum
- Be clear with respect to definitions of capsular laxity, subluxation, & dislocation
- If in doubt, repeat US in 2-4 weeks

SELECTED REFERENCES

1. Kolovos S et al: Ultrasonographic screening for developmental dysplasia of the hip: the Graf method revisited. Eur J Orthop Surg Traumatol. 34(2):723-34, 2024

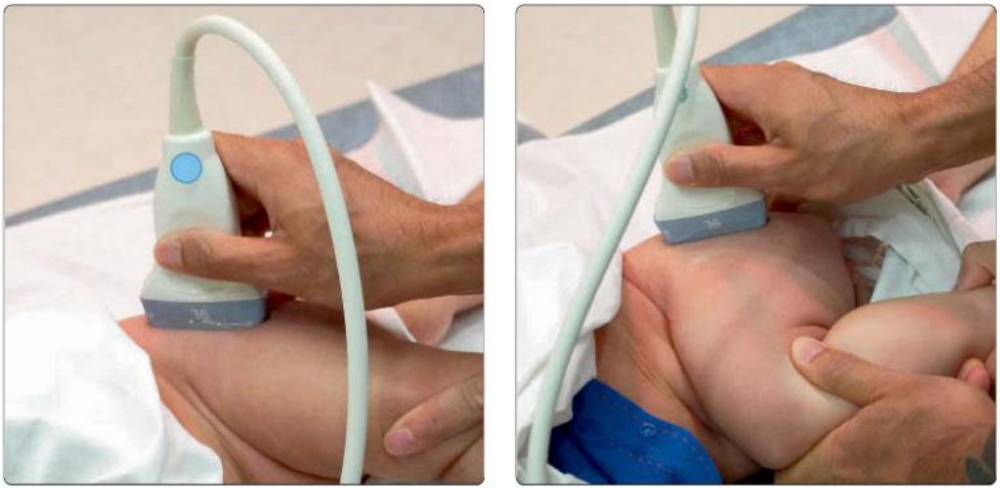

(Left) *Clinical photograph shows the position of a baby during scanning for nonstress views of hip. The baby is in the lateral decubitus position with the hip flexed to only ~ 20°. The transducer is oriented in a nearly coronal position.* **(Right)** *Clinical photograph shows the technique for obtaining stress views of the hip. The baby is in a lateral decubitus position. The hip is adducted and flexed with a steady applied force being directed posteriorly. The transducer remains orientated in a nearly coronal position (a counter force to the back is provided by a helper).*

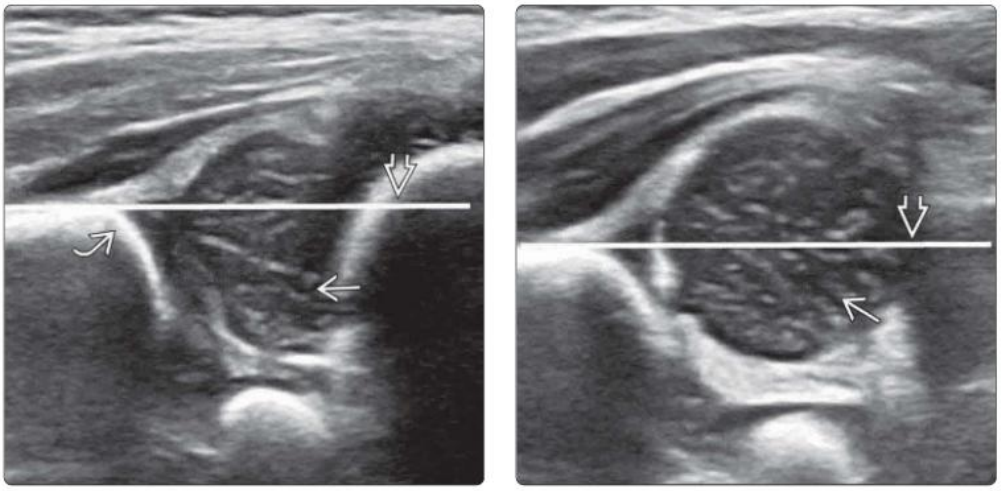

(Left) *Longitudinal US shows an immature acetabulum with a roundish acetabular promontory ⇒. Most of the unossified femoral head ⇒ lies below the iliac line ⇒. In other words, > 50% of the femoral head is covered by bony acetabulum, indicating good bony coverage.* **(Right)** *Longitudinal US in the same patient during a stress maneuver shows that > 50% of the femoral head ⇒ lies slightly above the iliac line ⇒. This indicates capsular laxity and is common in newborns and premature infants.*

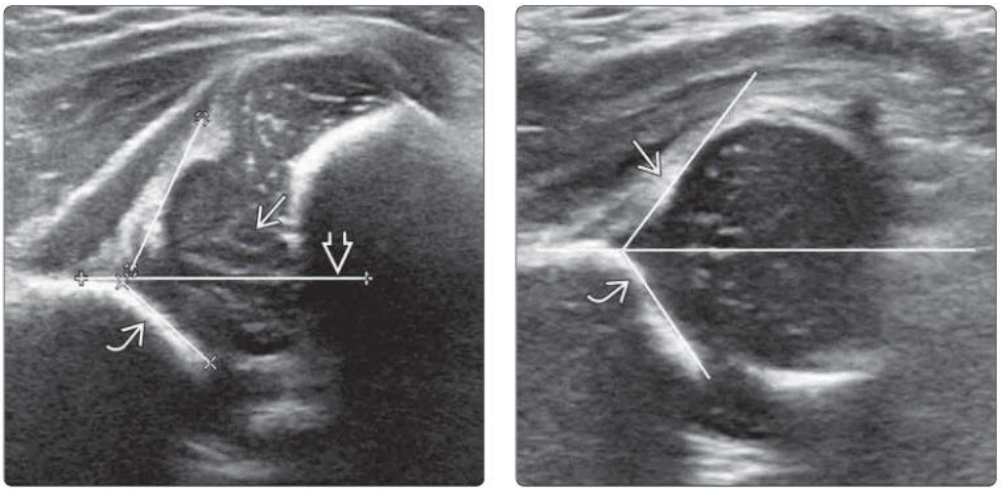

(Left) *Longitudinal coronal US in a neonate shows an immature shallow acetabulum ⇒ with a decreased a angle (45°). The femoral head ⇒ is mildly subluxed being located mainly above the iliac line ⇒.* **(Right)** *Longitudinal coronal US of the same hip 3 months later shows that the previously shallow bony acetabulum has now become less shallow (a angle = 57°) ⇒. This is an expected normal maturation of the acetabulum. Note the normal acetabular labrum ⇒.*

(Left) *Longitudinal coronal US of the hip shows a roundish acetabular promontory ➡, indicative of acetabular immaturity. The acetabulum ➡ is still deep with good bony coverage of the femoral head.* **(Right)** *Longitudinal coronal US of the same hip during stress testing shows moderate capsular laxity with < 50% coverage of the femoral head by the bony acetabulum, as indicated by the iliac line ➡. Treatment is indicated as well as follow-up US in 4 weeks.*

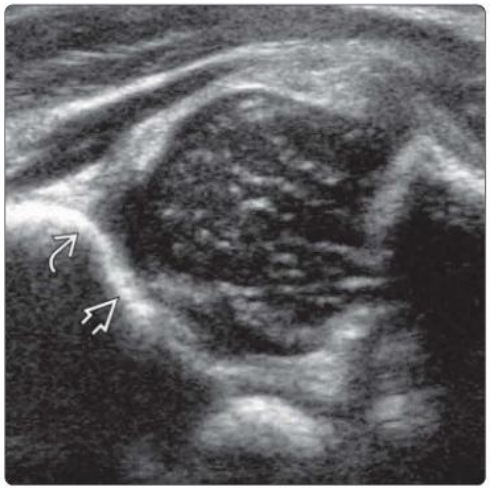

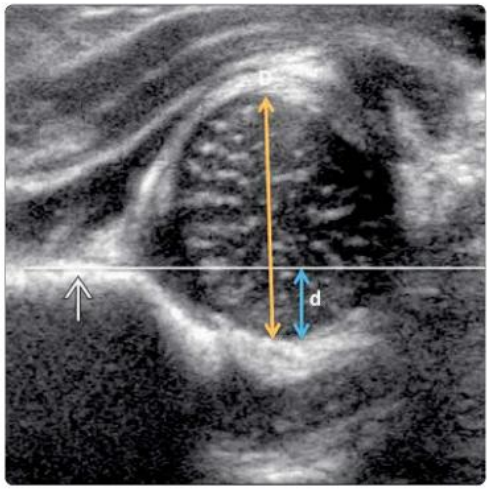

(Left) *Longitudinal coronal US of the same hip 4 weeks later shows that the femoral head is now not subluxed during stress maneuver, i.e., d/D > 50%. The acetabulum promontory is also sharper ➡. Early diagnosis and proper treatment can lead to dramatic improvement.* **(Right)** *Longitudinal US of the contralateral hip in the same patient shows a slightly roundish acetabular promontory ➡. However, the acetabular bony roof ➡ is well formed and deep.*

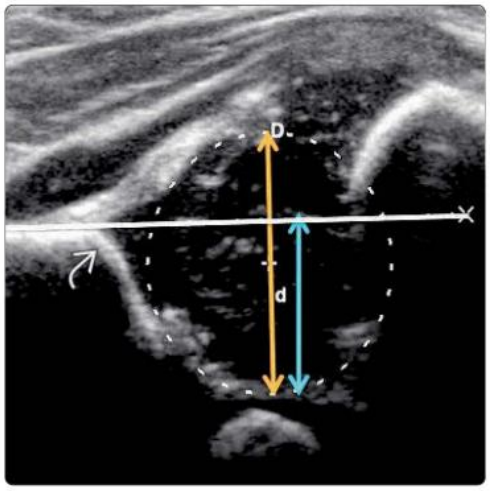

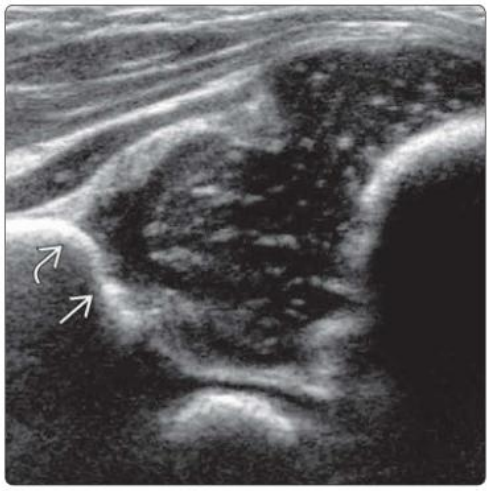

(Left) *Longitudinal coronal US shows a moderately dysplastic hip with a shallow acetabulum ➡. The a angle is 44° (type IIc). Moderate femoral head subluxation is present. The acetabular labrum ➡ is everted. The femoral head ➡ is relatively small.* **(Right)** *Longitudinal US of the hip shows a severely hypoplastic acetabulum ➡ with a dislocated femoral head ➡. The labrum ➡ is interposed between the bony acetabulum and the femoral head. These features are compatible with type IV developmental dysplasia of the hip (DDH).*

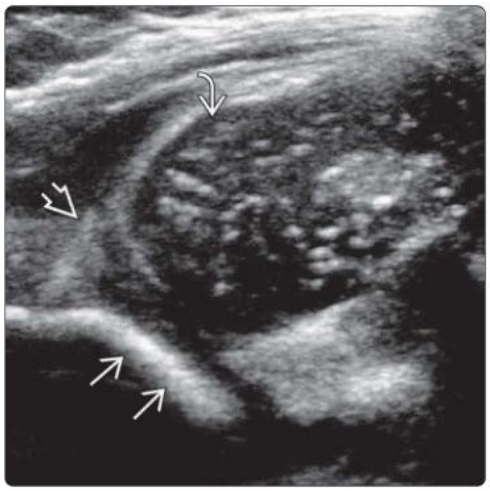

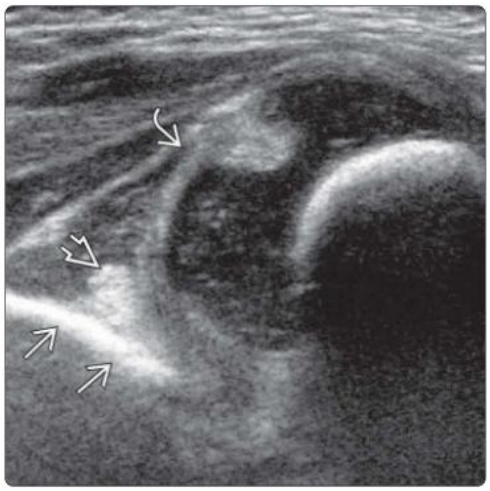

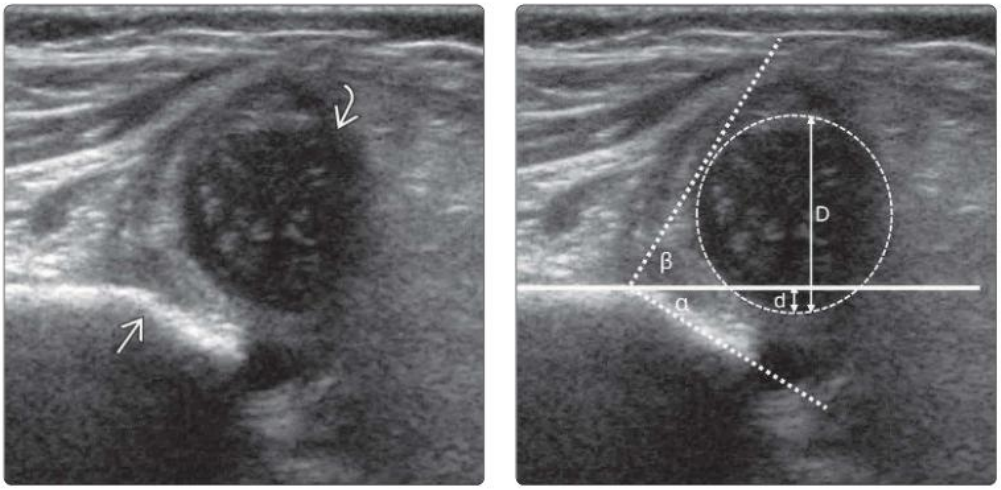

(Left) *Longitudinal US shows a severely dysplastic hip with a rounded shallow acetabulum ➡. The femoral head ➡ is severely subluxed.* **(Right)** *Longitudinal US of the hip in the same patient shows severe reduction in a angle measuring 38° and increase in β angle measuring 60°, classified as type IV DDH. The acetabular bony coverage is only 23% at rest, indicative of a subluxed hip.*

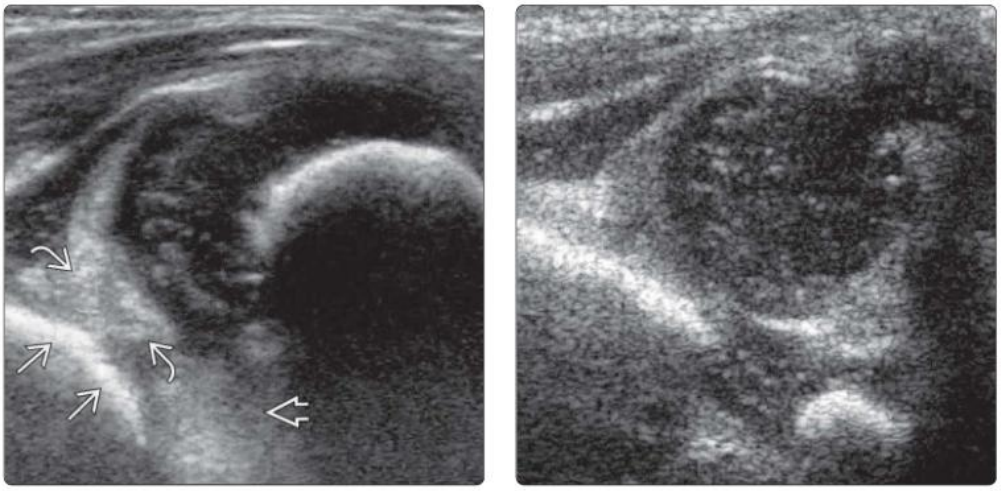

(Left) *Longitudinal US shows a severely dysplastic hip ➡ with lateral and cephalad displacement of the femoral head. The labrum ➡ is interposed between the femoral head and acetabulum and is thickened. The pulvinar ➡ is also thickened. The hip is classified as type IV DDH.* **(Right)** *Longitudinal US shows a severely dysplastic acetabulum with a dislocated hip. The bony acetabulum is not measurable, and the labrum cannot be well delineated. These features are compatible with type IV DDH.*

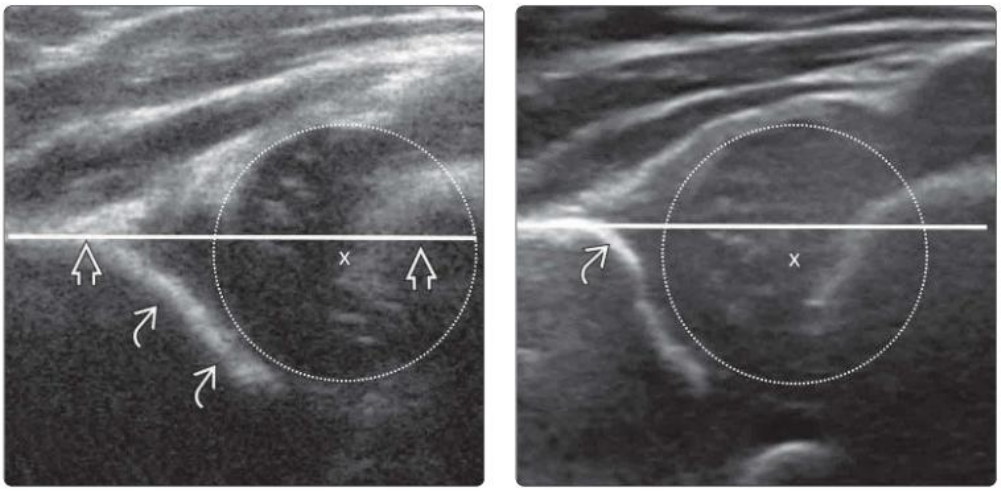

(Left) *Longitudinal coronal US shows an immature shallow acetabulum ➡ in a neonate with decreased a angle (42°). The femoral head is not subluxed, as the center (x) of the femoral head (dotted circle) is below the iliac line ➡.* **(Right)** *Longitudinal coronal US of the same hip on follow-up 14 weeks later shows that the previously shallow bony acetabulum is now of normal depth (a angle = 66°) ➡, though the promontory is still roundish, reflecting some residual immaturity after conservative treatment.*

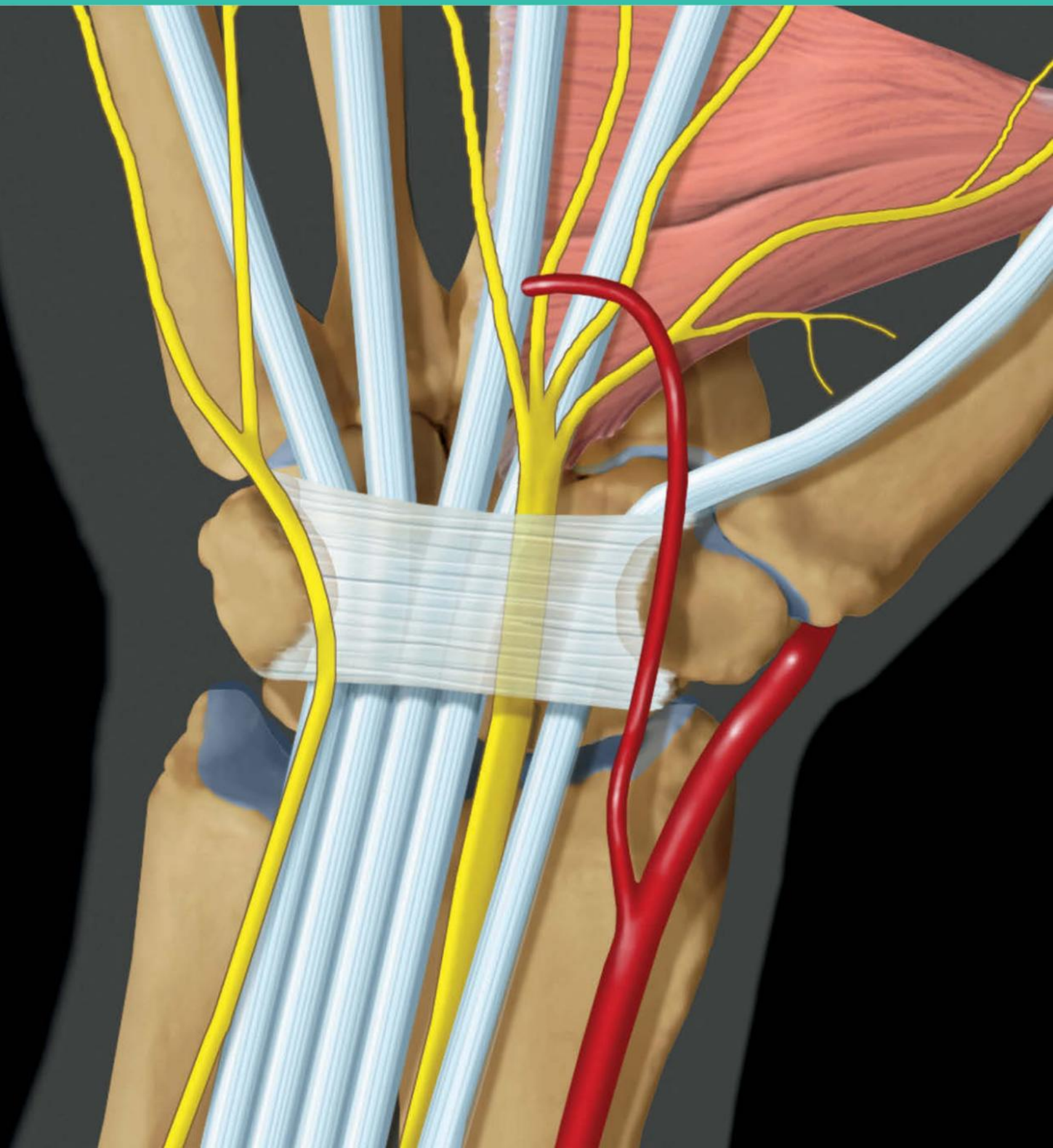

PART III
SECTION 4

Neurovascular Abnormalities

Nerve Injury	580
Carpal Tunnel Syndrome	590
Cubital Tunnel Syndrome	598
Brachial Plexus Pathology	602
Tarsal Tunnel Syndrome	608
Nerve Sheath Tumors	614
Vascular Dilatation or Inflammation	626

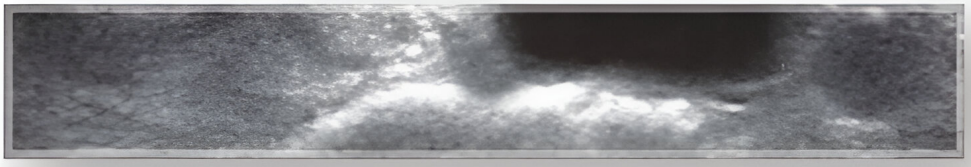

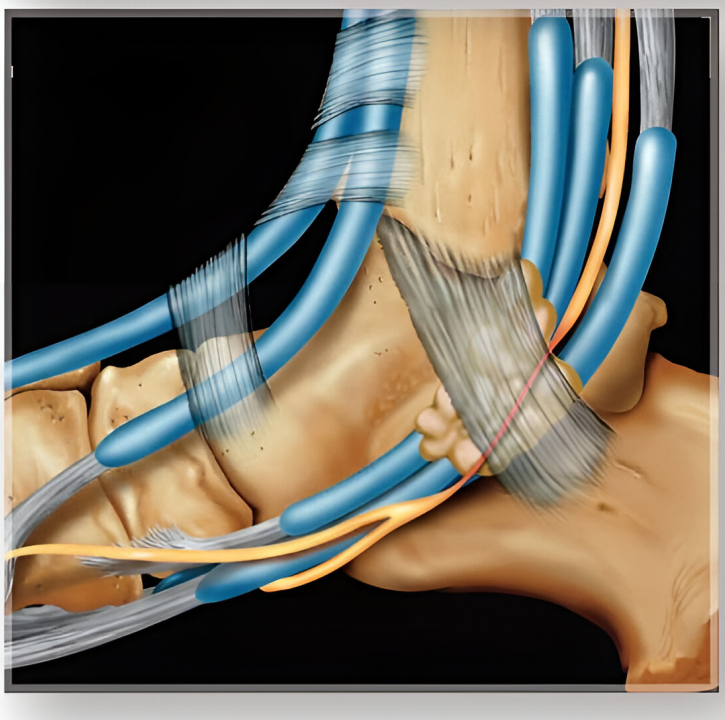

KEY FACTS

TERMINOLOGY

- Neurapraxia → impaired nerve function due to conduction block
- Axonotmesis = "axon cutting" → impaired nerve function due to tear of axon or axons & sheath
- Neurotmesis = "nerve cutting" → loss of nerve function due to complete tear of nerve
- End neuroma with complete transection
- Neuroma-in-continuity (NIC) with partial transection

IMAGING

- Disruption of normal fascicular pattern of nerve & focal nerve swelling
- Digital > median > ulnar > sciatic > radial > peroneal nerves
- US best shows nerve injury
- MR best shows denervated muscle changes
- Scan transversely along course of nerve
  - Observe caliber, integrity of nerve, echogenicity, & compressibility of perineural fat
- Align transducer along long axis of nerve
  - Best plane to appreciate continuity & discontinuity of epineurium & fascicles
- Measure cross-sectional area if swollen (vs. contralateral side)
- If partial tear, estimate degree (%) of transection
- Measure retraction gap, if present
- Neurapraxia: Nerve usually looks normal
  - ± focal swelling of nerve/fascicles
- Axonotmesis: Incomplete tear of nerve
- Neurotmesis: Complete tear of nerve ± retraction

DIAGNOSTIC CHECKLIST

- US is very good at localizing site of injury, determining severity of injury, & detecting perineural fibrosis/neuroma
- Check for integrity of epineurium followed by integrity of individual fascicles, if visible
- US, in general, probably slightly overestimates rather than underestimates nerve injury

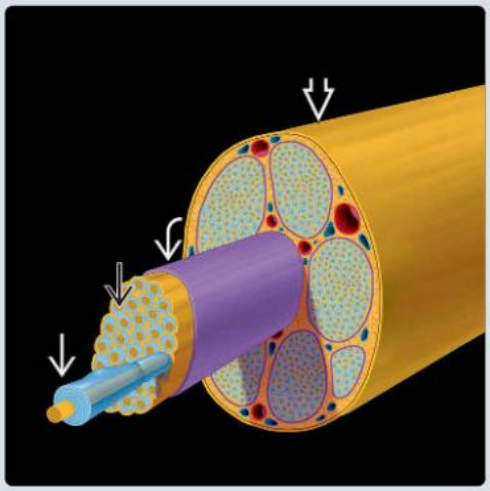

(Left) *Graphic of normal nerve structure shows myelinated axons ⇨ embedded in endoneurium ⇨ (seen as yellow). The fascicles are surrounded by perineurium ⇨. The nerve is surrounded by epineurium ⇨.* **(Right)** *Longitudinal US of the ulnar nerve ⇨ 1 month following blunt trauma shows mild localized swelling with poor definition of fascicular echo pattern ⇨ on the medial aspect of the elbow. No loss of neural continuity is evident. Appearances are consistent with neurapraxia.*

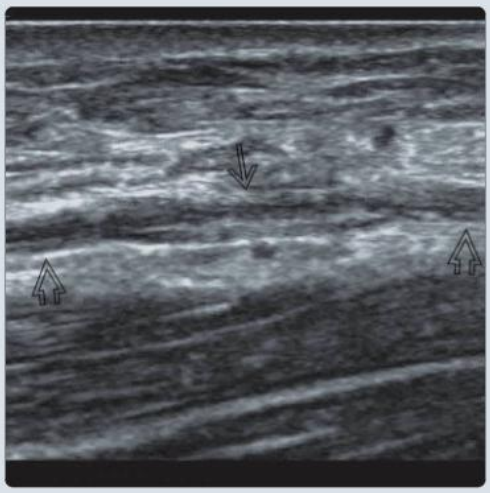

(Left) *Transverse US in a patient with suspected median nerve injury following brachial artery cannulation for endovascular procedure is shown. The median nerve ⇨ is swollen to over 2x its normal size. Surrounding soft tissues are swollen, the brachial artery ⇨ is irregular, and the endovascular procedure scar ⇨ is visible.* **(Right)** *Longitudinal US of the same area shows moderate swelling and impaired definition ⇨ of the median nerve ⇨ but no neural transection. This pattern of nerve injury is consistent with neurapraxia.*

TERMINOLOGY

Synonyms

- Neurapraxia: Saturday night palsy, honeymoon syndrome, crutch syndrome, wheelchair syndrome

Definitions

- Neurapraxia = impaired nerve function due to conduction block
  - Praxis = function (Greek)
- Axonotmesis = 'axon cutting' → impaired nerve function due to tear of axon or axons ± sheath
  - Severity variable depending on number of axons torn
- Neurotmesis = 'nerve cutting' → loss of nerve function due to disruption of entire nerve

IMAGING

General Features

- Best diagnostic clue
  - Disruption of normal fascicular pattern of nerve + focal nerve swelling
- Location
  - Digital > median > ulnar > sciatic > radial nerve > peroneal > tibial > femoral nerves
- Size
  - Ranging from marginally swollen nerve up to ~ 4x normal size
    - Chronic denervation → muscle atrophy
- Morphology
  - Ranges from focal nerve swelling to complete discontinuity with retraction ± neuroma
    - Slightly enlarged muscle in acute denervation → severe fatty atrophy with chronic denervation

MR Findings

- T1WI
  - Acute/subacute denervation → ± mild muscle swelling
  - Chronic denervation → muscle atrophy
- T2WI FS
  - Acute/subacute denervation → hyperintense muscle
    - ± mild ↑ in muscle size
- T1WI C+
  - Acute/subacute denervation → enhancement of denervated muscle
- Muscle edema & enhancement may be seen 24 hours after denervation
  - ↑ muscle edema parallels ↑ in muscle enhancement
    - Both probably reflect ↑ capillary engorgement & ↑ blood volume within affected muscle
  - Pattern of muscle involvement can predict likely nerve injury
- Muscle edema & enhancement reverse with reinnervation of muscle

Ultrasonographic Findings

- Detection of injury
  - Neurapraxia
    - Nerve & surrounding tissues often appear normal
    - ± focal swelling of nerve/fascicles
  - Axonotmesis & neurotmesis
    - Disruption of nerve continuity
    - Disruption of epineurium ± fascicles
    - ± surrounding hemorrhage or edema if acute
    - Evaluation in acute stage may be limited due to artifact caused by overlying wound
- Localization of injury
  - Nerves divide at inconstant levels
  - US can depict bifurcation level & confirm if main or distal branch is affected
- Type of injury
  - Axonotmesis: Incomplete tear of nerve
  - Neurotmesis: Complete tear (transection) of nerve
    - ± retraction (nerve < tendon)
    - Up to few cm, greater retraction if over mobile joint
- Presence of perineural fibrosis
  - Irregular hypoechoic tissue replacing echogenic perineural fat
  - Focal swelling of nerve
  - ± encroachment ± tethering of nerve
  - ± reduced motility of nerve on dynamic testing
- Presence of neuroma
  - Quite common finding
  - Hypoechoic rounded or ovoid mass at site of disrupted nerve
  - Connected to proximal end of severed nerve
    - Partial nerve injury → neuroma-in-continuity
  - Largely avascular
  - May be small & intraneural
    - Small neuromas may be difficult to distinguish from nodular fibrosis
  - End neuroma associated with complete nerve transection more common than neuroma-in-continuity with partial tear
- Direct impingement of nerve by fractured bone fragments/surgical material/fixation screws
- Muscle denervation
  - Mild swelling & ↑ echogenicity of affected muscle seen after 2 weeks
    - Due to capillary dilatation & muscle edema
  - Later → ↓ muscle bulk & ↑ echogenic fat within & between muscle bundles
    - Due to muscle atrophy & fatty replacement

Imaging Recommendations

- Best imaging tool
  - US best shows nerve injury
    - High resolution: Better visualization of fascicular anatomy & small nerves, e.g., digital nerve
    - Easy orientation along long & short axes of nerve
  - MR best shows denervated muscle changes
- Protocol advice
  - Scan transversely along course of nerve
    - Easiest plane to trace course of nerve
    - Observe caliber, integrity of nerve, echogenicity, & compressibility of perineural fat
  - Align transducer along long axis of nerve
    - Best plane to appreciate continuity & discontinuity of epineurium & fascicles
  - Measure CSA if swollen (vs. contralateral side)
  - If partial tear, estimate degree (%) of transection
  - Measure retraction gap, if present

- Observe nerve movement when passively moving adjacent joints

DIFFERENTIAL DIAGNOSIS

Tendon Injury

- Sometimes torn in conjunction with nerve
- Discontinuity of tendon fibers

Nerve Sheath Tumor

- May mimic traumatic neuroma
- Often visible entering & exiting nerve
- Traumatic neuromas are less vascular

Nerve Entrapment

- Typical locations
- Nerve swelling proximal to level of entrapment
  - Demyelination and endoneural fibrosis of entrapped nerve with secondary changes in innervated muscle

PATHOLOGY

General Features

- Etiology
  - Traction, blunt, or penetrating injury
    - Includes iatrogenic causes: Fracture repair & fixation, arthroscopy, carpal tunnel release, surgical exploration
- demyelination (neurapraxia) of entrapped nerve with secondary changes in affected muscle
- Relevant anatomy
  - Axon ± covered by myelin (myelinated or nonmyelinated nerve fiber)
  - Endoneurium = loose connective tissue between nerve fibers
  - Perineurial sheath groups nerve fibers into fascicles
  - Epineurium encircles & runs between fascicles; outer layers of epineurium are condensed into sheath
- Fascicles within large peripheral nerve continually divide & reunite (fascicular plexus)
  - Particularly in brachial & lumbar plexuses

Staging, Grading, & Classification

- Sunderland grading system
  - Grade 1: Neurapraxia
    - Neural tubes intact
      - No axonal regeneration required
  - Grades 2-4: Axonotmesis
    - Grade 2 (mild): Axon is disrupted but endo-, peri-, & epineurium intact
      - Regenerating axons always reach original motor & sensory targets
    - Grade 3 (moderate): Axons & endoneurium are disrupted but peri- & epineurium intact
      - Regenerating axons may not reach original motor & sensory targets
    - Grade 4 (severe): Axons, endo- & perineurium are disrupted but epineurium is intact
      - Regenerating axons usually do not reach original motor & sensory targets
  - Grade 5: Neurotmesis
    - Complete transection of all neural tubes
      - Regenerating axons invariably do not reach original motor & sensory targets
    - Classification system is difficult to apply clinically as mixed injury is common

Gross Pathologic & Surgical Features

- Axonal injury → Wallerian degeneration → regeneration

Microscopic Features

- Axonal apoptosis followed by phagocytosis
- Schwann cell proliferation
- Sprouting axonal filopodia → growth cone, guided by neurotrophic & neurotropic mediators

CLINICAL ISSUES

Presentation

- Most common signs/symptoms
  - Weakness ± numbness ± pain
- Other signs/symptoms
  - Nerve function fails sequentially
  - Motor function initially fails, followed by proprioception, touch, temperature, pain & autonomic function
    - Recovery in reverse order

Demographics

- Age
  - More common in young adults
- Sex
  - M:F = 2.2:1
- Epidemiology
  - 2-3% of patients admitted to level I trauma center
  - More common in dominant limb

Natural History & Prognosis

- Neurapraxia has excellent prognosis
- Axonotmesis & neurotmesis have variable prognosis depending on degree of injury
- Axons regenerate at ~ 1 mm/day (slower in older patients)

Treatment

- Neurapraxia: Supportive treatment
- Axonotmesis or neurotmesis
  - Immediate or delayed repair
    - Immediate repair if clean wound, no crush injury, good vascular supply, & soft tissue coverage
  - End-to-end closure
  - Nerve graft ± vascularization
  - Nerve transfer

DIAGNOSTIC CHECKLIST

Consider

- US is very good at localizing site of injury in axonotmesis/neurotmesis & detecting perineural fibrosis/neuroma
  - In general, US probably slightly overestimates rather than underestimates nerve injury

SELECTED REFERENCES

1. Bourke G et al: Updates in diagnostic tools for diagnosing nerve injury and compressions. J Hand Surg Eur Vol. 49(6):668-80, 2024

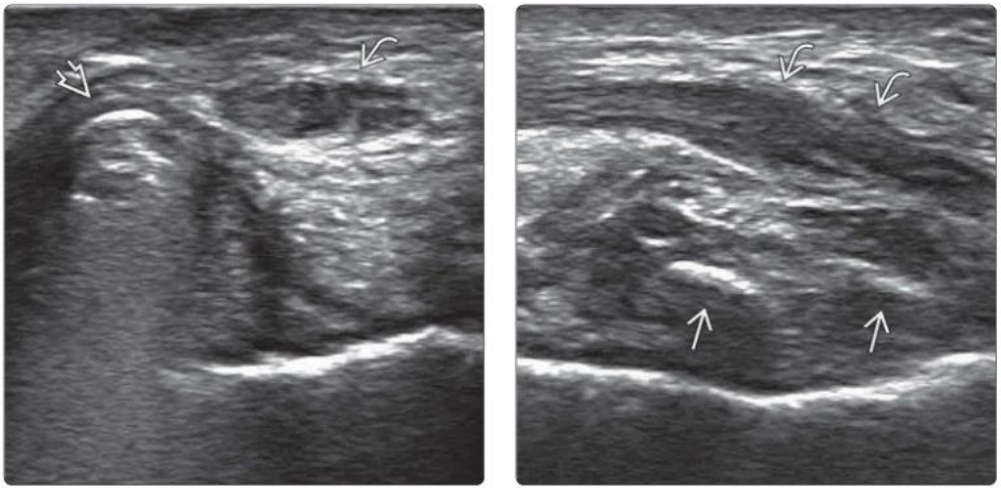

(Left) *Transverse US shows a swollen ulnar nerve in a patient with distal humeral fracture with internal fixation. The normal fascicular appearance is lost. The fixation screw is not impinging onto the nerve.* **(Right)** *Longitudinal US of the same area shows a segment of swollen ulnar nerve with loss of the normal fascicular appearance. Neural continuity is preserved. Features are compatible with severe neurapraxia. A few small displaced bone fragments are shown.*

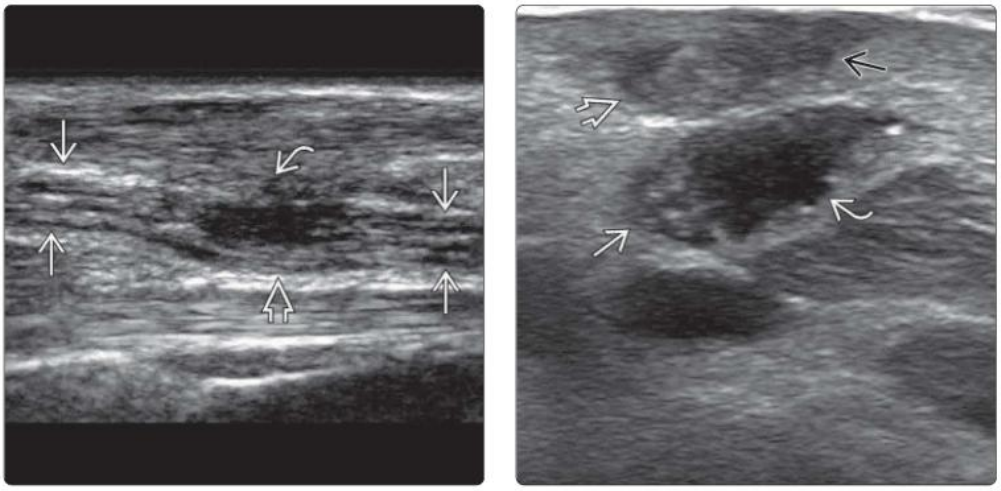

(Left) *Longitudinal US shows partial transection of the median nerve following a laceration with tear of the superficial fascicles. 50% of the nerve fascicles are estimated as torn with the deeper fascicles intact.* **(Right)** *Transverse US in a patient with wrist laceration injury shows partial transection of the median nerve with 60-70% of the fascicles torn on the radial aspect of the nerve. The torn palmaris longus tendon has been repaired with thickening and adjacent fibrosis.*

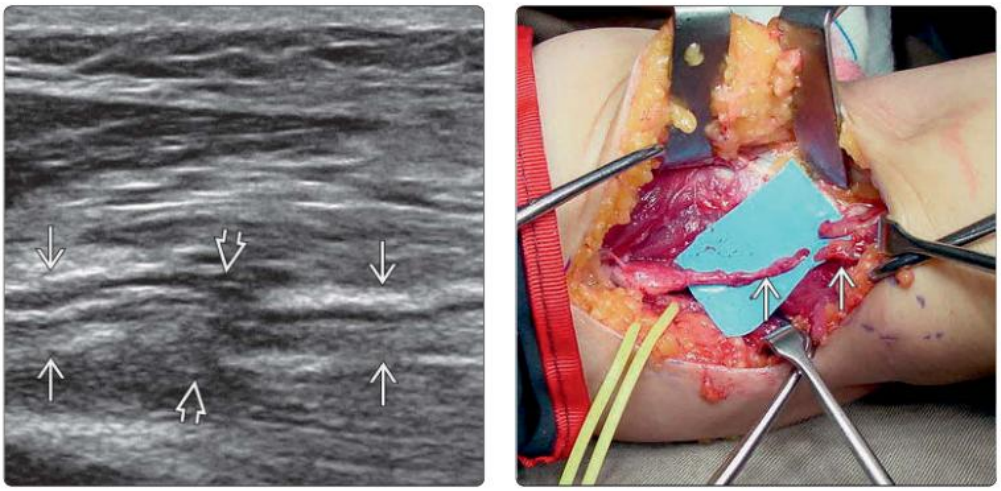

(Left) *Longitudinal US of the posterior arm region following a chop injury shows complete laceration (neurotmesis) and mild displacement of a swollen radial nerve.* **(Right)** *Clinical photograph shows the complete transection of the median nerve following a forearm laceration. (Courtesy P. C. Ho, MD.)*

(Left) *Graphic shows a normal nerve ⇄ with individual nerve fascicles shown.* **(Right)** *Graphic shows neurapraxia. In mild neurapraxia ⇄, the nerve, and its nerve fascicles, is mildly swollen. In moderate to severe neurapraxia ⇄, the nerve is moderately to severely swollen with swelling of the nerve fascicles. There is no discontinuity of any neural element. The swelling resolves with time and prognosis is excellent with complete restoration of neural function.*

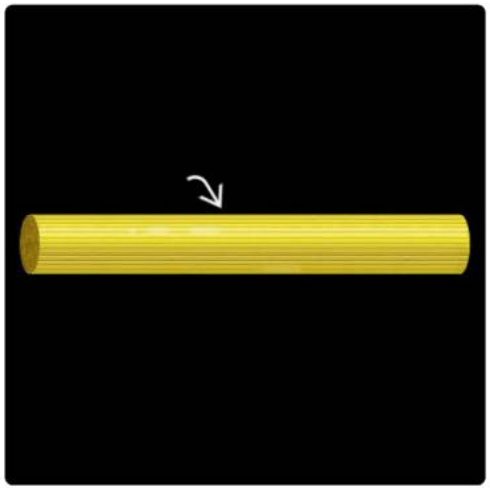

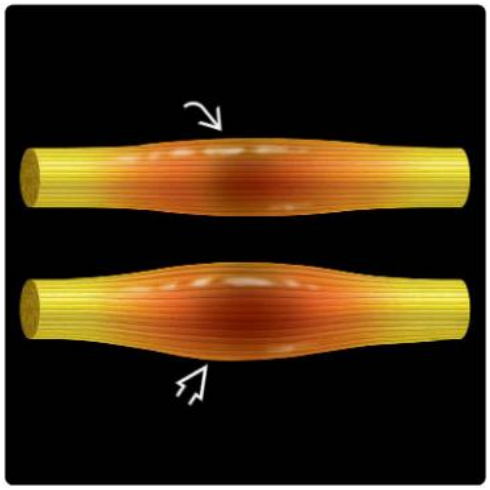

(Left) *Graphic shows partial transection ⇄ of a nerve with an intact epineurium ⇄ (an intraneural tear). The tear may heal with various degrees of intraneural fibrosis or result in neuroma formation.* **(Right)** *Graphic shows healing of an intraneural tear with mild ⇄ to moderate ⇄ intraneural fibrosis. The fibrosis forms at the site of the tear and appears as an ill-defined area of hypoechogenicity within the nerve.*

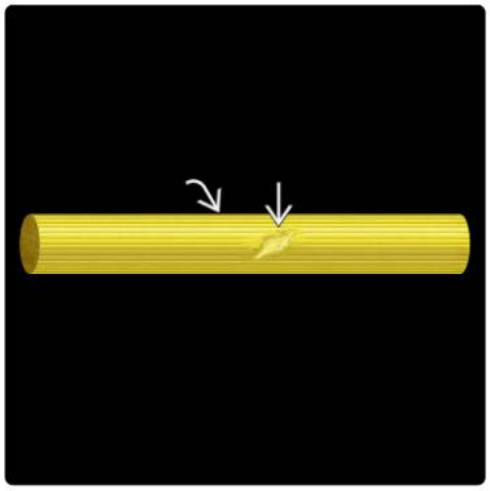

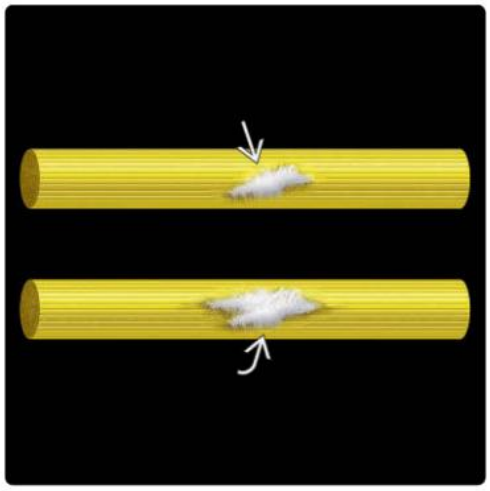

(Left) *Graphic shows another sequalae of an intra-eural tear with neuroma formation . ⇄. The neuroma is nodular and hypoechoic. As the epineurium ⇄ is intact, the neuroma lies within the confines of the nerve and is a form of neuroma-in-continuity (NIC).* **(Right)** *Graphic shows partial transection of a nerve with a disrupted epineurium ⇄. The tear may heal with fibrosis or result in neuroma formation.*

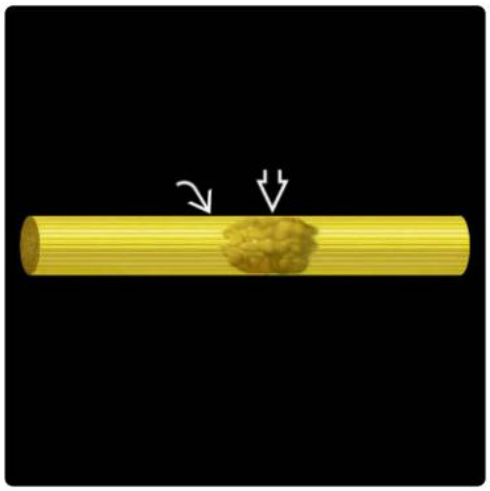

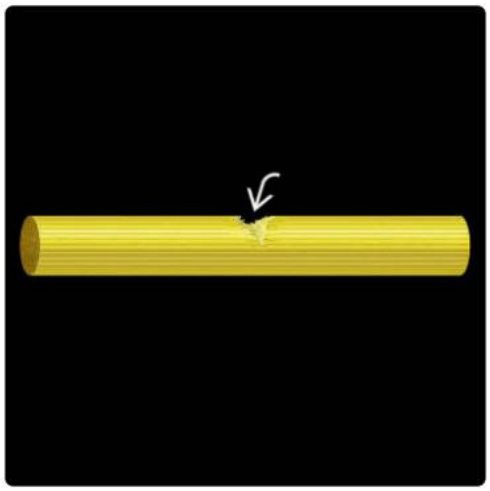

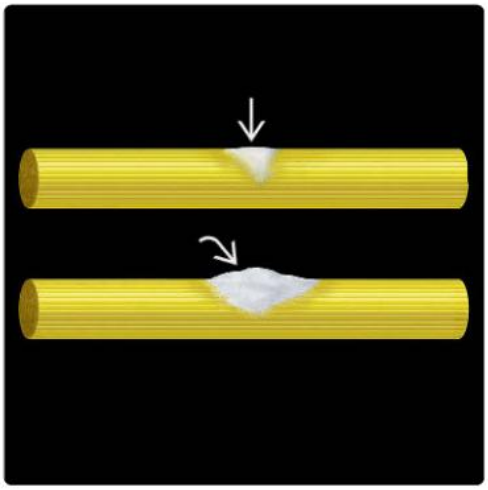

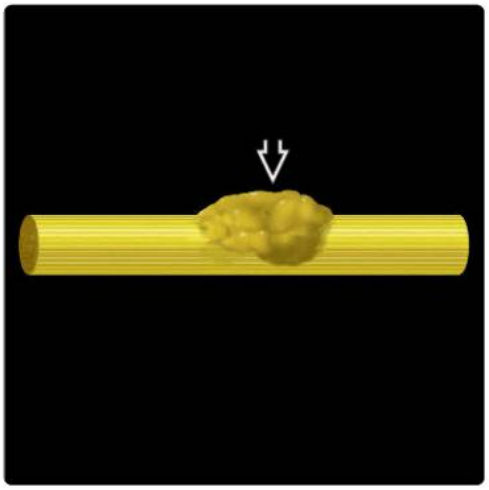

(Left) *Graphic shows healing at the site of partial nerve transection with mild ➡ to moderate ➡ fibrosis. The fibrotic scar may extend along and outside the nerve beyond the site of the tear to form a fibrotic mass, especially with more severe degrees of transection.* **(Right)** *Graphic shows neuroma formation ➡ at the site of partial nerve transection. The neuroma forms at the site of the tear with bulbous appearance at the site of disrupted epineurium and is also a form of NIC.*

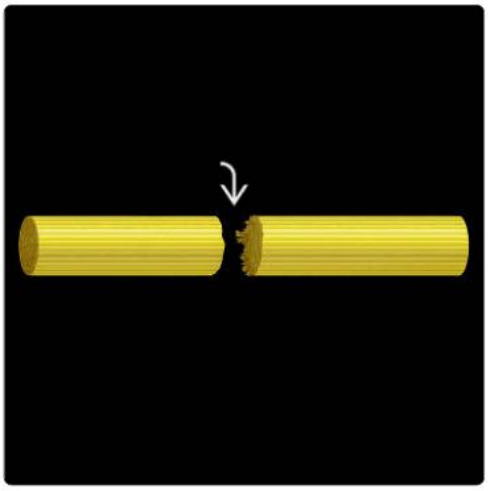

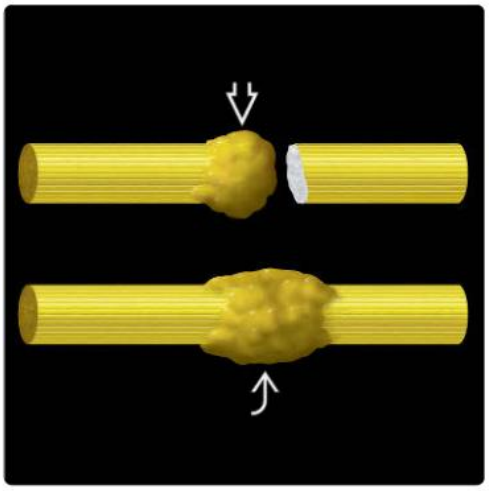

(Left) *Graphic shows complete transection ➡ of a nerve.* **(Right)** *Graphic shows neuroma formation ➡ at the proximal stump of a completely transected nerve, forming a bulbous nodule (also called a stump or terminal' neuroma). When the torn ends of the nerve are in close proximity, the neuroma may connect with the distal stump and form an NIC ➡. Localized pain or hypersensitivity can be elicited upon compression. Fibrosis can also form at the site of tear (not shown).*

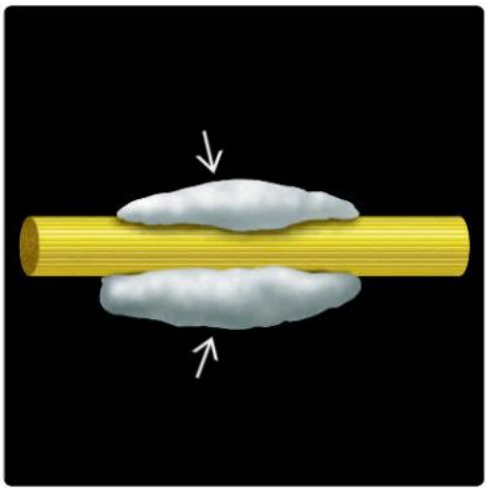



(Left) *Graphic shows solid perineural fibrosis ➡. This usually results from either perineural soft tissue injury with scarring or previous irradiation. Dense perineural scar tissue may encase or tether the nerve and lead to nerve entrapment symptoms.* **(Right)** *Graphic shows patchy perineural fibrosis ➡, which usually forms as a result of less severe perineural soft tissue injury or less intense irradiation. Noncompact fibrosis may form around the nerve and may also lead to nerve entrapment symptoms.*

(Left) *Longitudinal US of median nerve following self-induced injury 4 months earlier shows a fibrotic mass ⇨ replacing median nerve ⇨ at the wrist. No normal neural tissue is present though there is no neural discontinuity. At operation, the nerve was completely transected.* **(Right)** *Clinical photograph shows repaired ⇨, complete transection (neurotmesis) of the median nerve ⇨. Most traumatic nerve injuries are readily apparent clinically and usually do not require preoperative imaging. (Courtesy P. C. Ho, MD.)*

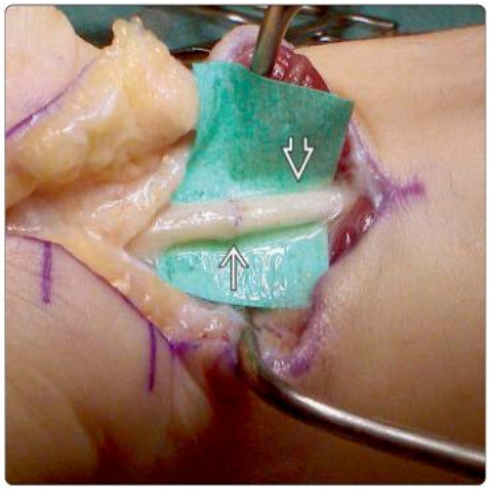

(Left) *Transverse US shows a displaced fractured bone fragment ⇨ mildly impinging onto the ulnar nerve ⇨ at the proximal forearm. There is thickening of some of the nerve fascicles ⇨ with intervening echogenic tissue ⇨ suggestive of reparative fibrosis.* **(Right)** *Longitudinal US of the same area shows that the bone fragment ⇨ is impinging onto the ulnar nerve ⇨. Overlying soft tissue injury with scarring ⇨ is noted.*

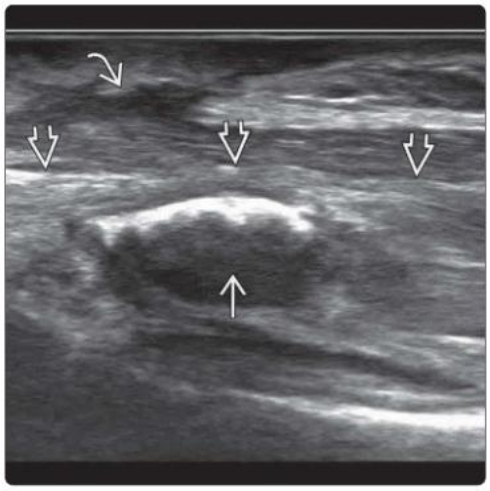

(Left) *Longitudinal US lateral to previous image centered on the ulnar nerve ⇨ shows echogenic fibrotic tissue ⇨ along the nerve. Most of the nerve fascicles ⇨ are intact. Features indicate mild partial transection with reparative fibrosis.* **(Right)** *Longitudinal US in a patient with laceration injury to the radial midpalm shows transection of the radial palmar digital nerve ⇨. A hypoechoic oval nodule ⇨ is present at the proximal stump, compatible with a stump neuroma. The metacarpal head ⇨ is noted.*

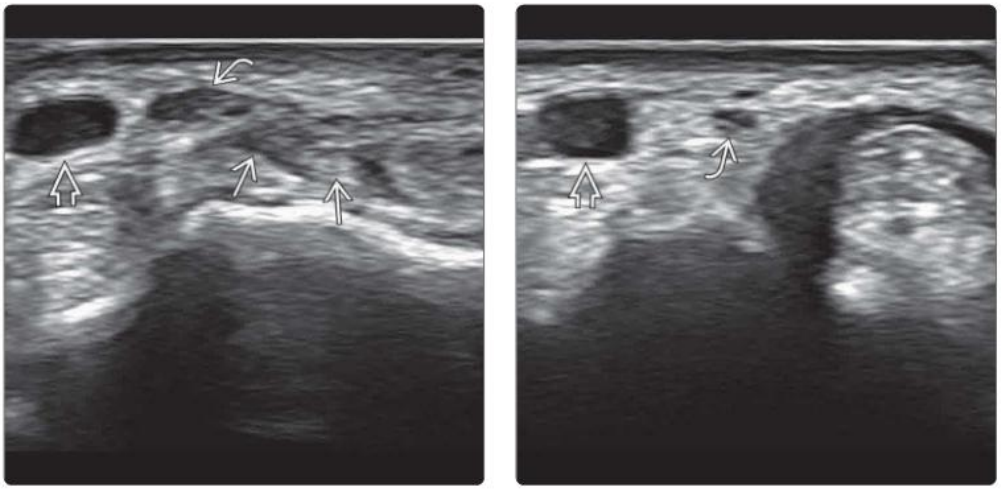

(Left) *Transverse US of a patient with previous resection of tenosynovial giant cell tumor from the dorsal radial wrist shows an oval hypoechoic neuroma of the sensory branch of the radial nerve (SRN). Moderate adjacent scarring is also present, causing entrapment of the SRN (Wartenberg syndrome). The radial artery is noted.* **(Right)** *Transverse US of the unaffected contralateral side shows a normal SRN and radial artery for comparison.*

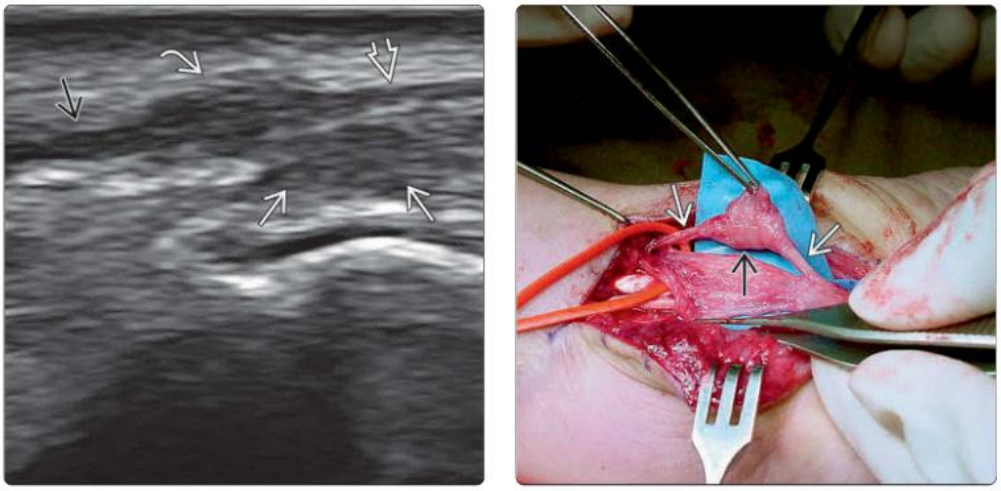

(Left) *Longitudinal US in the same patient shows SRN neuroma continuous with proximal and distal ends of nerve, compatible with a neuroma-in-continuity. Adjacent scar tissue is again noted.* **(Right)** *Clinical photograph shows a posttraumatic median nerve neuroma. The neuroma connects the 2 torn nerve endings. Most traumatic neuromas occur following complete nerve transection, though some can arise from incomplete nerve transection. (Courtesy P. C. Ho, MD.)*

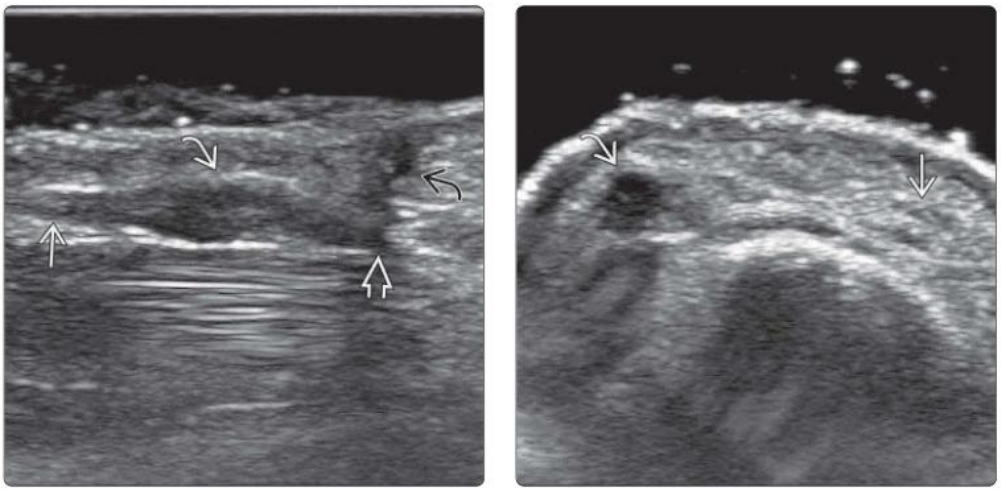

(Left) *Longitudinal US in a patient with previous laceration injury to the thumb shows high-grade partial transection injury of the radial digital nerve with neuroma formation. The soft tissue scar at the laceration site is shown.* **(Right)** *Transverse US in the same patient shows a hypoechoic nodule of the radial digital nerve, compatible with a neuroma. The normal ulnar digital nerve is shown. High-resolution US is the best imaging modality for assessment of small nerves.*

(Left) *Transverse US in a patient with history of trigger thumb release shows moderate hypoechoic scar tissue along the operative bed adjacent to the flexor pollicis longus tendon. The normal radial digital nerve is entrapped by the scar and cannot be distinguished from it.* **(Right)** *Transverse US of the contralateral unaffected side in the same patient shows a normal radial digital nerve and digital artery for comparison. The flexor pollicis longus tendon and A1 pulley are also shown.*

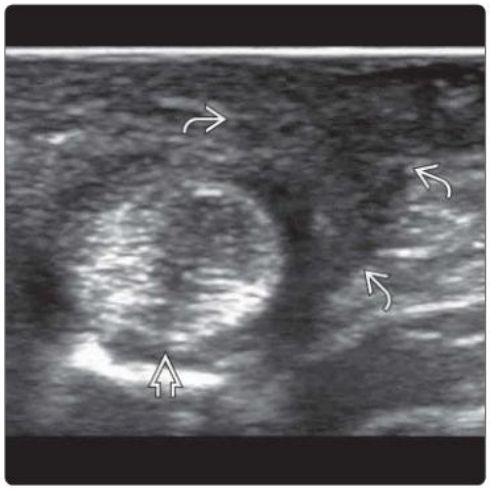

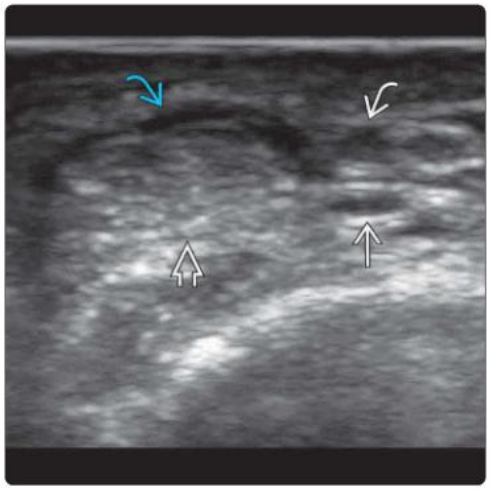

(Left) *Transverse US shows the normal radial nerve at the posterior aspect of the humeral shaft. There is an accompanying profunda brachii artery and vein.* **(Right)** *Transverse US in a patient with a healed malaligned humerus shaft fracture and radial nerve palsy shows a thickened radial nerve that has become partially entrapped in a fracture callus at the posterior aspect of the fracture site.*

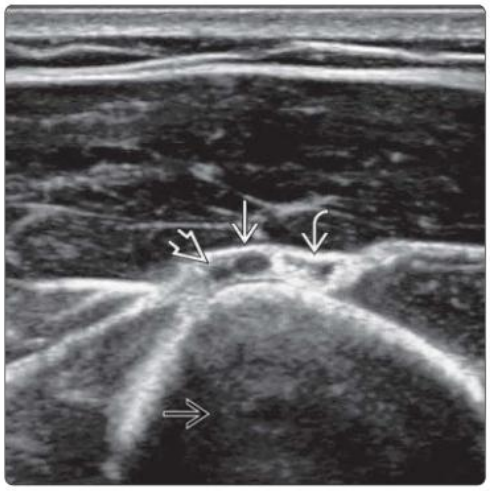

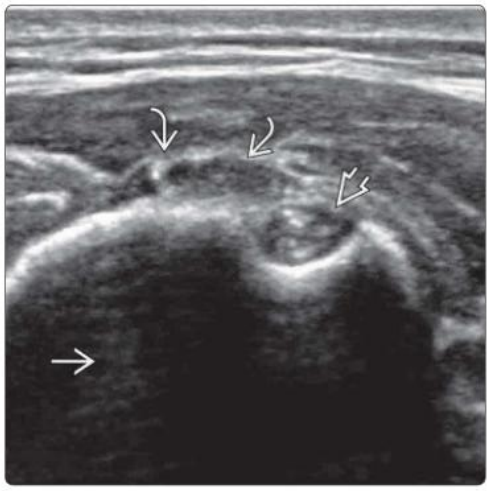

(Left) *Axial PD MR in the same patient shows the thickened radial nerve at the posterior aspect of the malaligned humeral shaft.* **(Right)** *Axial PD MR in the same patient shows the radial nerve partially entrapped in a healed fracture callus at the posterior aspect of the humeral shaft. As radial nerve palsy was gradually improving with conservative treatment, no surgical intervention was undertaken.*

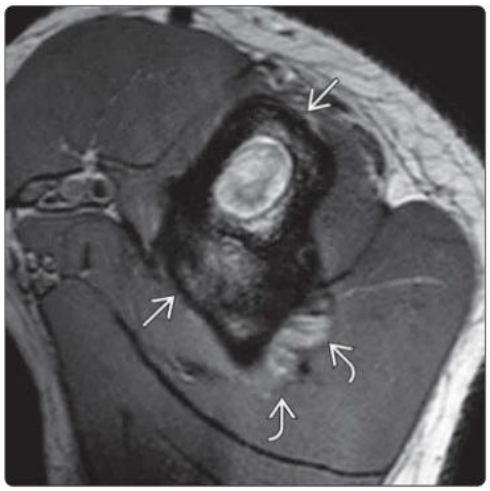

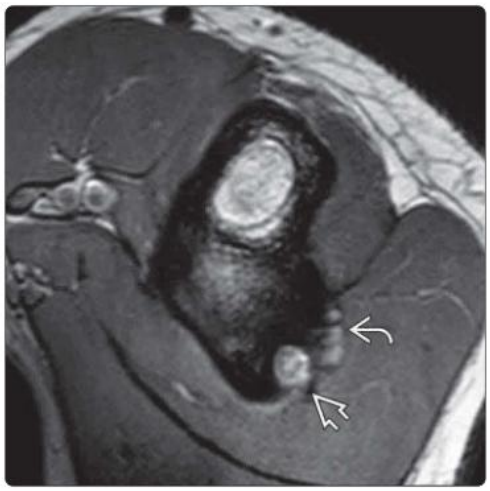

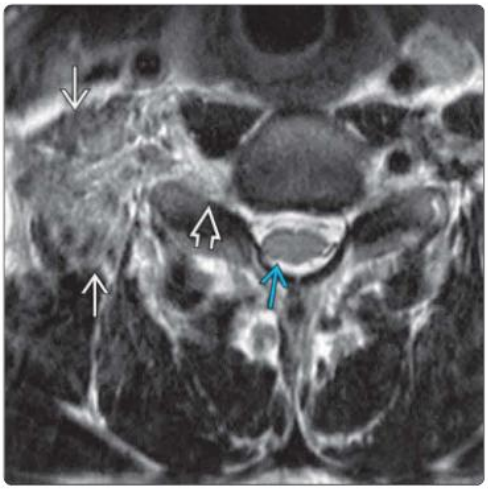

(Left) *Axial T2 MR shows a hematoma within ⇨ and just outside ⇨ of the right C6/C7 exit foramen in a patient with traction injury to the brachial plexus. This suggests an avulsive injury of the C7 root. The right side of the spinal cord ⇨ is slightly swollen.* **(Right)** *Sagittal T2 MR in the same patient shows a small hematoma ⇨ at the edge of the spinal cord at the site of origin of the right C7, suggestive of an avulsive nerve root injury. MR, rather than US, is recommended to assess preganglionic traction injury of the brachial plexus.*

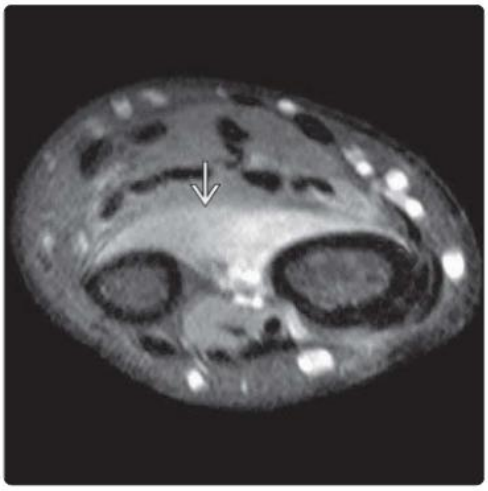

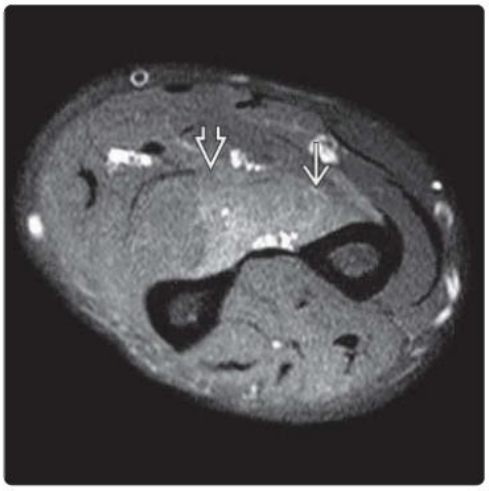

(Left) *Axial T2 FS MR in a patient with forearm pain and weakness of thumb pincer movement shows moderate edema of the pronator quadratus muscle ⇨.* **(Right)** *Axial T2 FS MR in the same patient shows mild edema of the flexor pollicis longus ⇨ and flexor digitorum profundus (index and middle) ⇨, consistent with subacute anterior interosseous syndrome (AIS). Mild muscle edema is not well appreciated on US. In chronic denervation, fatty muscle atrophy develops, which can be readily depicted on US.*

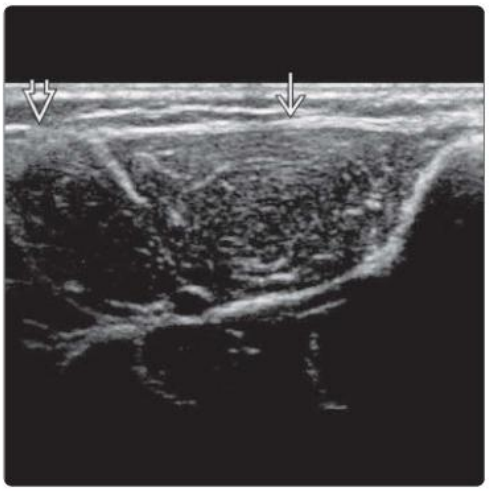

(Left) *Transverse US in a young patient with previous deep peroneal nerve injury shows severe fatty atrophy of the anterior compartment muscles (tibialis anterior ⇨ and extensor digitorum longus ⇨). The tibia ⇨ is normal.* **(Right)** *Transverse US of the contralateral limb in the same patient shows the normal tibialis anterior ⇨ and extensor digitorum longus ⇨ muscles for comparison.*

KEY FACTS

TERMINOLOGY

- Carpal tunnel syndrome (CTS)
  - Symptoms due to compression of median nerve in carpal tunnel
  - Most common entrapment neuropathy

IMAGING

- Majority (> 90%) of CTS is primary
- More swollen the median nerve, more likely is the possibility of CTS
- Measure nerve cross-sectional area (CSA) at distal forearm, immediately proximal to tunnel, at tunnel inlet, at tunnel outlet, & immediately distal to tunnel outlet
- 2 main measurement methods
  - **Largest CSA**
    - Median nerve CSA ≥ 14 mm² at any location is strong positive predictor of CTS (sensitivity/specificity/accuracy > 88%)
  - **Relative increase in nerve CSA**
    - Measure difference between CSAf (distal forearm) & largest carpal tunnel measurement (CSAc)
    - CSAc minus CSAf > 4 mm² is positive predictor of CTS
- Additional US signs of CTS have less discriminatory power if used in isolation, though can improve discrimination when used with CSA measurements
  - Neural hyperemia, especially at most swollen site, low sensitivity but high specificity for CTS
  - Perpendicular distance between undersurface of flexor retinaculum (FR) & transcarpal line: > 1 mm at outlet (specificity > 90%)
  - If median nerve CSA > 14 mm² or palmar bowing of FR at outlet > 1 mm, sensitivity, specificity & accuracy for CTS are 100%, 84%, & 93%, respectively
- **Following carpal tunnel release (CTR)**
  - Median nerve will remain unduly swollen (> 14 mm²) long-term following CTR despite good clinical response
  - FR will reform in 1/10 of patients by 3 months & 2/3 by 12 months

(Left) *Graphic shows the median nerve ⇨ deep to the flexor retinaculum ⇨ & superficial to the flexor tendons. The nerve usually divides just beyond the tunnel outlet.* **(Right)** *Axial graphic of the carpal tunnel shows the median nerve ⇨ lying immediately below the flexor retinaculum ⇨ & superficial to the flexor digitorum tendons, which are surrounded by the ulnar bursa ⇨ & the flexor pollicis longus, which is surrounded by the radial bursa ⇨. The extrinsic ligaments ⇨ lie above the carpal bones.*

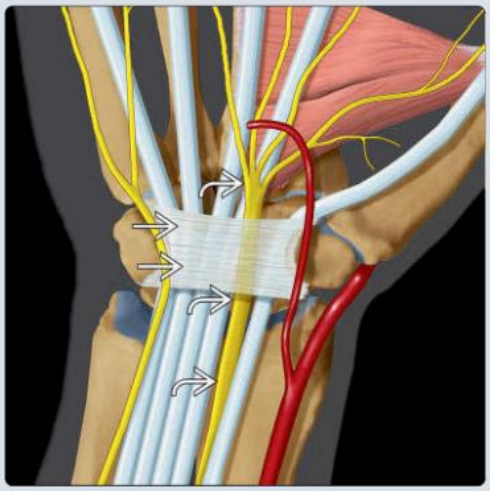

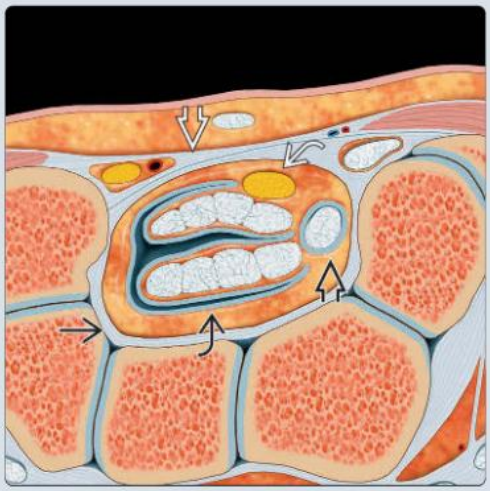

(Left) *Transverse US of the median nerve just proximal to the carpal tunnel inlet shows enlargement (15 mm²) ⇨. Cross-sectional area (CSA) > 14 mm² is a positive predictor for carpal tunnel syndrome (CTS). Note also the loss of neural fascicular structure, which is an additional sign of CTS.* **(Right)** *Transverse US in the same patient shows CSA measurement by continuous tracing around the nerve perimeter. As the nerve is occasionally irregular in outline, continuous tracing is more accurate than using ellipsoid calipers.*

TERMINOLOGY

Abbreviations

- Carpal tunnel syndrome (CTS)
- Flexor retinaculum (FR)
- Cross-sectional area (CSA)

Definitions

- Symptoms secondary to compression ± ischemia of median nerve in carpal tunnel area
  - Most common entrapment neuropathy

IMAGING

General Features

- Best diagnostic clue
  - Swollen median nerve immediately proximal or distal to carpal tunnel
  - Neural hyperemia (uncommon)
- Size
  - Normal nerve CSA varies from 7 mm² to ~ 12 mm²
    - Normal median nerve CSA measured on US is 15-20% smaller than on MR or anatomy
      - US measurements do not include epineurium
- Morphology
  - Hourglass-type appearance of nerve due to compression in carpal tunnel with swelling proximally & distally

Ultrasonographic Findings

- Increase in nerve caliber is, by far, most reliable US criterion of CTS
  - Swelling of median nerve either immediately proximal to, within, or immediately distal to carpal tunnel
    - Proximal: Proximal to FR
    - Inlet: Between scaphoid tubercle & pisiform
    - Outlet: Between trapezium tubercle & hook of hamate
    - Distal to carpal tunnel: Distal to FR
  - More swollen the median nerve, more likely is the possibility of CTS
  - Rigid diagnostic criteria not useful in clinical practice as median nerve compression is continuum rather than "all or none" phenomenon
  - Measure CSA by tracing around nerve perimeter (continuous tracing method)
    - Measure around hypoechoic neural fascicles
      - Echogenic epineurium is not well delineated from perineural fat on US
  - 2 main measurement methods based on median nerve CSA, either of which can be used
    - **Largest CSA of nerve**
      - Median nerve CSA measured at 4 points: Immediately proximal to tunnel inlet, at tunnel inlet, at tunnel outlet, & immediately distal to tunnel outlet
      - Optimal cutoff point: Median nerve CSA ≥ 14 mm²
      - Median nerve CSA ≥ 14 mm² at any location is strong positive predictor of CTS (sensitivity/specificity/accuracy > 88%)
      - Median nerve tends to be most swollen just proximal or distal to tunnel due to compression at tunnel inlet or outlet
    - **Relative increase in nerve CSA**
      - Median nerve CSA measured in forearm at proximal 1/3 of pronator quadratus muscle (CSAf) & immediately proximal to tunnel inlet, at tunnel inlet, & tunnel outlet (CSAc)
      - CSAc minus CSAf should not be > 4 mm²
      - Difference in CSA > 4 mm² is strong positive predictor of CTS
- Additional US signs of CTS
  - Increased neural vascularity on color Doppler imaging
    - Reactive hyperemia is marker of neural ischemia
    - High specificity but low sensitivity for CTS
  - Median nerve edema
    - Nerve becomes hypoechoic with loss of normal fascicular pattern
    - Prone to anisotropy & difficult to quantify
  - Altered median nerve movement on dynamic US testing
    - Decrease longitudinal movement or increase volar-dorsal movement between flexor tendons during wrist flexion
    - No objective criteria & difficult to judge
  - Increased retinacular bowing
    - Increased volar convexity of FR
    - Transcarpal line (between tip of scaphoid tubercle & pisiform; trapezium tubercle & hook of hamate)
    - Perpendicular distance between undersurface of FR & transcarpal line: > 1 mm at outlet (specificity > 90%)
  - Flattening ratio
    - Width:depth ratio > 3 of median nerve increases with CTS
- Can be used with CSA measurements in equivocal cases
  - If nerve CSA > 14 mm² or palmar volar bowing of flexor retinaculum at outlet > 1 mm, sensitivity, specificity, & accuracy for CTS are 100%, 84%, & 94%, respectively
- Secondary CTS mainly due to mass effect within carpal tunnel
  - Accessory muscle within carpal tunnel
  - Flexor digitorum tenosynovitis
  - Ganglion, lipoma, or gouty tophus
  - Nerve sheath tumor median nerve
  - Hamartomatous fibrolipoma of median nerve

Following Carpal Tunnel Release

- Median nerve will remain unduly swollen (> 14 mm²) following carpal tunnel release (CTR) despite good clinical response
  - Due to chronic compressive neuropathy resulting in irreversible endoneurial fibrosis of median nerve
  - Increased median nerve CSA is not reliable sign of persistent compression following CTR
- FR will reform in 1/10 of patients by 3 months & 2/3 by 12 months
  - FR is expected to reform though in elongated form leading to increased carpal tunnel volume
- Without preoperative comparative imaging, US has limited ability to diagnosis persistent median nerve compression
  - Postoperatively, US is mainly helpful to look for perineural fibrosis & neural tethering rather than persistent median nerve compression
    - Perineural fibrosis & tethering can be treated with US-guided hydrodissection

MR Findings

- Undue swelling of median nerve > 15 mm²
  - T2 hyperintensity with swollen fascicles
  - Palmar bowing of FR

Imaging Recommendations

- Best imaging tool
  - US as it is accurate, quick, comfortable, & relatively inexpensive
- Protocol advice
  - Wrist supported on flat surface with fingers relaxed
  - Measure nerve CSA at distal forearm, proximal to tunnel inlet, at tunnel inlet, at tunnel outlet, & distal to tunnel outlet
  - Keep transducer aligned at right angles to nerve rather than oblique
    - However, slight transducer angulation can utilize anisotropy to optimize delineation of nerve boundary
  - Measure median nerve CSA by continuous tracing rather than ellipsoid calipers
  - If median nerve bifid, measure CSA of both components & summate
  - Assess vascularity of median nerve, especially at most swollen area
  - If CSA measurements equivocal for CTS, measure volar bowing of FR at tunnel outlet

DIFFERENTIAL DIAGNOSIS

Tenosynovitis

- Tenosynovial effusion, proliferation & hyperemia predominates
  - ± secondary CTS

Inflammatory Synovitis

- Synovial swelling & hyperemia predominates
  - ± secondary CTS

Neural Tumor

- Nerve sheath tumor, fibrolipomatous hamartoma

PATHOLOGY

General Features

- Etiology
  - Due to chronic compression ± ischemia of median nerve in carpal tunnel
  - Majority primary rather than secondary
  - Increased risk in
    - Females, > middle age, higher body mass index
    - Repetitive physical work

Staging, Grading, & Classification

- Mild CTS: Intermittent paresthesia & pain; normal clinical examination; < 15% prolongation of sensory peak distal latency (SDL) & motor distal latency (MDL)
- Moderate CTS: Constant symptoms; decreased fine touch & pinprick but normal 2-point discrimination & no thenar weakness; 15-30% prolongation of SDL & MDL
- Severe CTS: Severe sensory loss with absent 2-point discrimination & thenar muscle weakness; > 30% prolongation of SDL & MDL

Gross Pathologic & Surgical Features

- Swollen median nerve

Microscopic Features

- Venous congestion, neural swelling, endoneurial fibrosis, Wallerian degeneration, axonal damage

CLINICAL ISSUES

Presentation

- Most common signs/symptoms
  - Nocturnal & morning paresthesia & pain over distribution of median nerve
    - Exacerbated by prolonged strenuous work
- Other signs/symptoms
  - ± thenar eminence wasting followed by atrophy (late finding) = "ape hand"
- Clinical profile
  - Nocturnal & morning exacerbation
    - Wrists tend to flex during sleep
    - Hands swell at nighttime
  - Positive Tinel & Phalen signs
  - Electrodiagnostic studies test functional integrity of nerve
    - Impaired median nerve sensory (SDL) & MDL
      - Compared with ipsilateral ulnar nerve

Demographics

- Age
  - Peak: 50 years ± 15 years
- Sex
  - M:F = 1:6
- Epidemiology
  - Cumulative lifetime prevalence rate: 10%
    - 0.5 million CTR performed annually in USA

Natural History & Prognosis

- Symptoms usually remain over months or years
  - Tendency to improve clinically & electrophysiologically over time even without specific treatment
    - CTS will continue to progress in minority of patients

Treatment

- Conservative
  - Neutral position wrist splint
  - US-guided steroid injection into carpal tunnel
    - Symptom improvement for up to 12 weeks
- Surgical
  - Flexor retinaculum release; open vs. endoscopic ± US guidance

DIAGNOSTIC CHECKLIST

Consider

- CTS in all patients with unexplained hand, wrist, or distal forearm paresthesia ± pain, even though symptoms atypical for CTS

SELECTED REFERENCES

1. Padua L et al: Carpal tunnel syndrome: updated evidence and new questions. Lancet Neurol. 22(3):255-67, 2023

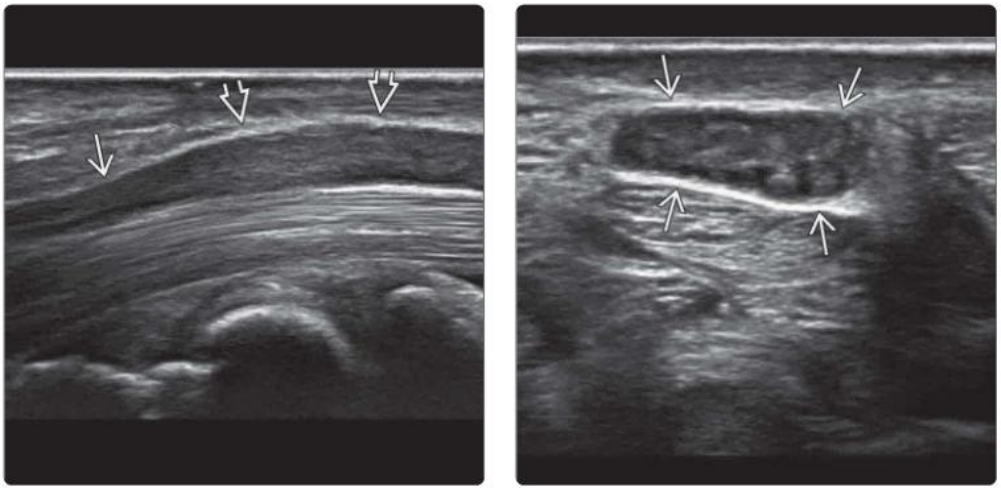

(Left) *Longitudinal US of the median nerve shows mild abrupt change in nerve caliber ⇨ at the carpal tunnel outlet, consistent with compression. Note swelling of the median nerve proximal to and within the carpal tunnel ⇨ with loss of the normal fascicular pattern.* **(Right)** *Transverse US of the median nerve in the same patient just proximal to the carpal tunnel inlet shows the swollen median nerve with loss of normal neural fascicular echo pattern ⇨.*

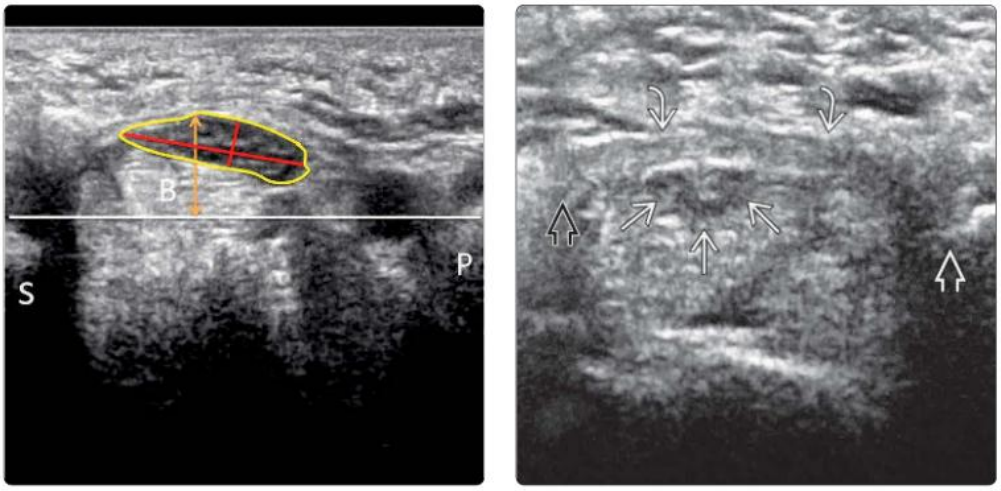

(Left) *Transverse US of the median nerve at the inlet shows features of CTS with severe palmar retinaculum bowing (B) relative to the transverse carpal line drawn between scaphoid tubercle (S) & pisiform (P), high flattening ratio (red lines), & increased CSA of the median nerve (outlined by yellow).* **(Right)** *Transverse US of the carpal tunnel outlet at the level of hamate ⇨ and trapezium ⇨ shows flattening of the median nerve ⇨ with moderate retinaculum thickening ⇨.*

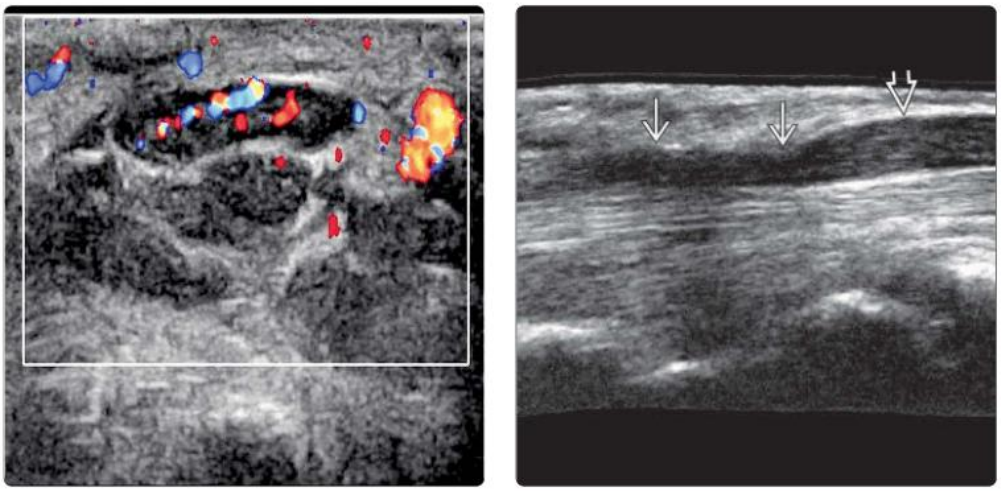

(Left) *Transverse color Doppler US shows moderate intraneural hyperemia proximal to the carpal tunnel in a patient with CTS. Intraneural vascularity should be assessed where the nerve is most swollen.* **(Right)** *Longitudinal US of the median nerve shows severe abrupt change in nerve caliber ⇨ at the inlet of the carpal tunnel, consistent with compression. Note swelling of the median nerve proximal to the carpal tunnel ⇨ with loss of the normal fascicular pattern.*

(Left) *Transverse US of the median nerve just proximal to the carpal tunnel inlet shows median nerve enlargement* ⇨ *with loss of neural fascicular pattern. This is associated with flexor tenosynovitis with tenosynovial hypertrophy* ⇨ *and tendon swelling* ⇨. **(Right)** *Longitudinal US in the same patient shows severe compression of the median nerve within the carpal tunnel due to flexor tenosynovitis. The nerve has an hourglass configuration, being swollen both proximal & distal to the compressed site* ⇨.

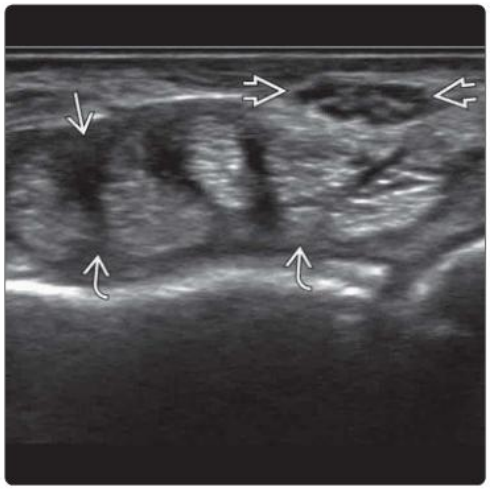

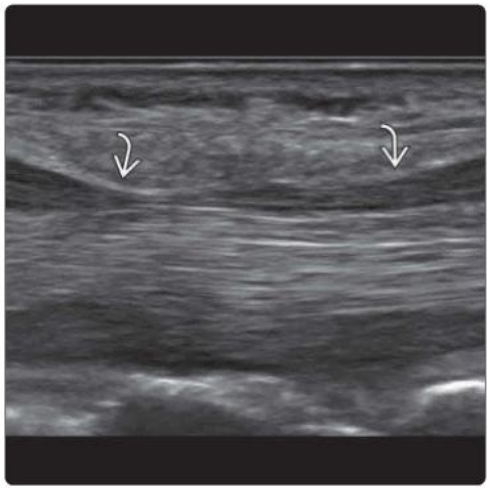

(Left) *Transverse US of the carpal tunnel outlet between hook of hamate* ⇨ *and pisiform* ⇨ *in the same patient shows severe flattening of the median nerve with flattening ratio of 4.1 (width/depth of median nerve).* **(Right)** *US shear and strain wave elastography shows promise for diagnosis and staging of CTS though universal threshold criteria have yet to be established. Increase in CTS severity is associated with increased median nerve stiffness.*

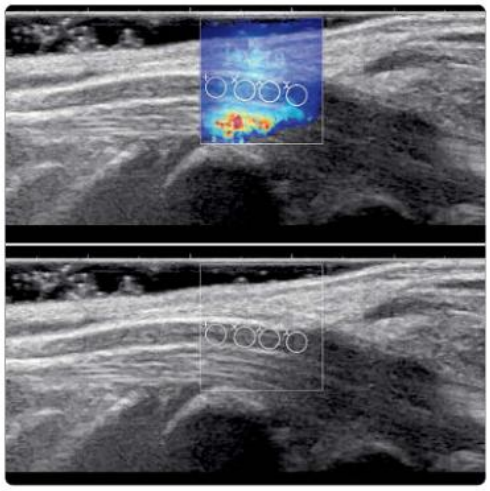

(Left) *Transverse US shows median nerve enlargement (17 mm²)* ⇨ *just proximal to the carpal tunnel inlet. Note reduction in neural fascicular structure. The antebrachial fascia overlies the nerve* ⇨. *The palmaris longus tendon is superficial* ⇨. **(Right)** *Axial PD MR in the same patient shows the same severely swollen median nerve* ⇨ *just proximal to the tunnel inlet. The nerve fascicles are swollen. The antebrachial fascia* ⇨ *is noted. The palmaris longus tendon is superficial* ⇨.

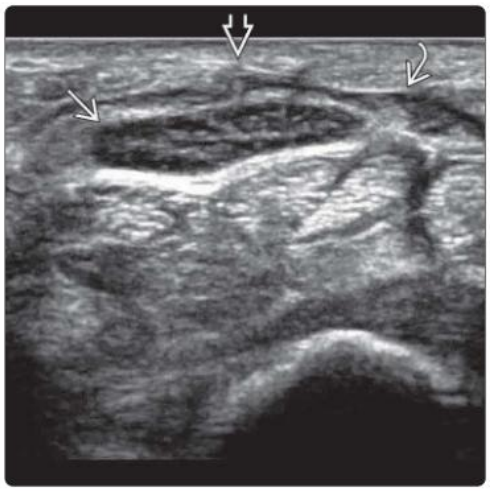

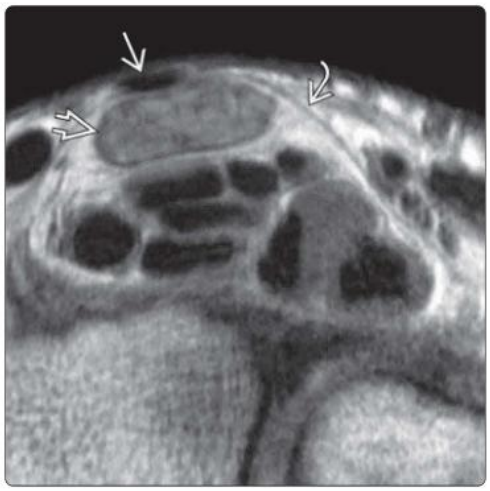

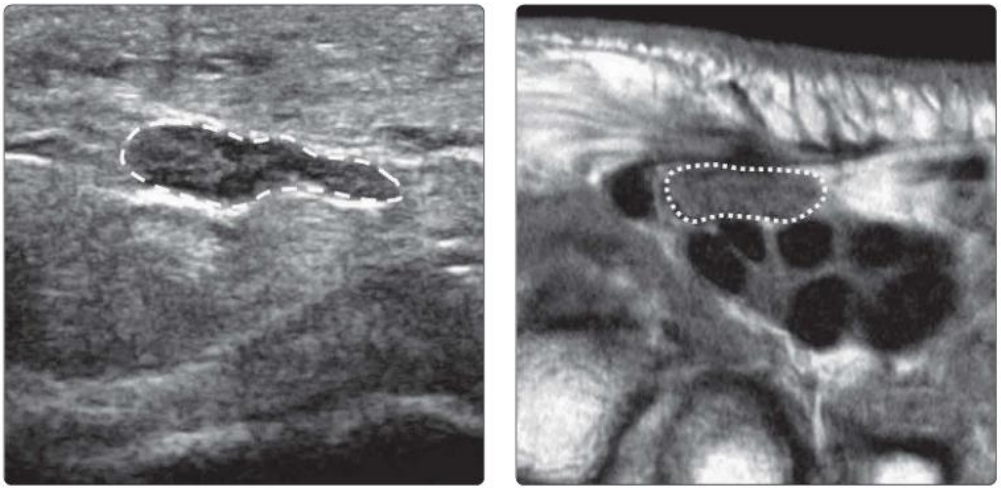

(Left) *Transverse US in the same patient shows severe median nerve swelling just distal to the tunnel outlet (broken line). The median nerve has a hypoechoic echo pattern with loss of the normal fascicular pattern. Continuous tracing is best for measurement of median nerve CSA.* **(Right)** *Axial PD MR in the same patient shows the severely swollen median nerve (dotted line) just distal to the tunnel outlet.*

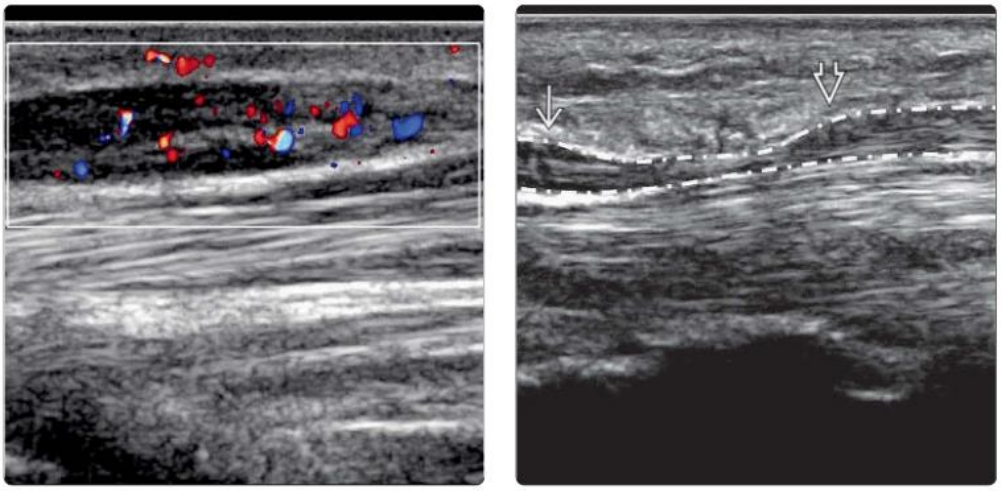

(Left) *Longitudinal color Doppler US in the same patient shows severe neural hyperemia proximal to the carpal tunnel. This is reactive hyperemia secondary to compression and ischemia more distally.* **(Right)** *Longitudinal US in the same patient shows severe compression of the median nerve (broken lines) within the carpal tunnel. The nerve has an hourglass configuration, being swollen both proximal ⇨ & distal ⇨ to the compression site.*

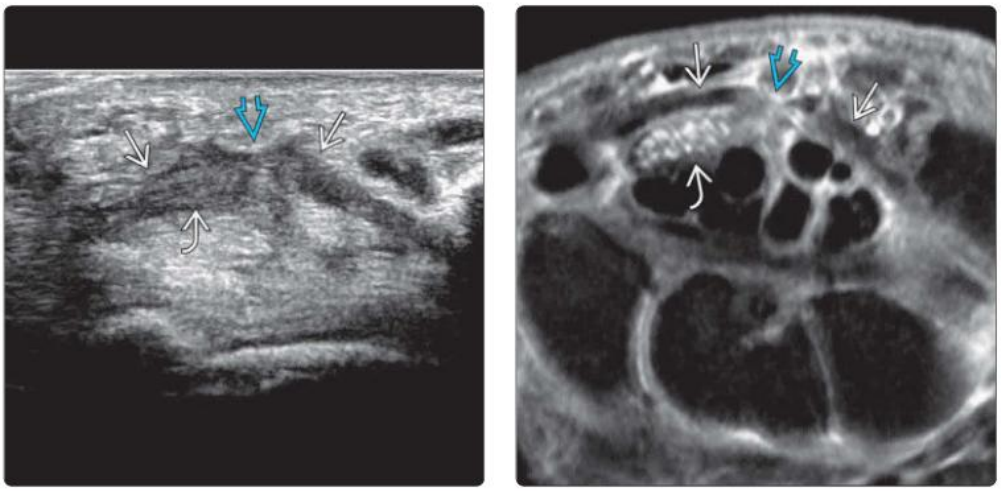

(Left) *Transverse US of the tunnel inlet 3 months following carpal tunnel release is shown. The retracted ends of the transected flexor retinaculum (FR) ⇨ are seen with a central defect ⇨. The median nerve ⇨ lies just deep to the defect and is inseparable from the FR.* **(Right)** *Axial PD MR of the tunnel inlet in the same patient shows the retracted ends of the transected FR ⇨ & the intervening central defect ⇨. The median nerve ⇨ lies just under the FR.*

(Left) *Transverse US in a patient with CTS shows echogenic gouty tophi ⇄ with posterior acoustic shadow within the carpal tunnel causing compression of the median nerve ⇒. The flexor tendons cannot be clearly identified due to gouty crystal deposition.* **(Right)** *Longitudinal US in the same patient shows the median nerve ⇒ being compressed within the carpal tunnel. The echogenic gouty tophi ⇄ with posterior acoustic shadow are located deep to the median nerve.*

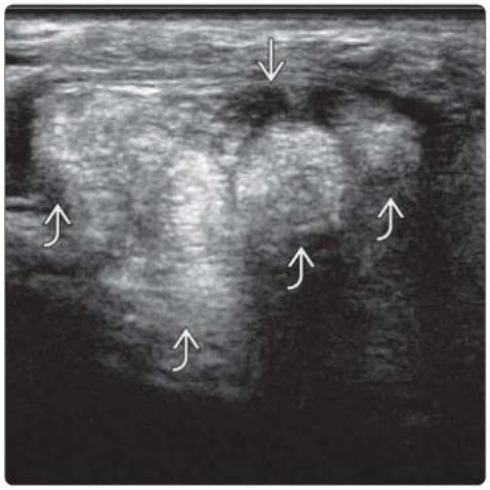

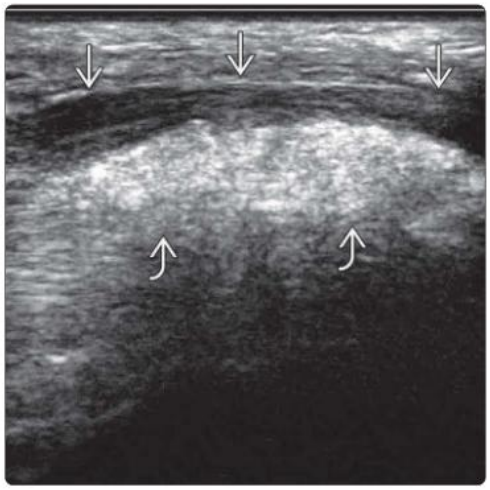

(Left) *Transverse US of the carpal tunnel inlet shows ulnar ⇒ & radial ⇄ components of the bifid median nerve with a persistent median artery ⇒ coursing between these two components. In this situation, the CSA of both components should be measured separately and summated.* **(Right)** *Transverse power Doppler US of the carpal tunnel inlet in the same patient shows normal flow in the persistent median artery. Thrombosis of a persistent median artery is one secondary cause of CTS.*

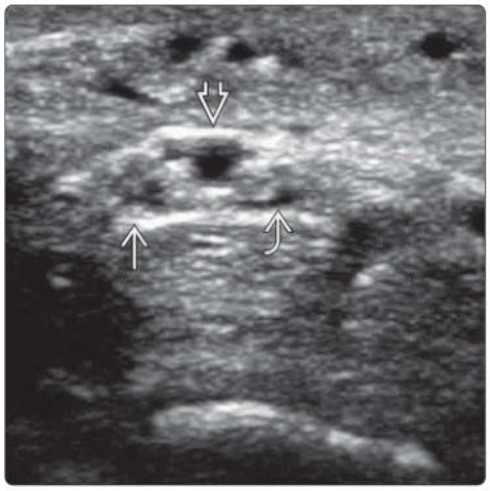

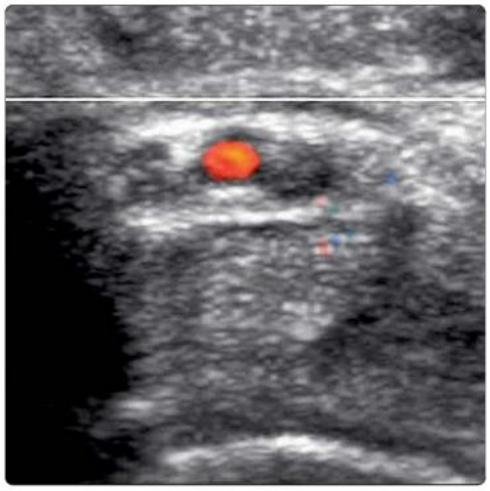

(Left) *Longitudinal US of the wrist shows an echogenic mass ⇒, consistent with lipoma of the median nerve.* **(Right)** *Transverse PD MR at the outlet of the carpal tunnel in the same patient confirms a lipoma ⇄ within the ulnar aspect of the median nerve ⇒.*

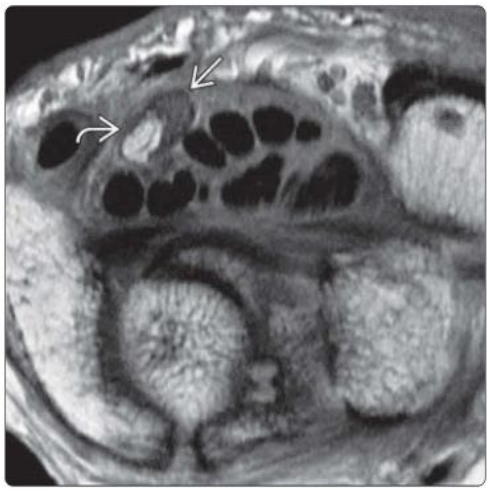

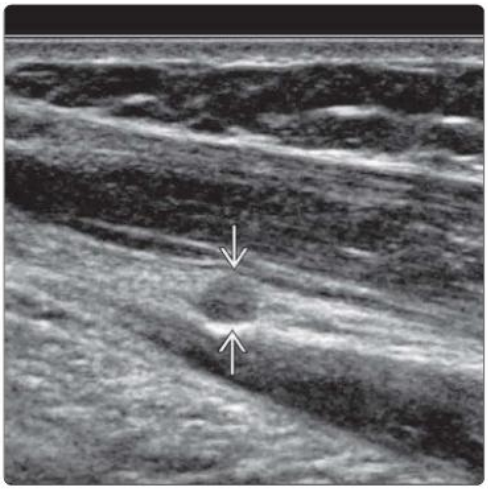

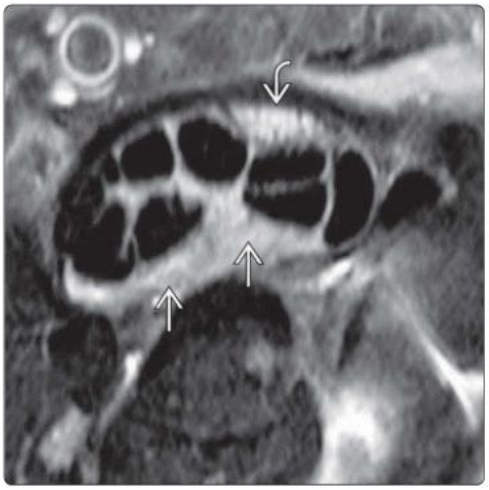

(Left) *Longitudinal US of the median nerve at the distal forearm shows a well-defined hypoechoic, round intraneural lesion ➡, consistent with a small nerve sheath tumor. MR (not shown) revealed an enhancing intraneural lesion, compatible with a nerve sheath tumor.* **(Right)** *Transverse PD FS MR in a patient with CTS symptoms shows median nerve flattening ➡ at the tunnel outlet with synovial proliferation of the flexor synovial sheath ➡, consistent with flexor tenosynovitis.*

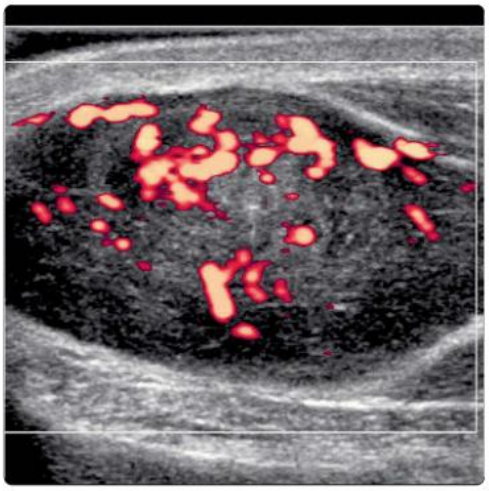

(Left) *Longitudinal US in a patient with CTS symptoms shows a large, heterogeneous, oval-shaped tumor ➡ continuous with the median nerve just proximal to the carpal tunnel. The nerve immediately adjacent to the tumor is mildly thickened ➡. Features are compatible with a large median nerve sheath tumor.* **(Right)** *Longitudinal power Doppler US shows moderate tumoral hyperemia with an irregular vascular pattern, consistent with a nerve sheath tumor.*

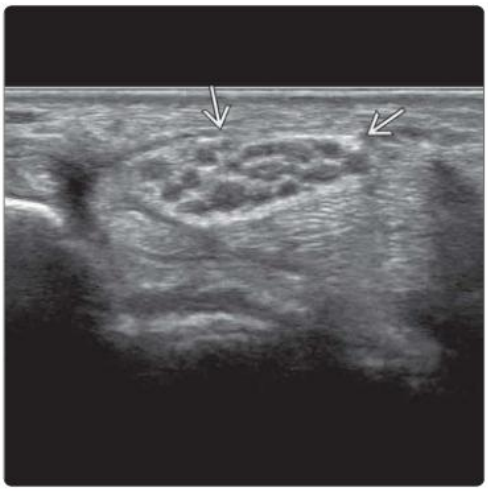

(Left) *Transverse US in a patient with CTS symptoms shows a very enlarged (74 mm²) median nerve ➡ immediately proximal to the tunnel inlet with thickened hypoechoic neural fascicles. These appearances are consistent with hamartomatous fibrolipoma of the median nerve.* **(Right)** *Frontal radiograph of another patient with hamartomatous fibrolipoma of the median nerve shows middle finger macrodactyly, a known association of median nerve fibrolipoma & a more common clinical presentation than CTS.*

KEY FACTS

TERMINOLOGY

- Cubital tunnel syndrome (CUTS)
  - Due to compression of ulnar nerve at cubital tunnel
- Symptoms can also be due to ulnar nerve traction & friction secondary to instability

IMAGING

- Best diagnostic clue: Swollen ulnar nerve within cubital tunnel
- 3 elements of CUTS should be evaluated
  - Mass within cubital tunnel
    - Ganglia, synovitis, osteophytosis, muscle, or tumor
  - Compression of ulnar nerve with swelling
    - Ulnar nerve cross-sectional area (CSA) measured proximal to tunnel & within tunnel
    - The more swollen the ulnar nerve, the greater the likelihood of CUTS
    - If ulnar nerve CSA at cubital tunnel ≥ 10 mm², 85% sensitivity & 91% specificity for CUTS
    - Alternatively, consider CUTS if ulnar nerve CSA in tunnel > 1.5x than at middistal arm level
  - Ulnar nerve instability
    - As elbow flexes, cubital tunnel roof moves distally enabling ulnar nerve to sublux
    - Subluxation or dislocation: Present in 25% of CUTS patients; 20% of normal subjects

PATHOLOGY

- Most CUTS secondary due to osteophytes, synovitis, ganglion, muscle encroaching onto cubital tunnel
- 40% of patients with CUTS will have same positive findings on asymptomatic contralateral side

DIAGNOSTIC CHECKLIST

- First, look for encroachment onto cubital tunnel
- More swollen ulnar nerve = more likely possibility of CUTS
- In CUTS due to ulnar nerve instability, cubital tunnel encroachment & neural swelling may be less pronounced

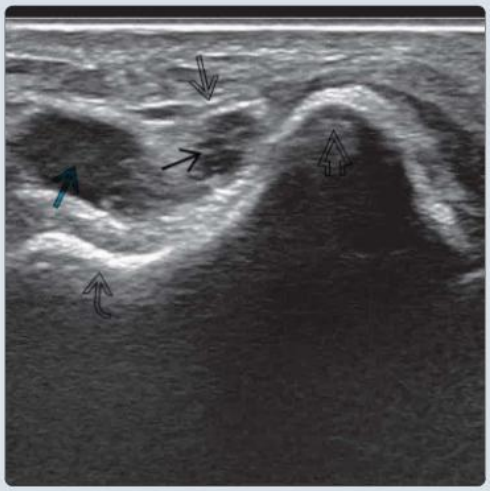

(Left) *Transverse US shows a normal-caliber (8-mm²) ulnar nerve ⇨ with preserved fascicular appearance in the cubital tunnel, covered by Osborne ligament ⇨. Note medial epicondyle ⇨, olecranon ⇨, and triceps medial head ⇨.* **(Right)** *Transverse US shows a mildly enlarged (12-mm²) ulnar nerve ⇨ within the cubital tunnel with loss of fascicular pattern. An ulnar nerve cross-sectional area of ≥ 10 mm² indicates the possibility of cubital tunnel syndrome. Medial epicondyle ⇨ is shown.*

(Left) *Transverse US in the extended elbow position shows moderate enlargement (16 mm²) of the ulnar nerve ⇨ within the cubital tunnel with loss of fascicular appearance. These features are compatible with cubital tunnel syndrome. Medial epicondyle ⇨ is shown.* **(Right)** *Transverse US shows a severely enlarged (22-mm²) ulnar nerve ⇨ within the cubital tunnel alongside the medial epicondyle ⇨. The large anconeus epitrochlearis muscle ⇨ is likely to be contributing to ulnar nerve compression.*

TERMINOLOGY

Abbreviations

- Cubital tunnel syndrome (CUTS)

Definitions

- Symptoms secondary to compression or irritation of ulnar nerve at cubital tunnel
  - 2nd most common peripheral entrapment neuropathy after carpal tunnel syndrome

IMAGING

General Features

- Best diagnostic clue
  - Swollen ulnar nerve within cubital tunnel
- Location
  - Between medial epicondyle of humerus & olecranon
- Size
  - Normal mean nerve cross-sectional area (CSA) is 9 mm²; most studies use 10 mm² as cutoff for abnormal
    - As wide variation in ulnar nerve size, can only be confident about CUTS when CSA > 15 mm²
- Morphology
  - Fusiform appearance on longitudinal scanning due to localized swelling

Radiographic Findings

- Radiography
  - Osteophytic encroachment in hypertrophic-type osteoarthritis
  - Posttraumatic deformity, chronic inflammatory arthropathy, gouty tophi

MR Findings

- T1WI/ T2WI ± FS: Ulnar nerve swelling (> 15 mm²) with moderate T2 hyperintensity over longitudinal length > 10 mm

Ultrasonographic Findings

- Unlike carpal tunnel syndrome, 2 elements to CUTS
  - Compressive neuropathy: Cubital tunnel encroachment & ulnar nerve swelling dominate
  - Noncompressive neuropathy (i.e., ulnar nerve instability): Recurrent subluxation/dislocation results in friction neuritis; cubital tunnel encroachment & neural swelling not as pronounced
  - Both compressive & noncompressive elements commonly coexist
- Space-occupying lesion in cubital tunnel
  - Ganglia, osteophytes, hyperostosis, synovitis, muscle, gouty tophi, or tumor
  - Anconeus epitrochlearis muscle present in 25% of CUTS patients; 15% of normal subjects
    - Extends from medial epicondyle to medial border of olecranon replacing Osborne ligament
      - When present, contributes to roof of cubital tunnel
    - Osborne ligament considered fibrous vestigial remnant of anconeus epitrochlearis
  - Large medial head triceps (> 50% ulnar groove) present in 15% of CUTS patients, 10% of normal subjects
    - Attached to ulnar side of olecranon process
- Enlarged ulnar nerve in cubital tunnel
  - The more swollen the ulnar nerve, the greater the likelihood of CUTS
  - Mean ulnar nerve CSA in healthy subjects is 9.0 mm² at cubital tunnel
  - For cutoff of 10-mm² ulnar nerve CSA at cubital tunnel, up to 85% sensitivity & 91% specificity for CUTS
    - As wide variation in ulnar nerve size, can only be confident about CUTS when CSA > 15 mm²
  - Swelling ratio criterion
    - Probably less accurate than maximum CSA
      - Compare CSA of nerve within cubital tunnel with that in middistal arm; ratio of > 1.5x suggests CUTS
- Neural compression is continual process
  - Overlap between normal & abnormal values in 10-15 mm² range
  - Nerve caliber also increases with increasing body size so consider this when interpreting ulnar nerve CSA
  - Temper report to reflect degree of ulnar nerve swelling & likelihood of CUTS
    - If ulnar nerve CSA
      - 10-13 mm², report that "ulnar nerve seems slightly swollen, indicating mild possibility of CUTS"
      - 13-15 mm², report that "ulnar nerve seems moderately swollen, indicating moderate probability of CUTS"
      - > 15 mm², report that "ulnar nerve is swollen, compatible with CUTS"
- Instability of ulnar nerve during elbow flexion
  - As elbow flexes, olecranon & roof of cubital tunnel move distally, enabling ulnar nerve to subluxate
  - Subluxation (perched on apex of medial epicondyle): Present in 25% of CUTS patients; 10% of normal subjects
  - Dislocation (anterior to medial epicondyle): Present in 25% of CUTS patients; 10% of normal subjects
- Shear wave elastography may be helpful in diagnosis
  - Ulnar nerve stiffness > 61 kPa is highly specific for CUTS

Imaging Recommendations

- Best imaging tool
  - US: Efficient, accurate, & dynamic
- Protocol advice
  - Usually begin evaluating cubital tunnel with elbow extended ± at 90° flexion
  - Trace full length of nerve in transverse plane, from proximal arm to Guyon canal
  - Check contents of cubital tunnel: Osteophytes, synovitis, ganglion, anconeus epitrochlearis, or medial triceps muscle encroachment onto ulnar nerve
  - Measure nerve caliber just proximal to & within tunnel
  - Check specifically for possible ulnar nerve compression around elbow
    - Proximally: Arcade of Struthers, medial intermuscular septum
    - Distally: Deep to flexor pronator aponeurosis (humeroulnar arcade) & between ulnar & humeral heads of flexor carpi ulnaris (FCU)
  - Check for ulnar nerve instability with dynamic assessment from full extension to full flexion
  - General tips
    - Use minimal transducer pressure to avoid compressing nerve

- Keep transducer aligned at true transverse plane & not oblique to nerve
- Measure immediately after freezing image
- Measure nerve CSA by tracing rather than with ellipsoid calipers
- Slight angulation of transducer can utilize anisotropy to improve nerve delineation
- When testing for ulnar nerve instability, take cine clip from midflexion to full flexion, keeping cubital tunnel in view
- 40% of patients with CUTS will have similar, albeit often less severe, positive findings on asymptomatic contralateral side

DIFFERENTIAL DIAGNOSIS

Common Flexor Tendon Origin Tendinosis With Peritendinitis ± Tear

- May irritate ulnar nerve in cubital tunnel

PATHOLOGY

General Features

- Majority due to compression of ulnar nerve within cubital tunnel
  - Muscle anomaly in younger patients, osteophytes in older patients
  - Minority due to friction neuritis of ulnar nerve from recurrent subluxation or dislocation
- Anatomy of cubital tunnel
  - Roof
    - Proximally: Osborne ligament, which is fascial band between medial epicondyle & olecranon, probably vestigial remnant of anconeus epitrochlearis
    - Distally: Arcuate ligament, which bridges humeral & ulnar heads of FCU
  - Floor: Elbow joint capsule & olecranon
- Etiology
  - Majority have specific structural cause
  - Increased likelihood of CUTS with
    - Cubital tunnel encroachment by osteophytes, ganglion, synovial proliferation
    - Recurrent ulnar nerve instability
    - Large medial triceps muscle (i.e., muscle occupying > 50% ulnar groove)
    - Presence of accessory anconeus epitrochlearis muscle
    - Snapping triceps syndrome
    - Valgus or varus deformity of elbow
- Epidemiology
  - Prevalence ~ 1% of general population

Gross Pathologic & Surgical Features

- Compressed nerve in cubital tunnel

Microscopic Features

- Nerve compression or ischemia leads to fluid leakage & edema with increase in endoneurial pressure
  - Leads to demyelination, inflammation, diminished axoplasmic flow, distal axonal degeneration, fibrosis, growth of new axons, remyelination, & thickening of perineurium & epineurium

CLINICAL ISSUES

Presentation

- Most common signs/symptoms
  - Paraesthesia & numbness of ulnar 1 & 1/2 digits, but frequently difficult to localize
- Other signs/symptoms
  - Pain in medial elbow region
  - Reduced hand grip due to intrinsic muscle (lumbrical & interosseous) weakness & atrophy
  - Ulnar claw hand: Hyperextension at metacarpophalangeal joint & flexion at proximal interphalangeal joint & distal interphalangeal joint of ring & little fingers
- Clinical profile
  - US findings supported by combination of history, physical examination, specific provocative tests, & electrophysiologic tests
  - Provocative tests
    - Positive Tinel test, elbow flexion test
  - Electrodiagnostic studies test functional neural integrity
    - Ulnar nerve motor conduction velocity across elbow is positive if < 50 m/s
    - May aid localization of neural compression
    - Can identify other disease processes, such as upper motor neuron disease or peripheral neuropathy

Demographics

- Age
  - Peak: 45 ± 12 years
- Sex
  - M:F = 1:3

Treatment

- Conservative
  - Antiinflammatory or vitamin B medication, elbow pad activity modification, splints to limit motion, nocturnal splinting, physical therapy
  - US-guided perineural injections
    - No proven benefit of perineural steroid injection or hydrodissection
- Surgical: In situ decompression, neural transposition, medial epicondylectomy

DIAGNOSTIC CHECKLIST

Consider

- CUTS in all patients with unexplained hand, wrist, or distal forearm paresthesia ± pain on ulnar side

Image Interpretation Pearls

- The more swollen the ulnar nerve, the more likely the possibility of CUTS

SELECTED REFERENCES

1. Hussein M et al: Cubital tunnel syndrome: anatomy, pathology, and imaging. Skeletal Radiol. ePub, 2024
2. Schwabl C et al: Nerve entrapment syndromes: detection by ultrasound. Ultrasonography. 42(3):376-87, 2023

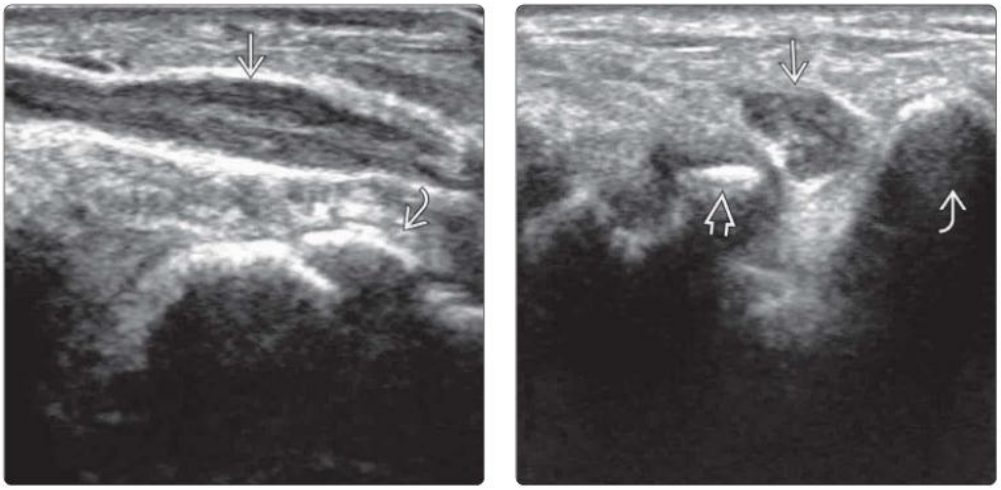

(Left) *Longitudinal US shows a focally enlarged ulnar nerve within and just proximal to the cubital tunnel. Note the medial epicondyle. This exaggerated fusiform swelling of the ulnar nerve is seen in cubital tunnel syndrome.* **(Right)** *Transverse US shows moderate enlargement (18 mm²) of the ulnar nerve alongside the medial epicondyle. There are large elbow osteophytes indenting the base of the cubital tunnel, displacing the ulnar nerve, and contributing to cubital tunnel syndrome.*

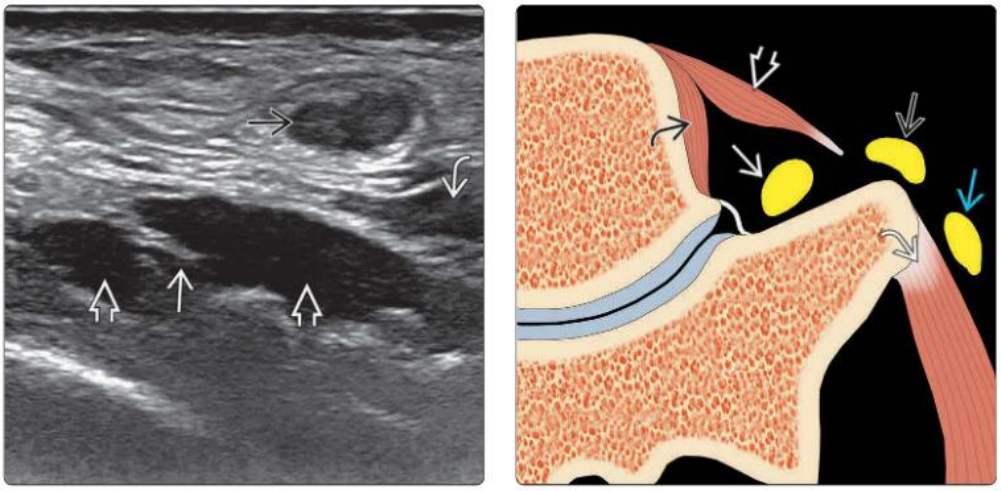

(Left) *Transverse US in a patient following ulnar nerve anterior transposition is shown. Normally, the nerve lies between the 2 heads of the flexor carpi ulnaris (FCU). Here, the transposed nerve instead lies anterior and superficial to the FCU and flexor digitorum superficialis.* **(Right)** *Graphic shows a normal, subluxed, and dislocated ulnar nerve position. Note the medial head of triceps muscle, anconeus epitrochlearis muscle (accessory muscle), and common flexor tendon origin.*

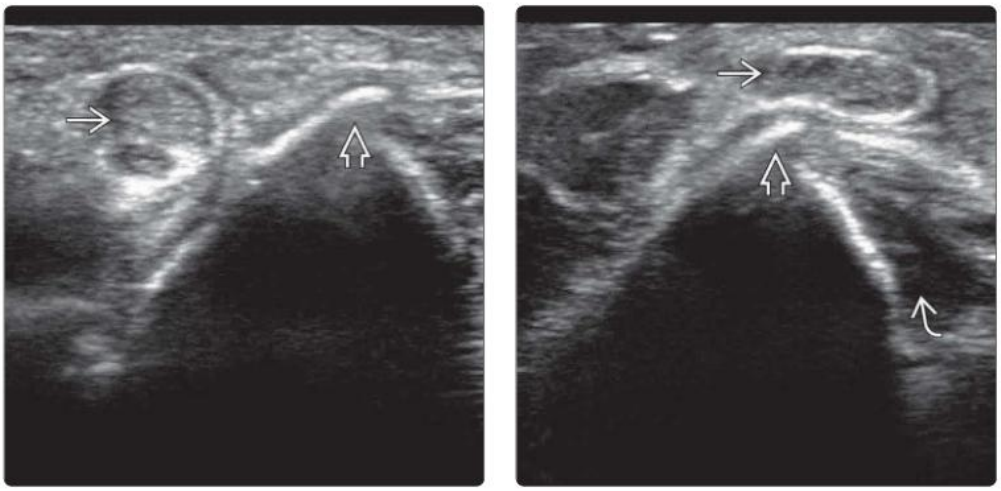

(Left) *Transverse US shows a severely enlarged (24-mm²) ulnar nerve within the cubital tunnel. The nerve remains posterior to the medial epicondyle during partial elbow flexion.* **(Right)** *Transverse US in the same patient at full elbow flexion shows subluxation of the ulnar nerve, which is now flattened and perched on the medial epicondyle. Note common flexor tendon origin. Recurrent subluxation or dislocation can lead to friction neuritis of ulnar nerve and cubital tunnel symptoms.*

KEY FACTS

IMAGING

- Examine contralateral asymptomatic side first
  - Good side-to-side concordance normally in appearance of brachial plexus
    - Though considerable intrapopulation variation
  - Smooth & diffuse thickening suggests nontumoral etiology, such as irradiation plexopathy or inflammatory neuropathy
  - Focal swelling indicates primary tumor, malignancy, or nodular fibrosis
- **Postradiation plexopathy**: Diffuse enlargement ± hypoechoic fibrotic atrophied perineural fat
- **Traumatic plexopathy**: Swelling of injured nerves
- **Benign neurogenic tumor**: Discrete, well-defined, ovoid hypoechoic mass inseparable from brachial plexus
- **Metastatic infiltration**: Focal, often irregular mass infiltrating neural components without tethering
- **Neuralgic amyotrophy**: Focal enlargement of individual nerves
- **Inflammatory plexopathy**: Diffuse enlargement of affected nerves bilaterally with normal surrounding fat
- **Thoracic outlet syndrome**: Examine from interscalene to infraclavicular region before & after provocative movement

DIAGNOSTIC CHECKLIST

- 2/3 of brachial plexus examinations are normal on both US & MR
- US is almost as accurate as MR for identifying & characterizing brachial plexopathy
- If US normal, likelihood of finding abnormality on MR is very low
  - Main additional benefits of MR
    - Shows foraminal stenosis or intraspinal pathology that may account for symptoms
    - Shows parascapular muscle denervation as indirect sign of brachial plexus pathology

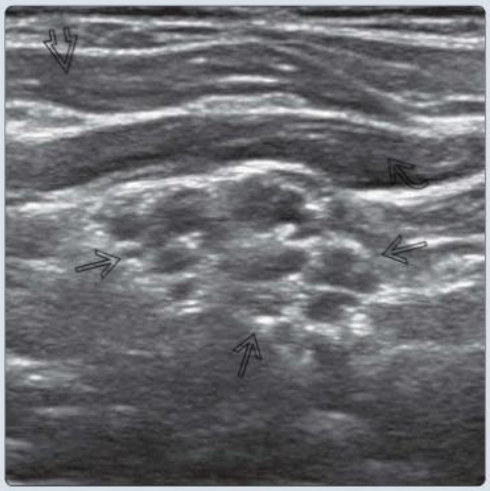

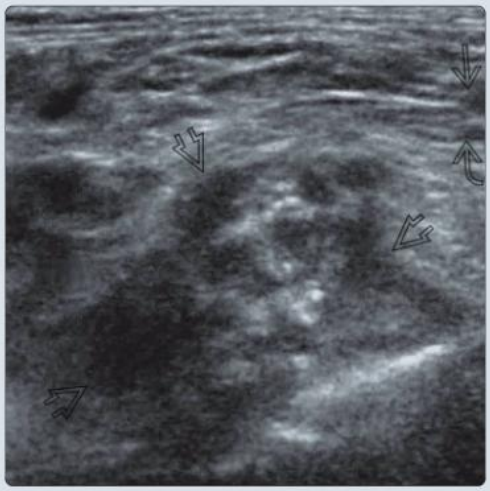

(Left) *Transverse US of the contralateral side in a 56-year-old woman with prior radiotherapy and arm pain shows normal divisions ⇨ (bunch of grapes appearance). Overlying omohyoid ⇨ and trapezius ⇨ muscles are also normal.* **(Right)** *Transverse US on the symptomatic side shows thickened divisions with tethering and hypoechoic ("dirty") intervening perineural fat ⇨ due to fibrosis compatible with moderate radiation plexopathy. The overlying omohyoid ⇨ and trapezius ⇨ muscles are moderately atrophic.*

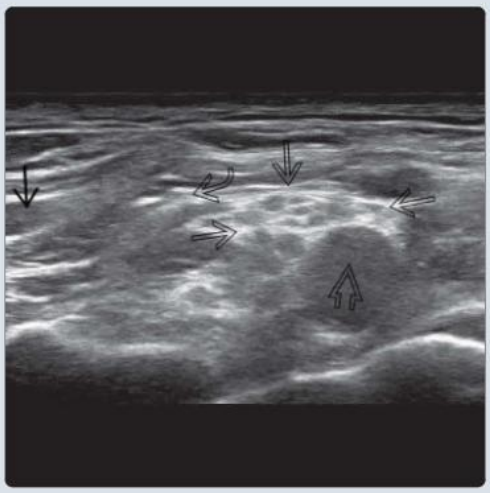

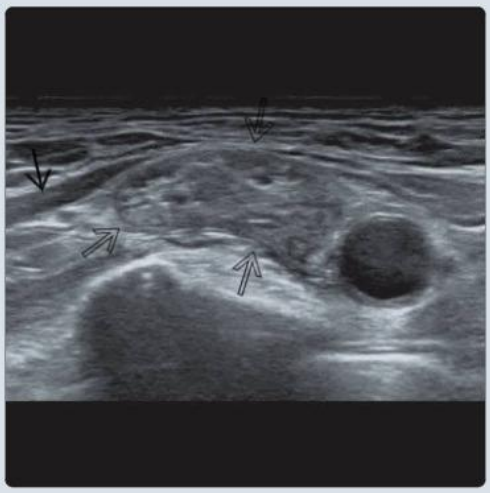

(Left) *Transverse US of the contralateral supraclavicular region in a 68-year-old man with diffuse large B-cell lymphoma and arm pain shows normal divisions ⇨ alongside subclavian artery ⇨. Suprascapular nerve ⇨ deep to omohyoid muscle ⇨ is normal.* **(Right)** *Transverse US of the same area on the symptomatic side shows focal, mass-like soft tissue thickening encasing the divisions ⇨ consistent with lymphoma infiltration. The suprascapular nerve deep to the omohyoid muscle ⇨ is not affected.*

TERMINOLOGY

Definitions

- Brachial plexus extends from ventral rami of C5-T1 roots to terminal branches in axilla
  - Brachial plexus comprises roots, trunks, divisions, cords, & terminal branches distal to dorsal root ganglion
  - Dorsal root ganglion & preganglionic rootlets are not part of brachial plexus
- **Postradiation plexopathy**: Comprises both early transient radiation-induced plexopathy & later sequelae of radiation-induced fibrosis, due to irradiation therapy for lower neck & upper thoracic malignancy
- **Traumatic plexopathy**: Injury to the brachial plexus from traction, penetrating or direct blunt trauma
  - Posttraumatic neuroma: Focal discontinuity proliferation of neural components due to haphazard neural regeneration & connective tissue repair; 2 types
    - Neuroma-in-continuity (NIC) continuous with partially transected nerve
    - End-bulb neuroma at proximal stump of completely transected nerve
- **Benign neurogenic tumor**: Benign peripheral nerve sheath tumor, e.g., schwannoma, neurofibroma
- **Malignant infiltration**: Breast, lung, & less commonly, head & neck cancer metastasis, lymphoma, or direct infiltration from regional primary tumor
- **Inflammatory plexopathy**: Nontraumatic demyelinating neuropathy due to neural inflammation
- **Neuralgic amyotrophy**: Focal neural inflammatory condition with immunological, mechanical ± genetic predisposition
- **Thoracic outlet syndrome**: Neural or vascular compression typically from fibrous bands or bony compression

IMAGING

General Features

- Best diagnostic clue
  - Contralateral asymptomatic or less symptomatic side should always be examined first to allow appreciation of normal anatomy for patient
    - Little side-to side variation in neural size & perineural fat normally exists though considerable variation exists across population
  - Look for
    - Enlargement of roots/trunks/divisions/cords/terminal branches of brachial plexus
    - Altered echogenicity of or reduction in perineural fat
    - Tethering of neural components
    - Focal discontinuity ± neuroma
- Location
  - Lower cervical region
    - Medial to scalene muscles: Roots
    - Interscalene triangle: Trunks
    - Lateral to scalene muscle & above clavicle: Divisions
  - Subcoracoid recess: Cords
  - Axilla: Terminal branches
- Size
  - Should not be > 20% larger than normal side
  - Normal cross-sectional areas of trunks: Upper 16.7 ± 2.8 mm^2, middle 14.0 ± 2.7 mm^2, lower 13.8 ± 2.6 mm^2
  - Measurements are a guide only & not widely used
- Morphology
  - Smooth, diffuse swelling indicates nontumoral etiology
  - Focal nodular swelling indicates tumoral etiology

Radiographic Findings

- May show apical lung mass, bony infiltration, posttraumatic deformity or cervical rib

CT Findings

- CT myelography may demonstrate pseudomeningocele due to traumatic dural tear
  - 1/5 of root avulsions do not have dural tear
  - Dural tear not invariably associated with root avulsion
- May demonstrate rib injury or bone deformity

MR Findings

- US almost as accurate as MR for depicting brachial plexus pathology; main benefits of MR include
  - Depiction of parascapular muscle denervation with higher sensitivity than US
  - Depiction of preganglionic lesion or foraminal stenosis, which cannot be seen on US
- Thickening & T2-hyperintensity of abnormal brachial plexus neural components
- Signal changes in innervated muscles
  - T2-hyperintensity denervation edema
  - T1-hyperintensity fatty atrophy
- Postradiation plexopathy: Smooth neural thickening ± clumping ± T2-hyperintensity ± mild enhancement
  - Variable effacement of perineural fat planes best appreciated on T1-weighted sagittal images
- Pseudomeningocele suggests root avulsion & high-grade preganglionic traumatic injury
- Benign neurogenic tumor: Well-circumscribed, homogeneously enhancing, oval lesion with smooth margins along length of nerve
  - Target sign of central T2 hypointensity & peripheral T2 hyperintensity may be seen in neurofibromas
- Metastasis: Focal nodular mass lesion or focal neural enlargement, T2 hyperintensity of affected nerves, & contrast enhancement

Ultrasonographic Findings

- **Postradiation plexopathy**: Diffuse enlargement ± with hypoechoic fibrotic atrophied perineural fat
  - Usually involves > 1 component of brachial plexus, mainly supraclavicular components
  - Thickening, hypoechogenicity, & stiffness of subcutaneous & deeper perineural tissues due to fibrosis
- **Traumatic plexopathy**: Swelling of injured nerves
  - Focal discontinuity of swollen nerve indicates partial or complete transection
    - Best depicted on longitudinal plane
    - Retraction indicative of complete transection
  - May develop posttraumatic NIC or end-neuroma
    - Posttraumatic neuroma resembles nerve sheath tumor & is typically < 2 cm diameter
- **Benign neurogenic tumor**: Discrete, well-defined, ovoid hypoechoic mass inseparable from brachial plexus

- **Metastatic infiltration**: Focal, often irregular mass infiltrating neural components without tethering
  - ± hypervascular on color Doppler US
  - Often coexistent malignant-type lymphadenopathy
    - May need US-guided biopsy to distinguish from nodular fibrosis
- **Neuralgic amyotrophy**: Focal enlargement of nerve
  - Suprascapular nerve most commonly affected: Cross-sectional area > 4.2 mm² used as cut-off
- **Inflammatory plexopathy**: Diffuse enlargement of affected nerves with normal surrounding fat
- **Thoracic outlet syndrome**: Scan from interscalene to infraclavicular region at rest & after provocative movement
  - Neurologic > venous > arterial compression
  - Spectral analysis of subclavian artery & vein
    - Subclavian & axillary arteries at rest, axillary artery in abduction
  - Focal nerve entrapment ± altered spectral waveform
    - Abnormal if flow diminished (peak systolic velocity increases 2x resting value), monophasic, or absent flow
    - Reduced flow frequently seen in normal subjects so if abnormal, compare with contralateral side

Imaging Recommendations

- Best imaging tool
  - High-resolution US with linear transducer
  - MR may be able to provide more information on preganglionic nerve roots & infraclavicular region
  - MR or CT angiography in neutral & arm abducted position useful in vascular thoracic outlet syndrome
- Protocol advice
  - Neural components best examined transversely
    - Longitudinal plane helpful to show neural transection
  - Always examine contralateral asymptomatic or less symptomatic side first
    - Provides good indication as to normal appearances of brachial plexus in patient being examined
  - Roots, trunks, & divisions examined with arm by side & head turned slightly to contralateral side
    - Start scanning trunks in interscalene region, then move medially to examine roots & then laterally to examine divisions
  - Cords examined with arm abducted to 90°
  - Terminal branches examined with arm fully extended

DIFFERENTIAL DIAGNOSIS

Cervical Radiculopathy

- Normal brachial plexus US; MR will be confirmatory

PATHOLOGY

General Features

- Early transient radiation-induced plexopathy due to inflammatory response & small vessel ischemic changes
- Radiation-induced fibrosis occurs due to progressive fibrosis of endo- & perineural tissues
- Inflammatory plexopathy due to variety of causes
  - Most commonly chronic inflammatory demyelinating polyneuropathy, multifocal motor neuropathy

Staging, Grading, & Classification

- Neuropraxia represents low-grade (1st degree) nerve injury, characterized by impaired nerve conduction without axonal disruption & intact neural coverings
- High-grade nerve injury characterized by partial or complete nerve transection ± neuroma

CLINICAL ISSUES

Presentation

- Most common signs/symptoms
  - Upper limb numbness, pain & weakness
    - Sudden onset of unilateral shoulder girdle or upper limb pain suggests neuralgic amyotrophy
  - Early transient radiation-induced plexopathy, 3-10 months after irradiation therapy with mild symptoms
  - Radiation-induced fibrosis > 6 months to several years after radiotherapy

Demographics

- Younger patients, traumatic injury or primary tumor
- Older patients, postradiation plexopathy or metastasis

Natural History & Prognosis

- Low-grade neuropraxic traumatic injury gradually recovers
- Intermediate-grade traumatic injury gradually heals with mild fibrosis, often with mild residual functional deficit
- High-grade traumatic injury has minimal recovery potential

Treatment

- Supportive ± steroids ± immunoglobulin therapy for radiation-induced fibrosis, inflammatory polyneuropathy & neuralgic amyotrophy
- Surgery for tumor excision or nerve reconstruction
  - Primary repair, nerve grafting, nerve ± myotendinous transfer

DIAGNOSTIC CHECKLIST

Consider

- US is almost as accurate as MR for identifying & characterizing brachial plexopathy
- 2/3 of brachial plexus examinations are normal on both US & MR
  - If US is normal, likelihood of finding abnormality on MR is very low
    - Main exception is neuralgic amyotrophy, so if this is suspected & US is normal, proceed to MR

Image Interpretation Pearls

- Always examine contralateral asymptomatic or less symptomatic side first

Reporting Tips

- Grade postradiation plexopathy depending on degree of nerve swelling, perineural fibrosis, & clumping

SELECTED REFERENCES

1. Yip SWY et al: Ultrasound accuracy for brachial plexus pathology. Clin Radiol. 79(7):e916-23, 2024

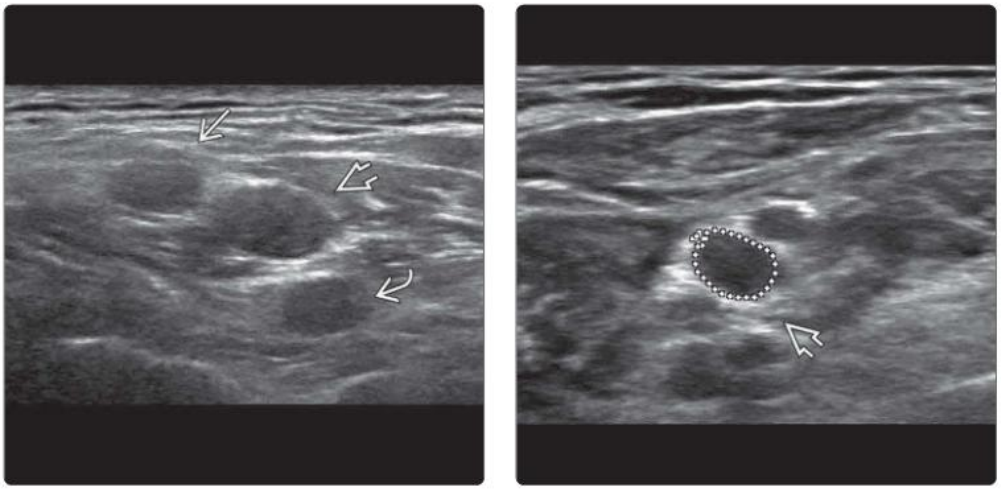

(Left) *Transverse US of the interscalene region in a 48-year-old man with chronic inflammatory demyelinating polyneuropathy (CIDP) shows severe smooth enlargement of the superior ➡, middle ➡, and inferior ➡ trunks. The middle trunk measured 26 mm². Perineural fat is normal.* **(Right)** *Transverse US of the contralateral left side in the same patient shows moderate smooth enlargement of the middle trunk measuring 12 mm² ➡, compatible with inflammatory polyneuropathy, more severe on the right side.*

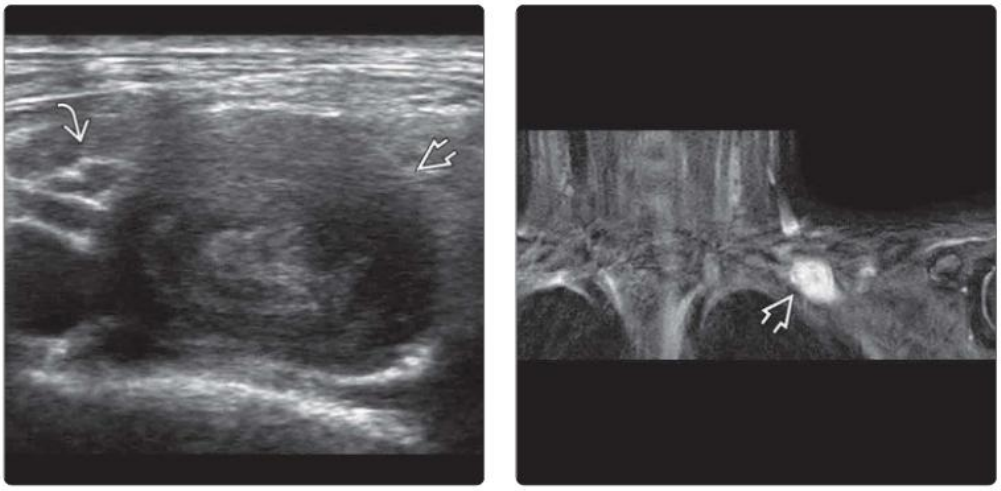

(Left) *Transverse US of the supraclavicular region in a 23-year-old man with arm pain shows a medium-sized, smooth, well-defined soft tissue mass indicative of a nerve sheath tumor ➡ arising from the posterior aspect of the divisions superolateral to the subclavian artery ➡.* **(Right)** *Coronal T2 FS MR in the same patient shows a T2-hyperintense neurogenic tumor ➡ along the posterior divisions. Mild motion artifact is present. Surgical excision confirmed a benign schwannoma.*

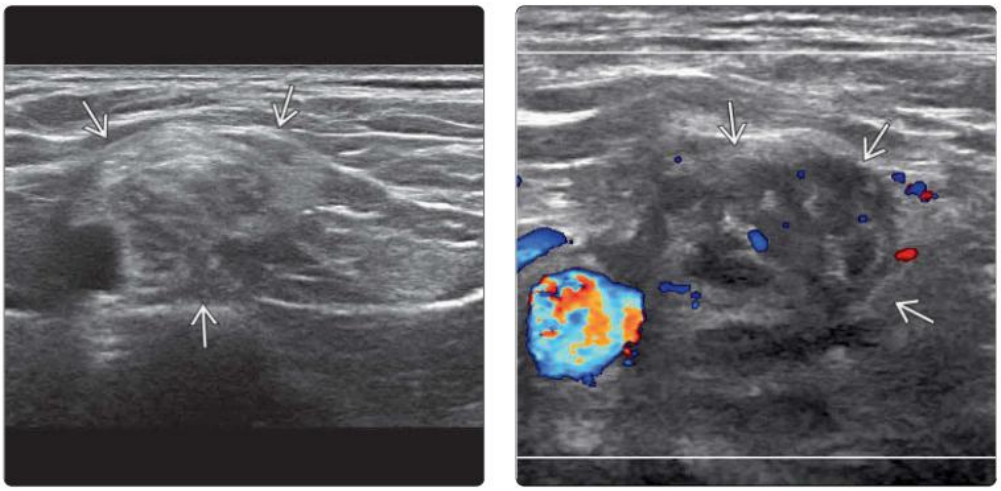

(Left) *Transverse US of the supraclavicular region in a 72-year-old man with axillary swelling and arm weakness shows a large, heterogeneous mass ➡ completely encasing the divisions of the brachial plexus.* **(Right)** *Color Doppler US of the same area shows moderate hypervascularity within this heterogeneous mass ➡ suggestive of a malignant tumor.*

(Left) *Transverse US more distally shows the mass completely encasing the cords of the brachial plexus. Surgery revealed a diffuse large B-cell lymphoma completely encasing the divisions and cords of the brachial plexus.* **(Right)** *Transverse US of interscalene region in a 64-year-old woman with previous left-sided radiotherapy for breast cancer with progressive left arm pain shows severe smooth thickening of the superior, middle, & inferior trunks with atrophy of the perineural fat.*

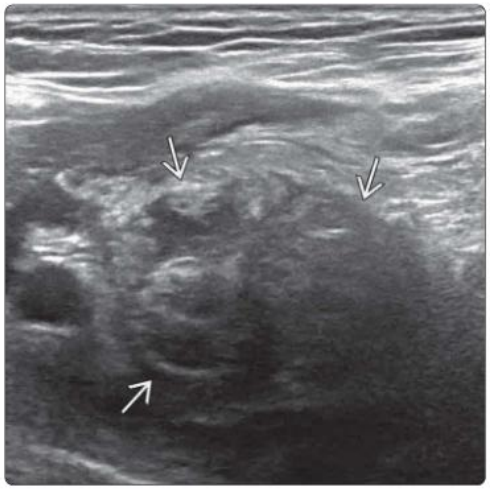

(Left) *Transverse US of the subcoracoid recess in the same patient shows diffusely thickened, partially tethered terminal divisions and cords of the brachial plexus adjacent to the axillary artery.* **(Right)** *Transverse US in the same patient shows moderate to severe enlargement of the terminal branches of the brachial plexus along the axillary artery. This is compatible with severe radiation plexopathy involving the trunks to terminal branches.*

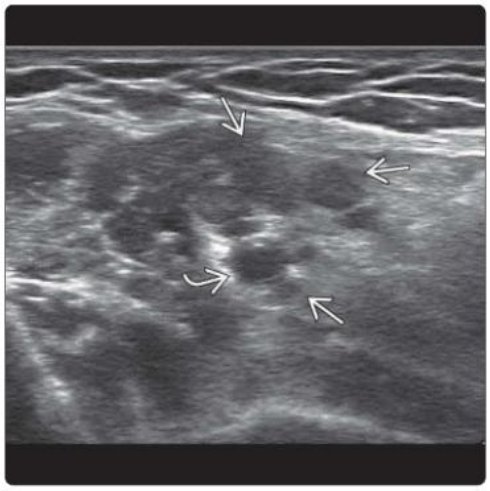

(Left) *Clinical photograph of a 62-year-old man with left arm pain and weakness 20 years after radiotherapy for nasopharyngeal carcinoma shows postradiotherapy skin changes.* **(Right)** *Transverse US in the same patient shows severe radiation fibrosis of the interscalene region with fibrosis of the perineural fat surrounding the mildly swollen trunks, poor muscle definition, and severe dermal-subcutaneous thickening.*

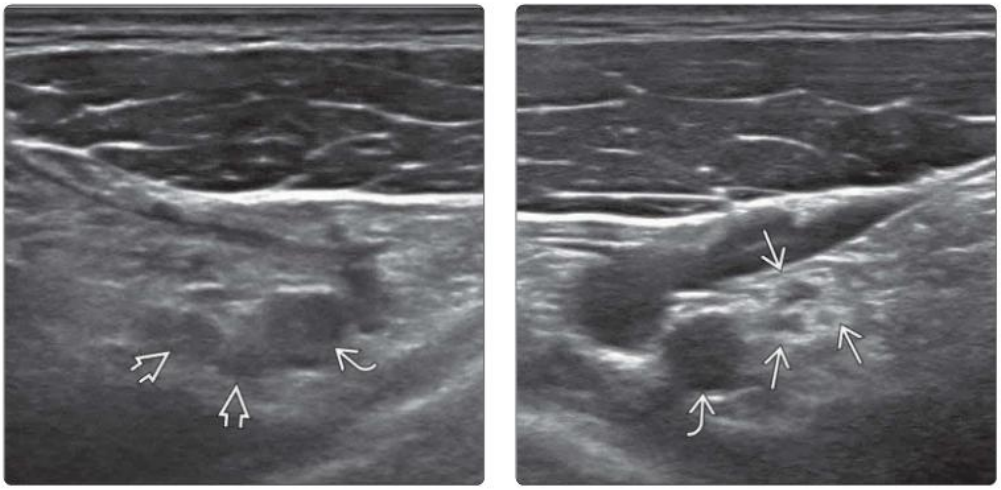

(Left) *Transverse US of the subcoracoid recess in a 27-year-old male MVA victim with arm weakness shows moderate thickening of the posterior and lateral cords ⇨ adjacent to the axillary artery ⇨, suggestive of moderate to severity traction injury.* **(Right)** *Transverse US of the asymptomatic side at the same region shows normal lateral, posterior, and medial cords ⇨ alongside the axillary artery ⇨.*

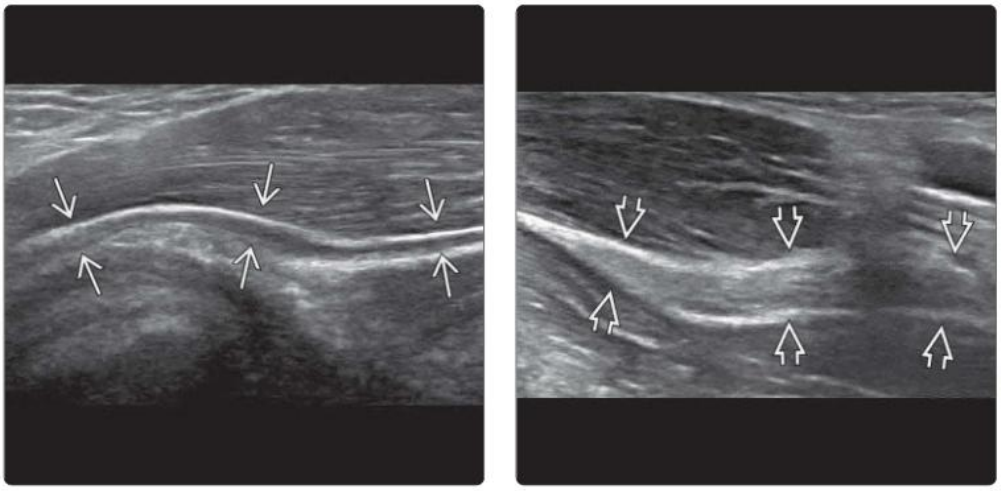

(Left) *Longitudinal US of the noninjured side in the same patient shows a normal left musculocutaneous nerve ⇨.* **(Right)** *Longitudinal US of the injured side in the same patient shows severe smooth thickening of the musculoskeletal nerve ⇨ indicative of severe traction injury.*

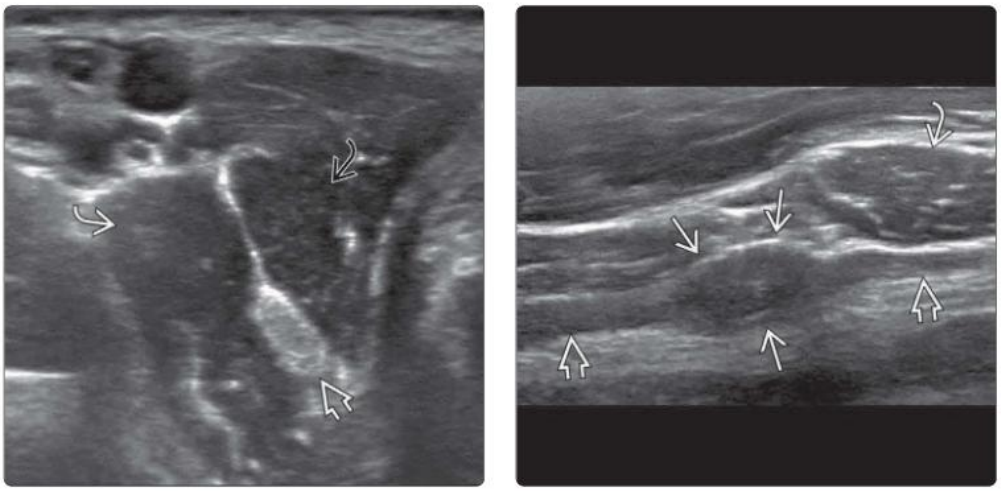

(Left) *Transverse US in the same patient shows marked enlargement of the proximal right musculoskeletal nerve measuring 14.1 mm² ⇨ as it courses between the biceps ⇨ and coracobrachialis ⇨ muscles. Surgery confirmed complete loss of musculocutaneous nerve function and severe injury to lateral and posterior cords.* **(Right)** *Longitudinal US in the same patient shows a neuroma-in-continuity ⇨ of the posterior cord ⇨ deep to the pectoralis minor muscle ⇨.*

KEY FACTS

TERMINOLOGY

- Tarsal tunnel syndrome (TTS): Entrapment neuropathy of tibial nerve & its branches (medial, lateral plantar nerves) on medial aspect of ankle
  - Much less common than carpal or cubital tunnel syndrome
  - 2 forms
    - Lower: Compression deep & distal to abductor hallucis muscle (variant)
    - Upper: Compression within tarsal tunnel (classic)

IMAGING

- Demonstration of structural abnormality within tarsal tunnel is currently of greater diagnostic value than nerve caliber measurements
  - Value & diagnostic capacity of nerve caliber measurements not well established
- Mass within tarsal tunnel (ganglion, lipoma, tendon disorder with peritendinitis, varicosities)
- Extrinsic mass encroaching on tarsal tunnel (synovial proliferation, bony overgrowth)
- Intrinsic nerve abnormality (fibrosis, tumor, diffuse enlargement)
- Altered tibial nerve caliber (enlarged with tarsal tunnel, compared to proximally & contralateral side)
- Normal CSA tibial nerve at tarsal tunnel ~ 11 mm²
- Tibial nerve CSA at tarsal tunnel > 15 mm² has 74% sensitivity & 100% specificity for TTS
  - Tibial nerve in-tunnel CSA minus pre-tunnel CSA of > 5 mm² has 81% sensitivity, 100% specificity for TTS
- Side-to-side difference in tibial nerve CSA > 1.8 mm² considered abnormal
- US Tinel sign can be performed by tapping over nerve to see if symptoms elicited
- Consider examining tarsal tunnel in standing position if symptoms aggravated by weightbearing
  - Weightbearing will exaggerate heel valgus & distend varicosities

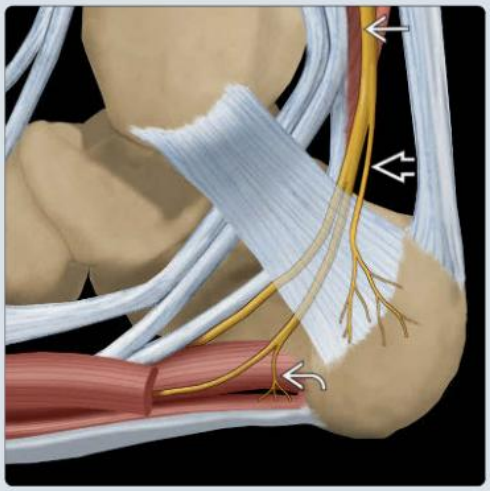

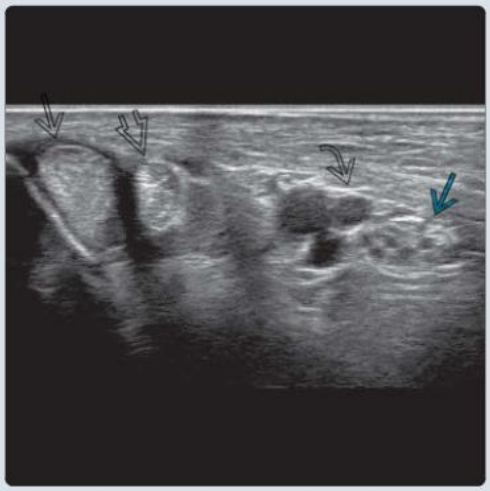

(Left) *Graphic shows the tarsal tunnel with the tibial nerve ➡ dividing into the medial and lateral plantar nerves under the flexor retinaculum. The medial calcaneal nerve ➡ normally comes off the tibial nerve proximal to retinaculum. The inferior calcaneal nerve ➡ is 1st branch of the lateral plantar nerve.* **(Right)** *Transverse US shows the normal tarsal tunnel with the tibialis posterior ➡ and flexor digitorum longus ➡ tendons, the posterior tibial artery ➡, and accompanying veins, as well as the tibial nerve ➡.*

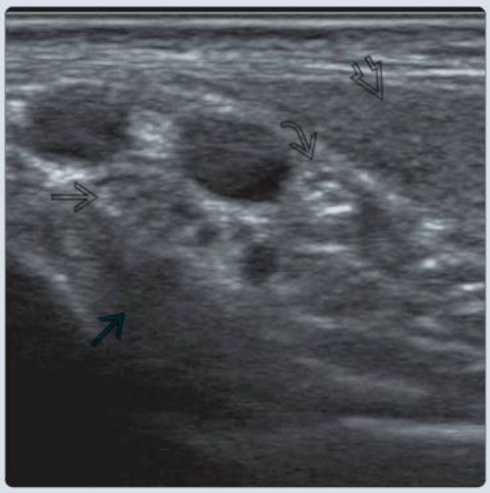

(Left) *Transverse US shows the posterior tibial artery ➡, accompanying veins, and tibial nerve ➡, which are about to divide into its plantar branches deep to the flexor retinaculum ➡.* **(Right)** *Transverse US shows medial ➡ and lateral ➡ plantar nerves in the lower tarsal tunnel with accompanying veins between the abductor hallucis ➡ and quadratus plantae ➡ muscles.*

TERMINOLOGY

Abbreviations

- Tarsal tunnel syndrome (TTS)

Definitions

- Entrapment neuropathy of tibial nerve & its branches on medial aspect of ankle
- Causes pain, burning sensation, paraesthesia, & numbness medial 3 toes, sole of foot, & heel region
- 2 forms of TTS
  - Upper (tibiotalar): Compression of tibial nerve within tarsal tunnel
    - Upper tarsal tunnel extends from retromalleolar region to proximal end of abductor hallucis muscle
  - Lower (tibiocalcaneal): Compression of plantar nerves in their separate tunnels deep & distal to abductor hallucis muscle
    - Lower tarsal tunnel lies distal to abductor hallucis muscle

IMAGING

General Features

- Location
  - Tarsal tunnel is posteroinferior to medial malleolus
    - Roof: Flexor retinaculum & abductor hallucis muscle
      - Flexor retinaculum of tarsal tunnel is less taut & more distensible than that of carpal tunnel
    - Floor: Calcaneum, talus, posterior talocalcaneal articulation, deltoid ligament, distal tibia
    - Contents: "**T**om, **D**ick, **A**nd a **V**ery **N**ervous **H**arry" (**T**ibialis posterior tendon, flexor **D**igitorum longus tendon, posterior tibial **A**rtery, posterior tibial **V**eins, tibial **N**erve, flexor **H**allucis longus tendon)
  - Tibial nerve passes deep to flexor retinaculum & divides into medial & lateral plantar branches
    - In 20% of subjects, tibial nerve divides into its terminal branches just before it enters tarsal tunnel
  - Medial calcaneal nerve is 1st branch of tibial nerve at ankle
    - Usually arises directly from tibial nerve proximal to tunnel or, less frequently, arises from lateral plantar nerve
      - 1/4 of subjects have 1, 1/2 have 2, & 1/4 of subjects have 3-5 medial calcaneal nerves
    - Supplies skin of heel & medial side sole of foot
  - Medial plantar nerve innervates abductor hallucis, flexor digitorum brevis, flexor hallucis brevis, & 1st lumbrical muscle
    - Larger branch of tibial nerve
    - Runs from anteromedial aspect calcaneum close to flexor hallucis longus tendon along medial aspect of foot
    - Provides sensation to medial aspect sole of foot & medial 3 toes
    - Can be compressed by thickened knot of Henry, which is flexor hallucis longus/flexor digitorum longus tendon intersection at distal end of sustentaculum tali (jogger's foot)
  - Lateral plantar nerve innervates remaining deep foot muscles, including quadratus plantae & abductor digiti minimi
    - Descends steeply between abductor hallucis & quadratus plantae before running anterolaterally on surface of quadratus plantae, then to base of little toe
    - Provides sensation to lateral part of sole of foot & lateral 2 toes
  - Inferior calcaneal nerve (Baxter nerve) is 1st branch of lateral plantar nerve
    - Arises at lower end of abductor hallucis, then runs between quadratus plantae & flexor digitorum brevis
      - Passes superficial to medial calcaneal tuberosity, then innervates digiti minimi muscle
      - Visible on US deep to flexor digitorum brevis at leading edge of calcaneum
    - Inferior calcaneal nerve is mixed motor & sensory nerve
      - Motor innervation to abductor digiti minimi & part of quadratus plantae
      - Sensory to calcaneal periosteum & long plantar ligament
      - Baxter nerve impingement or neuritis can give symptoms indistinguishable from plantar fasciitis
    - Compression leads to abductor digiti minimi atrophy
      - However, moderately severe adductor digiti minimi atrophy is seen in 10% of asymptomatic subjects

MR Findings

- T1WI or PD
  - Useful for assessing nerve anatomy, branching variations, assessment of perineural fibrosis, & space-occupying lesions
    - Atrophic fatty atrophy of foot muscles graded as mild (< 25%), moderate (26-50%), severe (51-75%), or very severe (> 76%)
  - Also useful for assessing osseous or synovial encroachment onto tarsal tunnel
- T2WI FS
  - Best for detection of nerve swelling, hyperintensity, & muscle edema

Ultrasonographic Findings

- Mass lesion within tarsal tunnel
  - Ganglion, lipoma, synovial proliferation, tendon disorder with peritendinitis, varicosities, accessory muscle, or hypertrophied muscle
- Change in tibial nerve caliber (enlarged proximally, narrowed at site of compression)
  - US diagnostic criteria for TTS not firmly established

Imaging Recommendations

- Best imaging tool
  - US because tibial nerve can be consistently seen, as well as compression or abnormality of tibial nerve
    - No established diagnostic US criteria for TTS, unlike carpal tunnel & cubital tunnel syndrome
  - MR is helpful if symptoms not fully explained by US
    - Particularly helpful in assessing distal part of lower tarsal tunnel, where thick plantar skin can limit US examination

- Nerve conduction studies show absent sensory potentials & prolonged motor latencies
  - Not specific for TTS as may be seen in polyneuropathy or in older patients
  - Overall of limited value in TTS
- Protocol advice
  - Patient lies in lateral decubitus position with medial ankle facing upward
  - Scan transversely over tarsal tunnel (malleolar calcaneal axis) keeping tibial nerve in cross section
  - Diagnosis of TTS depends more on demonstration of structural abnormality than nerve caliber change
  - Check especially for
    - Mass present within tarsal tunnel (lipoma, ganglion, tendinosis or tenosynovitis, varicosities, varix, aneurysm)
      - Varicosities can cause intermittent tarsal tunnel syndrome on weightbearing
    - Mass encroaching onto tarsal tunnel (synovial proliferation, bony overgrowth)
    - Intrinsic abnormality of tibial nerve (fibrosis, tumor, diffuse enlargement)
  - Measure tibial nerve caliber in tarsal tunnel & 10 cm proximal to tunnel
    - Normally little difference between these 2 measurements
    - Normal cross-sectional area (CSA) tibial nerve at tarsal tunnel ~ 11 mm^2
    - Tibial nerve CSA at tarsal tunnel > 15 mm^2 has 74% sensitivity & 100% specificity for TTS
    - Tibial nerve in-tunnel CSA minus pre-tunnel CSA of > 5 mm^2 has 81% sensitivity, 100% specificity for TTS
  - Side-to-side difference in tibial nerve CSA > 1.8 mm^2 considered abnormal
    - Side-to-side comparison in patients with unilateral TTS may be more accurate than absolute measurements
  - US-elicited Tinel sign by tapping over nerve to see if symptoms elicited
  - Consider examining tarsal tunnel in standing position if symptoms worse on weightbearing
    - Weightbearing will exaggerate heel valgus in pes planus & exaggerate venous distension
      - May see sustentaculum tali compressing plantar nerves
      - Plantar vein > 5 mm dilatation indicates varicosity
      - US has advantage over MR, as MR is usually performed only in non-weightbearing position
  - Check for atrophy of hindfoot muscles
    - Compare with contralateral side
  - US-guided injection of local anesthetic ± steroid into tarsal tunnel may be of diagnostic & possibly therapeutic benefit

DIFFERENTIAL DIAGNOSIS

Posterior Tibial Disorders

- Thickening, hypoechogenicity with loss of normal fibrillar pattern of posterior tibialis tendon
  - Many have split tendon tears ± variable degree of peritendinitis
    - May lead to TTS

Tarsal Coalition

- Hypertrophic bone protruding from midtalocalcaneal articulation is strong US sign of subtalar coalition

Plantar Fasciitis

- Thickening (> 4.3 mm) of plantar fascia at leading edge of medial calcaneal tuberosity
  - ± perifascial edema or plantar calcaneal spur
- Identical symptoms to inferior calcaneal neuropathy (Baxter neuritis)

CLINICAL ISSUES

Presentation

- Most common signs/symptoms
  - Medial malleolar pain radiating to medial aspect of foot
    - If symptoms confined to either plantar nerve, distal tarsal tunnel compression may be implicated
- Other signs/symptoms
  - Tenderness behind medial malleolus ± positive Tinel sign
  - Paraesthesia or burning sensation on plantar aspect of foot ± hyperesthesia on medial aspect of sole
    - Sparing of heel region, which is innervated by medial calcaneal nerve
  - Weakness ± atrophy of foot muscles
    - Weakness is usually asymptomatic, as function is not affected
  - Induction of symptoms by passive dorsiflexion & eversion of ankle for 10 seconds

Demographics

- Age
  - Typically young or middle-aged patients
- Epidemiology
  - Many causes of TTS
  - Mass within tarsal tunnel (ganglion, lipoma, nerve sheath tumor, synovial proliferation, tendon enlargement, venous engorgement)
  - Deformity with heel valgus
  - Osseous impingement from ankle/hindfoot arthropathy, talocalcaneal coalition, calcaneal fracture
  - Accessory muscles
    - Flexor digitorum accessorius muscle (medial aspect of distal tibia to quadratus plantae)
    - Peroneocalcaneus internus muscle (distal fibula to medial aspect calcaneum)
  - Posttraumatic perineural fibrosis
  - Intrinsic nerve abnormality (chronic inflammatory demyelinating polyneuropathy, nerve sheath tumor)
  - Thickened flexor retinaculum (normal 0.64 ± 0.03 m)
  - No cause found in 20% of patients with TTS

Treatment

- Conservative treatment
- Surgical division (open or endoscopic) of flexor retinaculum ± abductor hallucis muscle fasciotomy
  - Leads to symptomatic improvement in 50% of patients

SELECTED REFERENCES

1. Duarte ML et al: Weight-bearing ultrasound to diagnose talar dislocation causing tarsal tunnel syndrome. Prague Med Rep. 125(2):172-7, 2024

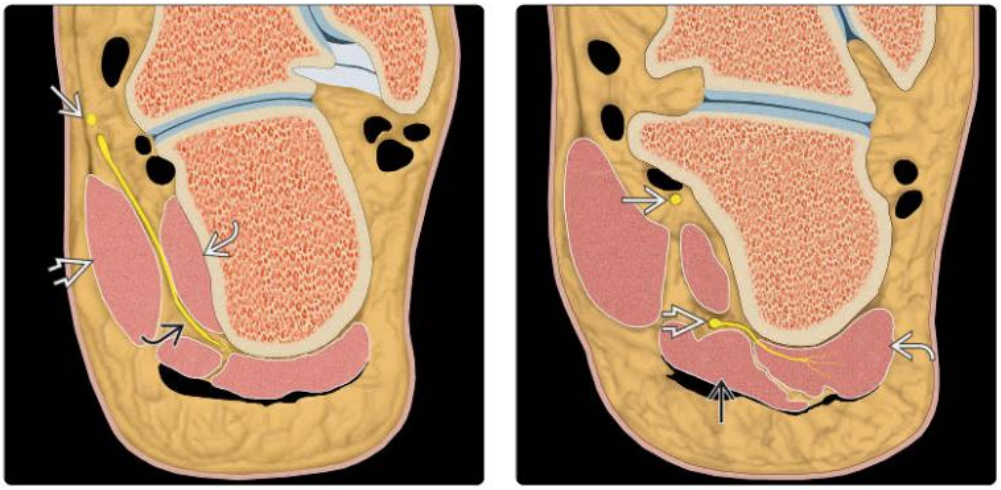

(Left) *Graphic shows medial ➡ and lateral ⇨ plantar nerves in the proximal portion of the lower tarsal tunnel. Note how the lateral plantar nerve dips deeply between the abductor hallucis ➡ and quadratus plantae ➡ muscles.* **(Right)** *Graphic of the distal portion of the lower tarsal tunnel shows the medial ➡ and lateral ➡ plantar nerves. Note how the lateral plantar nerve extends deep to the flexor digitorum brevis muscle ⇨ before supplying the abductor digiti minimi muscle ➡.*

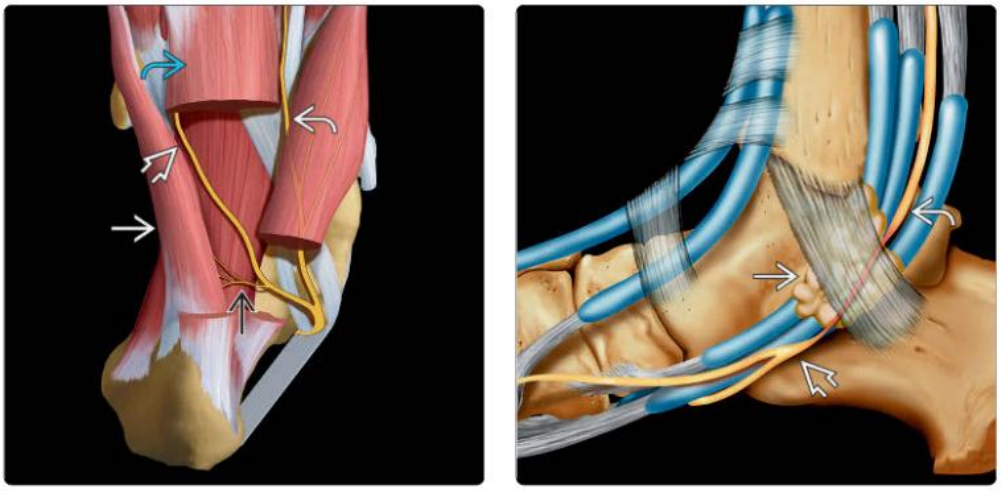

(Left) *Graphic of the hindfoot undersurface shows the inferior calcaneal nerve ⇨ passing laterally between the calcaneum and flexor digitorum brevis muscle ⇨ to supply the abductor digiti minimi ➡. The medial ➡ and lateral ➡ plantar nerves can be seen on US on both sides of the flexor digitorum brevis muscle.* **(Right)** *Graphic shows a ganglion ➡ compressing the tibial nerve ➡ within the tarsal tunnel. Here, the tibial nerve divides ➡ distal to the tarsal tunnel, which is an uncommon anatomic variant.*

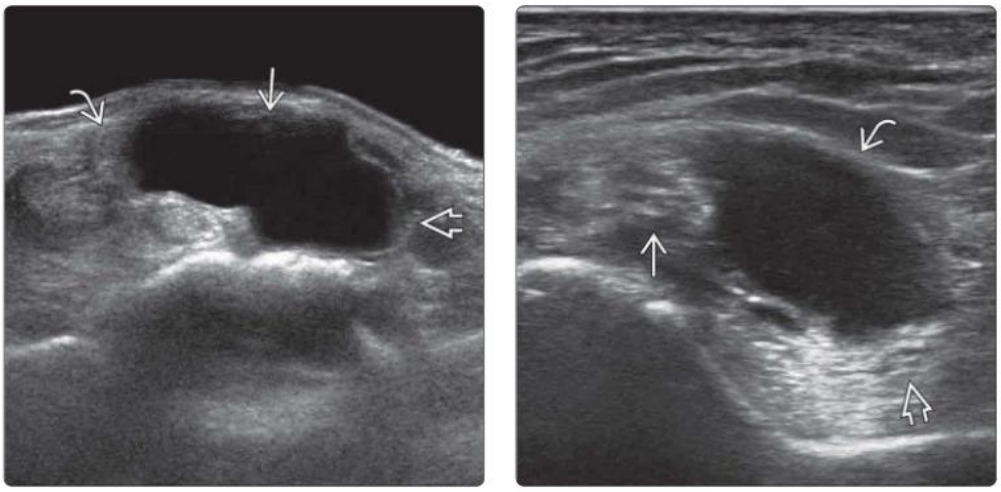

(Left) *Transverse US in a patient with tarsal tunnel syndrome (TTS) shows a medium-sized ganglion ➡ located within the tarsal tunnel between the flexor digitorum longus tendon ➡ and the posterior tibial neurovascular bundle. The tibial nerve ➡ is compressed.* **(Right)** *Transverse US of the tarsal tunnel shows a ganglion cyst ➡ at the bifurcation of the tibial nerve, mildly compressing onto the medial ➡ and lateral ➡ plantar nerves.*

(Left) *Transverse US in a 48-year-old man with medial ankle pain shows a medium-sized ganglion ➡ between the flexor digitorum longus ➡ and the tibial neurovascular bundle. The ganglion, which arises from the ankle, mildly compresses the tibial nerve ➡.* **(Right)** *Transverse US in a patient with TTS shows marked largely hypoechoic synovial proliferation ➡ from the posterior talocalcaneal articulation and ankle joint bulging into the tarsal tunnel with compression of the tibial nerve ➡. The calcaneum ➡ is normal.*

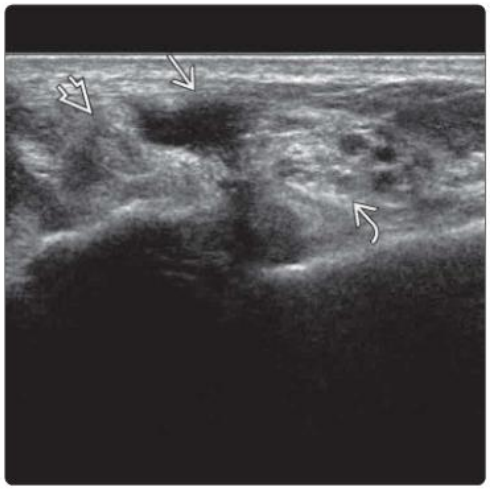

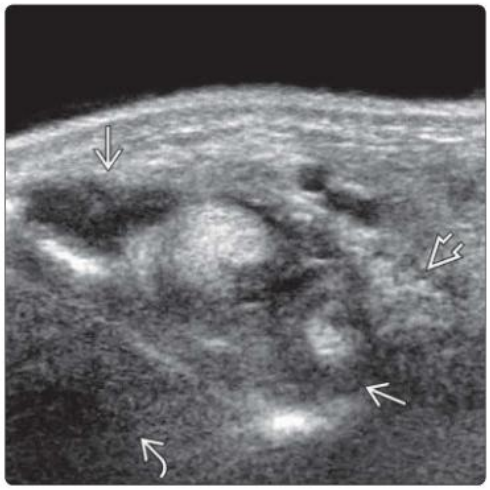

(Left) *Transverse US shows a large nerve sheath tumor ➡ of the tibial nerve within the tarsal tunnel. The tumor is arising eccentrically from the tibial nerve ➡. Mild tumoral hyperemia was present on color Doppler imaging.* **(Right)** *Transverse US in a patient with symptoms of TTS and clinically suspected chronic inflammatory demyelinating neuropathy shows an enlarged tibial nerve ➡ within the tarsal tunnel. The tibial nerve cross-sectional area was 34 mm². The tibial artery and veins ➡ are displaced.*

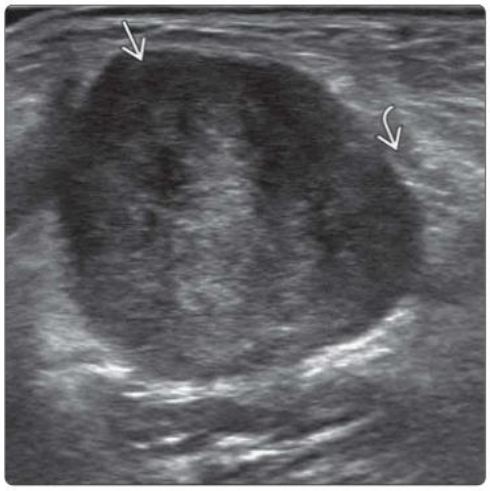

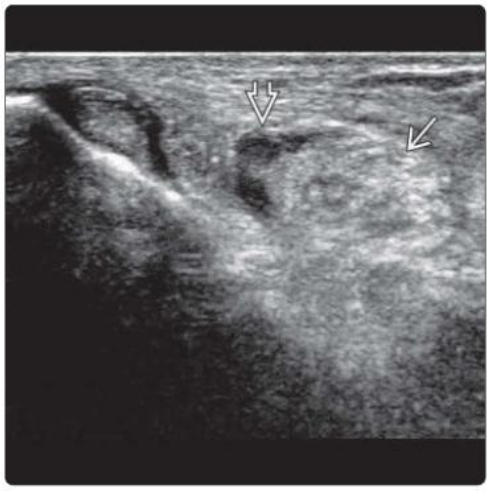

(Left) *Transverse US in a patient with TTS shows severe posterior tibialis tendinosis ➡ with moderate peritendinitis and thickening of the flexor retinaculum ➡. This swelling and edema can lead to tibial nerve compression within the upper tarsal tunnel.* **(Right)** *Axial T1 MR shows an accessory flexor digitorum muscle ➡, which can extend into the tarsal tunnel and contribute to compression of the tibial nerve. There is a similar, although smaller, accessory muscle ➡ on the contralateral side.*

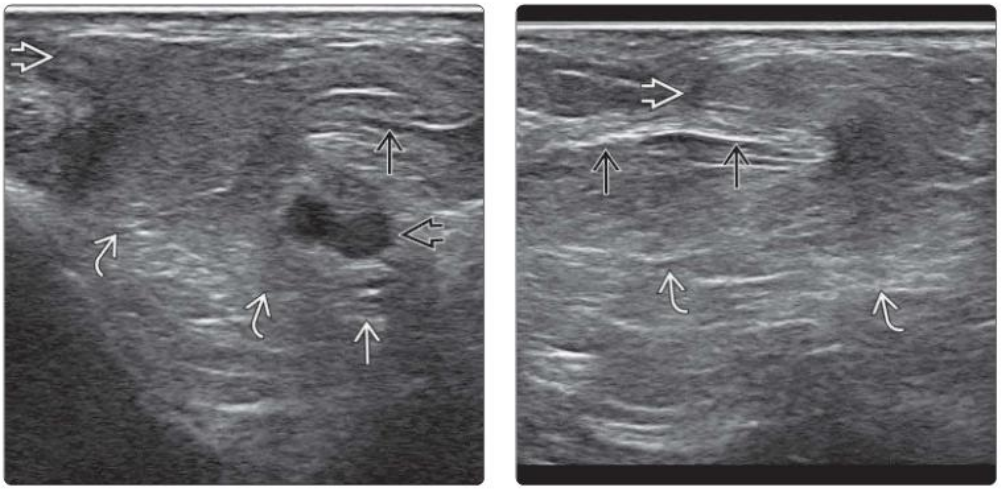

(Left) *Transverse US shows a large lipoma within the tarsal tunnel extending through the thickened flexor retinaculum into the subcutaneous layer. The tibial nerve seems to be compressed. The posterior tibial vessels are abutted.* **(Right)** *Longitudinal US of the same lipoma shows it filling the tarsal tunnel and extending through the thickened flexor retinaculum into the subcutaneous layer.*

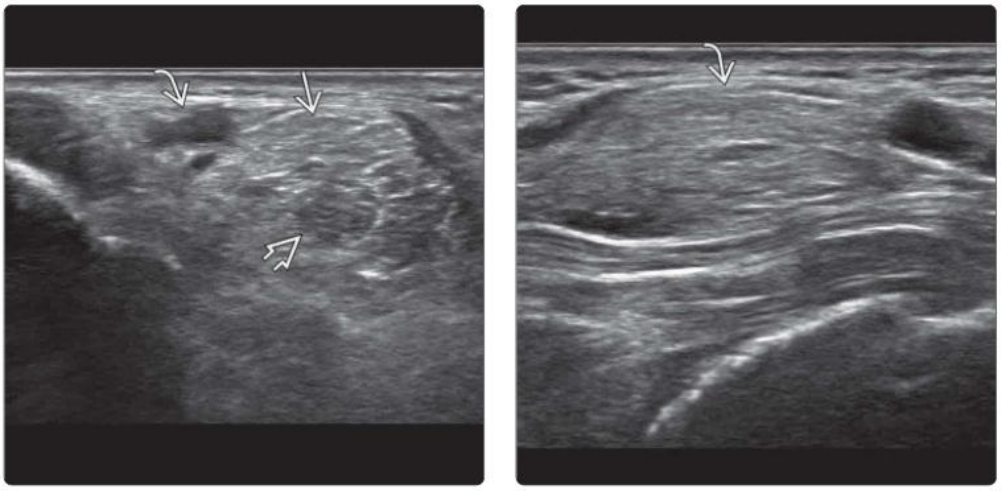

(Left) *Transverse US shows a medium-sized lipoma within the tarsal tunnel alongside the posterior tibial artery and veins. The lipoma is partially encasing the slightly swollen tibial nerve.* **(Right)** *Longitudinal US of the same tarsal tunnel mass shows the typical finely striated appearance of a lipoma, helping distinguish this tarsal tunnel fatty mass from lipomatosis or lipohypertrophy.*

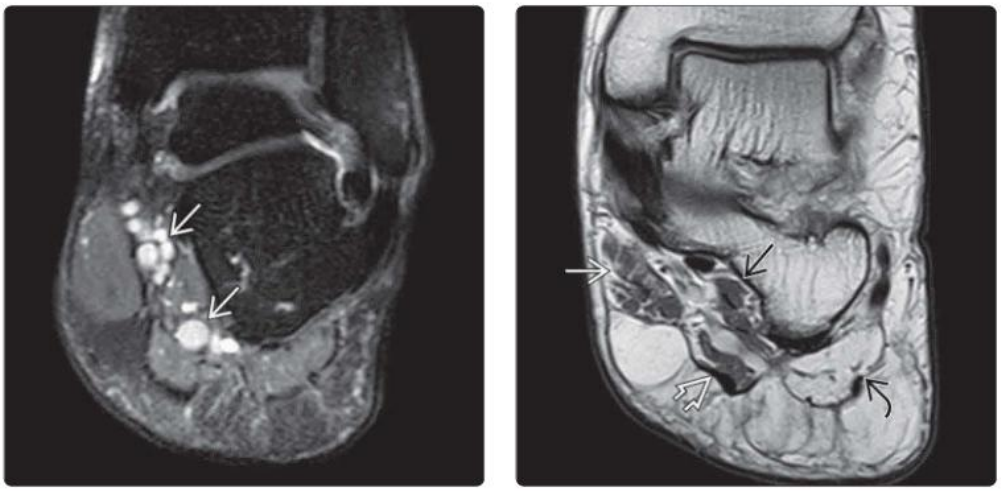

(Left) *Coronal T2 FS MR in a patient with TTS shows venous dilation of the lower tarsal tunnel, which can cause compression of medial and lateral plantar nerves.* **(Right)** *Coronal T1 MR in a patient with TTS shows moderate abductor hallucis, flexor digitorum brevis, and quadratus plantae atrophy with severe abductor digiti minimi atrophy, due to tarsal tunnel syndrome, affecting inferior calcaneal nerve (Baxter nerve). (Courtesy K. A. Al-Ismail, MD.)*

KEY FACTS

TERMINOLOGY

- Tumor arising from peripheral nerve; vast majority are schwannoma & neurofibroma
  - Nonneurogenic nerve tumors include
    - Lipoma, ganglion, fibrolipomatous hamartoma
    - Metastasis
    - Traumatic end neuroma, neuroma-in-continuity
  - Neurofibroma → distinct & plexiform types

IMAGING

- Any peripheral nerve can be affected
- Well-defined, largely homogeneous, hypoechoic mass
- Typically fusiform or oblong-shaped, oriented along long axis of nerve
- Nerve entering or exiting from tumor seen in 50%
- Posterior enhancement common (70%)
- Nerve sheath tumors, especially schwannoma, often contain cystic areas representing myxoid degeneration, hemorrhage, or necrosis
- Vascular pattern varied, usually moderate intrinsic vascularity
- US appearances of schwannoma & neurofibroma overlap
- US appearances of benign & malignant nerve sheath tumors overlap
  - → percutaneous biopsy, if suspicious
- Accurate diagnosis of nerve sheath tumor often feasible based on US findings alone
  - Neural continuity enables definitive diagnosis to be made without need for biopsy

DIAGNOSTIC CHECKLIST

- Consider nerve sheath tumor, even if parent nerve is not seen, provided other US features are compatible
- Most nerve sheath tumors of medium-sized or large nerves can be confidently diagnosed based on US appearances alone
  - Specificity for diagnosis of nerve sheath tumor arising from smaller nerves is much lower

(Left) *Longitudinal US of nerve sheath tumor (schwannoma) of sciatic nerve shows neural continuity and mild neural thickening proximally and distally. The tumor is slightly eccentric to the sciatic nerve. Moderate posterior acoustic enhancement is present.* **(Right)** *Longitudinal US of histologically proven schwannoma of common peroneal nerve shows moderate cystic change, due, most likely, to myxoid tissue.*

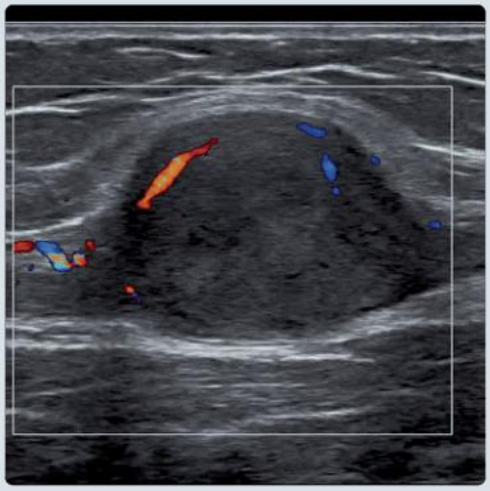

(Left) *Longitudinal US shows a medium-sized nerve sheath tumor (neurofibroma) of the ulnar nerve in the midforearm. Neurofibromas are less distinct than schwannomas, as they do not have a capsule or pseudocapsule.* **(Right)** *Longitudinal color Doppler US of the same tumor shows mild hyperemia. Schwannomas are generally more heterogeneous and more vascular than neurofibromas. Discrimination between schwannoma and neurofibroma on US is not, however, always clear-cut.*

TERMINOLOGY

Definitions

- Tumor arising from peripheral nerve
  - Vast majority are schwannoma & neurofibroma

Associated Syndromes

- Neurofibromatosis type 1 (NF1), von Recklinghausen disease associated with neurofibroma

IMAGING

General Features

- Best diagnostic clue
  - Well-defined, largely hypoechoic, oblong-shaped mass arising from nerve
- Location
  - Any peripheral nerve
    - Intermuscular > subcutaneous > intramuscular
- Size
  - Usually < 5 cm, up to 20 cm
  - Nerve tumors usually grow slowly, then stop growing
- Morphology
  - Soft tissue mass along nerve

MR Findings

- T1WI
  - Soft tissue mass isointense to muscle; split-fat sign (intermuscular fat splits to encompass tumor)
- T2WI
  - Well-defined, fusiform mass hyperintense to muscle; target sign: Hypointense center due to collagen & more myxoid hyperintense tissue peripherally; neural tail sign
- T1WI C+
  - Variable enhancement: May see mainly peripheral enhancement or reverse target sign (enhancing central fibrous component & nonenhancing peripheral myxoid component)
- MR appearances of schwannoma & neurofibroma overlap considerably
- To distinguish malignancy, ADC on DWI with lowest tumor signal intensity (ADCdark) yields highest diagnostic accuracy
  - ADCdark value of > 1.6×10^{-3} mm/s means nerve sheath tumor (NST) in question is more likely to be benign NST [rather than atypical neurofibroma or malignant peripheral NST (MPNST)] with 85% sensitivity, 93% specificity
  - ADCdark value of > 1.4×10^{-3} mm/s means NST in question is more likely to be benign NST or atypical neurofibroma (rather than MPNST) with 83% sensitivity, 94% specificity

Ultrasonographic Findings

- Well-defined, hypoechoic mass; occasionally heterogeneous
  - Heterogeneity due to myxoid tissue, hemorrhage, fibrosis, or calcification
    - Target sign: Central hyperechogenic fibrocollagenous component surrounded by peripheral hypoechogenic myxoid component; more commonly seen in neurofibroma
  - Nerve entering or exiting from tumor seen in 50%
    - Parent nerve often slightly thickened just proximal & distal to tumor
    - Entering/exiting nerve usually not seen when NST arises from small peripheral nerve
    - Compressed fascial planes may mimic nerve on longitudinal plane; always confirm on transverse plane
  - Intratumoral hemorrhage may lead to recent ↑ in tumor size
- Occasionally, tumor has echogenic rim due to fibrous capsule, fibrous pseudocapsule, or compression of surrounding fat
- Vascular pattern varied
  - Usually moderately vascular with central irregular vascular pattern
    - Occasionally predominantly peripheral vascularity
- US diagnosis of NST is based on consortium of features rather than single feature
- Neural continuity enables definitive diagnosis to be made without need for biopsy
  - Biopsy may be very painful
- US appearances of schwannoma & neurofibroma overlap considerably
  - Schwannomas tend to be
    - More eccentric to parent nerve
    - More heterogeneous
    - More encapsulated
    - Have oblong or rounded rather than fusiform shape
    - Have smooth rather than lobulated contour
    - Have more echopoor areas (seen in 50% of schwannomas, < 5% of neurofibromas)
      - Due to myxoid accumulation, previous hemorrhage, or necrosis
      - Degenerative "ancient schwannomas" are predominantly cystic
    - Located more deeply (schwannoma close to fascia, neurofibroma close to dermis)
    - More likely to have neural continuity (50% of schwannomas, 15% of neurofibromas)
    - More vascular (90% of schwannomas & 50% of neurofibromas have demonstrable vascularity)
      - Though dependent on color sensitivity of US system
  - While important surgically, do not focus on characterizing type of NST on imaging as it is unreliable in this regard
  - Instead report on centric/eccentric location of tumor to parent nerve, as this influences surgical resection
- Diffuse plexiform neurofibroma: Thickening of skin & subcutaneous tissue with retinacular hypoechoic pattern
  - No discrete mass, hyperemic
    - Can mimic soft tissue infection, lymphoma, or vascular malformation
- Nodular plexiform neurofibroma: Diffuse nodular enlargement of nerves with "bag of worms"
  - ± discrete lobulated masses
- US appearances of benign & MPNSTs overlap considerably
  - NF1 is most important risk factor for MPNST
  - No single feature can reliably differentiate between benign & MPNST
  - Clinical indicators are helpful, such as large size (> 5 cm), rapid growth, & change in neurology

- Irregular margins, inhomogeneity, necrosis, & peritumoral inflammation are more common in MPNSTs
- On PET imaging, suspect MPNST if tumoral SUV > 3.2
- If clinical or imaging appearances suspicious of MPNST, undertake US-guided biopsy

Imaging Recommendations

- Best imaging tool
  - US will enable definitive or provisional diagnosis of most NSTs
    - Usually provides all information necessary for management
  - MR better at assessing extent of plexiform neurofibroma

DIFFERENTIAL DIAGNOSIS

Vascular Leiomyoma

- No entering or exiting nerve
- May be painful
- 60% have eccentric vascular confluence
- More common in lower limbs

Giant Cell Tumor of Tendon Sheath

- Mass related to tendon sheath or continuity with joint

Malignant Lymph Node

- Malignant or lymphomatous node with loss of distinction cortex & hilum may simulate NST
  - Does not have entering or exiting nerve
  - Occurs at different locations than NSTs

Fibromatosis

- Can have similar appearance to neurofibroma with fibrous-type appearance & little vascularity
- Tend to be more spiculated than neurofibromas

PATHOLOGY

General Features

- Genetics
  - NF1, von Recklinghausen disease
    - Affects 1 in 3,000 people
    - Autosomal dominant; 50% sporadic
    - Genetic mutation on *NF1* gene chromosome 17

Staging, Grading, & Classification

- Schwannoma
  - Usually solitary, malignant change rare
    - Occasionally > 1 schwannoma may occur along same nerve (schwannomatosis)
      - Schwannomatosis most commonly affects ulnar nerve
- Neurofibroma
  - Sporadic or associated with NF1
  - Plexiform neurofibroma pathognomonic of NF1
  - Malignant change occurs in 10% of NF1 patients
    - Plexiform neurofibromas have 10% lifelong risk of MPNST; uncommon with discrete neurofibroma
- Atypical neurofibroma considered premalignant precursor to MPNST

Gross Pathologic & Surgical Features

- Schwannoma
  - Tumor of Schwann cells, capsulated or pseudocapsulated
  - Can be enucleated from parent nerve
- Neurofibroma
  - Arise from connective tissue of nerve, not encapsulated, merging imperceptibly with parent nerve
  - Neural segmental resection required for excision

Microscopic Features

- Schwannoma
  - Arise from Schwann cells and composed of spindle cells & myxoid tissue
    - Strongly periodic acid-Schiff (PAS) positive
- Neurofibroma
  - Composed of interlacing bundles of fibroblasts, Schwann cells, & perineural-like cells
  - S100 positive in Schwann cells, CD34 positive in stroma

CLINICAL ISSUES

Presentation

- Most common signs/symptoms
  - Slowly growing, painless mass with positive Tinel sign
    - If increasing pain or rapid growth → consider MPNST
- Clinical profile
  - NF1: Café au lait spots, axillary or inguinal freckling, optic nerve glioma, Lisch nodules, kyphoscoliosis, tibial pseudoarthrosis, rib deformity, sphenoid wing dysplasia
  - > 50% of MPNSTs occur in NF1 patients

Demographics

- Age
  - 20-30 years
- Epidemiology
  - Comprise 5% of soft tissue masses referred for US assessment

Treatment

- Surgical excision of symptomatic lesions
  - Complete resection with sparing of parent nerve
  - Incomplete resection with sparing of parent nerve to minimize neurologic impairment
  - Complete resection with excision of parent nerve
    - Autologous nerve graft or biodegradable nerve conduit if defect > 20 mm

DIAGNOSTIC CHECKLIST

Consider

- NST, even if parent nerve not seen, provided other US features are compatible

SELECTED REFERENCES

1. Ristow I et al: Discrimination of benign, atypical, and malignant peripheral nerve sheath tumors in neurofibromatosis type 1 using diffusion-weighted MRI. Neurooncol Adv. 6(1):vdae021, 2024
2. Lefebvre G et al: Ultrasound and MR imaging of peripheral nerve tumors: the state of the art. Skeletal Radiol. 52(3):405-19, 2023

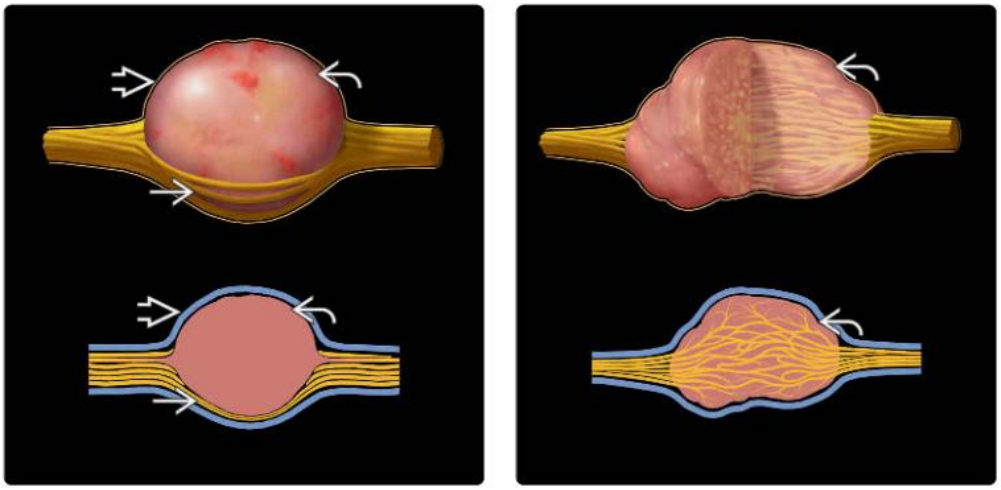

(Left) *Graphic shows a schwannoma. Each nerve is composed of axons arranged into fascicles. Each axon is covered by a myelin sheath composed of Schwann cells from which schwannomas derive. Each fascicle is covered by perineurium. All the fascicles are covered by epineurium.* **(Right)** *Graphic shows a neurofibroma. Neurofibromas arise from primitive neural cells, which differentiate into different neural and perineural cell elements instead of Schwann-cell type.*

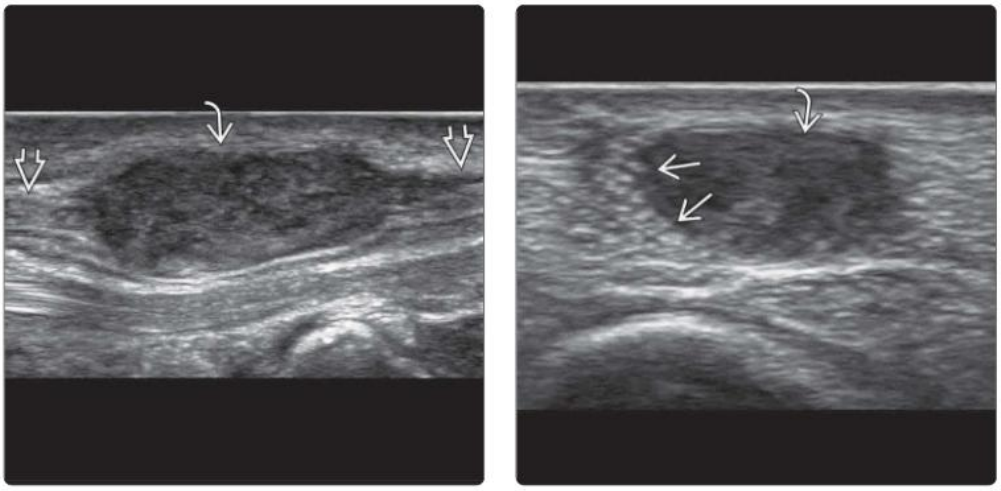

(Left) *Longitudinal US shows nerve sheath tumor (schwannoma) arising eccentrically from the median nerve near the wrist.* **(Right)** *Transverse US of same patient shows that most of the median nerve fascicles are located eccentric to the tumor.*

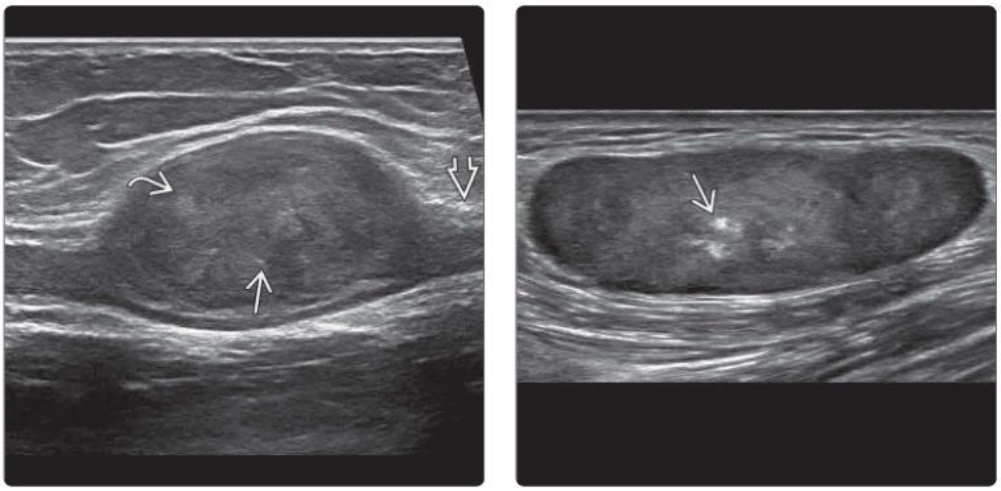

(Left) *Longitudinal US of schwannoma of the deep branch of the peroneal nerve shows an ill-defined echogenic area, possibly due to hemorrhage and small echogenic foci, possibly due to microcalcification.* **(Right)** *Longitudinal US of a subfascial mass located between the investing fascia and tibialis anterior muscle is shown. There is mild central calcification. No neural continuity was evident. Biopsy confirmed nerve sheath tumor.*

(Left) *Longitudinal US of patient with a distal forearm mass shows a nerve sheath tumor (schwannoma) arising eccentrically from the median nerve. Most of the nerve fibers lie on the deeper margin of the parent nerve.* **(Right)** *Longitudinal color Doppler US of the same patient shows moderate tumoral hyperemia, typical of schwannoma.*

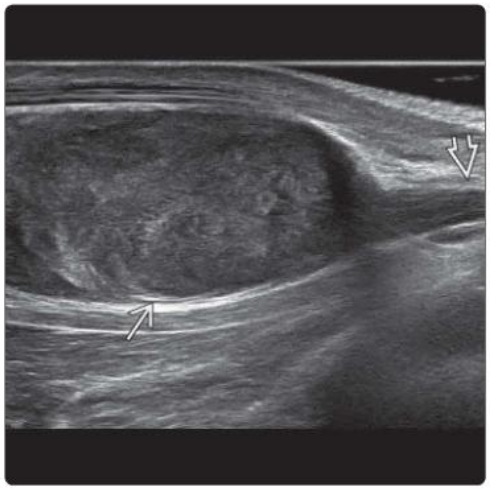

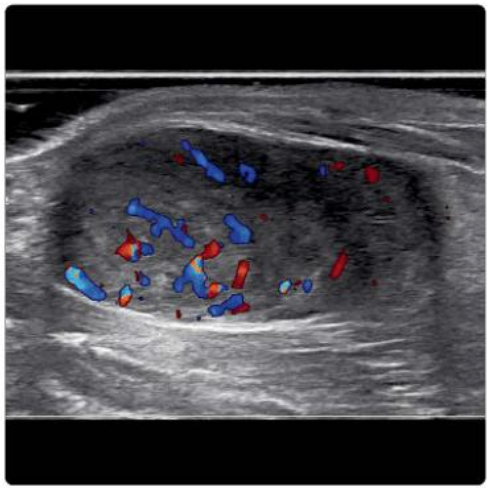

(Left) *Longitudinal US of a radial nerve tumor made up of a 30% solid component and a 70% cystic component is shown. Cystic degeneration is mainly due to myxoid accumulation rather than hemorrhage or necrosis. It is more common in schwannoma.* **(Right)** *Longitudinal US of the same patient shows tumor in continuity with the radial nerve posterior to the humeral shaft.*

(Left) *Clinical photograph of an older adult patient with midforearm swelling for many years is shown.* **(Right)** *Longitudinal US of the same patient shows a large cystic nerve sheath tumor of the median nerve consistent with an "ancient schwannoma." The patient was not keen for surgery. Following biopsy of the solid component, the cystic component of the tumor was aspirated under US guidance with marked reduction in tumor size and good clinical effect.*

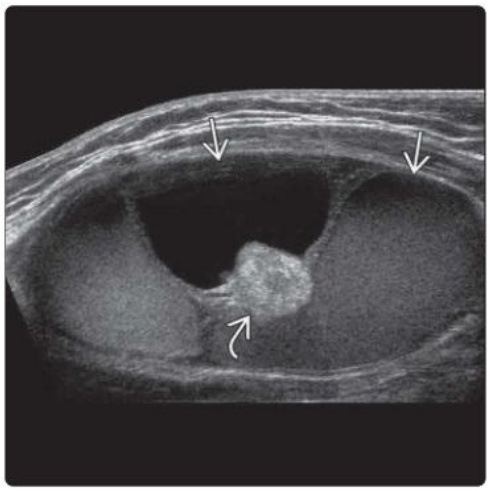

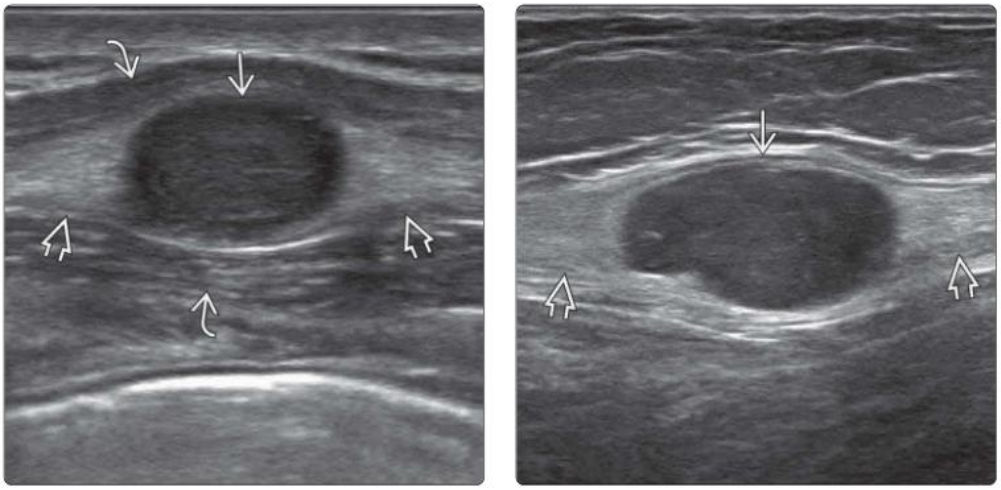

(Left) *Transverse US shows nerve sheath tumor within the pectoralis major muscle. The echogenic fat around the tumor mass could masquerade as a thickened parent nerve.* **(Right)** *Longitudinal US shows nerve sheath tumor within gracilis muscle. The atrophic muscle around the tumor could be wrongly interpreted as a thickened parent nerve.*

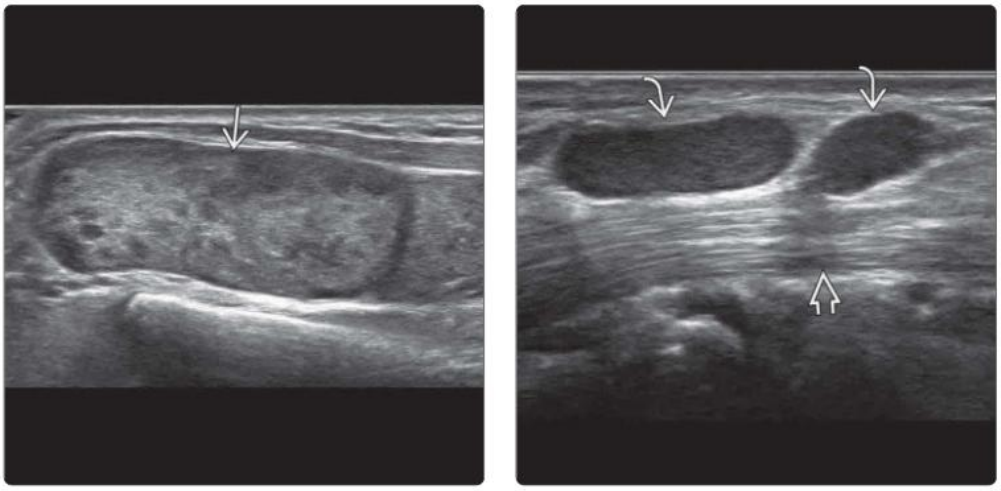

(Left) *Longitudinal US of the forearm shows a nerve sheath tumor (schwannoma) of the ulnar nerve (parent nerve not shown).* **(Right)** *More distal longitudinal US of the same patient shows 2 more nerve sheath tumors of the ulnar nerve (not shown on this image). Schwannomatosis, with > 1 schwannoma affecting the same nerve, is seen uncommonly and most frequently affects the ulnar nerve. The more deeply located flexor tendons are normal.*

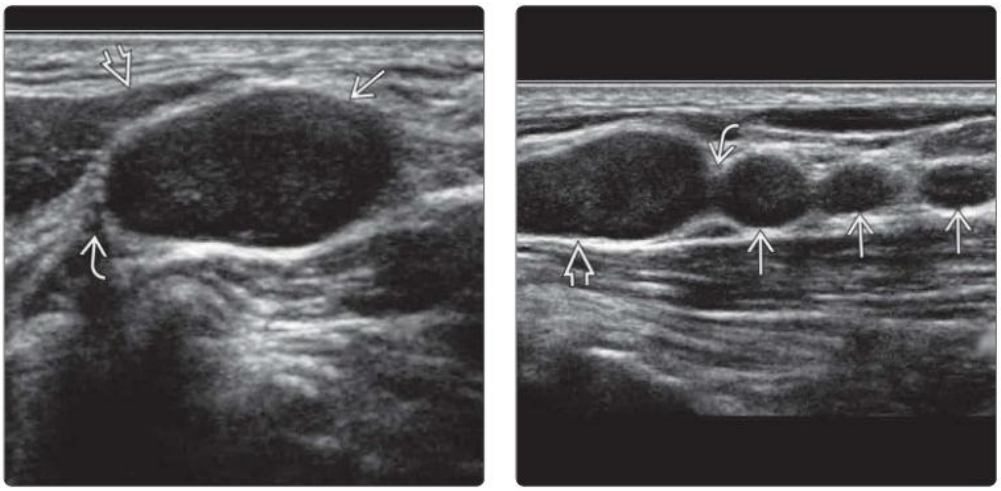

(Left) *Transverse US of a patient with neurofibromatosis type 1 (NF1) shows a well-defined nodule in the neck just deep to the posterior edge of sternocleidomastoid muscle. The nodule is arising from the phrenic nerve, which is better shown in the longitudinal plane.* **(Right)** *Longitudinal US of the same patient shows 3 smaller nodules caudal to the larger nodule shown on previous image. Overall features are compatible with multiple phrenic nerve neurofibromas.*

(Left) *Flow chart shows nerve sheath tumor subtypes. Most neurofibromas are discrete rather than plexiform. Plexiform neurofibromas may be superficial or deep. The diffuse form commonly involves both superficial or deep tissues, while the nodular form tends to occur only in the deep tissues. The diffuse and nodular forms of plexiform neurofibroma often overlap.* **(Right)** *Transverse US of chest wall shows a small, mildly lobulated ➡ nerve sheath tumor, most likely a neurofibroma, overlying the anterior aspect of the rib ➡.*

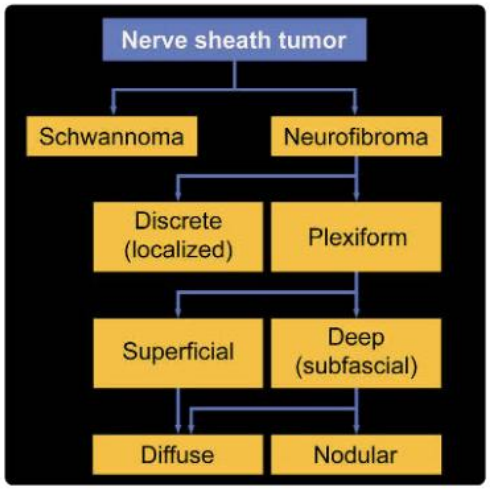

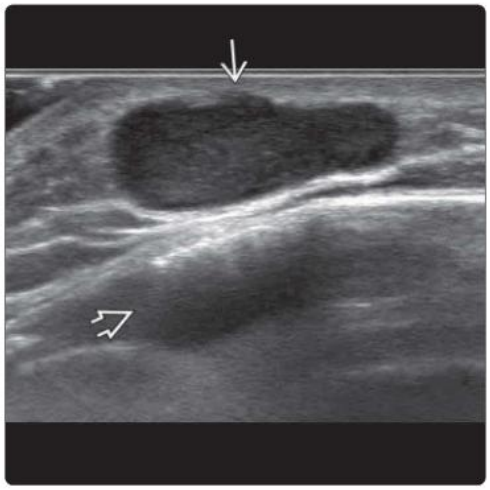

(Left) *Transverse color Doppler US of the same tumor shows mild peripheral hyperemia. Neurofibromas tend to be less vascular than schwannomas.* **(Right)** *Longitudinal US of a 47-year-old woman shows a small, biopsy-proven neurofibroma ➡ in the deeper aspect of the subcutaneous tissues of the thigh. This neurofibroma is quite typical in appearance, except that is it located deeper than usual. Most neurofibromas tend to be located closer to the dermis. No neural continuity is evident.*

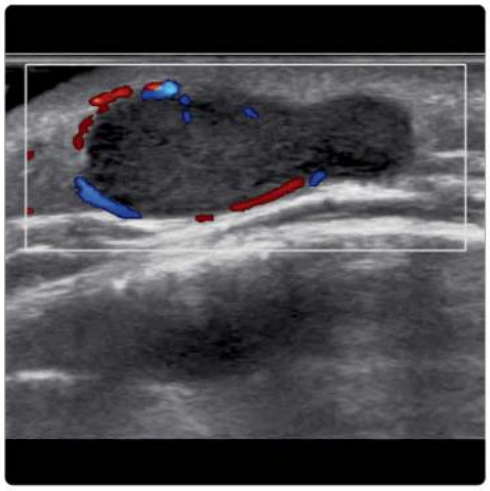

(Left) *Longitudinal US of a 46-year-old man shows a small, biopsy-proven, plaque-like subcutaneous neurofibroma ➡ anterior to the ankle ➡. No vascularity was evident on color Doppler imaging (not shown).* **(Right)** *Transverse US of same area shows that the neurofibroma ➡ is as wide as it is long.*

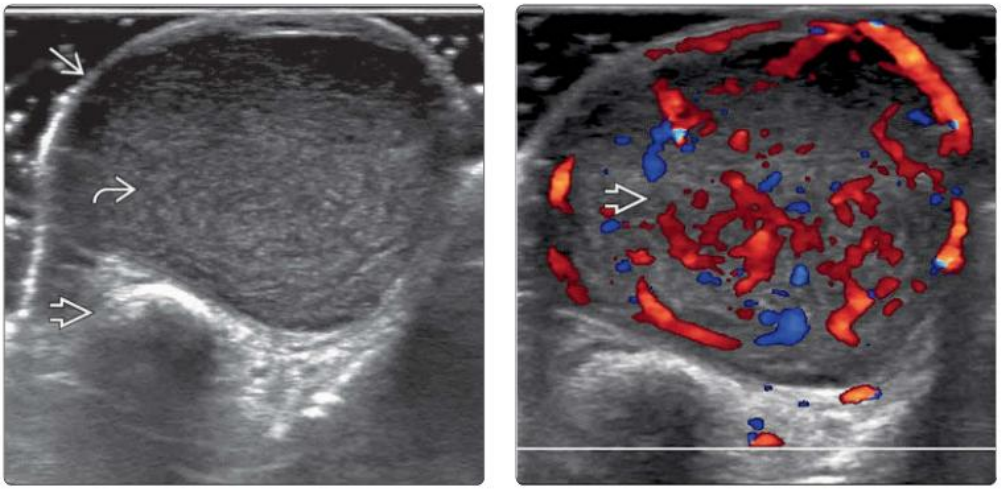

(Left) *Transverse US of the 3rd toe shows a well-defined, round, hypoechoic lesion* ⇨ *with diffuse homogeneous speckles* ⇨. *The lesion is abutting the 3rd metatarsal head* ⇨. **(Right)** *Transverse color Doppler US of the same mass shows marked intrinsic vascularity* ⇨. *Excision confirmed a neurofibroma. This neurofibroma is usually hyperemic.*

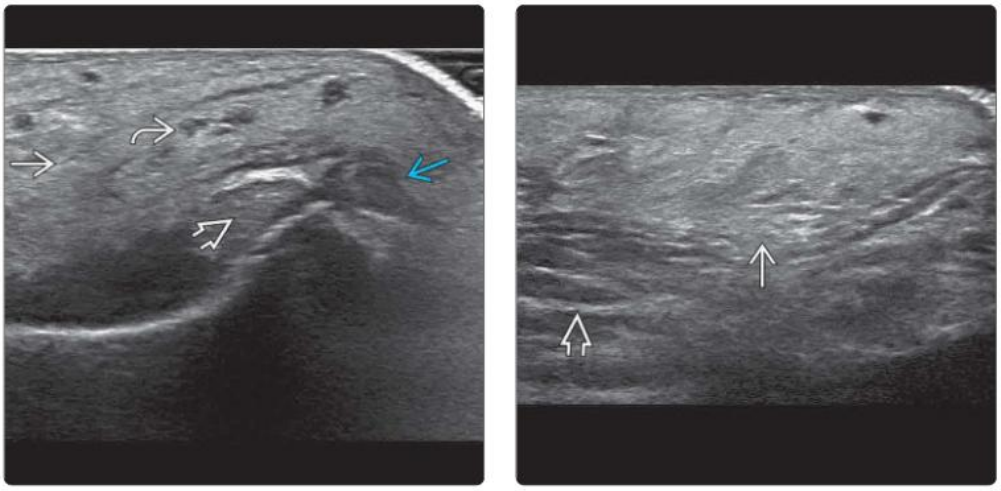

(Left) *Longitudinal US of a 10-year-old boy with lateral ankle swelling shows an ill-defined, hyperechoic, infiltrative area of subcutaneous tissue thickening* ⇨. *The lesion encases small, subcutaneous vessels* ⇨ *as well as the peroneus longus* ⇨ *and brevis* ⇨ *tendons.* **(Right)** *Longitudinal US of an adjacent area in the same case shows an abrupt zone of transition between normal-appearing, hypoechoic subcutaneous fat* ⇨ *and the hyperechoic plexiform neurofibroma tissue* ⇨.

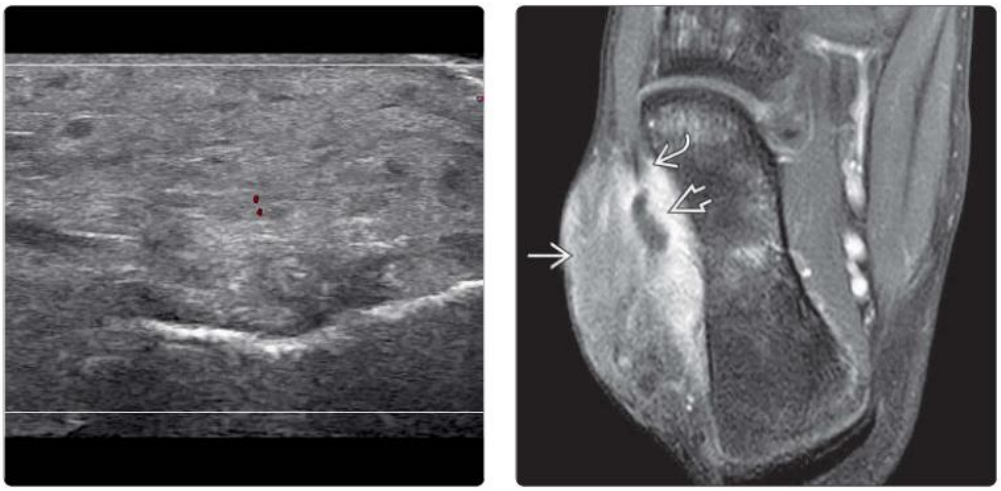

(Left) *Color Doppler US of the same lesion shows minimal vascularity within the lesion. US-guided biopsy confirmed diffuse cutaneous plexiform neurofibroma.* **(Right)** *Axial T1WI C+ FS MR of the same lesion shows avid, plaque-like enhancement on the lateral aspect of the hindfoot* ⇨, *consistent with diffuse neurofibroma. The peroneal longus* ⇨ *and peroneal brevis* ⇨ *tendons are encased corresponding to the US findings.*

(Left) *Transverse US of the occipital region in a teenager shows a poorly defined, infiltrative area of subcutaneous tissue thickening ⇨. No involvement of the posterior neck muscles ⇨ is present.* **(Right)** *Transverse color Doppler US of the same area shows moderate hyperemia ⇨. The appearances are those of an infiltrative diffuse cutaneous plexiform neurofibroma, confirmed by percutaneous biopsy and histology.*

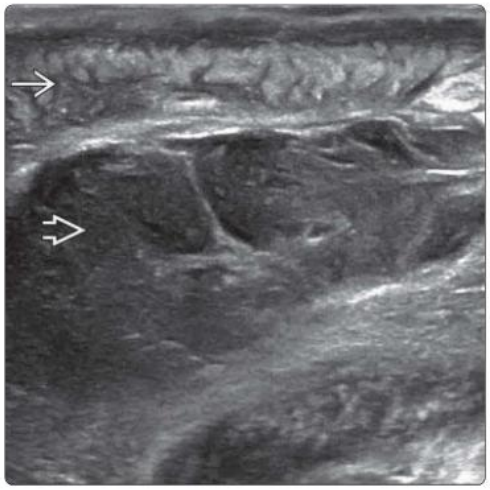

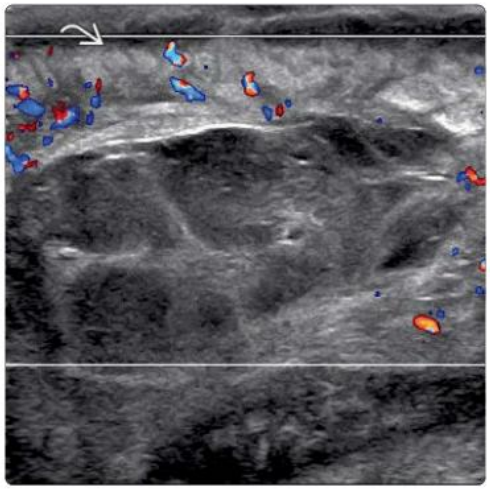

(Left) *Axial T1WI C+ FS MR of the same lesion shows avid, reticular-like subcutaneous enhancement in the right occipital region ⇨ with involvement of the dermis and subdermal tissues, consistent with diffuse cutaneous plexiform neurofibroma.* **(Right)** *Clinical photograph of the foot and ankle of a patient with NF1 shows a localized swelling ⇨ on the dorsum of the mid- and hindfoot with multiple small skin nodules ⇨ due to neurofibromatosis.*

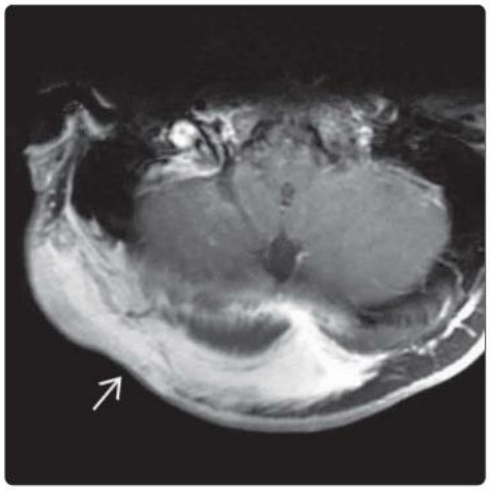

(Left) *Transverse color Doppler US of the dorsal foot swelling shows a diffuse plexiform neurofibroma with moderate intratumoral hyperemia ⇨. The tumor is encasing the extensor hallucis longus tendon ⇨.* **(Right)** *Sagittal T1WI C+ FS MR of the same plexiform neurofibroma shows avid tumoral enhancement ⇨ encasing the extensor hallucis longus tendon ⇨. Plexiform neurofibroma is diagnostic of NF1 and associated with a 10% risk of malignant change.*

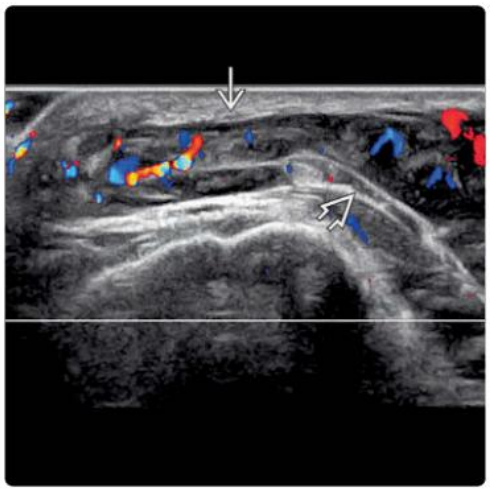

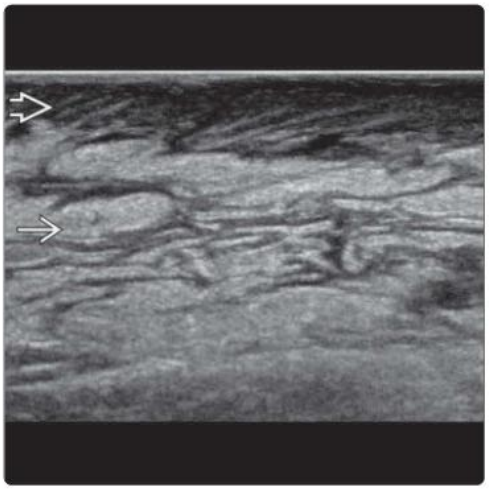

(Left) *Clinical photograph of an 18-year-old woman with known NF1 shows a large mass on the dorsolateral chest wall with café au lait spots and multiple small neurofibromas.* **(Right)** *Transverse US of the mass lesion shows severely thickened dermal and subcutaneous tissue with increased reticulation, compatible with diffuse plexiform neurofibroma.*

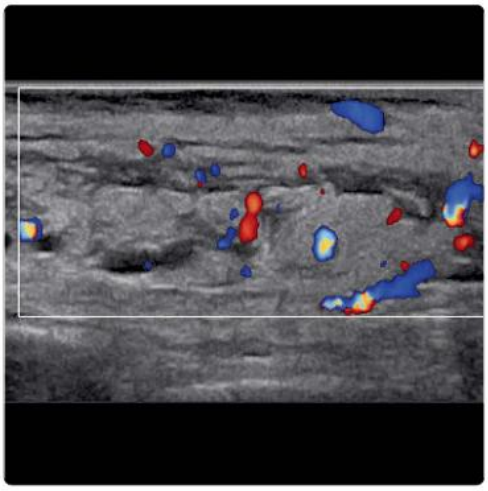

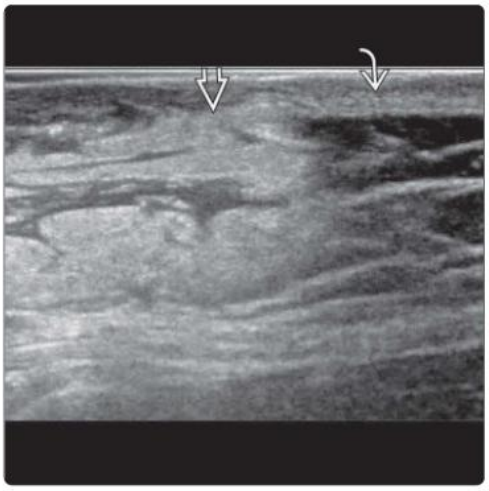

(Left) *Transverse color Doppler US of the same area shows moderate hyperemia. This should not be confused with subcutaneous cellulitis, vascular malformation, or lymphoma.* **(Right)** *Transverse US at the edge of the mass lesion shows the abrupt transition between thickened hyperechoic diffuse plexiform neurofibroma tissue and normal hypoechoic subcutaneous fat.*

(Left) *Clinical photograph of a patient known to have a large nerve sheath tumor at the distal end of the leg anteriorly is shown. As the mass was enlarging, a site had been marked for percutaneous biopsy.* **(Right)** *Transverse US of the same mass shows a large tumor with central hyperechogenicity, most likely due to dense fibrous tissue.*

(Left) *Transverse color Doppler US of another area of the same tumor shows mild hyperemia with a central area of myxoid degeneration* ➡. **(Right)** *Transverse T2WI FS MR of the same tumor shows large, lobulated masses, each displaying a target sign with a more centralized hypointense fibrous component* ➡ *and a more peripheral hyperintense myxoid component* ➡. *There is also an area of myxoid degeneration* ➡. *Biopsy revealed schwannoma with no evidence of malignancy.*

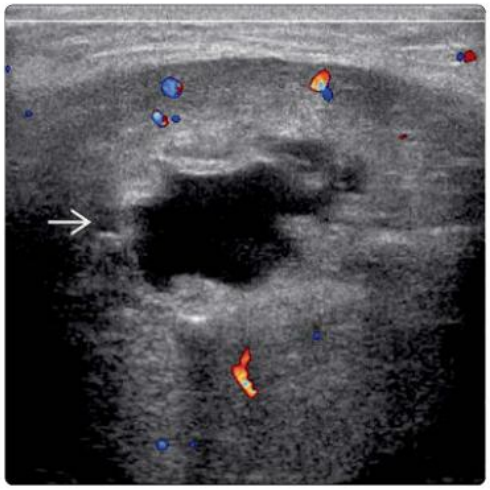

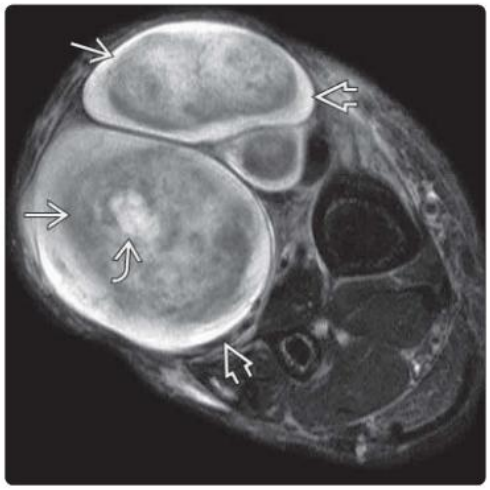

(Left) *Transverse US of a young patient with posterior thigh swelling shows a severely thickened hypoechoic sciatic nerve* ➡ *at the level of the ischial tuberosity* ⇨ *and proximal femur* ⇨. **(Right)** *Longitudinal US of the same sciatic nerve* ➡ *shows it to be diffusely and severely thickened with loss of the normal fibrillar pattern.*

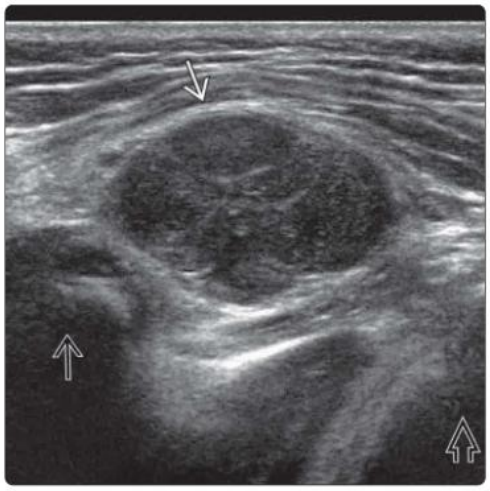

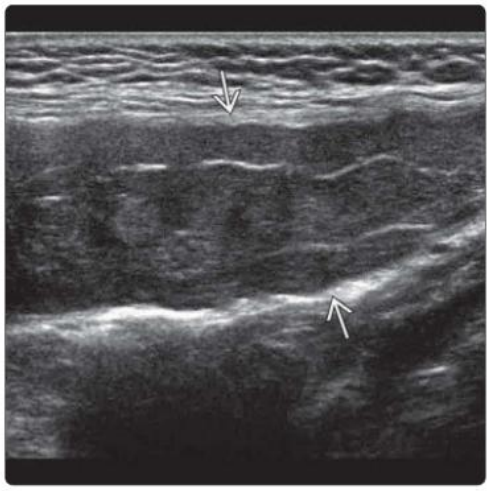

(Left) *Transverse color Doppler US of the same thickened sciatic nerve shows minimal intralesional hyperemia. Small intratumoral echogenic foci* ➡ *with acoustic shadowing are present, which are most likely due to intraneural calcification.* **(Right)** *Axial T1WI MR of the same lesion shows the thickened isointense sciatic nerve* ➡. *There is a thin rim of hyperintense fat* ➡ *surrounding the tumor. There is no local invasion. This child was otherwise well with no features of NF1.*

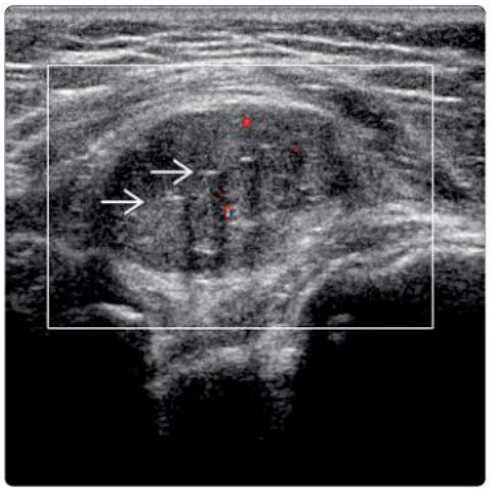

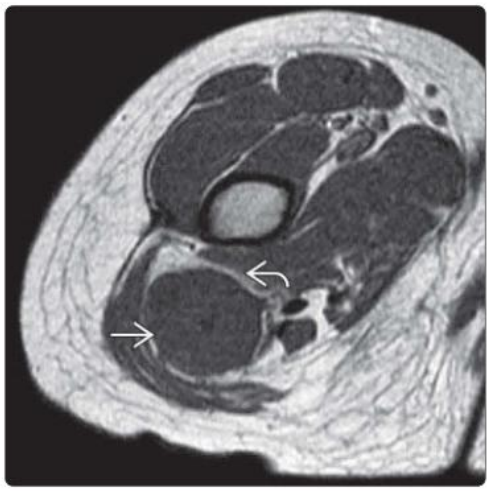

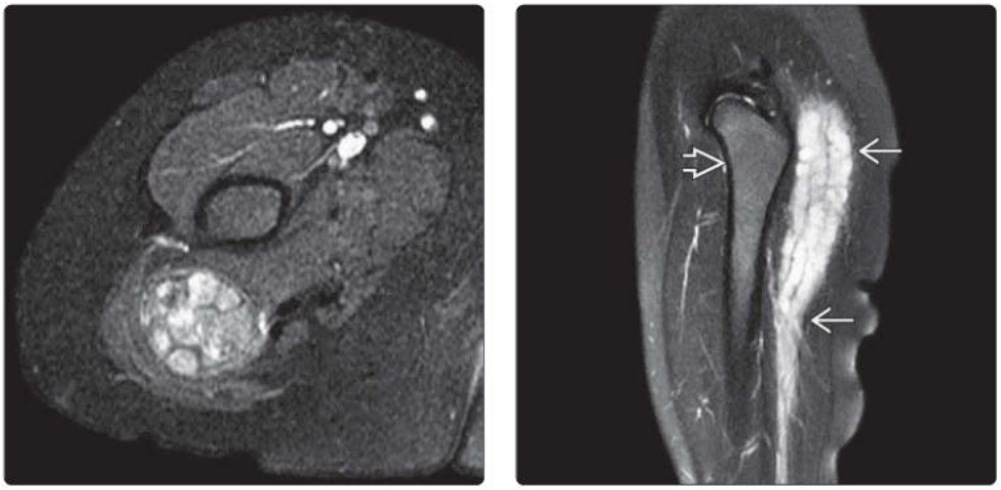

(Left) *Transverse T1WI C+ FS MR of the same lesion shows moderate intratumoral contrast enhancement. The fascicular appearance of the tumor can be more readily appreciated than on T1 images.* **(Right)** *Sagittal T2WI FS MR of the same lesion shows severe, diffuse sciatic nerve enlargement ⇨ posterior to femur ⇨, consistent with a nerve sheath tumor. Pathology revealed a malignant nerve sheath tumor. Benign and malignant nerve sheath tumors share similar imaging features.*

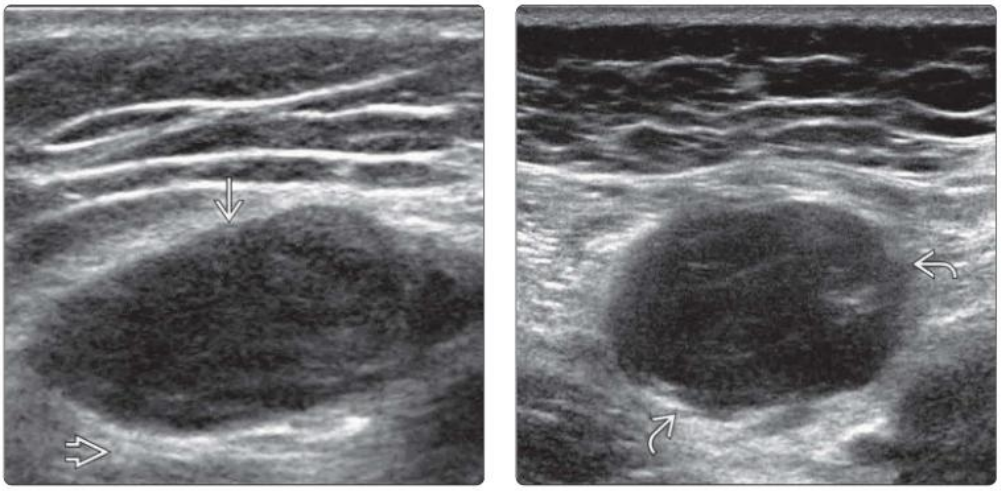

(Left) *Longitudinal US shows a fusiform hypoechoic nerve sheath tumor ⇨ of the radial nerve in the posterior arm region. There is moderate posterior acoustic enhancement ⇨.* **(Right)** *Transverse US of the same tumor shows a slightly irregular tumor border ⇨. Clinically, the mass was enlarging, so a follow-up US examination was arranged for 6 months later. There were no clinical features of NF1.*

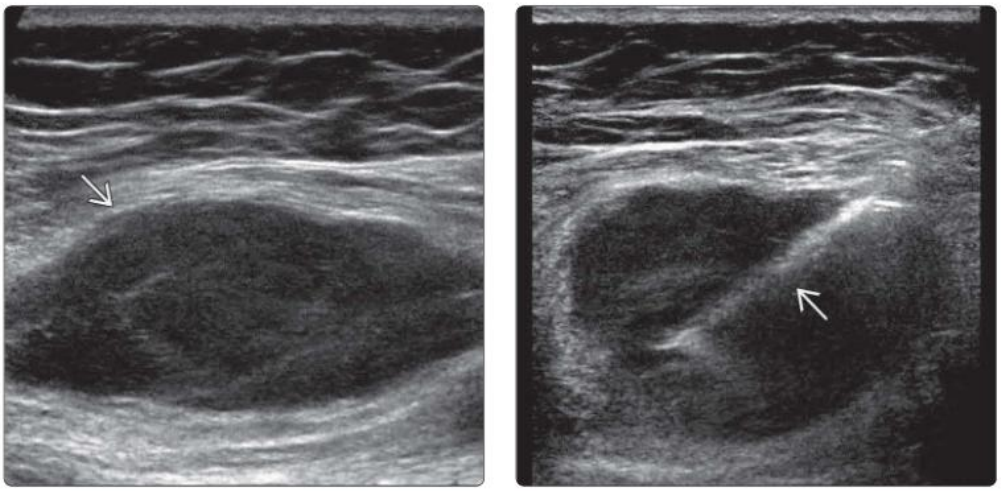

(Left) *Follow-up longitudinal US of the same tumor ⇨ 6 months later shows mild to moderate interval increase in tumor size.* **(Right)** *Even benign nerve sheath tumors will grow, but rapid, irregular growth is an indicator of malignant transformation. The tumor was biopsied ⇨, and histology revealed a malignant peripheral nerve sheath tumor.*

KEY FACTS

IMAGING

- **Intravascular papillary endothelial hyperplasia**
  - Organizing thrombus with excessive reactive papillary endothelial proliferation
  - Predilection for subcutaneous tissues of extremities, particularly upper limbs
  - Focal vascular dilatation with intraluminal mass
    - Hypoechoic compared with subcutaneous fat
    - Hyperechoic septum (70%)
    - Little or no color flow (30%); moderate (40%); high color flow (30%)
- **Superficial thrombophlebitis**
  - Thrombosed vein surrounded by halo of hyperechoic edematous subcutaneous fat; ± perivascular hyperemia
- **Venous varix**
  - Focal dilatation of vein
- **Intravascular organized hematoma**
  - Focal hypoechoic to hyperechoic lesion within lumen
    - i.e., hematoma-like lesion within vein
    - No flow on color Doppler imaging
- **Pseudoaneurysm**
  - Hypoechoic or anechoic perivascular mass
    - Neck connects artery → pseudoaneurysm lumen
    - Characteristic to-&-fro flow pattern at neck of pseudoaneurysm
    - Yin-yang sign within lumen
- **Arteriovenous fistula**
  - Abnormal high-velocity connection between artery & adjacent vein
- **Kimura disease**
  - More common in Asians
  - Fusiform-shaped hypoechoic tumor of arterial wall
    - Variable intratumoral hyperemia

DIAGNOSTIC CHECKLIST

- US is best imaging modality for all focal vascular abnormalities, provided vessel is accessible

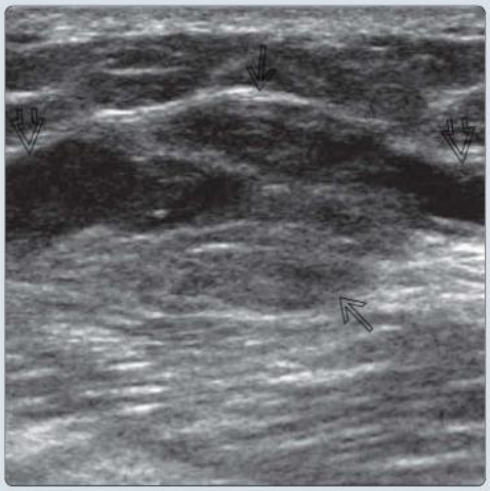

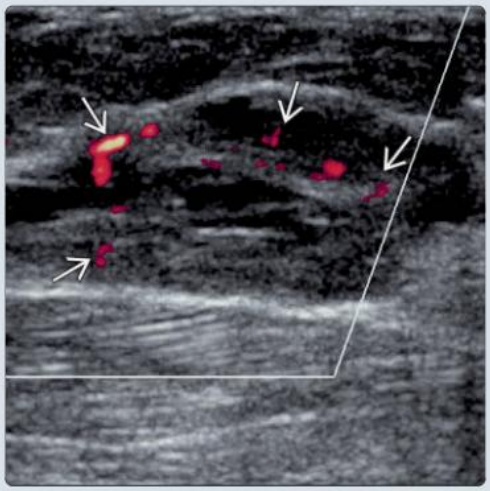

(Left) *Longitudinal US shows focal dilatation of the short saphenous vein ⇨ in the popliteal fossa. There is a mildly hypoechoic mass ⇨ and septum within and around the dilated vein.* **(Right)** *Longitudinal power Doppler US of the same patient shows mild internal vascularity ⇨ within the septum and mass. These appearances are consistent with intravascular papillary endothelial hyperplasia.*

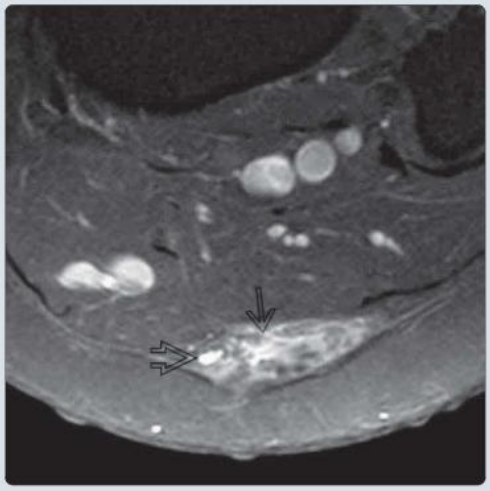

(Left) *Sagittal T1 C+ FS MR of the same area shows focal dilatation ⇨ of the short saphenous vein ⇨. The vascular and perivascular tumor component shows heterogeneous contrast enhancement ⇨. Excision biopsy revealed Masson tumor (intravascular papillary endothelial hyperplasia).* **(Right)** *Axial T1W C+ FS MR of the same area shows heterogeneous tumor enhancement ⇨. The mass arises eccentrically from the short saphenous vein ⇨.*

TERMINOLOGY

Synonyms

- **Intravascular papillary endothelial hyperplasia (IPEH)**: Masson tumor, Masson hemangioma, intravascular angiomatosis, vegetant intravascular hemangioendothelioma
- **Pseudoaneurysm**: False aneurysm

Definitions

- **IPEH**
  - Organizing thrombus with excessive reactive papillary endothelial proliferation
- **Superficial thrombophlebitis**
  - Inflammation of superficial vein
- **Venous varix**
  - Focal dilatation of vein
- **Intravascular organized hematoma**
  - Organized hematoma within vessel, usually vein
- **Pseudoaneurysm**
  - Luminal outpouching of artery with
    - Full-thickness wall defect with bleeding contained by hematoma & surrounding soft tissues
    - Less commonly, due to defect in tunica intima & media with preservation of adventitia
- **Arteriovenous fistula**
  - Abnormal communication between artery & vein
- **Kimura disease**
  - Inflammatory response associated with self-limiting allergic or autoimmune reaction to unknown stimulus

IMAGING

General Features

- Location
  - **IPEH**: Usually within vein; rarely within artery
    - Predilection for subcutaneous tissues of extremities, particularly upper limbs
  - **Superficial thrombophlebitis**
    - Superficial vein, upper or lower limbs
  - **Venous varix**: Most commonly in superficial vein
  - **Intravascular organized hematoma**: Any vessel, most commonly within vein
  - **Pseudoaneurysm**: Arises from punctured wall of artery
    - Frequency affects common femoral or radial arteries related to iatrogenic needle puncture
  - **Kimura disease**: Most commonly involves head & neck region

CT Findings

- **Pseudoaneurysm**: Arterial enhancement of cavity
  - Contrast extravasation indicates pseudoaneurysm rupture
  - CT reconstruction is useful for delineation of anatomy & assessing suitability for intervention

MR Findings

- **IPEH**
  - T1WI: Isointense mass with node-like hyperintense foci
  - T2WI: Heterogeneous hyperintense mass with node-like hypointense foci
- **Intravascular organized hematoma**
  - Signal intensity depends on age of hematoma
- **Pseudoaneurysm**
  - T1WI
    - Pseudoaneurysm luminal flow void
    - High signal in methemoglobin-containing portions of surrounding hematoma
  - MRA
    - Contrast-enhanced MRA preferred to time-of-flight or phase-contrast technique because of superior signal:noise ratio

Ultrasonographic Findings

- **IPEH**
  - Focal, oblong-shaped vascular dilatation with intraluminal mass
    - Detectable vessel of origin only seen in 40%
  - Mass hypoechoic compared with subcutaneous fat
    - Acoustic enhancement (100%)
    - Hyperechoic septum (70%)
      - Possibly reflecting thickening of venous valve
  - Color Doppler imaging
    - Septal & peripheral vascularity
    - Minimal or absent color flow (30%); moderate (40%); high color flow (30%)
- **Superficial thrombophlebitis**
  - Thrombosed vein with thickened vein wall
  - Halo of edematous hyperechoic subcutaneous fat
  - ± perivascular hyperemia
- **Venous varix**
  - Focal, easily compressible, saccular or fusiform dilatation of vein ± low-level internal echoes due to slow or turbulent flow
- **Intravascular organized hematoma**
  - Focal hypoechoic to hyperechoic lesion within vascular lumen (i.e., hematoma-like lesion within vein)
    - Mild to moderate vascular dilatation
    - No color flow on color Doppler imaging
- **Pseudoaneurysm**
  - Hypoechoic or anechoic, perivascular, saccular-shaped mass
  - Neck connects artery → pseudoaneurysm
  - Spectral Doppler imaging
    - Characteristic to-&-fro flow pattern at neck of pseudoaneurysm
    - ± turbulent, high-velocity flow if neck is narrowed
    - Flow can sometimes be seen only in pseudoaneurysm neck & not in lumen (if lumen thrombosed)
  - Color Doppler imaging
    - Yin-yang sign within lumen of pseudoaneurysm, a.k.a. Pepsi sign
      - Bidirectional swirling flow → different color signals within lumen
      - Not pathognomonic of pseudoaneurysm
      - May be seen less commonly in aneurysm with bidirectional flow or false lumen
      - Visible neck with to-&-fro flow more specific for diagnosis of pseudoaneurysm
- **Arteriovenous fistula**
  - Abnormal, high-velocity connection between artery & adjacent vein
  - Arterialization ± enlargement of vein draining fistula

- **Kimura disease**
  - Tumor arising from arterial wall
    - Fusiform-shaped, hypoechoic arterial wall thickening
      - Variable flow in thickened arterial wall on color Doppler imaging

Imaging Recommendations

- Best imaging tool
  - US for all focal vascular abnormalities, provided vessel is accessible
- Protocol advice
  - **IPEH**
    - Tourniquet application is useful if arising from vein to maximize venous distension & optimally show intraluminal content
  - **Superficial thrombophlebitis**
    - Valsalva maneuver or compression augmentation can help with flow detection

DIFFERENTIAL DIAGNOSIS

Angiosarcoma or Kaposi Sarcoma

- Rarely confined to vascular wall or lumen

Angiolymphoid Hyperplasia

- Histology similar to Kimura disease
- Eosinophilia less prevalent than in Kimura disease
- IgE level is normal

PATHOLOGY

General Features

- Etiology
  - **IPEH**
    - Macrophage-derived basic fibroblast growth factor (bFGF) stimulates papillary proliferation of plump endothelial cells, which release more bFGF
      - Anomalous thrombus organization rather than primary vascular tumor
      - Less commonly arises in vascular anomaly; rarely in hematoma
      - 0.5-2.0 cm
  - **Superficial thrombophlebitis**
    - Preexisting deep venous thrombosis or cellulitis
    - Recent cannulation
  - **Venous varix**
    - Valvular incompetence, varicose veins, previous trauma or surgery
  - **Intravascular organized hematoma**
    - Previous trauma
  - **Pseudoaneurysm**
    - Usually acquired; iatrogenic or traumatic needle puncture
  - **Arteriovenous fistula**
    - Usually acquired; iatrogenic or traumatic needle puncture
  - **Kimura disease**
    - Immunologically mediated disorder

Microscopic Features

- **IPEH**
  - Papillary projections composed of plump endothelial cells within fibrinous matrix & dilated vascular spaces
    - Microthrombi in various stages of organization
- **Kimura disease**
  - Eosinophilic infiltration with microabscesses
  - Well-developed lymphoid follicles

CLINICAL ISSUES

Presentation

- Most common signs/symptoms
  - **IPEH**
    - Slowly growing palpable lesion, often with bluish or reddish discoloration of overlying skin ± pain
  - **Superficial thrombophlebitis**
    - Swollen, tender area with increased warmth
  - **Venous varix**
    - Palpable, soft, fully compressible mass
  - **Intravascular organized hematoma**
    - Painful palpable lesion along course of vein
  - **Pseudoaneurysm**
    - Increased swelling, which may be pulsatile, at site of needle puncture, surgery, or trauma
  - **Kimura disease**
    - Painless subcutaneous mass

Demographics

- Ethnicity
  - **Kimura disease**
    - More common in Asians

Treatment

- **IPEH**
  - Complete surgical excision
- **Superficial thrombophlebitis**
  - Antiinflammatory agents or heat therapy
- **Venous varix**
  - Pressure garment or surgery
- **Intravascular organized hematoma**
  - Conservative treatment
- **Pseudoaneurysm**
  - US-guided compression
    - Success rate: 90%
  - US-guided thrombin injection
  - Percutaneous transarterial embolization or covered stenting
  - Direct surgical repair or bypass surgery
- **Arteriovenous fistula**
  - Percutaneous catheter embolization or surgery
- **Kimura disease**
  - Surgical excision

DIAGNOSTIC CHECKLIST

Consider

- US best imaging modality for focal vascular abnormalities, provided vessel is accessible

SELECTED REFERENCES

1. Damadian BE et al: I saw the sign: he felt a pang and we saw the Yin-Yang (sign). Clin Imaging. 107:110087, 2024

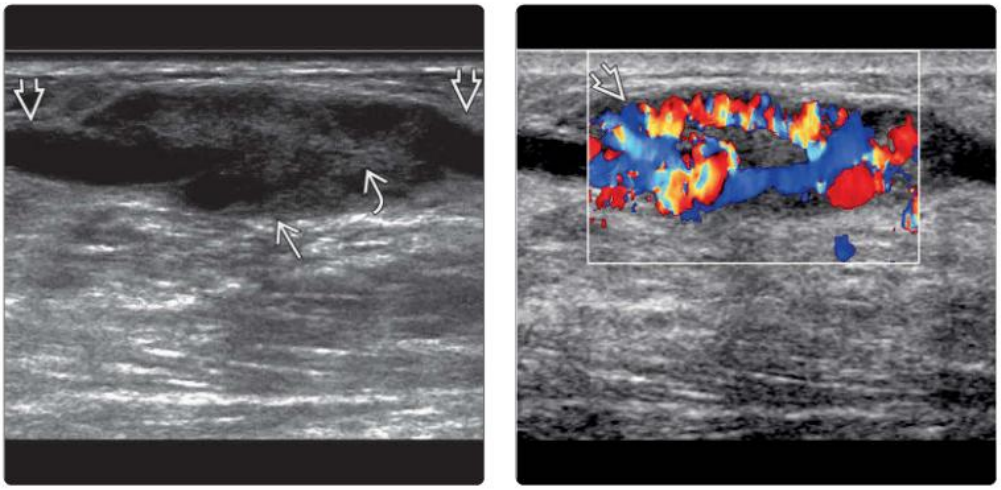

(Left) *Longitudinal US shows a focally dilated ⇨, long saphenous vein ⇨ on the medial aspect of the thigh. There is a mildly hypoechoic tumor ⇨ and septation within the dilated vein, compatible with a histologically proven Masson tumor (intravascular papillary endothelial hyperplasia).* **(Right)** *Longitudinal color Doppler US of the same tumor shows marked tumoral vascularity ⇨. This color flow helps differentiate intravascular papillary endothelial hyperplasia from intravascular thrombosis.*

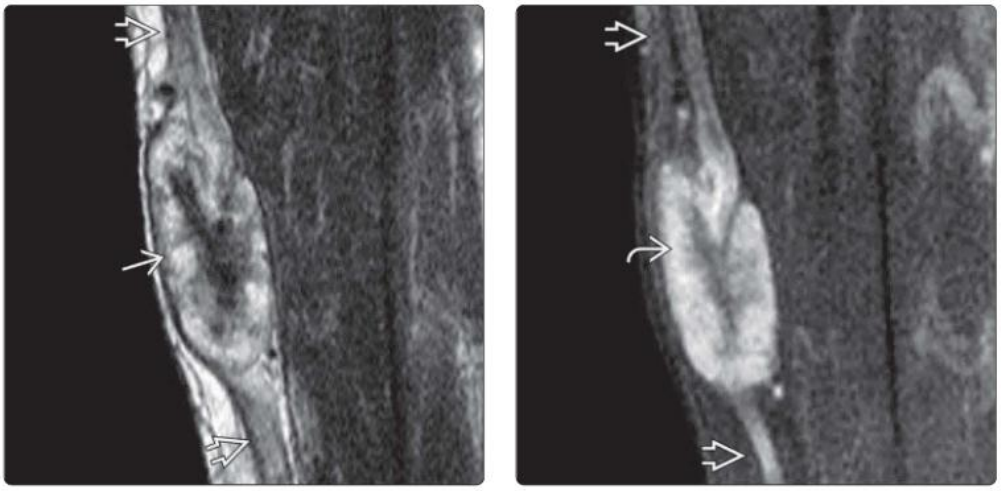

(Left) *Sagittal T2 MR of the same tumor shows the fusiform-shaped, dilated, long saphenous vein ⇨ filled with a heterogeneously hyperintense tumor ⇨.* **(Right)** *Sagittal T1 C+ FS MR of the same tumor shows homogeneous enhancement ⇨ of the Masson tumor within the long saphenous vein ⇨. This enhancement is compatible with the hyperemia seen on color Doppler imaging.*

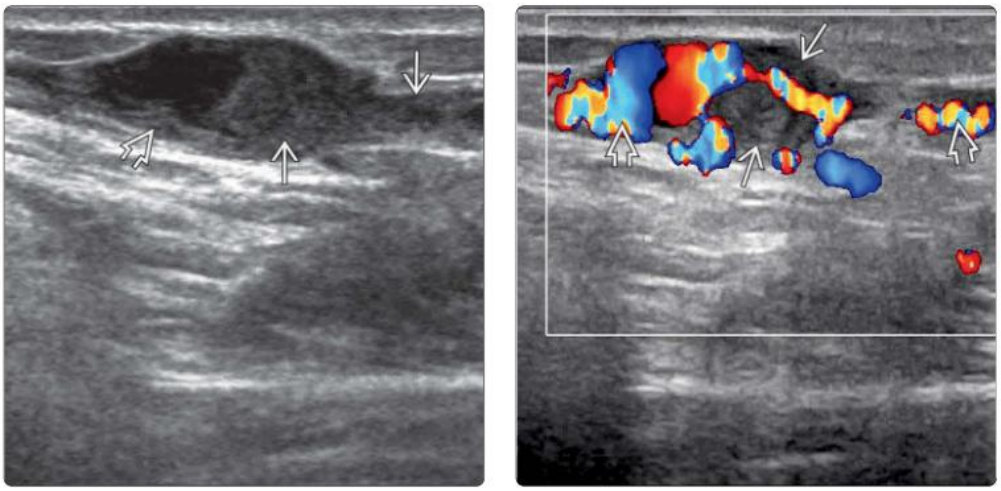

(Left) *Longitudinal US shows focal dilatation ⇨ of the short saphenous vein on the medial aspect of the knee. The dilated vein and proximal venous segment are partially filled with mildly hypoechoic tissue ⇨. Histology confirmed a Masson tumor (intravascular papillary endothelial hyperplasia).* **(Right)** *Longitudinal color Doppler US of the same tumor shows no tumoral vascularity ⇨, which is an atypical feature. There is flow ⇨ within the short saphenous vein.*

(Left) *Clinical photograph shows moderate erythema ➡ and mild swelling of the midforearm with a small puncture ➡ wound following removal of an intravenous catheter.* **(Right)** *Transverse US at the same location shows thrombosis of a mildly distended cephalic vein ➡ with moderate surrounding subcutaneous soft tissue edema ➡. There is echogenic thrombus filling the distended vein. A nonthrombosed subcutaneous vein ➡ is also shown.*

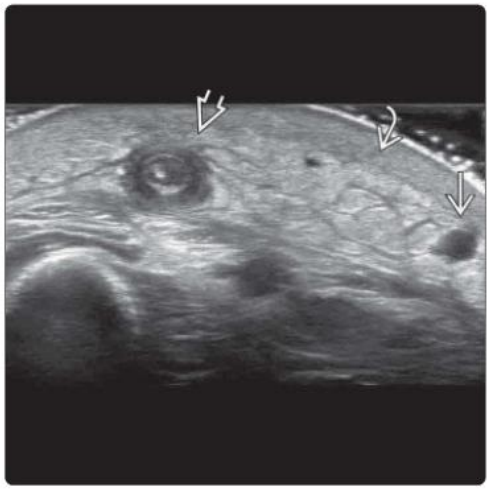

(Left) *Longitudinal US at the same location shows a thickened proximal cephalic vein ➡ with echogenic thrombus filling the lumen. The more distal, nonthrombosed portion of the vein ➡ is shown (as are the normal investing fascia ➡ and muscle, deep to the area of superficial thrombophlebitis).* **(Right)** *Longitudinal color US along the same cephalic vein shows moderate mural ➡ and perivenous ➡ hyperemia, indicative of perivascular inflammation. The lumen ➡ of the more distal venous segment is patent.*

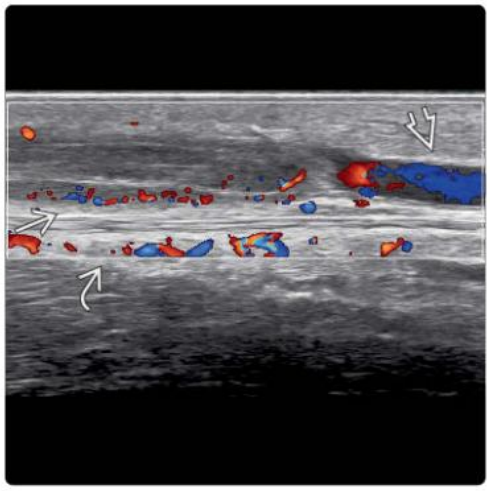

(Left) *Clinical photograph of the leg shows erythema and swelling ➡, which had developed over the previous week around the site of the subcutaneous lipoma excision ➡ performed 1 year earlier.* **(Right)** *Longitudinal US of the same area shows mild subcutaneous vein dilatation ➡ with moderate adjacent subcutaneous edema ➡ and hyperemia (not shown), indicative of cellulitis. As the inflammation is not centered around the vein, this is subcutaneous cellulitis rather than primary superficial thrombophlebitis.*

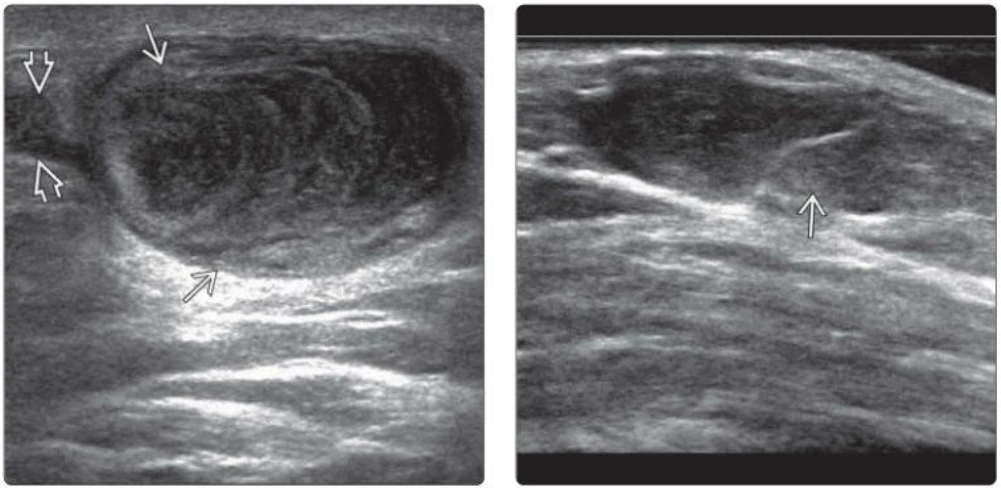

(Left) *Longitudinal US shows an organized intravascular hematoma ⇨ on the volar aspect of the elbow. The hematoma causes focal dilatation of the superficial vein ⇨.* **(Right)** *Longitudinal color Doppler US shows an intravascular organized hematoma ⇨ within the long saphenous vein in the thigh. No vascularity was evident within the hematoma on color Doppler US (not shown).*

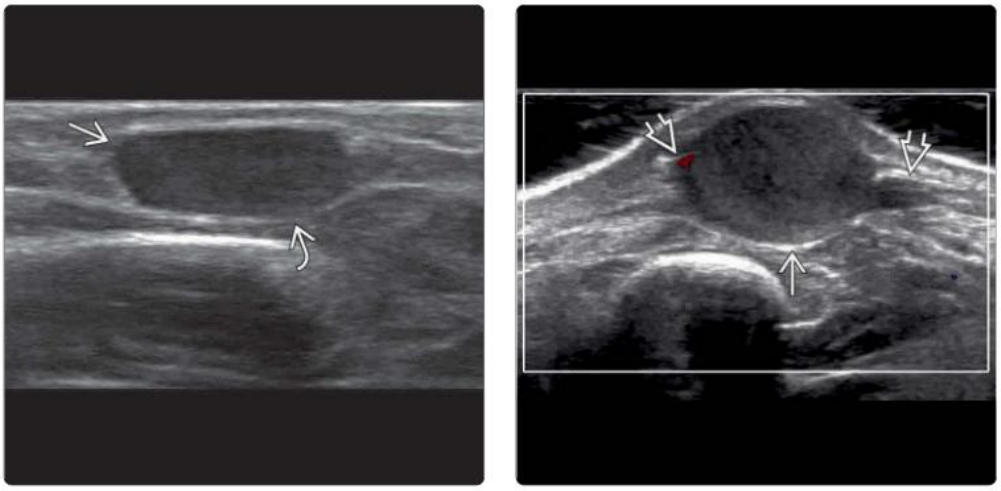

(Left) *Longitudinal US shows a fusiform-shaped subcutaneous slow-flow venous varix ⇨ on the dorsum of the foot. There is partially stagnant flow ⇨ within the varix, which mimics a hypoechoic mass. The mass was fully compressible (not shown).* **(Right)** *Transverse US of the same area shows how the venous varix ⇨ is continuous with a superficial vein ⇨ on the dorsum of the foot. Note use of copious acoustic jelly with minimal transducer pressure to avoid compression and enable demonstration of venous continuity.*

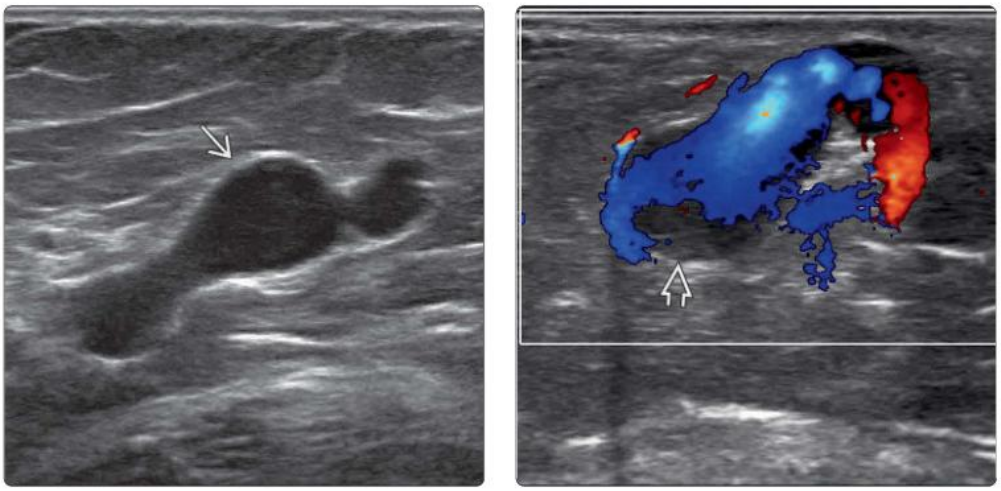

(Left) *Longitudinal US shows a multilobulated irregular venous outpouching ⇨ of the long saphenous vein extending from the femoral triangle to the midthigh region, consistent with a segmental venous varix.* **(Right)** *Transverse color Doppler US of the same area without compression confirms the presence of venous flow within this lobulated venous varix. Mildly echogenic content ⇨ represents sluggish blood flow with rouleaux formation of RBCs.*

(Left) *Longitudinal US of an intravenous drug user with antecubital fossa swelling shows focal aneurysmal dilatation ➡ of the brachial artery ➡, deep to a wide granulation tissue tract from a repeated heroin injection ➡.* **(Right)** *Color Doppler US of same brachial artery shows the yin-yang sign, indicating bidirectional flow within the lumen. As no luminal neck was present, these appearances were compatible with an aneurysm rather than a pseudoaneurysm. Mild surrounding subcutaneous edema ➡ is present.*

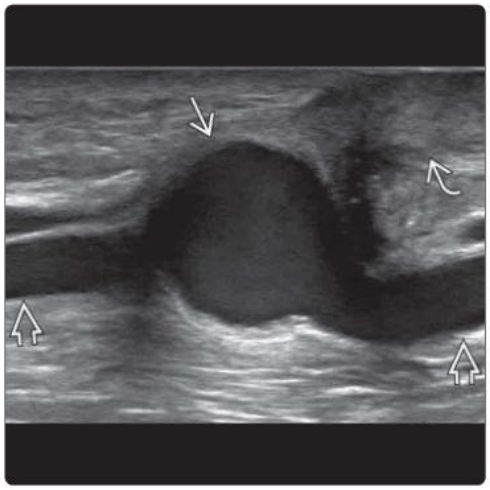

(Left) *Lateral radiograph shows soft tissue swelling ➡ on the posterior aspect of the distal thigh with an osteochondroma ➡ in the metaphysis of the distal femur. Malignant transformation was suspected clinically.* **(Right)** *Transverse power Doppler US of the same patient shows a large pseudoaneurysm ➡ arising from the superficial femoral artery with swirling color flow (yin-yang sign) within the lumen and to-and-fro arterial flow ➡ at the neck of the pseudoaneurysm.*

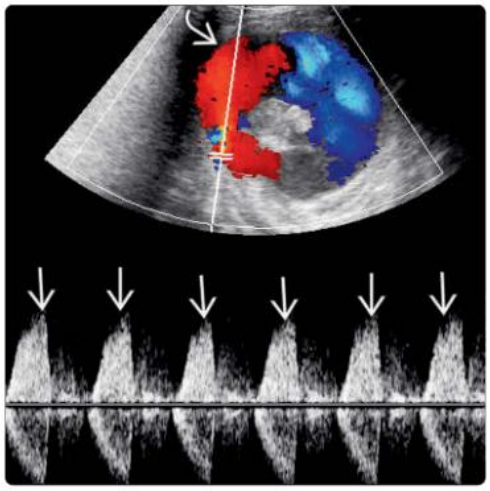

(Left) *Anteroposterior digital subtraction angiography (DSA) in the same patient shows the pseudoaneurysm ➡ arising from a displaced and narrowed superficial femoral artery ➡. Angiographic embolization was subsequently performed.* **(Right)** *Anteroposterior DSA of the same lesion following embolization shows complete obliteration of the pseudoaneurysm by embolization coils ➡.*

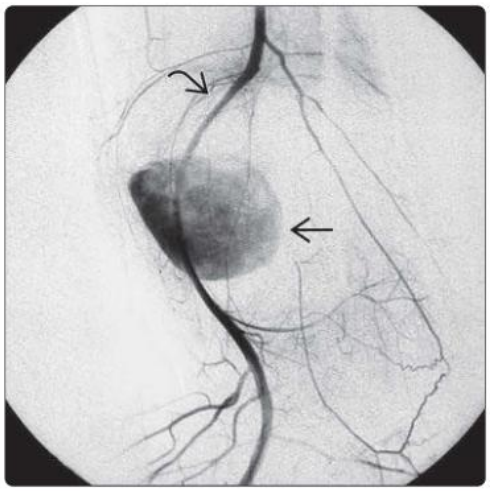

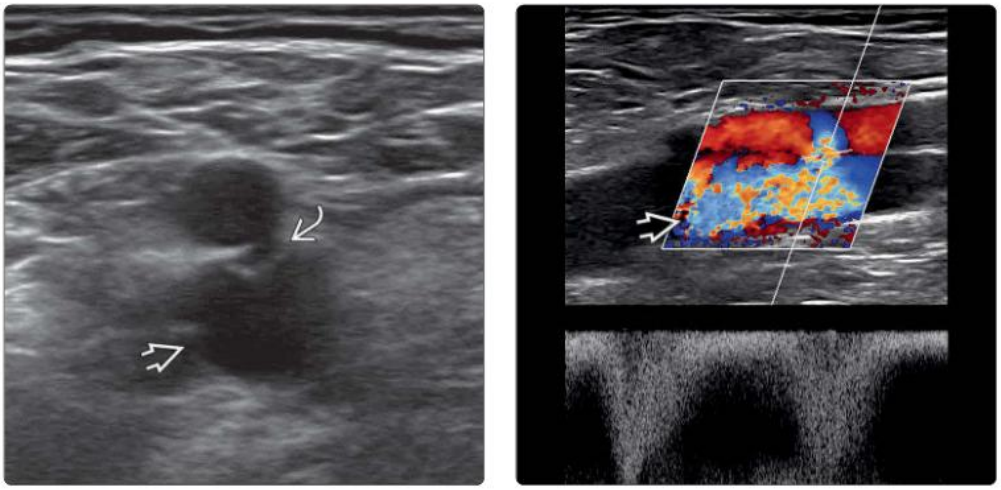

(Left) *Transverse US of the groin region shows a small communication ⇨ between the superficial femoral artery and the common femoral vein due to a small arteriovenous fistula. The vein ⇨ is moderately distended.* **(Right)** *Longitudinal color Doppler US of the same patient shows turbulent, very high-velocity flow (up to > 400cm/s) within both the proximal common femoral vein ⇨ and at the fistula site.*

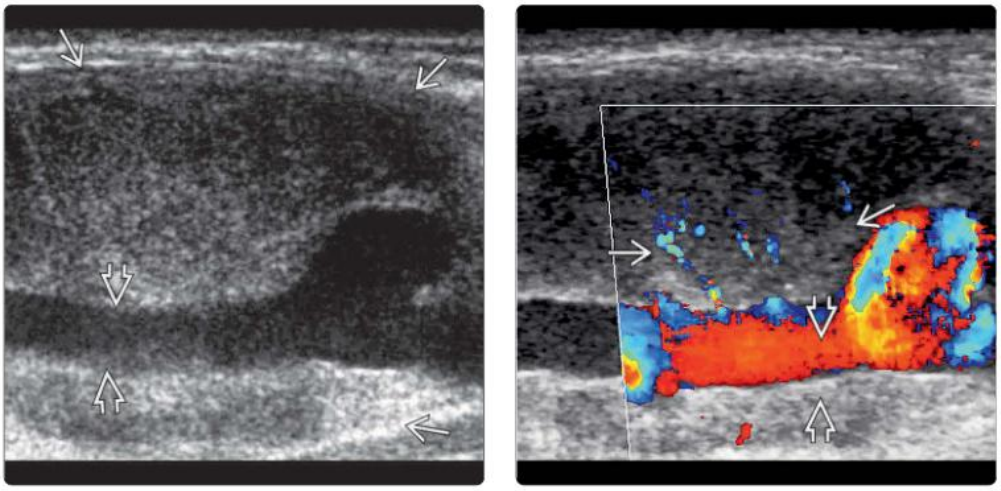

(Left) *Longitudinal oblique US shows a thick hypoechoic mass ⇨ arising from the arterial wall of the proximal brachial artery ⇨.* **(Right)** *Longitudinal oblique color Doppler US shows mild internal vascularity ⇨ of the hypoechoic mass supplied by arterioles arising from the brachial artery lumen ⇨. US-guided percutaneous biopsy of the arterial wall revealed Kimura disease.*

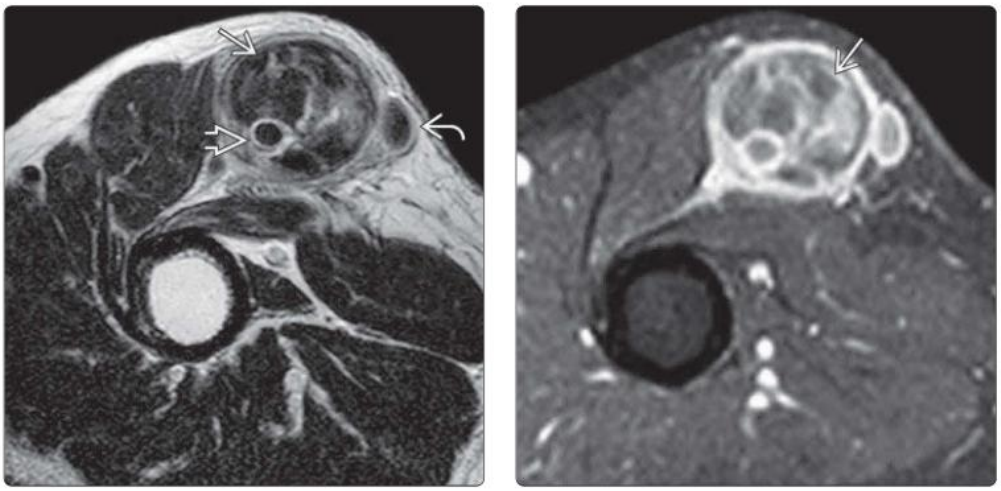

(Left) *Axial T2 MR of the same patient shows a heterogeneous hypointense mass ⇨ due to Kimura disease arising largely eccentrically from the wall of the brachial artery ⇨. The brachial vein ⇨ is normal.* **(Right)** *Axial T1 C+ FS MR of the same patient shows mild heterogeneous enhancement of the Kimura disease mass ⇨. Segmental brachial artery excision was performed followed by arterial repair.*

PART III
SECTION 5

Infection

Soft Tissue Infection	636
Bone Infection	644
Joint Infection	654
Postoperative Infection	660

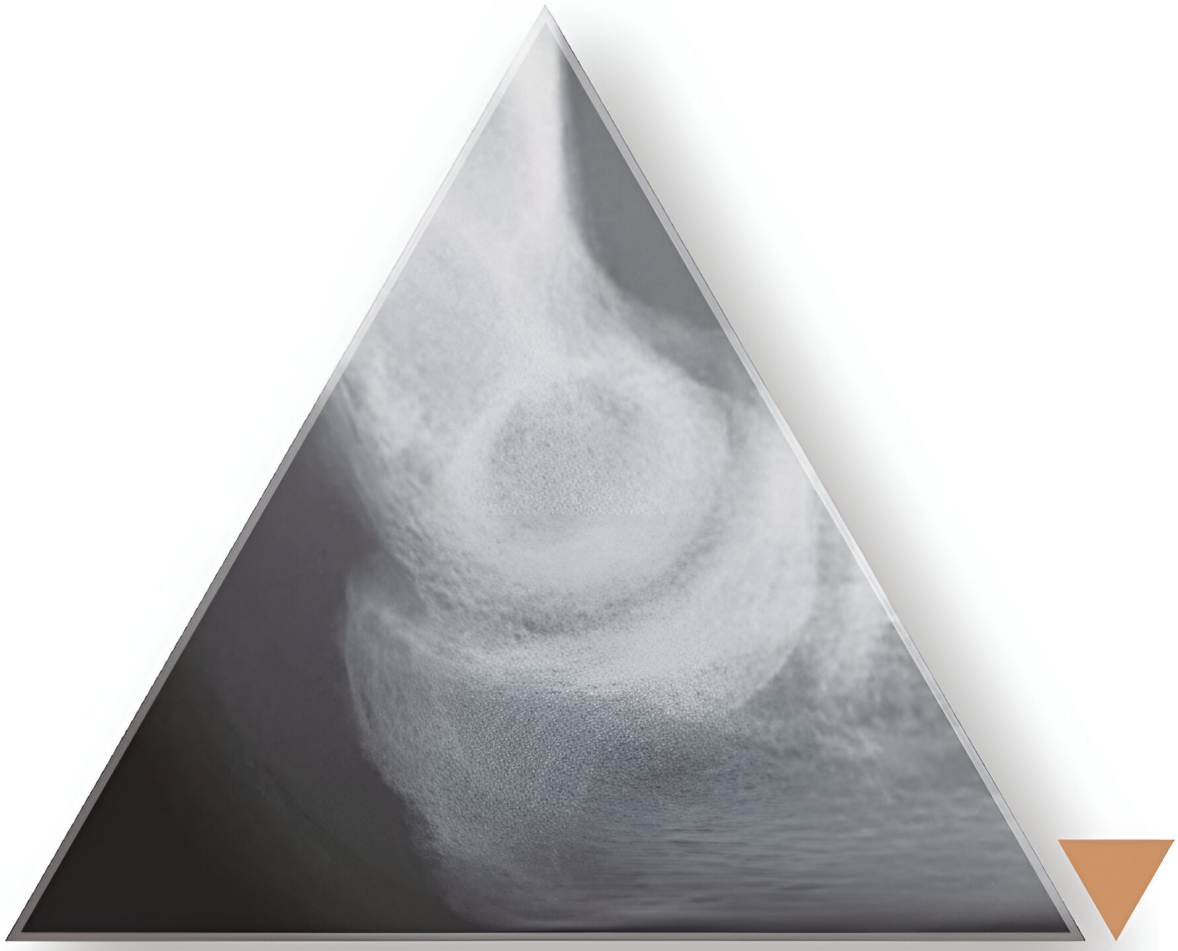

KEY FACTS

TERMINOLOGY

- Infection of soft tissue, including cellulitis, pyomyositis, phlegmon, abscess, & necrotizing fasciitis

IMAGING

- US is excellent for localized soft tissue infection
- US ± CT or MR for more generalized infection
- US cannot distinguish infective from noninfective fluid
- Always consider synchronous bone or joint infection
- **Cellulitis**
  - Most common soft tissue infection
  - Confined to skin & subcutaneous tissues
  - Edematous hyperemic subcutaneous fat
    - Hyperemia helps differentiate subcutaneous inflammation from subcutaneous edema
    - Subcutaneous inflammation normally, but not always, equates to infection, i.e., cellulitis
  - Thickened edematous interlobular septa
  - Check for phlegmon, abscess, or deep infection
- **Pyomyositis**
  - Diffuse edematous hyperechoic muscle swelling with indistinct fibrillary pattern
  - Hyperemia ± gas locules
- **Abscess**
  - Echogenicity of fluid may vary from hypoechoic to isoechoic to hyperechoic
  - Posterior acoustic enhancement characteristic
  - Echo movement on real-time imaging
  - Peripheral hyperemia ± septation ± gas locules
  - Proceed to US-guided aspiration or drainage
- **Necrotizing fasciitis**
  - Necrotizing soft tissue infection, > lower limbs
  - Predominantly clinical diagnosis aided by serology, imaging supportive
  - Gas, perifascial inflammation, extensive tissue inflammation, fluid collection, necrosis, ischemia
  - US findings are suggestive but CT is most useful imaging test

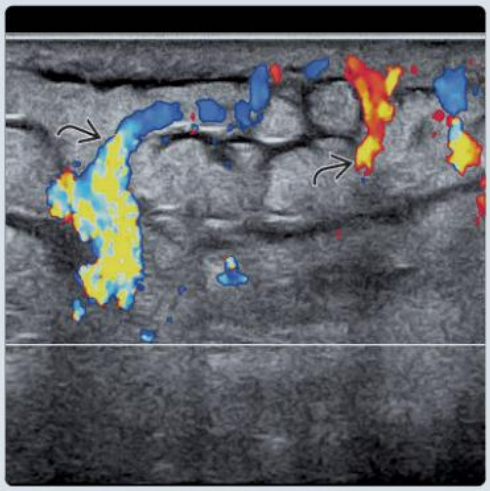

(Left) *Transverse US of the calf region shows severe, subcutaneous tissue thickening and edema. Increased subcutaneous fluid leads to thickened interlobular septa with intervening, hyperechoic swollen fat lobules.* **(Right)** *Transverse color Doppler US of the same area shows moderate-severity hyperemia. This hyperemia allows distinction between noninflamed edema ("bland edema") and inflamed subcutaneous tissue edema, i.e., cellulitis.*

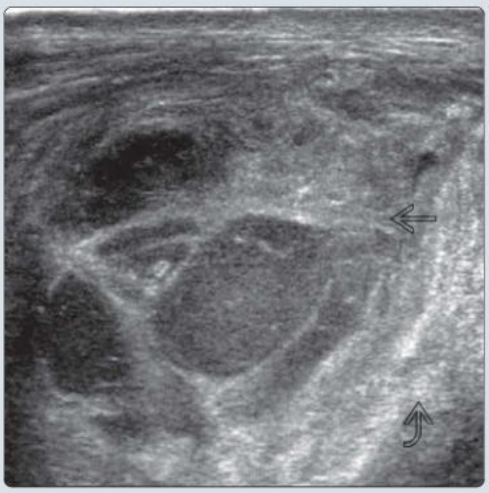

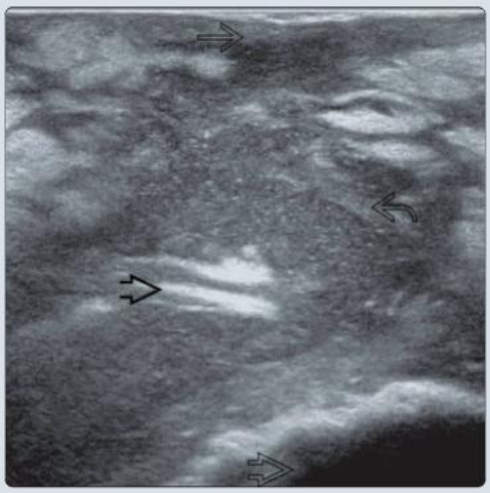

(Left) *Transverse US of the posterior thigh shows a multiloculated intramuscular abscess within the semimembranosus muscle. There is associated severe surrounding soft tissue edema.* **(Right)** *Transverse US of the buttock region in a tetraplegic patient shows extensive soft tissue edema with ill-defined abscess formation overlying the ischial tuberosity, extending to a cutaneous opening. There is a linear, hyperechoic gas artifact present within the abscess.*

TERMINOLOGY

Definitions

- Cellulitis: Localized or diffuse soft tissue inflammation of skin & subcutaneous tissues
- Pyomyositis: Suppurative bacterial infection of muscle
- Phlegmon: Localized, intense inflammation prior to development of abscess
- Abscess: Localized collection of pus
- Infective fasciitis: Infection centered around fascia
- Necrotizing fasciitis: Rapidly progressive, necrotizing, soft tissue infection with vascular occlusion

IMAGING

General Features

- Best diagnostic clue
  - Edema & hyperemia of affected tissues ± fluid accumulation
- Location
  - Any soft tissue can become infected
  - Most common sites
    - Cellulitis: Legs, dorsum of feet & hands
    - Pyomyositis: Large muscles of pelvis & lower limb; frequently multifocal
    - Necrotizing fasciitis: Thigh & leg
- Size
  - Varies from small, localized abscess to multicompartmental disseminated infection
- Morphology
  - Inflammation ± fluid ± abscess

Radiographic Findings

- Helps exclude other causes of soft tissue swelling, such as fracture
- Soft tissue swelling with obliteration of fascial planes
  - Useful for detecting gas locules, radiopaque foreign body, concomitant osteitis, or osteomyelitis

CT Findings

- Increased attenuation of subcutaneous fat
- Swelling of subcutaneous tissue ± muscles
- Fascial thickening or perifascial fluid
- ± gas locules within soft tissues ± foreign body ± concomitant osteitis or osteomyelitis
  - Highest sensitivity for detection of soft tissue gas & foreign body
- Contrast enhancement is useful for identifying fluid collection, abscess, or necrosis

MR Findings

- T2WI FS
  - Cellulitis: Diffuse hyperintensity of subcutaneous tissues
    - ± feathery edema of adjacent tissues
  - Pyomyositis: Diffuse hyperintensity of muscle
    - ± fluid collection
    - ± edematous changes in adjacent subcutaneous tissue > fascial planes > bone & joints
  - Abscess: High signal intensity area with surrounding edema ± hyperemia
    - ± hypointense foci due to gas locules
  - Necrotizing fasciitis: Hyperintense thickening of soft tissues & fascia with perifascial fluid
    - Myositis & myonecrosis
    - ± fluid areas indicative of necrosis, exudate, or abscess
    - ± hypointense foci due to gas locules
- T1WI C+
  - Useful in delineating fluid collection, sinus, abscess, or necrosis

Ultrasonographic Findings

- **Cellulitis**
  - Most common soft tissue infection
  - Confined to skin & subcutaneous tissues
  - Edema & hyperemia of subcutaneous fat
    - Edematous fat is echogenic on US
    - Thickened interlobular septa; characteristic cobblestone appearance
    - ± periseptal fluid & fluid around investing fascia
    - Varies from amorphous swelling with indistinct lobules to cobblestone appearance with accentuated lobules
    - ± secondary tenosynovial swelling
    - Need combination of edema & hyperemia to diagnose cellulitis
      - Hyperemia is not seen with noninflammatory edema in, e.g., venous insufficiency, heart failure, or lymphedema ("bland edema")
  - US is helpful to identify concomitant abscess, superficial thrombophlebitis, or deep infection
- **Pyomyositis**
  - Diffuse muscle swelling with edema ± hyperemia
  - Edematous muscle is echogenic on US with indistinct fibrillary pattern
  - ± focal hypoechoic areas due to phlegmon, serous exudate, abscess, or necrosis
  - Usually involves single muscle; multiple muscles involved in 40% of cases
- **Abscess**
  - Posterior enhancement is characteristic
  - Depending on maturity & content, echogenicity of fluid may vary from hypoechoic to isoechoic to hyperechoic
    - If thick fluid or debris is present, it may mimic solid mass, so best to have low threshold for aspiration, as fluid is not readily discernible
  - Echo movement on real-time imaging
  - ± gas locules with comet-tail artifact or shadowing artifact ± septations ± peripheral hyperemia
  - Wall thickness is proportional to chronicity of abscess
  - Proceed to US-guided aspiration or drainage
- **Necrotizing fasciitis**
  - Affects subcutaneous fat, fascia, & muscle
  - Necrotizing soft tissue infection rather than fascial infection
    - Mainly clinical diagnosis aided by serology (LRINEC score) with imaging supporting diagnosis
  - Thickened deep fascia with perifascial fluid (above & below investing fascia)
    - Severe (> 2 mm) & extensive fluid collection along fascial planes
  - Severe, associated subcutaneous & muscle edema
  - ± muscle necrosis, abscess

- Gas locules with comet-tail artifacts or shadowing artifact are highly suggestive
- US-guided aspiration of fluid for culture & sensitivity
  - Occasionally, little or no fluid can be aspirated despite visibly moving echoes

Imaging Recommendations

- Best imaging tool
  - US ± US-guided aspiration usually give sufficient information to make prompt diagnosis & guide treatment
- Protocol advice
  - Look for focal hypoechoic areas representing fluid collection, abscess, or necrosis
    - If fluid is present, consider aspiration for culture
    - Imaging cannot distinguish between infective & noninfective fluid
    - Intense phlegmon can simulate fluid collection though little or no fluid can be aspirated
      - Still send minimal aspirate for microbiology
  - Routinely assess with color Doppler imaging
  - Check for associated bone or joint infection
  - CT is most efficient modality to assess necrotizing fasciitis

DIFFERENTIAL DIAGNOSIS

Subcutaneous Edema

- Similar to cellulitis though no hyperemia

Muscle Hematoma

- Similar to muscle abscess but less inflammatory component
- Hypoechoic mass with posterior enhancement, variable liquefaction, & surrounding edema

Muscle Infarction

- Similar to focal pyomyositis but less inflammatory component
- Hypoechoic mass with surrounding edema & hyperemia

Noninfectious Fasciitis

- Eosinophilic fasciitis: Associated with peripheral eosinophilia
  - Usually quite diffuse fascial inflammation & swelling
  - US-guided fascial biopsy will reveal fasciitis with lymphocytic & eosinophilic infiltrate

PATHOLOGY

General Features

- Etiology
  - Predisposing conditions
    - Old age, diabetes, immunosuppression, intravenous drug use, peripheral vascular disease, trauma, surgery, obesity, alcoholism, malnutrition
  - Route of infection
    - Loss of skin integrity from trauma, surgery, or cutaneous ulceration; hematogenous route is less common
  - Causative organisms
    - Usually polymicrobial with combination of aerobic & anaerobic organisms; fungal & atypical organism sometimes seen
    - Cellulitis: *Staphylcoccus pyogenes*, *Staphylococcus aureus*
    - Pyomyositis: *S. aureus*, *Streptococcus*, *Mycobacterium tuberculosis*
    - Necrotizing fasciitis
      - Type 1: Polymicrobial with both aerobic & anaerobic bacteria
      - Type 2: Streptococci, particularly β-hemolytic streptococci, also staphylococci
      - Type 3: Gram-negative bacteria, *Clostridium difficile*

Gross Pathologic & Surgical Features

- Cellulitis: Acute inflammatory reaction
- Pyomyositis: Bacterial infection of skeletal muscle ± necrosis or abscess
- Necrotizing fasciitis: Extensive, severe infection, fluid collection, necrosis, thrombosis

Microscopic Features

- Cellulitis: Acute inflammatory infiltrate, capillary dilatation ± abscess formation
- Pyomyositis: Acute inflammatory infiltrate, capillary dilatation ± abscess formation
- Necrotizing fasciitis: Fascial inflammation & necrosis, subcutaneous & muscle necrosis, arterial & venous thrombi

CLINICAL ISSUES

Presentation

- Most common signs/symptoms
  - Cellulitis: Redness, heat, swelling, pain ± lymphangitis, blistering necrosis ± lymphadenopathy
  - Pyomyositis: Deep pain, tenderness ± mass
  - Necrotizing fasciitis: Rapidly progressive with severe pain & inflammation, blistering necrosis, severe tenderness, high fever, & shock

Demographics

- Age
  - More common in older patients
- Epidemiology
  - Cellulitis > > pyomyositis > necrotizing fasciitis

Natural History & Prognosis

- Cellulitis: Responds well to treatment
- Pyomyositis: Less favorable response in immunocompromised patients
- Necrotizing fasciitis: May requite amputation; mortality up to 30%

Treatment

- Cellulitis: Elevation, splinting + antibiotic therapy
- Pyomyositis: Antibiotic therapy
  - Abscess: Either US-guided percutaneous aspiration catheter drainage ± surgical drainage
- Necrotizing fasciitis: Early radical surgical debridement + irrigation + antibiotic therapy

SELECTED REFERENCES

1. Matcuk GR Jr et al: Lower extremity infections: essential anatomy and multimodality imaging findings. Skeletal Radiol. 53(10):2121-41, 2024
2. Pal D et al: Imaging features of soft-tissue infections. Skeletal Radiol. (10):2211-26, 2024

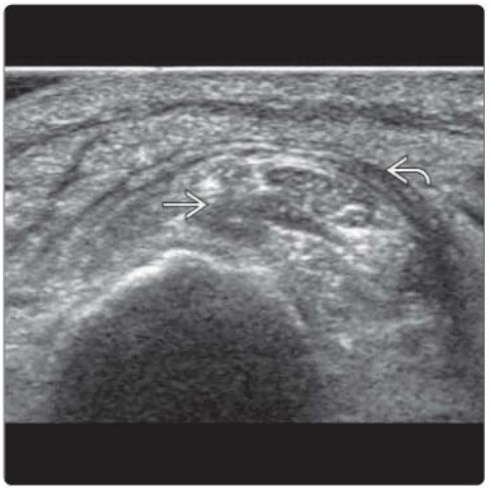

(Left) *Clinical photograph of a patient with ankle swelling and fever shows soft tissue swelling and skin erythema over the lateral aspect of the ankle.* **(Right)** *Transverse US in the same patient shows moderate subcutaneous edema on the lateral aspect of the ankle. Mild edematous thickening of the superior peroneal retinaculum, but no subfascial extension, is present. The peroneal tendons are normal. Color Doppler imaging (not shown) revealed hyperemia, consistent with subcutaneous cellulitis.*

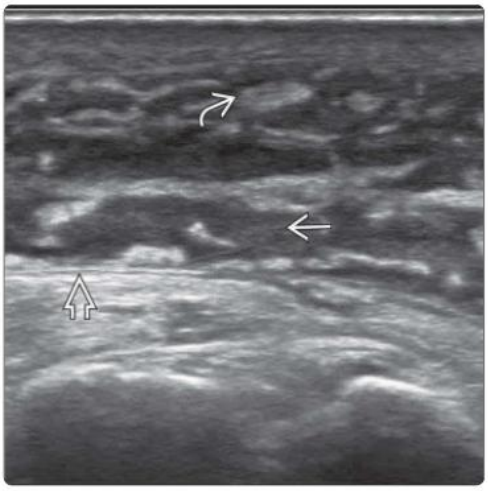

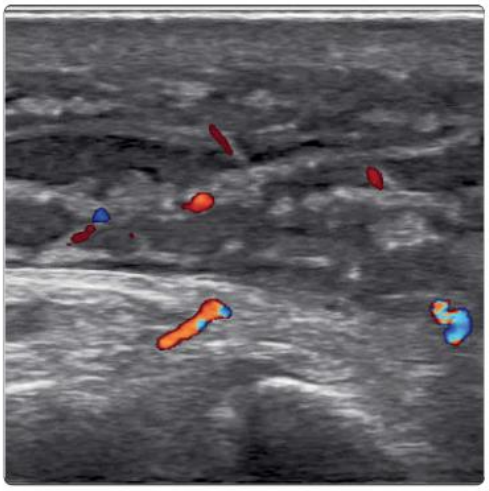

(Left) *Transverse US of the ankle in a patient with extensive swelling and erythema of the lower limb shows severe edema of the subcutaneous tissue with extensive hypoechoic areas interspersed between swollen fat lobules. Note the normal investing fascia and subfascial soft tissues.* **(Right)** *Transverse color Doppler US of the ankle in the same patient shows moderate hyperemia of the edematous subcutaneous soft tissues.*

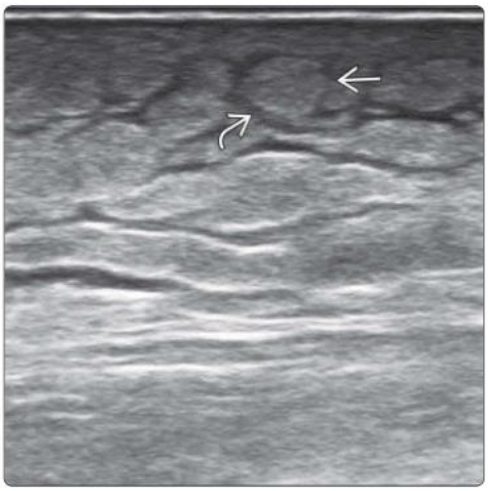

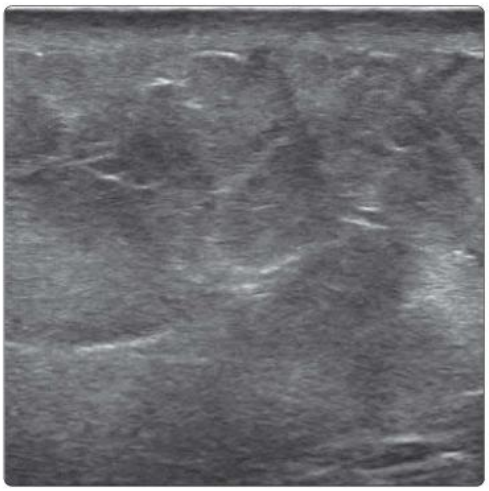

(Left) *Longitudinal US of the leg region shows swollen echogenic subcutaneous fat lobules and mildly thickened interlobular septa.* **(Right)** *Transverse US in the same patient more distally shows swollen subcutaneous fat with indistinct fat lobules, representing early cellulitis. There is no significant interstitial edema at this location. Appearance of subcutaneous edema varies according to severity and architecture of subcutaneous fat.*

(Left) *Transverse US in a patient with extensive hand swelling and erythema shows severe, subcutaneous soft tissue thickening* ⇨ *with edematous interlobular septa* ⇨ *on the dorsum of the hand. The metacarpal shafts* ⇨ *are normal.* **(Right)** *Transverse color Doppler US in the same patient shows severe subcutaneous* ⇨ *and peritendinous* ⇨ *soft tissue hyperemia indicative of primary severe cellulitis with secondary tenosynovitis.*

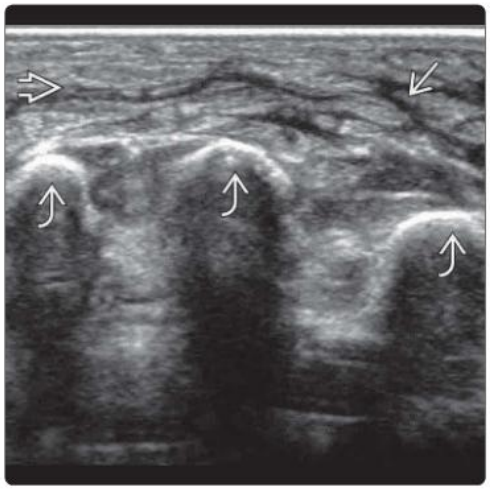

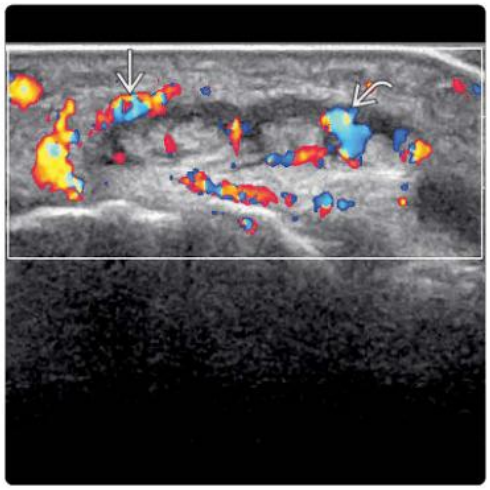

(Left) *Longitudinal US of the index finger in a patient with a recent cat bite shows severe cellulitis, mainly superficial to* ⇨ *but also deep to* ⇨ *the extensor tendon* ⇨ *at the metacarpophalangeal joint* ⇨ *level.* **(Right)** *Transverse US in the same patient shows the inflammation surrounding the extensor tendon* ⇨*. The extensor tendon* ⇨ *is moderately swollen, indicative of cellulitis involving both the subcutaneous tissues and the extensor tendon.*

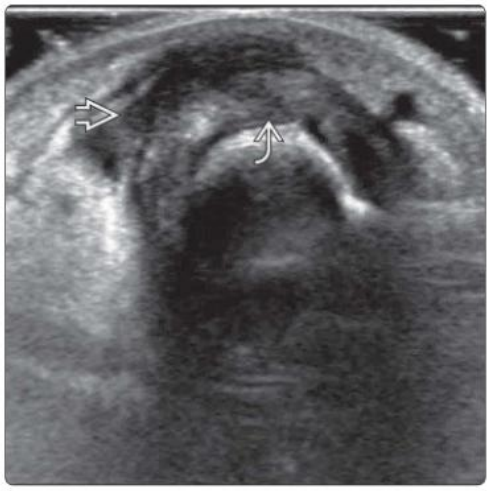

(Left) *Transverse US of the posterior calf shows a localized area of severe thickening of the investing fascia* ⇨ *with adjacent hyperechoic edematous subcutaneous tissue* ⇨*. The swollen investing fascia has a laminated appearance.* **(Right)** *Longitudinal color Doppler US of the same area shows fascial and gastrocnemius muscle hyperemia* ⇨*. The gastrocnemius muscle deep to the investing fascia is moderately edematous with an indistinct fibrillary pattern* ⇨*.*

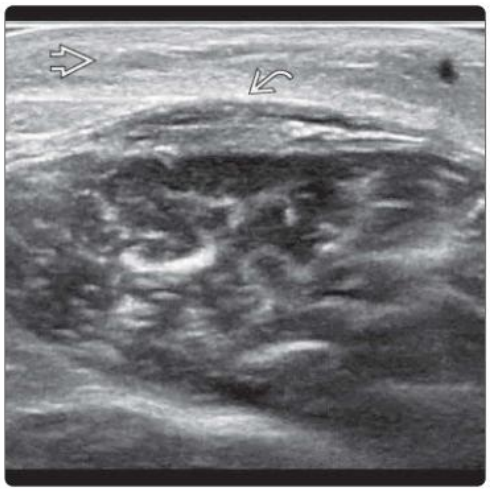

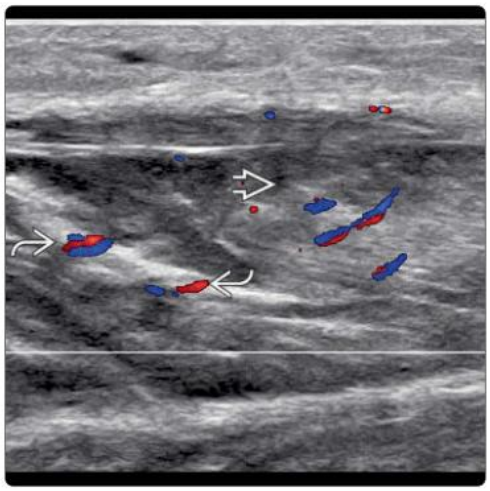

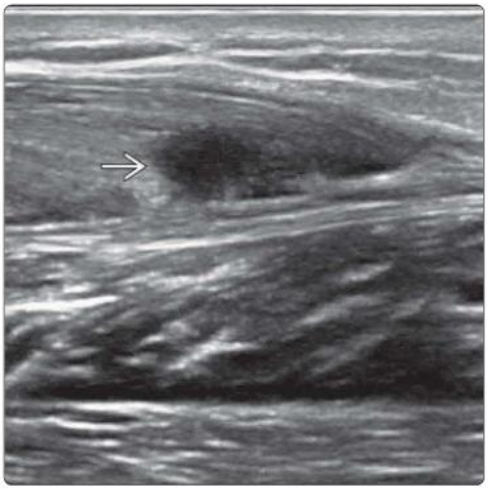

(Left) *Longitudinal US of a more distal part of the gastrocnemius muscle in the same patient shows a small intramuscular abscess ➡. Overall appearances are indicative of infective fasciitis with cellulitis and pyomyositis.* **(Right)** *Transverse US of the calf shows thickening of the investing fascia ➡ with hypoechoic phlegmonous tissue ➡ located both superficial and deep to the investing fascia. Hyperemia (not shown) was present in the phlegmonous tissue, indicating inflamed nonliquefied tissue.*

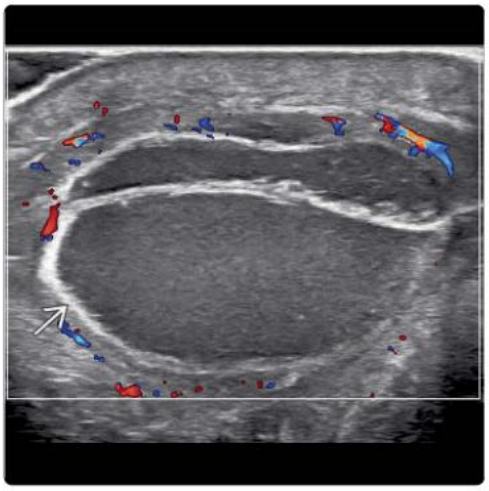

(Left) *Transverse US of the lateral aspect of the leg shows severe thickening of subcutaneous tissue ➡ and investing fascia ➡ with a fluid collection ➡ along and deep to the investing fascia.* **(Right)** *Longitudinal US in the same patient shows moderate hyperemia of the subcutaneous tissue, investing fascia and muscle. The liquefied subfascial collection ➡ shows no hyperemia compared to the phlegmonous tissue in the prior patient. US is helpful for identifying tissue liquefaction suitable for aspiration.*

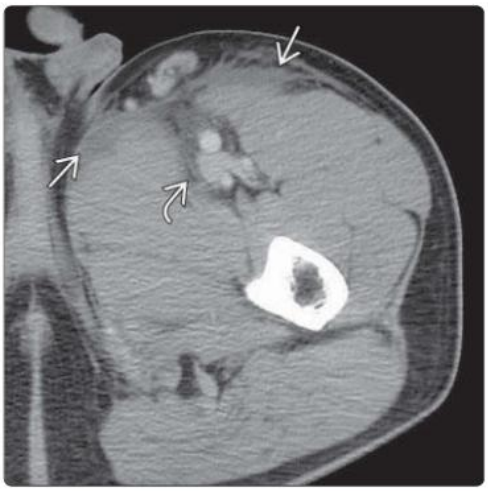

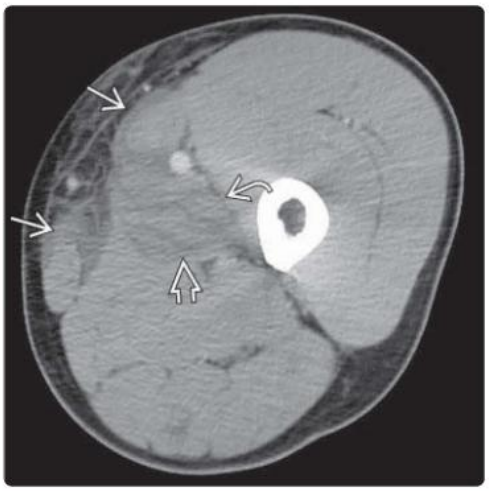

(Left) *Axial CECT in a patient with early necrotizing fasciitis show severe edema ➡ along the fascia overlying the adductor longus, brevis, and sartorius muscles. Edema also extends to the intermuscular fascial plane and around the femoral vascular bundle ➡.* **(Right)** *Axial CECT in the same patient shows superficial ➡ and deep ➡ fascial edema in the midthigh region. There is heterogeneous contrast enhancement of the adductor muscles ➡ suggestive of early necrosis.*

(Left) *Transverse US of the forearm in a patient with clinically progressive cellulitis shows severe edema of the flexor carpi radialis, palmaris longus, and flexor digitorum superficialis muscles. Mild to moderate subcutaneous edema is present. The appearances are indicative of polymyositis.* **(Right)** *Transverse color Doppler US in the same patient shows mild hyperemia within the flexor muscles. The palmaris longus muscle close to the central tendon is relatively normal in appearance.*

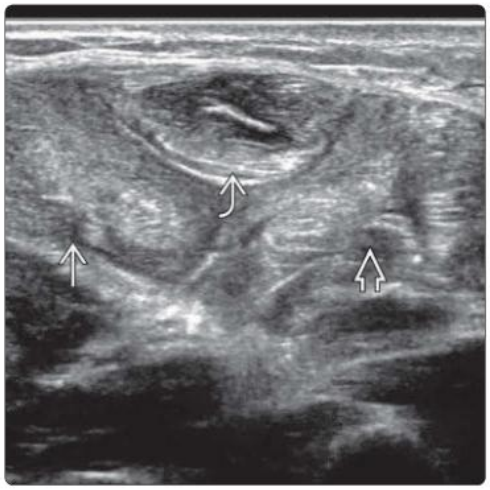

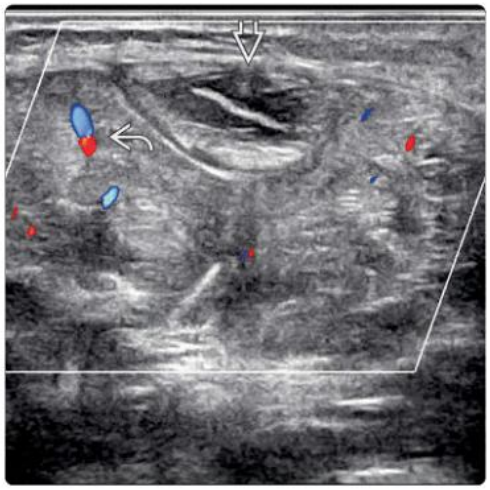

(Left) *Transverse US of the dorsal forearm in the same patient shows normal extensor musculature with moderate subcutaneous edema.* **(Right)** *Axial T1 C+ subtraction MR in the same patient shows increased flexor muscle enhancement, most severely affecting the flexor carpi radialis muscle, consistent with pyomyositis. Pyomyositis is typically multifocal. Note the diffuse subcutaneous tissue edema indicative of associated cellulitis.*

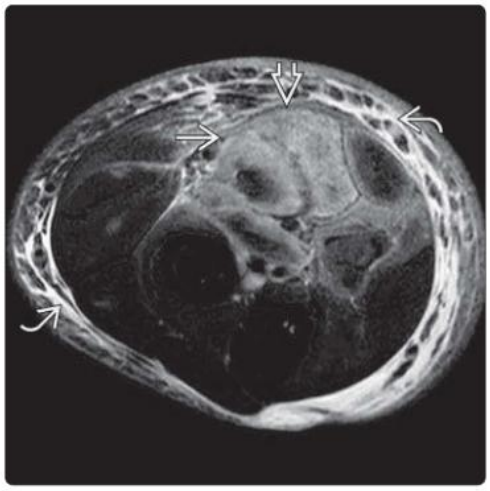

(Left) *Transverse US in an immunocompromised patient shows severe subcutaneous edema with severe semimembranosus muscle edema. There is fluid tracking between the muscle fibers and between adjacent muscles.* **(Right)** *Longitudinal US in the same patient shows the swollen semimembranosus muscle with largely intact muscle fibers. The appearances represent an infective pyomyositis. A small amount of fluid is tracking between the muscle fibers.*

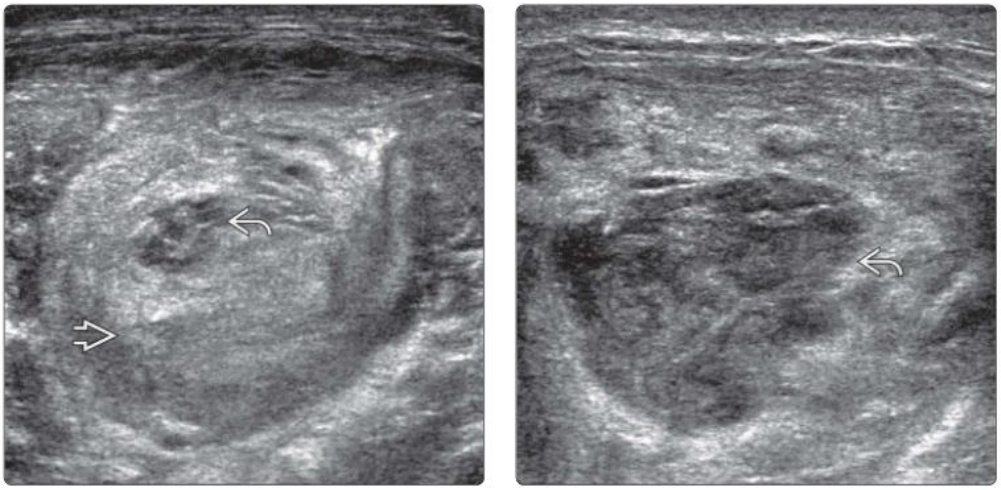

(Left) *Transverse US in the same patient 10 days later shows progressive myositis with loss of the normal fibrillary pattern. A small, hypoechoic intramuscular focus due to early abscess formation is present.* **(Right)** *Transverse US in the same patient 4 days later shows evolving pyomyositis with an enlarged area of liquefaction due to abscess formation. US-guided aspiration of the abscess yielded Stenotrophomonas maltophilia bacteria.*

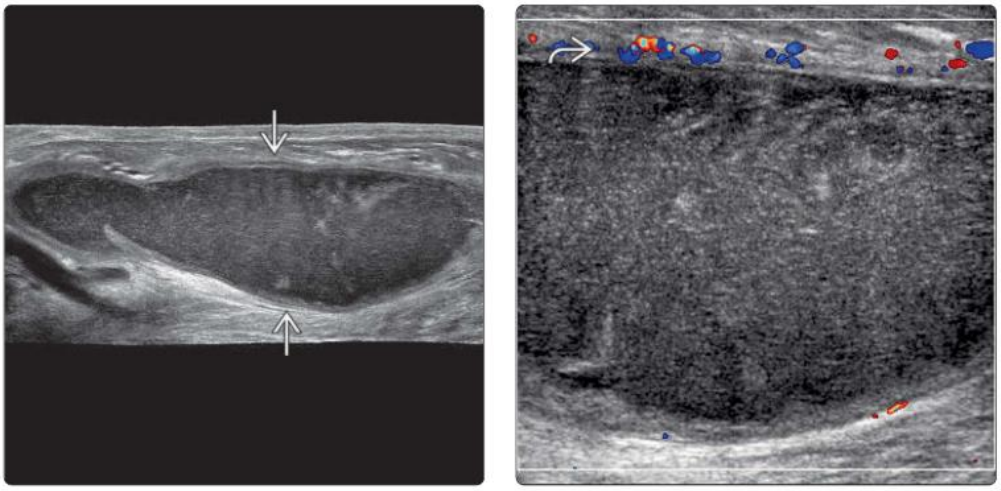

(Left) *Extended field-of-view US in a patient with intravenous drug use shows a large, well-defined, hypoechoic collection within the medial belly of the gastrocnemius muscle. The well-defined, thickened wall of the collection and the lack of surrounding soft tissue edema are indicative of a chronic abscess.* **(Right)** *Transverse color Doppler US of the same area shows mild to moderate hyperemia along the wall of the collection. US-guided aspirate grew Staphylococcus aureus.*

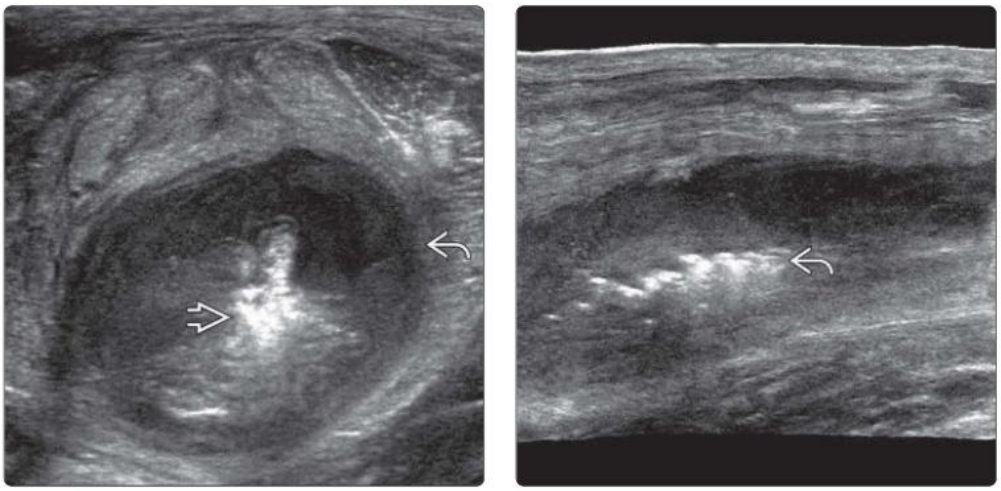

(Left) *Transverse US of the thigh shows severe inflammation of the hamstring muscles with a large, well-defined abscess within the semitendinosus muscle. The hyperechoic foci within the abscess are due to gas.* **(Right)** *Extended field-of-view US in the same patient shows multiple hyperechoic foci with comet-tail artifact within this gas-forming abscess. US-guided aspirate yielded Streptococcus milleri, S. aureus, and Klebsiella species.*

KEY FACTS

IMAGING

- Periosteal thickening & hyperemia with juxtacortical edema
- US can depict outer cortical, periosteal, & extraosseous areas
  - Periosteal thickening
  - ± juxtacortical soft tissue edema & hyperemia
  - ± cortical irregularity
  - ± sympathetic joint effusion
- Severe infection may show
  - Subperiosteal exudate or, less commonly, abscess
  - Soft tissue abscess
  - Cortical disruption ± extraosseous inflammatory mass
- Chronic osteomyelitis may show
  - Sinus tracts
  - Cloaca
  - Sequestra
- US is useful in neonates & young infants when clinical signs are often nonspecific
  - High propensity to develop periosteal reaction in children
  - US shows features of acute osteomyelitis several days earlier than radiography
- US is useful in postoperative patients when metallic implants limit MR assessment
- US is useful in assessment of involvement of adjacent soft tissue & guiding aspiration or biopsy
- MR has highest sensitivity & specificity for both acute & chronic osteomyelitis
  - Marrow replacement changes in chronic osteomyelitis can be due to repair or inflammation
- CECT also helpful in for chronic > acute osteomyelitis

TOP DIFFERENTIAL DIAGNOSES

- Soft tissue infection
- Septic arthritis
- Bone sarcoma
- Leukemia or metastatic infiltration

(Left) *Longitudinal US in a neonate with acute osteomyelitis of the femur shows focal cortical irregularity ⇨ at the distal femoral metaphysis. This is associated with periosteal soft tissue thickening ⇨ and a small amount of subperiosteal fluid ⇨.* **(Right)** *Lateral US of the contralateral femur in the same patient shows the smooth cortex of the femoral metaphysis ⇨ and normal thin hyperechoic periosteum ⇨. The physis ⇨ and epiphysis ⇨ are normal.*

(Left) *Longitudinal US shows acute osteomyelitis with a focal bone erosion ⇨ filled by hypoechoic inflammatory soft tissue at the distal ulnar metaphysis with associated periosteal thickening ⇨ and a small amount of subperiosteal exudate ⇨.* **(Right)** *Longitudinal US shows partially mineralized, thickened mature periosteal reaction ⇨, compatible with involucrum, deep to a large infective collection ⇨. This is due to chronic osteomyelitis in the femoral diaphysis. The femoral bony cortex ⇨ in this section is largely intact.*

TERMINOLOGY

Definitions

- Osteomyelitis: Infection of bone marrow
- Acute osteomyelitis: Symptomatic osteomyelitis < 6 weeks of duration
- Chronic osteomyelitis: Symptomatic osteomyelitis > 6 weeks of duration
- Infective osteitis: Infection of bone cortex (usually contiguous with juxtacortical infection)
- Sequestrum (meaning separated): Fragment of dead bone surrounded by granulation tissue
- Involucrum (meaning to wrap in): Layer of living periosteal new bone formed around dead bone
- Cloaca (meaning drain): Opening in cortex or involucrum through which sequestrum, fluid, or granulation tissue is discharged
- Brodie abscess: Focal area of chronic osteomyelitis with abscess & surrounding sclerosis

IMAGING

General Features

- Best diagnostic clue
  - Periosteal thickening & hyperemia with juxtacortical edema
- Location
  - Acute osteomyelitis: Metaphyses of long tubular bones
    - Metaphyses & epiphyses in infant
  - Chronic osteomyelitis: Diaphyses of long tubular bones
  - Osteitis: Alongside area of chronic soft tissue infection or ulceration
- Size
  - Acute osteomyelitis usually less extensive than chronic osteomyelitis
- Morphology
  - Acute osteomyelitis: Bony resorption
  - Chronic osteomyelitis: Simultaneous bony resorption, draining infection (sequestra, cloaca, sinus tract), & bony repair (bone deposition, expansion)

Radiographic Findings

- Radiography
  - Insensitive for early acute osteomyelitis
    - Radiographic bony changes occur 10-14 days after symptom onset, depending on severity of infection
  - Sensitive for chronic osteomyelitis
    - Sclerosis, periosteal thickening, sequestra, cloaca, expansion ± bowing
    - Involucrum rarely seen nowadays

CT Findings

- NECT
  - Useful when MR is not available
  - Useful in chronic osteomyelitis for depicting cloaca, sequestra, & sinus tracts
    - Sequestra may be difficult to see on MR (hypointense) or radiography (if marked sclerosis & cortical thickening)
- CECT
  - Abscesses & sinus tracts enhance peripherally

MR Findings

- T1WI
  - Hypointense marrow edema ± cortical destruction
- T2WI FS
  - Acute osteomyelitis: Hyperintense marrow edema without discrete mass
    - ± focal cortical destruction ± periosteal thickening (lamellar, Codman triangle)
    - ± juxtacortical edema, inflammation, or inflammatory mass
    - MR = highly sensitive & specific for acute osteomyelitis
  - Chronic osteomyelitis; additional findings include
    - ± intraosseous, transcortical, or extraosseous sinus tracts
    - ± hypointense sequestra
    - ± periosteal thickening (from lamellar immature to thick mature)
    - Appearances vary with level of inflammatory activity
  - Brodie abscess (intramedullary abscess cavity): Hyperintense with hypointense sclerotic rim
    - Abscess surrounded by reactive sclerotic bone & inflammation
- T1WI C+
  - Differentiates abscess (rim enhancement) from inflammatory tissue (diffuse enhancement)
    - Sequestrum may also enhance peripherally & simulate abscess
    - Enhancing tissue in chronic osteomyelitis may represent reparative or inflammatory tissue

Ultrasonographic Findings

- US is useful in neonates & young infants when clinical signs are often nonspecific
  - Shows features of acute osteomyelitis several days earlier than radiography
  - Less sensitive than MR or scintigraphy
- US sensitivity is highest in suspected osteomyelitis of tubular bones in children, where propensity to develop periosteal reaction is highest
- US is also useful in postoperative patients when metallic implants limit MR assessment
- US usually only depicts outer cortical, periosteal, & extraosseous areas
  - Periosteal thickening is seen as periosteal hyperemic rim, usually with hyperemia
  - ± juxtacortical soft tissue edema & hyperemia
  - ± cortical irregularity
  - ± sympathetic joint effusion
- Severe infection may show
  - Subperiosteal exudate or, less commonly, abscess
  - Soft tissue abscess
  - Cortical disruption ± extraosseous inflammatory mass
    - Visualization of medullary canal if osteolysis of overlying cortex provides acoustic window
  - US-guided aspiration & biopsy for periosteal fluid & inflammatory soft tissue mass, respectively
- Chronic osteomyelitis may show
  - Sinus tracts
  - Cloaca
  - Sequestra
- US appearances of acute bone infection are nonspecific

- Periosteal thickening ± subperiosteal fluid ± soft tissue edema also seen in
  - Stress reaction of bone
  - Bone sarcoma
  - Sickle cell disease with medullary infarction
- In neonates & young children, pure chondral infection may occur
  - May be difficult to detect on US, as hypoechoic fluid has similar echogenicity to hypoechoic cartilage

Nuclear Medicine Findings

- tc-99m-MDP SPECT/CT, gallium scan, WBC scan, & PET/CT
  - Particularly helpful for metallic implants & chronic osteomyelitis

Imaging Recommendations

- Best imaging tool
  - MR has high sensitivity & specificity for both acute & chronic osteomyelitis
    - Very high negative predictive value, i.e., normal MR excludes osteomyelitis
  - US when MR unavailable or inappropriate
    - Guide aspiration or biopsy for histology, microbiology, & treatment
    - Useful with orthopedic instrumentation where infection might not be seen by MR or CT
    - Useful for assessment of soft tissue infection, especially in chronic osteomyelitis
- Protocol advice
  - In acute osteomyelitis, periosteal reaction is most specific sign
    - Proceed to MR if US is positive for periosteal reaction or if there is strong clinical suspicion of osteomyelitis
  - Check for signs of osteomyelitis when undertaking US for suspected soft tissue or joint infection

DIFFERENTIAL DIAGNOSIS

Soft Tissue Infection

- Soft tissue edema & inflammation ± inflammatory mass ± abscess
- Check bone surface for signs of osteomyelitis

Septic Arthritis

- Similar clinical picture to acute osteomyelitis
- Medium to large joint effusion ± hyperemia ± positive joint aspiration

Bone Sarcoma

- No clinical signs of infection
- Cortical destruction ± extraosseous soft tissue mass ± spiculated new bone formation

Leukemia or Metastatic Infiltration

- Usually known primary tumor
- Multiple sites of involvement in leukemia

PATHOLOGY

General Features

- Etiology
  - *Staphylococcus aureus*: Most common infecting organism in all age groups
  - Common organisms: *Streptococcus*, *Pseudomonas*, *Haemophilus*, *Enterobacter*, *Mycobacterium*
  - May be due to mixed organisms
    - Especially chronic osteomyelitis

Gross Pathologic & Surgical Features

- Hematogenous seeding
- Direct contamination

Microscopic Features

- Inflammation of marrow
- Vascular compromise
- Necrosis, abscesses, sequestra

CLINICAL ISSUES

Presentation

- Most common signs/symptoms
  - Pain, tenderness, fever with signs of inflammation
- Other signs/symptoms
  - Restricted motion, constitutional symptoms
- Clinical profile
  - Acute osteomyelitis progresses over days to weeks
    - ± positive blood cultures
  - Chronic osteomyelitis usually presents de novo without preexisting acute osteomyelitis
    - Typically established at time of presentation
    - Early disease is subclinical

Demographics

- Age
  - Acute osteomyelitis more common in young children
  - Chronic osteomyelitis more common in older age group
- Epidemiology
  - Both acute & chronic osteomyelitis less common worldwide with improving global health status
  - Chronic > acute osteomyelitis can be precipitated by trauma

Natural History & Prognosis

- Good prognosis for acute osteomyelitis (if treated early)
- Chronic osteomyelitis difficult to fully eradicate with relapsing-remitting clinical course

Treatment

- Conservative
  - Rest, elevation, intravenous antibiotics
- Surgical
  - Debridement ± antibiotic-impregnated beads

DIAGNOSTIC CHECKLIST

Consider

- Bone infection if unexplained periosteal thickening or juxtacortical inflammatory mass is detected even though cortex seems intact

SELECTED REFERENCES

1. Hosokawa T et al: Ultrasonography for the detection of osteomyelitis in pediatric patients with soft tissue infection: a pilot study. J Ultrasound Med. 43(7):1223-34, 2024

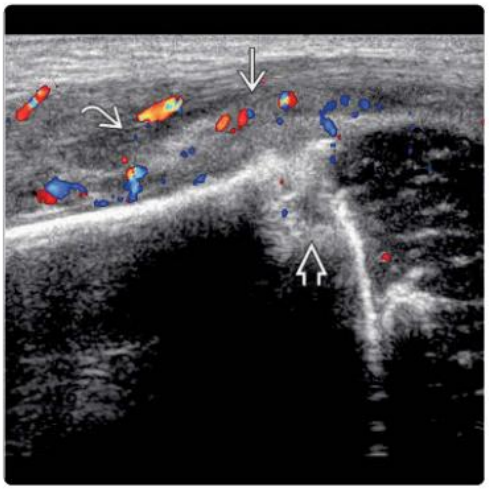

(Left) *Frontal radiograph in a 13-day-old neonate with fever and decreased leg movement shows mild cortical resorption ➡ at the distal femoral metaphysis with a fine periosteal reaction ➡.* **(Right)** *Longitudinal color Doppler US in the same patient shows acute osteomyelitis with focal metaphyseal cortical resorption ➡, moderate periosteal soft tissue thickening, and hyperemia ➡. A small amount of fluid ➡ is present alongside the periosteal soft tissue.*

(Left) *Sagittal STIR MR in the same patient shows metaphyseal marrow edema ➡ with thickened, hyperintense, inflamed periosteal soft tissue ➡, consistent with acute osteomyelitis.* **(Right)** *Lateral radiograph in an adult patient with fever and elbow pain shows soft tissue swelling ➡ at the posterior aspect of the elbow joint with a focal subtle cortical defect ➡ at the tip of the olecranon process. There is also some unrelated focal hyperostosis of the distal humeral shaft ➡.*

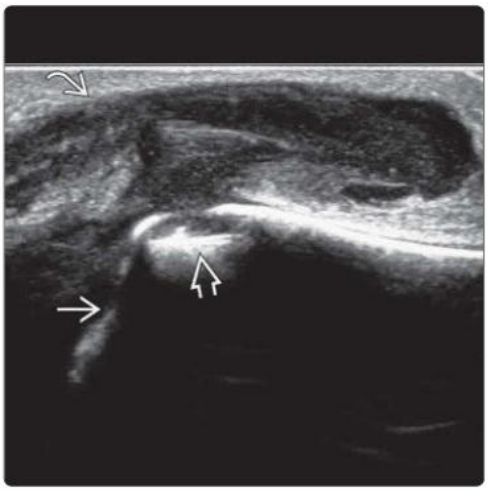

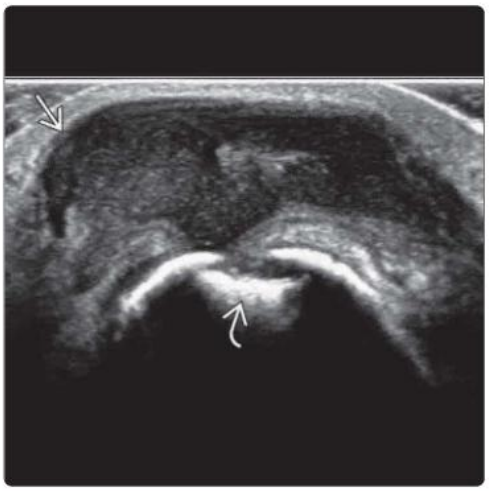

(Left) *Longitudinal US in the same patient shows a localized, partially liquefied abscess ➡ at the posterior aspect of the olecranon process ➡ and proximal ulna. Note a small cortical defect ➡ at the posterior tip of the olecranon process.* **(Right)** *Transverse US of the same region shows the olecranon cortical defect ➡. Osteomyelitis of the olecranon process leads to focal cortical disruption and a secondary juxtacortical abscess ➡. This abscess should not be confused with primary olecranon bursitis.*

(Left) *Frontal radiograph in a 14-year-old patient with fever and wrist pain shows a lytic lesion ➡ with a wide zone of transition in the distal ulnar metaphysis.* **(Right)** *Transverse US in the same patient shows prominent, solid-appearing, juxtacortical soft tissue thickening ➡ surrounding the distal ulna ➡. Echogenic seams represent new bone formation. An outer hypoechoic area ➡ representing fluid or severe edema is present.*

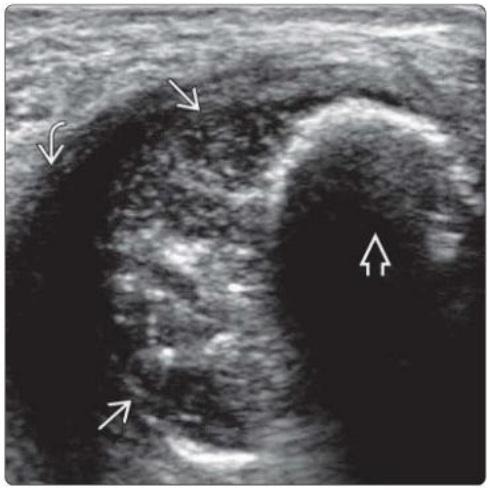

(Left) *Transverse color Doppler US in the same patient shows moderate to severe hyperemia ➡ in the juxtacortical soft tissues. Overall appearances favor either bone sarcoma or infection.* **(Right)** *Coronal T2 FS MR in same patient shows moderate marrow edema ➡ at the distal ulnar metaphysis with involvement of the physis ➡. MR is better than US in depicting physeal or transphyseal involvement. Percutaneous biopsy confirmed acute osteomyelitis.*

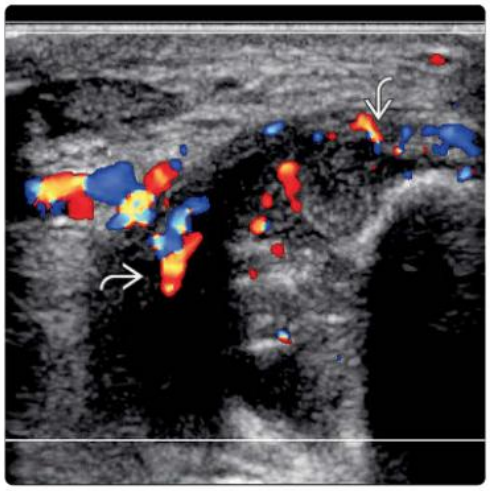

(Left) *Transverse US in a 75-year-old woman with gluteal pain and swelling after iliac crest bone marrow biopsy shows a lobulated collection ➡ overlying the iliac crest biopsy site ➡.* **(Right)** *Color Doppler US at the same location shows peripheral hyperemia and mild soft tissue inflammation, compatible with an abscess. 13 mL of purulent fluid was aspirated, which grew Staphylococcus aureus. Soft tissue infection in contact with a disrupted bone cortex ➡ carries a high likelihood of osteomyelitis.*

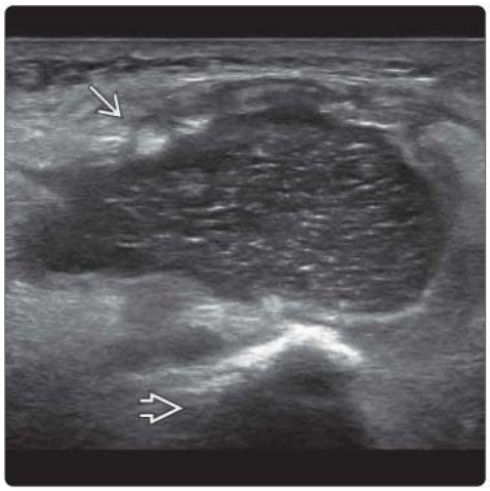

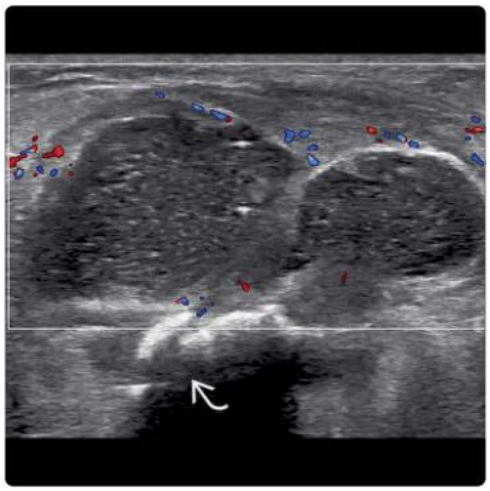

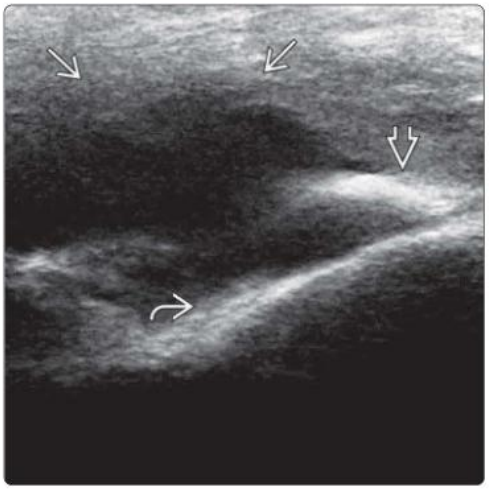

(Left) *Lateral radiograph in an 11-year-old patient with subacute thigh pain shows mild, diffuse osteosclerosis with irregular, mature-type periosteal thickening along the femoral diaphysis posteriorly.* **(Right)** *Longitudinal US in the same patient shows a hypoechoic extraosseous collection extending deep to the thickened, ossified periosteal tissue on the posterior femoral cortex, indicative of a subacute exacerbation of chronic osteomyelitis.*

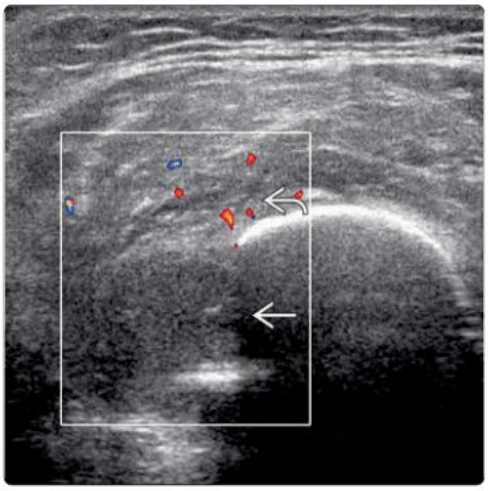

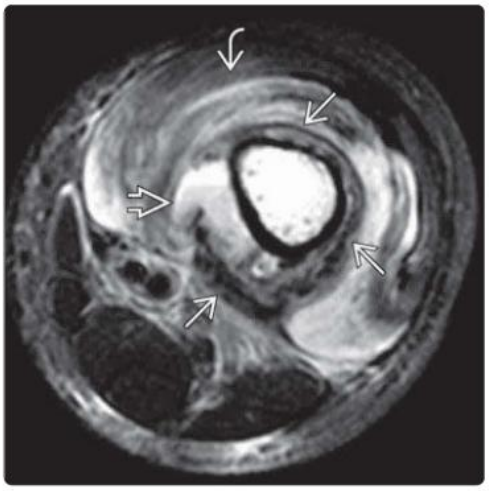

(Left) *Transverse color Doppler US at same location shows mild juxtacortical hyperemia and soft tissue thickening, indicative of moderate active inflammation. The hypoechoic collection shows no intrinsic vascularity.* **(Right)** *Axial T2 FS MR in the same patient shows bone marrow with a hypointense thickened periosteum due to ossification (involucrum). A subperiosteal collection with a fluid level is associated with this subacute infection. There is severe quadriceps muscle edema.*

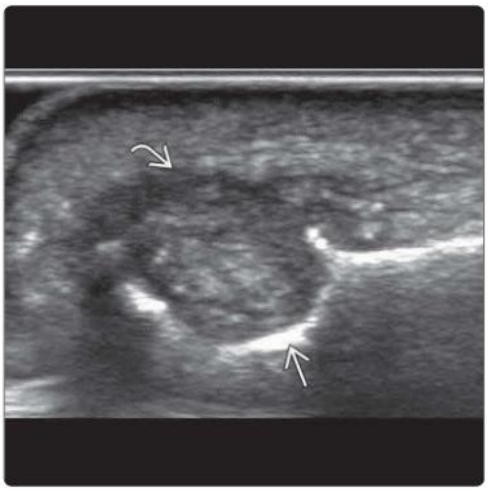

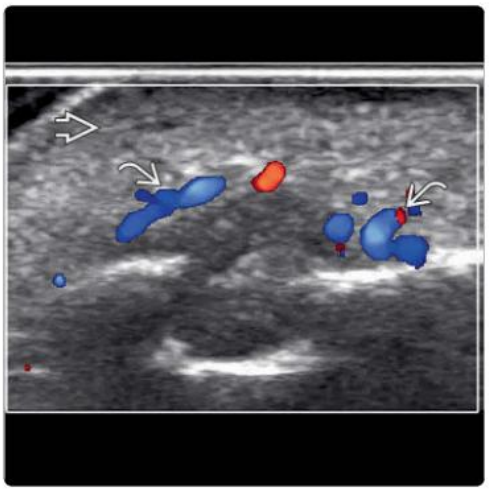

(Left) *Longitudinal US of the index finger in a patient with recent penetrating injury to the nail fold shows a focal cortical erosion in the distal phalanx. The cortical erosion is filled with hypoechoic inflammatory soft tissue. No foreign body is present.* **(Right)** *Longitudinal color Doppler US of the same region shows moderate hyperemia around the soft tissue mass, indicating moderate to severe active inflammation. The surrounding subcutaneous soft tissues are moderately edematous.*

(Left) *Frontal radiograph in the same patient shows a well-defined area of osteolysis ➡ in the distal phalanx. The cortical erosion is filled by soft tissue, similar to that depicted on US on the previous image, highlighting the mutual benefits of both radiography and US when assessing bone infection.* **(Right)** *Coronal T1 C+ FS MR of the same region shows an enhancing inflammatory mass ➡ at the site of osteolysis, and there is a small abscess ➡ present, all consistent with distal phalangeal osteomyelitis.*

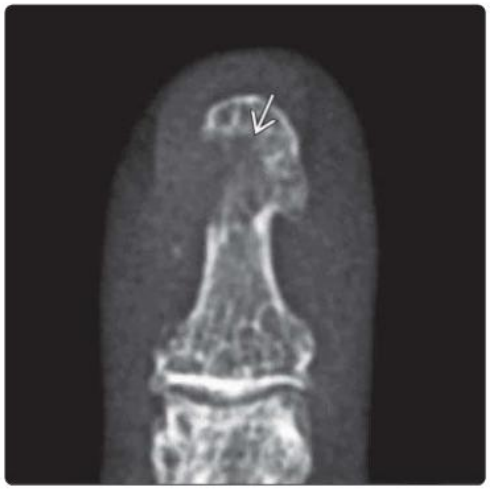

(Left) *Longitudinal US shows moderate irregularity of the midtibial shaft ⇨ with a small focal defect ➡ anteriorly communicating via a small sinus tract ➡ to the dermis in this 65-year-old man with chronic tibial osteomyelitis. The overlying dermis and the subdermal tissues ➡ are moderately fibrotic.* **(Right)** *Transverse US better depicts the sinus tract ➡ extending from the anteromedial tibia ⇨ to the dermis. There is no evidence of active infection or abscess. Features are compatible with inactive chronic osteomyelitis.*

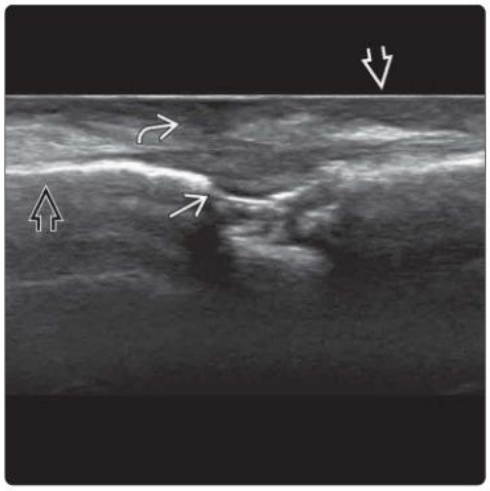

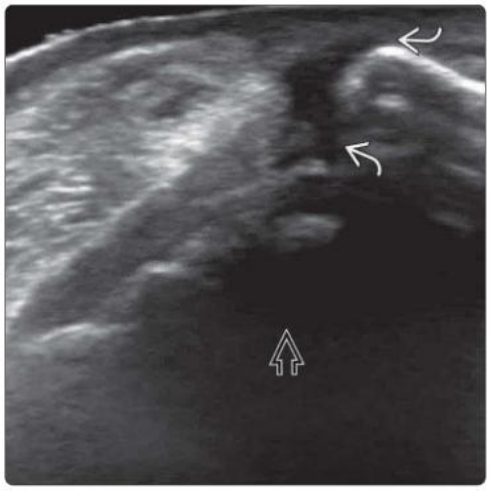

(Left) *Coronal T2 FS MR of the same location shows a focal, well-marginated area of T2 hyperintensity ➡ in the cortical and juxtacortical anteromedial tibial shaft with focal cortical irregularity, compatible with inactive chronic osteomyelitis.* **(Right)** *Corresponding transverse T2 FS MR confirms the small sinus tract ➡ extending from the tibial cortex ➡ to the overlying dermis. There is no evidence of active inflammation.*

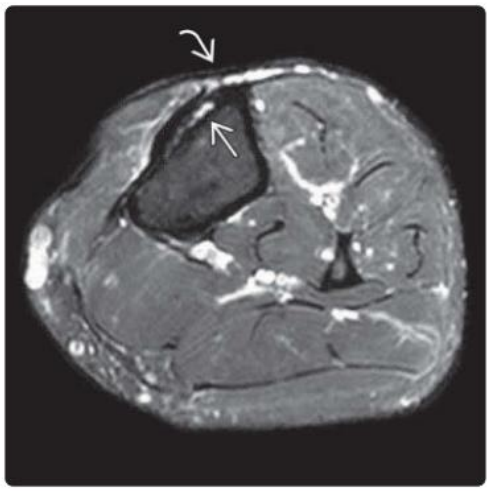

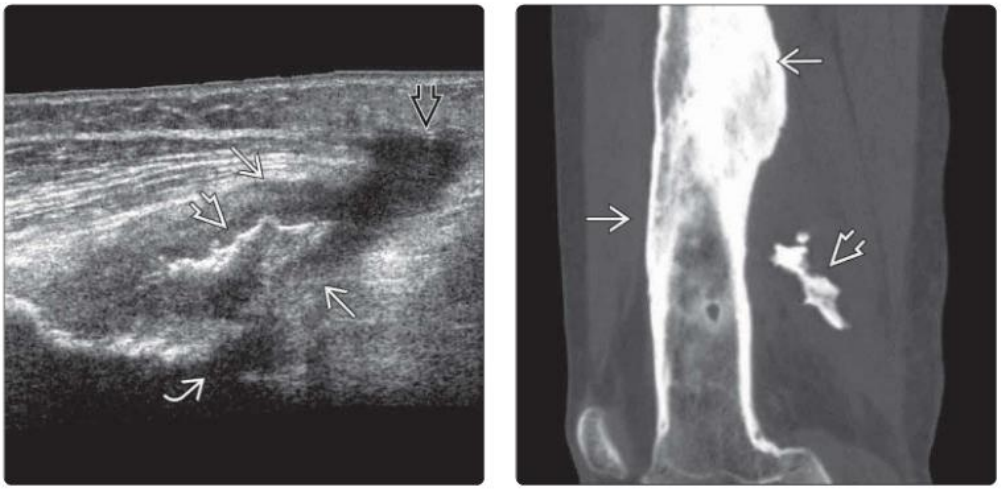

(Left) *Longitudinal US with extended field of view shows a large sequestrum ⇨ within a sinus tract ⇨ extending from an irregular femoral cortex ⇨ to the investing fascia of the thigh ⇨.* **(Right)** *Longitudinal NECT with sagittal reconstruction of the same patient shows the sequestrum ⇨ and a severely thickened sclerotic femoral diaphysis ⇨, all indicative of chronic osteomyelitis.*

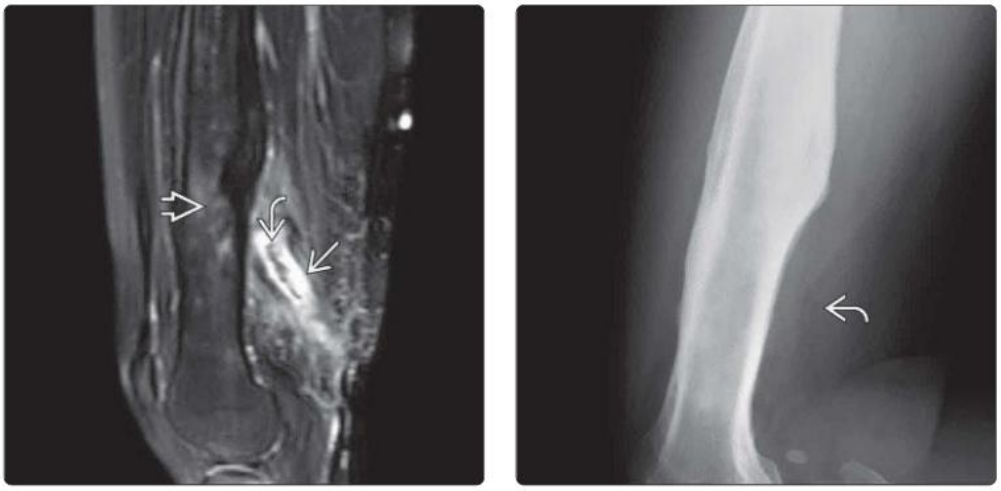

(Left) *Sagittal STIR MR in the same patient shows a hypointense sequestrum ⇨ with surrounding hyperintense, inflamed granulation tissue ⇨ within a thin sinus tract. Mild medullary canal edema ⇨ and extraosseous soft tissue indicate low-grade chronic inflammation.* **(Right)** *Lateral radiograph of the femur in the same patient following sequestrectomy and debridement shows clearance ⇨ of the sequestrum.*

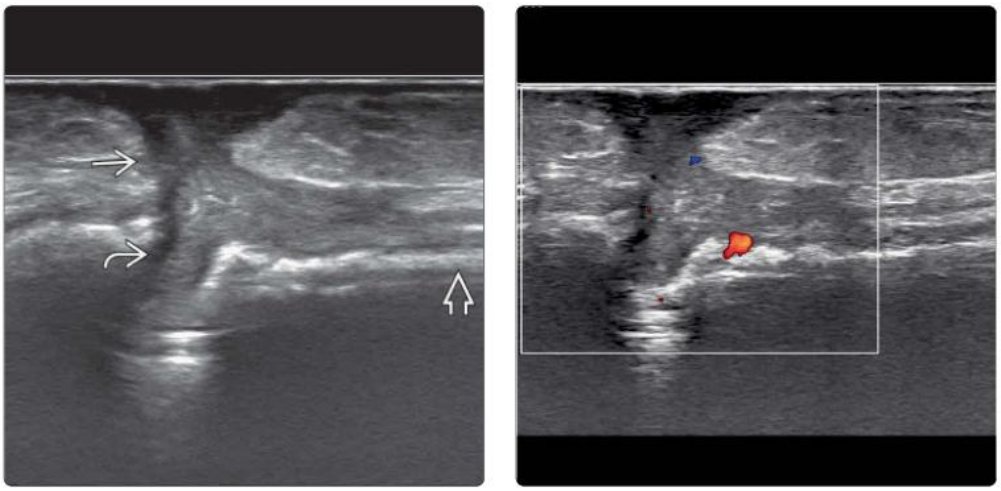

(Left) *Longitudinal US in a patient with a previous fracture of the distal tibia is shown. There is a medium-sized sinus tract ⇨ filled with inflammatory-type granulation or gelatinous-type tissue extending from the anterior aspect of the distal tibia ⇨ to the skin. This tract communicates with a 6-mm-wide bone defect ⇨ in the distal tibia at the previous fracture site. Low-grade bone infection is likely.* **(Right)** *Color Doppler US at the same site shows minimal hyperemia, indicative of low-level disease activity.*

(Left) *Frontal radiograph shows mild expansion, mixed sclerosis, and lysis of the midhumeral diaphysis ⇄ with soft tissue thickening ➡ distally. The radiographic appearances are suggestive of sarcoma or chronic osteomyelitis.* **(Right)** *Longitudinal US of the same arm shows focal cortical disruption ➡ of the midhumeral diaphysis, a large extramedullary inflammatory-type mass ➡ with a small cystic area ⇄, indicative of acute exacerbation of chronic osteomyelitis.*

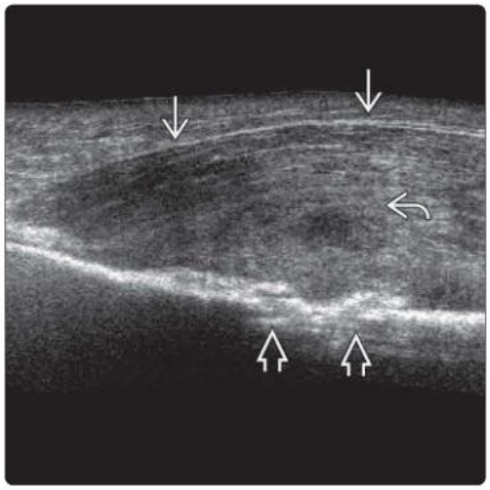

(Left) *Longitudinal T1 C+ MR in the same patient shows several small intramedullary abscesses ➡ with a large juxtacortical inflammatory mass ➡ distally, compatible with acute exacerbation of chronic osteomyelitis.* **(Right)** *CECT in a patient with pain, swelling, and discharge from a recent sternotomy site shows some enhancing soft tissue ➡ filling the sternotomy site, which extends to the cutaneous surface ⇄.*

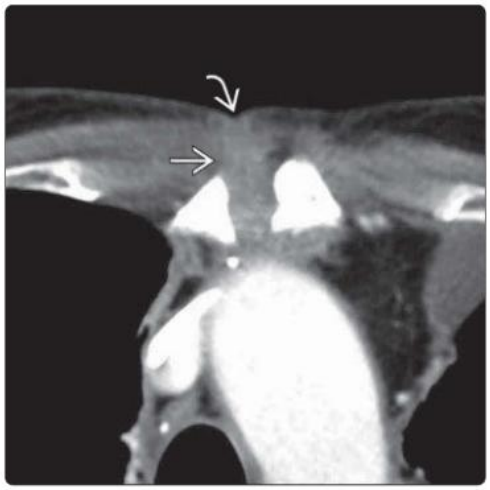

(Left) *Transverse US in the same patient shows the defect ➡ in the manubrium. There is a midline sinus tract ⇄ extending superficially from the manubrium to the skin, associated with diffuse low-grade inflammation of the adjacent soft tissues ➡.* **(Right)** *Longitudinal US of the same region shows the sinus tract ➡ filled with hypoechoic granulation tissue. The sinus tract is extending to a cutaneous opening ⇄. There is no abscess or collection present.*

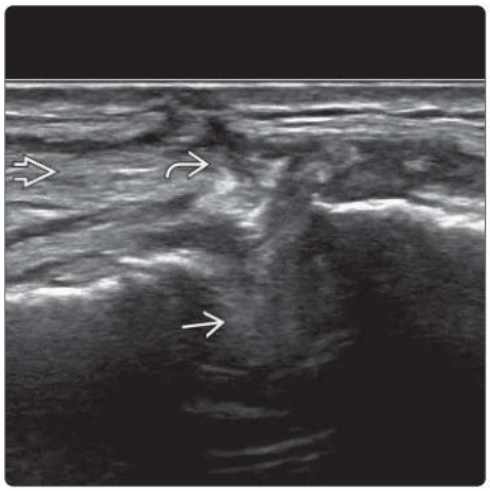

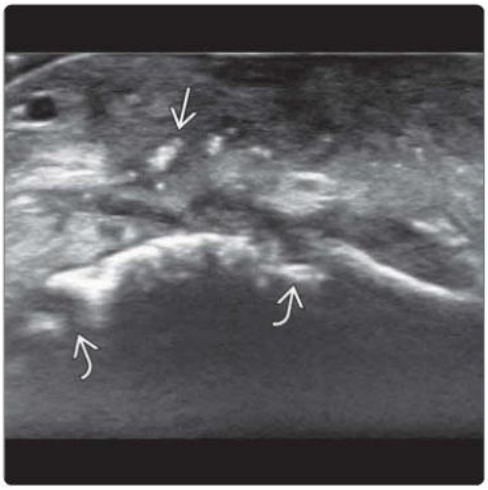

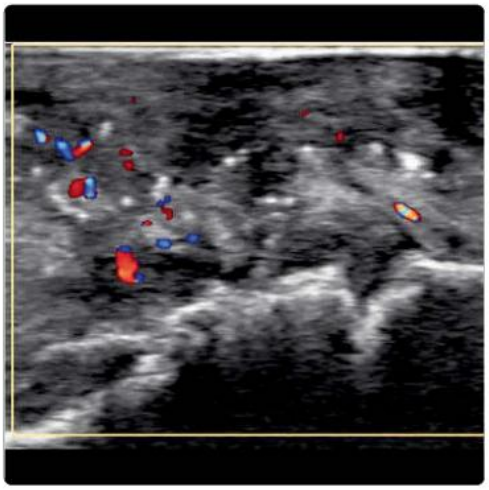

(Left) *Transverse US shows multiple cortical erosions ➡ of the tarsal bones with overlying severe soft tissue thickening and swelling containing echogenic osseous debris ➡ in this 59-year-old man with painful swelling over the dorsal midfoot.* **(Right)** *Corresponding color Doppler US shows moderate soft tissue hyperemia. Features are compatible with chronic osteomyelitis with inflammatory phlegmon. No abscess is present.*

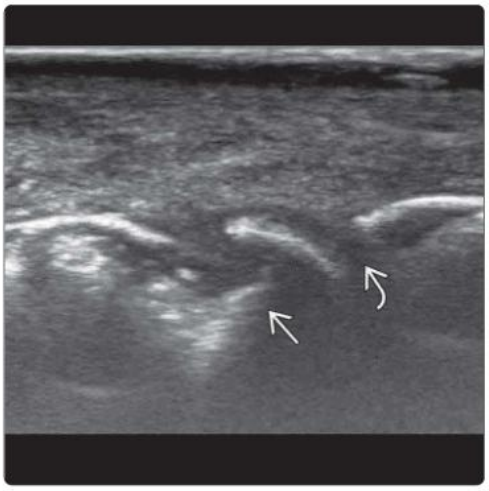

(Left) *CT of the same patient shows patchy osteolysis with sclerosis of the tarsal bones and severe surrounding soft tissue swelling. CT-guided biopsy confirmed chronic osteomyelitis. No organism was cultured from the bone biopsy.* **(Right)** *Longitudinal US of the forefoot in a 66-year-old diabetic man shows a large focal defect ➡ on the dorsum of the 5th metatarsal head with extension of the soft tissue inflammatory process into the medullary canal. Only minimal soft tissue hyperemia was present (not shown). The 5th MTP joint ➡ is normal.*

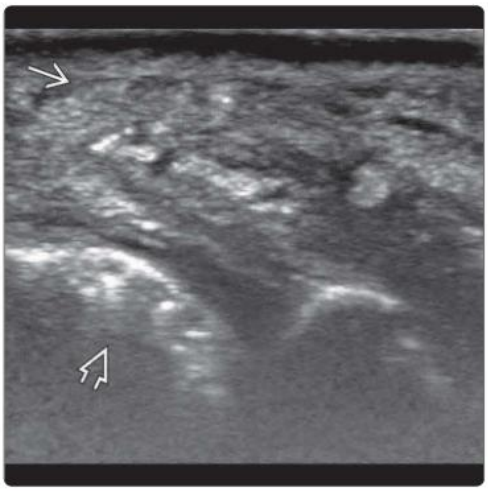

(Left) *Longitudinal US of the same area shows moderate low-grade subcutaneous inflammation ➡ of the dorsal forefoot with cortical resorption of the 5th metatarsal head ➡, compatible with low-grade chronic osteomyelitis.* **(Right)** *Frontal radiograph in same patient shows ill-defined focal lucency of the 5th metatarsal head ➡ with moderate adjacent soft tissue swelling ➡, compatible with a chronic osteomyelitis, which was confirmed on subsequent surgical amputation. Arterial calcification ➡ is present.*

KEY FACTS

IMAGING

- Joint effusion with synovial/capsular thickening ± hyperemia, particularly if low-level echoes present within joint fluid
- Normal US examination excludes septic arthritis
  - Provided joint capsule is intact, then absence of joint effusion or synovial proliferation = no septic arthritis
- **Joint effusion** is cardinal sign of septic arthritis
  - ± fine internal echoes within joint fluid ± swirling echoes
  - In small or nondistensible joints (e.g., acromioclavicular, sternoclavicular, sacroiliac joints), effusion is minimal but synovial/capsular thickening will be present
- Synovial/capsular thickening
  - Chronic infection in prosthetic joints may comprise only synoviocapsular thickening
- Bone & cartilage change
  - Marginal erosion (osteolysis)
  - Progressive joint space narrowing (chondrolysis)
  - Features of osteomyelitis
  - Secondary degenerative change
- Periarticular soft tissue inflammation ± collection
- ± visible capsular rupture
  - ± pericapsular inflammatory mass or abscess
- As chronicity of infection increases
  - Amount of effusion decreases
  - Degree of synovial proliferation, bone & cartilage damage increases
- US appearances of infective arthritis & noninfective inflammatory arthritis overlap considerably
  - Patients with inflammatory arthropathy, osteoarthritis, and joint prosthesis more prone to infection
- Joint fluid aspiration, analysis, & culture best way to exclude joint infection
- Synovial biopsy is excellent alternative if no synovial fluid present
  - Prosthetic joint infections, in particular, tend to have pronounced synovial proliferation & relatively less fluid

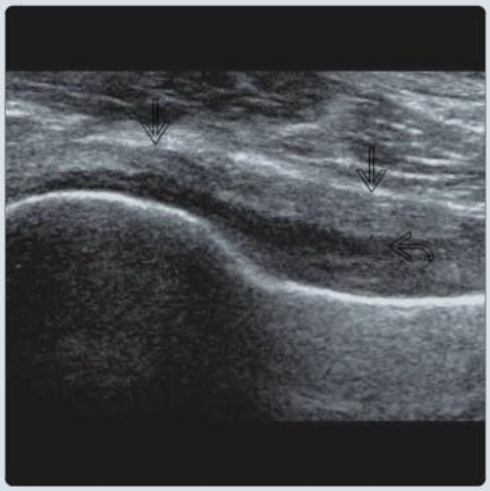

(Left) *Longitudinal US shows a moderate-sized glenohumeral effusion ⇄ with no synovial proliferation due to acute septic arthritis (Salmonella enteritidis). Note the clear visualization of articular cartilage ⇄ and posterior glenoid labrum ⇄.* **(Right)** *Longitudinal US of the hip shows moderate synovial proliferation ⇄ with a small effusion ⇄ in a patient with juvenile rheumatoid arthritis. This may be due to either infective or inflammatory arthritis. Joint aspirate yielded Moraxella species.*

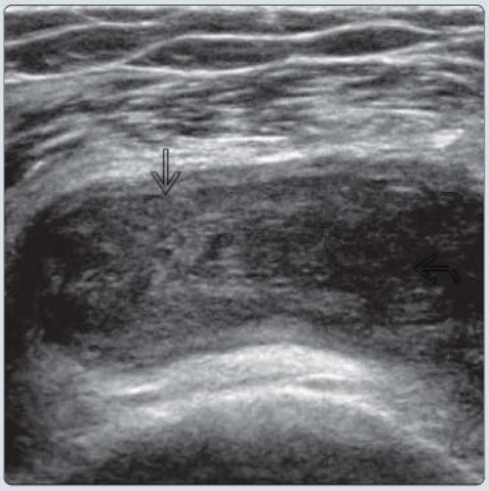

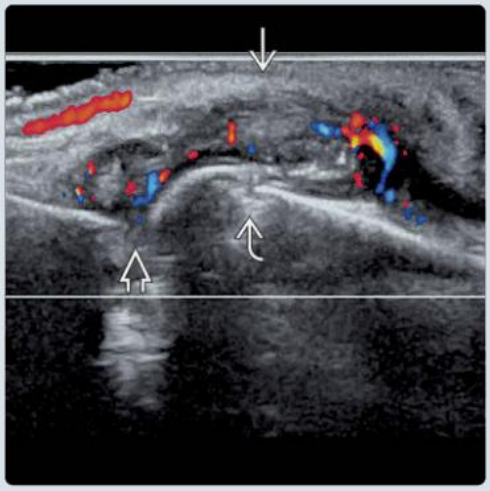

(Left) *Transverse US of the knee shows a small effusion ⇄ in the suprapatellar pouch with severe synovial proliferation ⇄ due to chronic joint infection with Staphylococcus aureus.* **(Right)** *Longitudinal color Doppler US shows moderately hyperemic synovial proliferation ⇄ on the dorsum of the index metacarpophalangeal joint ⇄. There is a small erosion ⇄ of the 2nd metacarpal neck. This arthritis was due to tuberculosis confirmed by histology and microbiology following surgical exploration.*

TERMINOLOGY

Synonyms

- Infective arthritis, septic arthritis

Definitions

- Infection of joint

IMAGING

General Features

- Best diagnostic clue
  - Joint effusion with synovial/capsular thickening ± hyperemia, particularly if low-level echoes present within joint fluid
    - Confirmed by positive joint aspirate or synovial biopsy
- Location
  - Any joint can be infected
    - Knee > hip > shoulder > wrist
      - More common in synovial joints as usually blood-borne infection
    - May be multifocal, especially in at-risk patients
    - Gonococcal arthritis: Predilection for small joints of hands & feet (disseminated gonococcal infection)

Radiographic Findings

- Radiography
  - Early stages: Normal
    - Later visible joint effusion, joint space widening, periarticular swelling & fat plane obliteration, periarticular osteopenia
  - Late stages
    - ± narrowing of joint space (chondrolysis), marginal erosions (osteolysis), secondary osteoarthritis

MR Findings

- T1WI
  - Hypointense or isointense joint effusion
  - ± hypointense periarticular marrow edema, hypointense periarticular soft tissue extension
- T2WI
  - Hyperintense joint effusion with capsular distension
    - ± synovial proliferation, periarticular edema, inflammation, or abscess
- T1WI C+
  - Enhancement of synovium, capsule, pericapsular tissues

Ultrasonographic Findings

- Normal US examination excludes septic arthritis provided that joint is well seen
- **Joint effusion**
  - Cardinal sign of septic arthritis
    - US can detect 1 mL of joint fluid
  - ± clumps of echoes or multiple fine echoes within joint fluid
    - Swirling or moving echoes on real-time imaging
  - Anechoic joint fluid does not exclude septic arthritis
    - Joint aspiration & analysis of joint fluid is only way to truly exclude joint infection
  - In some nondistensible joints (e.g., acromioclavicular, sternoclavicular, sacroiliac joints), effusion is minimal
  - Amount of joint fluid decreases & viscosity of joint fluid increases as infection becomes more chronic
  - Comparison with contralateral joint is helpful
    - Physiological joint fluid is small in degree & usually comparable bilaterally
  - Joint effusion & mild synovitis common in moderate to severe osteoarthritis
    - Is degree of effusion & synovitis commensurate with underlying arthropathy?
      - If more than expected, consider infective arthritis
- **Synovial/capsular thickening**
  - Synovial proliferation & capsular thickening increase as chronicity of infection increases
    - Chronic infection in prosthetic joints may comprise only synoviocapsular thickening
  - ± hyperemia, which reflects severity of active inflammation
  - Prominent synovial/capsular thickening & hyperemia in nondistensible or small joints
  - Disproportionate synovial thickening & prominent periarticular myositis in children should raise suspicion of *Kingella Kingae* infection
- **Bone & cartilage change**
  - Seen in subacute or chronic infection
  - Progressive joint space narrowing (chondrolysis)
  - Marginal erosions (osteolysis)
  - Secondary degenerative change
  - Features of osteomyelitis: Periosteal thickening ± subperiosteal fluid ± cortical resorption
- **Periarticular soft tissue mass/extension**
  - Inflammatory-type periarticular with moderate hyperemia or abscess ± visible capsular rupture
  - Biopsy of this inflammatory-type mass surrounding joint can be confirmatory

Imaging Recommendations

- Best imaging tool
  - US, as nearly all joints are accessible to US examination
    - No metallic artifact from joint prosthesis
- Protocol advice
  - US-guided aspiration for culture, cell count, & crystals (adults) prior to initiation of antibiotics
  - Cell count: Turbid, low-viscosity fluid with leucocyte count > 50,000 per mm^3
    - ~ 90% polymorphs
  - Crystal: Compensated polarized light microscopy sample should be fresh (i.e., not mixed with water or alcohol, as these will dissolve crystals)
    - Concurrent crystalline & infective arthritis may occur
  - Gram stain & culture
    - Send sample for culture immediately
    - Aerobic, anaerobic, mycobacterial, & fungal cultures
    - Gram stain positive in 50% of infective arthritis
    - Culture positive in 90% of infective arthritis
  - rt-PCR of joint fluid or synovial tissue for *Kingella Kingae* in children with initially negative culture or suspicious imaging features
  - US-guided synovial biopsy
    - Indicated if no or only minimal joint fluid is present
    - 100% accuracy for infection of native joints, 78% accuracy for prosthetic joints

- 3 synovial cores sufficient for native joints
- More synovial cores (up to 12) required in prosthetic joints
- ± repeat synovial biopsy if yield negative & clinical suspicion of infection is high

DIFFERENTIAL DIAGNOSIS

Transient Synovitis of Hip

- Self-limiting & predominantly in children
- Echogenic fluid ± synovial/capsular thickening
  - Often subclinical synovitis of contralateral hip

Inflammatory Arthritis

- Patients with chronic arthropathy, differentiated clinically & by aspiration/biopsy
- More pronounced synovial proliferation & hyperemia in active inflammatory arthritis

Crystal Arthropathy

- Synovitis ± effusion ± crystalline particles (seen as echogenic foci)
  - ± periarticular tophi, ± elevated serum uric acid

Hemarthrosis

- Traumatic or spontaneous onset ± underlying coagulopathy
- Finely echogenic fluid similar to acute septic arthritis
  - Synovial/capsular thickening from repeated hemarthrosis

PATHOLOGY

General Features

- Etiology
  - Most commonly due to bacteremic seeding of synovium
  - Less common causes
    - Arthroplasty, spread from adjacent osteomyelitis, needle inoculation, penetrating trauma
- Organisms
  - *Staphylococcus aureus*
    - Most common organism, especially in diabetic & rheumatoid arthritis patients
    - Late (> 3 months) infection of prosthesis
    - Early infection of prosthesis related to surgical contamination & is more commonly due to *Staphylococcus epidermidis*
  - *Streptococcus pyogenes*
  - Gram-negative organisms (*Pseudomonas aeruginosa*, *Escherichia coli*, *Neisseria gonorrhoeae*, *Kingella kingae*)
    - Especially IV drug users, extremes of age, & immunosuppressed patient
    - *Neisseria gonorrhoeae* may lead to disseminated gonococcal infection
    - *Kingella kingae* should be considered as cause of osteoarticular infection in young children
  - Mycobacterium tuberculosis
    - Presents relatively late due to indolent nature with quite pronounced imaging findings & relatively mild clinical symptoms

Gross Pathologic & Surgical Features

- No limiting basement membrane under well-vascularized synovium; facilitates bacterial entry to joint
  - → bacterial adherence & colonization
  - → bacterial proliferation → acute inflammatory response
  - → cytokine release → tissue damage

CLINICAL ISSUES

Presentation

- Most common signs/symptoms
  - Monoarticular new onset pain, swelling, erythema, & limitation of movement ± fever, malaise

Demographics

- Age
  - Young children or older adults
- Sex
  - Nongonococcal arthritis: M:F = 1:1
  - Gonococcal arthritis: M:F = 1:10
- Epidemiology
  - Incidence: 2-10 per 100,000 per year
  - More common in groups of patients with
    - Age over 60 years old
    - Rheumatoid arthritis (10x more common than general population)
    - Diabetes, poor health, on long-term corticosteroid
    - Joint prosthesis

Natural History & Prognosis

- Depends on immunocompetency of host, virulence of organism, rapidity of detection, treatment response
  - Nongonococcal septic arthritis
    - Prognosis is good if detected & treated early (≤ 7 days after symptom onset)
    - Prognosis is poor if > 6 days to make joint (clinically) sterile after onset of treatment
- Morbidity: 5-20% due to bacteremia
  - Septic oligoarthritis (30% mortality)
  - Septic oligoarthritis + rheumatoid arthritis or *Staphylococcus aureus* infection = 50% mortality
- Gonococcal septic arthritis: Good prognosis
  - Symptoms decrease rapidly without sequelae

Treatment

- Conservative
  - IV antibiotics
  - Splinting to prevent contractures
  - ± repeated US-guided aspiration or irrigation
- Arthrotomy, arthroscopic debridement, wound irrigation
- Infected prosthesis usually requires replacement

DIAGNOSTIC CHECKLIST

Consider

- Ultimate diagnosis rests on isolating pathogens from aspirated joint fluid or synovial biopsy
  - Early diagnosis & treatment is key to success
- Normal US examination excludes septic arthritis
  - Nearly all appendicular joints are accessible to US
- US & aspiration establishes diagnosis; MR assesses damage

SELECTED REFERENCES

1. Griffith JF et al: Infection. In Davies M et al: Imaging of the Knee Techniques and Applications. Springer, Cham, 407-26, 2023

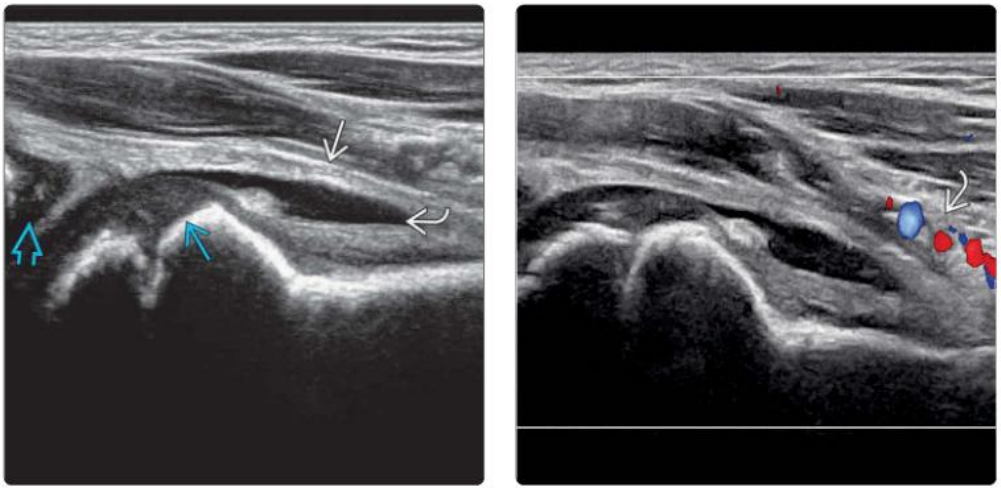

(Left) *Longitudinal US in a child with acute hip pain shows mild synoviocapsular thickening ➡ with a small effusion ⇨. Note the normal, incompletely ossified cartilage of the femoral head ⇨ and acetabulum ⇨.* **(Right)** *Longitudinal color Doppler US shows mild hyperemia ⇨ of the periarticular soft tissues. The US appearances of acute septic arthritis are similar to those of transient synovitis of the hip. Blood culture yielded group D Salmonella indicative of septic arthritis.*

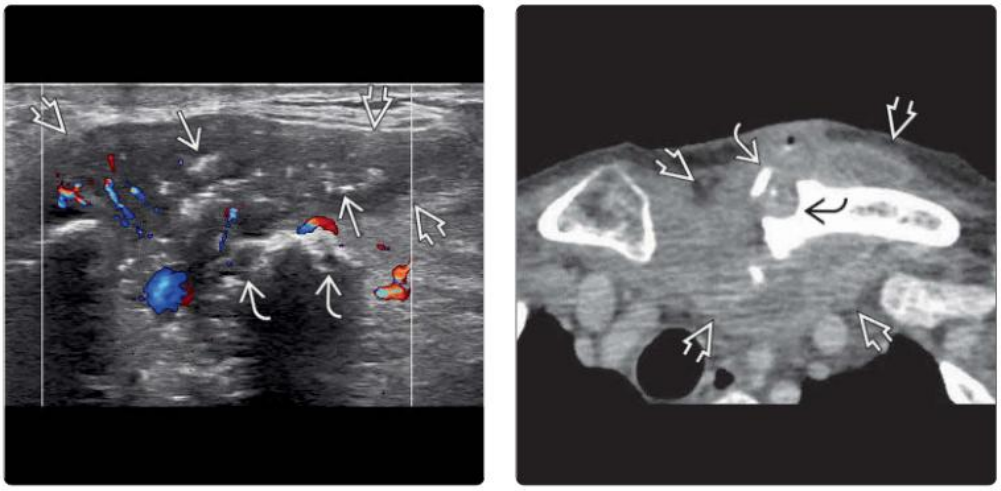

(Left) *US shows destruction of sternoclavicular joint with periarticular erosions ⇨ in the clavicular head and a large, periarticular, inflammatory-type mass ➡ with mild hyperemia and dystrophic calcification ➡, indicative of chronic infection. US-guided biopsy yielded TB.* **(Right)** *Axial CT in the same patient shows severe, established sternoclavicular joint septic arthritis with erosion of the medial clavicle ⇨. A large, periarticular, inflammatory mass ➡ with cystic areas and osseous debris ⇨ is present.*

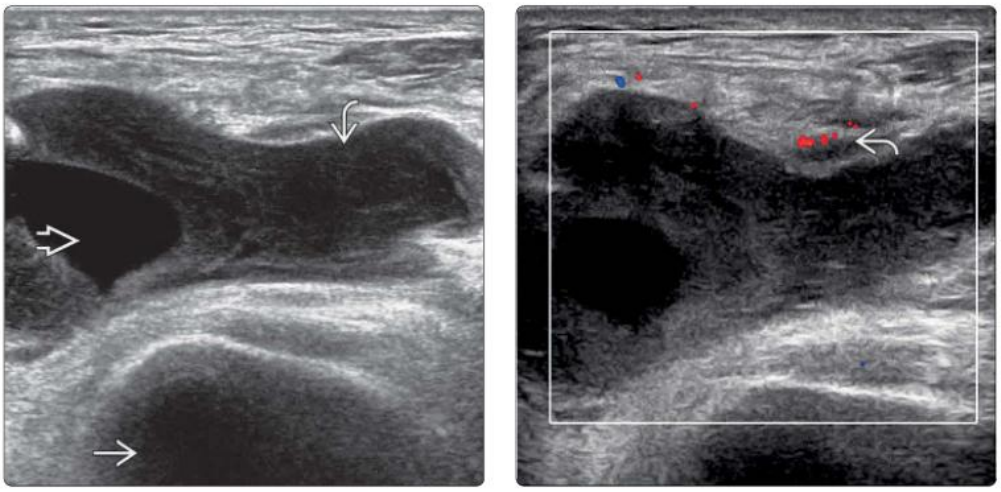

(Left) *Transverse US in a patient with chronic septic arthritis of the knee shows moderate to severe synovial proliferation ⇨ with a relatively small effusion ➡. The distal femur is normal ➡.* **(Right)** *Transverse color Doppler US in the same patient shows only mild peripheral hyperemia ⇨, indicative of low-grade active inflammation. Aspirated joint fluid grew group G Streptococcus.*

(Left) *Longitudinal US of the shoulder in a patient with subacute shoulder pain and swelling shows marked distension of both the subacromial-subdeltoid bursa* ➡ *and the shoulder joint associated with asymmetrical synovial thickening* ➡. **(Right)** *Longitudinal US in the same patient shows multiple nodular* ➡ *fibrinous rice bodies within the distended subacromial-subdeltoid bursa indicating chronic inflammation. US-guided synovial biopsy culture yielded Mycobacterium tuberculosis.*

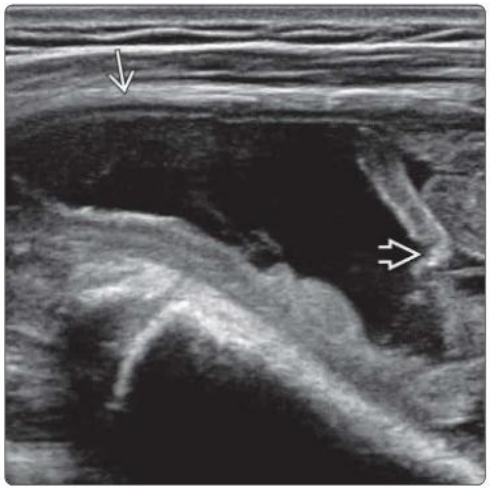

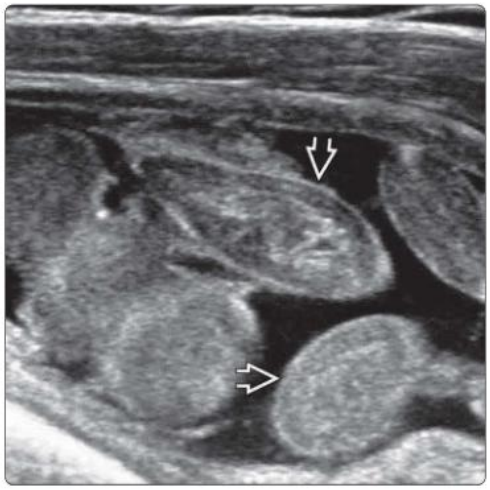

(Left) *Transverse Doppler US in a 81-year-old woman with recent shoulder swelling and pain shows severe active synovial proliferation* ➡ *in the subacromial-subdeltoid bursa with severe hyperemia both within the thickened synovium and in the surrounding periarticular soft tissues, compatible with septic arthritis. A small amount of fluid* ➡ *is present.* **(Right)** *US-guided joint aspiration using a 23-g hypodermal needle* ➡ *yielded small amount of pus, which grew methicillin-resistant S. aureus (MRSA).*

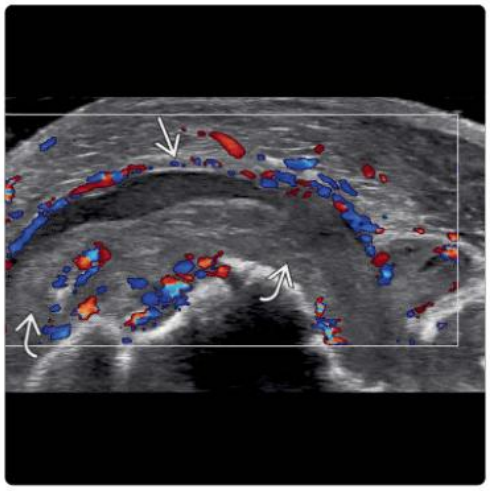

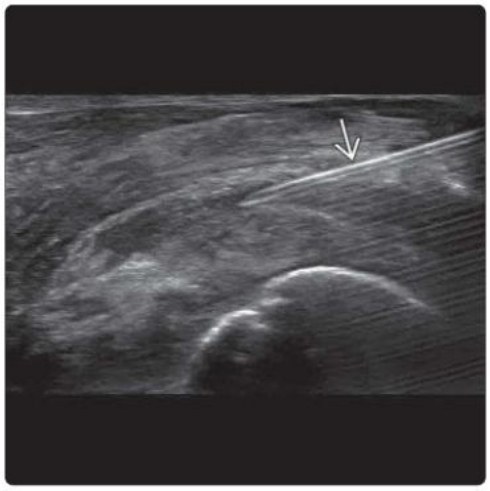

(Left) *Clinical photograph of a patient with a slow-growing hand mass shows a focal swelling* ➡ *with skin discoloration on the dorsoradial aspect of the hand.* **(Right)** *Longitudinal US in the same patient shows a large, heterogeneous mass* ➡ *with internal calcification* ➡ *and moving echoes on real-time imaging. This was confirmed to be due to a tuberculous cold abscess extending from the metacarpophalangeal joint* ➡ *into the subcutaneous soft tissues.*

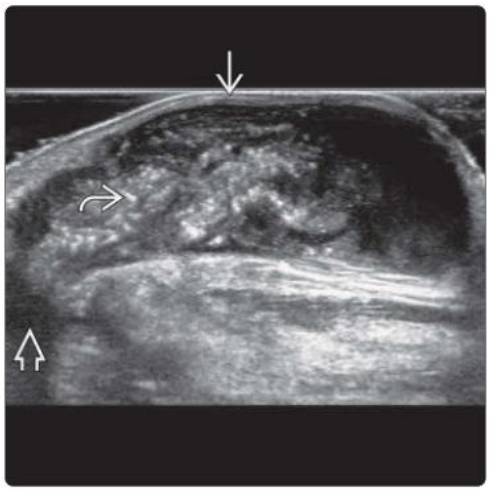

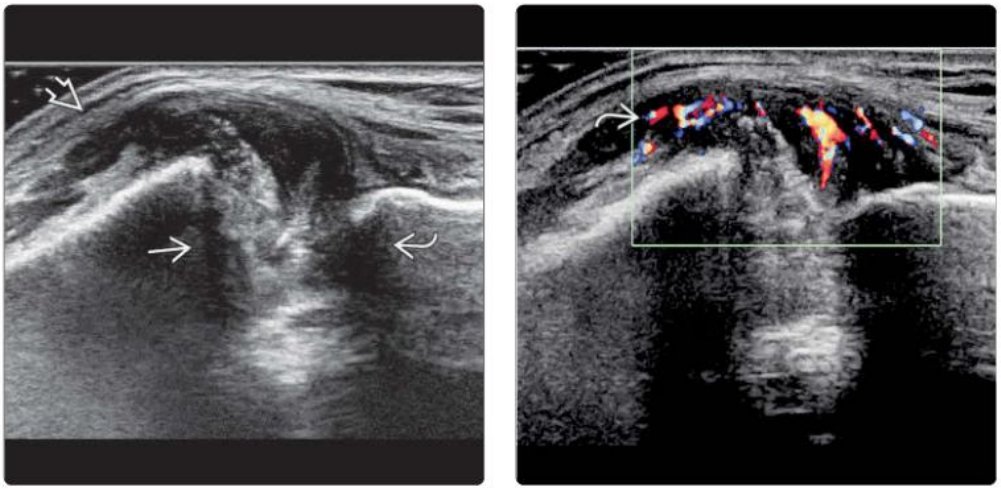

(Left) *Transverse US shows a widened sternoclavicular joint between the medial end of the clavicle ➡ and the sternum ➡ with capsular disruption superficially leading to a medium-sized periarticular inflammatory mass ➡.* **(Right)** *Transverse color Doppler US shows hyperemia ➡ indicating joint distension by inflammatory tissue rather than fluid. This patient had concomitant streptococcal septic arthritis of the knee. The sternoclavicular joint septic arthritis settled with antibiotics.*

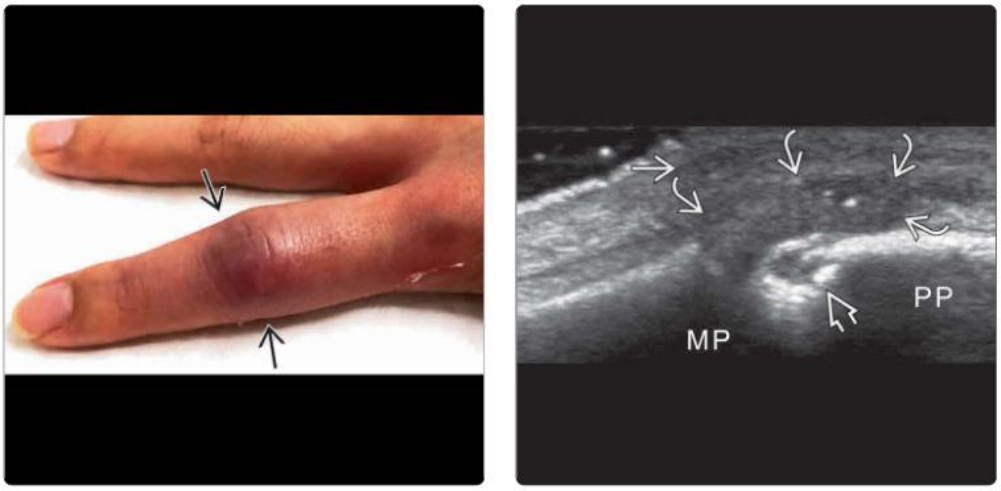

(Left) *Clinical photograph of the middle finger of a 28-year-old female psychiatric nurse bitten by a patient 2 weeks prior shows focal swelling and erythema around the proximal interphalangeal joint ⇨.* **(Right)** *Longitudinal US in the same patient shows marked soft tissue swelling ➡ on the dorsum of the proximal interphalangeal joint with moderate, ill-defined synovial thickening ➡. There is also an adjacent bony defect on dorsal aspect of the head of proximal phalanx (PP) ➡. MP = middle phalanx.*

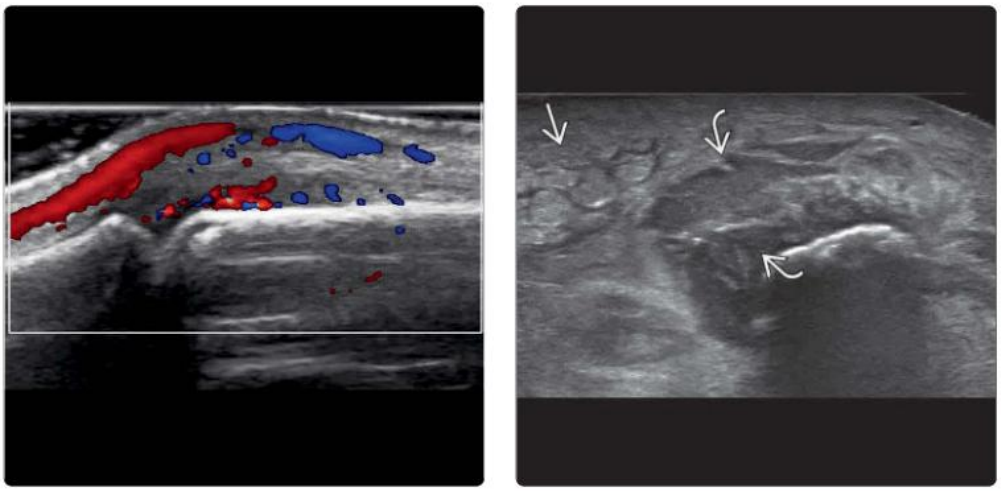

(Left) *Doppler US in the same patient shows marked marginal and synovial hyperaemia. US was suggestive of a subacute septic arthritis with osteomyelitis, which was confirmed surgically.* **(Right)** *Longitudinal US in a 66-year-old woman with acute pain and swelling of the acromio-clavicular joint shows a multiloculated collection ➡ on the anterosuperior aspect of the joint. There is moderate overlying subcutaneous cellulitis ➡. Aspiration yielded MRSA.*

KEY FACTS

TERMINOLOGY

- Infection at surgical site within 1 month of surgery or within 1 year of prosthetic implantation

IMAGING

- US not prone to metallic artifact & suited to assessment of postoperative patient
- Mild soft tissue edema, fluid, & hyperemia are very common signs in early postoperative period
- Intensity & pattern of edema, fluid, & hyperemia helps differentiate infectious from noninfectious inflammation
  - Inflammation from surgical disruption of tissues & subsequent repair follows expected pattern & is usually mild in degree
  - Inflammation from postoperative infection is more severe & does not follow expected pattern
- Edematous tissue = hyperechoic if mildly edematous, hypoechoic if more intensely edematous
- Fluid of variable echogenicity may collect as discrete collection or accumulate at fascial or tissue interfaces
  - Cannot reliably differentiate between infected collection & noninfected collection
  - Check gravity-dependent areas around surgical site as fluid will tend to collect here
- Synovial biopsy helpful to exclude suspected prosthetic joint infection, if no joint effusion exists

TOP DIFFERENTIAL DIAGNOSES

- Postoperative inflammation
- Hematoma
- Deep venous thrombosis

DIAGNOSTIC CHECKLIST

- US helps to define site of soft tissue infection, isolate fluid, & provide aspirate for culture
- ± US-guided soft tissue biopsy if no fluid collection seen
- Synovial biopsy should be repeated on 3 separate occasions before prosthetic joint infection can be fully excluded

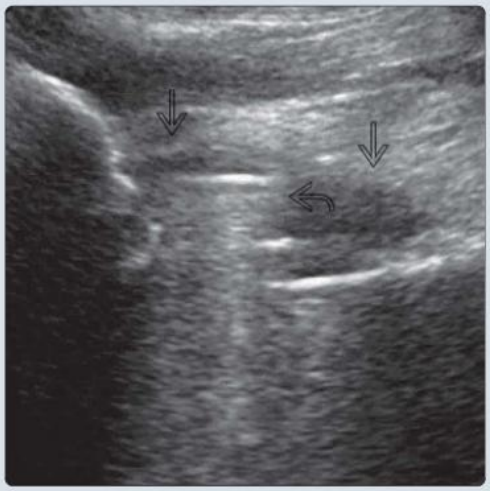

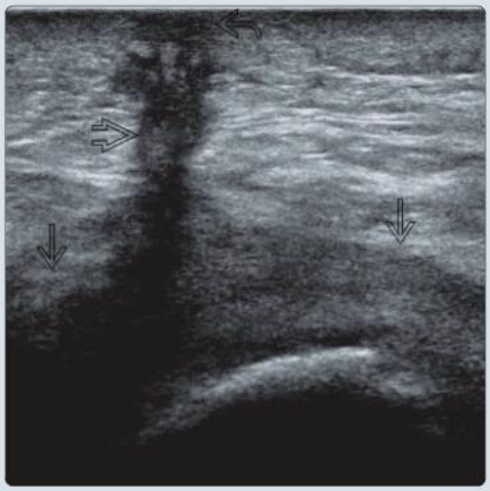

(Left) *Longitudinal US shows mild distention of a prosthetic hip joint ⇨ with a small amount of internal gas ⇨. This is a normal appearance 1 week after hip surgery.* **(Right)** *Longitudinal US in a patient with hip surgery 2 months prior shows a moderately thick band of granulation tissue ⇨ extending from the distended hip joint ⇨ to the cutaneous wound ⇨. Color Doppler US (not shown) revealed only mild hyperemia. This is a normal postoperative appearance.*

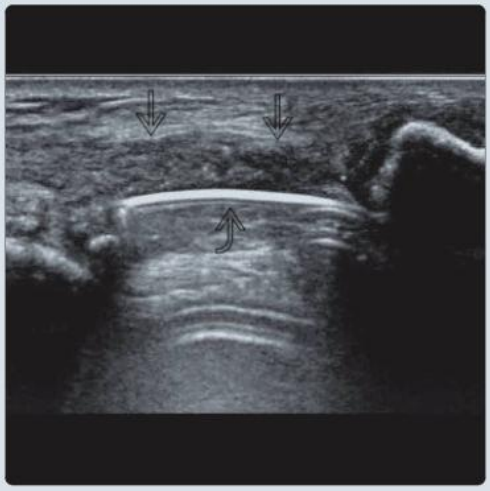

(Left) *Transverse US shows an infected hypoechoic collection ⇨ at the lateral aspect of the proximal femur ⇨ in a patient with hip implant revision 2 weeks previously. There is moderate surrounding deep soft tissue edema ⇨ and subcutaneous soft tissue edema ⇨.* **(Right)** *Transverse US in a patient with an infected elbow implant shows a moderate degree of inflammatory soft tissue ⇨ and edema surrounding the implant ⇨.*

TERMINOLOGY

Definitions

- Infection at surgical site within 1 month of surgery or within 1 year of surgical implant

IMAGING

General Features

- Best diagnostic clue
  - Inflammation ± collection persisting > 1 week after surgery
- Location
  - Soft tissue, joint or bone
  - Hip, knee, spine, or any operative site
- Morphology
  - From localized wound infection to acute osteomyelitis

Radiographic Findings

- Progressive osteolysis is key to recognizing infection
  - Aids interpretation of US & other investigations
- Radiographs normal in 50% of periprosthetic implant infections

CT Findings

- CECT
  - CT less prone to metallic artifact than MR
    - CT or MR provides more reliable assessment of infection after implant has been removed
  - Delineates bony abnormality & soft tissue infection
    - ± CT-guided aspiration or drainage

MR Findings

- MR often limited by metallic susceptibility artifact
- T1WI
  - Hypointense soft tissue swelling
- T2WI FS
  - Hyperintense soft tissue swelling ± hyperintense fluid or fluid collection
- T1WI C+
  - Infective, noninfective, inflammatory, & reparative tissue all enhance
    - Generally, greater enhancement indicates more likely infection
  - Useful at delineating fluid collections
    - Degree of wall enhancement is greater with abscesses than with sterile collections

Ultrasonographic Findings

- US is not prone to metallic artifact
  - Good visualization of preprosthetic soft tissues
- US can access most postoperative locations
- Helps localize site of infection (superficial or deep), identify drainable collection, & guide fluid aspiration or tissue biopsy for diagnosis
- Mild soft tissue edema, joint fluid & capsular hyperemia are common early postoperative findings
- Intensity & pattern of edema, fluid, & hyperemia helps differentiate infectious from noninfectious inflammation
  - Inflammation from surgical disruption of tissues & subsequent repair follows expected pattern & is usually mild in degree
  - Inflammation from postoperative infection is more severe & does not follow expected pattern
- Greater the degree of soft tissue edema & inflammation, greater the likelihood of postoperative infection
- Edematous tissue is hyperechoic if mildly edematous, hypoechoic if more intensely edematous
- Fluid may collect as discrete collection or along fascial & tissue interfaces
  - Usually accumulates at most dependent areas
  - Anechoic, hypoechoic, or hyperechoic fluid collection
  - ± echogenic debris
  - Usually unable to distinguish between infected collection, noninfected seroma, and liquefied hematoma
    - Need to aspirate fluid for microbiology, cell count, & biochemical analysis
    - Synovial fluid leukocyte count, percentage of polymorphonucleocytes, C-reactive protein (CRP), & other synovial fluid biomarkers are predictive of periprosthetic joint infection
      - Combined synovial fluid CRP > 7.26 mg/L & serum CRP > 10.2 mg/L has high PPV for periprosthetic joint infection
- Synovial/capsular thickening is common after surgery
  - Joint capsule disruption during surgery or arthroplasty
    - Limits development of postoperative effusion
      - If capsule has been disrupted, there may be little, if any, joint effusion even with infection as joint fluid drains into periarticular tissues
  - Synovial thickening does not imply infection
    - Synovial biopsy has 78% accuracy for injection of prosthetic joint when no joint fluid present to aspirate
    - Need to take up to 12 cores of synovial tissue for culture as bacterial load in synovium typically low
      - Repeat biopsy 3x if clinical suspicion high
- ± gas around operative site
  - May be present normally days after surgery or longer with open wound or drain inserted
- Limitations of US
  - Cannot differentiate mild postoperative infection from noninfective postoperative inflammation
  - Transducer access is occasionally limited by external fixators, bandaging, or cutaneous wound
    - Some areas, such as spine, have limited transducer access
  - Not sensitive at detecting osteomyelitis
- Synovial biopsy should be performed to exclude prosthetic infection when there is clinical suspicion

Nuclear Medicine Findings

- Bone scan
  - Used for diagnosis of periprosthetic infection & best if combined with labeled leukocyte scintigraphy or gallium scintigraphy
  - No periprosthetic uptake = no infection
  - Periprosthetic uptake indicates loosening or infection
    - Uptake at same site on labeled leukocyte scintigraphy or gallium scintigraphy makes infection likely
    - No uptake at same site on labeled leukocyte scintigraphy or gallium scintigraphy makes loosening more likely
  - High sensitivity with moderate specificity

- PET/CT
  - Combines high sensitivity of PET imaging with high resolution of CT imaging
    - Decreased specificity, particularly in postoperative cases
    - Glucolysis also feature of noninfectious inflammation & repair
  - Activity around shaft and tip of hip prosthesis increases likelihood of infection compared to activity around head & neck of prosthesis

Imaging Recommendations

- Best imaging tool
  - US
- Protocol advice
  - Remove bandaging; cover suture line with thin polyurethane adhesive dressing
  - Examine gravity-dependent areas carefully since collections will preferentially accumulate there
    - e.g., following hip arthroplasty, roll patient to lateral decubitus position to examine gluteal & posterior thigh regions
  - Perform US-guided aspiration of joint or fluid collection ± US-guided biopsy of synovium or inflammatory soft tissue
    - If performing aspiration, ensure meticulous aseptic technique, as damaged tissues are particularly susceptible to bacterial inoculation

DIFFERENTIAL DIAGNOSIS

Postoperative Inflammation/Prosthetic Synovitis

- Difficult to distinguish from postoperative infection
- Pattern & intensity of edema, fluid accumulation, & degree of hyperemia are helpful in making this distinction

Hematoma

- Hypoechoic avascular mass with fixed fine internal echoes

Deep Venous Thrombosis

- May coexist with postoperative infection
- Noncompressible vein

PATHOLOGY

General Features

- Etiology
  - Risk of infection following knee or hip arthroplasty = 0.5-2.0%
    - Early infection (< 3 months after surgery) is mostly due to surgical contamination
    - Late infection (within 1 year of surgery) is mostly due to hematogenous seeding of operative site
    - Prostheses: Disrupt integrity of tissues, affect blood supply, & provide surface for bacterial adherence
  - *Staphylococcus aureus*
    - Responsible organism in 1/2 of cases
  - Gram-negative bacilli (*Bacteroides*, *Escherichia coli*, *Pseudomonas*, *Proteus*, *Klebsiella*, *Enterococcus*)

Gross Pathologic & Surgical Features

- Cellulitis, pyomyositis, abscess

Microscopic Features

- Acute or acute on chronic inflammatory infiltrate, capillary dilatation ± abscess formation

CLINICAL ISSUES

Presentation

- Most common signs/symptoms
  - Pain & swelling
- Other signs/symptoms
  - Wound oozing, inflammation, fever
- Clinical profile
  - Leukocytosis, raised inflammatory markers

Demographics

- Age
  - Less common in young patients
- Epidemiology
  - Risks related to surgery
    - Long operation time (> 3 hours), high blood loss (> 1,000 mL), instrumentation, multiple surgical sites (e.g., fixation + bone grafting), staged operation or repeat operation
  - Risks related to patient
    - Frailty, coexistent morbidity, coexistent remote site infection, obesity, smoking

Natural History & Prognosis

- Superficial infection can usually be treated successfully with antibiotic therapy
- Established deep infection is often difficult to eradicate without removing implant

Treatment

- Antibiotic therapy
- Aspiration or drainage (US guided) of collection(s)
- ± debridement
- ± implant removal & revision

DIAGNOSTIC CHECKLIST

Consider

- Accurate & timely recognition is key to successful eradication of postoperative infection
- Most postoperative infections are clinically evident
  - US helps to define site of soft tissue infection, isolate fluid, & provide aspirate for culture
  - Accuracy of single synovial biopsy is less in prosthetic joints
    - Synovial biopsy should be repeated on 3 separate occasions before prosthetic joint infection can be fully excluded
- Integrity of recently operated bone is impaired
  - If juxtacortical infection present, high probability that bone is also infected

SELECTED REFERENCES

1. Shihabul Hassan M et al: Current updates in MSK infection imaging: a narrative review. J Clin Orthop Trauma. 51:102396, 2024
2. Macnair R et al: Image-guided synovial biopsy with a focus on infection. Skeletal Radiol. 52(5):831-41, 2023

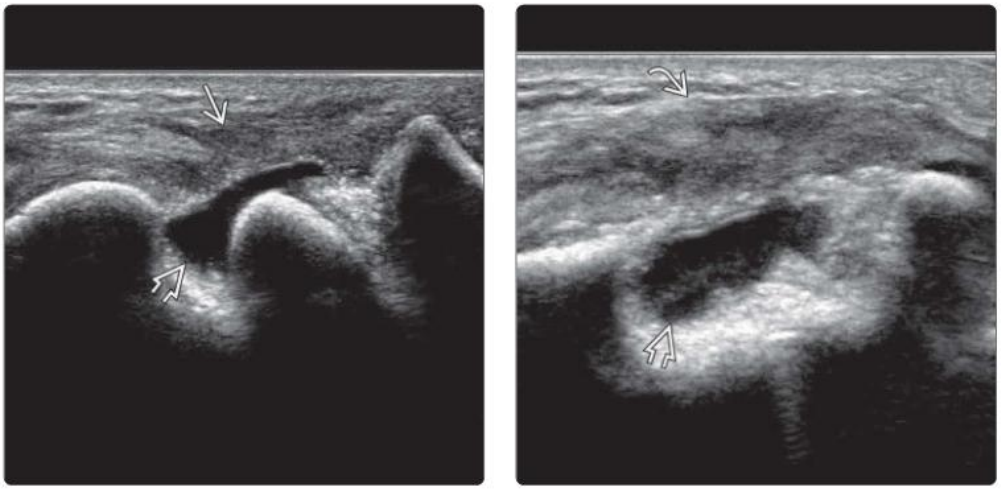

(Left) *Longitudinal US in a patient after elbow replacement shows mild fluid distention of the elbow joint* ➡ *with marked capsular thickening and periarticular soft tissue edema* ➡. **(Right)** *Transverse US in the same patient shows a small effusion* ➡ *but more severe capsular thickening* ➡. *This degree of capsular thickening and joint fluid is common in the early postoperative period and does not necessarily imply infection.*

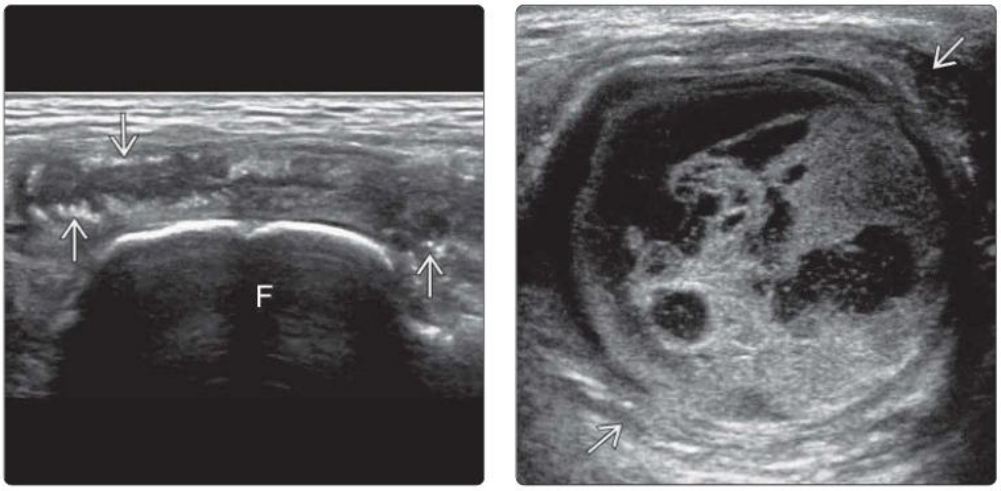

(Left) *Transverse US of a prosthetic knee joint shows linear echogenic foci* ➡ *lining the inner margin of the moderately thickened synovium representing a "metal-line," indicative of chronic prosthetic synovitis. There was no hyperemia. Synovial biopsy confirmed aseptic prosthetic synovitis, without active infection. F = femur.* **(Right)** *Transverse US in a patient after groin surgery shows an echogenic collection* ➡ *with a thickened wall and multiple fine internal echoes due to an infected organizing hematoma.*

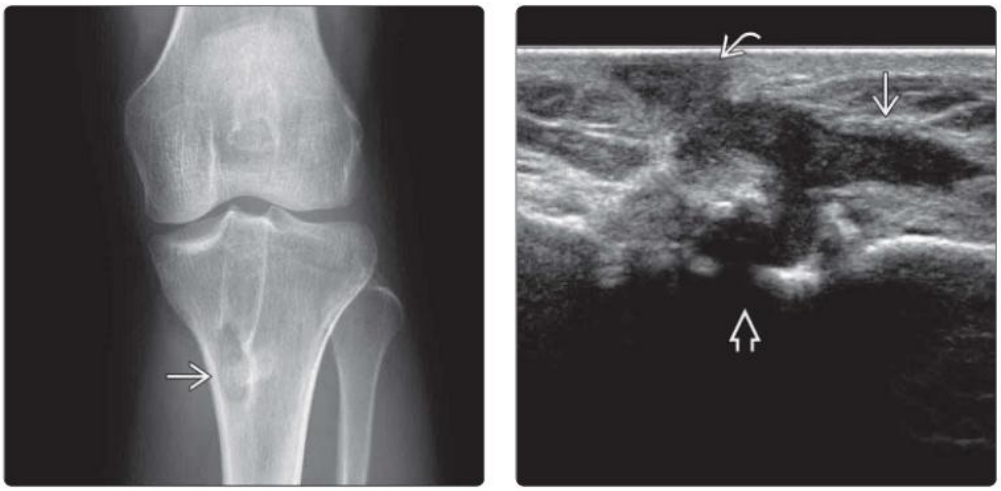

(Left) *Frontal radiograph in a patient with previous anterior cruciate ligament grafting shows an area of osteolysis* ➡ *with a partially sclerotic border at the distal end of the tibial tunnel.* **(Right)** *Longitudinal US in the same patient shows hypoechoic inflammatory tissue* ➡ *adjacent to the tibial tunnel cortical defect* ➡ *extending to the skin* ➡. *The combined radiographic and US features are consistent with postoperative infection of the tibial tunnel.*

(Left) *Transverse US in the same patient shows moderate cortical irregularity around the tibia tunnel opening with juxtacortical hypoechoic inflammatory tissue.* **(Right)** *Transverse color Doppler US in the same patient shows a mild degree of hyperemia within the hypoechoic inflammatory soft tissue. This hyperemia is helpful at differentiating hypoechoic inflammatory tissue from fluid.*

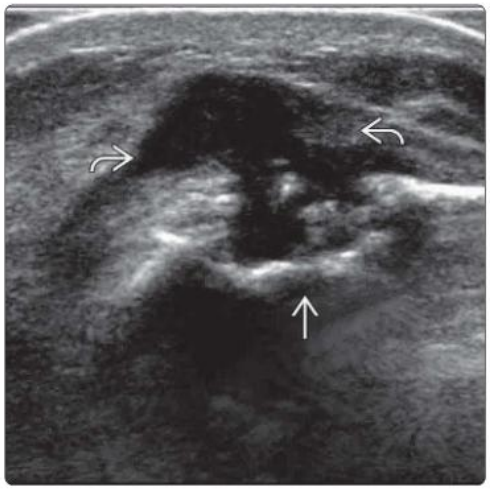

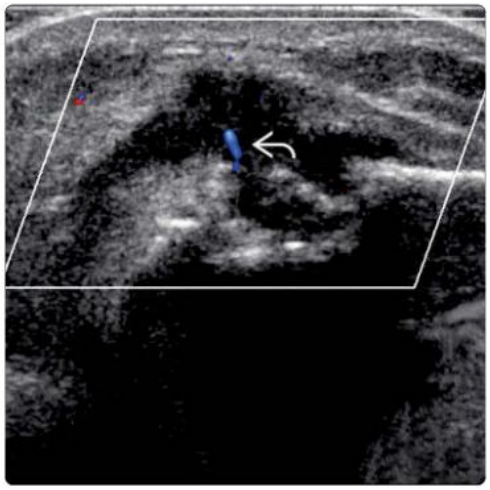

(Left) *Longitudinal US shows a periprosthetic infection of the hip with a moderate degree of hypoechoic inflammatory soft tissue adjacent to the prosthesis. There is a small anechoic fluid component within the inflammatory soft tissue.* **(Right)** *Longitudinal US in the same patient in a slightly more lateral location shows multiple echogenic foci due to surgically implanted antibiotic beads within the soft tissues.*

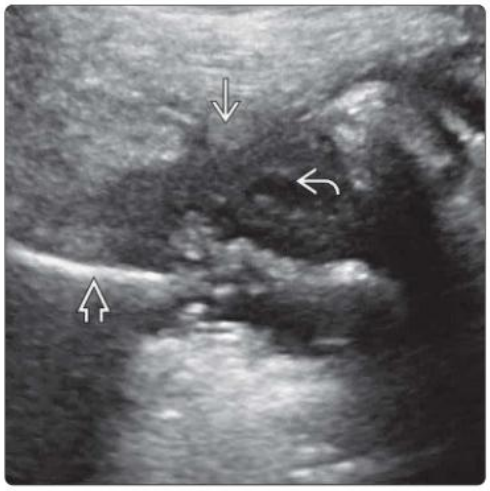

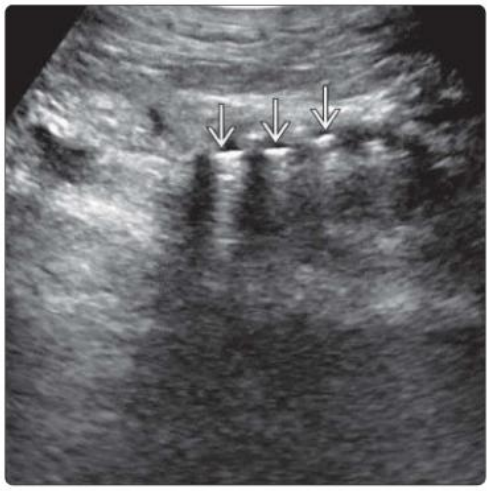

(Left) *Longitudinal US in a patient with an infected elbow replacement shows severe periprosthetic soft tissue edema. There is a small amount of fluid or very edematous inflammatory tissue immediately alongside the prosthesis.* **(Right)** *Longitudinal color Doppler US in the same patient shows moderate hyperemia of the inflamed periprosthetic soft tissue. The periprosthetic hypoechogenicity is due to edematous inflammatory tissue rather than fluid.*

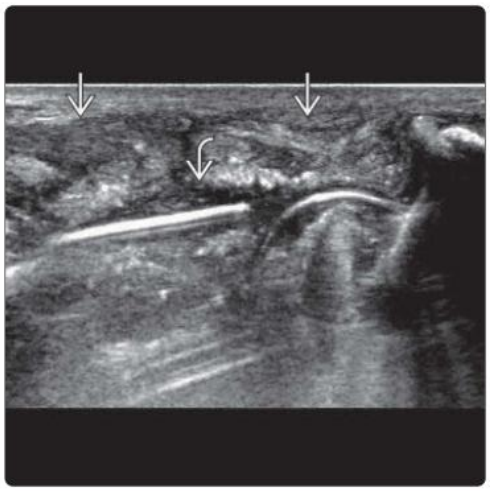

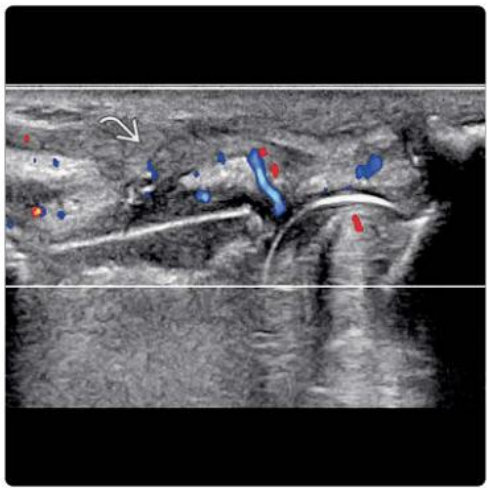

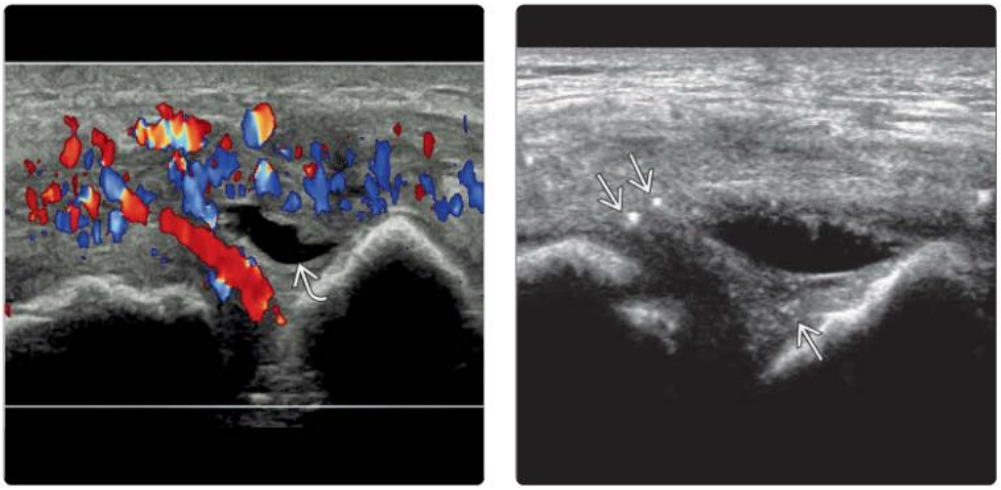

(Left) *Transverse US of a suspected infected prosthetic knee joint shows markedly thickened knee joint synovium with severe hyperemia. A small amount of joint fluid is present.* **(Right)** *Longitudinal US in the same patient shows echogenic metallic deposits lining the inner margin of the thickened knee joint synovium. These features are in keeping with chronic prosthetic synovitis with superimposed acute prosthetic septic arthritis. Synovial biopsy grew Staphylococcus aureus.*

(Left) *Clinical photograph of a patient with total knee replacement shows swelling and erythema of the skin around the surgical scar.* **(Right)** *Transverse color Doppler US of the same area shows severe synovial proliferation with hyperemia indicative of moderately active infective synovitis. Note linear echoes from metallic debris within the medium-sized joint effusion. Joint aspiration grew S. aureus.*

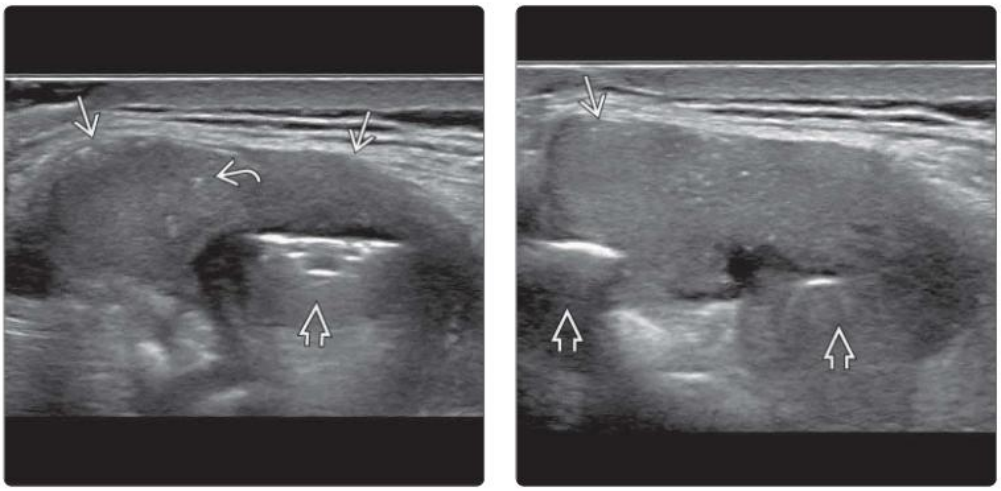

(Left) *Transverse US in an 80-year-old woman with increasing pain at the site of posterior spinal fixation shows a medium-sized gelatinous-type fluid collection alongside T12 screw with small echogenic foci, possibly due to calcification.* **(Right)** *Longitudinal US of the same area shows the collection straddling adjacent spinous processes. Color Doppler US showed no hyperemia. This favored a chronic periprosthetic abscess. Aspiration yielded 15 mL of purulent fluid, which grew Mycobacterium tuberculosis.*

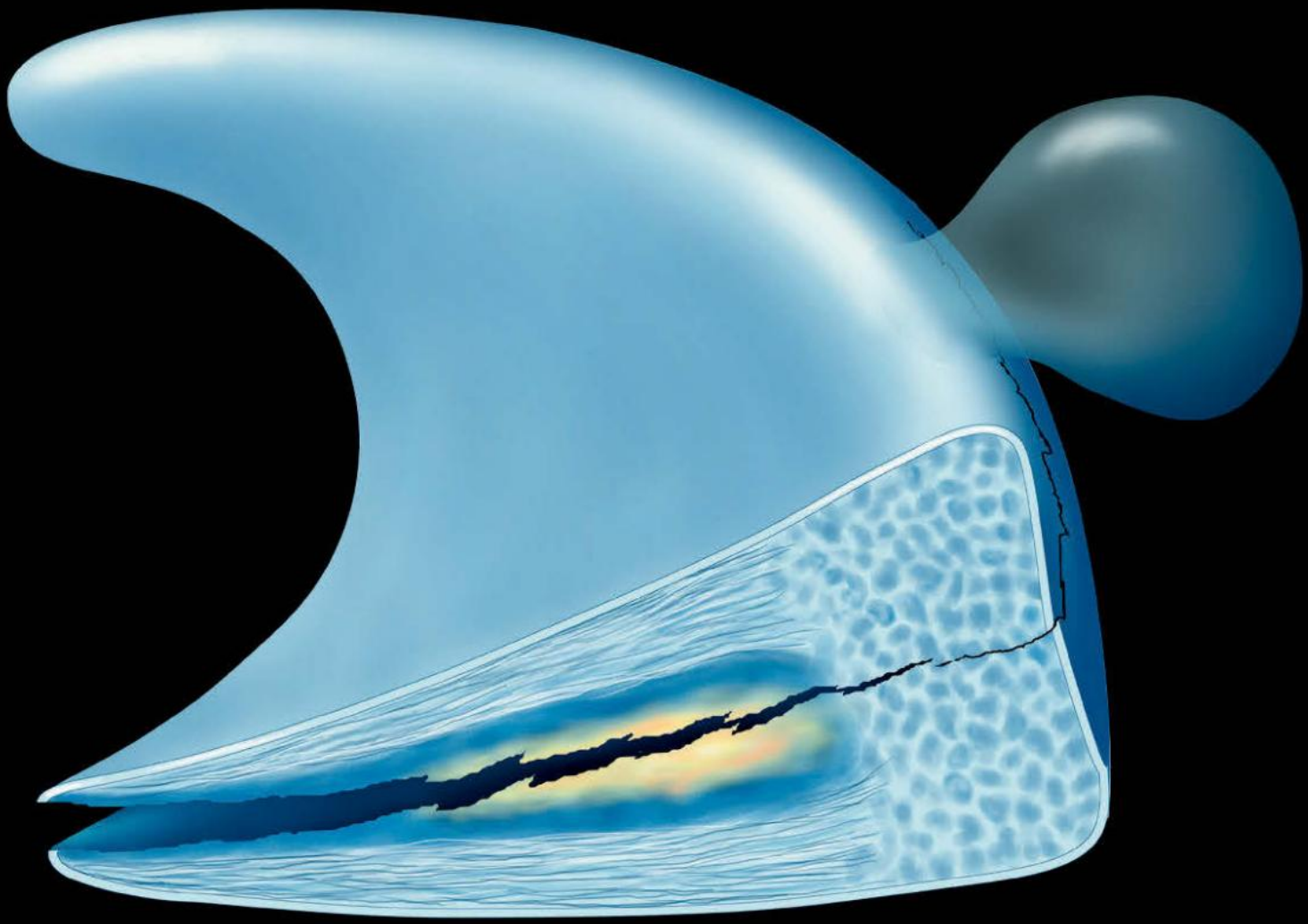

PART III
SECTION 6

Articular and Paraarticular Masses

Hemarthrosis and Lipohemarthrosis	668
Baker Cyst	672
Bursitis	678
Ganglion Cyst	690
Parameniscal Cyst	700
Synovial Tumor	704

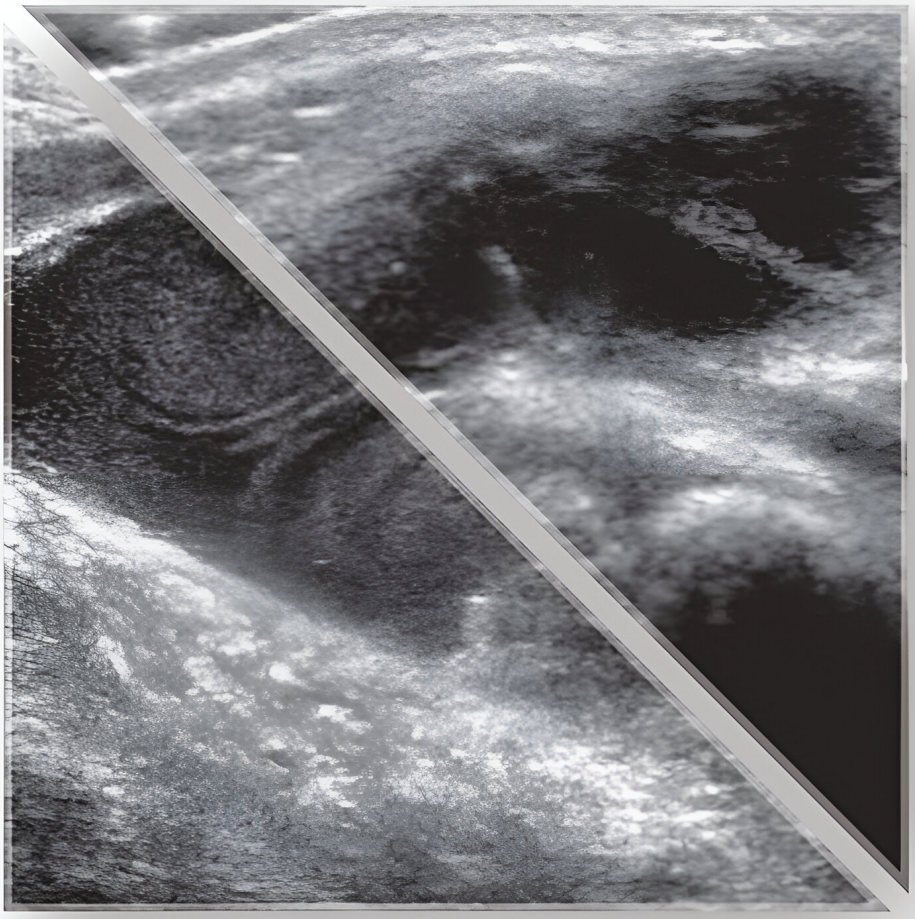

KEY FACTS

TERMINOLOGY

- Hemarthrosis: Blood in joint cavity
- Lipohemarthrosis: Blood & fat in joint cavity

IMAGING

- Layered joint effusion
- **Hemarthrosis initially seen as finely speckled echogenic joint fluid**
  - After ~ 5 minutes, may become 2-layered joint effusion
  - Superficial hypoechoic layer represents supernatant serum
  - Deep hyperechoic layer represents dependent red blood cells (RBCs)
- **Lipohemarthrosis initially seen as finely speckled echogenic joint fluid**
  - After ~ 10 minutes, may become 3-layered joint effusion
  - Superficial hyperechoic layer represents floating fat
  - Central hypoechoic layer represents supernatant serum
  - Deep hyperechoic layer represents dependent RBCs
  - ± hypoechoic areas within floating fat due to trapped blood
- **Hemophilia early arthropathy detection with US score (HEAD-US)**
  - Targeted examination of elbow, knee, ankle
  - Synovial hypertrophy graded as 0 (absent/minimal), 1 (mild/moderate), or 2 (severe) synovial proliferation
  - Subchondral bone graded as 0 (normal), 1 (mild), or 2 (moderate/severe) subchondral bone irregularity ± osteophytes
  - Cartilage thinning graded as 0 (normal), 1 (mild), 2 (moderate), 3 (severe), or 4 (complete) thinning

TOP DIFFERENTIAL DIAGNOSES

- Septic arthritis
- Gout
- Inflammatory synovitis

DIAGNOSTIC CHECKLIST

- Lipohemarthrosis is marker of intraarticular fracture

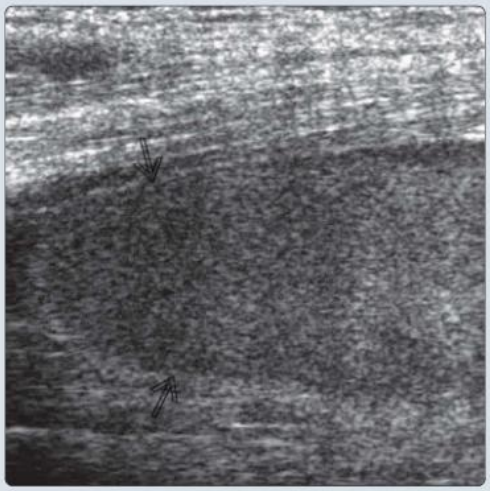



(Left) *Longitudinal US of suprapatellar pouch following knee trauma shows a distended joint capsule* ⇨ *with echogenic fluid consistent with hemarthrosis. No layering or sedimentation is present.* **(Right)** *Longitudinal US 15 minutes later at the same location shows the 3-layered appearance of lipohemarthrosis. The fat layer* ⇨*, serum layer* ⇨*, and cellular [red blood cell (RBC)] layer* ⇨ *are now apparent.*

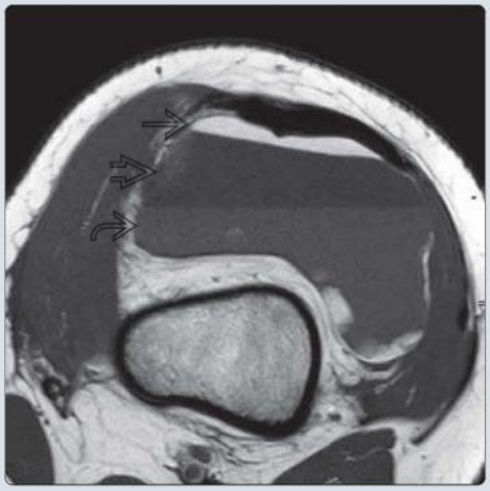

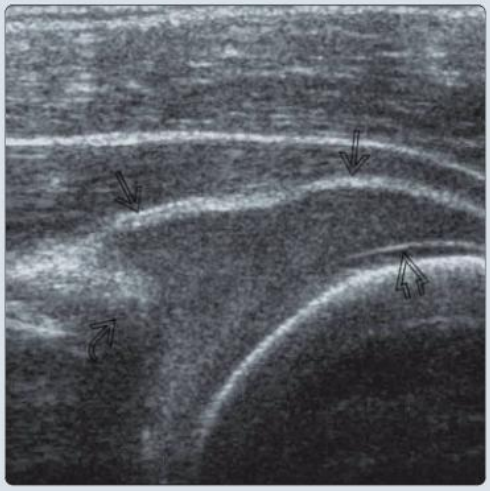

(Left) *Transverse T1 MR in a patient with patellar fracture shows the 3-layered appearance of lipohemarthrosis with fat* ⇨*, serum* ⇨ *and cellular* ⇨ *layers. The fat layer originates from leakage of fatty marrow.* **(Right)** *Transverse US of the posterior aspect of glenohumeral joint shows acute hemarthrosis with a distended joint capsule* ⇨*. No layering is present. Glenoid labrum* ⇨ *is shown as is the articular cartilage of humeral head* ⇨*. Shoulder joint hemarthrosis may accompany massive rotator cuff tear.*

TERMINOLOGY

Synonyms

- Posttraumatic hemarthrosis or lipohemarthrosis
- Spontaneous hemarthrosis
- Hemophilic arthropathy

Definitions

- Hemarthrosis: Blood in joint cavity
- Lipohemarthrosis: Blood & fat in joint cavity
  - Very specific for intraarticular fracture
- Spontaneous hemarthrosis: Hemarthrosis developing in absence of predisposing trauma, synovial tumor, or hemophilia
- Hemophilic arthropathy: Arthropathy secondary to repeated hemarthrosis due to inherited clotting disorder

IMAGING

General Features

- Best diagnostic clue
  - Layered joint effusion
- Location
  - Knee > ankle > elbow > shoulder > hip

Radiographic Findings

- Hyperdense joint effusion
  - Density of hemorrhage > simple synovial fluid
- Horizontal beam radiography for lipohemarthrosis: Fat-fluid level due to attenuation differences in fat & blood components
  - Fat is less dense & floats on blood surface
  - Lipohemarthrosis is present in 35% of knee intraarticular fractures
    - High specificity but low sensitivity for intraarticular fractures

CT Findings

- NECT
  - Hemarthrosis: 2 distinct layers
    - Superficial isodense layer [~ 30 Hounsfield units (HU)] = serum
    - Deep hyperdense layer (~ 70 HU) = red blood cells (RBCs)
  - Lipohemarthrosis: 3 distinct layers
    - Superficial hypodense layer (~ -70 HU) = fat
    - Central intermediate layer (~ 20 HU) = serum
    - Deep hyperdense layer (~ 90 HU) = RBCs

MR Findings

- T2WI
  - Hemarthrosis: 2 distinct signal bands
    - Superficial hyperintense band = serum
    - Deep isointense band = dependent RBCs
  - Lipohemarthrosis: 3 distinct signal bands
    - Superficial hyperintense band = floating fat
    - Central hyperintense band = serum
    - Deep isointense band = dependent RBCs
  - Low signal in synovium due to magnetic susceptibility artifact of hemosiderin

Ultrasonographic Findings

- Acute stage
  - Large effusion
    - Finely speckled echogenic joint fluid
    - Minimal or no synovial thickening or hyperemia
  - ± ↑ echogenicity from more hypoechoic (superficial) to more hyperechoic (deep)
    - Due to early sedimentation of cellular elements
  - ± layering of different fluid components
    - Specific for hemarthrosis or lipohemarthrosis
    - Seen after lying supine for few minutes to allow time to sediment
  - **Hemarthrosis is initially seen as uniformly, finely speckled echogenic joint fluid**
    - After ~ 5 minutes, may become 2-layered joint effusion
      - Superficial hypoechoic layer representing supernatant serum
      - Deep hyperechoic layer representing dependent RBCs
  - **Lipohemarthrosis initially seen as uniformly, finely speckled echogenic joint fluid**
    - After ~ 10 minutes, may become 3-layered joint effusion
      - Superficial hyperechoic layer = floating fat
      - Central hypoechoic layer = supernatant serum
      - Deep hyperechoic layer = dependent RBCs
    - ± hypoechoic areas within floating fat due to trapped blood
- Subacute stage
  - Blood clots: Discrete echogenic mass within joint
    - Can be difficult to distinguish from synovial proliferation
    - Aspirate if in doubt
  - Joint fluid: More anechoic
  - ± fibrinous adhesions
- Repeated hemarthrosis
  - Early hemophilic arthropathy: ↑ joint fluid, mild to moderate synovial proliferation
  - Late hemophilic arthropathy: Less joint fluid, severe synovial thickening
    - Hemosiderin deposition within synovium not apparent on US
    - Synovial hyperemia usually not apparent in hemophilic arthropathy
      - Vascularity in hemophilic arthropathy is below sensitivity threshold of Doppler systems
  - Secondary osteoarthritis
    - Diffuse cartilage thinning
    - Irregularity of subchondral bone
    - Marginal osteophytosis
  - ± Baker cyst
  - ± hematoma
  - ± pseudotumor (expanding hematoma)
    - Hypoechoic ± hyperechoic areas (recent bleeding) ± anechoic areas (liquefaction)
- **Hemophilia early arthropathy detection with US score (HEAD-US)**
  - Additive score to define joint status in hemophilic arthropathy

- Targeted examination of elbow, knee, ankle
  - Synovial hypertrophy graded as 0 (absent/minimal), 1 (mild/moderate), or 2 (severe) synovial proliferation
  - Cartilage thinning graded as 0 (normal), 1 (mild), 2 (moderate), 3 (severe), or 4 (complete) thinning
  - Subchondral bone graded as 0 (normal), 1 (mild), or 2 (moderate/severe) subchondral bone irregularity ± osteophytes

Imaging Recommendations

- Best imaging tool
  - US
- Protocol advice
  - Minimize movement of part under examination
  - ± repeat at 5-20 minutes to observe layering
    - Layering only seen in acute hemarthrosis

DIFFERENTIAL DIAGNOSIS

Septic Arthritis

- Gradual-onset joint swelling over 1-2 days
  - More insidious onset if nonpyogenic infection
- Very tender with marked limitation of movement
  - More severe inflammation than hemarthrosis/lipohemarthrosis
  - Aspirate if there is any doubt

Gout

- Severe inflammation with moderate synovial proliferation
- Echogenic crystal aggregates within joint fluid or synovium
  - ± adjacent tophi or erosions

Inflammatory Synovitis

- Moderate to severe synovial proliferation & hyperemia
  - Hyperemia not prominent feature of synovial proliferation in hemophilia
- ± polyarticular ± marginal erosions
- ± clinical/serologic features of inflammatory arthropathy

PATHOLOGY

General Features

- Etiology
  - Posttraumatic hemarthrosis/lipohemarthrosis
    - Bleeding from laceration of synovial vessels or leakage from marrow cavity
    - Lipohemarthrosis always signifies intraarticular fracture extension
  - Spontaneous hemarthrosis
    - Due to spontaneous bleeding from synovium
    - Not uncommon in knee osteoarthritis with mild to moderate reactive-type synovitis
- Genetics
  - Hemophilia A or B: X-linked recessive

Staging, Grading, & Classification

- Arnold-Hilgartner scale for hemophiliac arthropathy of knee
  - Stage 0: Normal joint
  - Stage I: Soft tissue swelling
  - Stage II: Osteoporosis & overgrowth of epiphysis
  - Stage III: Early subchondral bone cysts, squaring of patella, widening of intercondylar notch
  - Stage IV: As per stage III, but joint space is narrowed
  - Stage V: Fibrous joint contracture, loss of joint space, severe enlargement of epiphysis, & substantial disorganization of joint

Gross Pathologic & Surgical Features

- Synovial proliferation ± hemophilic arthropathy

Microscopic Features

- Acute on chronic inflammation
- Hemosiderin-laden macrophages; fibrosis

CLINICAL ISSUES

Presentation

- Most common signs/symptoms
  - Rapid-onset joint effusion with tense warm joint

Demographics

- Age
  - Posttraumatic hemarthrosis: Young adults
  - Spontaneous hemarthrosis: Older adults
  - Hemophilic arthropathy: Young onset, throughout life
- Sex
  - Hemophilia: Almost exclusively in males
- Epidemiology
  - Relative frequency: Hemophilia A (85%), hemophilia B (14%), other clotting disorders (1%)
    - 1 in 5,000 males; 60% of cases are severe

Natural History & Prognosis

- Acute hemarthrosis resolves over 1-2 weeks
- Hemophilic arthropathy
  - Repeated hemarthrosis → progressive arthropathy

Treatment

- Rest, ice, & analgesia
  - ± aspiration if very painful (distention)
- Hemophilic arthropathy with acute hemorrhage
  - Correct coagulation factor deficiency
    - Infusion of factor VIII (hemophilia A) or factor IX (hemophilia B)
- Hemophilic arthropathy with repeated hemarthroses
  - Chemical synovectomy with intraarticular administration of rifampicin or osmic acid (± US guidance)
  - Radiosynovectomy with intraarticular administration of yttrium, gold, or phosphorus (± US guidance)
  - Intraarticular administration of hyaluronic acid (± US guidance)
  - Surgery: Joint replacement (if severe arthropathy)

DIAGNOSTIC CHECKLIST

Image Interpretation Pearls

- Lipohemarthrosis has single-fluid level (fat fluid) on radiography but double-fluid level (fat, serum, RBCs) on US, CT, & MR

SELECTED REFERENCES

1. Bakeer N et al: Haemophilic arthropathy: diagnosis, management, and aging patient considerations. Haemophilia. 30 Suppl 3:120-7, 2024
2. Minno MNDD et al: How to assess, detect, and manage joint involvement in the era of transformational therapies: role of point-of-care ultrasound. Haemophilia. 29(1):1-10, 2023

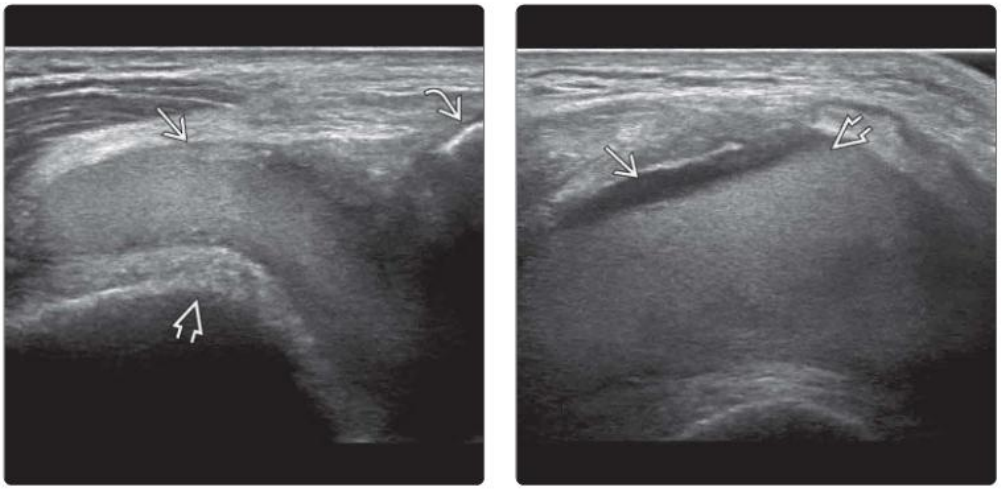

(Left) *Transverse US of the medial recess of the knee joint with acute hemarthrosis shows homogeneous echogenic fluid with no layering. Note the patella and the anterior aspect of the medial femoral condyle.* **(Right)** *Transverse US of the same area 5 minutes later shows acute hemarthrosis with a 2-layered appearance, an upper serum layer and a lower cellular (RBC) layer.*

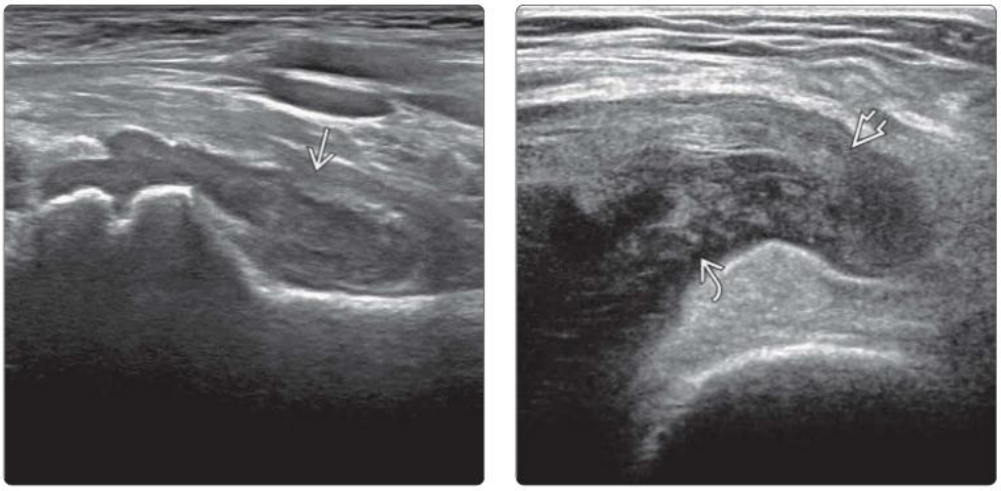

(Left) *Longitudinal hip US in an 8-year-old boy following trauma is shown. No radiographic fracture was present. There is moderate joint distention with echogenic fluid consistent with hemarthrosis. MR, including gradient-echo sequences, showed no occult fracture and confirmed hemarthrosis.* **(Right)** *US lateral patellar recess in a 72-year-old woman on anticoagulants with recent knee swelling shows synovial proliferation and echogenic joint fluid, suggestive of hemarthrosis and confirmed by aspiration.*

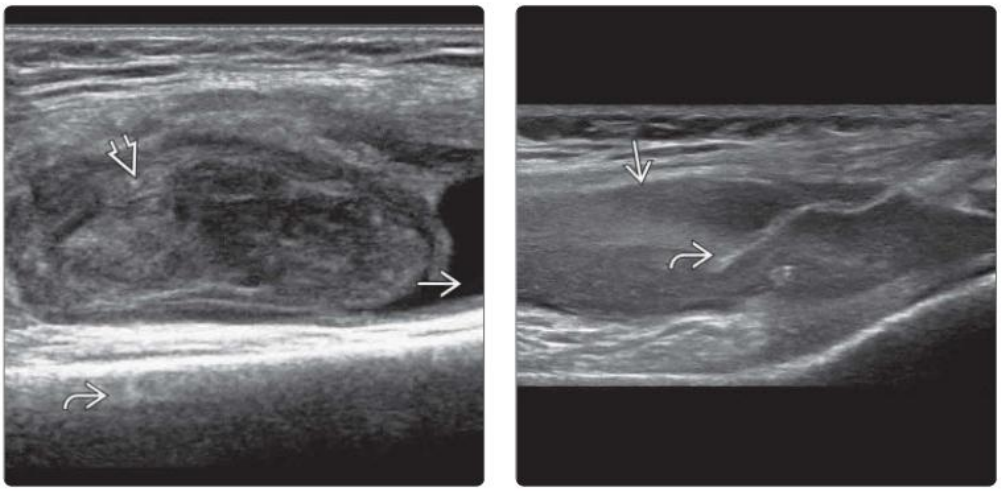

(Left) *Longitudinal US in a patient with hemophilia shows an acute hematoma in the synovium of the suprapatellar pouch. There is an anechoic joint effusion. The distal femur is noted.* **(Right)** *Longitudinal US in a 15-year-old boy shows acute hemarthrosis in the suprapatellar recess of the knee joint due to recent transient lateral patellar dislocation. Note the suprapatellar plica clearly visible in the distended suprapatellar recess.*

KEY FACTS

IMAGING

- Fluid-filled sac with neck arising from interspace between medial gastrocnemius muscle & semimembranosus tendon
  - Cyst must have neck emerging from gastrocnemius muscle & semimembranosus tendon interspace
  - Has "speech-bubble" configuration on transverse scan
- Cysts are typically well defined & thin walled
- As they communicate with knee joint, cyst content usually mirrors that of knee joint
  - Thick-walled cysts in inflammatory osteoarthritis, inflammatory arthropathy, or with intracystic hemorrhage
  - Thick-walled cysts often have hyperemic walls
- Cyst may be septated
- Contains anechoic synovial fluid; typically gelatinous in consistency
- Free-fluid tracking adjacent to cyst indicates recent leakage
  - Recent leakage is important to note as it can result in localized posteromedial knee pain
- Irregular & multiloculated cysts may result from repeated cyst leakage & collection
- Cysts usually extend distally superficial to medial belly of gastrocnemius muscle
- Contralateral subclinical Baker cyst is common finding
- US accurately confirms presence, extent, & content of Baker cyst
  - Examine with patient prone, knee extended
  - Follow medial belly of gastrocnemius proximally & locate interspace between medial gastrocnemius head & semimembranosus tendon
  - Routinely examine contralateral side
  - Can aspirate percutaneously if not too viscous, but high rate of recurrence
    - ± steroid injection, especially if inflammatory component is present (inflammatory-type exudate, thick walled, hyperemia)
    - Not possible to ascertain viscosity of cyst content from US appearance

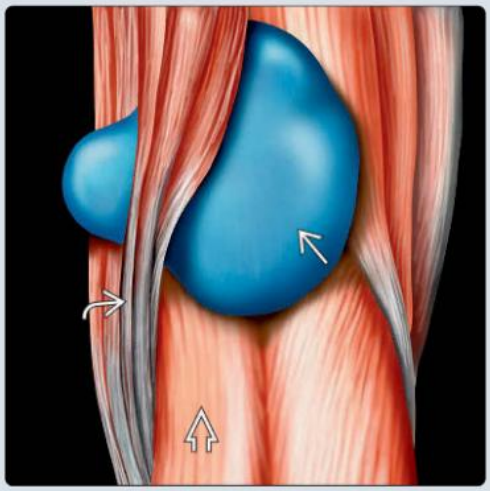

(Left) *Clinical photograph of the popliteal fossa shows focal swelling due to Baker cyst. Most patients with Baker cyst just have a palpable swelling rather than a visible focal fullness.* **(Right)** *Longitudinal graphic shows a Baker cyst located between the semimembranosus tendon & the medial belly of the gastrocnemius muscle.*

(Left) *Transverse US shows a typical Baker cyst with a "speech-bubble" configuration. The neck extends between the semimembranosus tendon and the medial belly of the gastrocnemius muscle.* **(Right)** *Transverse US shows a typical Baker cyst with the neck arising between the semimembranosus tendon and the medial belly of the gastrocnemius muscle. The finely speckled appearance of fluid within the cyst is due to colloid aggregates suspended in the gelatinous content of the cyst.*

TERMINOLOGY

Synonyms

- Popliteal cyst, popliteal synovial cyst
  - Baker cyst is preferred term since popliteal cyst can also refer to periarticular ganglion cyst or parameniscal cyst

Definitions

- Fluid distention of gastrocnemius-semimembranosus bursa

IMAGING

General Features

- Best diagnostic clue
  - Fluid-filled sac with neck arising from interspace between medial gastrocnemius muscle & semimembranosus tendon
- Location
  - Posterior to medial femoral condyle
- Size
  - Range: 1-30 cm across long axis or greater
    - Larger cysts often seen with inflammatory arthropathy
- Morphology
  - Small unilocular sac to large multiloculated sac extending to mid-1/3 of calf

Radiographic Findings

- Radiography
  - Soft tissue swelling of posteromedial knee
    - ± calcified debris/intraarticular loose bodies
    - ± displacement of calcified popliteal artery

MR Findings

- T1WI
  - Hypointense, well-defined mass in expected location
  - Subacute hemorrhage in cyst seen as areas of hyperintensity
- T2WI
  - Hyperintense mass: Gastrocnemius-semimembranosus bursa
    - ± fluid level ± hypointense foci (hemosiderin) ± calcified bodies (hypointense) ± thick synovial wall
  - ± surrounding free fluid

Ultrasonographic Findings

- Fluid-filled popliteal fossa mass
  - Anechoic with posterior enhancement
  - Must see neck arising from medial gastrocnemius-semimembranosus tendon interspace to make diagnosis of Baker cyst
    - Characteristic "speech-bubble" configuration on transverse scan
  - Extension through posterior knee capsule not seen
- Cyst is typically well defined & thin walled
- As they communicate with knee joint, cyst content usually mirrors that of knee joint
- Thick-walled cysts suggest association with inflammatory osteoarthritis, inflammatory knee arthropathy, or intracystic hemorrhage
  - Thick-walled cysts often have hyperemic walls
- Cyst may be septated
  - May be bilocular or trilocular
- Typically contains anechoic synovial fluid; gelatinous in consistency
  - ± fine echogenic speckles due to colloid suspensions
  - ± small echogenic comet-tail artifacts (secondary to colloid aggregates)
  - ± fibrinous-type exudate (particularly with inflammatory arthropathy)
  - ± calcific particulate matter
  - ± blood clots
- Iso- or hyperechoic fluid suggests recent intracystic bleeding or inflammatory exudate
- Free-fluid tracking adjacent to cyst indicates recent leakage
  - Irregular & multiloculated cysts result from repeated cyst leakage & recollection
  - Sharp angular (pointed or "stiletto tip") cyst contour suggests leakage
    - Fluid leaked from Baker cyst will not have discernible wall
    - Free-fluid tracts around posteromedial aspect of knee, into calf, & into distal thigh
      - Recent leakage is important to note as it can result in localized pain
- Cysts usually extend distally superficial to medial belly of gastrocnemius muscle
  - ± extension distally deep to medial belly of gastrocnemius
  - ± extension proximally deep to & around hamstring muscles, especially semimembranous muscle
  - ± intramuscular extension (uncommon)
    - Into medial belly of gastrocnemius, vastus medialis
    - Extends through myofascia weakened by cyst wall or perforating vessels
- Cannot usually ascertain viscosity of cyst content on US
- Contralateral subclinical Baker cysts are common
  - Routinely examine both popliteal fossae

Imaging Recommendations

- Best imaging tool
  - US
    - Confirms presence, extent, content, & recent leakage
- Protocol advice
  - Examine with patient prone, knees extended
  - Follow medial belly of gastrocnemius proximally & locate interspace between medial gastrocnemius head & semimembranosus tendon
    - Baker cyst arises from interspace between these 2 structures
    - Check cyst margins closely looking for fluid leakage, especially most distal margin
  - Routinely examine contralateral side

DIFFERENTIAL DIAGNOSIS

Parameniscal Cyst

- Usually associated with meniscal tear, typically horizontal tear
- Cyst extends to contact or very close to margin of meniscus
- Does not have typical configuration of Baker cyst
- Usually multiloculated

Popliteal Artery Aneurysm

- Saccular or fusiform dilation of popliteal artery
- Cystic adventitial disease of popliteal artery is alternative diagnosis

Cystic Periarticular Tumor

- Cystic synovial sarcoma, myxoma, or lymphangioma
- Does not have typical configuration of Baker cyst

Paraarticular Ganglion

- Does not emerge between medial gastrocnemius muscle & semimembranosus tendon

PATHOLOGY

General Features

- Etiology
  - Joint fluid decompressing into cyst
  - Fluid may communicate freely or be restricted with ball valve-like mechanism
- Associated abnormalities
  - Effusion associated with intraarticular pathology in ~ 85-98% of cases in adults
    - Meniscal tears, arthritis (degenerative, inflammatory), chondral defects, cruciate ligament tears
  - In children, usually not associated with intraarticular pathology or joint effusion
    - Possibly related to congenital predisposition
    - Frequently bilateral
- Slit-like capsular opening into gastrocnemius-semimembranosus bursa (Baker cyst) behind posterior horn of medial meniscus
  - Slit = 15- to 20-mm vertically oriented opening
    - Slit closed in extension, open in flexion
- Capsule unsupported at this location
  - Between expansions of semimembranosus tendon medially & posterior cruciate ligament laterally
- Slit present on cadaveric study in 50% of subjects > 50 years age
  - Prevalence increases with age
  - Probably due to degenerative thinning of joint capsule
- Synovial fluid extruded through slit into cyst
- Wall of cyst composed of fibrous tissue lined by synovium
  - Synovium of cyst in continuity with synovium of knee joint
- Synovial disorders of knee also affect Baker cyst
  - Synovitis, synovial osteochondromatosis, pigmented villonodular synovitis
- Other mechanisms whereby Baker cysts may develop
  - Accumulation of fluid within noncommunicating gastrocnemius-semimembranosus bursa
  - Herniation of posterior joint capsule due to increased intraarticular pressure

Gross Pathologic & Surgical Features

- Fluid-filled cyst in popliteal space

Microscopic Features

- Lined by synovium, similar to knee joint

CLINICAL ISSUES

Presentation

- Most common signs/symptoms
  - Painless mass on medial side of popliteal fossa
  - Symptoms from underlying internal derangement (meniscal tear, osteoarthritis, chondral defect, etc.)
- Other signs/symptoms
  - Sudden onset of calf pain due to
    - Expansion, leakage, intracystic bleeding
  - Anticoagulation for clinically suspected deep venous thrombosis may induce intracystic bleeding
  - Pressure effect on popliteal artery, vein, or tibial nerve is very rare

Demographics

- Age
  - Prevalence increases with age
- Sex
  - More common in male patients
- Epidemiology
  - Most commonly encountered cyst around knee
    - 15% of general population
    - 5% of pediatric MR knee studies
    - 15% of asymptomatic MR knee studies
    - 50% of older adult MR knee studies

Natural History & Prognosis

- Cyst may regress or enlarge
  - Overall good prognosis, especially in children
- In children, if cysts are treated conservatively, 1/2 will disappear & remainder will regress

Treatment

- Conservative
  - Treatment of associated internal derangement
  - NSAIDs, ice
  - Cyst aspiration ± intracystic steroid injection
    - High rate of recurrence
    - Occasionally, contents are too viscous to aspirate
    - Intracystic steroid injection, particularly if inflammatory component to cyst (inflammatory-type exudate, thick walled, hyperemia)
- Surgical
  - Excision ± closure of joint-bursal communication
    - Recurrence is common

DIAGNOSTIC CHECKLIST

Consider

- Intraarticular pathology, as this is very frequently associated with Baker cysts in adults
- Cyst content often mirrors content of knee joint

Image Interpretation Pearls

- Look for characteristic "speech-bubble" configuration of cyst on transverse imaging

SELECTED REFERENCES

1. Augustin D et al: Intramuscular dissecting Baker's cysts: a case series highlighting ultrasound diagnosis and differential considerations. Cureus. 16(2):e53658, 2024

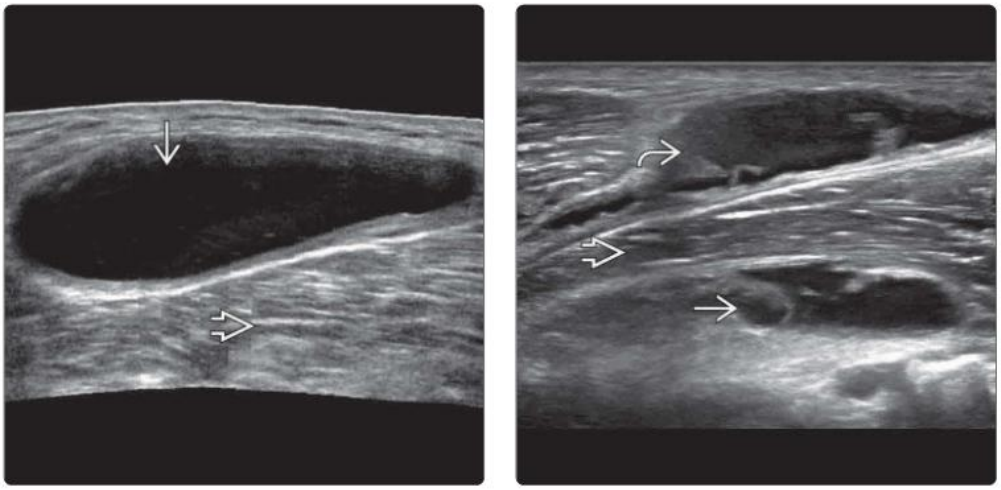

(Left) *Extended field-of-view US shows a thin-walled unilocular Baker cyst lying superficial to the medial belly of the gastrocnemius muscle.* **(Right)** *Longitudinal US shows a Baker cyst extending distally in the calf both superficial to and ruptured into the medial belly of the gastrocnemius muscle. Most cysts extend superficial to the gastrocnemius muscle.*

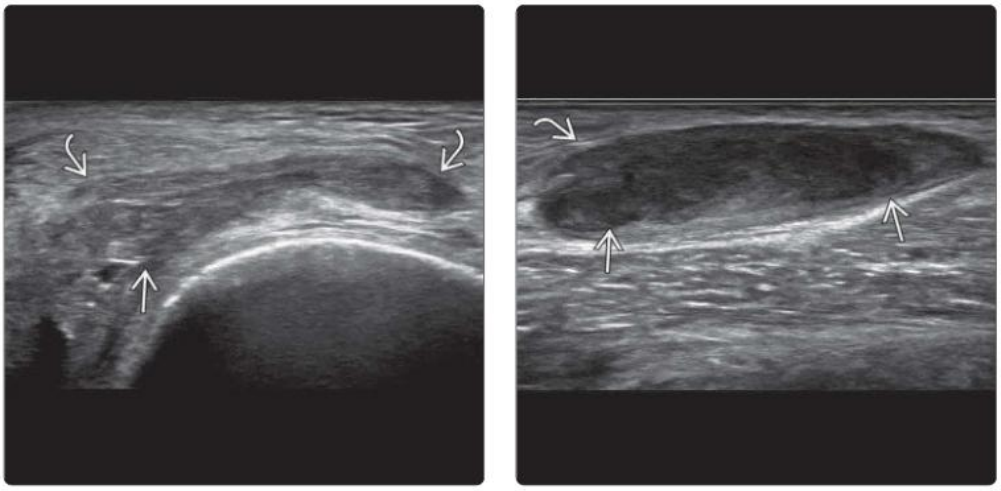

(Left) *Transverse US of the lateral patellar recess shows moderate low-grade synovial proliferation in a patient with a systemic inflammatory arthropathy.* **(Right)** *Longitudinal US in the same patient shows moderate synovial proliferation within the Baker cyst. The contents of a Baker cyst will usually mirror those of the knee joint.*

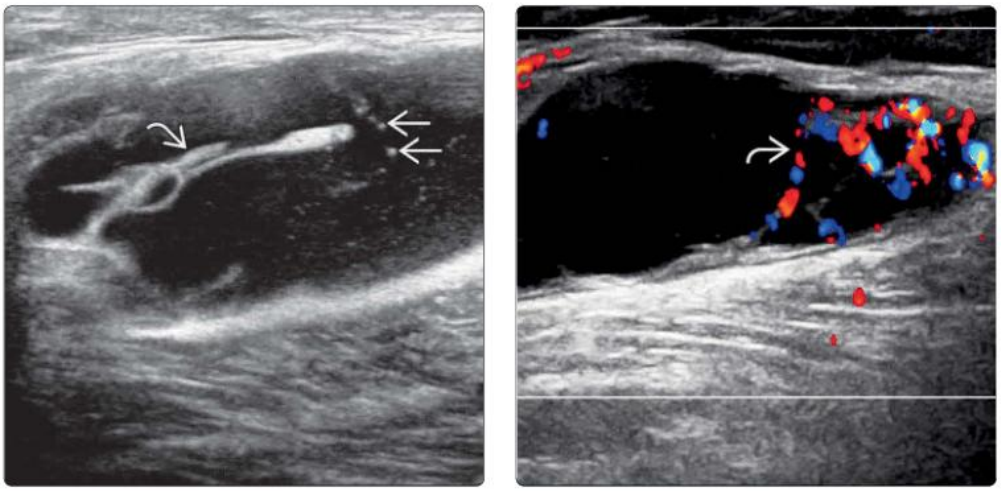

(Left) *Longitudinal US shows a Baker cyst containing thick synovial fronds and comet-tail artifacts. These comet-tail artifacts are due to colloid aggregates suspected in the gelatinous matrix of the cyst. The fronds are due to fibrous adhesions.* **(Right)** *Longitudinal color Doppler US in the same patient shows marked hyperemia of the hypertrophied synovial fronds.*

(Left) *Transverse US shows a Baker cyst ➡ with fibrinous stranding ➡ and a thick, fibrous-type exudate.* **(Right)** *Longitudinal color Doppler US shows moderate hypervascularity ➡ within mass-like synovial proliferation within a Baker cyst in a patient with an inflammatory arthropathy of the knee joint. One should relate the appearances seen in a Baker cyst to those seen in the knee joint.*

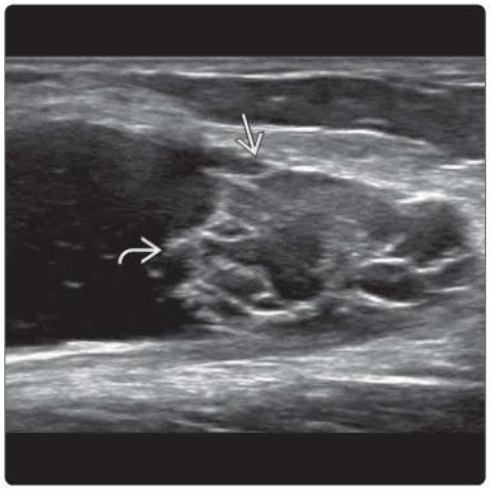

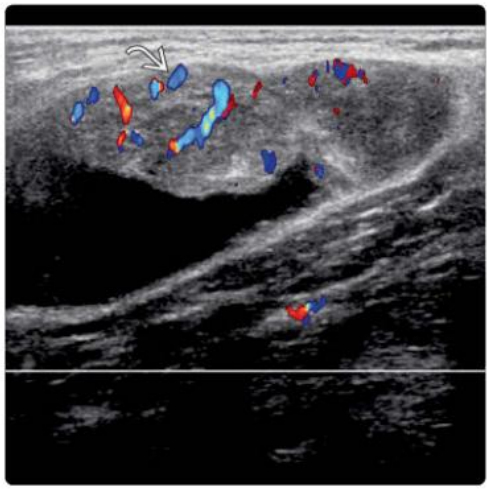

(Left) *Longitudinal US shows moderate synovial proliferation ➡ in a Baker cyst ➡ of a patient with chronic low-grade knee inflammation.* **(Right)** *Longitudinal US shows localized cyst leakage ➡ tracking down as evidenced by the small amount of extracystic free fluid adjacent to the Baker cyst ➡. Localized fluid leakage is much more common than frank cyst rupture.*

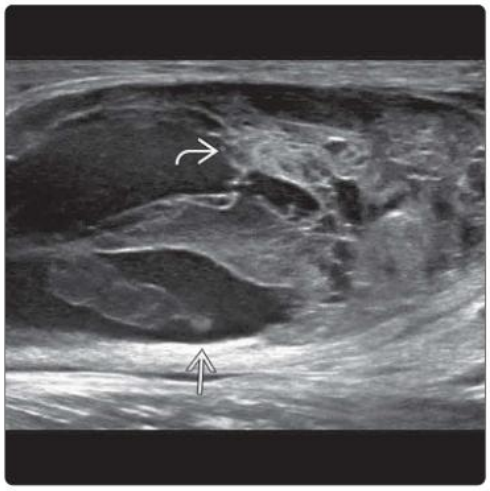

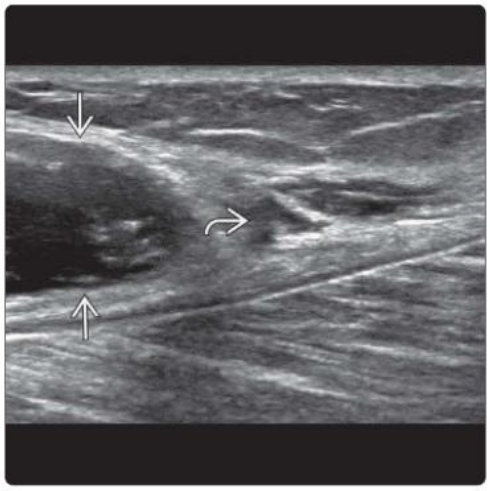

(Left) *Transverse US of a thick-walled Baker cyst ➡ shows small areas of calcified debris ➡ embedded in the hypertrophied synovium ➡.* **(Right)** *Transverse US in the same patient shows a calcified fragment ➡ within part of the Baker cyst ➡. Osseous fragments within the knee joint can extend into a Baker cyst. Osseous fragments may also enlarge within Baker cysts. Hence, very large calcified bodies can be seen in Baker cysts.*

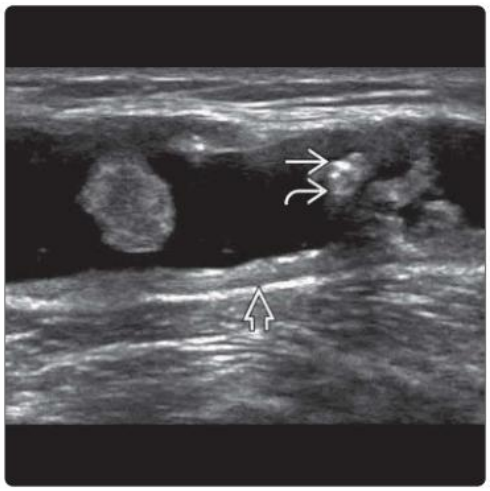

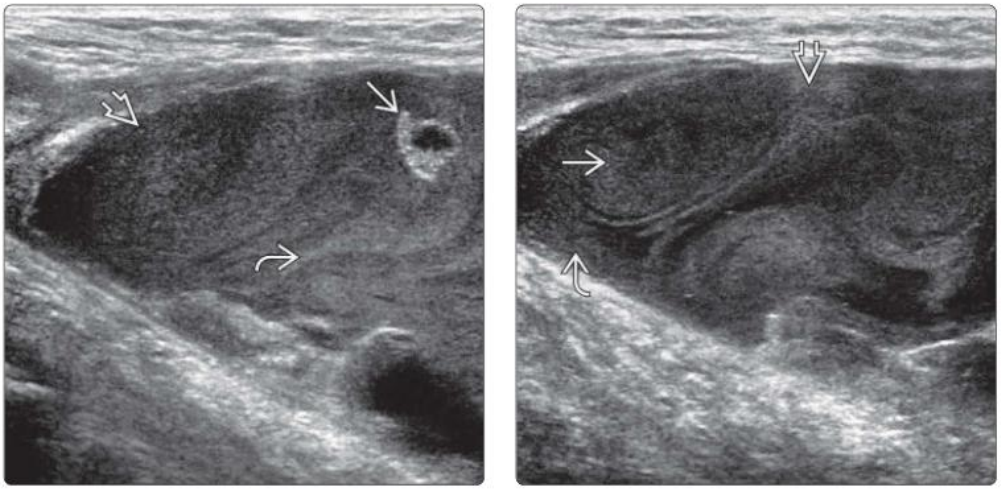

(Left) *Transverse US shows recent hemorrhage within a Baker cyst ➡ with finely speckled echogenic fluid ➡. The small hyperechoic ring ➡ may be due to a detached synovial fragment.* **(Right)** *Transverse US in the same patient shows recent hemorrhage into the Baker cyst ➡ with echogenic fluid ➡ and early clot ➡ formation within the cyst. The echogenicity and swirling pattern is characteristic of hemorrhage.*

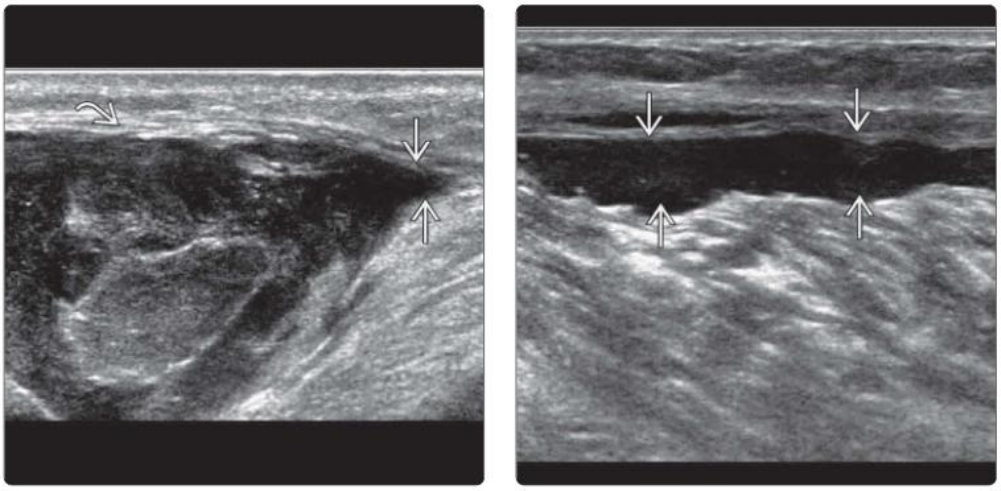

(Left) *Longitudinal US with extended field of view shows localized cyst leakage ➡ as evidenced by a sharp contour to the edge of the Baker cyst ➡ and lack of a discernible wall around the extracystic free fluid.* **(Right)** *Longitudinal US in the same patient shows fluid leakage ➡ tracking more distally superficial to the medial belly of the gastrocnemius muscle. Most Baker cyst fluid leakage occurs distally rather than proximally.*

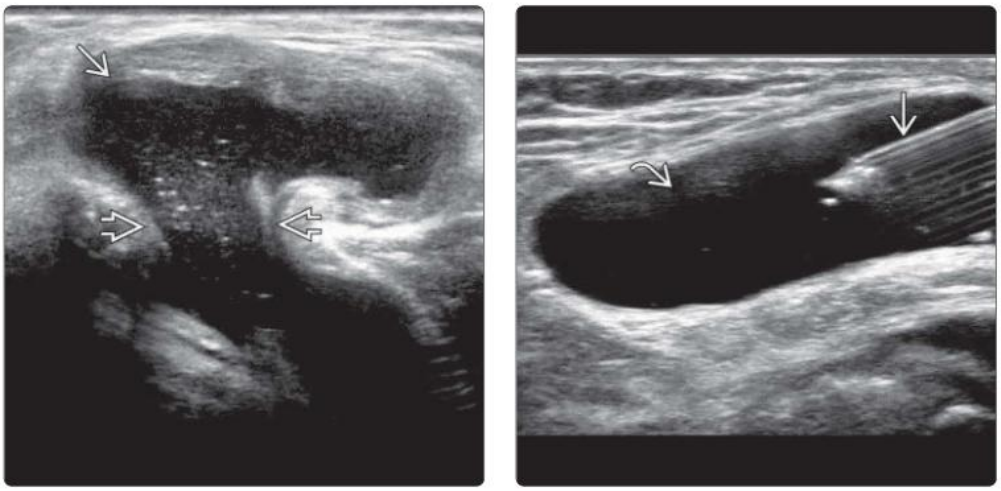

(Left) *Transverse US shows a Baker cyst ➡ with an unusually wide neck ➡.* **(Right)** *Longitudinal US shows percutaneous aspiration with a 21-g needle ➡ within a Baker cyst ➡. There is some reverberation artifact deep to the needle. It is difficult to determine the viscosity of Baker cyst contents prior to aspiration. As most Baker cysts tend to reaccumulate following aspiration, only temporary relief of symptoms is obtained. Intracystic steroid injection can also help.*

KEY FACTS

TERMINOLOGY

- Bursitis: Inflammation of lining of bursa

IMAGING

- Most bursae are not visible on US unless distended with fluid or proliferative synovial tissue
- Acute bursitis: Thin-walled bursa distended with hypoechoic fluid, peribursal hyperemia
- Chronic bursitis: Thickening of bursal wall, more mature synovial proliferation, more echogenic content, & increased likelihood of intrabursal hyperemia
  - Can simulate soft tissue mass or abscess
  - If echogenic foci in distended bursa, consider crystal deposition
- Most bursae are accessible to US examination
  - Use minimal transducer pressure to avoid effacement of superficial bursae
  - Amiable to US-guided aspiration ± injection

TOP DIFFERENTIAL DIAGNOSES

- Cystic collection from underlying structure, e.g., parameniscal cyst, ganglion cyst
- Abscess or collection
- Cyst adjacent to bursa, e.g., seroma or hematoma

CLINICAL ISSUES

- Treatment
  - Rest; antiinflammatory agents: US-guided corticosteroid ± long-acting, local anesthetic injection
  - Excision for resistant cases

DIAGNOSTIC CHECKLIST

- Small amount of fluid is normal in subacromial-subdeltoid bursa, deep infrapatellar bursa, & retrocalcaneal bursa
- Bursitis is common; infective bursitis is very uncommon
- Synovial-type bursae are susceptible to all synovial-based pathologies, such as synovial osteochondromatosis

(Left) *Clinical photograph shows a patient with posterior elbow swelling* ➡ *that had been present for many years with a recent increase in pain and size.* **(Right)** *Transverse US shows a large olecranon bursa with a moderately thickened bursal wall* ➡*. The bursa is distended by fluid and synovial proliferation and overlies the olecranon process* ➡*. Olecranon bursae frequently have a thickened wall, internal debris, and septa. A nondistended olecranon bursa is not visible on US.*

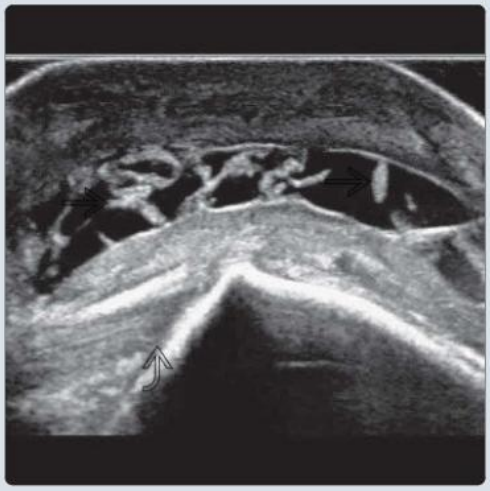

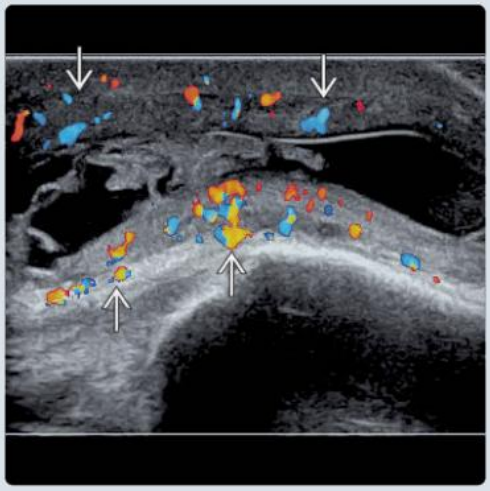

(Left) *Longitudinal US of the same bursa shows the distended, inflamed olecranon bursa with several thick internal septations* ➡*, giving the bursa a multiloculated appearance. The normal triceps tendon insertion* ➡ *into the olecranon process is shown.* **(Right)** *Longitudinal color Doppler US shows moderate hyperemia of the thickened bursal wall* ➡ *and peribursal tissues. The internal content and septations show no hyperemia.*

TERMINOLOGY

Synonyms

- Bursopathy, "student's elbow" (olecranon bursitis), ischial tuberosity (ischiogluteal) bursitis, trochanteric (hip) bursitis, "housekeeper's knee" (prepatellar bursitis), "preacher's knee" (infrapatellar bursitis)

Definitions

- Bursitis: Inflammation of lining of bursa
  - Bursa: Synovial-lined sac interspersed between tissues at areas of friction
  - 2 types of bursae
    - Synovial bursae: Constant synovial-lined bursae, which are present at birth in defined anatomic locations
    - Adventitial bursae: Nonsynovial-lined bursae acquired during life due to friction between opposing tissues
      - Can occur anywhere
- Infective bursitis: Very uncommon
- Hemorrhagic bursal distention: Usually following direct trauma or occasionally from spontaneous rupture of vessels in bursal wall
  - Strictly speaking, not bursitis

IMAGING

General Features

- Best diagnostic clue
  - Fluid-distended sac in typical location
- Location
  - Subacromial-subdeltoid bursa: Large bursa overlying rotator cuff tendons
    - Communicates with glenohumeral joint if full-thickness tear of supraspinatus/infraspinatus tendons
  - Olecranon bursa: Overlies olecranon process & distal end of triceps tendon
  - Ischial tuberosity bursa: Between ischial tuberosity (hamstring tendon attachment) & gluteus maximus muscle
  - Iliopsoas bursa: Large bursa between iliopsoas tendon & anterior part of hip joint
    - Communicates with hip joint in 15% of subjects
  - Trochanteric bursa: Overlies posterolateral aspect of greater trochanter proximal femur
  - Subgluteus minimus bursa: Between gluteus minimus tendon & anterior facet of greater trochanter
  - Subgluteus medius bursa: Between gluteus medius tendon & posterosuperior facet of greater trochanter
  - Semimembranous bursa: Posteromedial to semimembranous musculotendinous junction & tendon posteromedial aspect of distal thigh
  - Pes anserine bursa: Between sartorius, gracilis, & semitendinosus tendons & posteromedial aspect of tibia
  - Prepatellar bursa: Overlies inferior pole of patella & proximal patellar tendon
  - Infrapatellar bursa: Overlies mid to distal aspect of patellar tendon
    - Do not confuse with deep infrapatellar bursa, deep to patellar tendon
    - Small amount of fluid in deep infrapatellar bursa is normal
  - Retrocalcaneal bursa: Between calcaneus, Achilles tendon, & Kager fat pad
    - Small amount of fluid in retrocalcaneal bursa is normal
  - Superficial calcaneal bursitis: Overlies distal aspect of Achilles tendon
- Size
  - Few mm to several cm, depending on degree of bursal distention
- Morphology
  - Communicating or noncommunicating bursa
    - Communicating refers to bursa communicating with adjacent joint, e.g., iliopsoas bursa

Radiographic Findings

- Radiography
  - Soft tissue swelling

Ultrasonographic Findings

- General
  - Most bursae are not visible on US unless distended with fluid or proliferative synovial tissue
  - Distended hypoechoic bursa
    - Thickened wall ± internal septation ± hemorrhage
  - Acute bursitis: Thin-walled bursa distended with hypoechoic fluid, peribursal hyperemia
  - Chronic cases: Greater thickening of bursal wall, more mature synovial proliferation, more echogenic content, & increased likelihood of intrabursal hyperemia
    - May simulate abscess or soft tissue mass
    - Especially for olecranon & ischial bursa
- Subacromial-subdeltoid bursitis
  - Associated with rotator cuff tendinosis, tendon tears, & impingement
  - Fluid collects in dependent positions
    - Lateral aspect of greater tuberosity, over bicipital groove, near coracoid, & deep to acromion
  - Bursal wall thickening & hyperemia are generally not seen
    - If present, consider inflammatory arthropathy & check for rice bodies (uncommon)
- Olecranon bursitis
  - Common site for gouty crystal deposition (echogenic foci within distended bursa)
- Ischial tuberosity bursitis: Large, irregular bursa with moderate wall thickening ± internal septa ± debris
- Iliopsoas bursitis: Large bursa beneath musculotendinous portion of iliopsoas muscle, anterior to hip joint capsule
  - Usually associated with hip arthropathy, e.g., inflammatory arthropathy or osteoarthritis
- Trochanteric bursitis: Uncommon
  - Most cases of trochanteric pain syndrome due to gluteus medius or minimus tendinosis, tears, & peritendinitis
- Semimembranosus bursitis: May become inflamed due to impingement or as feature of semimembranosus tendinosis
- Pes anserinus bursitis: Large, distended bursa indented by 3 tendons (sartorius, gracilis, semitendinosus; looks like goose's foot)
  - Prone to synovial proliferation
- Prepatellar bursitis: Often just subtle, thin hypoechoic, ill-defined band in prepatellar tissues

- Usually due to repetitive trauma from kneeling (e.g., housemaid, carpet layer)
- Occasionally infected (penetrating trauma)
- Infrapatellar bursitis: Similar to prepatellar bursitis but located more distally
- Retrocalcaneal bursitis: Small amount of fluid in retrocalcaneal bursa seen in 1/3 of normal subjects
  - Larger amount of fluid, bursal wall thickening, synovial proliferation, & peribursal or intrabursal hyperemia are indicative of bursitis
  - Nearly always associated with insertional Achilles tendinosis ± Haglund deformity

MR Findings

- T2WI
  - Fluid-filled sac at typical location
  - ± inflammatory debris (isointense) or, less commonly, calcification (hypointense)
  - ± rice bodies (fibrin nodules, T1 & T2 hypointense)
- T1WI C+
  - ± bursal wall enhancement with delayed enhancement of bursal content

Imaging Recommendations

- Best imaging tool
  - US
    - Most bursae accessible to US
      - Facilitates US-guided aspiration or injection
- Protocol advice
  - High-resolution (> 10 MHz) linear transducer for superficial bursae
    - Lower resolution (~ 7 MHz) for deeper bursae
  - Decrease transducer pressure to avoid bursal effacement of superficial bursa
    - Use copious acoustic gel to lift transducer from skin
  - Transducer palpation or movement of part may allow fluid to be appreciated
  - Angulate transducer to minimize anisotropy & optimize tendon visibility
  - ± compare with opposite side
  - ± aspiration (for cell count, crystals, Gram stain, & culture, including fungal, TB culture)
  - Small amount of fluid in some bursae (deep infrapatellar, retrocalcaneal, subacromial-subdeltoid) may be normal
  - If subacromial-subdeltoid bursal fluid & no obvious tendon tear, pay particular attention to anterior leading edge supraspinatus tendon for small avulsive-type tear

DIFFERENTIAL DIAGNOSIS

Cystic Collection Adjacent to Bursa

- Ganglion: Loculated cystic collection around tendon
- Hematoma: History of trauma or bleeding tendency
- Abscess: Signs of infection

Cystic Collection Adjacent to Bursa & Arising Underlying Structure

- Fluid extension to subacromial bursa due to tendon tear at supraspinatus tendon
- Parameniscal cyst due to underlying meniscal tear

PATHOLOGY

General Features

- Etiology
  - Chronic frictional trauma or overuse
  - Acute blunt trauma
  - Crystalline deposition (gout > pseudogout), especially in olecranon bursitis
  - Inflammatory joint disease
  - Infection (± penetrating trauma) is uncommon

Gross Pathologic & Surgical Features

- Bursal sac inflammation with variable synovial-like proliferation
  - Variable amount of fluid

Microscopic Features

- Thickened synovial lining with inflammatory reaction

CLINICAL ISSUES

Presentation

- Most common signs/symptoms
  - Pain ± mass
- Other signs/symptoms
  - Inflammation with warmth, tenderness, & redness
- Clinical profile
  - Overuse phenomenon

Demographics

- Age
  - Typically middle age
- Sex
  - Overall, M = F
- Epidemiology
  - Common disorder, especially subacromial-subdeltoid bursitis & olecranon bursitis

Natural History & Prognosis

- Insidious onset
  - Typically resolves with cessation of aggravating activity or removal of aggravating factor

Treatment

- Conservative
  - Rest; antiinflammatory agents
    - US-guided corticosteroid ± long-acting, local anesthetic injection
- Surgical
  - Excision for resistant cases

DIAGNOSTIC CHECKLIST

Consider

- Small amount of fluid is normal in subacromial-subdeltoid bursa, deep infrapatellar bursa, & retrocalcaneal bursa

SELECTED REFERENCES

1. Grey TM et al: Intraobserver reliability on classifying bursitis on shoulder ultrasound. Can Assoc Radiol J. 74(1):87-92, 2023

(Left) *Clinical photograph shows a patient with posterior elbow swelling, which had caused pain for several months.* **(Right)** *Longitudinal US shows a large olecranon bursitis filled with chronic-type synovial proliferative tissue. The olecranon and triceps tendon are shown. This solid appearance is quite common for olecranon bursitis, which can still be diagnosed based largely on location and configuration. Biopsy rather than aspiration is usually more helpful in this solid-looking bursitis.*

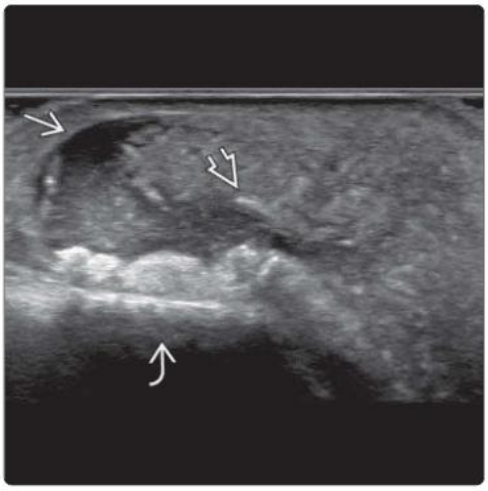

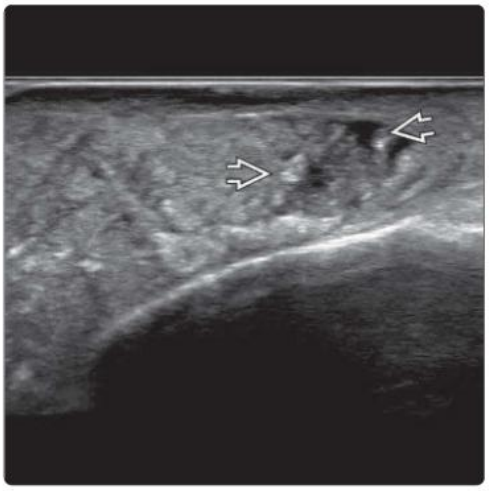

(Left) *Longitudinal US of the posterior elbow region in a patient with painful elbow swelling shows a distended olecranon bursa posterior to the proximal ulna. The distended bursa is filled with proliferative synovium containing many small echogenic foci, consistent with gouty crystal aggregates.* **(Right)** *Longitudinal US of the same bursa shows further echogenic crystal aggregates. With this appearance, there is no need to confirm gouty bursitis by aspiration if the patient has known gout.*

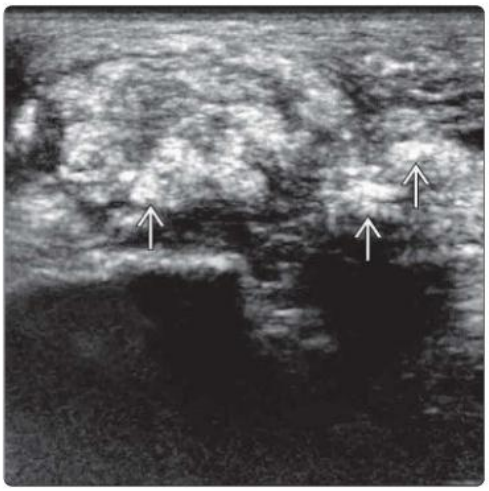

(Left) *Clinical photograph shows a patient with elbow pain and swelling present for 3-4 months.* **(Right)** *Transverse US of the same swelling shows an olecranon bursa distended with soft tissue containing many echogenic clumps, consistent with calcified crystal aggregates. Findings are compatible with chronic gouty olecranon bursitis. Chronic trauma, gout, and inflammatory arthropathy are common causes of aseptic bursitis.*

(Left) *Longitudinal oblique US shows a well-defined elbow mass located between the olecranon and the skin, compatible with olecranon bursitis. The bursa is distended by fluid with low-level echoes indicative of high proteinaceous or hemorrhagic content.* **(Right)** *Transverse US of the same bursa shows how it lies superficial to the triceps tendon and the olecranon. One can appreciate the varied appearances of olecranon bursitis.*

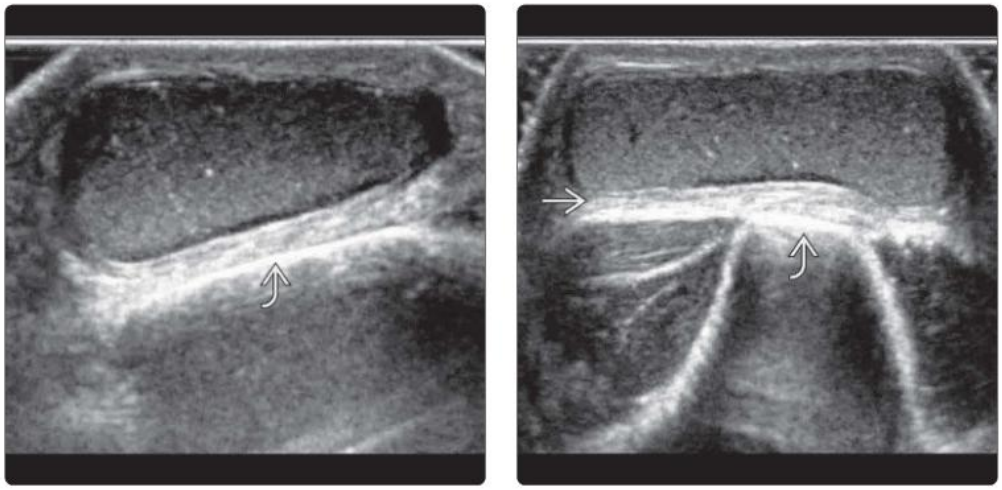

(Left) *Transverse US of the dorsal region in a patient with exaggerated dorsal kyphosis due to osteoporotic vertebral fractures shows an adventitial bursa present between the subcutaneous tissues and the investing fascia and an underlying thoracic spinous process.* **(Right)** *Transverse US of the same lesion with the transducer pressure released is shown. Continuity of the adventitial bursa can be more easily appreciated.*

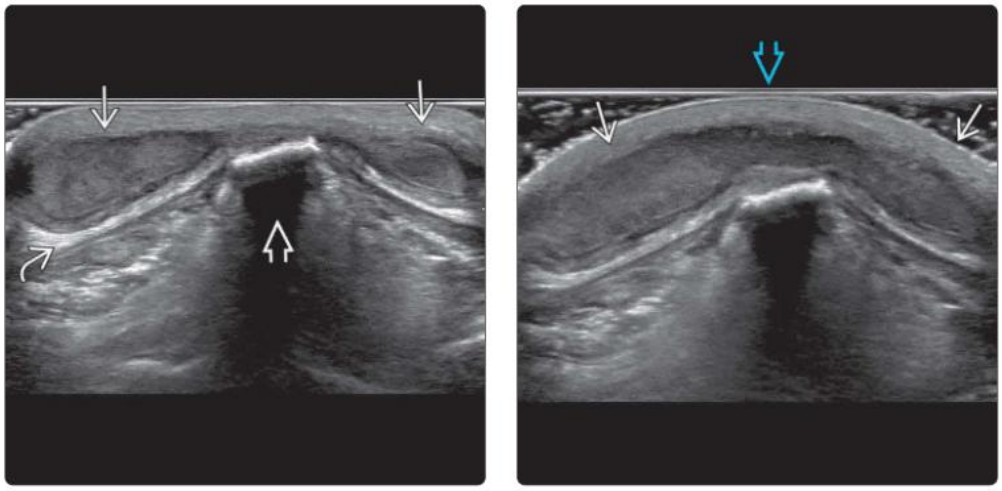

(Left) *Clinical photograph shows an avid ice skater who presented with bilateral medial painful ankle swellings of a few months' duration.* **(Right)** *Transverse oblique US shows moderate subcutaneous soft tissue swelling at the medial aspect of the right foot overlying the tibialis posterior tendon containing a very small amount of fluid. Features are indicative of adventitial bursitis related to subcutaneous fat impingement.*

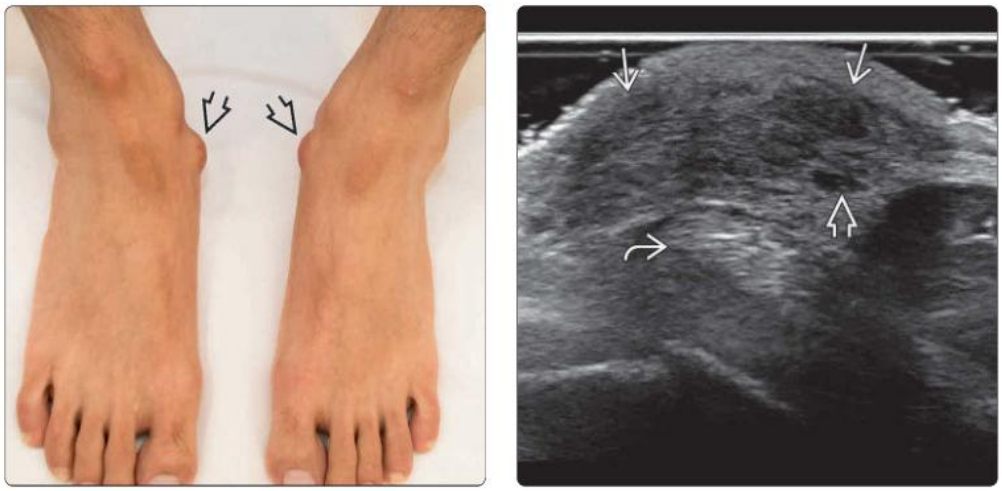

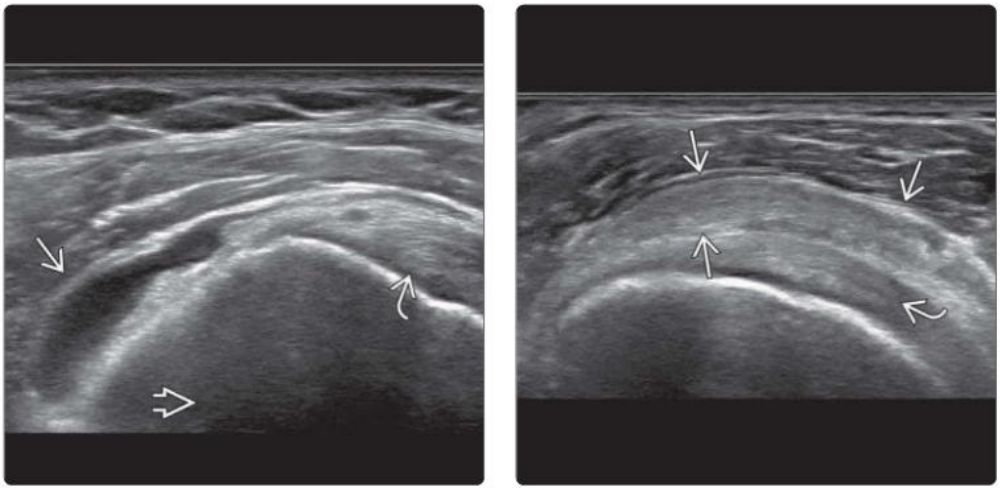

(Left) *Transverse US of the shoulder shows moderately distended subacromial (SA)-subdeltoid (SD) bursa alongside proximal humerus and distal to supraspinatus tendon. Intrabursal fluid accumulation occurs in more dependent regions.* **(Right)** *Transverse US in a patient following a direct fall onto the shoulder shows a distended SA-SD bursa due, most likely, to bursal hemorrhage and hematoma. In a different clinical setting, bursal synovial proliferation can look identical to this. Normal supraspinatus tendon is noted.*

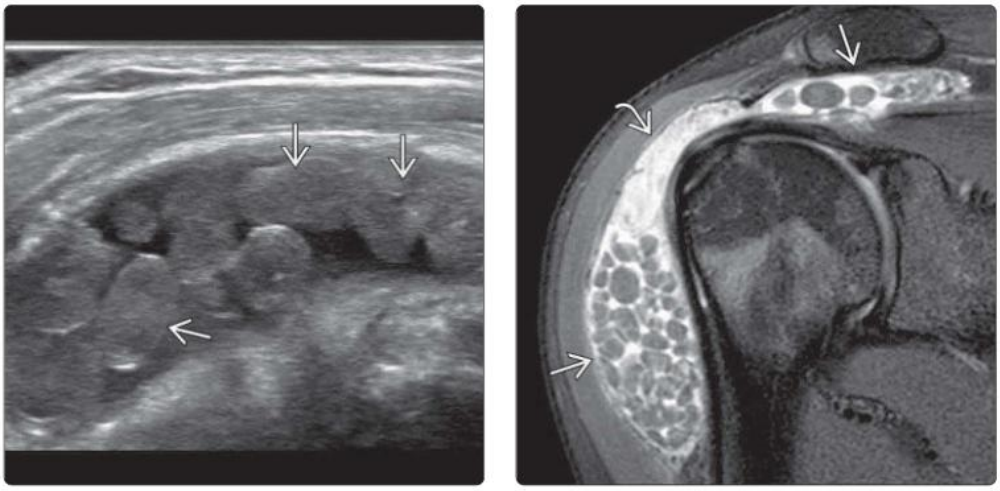

(Left) *Transverse shoulder US in a rheumatoid arthritis patient shows SA-SD bursa distended with multiple rice bodies. Rice bodies are an uncommon feature of chronic inflammatory or infective bursitis, being composed of protein aggregates due to proteinaceous bursal fluid.* **(Right)** *Coronal oblique T2 FS MR of the shoulder in a 41-year-old woman with rheumatoid arthritis and shoulder swelling for 6 months shows rice bodies and synovial proliferation in distended SA-SD bursa.*

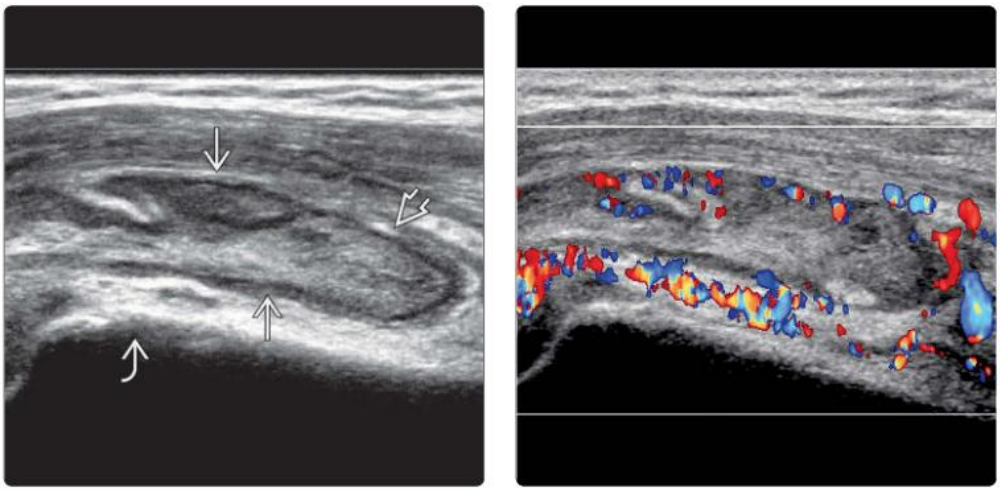

(Left) *Longitudinal US of the shoulder shows SA-SD bursa distended by heterogeneous echogenic tissue. The wall of the bursa is moderately thickened. The humerus is noted.* **(Right)** *Longitudinal color Doppler US of the same area shows severe peripheral hyperemia. Fine-needle aspiration yielded purulent fluid compatible with infective bursitis.*

(Left) *Longitudinal US of the elbow region shows a moderately distended bicipitoradial bursa partially surrounding the distal biceps tendon, just distal to the capitellum.* **(Right)** *Longitudinal US of the same bicipitoradial bursa during needle aspiration shows many echogenic foci, consistent with crystal aggregates within the distended bursa. The brachialis muscle lies deep to the distended bursa. Aspirate confirmed a gouty bursitis.*

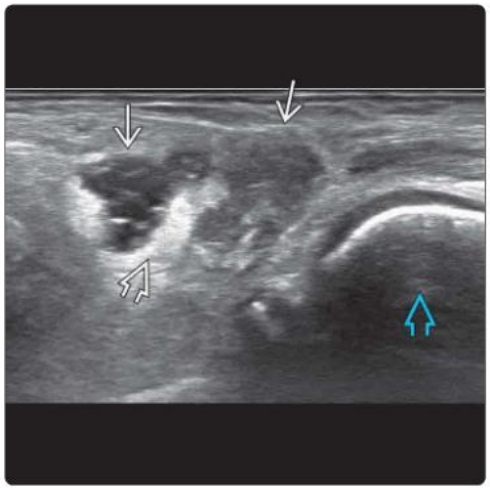

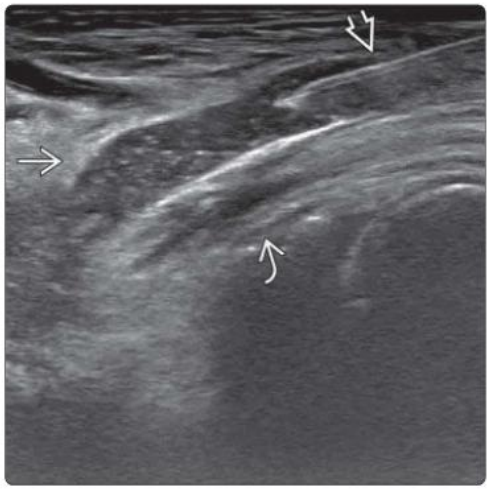

(Left) *Longitudinal US of the anterior elbow in a patient with end-stage renal failure and tertiary hyperparathyroidism shows a slightly lobulated mass with multiple fine echogenic foci within the distended bicipitoradial bursa, consistent with crystal aggregates. The biceps tendon is encased by the lobulated mass.* **(Right)** *Reconstructed sagittal CT of the same area shows multiple rounded calcifications surrounding the distal biceps tendon, consistent with bursal tumoral calcinosis.*

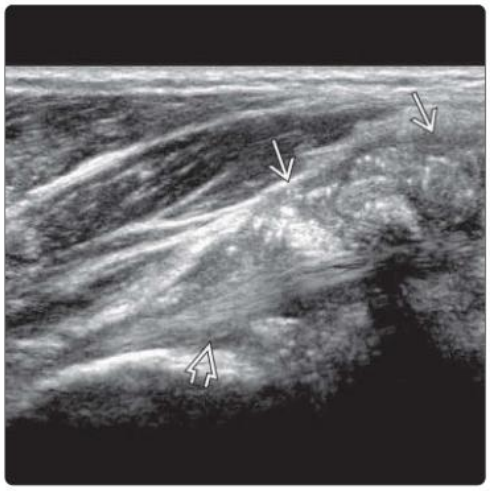

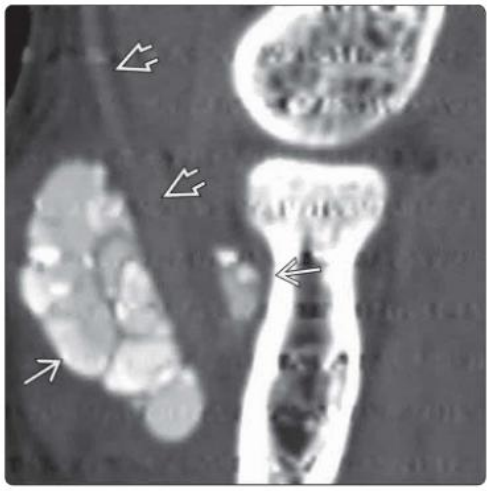

(Left) *Longitudinal US shows a distended subgluteus medius bursa deep to a normal gluteus medius tendon overlying the superior facet of the greater trochanter.* **(Right)** *Transverse US of the buttock shows a severely distended ischial bursitis with a mixed cystic and solid component overlying the ischial tuberosity. Features can be due to chronic infective bursitis or hemorrhagic bursitis. Aspiration would help to discriminate.*

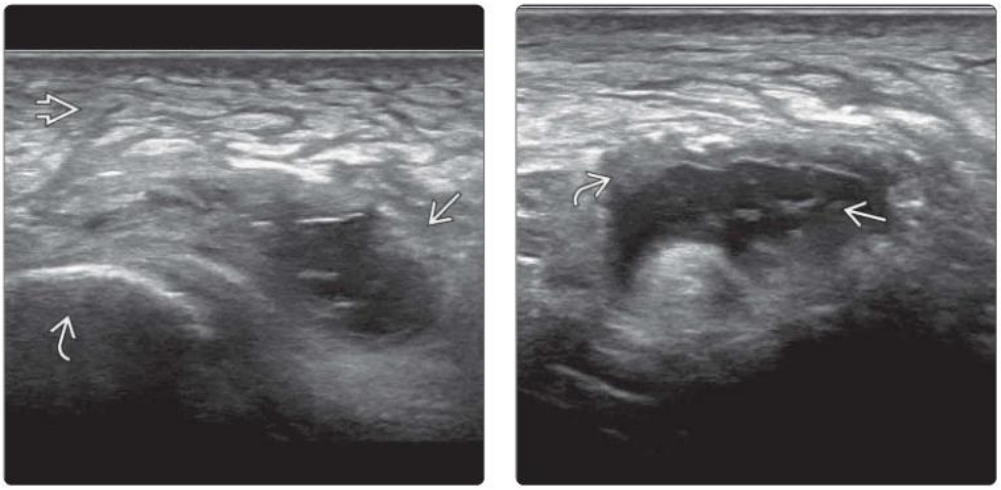

(Left) *Longitudinal US shows a mildly distended ischial bursitis ➡ overlying the ischial tuberosity ➡ in an older woman. The overlying gluteus maximus muscle (not seen) was very atrophic. The subcutaneous fat is moderately edematous ➡.* **(Right)** *Transverse US of the same distended bursa shows the moderately thick wall ➡ and echogenic particulate bursal content ➡, most likely due to proteinaceous aggregates.*

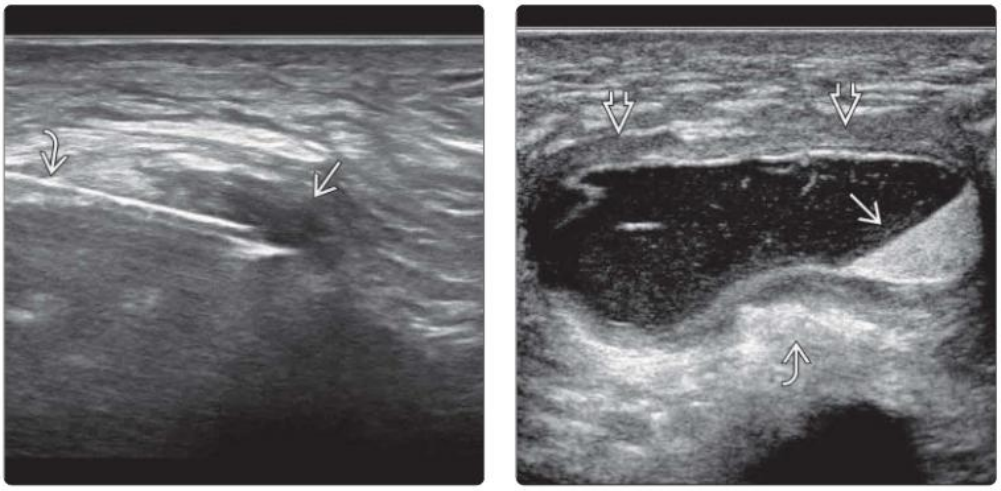

(Left) *Transverse US of the same ischial bursa ➡ during needle aspiration ➡ is shown. Clear fluid was aspirated. Steroid was injected. Aspirate culture was sterile.* **(Right)** *Transverse US of the buttock shows a thick-walled ➡, chronic ischial bursitis overlying the ischial tuberosity ➡. There is fine debris within the bursa, forming a fluid-fluid level ➡.*

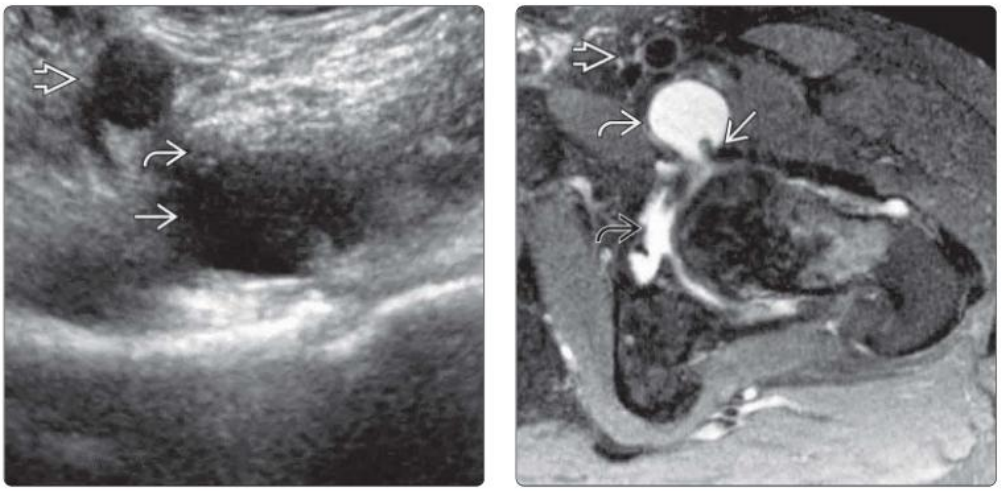

(Left) *Transverse US of the anterior hip region shows a fluid-distended bursa ➡ alongside the iliopsoas tendon ➡. Note the anteriorly located common femoral artery ➡.* **(Right)** *Axial T2 FS MR in the same patient shows moderate iliopsoas bursal distention ➡, which communicates via a short tract with the underlying joint ➡. The adjacent iliopsoas tendon ➡ and common femoral vessels ➡ are shown.*

(Left) *Longitudinal US of the hip in middle-aged man with progressive hip pain and fever shows a fluid-distended bursa with internal septations under the iliopsoas tendon. There is a small hip joint effusion.* **(Right)** *Coronal reformatted CT in the same patient shows moderate iliopsoas bursal distention. The adjacent iliopsoas tendon and common femoral vessels are normal. Purulent fluid aspirated from the bursa grew methicillin-resistant Staphylococcus aureus.*

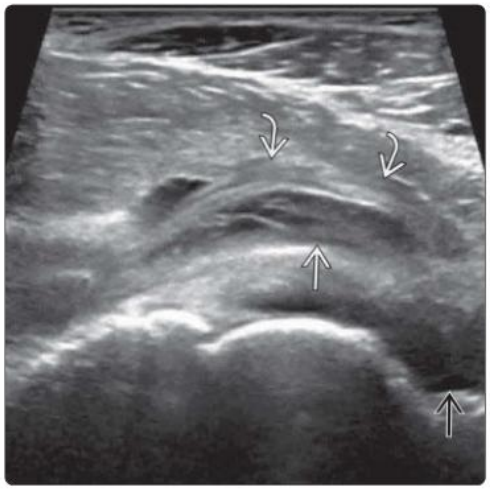

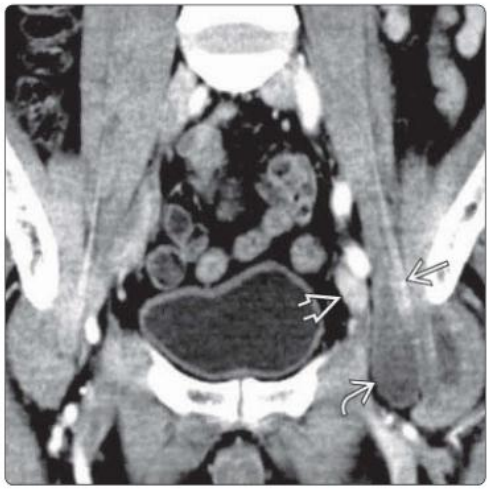

(Left) *Transverse US of the hip region shows moderate iliopsoas bursal distention anterior to the lesser trochanter. Note that the iliopsoas tendon is superficial to the bursal fluid.* **(Right)** *Coronal PD MR in the same patient shows a moderately distended iliopsoas bursa alongside the iliopsoas tendon. The bursal wall is better appreciated on MR imaging.*

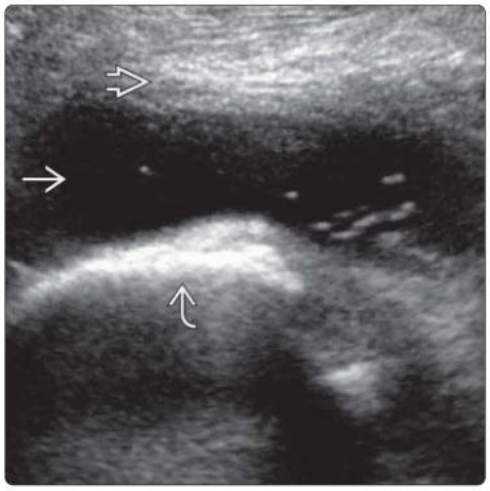

(Left) *Longitudinal US of the hip shows a large, distended iliopsoas bursa superficial to the femoral head. The echogenic strands within the bursa are due to clotted blood. The iliopsoas tendon is not visible on this image.* **(Right)** *Axial NECT of a corresponding level in the same patient shows the distended bursa with clear fluid at the iliopsoas bursa. A small fleck of calcification is present in the bursa wall. The iliopsoas tendon is at the inferomedial aspect of the bursa.*

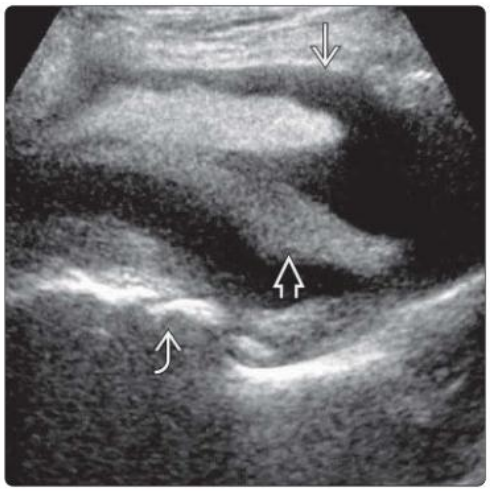

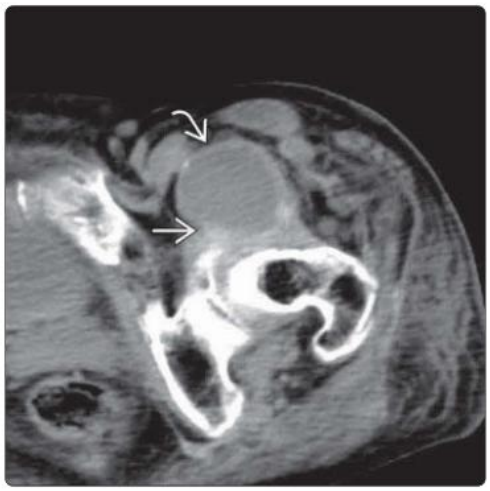

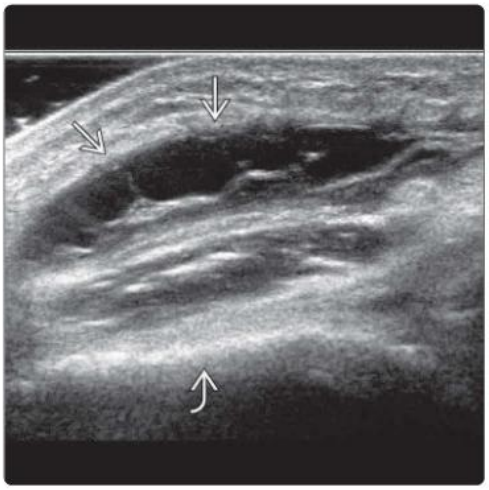

(Left) *Clinical photograph shows an eccentric prepatellar swelling ⇨ that had been present for 2 weeks.* **(Right)** *Longitudinal US of the same prepatellar region shows a mild to moderate prepatellar bursitis ⇨ superficial to the patellar bone ⇨. The bursa is distended with fluid with some thin internal septa.*

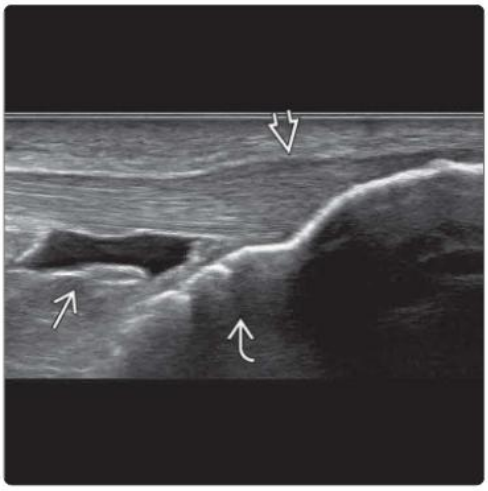

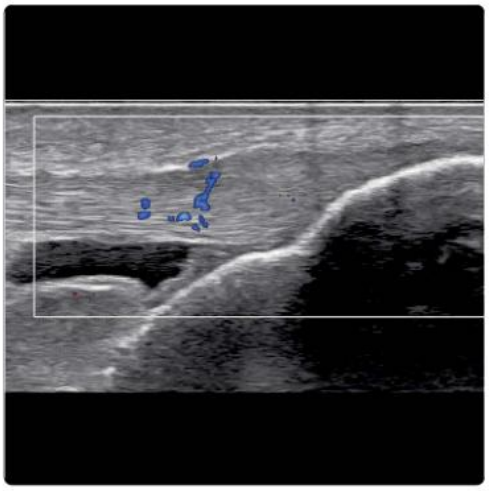

(Left) *Longitudinal US shows a deep infrapatellar bursa ⇨ just proximal to the tibia ⇨. This is more distended than the normal mild distention of this bursa. The increased bursal distention is most likely related to the overlying moderate severity patellar tendinosis ⇨.* **(Right)** *Longitudinal color Doppler US of the same area shows moderate intratendinous hyperemia indicating active tendinosis. There is no bursal hyperemia.*

(Left) *Longitudinal US shows a mildly distended, infrapatellar bursitis ⇨ superficial to the distal part of the patellar tendon ⇨. Small superficial bursae such as this can be overlooked if not specifically looked for with minimal transducer pressure.* **(Right)** *Longitudinal US shows a very distended, infrapatellar bursitis ⇨, filled with largely anechoic fluid, located superficial to the distal part of the patellar tendon ⇨. This bursa completely collapsed with needle aspiration.*

(Left) *Clinical photograph shows an older man with anterior knee swelling ⇨ following severe direct trauma.* **(Right)** *Longitudinal US of the knee in the same patient shows prepatellar bursa ⇨ distended with hematoma. There is no underlying patellar bone fracture ⇨.*

(Left) *Transverse US at the medial aspect of the popliteal fossa shows an irregular fluid collection ⇨ between the medial belly of the gastrocnemius ⇨ and the semitendinosus tendon ⇨, compatible with semitendinosus bursitis.* **(Right)** *Transverse color Doppler US in the same patient shows significant hyperemia of the peribursal soft tissues, consistent with acute inflammation.*

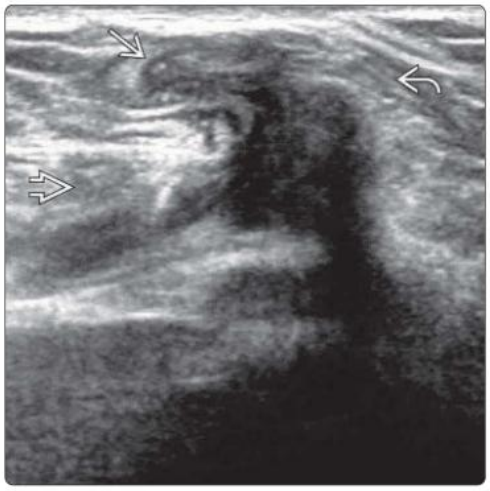

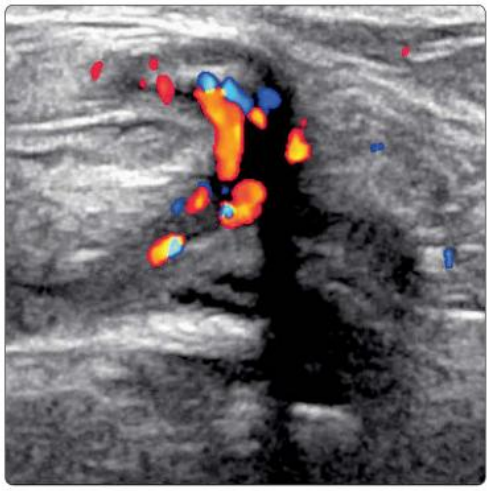

(Left) *Longitudinal oblique US of the knee close to the medial aspect of the proximal tibia ⇨ shows a fluid collection ⇨ with internal fibrous stranding ⇨ immediately adjacent to the pes anserinus tendons ⇨, compatible with a pes anserinus bursitis.* **(Right)** *Axial PD FSE FS MR of the same pes anserinus tendon bursitis shows a multiloculated cystic collection ⇨ alongside the pes anserinus tendons ⇨.*

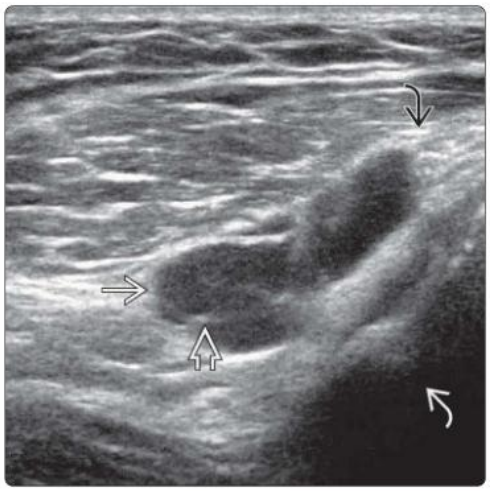

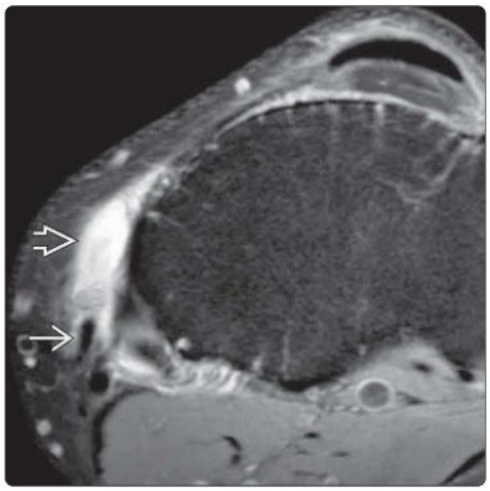

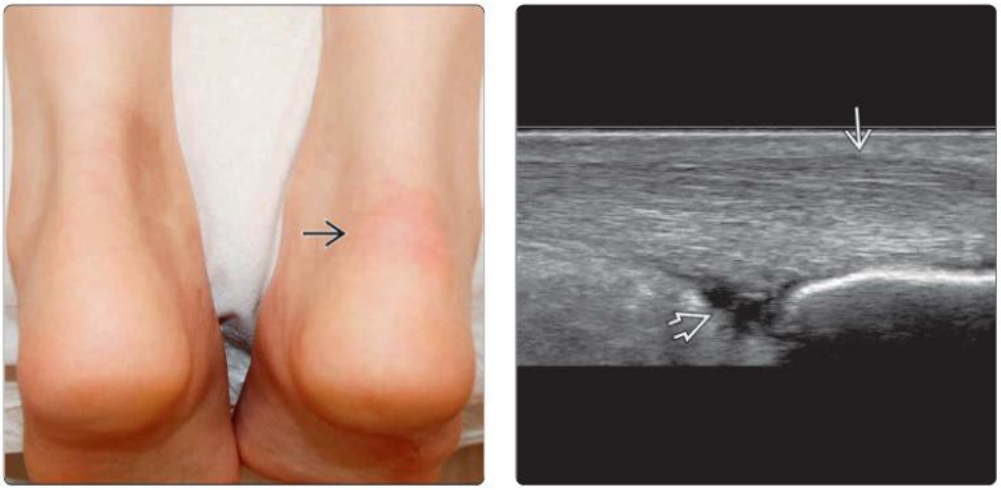

(Left) *Clinical photograph shows a patient with a history of posterior ankle swelling ⇨ and redness, who had had pain for 3 months.* **(Right)** *Longitudinal US in the same patient shows moderate Achilles insertional tendinosis ⇨ with moderate tendon thickening, some loss of the normal fibrillar pattern, and intratendinous hyperemia (not shown). There is mild retrocalcaneal bursal distention ⇨. No bursal hyperemia was present (not shown).*

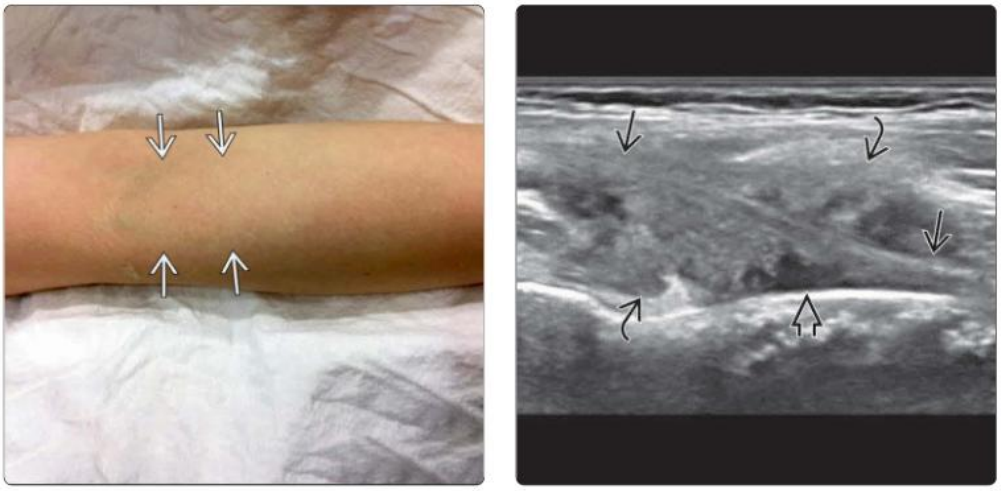

(Left) *Clinical photograph shows a 39-year-old woman with ill-defined proximal forearm soft tissue swelling ⇨ for several months, clinically suspicious of sarcoma.* **(Right)** *Longitudinal US of the same elbow shows the bicipitoradial bursa distended with proliferative synovium ⇨ and a small amount of fluid ⇨. The biceps tendon ⇨ is encased by this thickened, villonodular-like synovium.*

(Left) *Clinical photograph of a US-guided biopsy in the same patient using a coaxial-biopsy needle system is shown. Resultant biopsy specimens were sent for histology and culture to exclude infection.* **(Right)** *Transverse US during biopsy shows synovial tissue ⇨ filling the slot of the needle ⇨ prior to firing the biopsy device. Histology and culture revealed inflamed synovial tissue but no evidence of infection, crystal deposition, or malignancy.*

KEY FACTS

IMAGING

- Fluid-filled mass with stalk extending toward joint
- Ovoid or irregular configuration
  - Elongated neck allows cyst to surface at distance from joint of origin
- Anechoic with clear fluid
  - ± septation
  - ± comet-tail artifacts (due to colloid aggregates)
- Not compressible
- No hyperemia except with recent leakage when surrounding tissues may become inflamed
  - Leakage of ganglion contents induces pericystic soft tissue inflammation
- US allows diagnosis of most ganglion cysts
  - Multidirectional capability allows stalk to be traced toward joint
- Evaluate with color Doppler to exclude anechoic soft mass, such as vascular anomaly or nerve sheath tumor
- Although ganglia do not have synovial lining, joint communication enables joint pathology to occur in ganglia

CLINICAL ISSUES

- Present as palpable mass, pain due to recent leakage or extension, or, less commonly, nerve compression
- In adults, up to 50% of wrist ganglia will resolve without treatment within 6 years
- In children, > 90% of ganglion cysts will resolve without treatment within 1 year
- Aspiration (US guided)
  - > 70% complete resolution for ganglia alongside flexor tendon sheath (retinacular ganglia)
  - < 50% complete resolution for other ganglia, though they may become smaller & less symptomatic (incomplete resolution)
  - Greater success if ganglion present for < 1 year
- Surgical excision

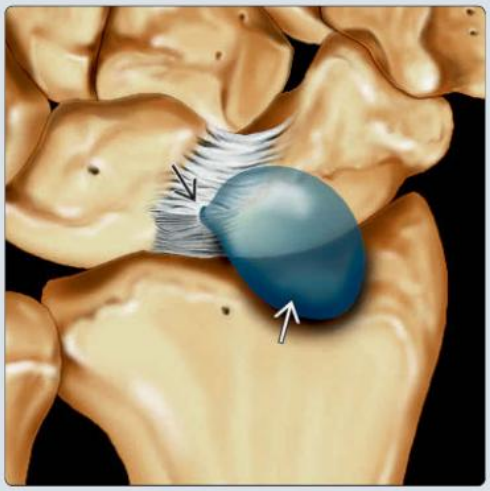

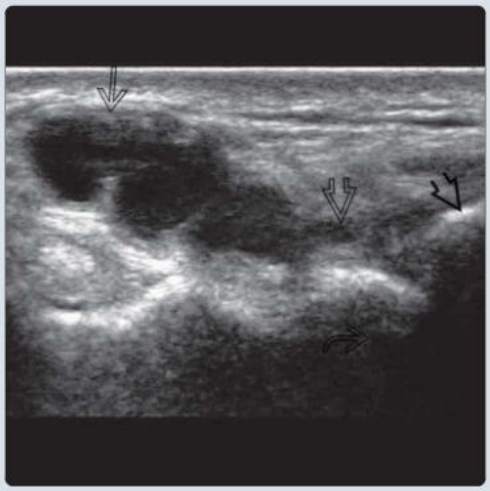

(Left) *Graphic shows the typical location of dorsal wrist ganglion cyst ➡ arising from a defect in the dorsal capsule of the scapholunate ligament ⇨. The ligament remains functionally intact.* **(Right)** *Oblique US shows a lobulated ganglion cyst ➡ on the dorsal aspect of the wrist. The stalk of the ganglion ➡ extends toward the articulation between the scaphoid ➡ and the distal radius ⇨.*

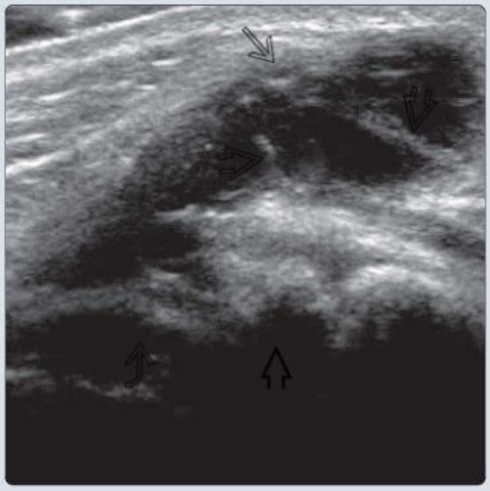

(Left) *Clinical photograph of the wrist of a young patient shows dorsal swelling ➡ suggestive of a ganglion cyst.* **(Right)** *Oblique US in the same patient shows a ganglion ➡ arising from the dorsal aspect of the radioscaphoid articulation. There is mild septation ➡ within the ganglion. The radial epiphysis ⇨ and scaphoid ➡ are shown. The small terminal branches of the posterior interosseous nerve, which may be compressed, are not easily visible on US.*

TERMINOLOGY

Synonyms

- Bible bump, Gideon disease, digital mucous cyst

Definitions

- Ganglion: Myxoid tissue encased in fibroblastic collagenous wall with no synovial lining
  - Occurs in predictable locations
- Occult ganglion: Ganglion not clinically apparent

IMAGING

General Features

- Best diagnostic clue
  - Fluid-filled mass with stalk extending toward joint
- Location
  - Dorsal wrist ganglia
    - May compress terminal branch of posterior interosseous nerve, one branch of which lies near dorsal aspect of scapholunate interval
    - Scapholunate joint
      - Typically emerge through or just distal to scapholunate ligament between 3rd & 4th extensor compartments
      - Most common type of dorsal wrist ganglion
      - Functionally intact scapholunate ligament
    - Also commonly arise from radioscaphoid joint, scaphotrapeziotrapezoid joint (triscaphe joint), & ulnocarpal joints
  - Volar wrist ganglia
    - Typically arise in weak spot between radioscaphocapitate & radiolunotriquetral ligaments (space of Poirier) overlying lunocapitate interval
    - Also arise from radioscaphoid joint, scaphotrapeziotrapezoid joint, ulnocarpal joints
    - Pisiform-triquetral joint
      - Can extend into Guyon canal & compress ulnar nerve
      - Do not confuse proximal (larger) or distal (smaller) pisotriquetral recesses with ganglia
  - Finger
    - Flexor tendon sheaths near A1 pulley or A2 pulley (retinacular ganglion)
    - Dorsal aspect of distal interphalangeal joint (digital mucous cyst)
  - Acromioclavicular joint
  - Shoulder
    - Posterosuperior, usually associated with labral tear
  - Lumbar facet joints (not usually demonstrable by US)
  - Hip: Anterosuperior, usually associated with labral tear
  - Knee
    - Paraarticular, near supracondylar attachment of medial or lateral belly of gastrocnemius
    - Around anterior & posterior cruciate ligaments
  - Proximal tibiofibular joint
    - Articular branch of deep peroneal nerve explains propensity of ganglia from this joint to extend intraneurally
    - Ganglia may extend intraneurally into deep peroneal nerve, common peroneal nerve, or even peroneal division of sciatic nerve
  - Distal tibiofibular syndesmosis
  - Foot & ankle: Cuneonavicular joint, intercuneiform joint, subtalar joint, talonavicular joint
- Size
  - Average: 5 mm; ganglia from large joint may reach > 50 mm in maximum dimension; may increase with activity
- Morphology
  - Ovoid or irregular configuration with stalk connecting to joint of origin

Radiographic Findings

- Radiography
  - Usually normal ± soft tissue density ± intraosseous carpal ganglion

MR Findings

- T2WI
  - Uniformly hyperintense soft tissue cystic mass
  - Narrow stalk connecting cyst to joint
  - Distention of capsular recess may simulate cyst
    - Capsular recesses occur in expected locations
    - If capsular recess is unusually distended for given amount of joint effusion, consider ganglion
    - Cysts often contain septations
- Very sensitive at detecting occult ganglia

Ultrasonographic Findings

- Well-defined, anechoic mass with stalk extending to joint
  - Typical locations
  - Elongated neck allows cyst to surface at distance from joint of origin
  - ± multiloculated ± thin septations
  - ± small comet-tail artifacts due to colloid aggregates
  - ± inflammatory exudate: Inflammatory content of joint can extend into ganglia
  - Not compressible
  - No hyperemia except with recent leakage when surrounding tissues may become inflamed
    - Ganglion content irritant to pericystic soft tissues
  - Check for compression of small nerves, such as posterior interosseous nerve or superficial branch of radial nerve
- Stalk may be thin & serpiginous
  - Locating joint entry site helps surgical planning
- Retinacular ganglia have no visible tendon sheath or joint communication
- Hemorrhagic cyst: Can have pseudosolid appearance
  - Will change appearance on follow-up imaging
- Ruptured cyst or cyst leakage
  - Collapsed cyst with pericystic inflammation

Imaging Recommendations

- Best imaging tool
  - US allows diagnosis of most ganglion cysts
    - Allows stalk to be traced toward joint
- Protocol advice
  - Trace stalk back toward joint of origin
  - Extension through joint capsule often not seen
    - Examining wrist in flexion ± extension may occasionally help

- Note relationship of cyst to tendons & neurovascular bundle
- Evaluate with color Doppler to exclude anechoic solid tumor
- Check for pericystic inflammation as marker of recent leakage

DIFFERENTIAL DIAGNOSIS

Giant Cell Tumor of Tendon Sheath

- Solid soft tissue mass, usually hyperemic
- Eccentrically located to tendon sheath

Vascular Anomaly

- Compressible
- ± phleboliths ± intrinsic vascular flow
- Lymphangiomas occur in different areas to ganglia
  - Do not communicate with joint

Cystic Schwannoma

- Occur at locations different to ganglia
- Neural continuity in 50%

PATHOLOGY

General Features

- Etiology
  - Typical locations are due to capsular weakness or nerve traversing capsule
    - Degenerative or traumatic tear in capsule
      - Only 15% are related to specific injury
    - Joint fluid pumped one way
    - Posttraumatic ganglia may develop over hours to days
- Associated abnormalities
  - Intraosseous ganglia are more common in subjects with soft tissue ganglia
  - Ganglion may rarely have both intraosseous & extracapsular components

Gross Pathologic & Surgical Features

- Cystic mucinous fluid is contained in pseudocapsule

Microscopic Features

- Capsular lining = compressed loose areolar tissue = pseudocapsule
- No inner cell lining (not lined by synovial tissue)
- Although ganglia do not have synovial lining, joint communication enables joint pathology to occur in ganglia

CLINICAL ISSUES

Presentation

- Most common signs/symptoms
  - Slowly growing soft tissue mass
- Clinical profile
  - Localized mass ± pain
    - Typically, pain on attempted full dorsiflexion of wrist
    - Cyst transilluminates
  - Nerve compression due to extension in carpal tunnel, cubital tunnel, tarsal tunnel, or Guyon canal (not common)

Demographics

- Age
  - 20-50 years
- Sex
  - M < F
- Epidemiology
  - 80% of all soft tissue masses of wrist & hand
    - 80% of clinically apparent wrist ganglia are located dorsally
    - 80% of wrist ganglia overall are located volarly (MR evidence)

Natural History & Prognosis

- In adults, up to 50% of wrist ganglia will resolve without treatment within 6 years
  - In children, > 90% of ganglion cysts will resolve without treatment within 1 year

Treatment

- Observe: 50% spontaneous resolution
- Active treatment
  - Indicated if cyst is painful or fails to resolve after 1 year or if it is cosmetically disfiguring
- Aspiration (US guided)
  - > 70% complete resolution for cysts alongside flexor tendon sheath (retinacular ganglia)
  - < 50% complete resolution for other ganglia, though they may become smaller & less symptomatic (incomplete resolution)
  - Greater success if ganglion is present for < 1 year
  - Aspiration ± hyaluronidase or steroid injection
    - Hyaluronidase degrades hyaluronic acid, macromolecular component of ganglion fluid
    - Leave needle in ganglion cyst; repeat aspiration after 15 minutes
  - ± dry needling to disrupt cyst wall
- Surgical
  - Open resection
    - Excision of stalk & small portion of joint capsule
      - ≤ 30% may have persistent pain or limitation of movement ± recurrence
      - 5-15% recurrence rate
  - Arthroscopic resection: Less scarring
    - Capsular defect, stalk, & cyst debrided from intraarticular approach
    - Similar recurrence rate to open resection

DIAGNOSTIC CHECKLIST

Image Interpretation Pearls

- Locate stalk of ganglion & trace toward joint of origin
- Check for free fluid or inflammation around cyst
  - These are signs of cyst leakage
- Examine with color Doppler
  - Nerve sheath tumor, giant cell tumor, & vascular anomalies may occasionally simulate cysts

SELECTED REFERENCES

1. Ferreira Branco D et al: Dorsal wrist ganglion: clinical and imaging correlation in symptomatic population based on high-field MRI. Eur Radiol. ePub, 2024
2. Reijnierse M et al: High-resolution ultrasound and MRI in the evaluation of the forefoot and midfoot. J Ultrason. 23(95):e251-71, 2023

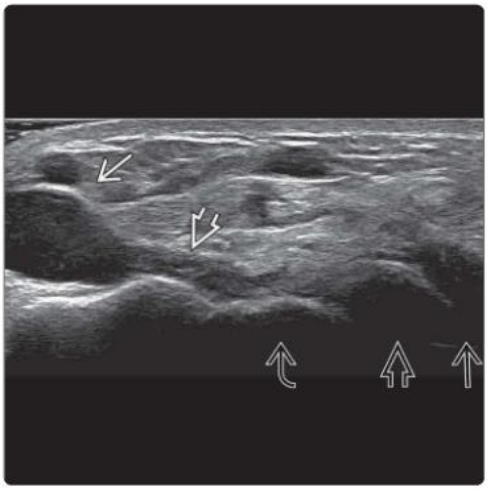

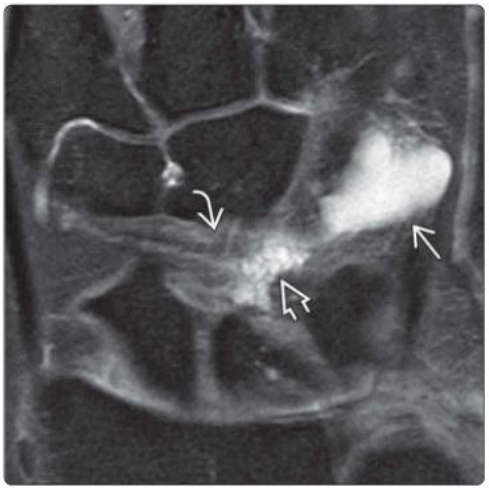

(Left) *Longitudinal US shows a ganglion ➡ arising from the dorsal aspect of the wrist. The long stalk ➡ of the ganglion allows the ganglion to be a distance from the joint of origin, the scaphocapitate articulation. Note the distal radius ⇨, scaphoid bone ⇨, and capitate bone ⇨.* **(Right)** *Coronal T2 FS MR in the same patient shows the ganglion cyst ➡ on the dorsal aspect of the wrist with a serpiginous stalk ➡ extending through the dorsal intercarpal ligament ⇨ to the scaphocapitate articulation.*

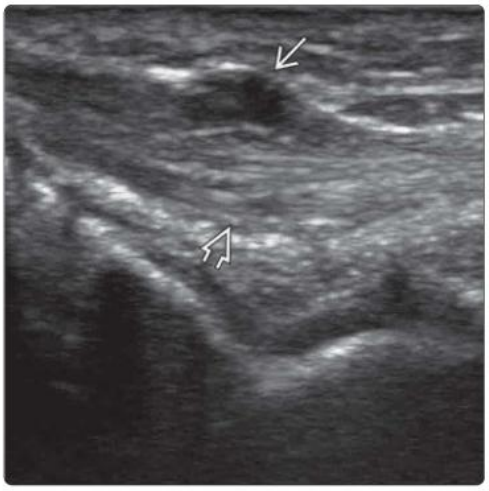

(Left) *Transverse US of the dorsal wrist shows a small ganglion ➡ on the dorsal aspect of the extensor digitorum tendon ➡. The ganglion lies within the extensor digitorum tendon sheath ⇨.* **(Right)** *Longitudinal US of the same lesion shows that the ganglion cyst ➡ lies just superficial to the extensor tendon to the little finger ➡.*

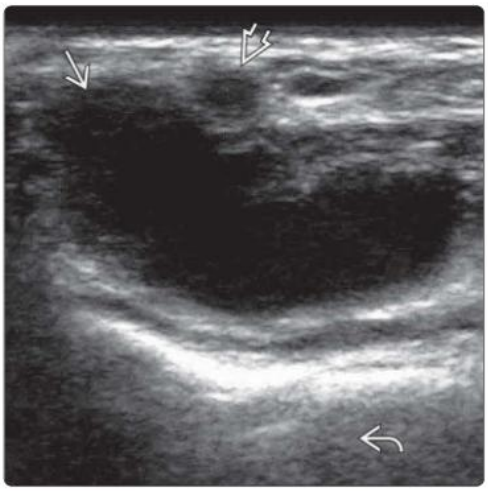

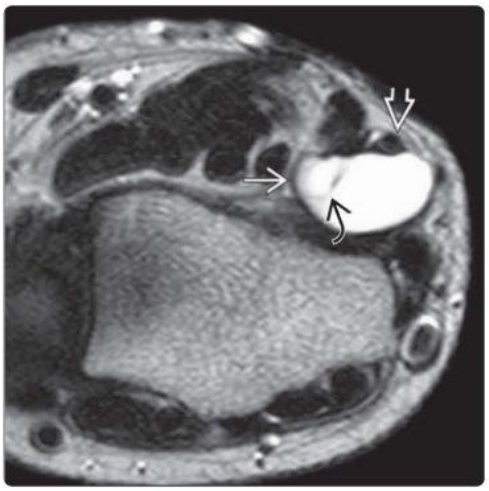

(Left) *Transverse US shows a medium-sized, lobulated ganglion ➡ on the volar aspect of the distal radius ⇨. The ganglion lies deep to the radial artery ➡.* **(Right)** *Axial T2 MR in the same patient shows the ganglion ➡ lying deep to the radial artery ➡. There is a thin septum ⇨ within the ganglion. It is important to identify any large arteries or nerves lying alongside ganglia.*

(Left) *Transverse US shows a multiseptated ganglion ➡. The ganglion lies on the superficial and ulnar aspect of the A1 pulley ➡ of the ring finger. This type of ganglion is sometimes referred to as a retinacular or pulley ganglion.* **(Right)** *Transverse US shows a small pulley ganglion ➡. The ganglion lies on the ulnar aspect of the A2 pulley ➡ of the ring finger. Ganglia are less common around the A2 pulley than around the A1 pulley.*

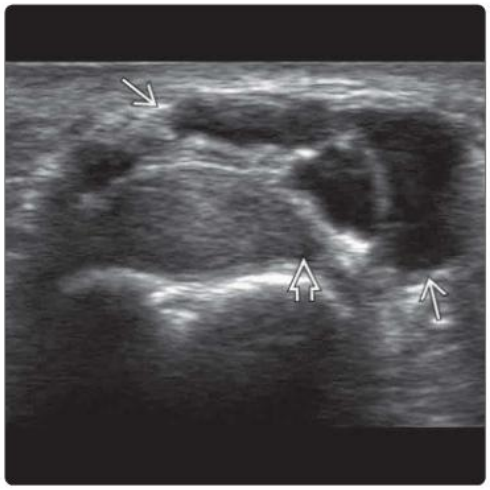

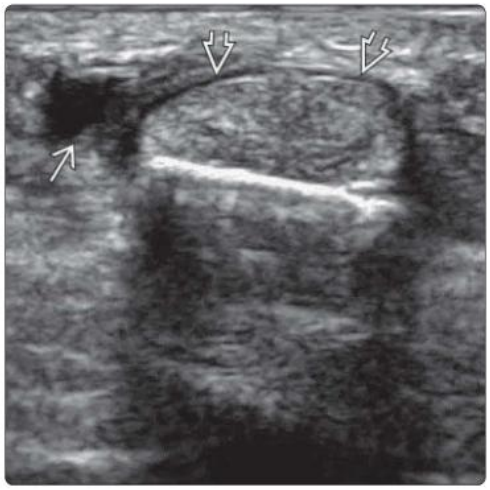

(Left) *Clinical photograph shows swelling ➡, consistent with a ganglion on the dorsal aspect of the middle finger. These cysts are covered only by skin and may be translucent.* **(Right)** *Longitudinal US in the same patient shows a subcutaneous unilocular ganglion ➡ located dorsal to the extensor tendon ➡ of the middle finger. This ganglion most likely arises from the distal interphalangeal joint and is sometimes called a digital mucous cyst.*

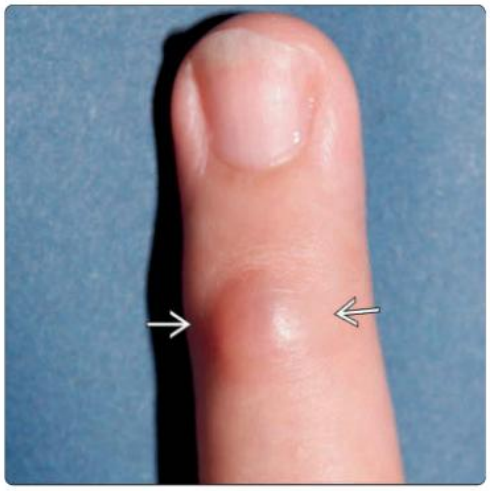

(Left) *Clinical photograph shows swelling ➡ that is suspicious of a ganglion on the ulnovolar aspect of the proximal phalanx close to the proximal interphalangeal joint of the index finger.* **(Right)** *Longitudinal US in the same patient shows an echogenic ganglion ➡ just proximal to the proximal interphalangeal joint ➡. No direct communication with the joint is visible, though the thin stalk ➡ of the ganglion does point toward the joint. A small percentage of ganglia are echogenic.*

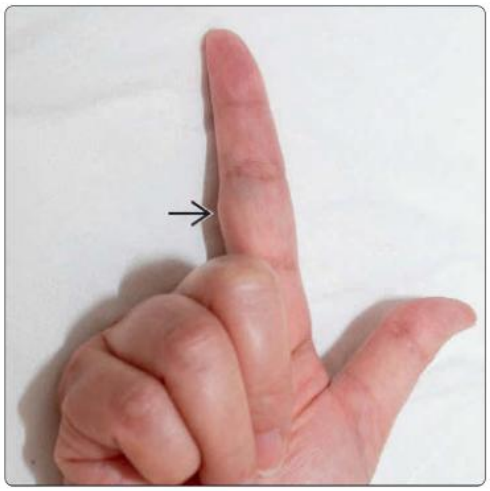

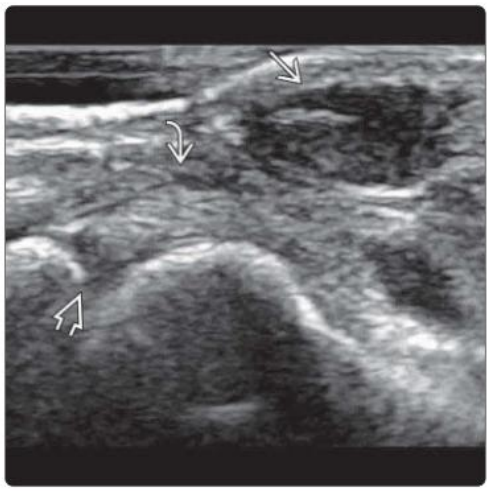

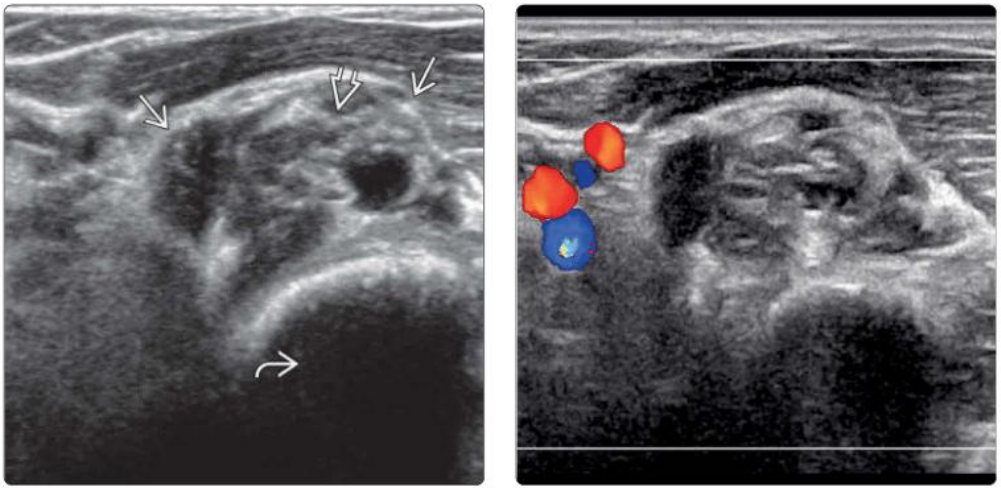

(Left) *Transverse US shows a complex ganglion ⇨ with thick septations ⇨ on the anterior aspect of the elbow just superficial to the radial head ⇨. This ganglion can simulate a solid mass.* **(Right)** *Transverse color Doppler US of the same ganglion shows no vascularity within the septa of the ganglion.*

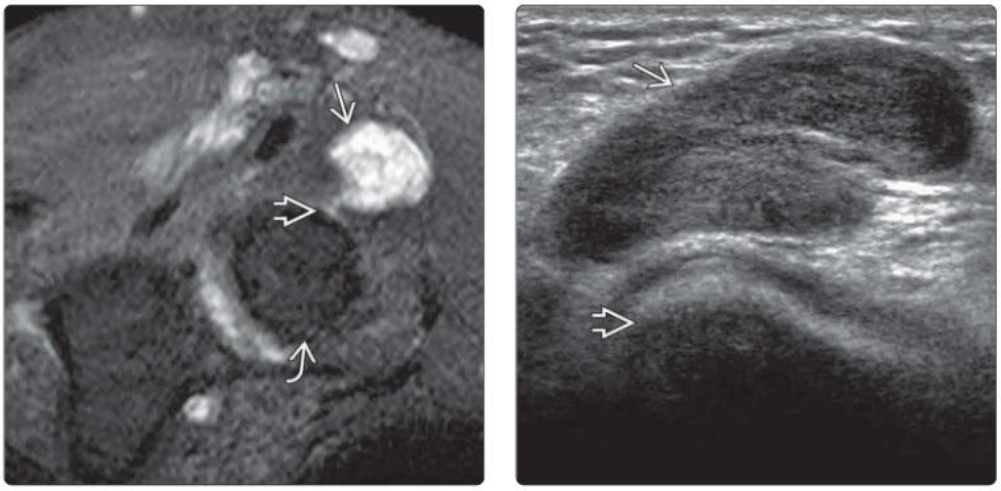

(Left) *Axial T2 FS MR of the same patient shows the ganglion ⇨ located anterior to the radial head ⇨. A small tract ⇨ extending from the ganglion toward the elbow joint is visible.* **(Right)** *Oblique US shows a ganglion ⇨ located posterior to the olecranon process ⇨. This should not be confused with an olecranon bursa. A bursa will not point toward the elbow joint.*

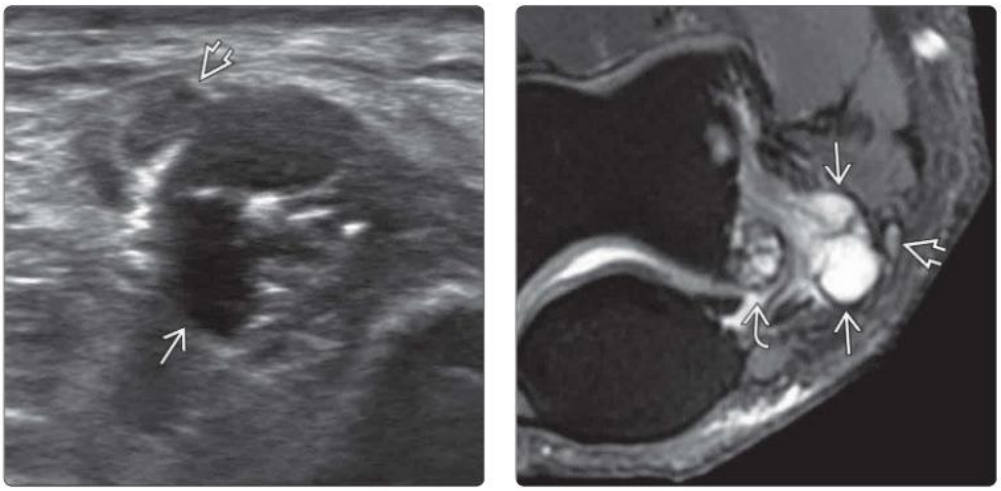

(Left) *Transverse US in 63-year-old man with recurrence of cubital tunnel syndrome symptoms 1 year after medial epicondylectomy shows a multiseptated ganglion cyst ⇨ with a tail extending to elbow joint (not shown). The cyst compresses and displaces the ulnar nerve ⇨ superficially.* **(Right)** *Axial T2 FS MR in the same patient confirms a ganglion cyst ⇨ arising from the medial elbow joint and compressing the ulnar nerve ⇨. Note the severe hypertrophic osteoarthritis of the elbow joint medially ⇨.*

(Left) *Transverse US shows a large ganglion ⇨ with septation ⇨ and internal echogenic foci due to colloid aggregates ⇨ superficial to the acromioclavicular joint ⇨. The stalk ⇨ of the ganglion extends toward the acromioclavicular joint.* **(Right)** *Transverse US shows a small ganglion ⇨ anterior to the acromioclavicular articulation. The thick-walled stalk ⇨ of the ganglion extends toward the acromioclavicular joint. The clavicle ⇨ and acromion ⇨ are shown.*

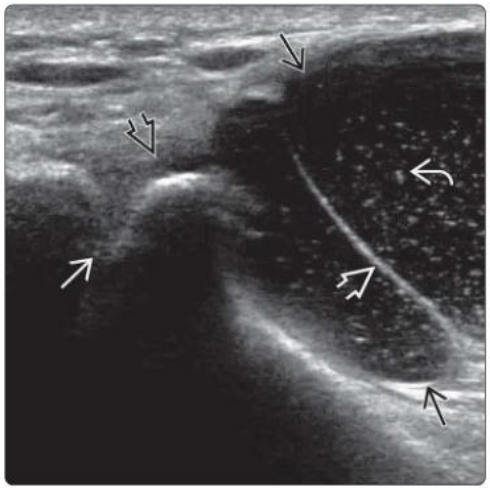

(Left) *Transverse US in an older adult woman with chronic shoulder pain shows a small ganglion cyst ⇨ within the suprascapular notch ⇨. The supraspinatus muscle ⇨ superficial to the suprascapular notch is shown.* **(Right)** *Coronal T2 FS MR in the same patient confirms the multilobulated ganglion cyst ⇨ located at the suprascapular notch ⇨. There was no muscle denervation or atrophy of the supraspinatus and infraspinatus muscles.*

(Left) *Transverse US of the posterior knee shows a ganglion ⇨ lying just posterior to the proximal tibiofibular joint between the tibia ⇨ and fibula ⇨. It has a pseudosolid appearance due to internal hemorrhage.* **(Right)** *Axial PD FS MR of the same ganglion ⇨ is located in the popliteal fossa alongside the popliteal artery ⇨ and vein ⇨.*

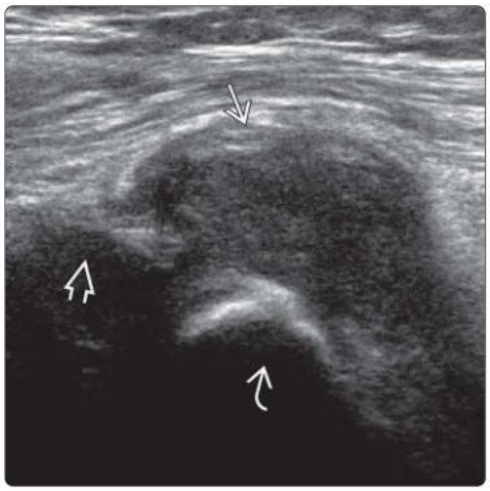

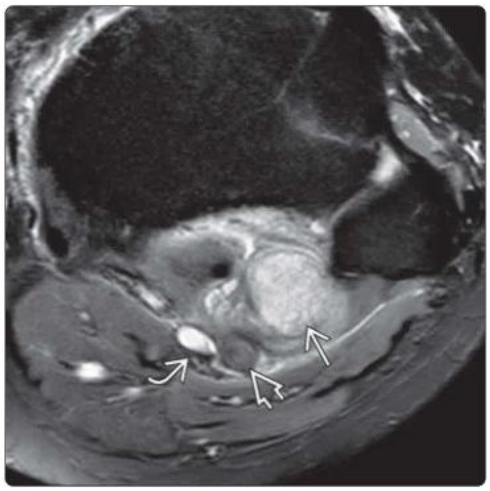

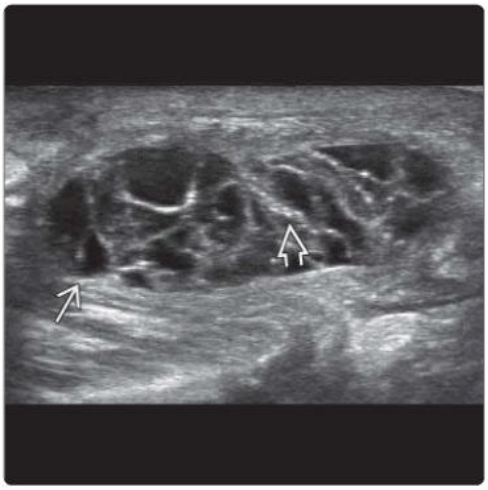

(Left) *Longitudinal US shows a paraarticular ganglion ⇨ on the anteromedial aspect of the knee joint. The ganglion is thick walled with thick septa ⇨. This thickening of the cyst wall is likely consequent on repeated intracystic hemorrhage.* **(Right)** *Transverse US of the same lesion more distally shows that the ganglion ⇨ communicates with the knee capsule ⇨. The tract ⇨ is filled with synovial tissue without any free fluid communication between the knee joint and this paraarticular ganglion cyst.*

(Left) *Transverse US of the knee region shows a ganglion ⇨ lying anterior to the external opening ⇨ of the tibial tunnel of an anterior cruciate ligament graft. This tunnel will communicate with the knee joint, allowing for expression of synovial fluid along the tunnel and into the ganglion.* **(Right)** *Clinical photograph shows a large, cystic swelling ⇨ on the lateral aspect of the ankle. This swelling occurred 2 days after a relatively minor ankle sprain.*

(Left) *Transverse US in the same patient shows a large, acute, posttraumatic ganglion ⇨ lateral to the fibula ⇨. The tiny echogenic foci ⇨ within the ganglion cyst are due to colloid aggregates suspected within the gelatinous matrix of the ganglion. They are not a sign of chronicity.* **(Right)** *Transverse color Doppler US in the same patient shows a small tract ⇨ from the anteromedial aspect of the ganglion extending toward the ankle joint with minimal vascularity ⇨ in the ganglion wall.*

(Left) *Oblique US shows a ganglion on the dorsal aspect of the foot superficial to the articulation between the intermediate cuneiform and the medial cuneiform. No artery is visible on this image.* **(Right)** *Oblique color Doppler US of the same area shows that the dorsalis pedis artery lies on the side of the ganglion. This artery could potentially be injured during percutaneous aspiration if no color Doppler imaging was performed beforehand.*

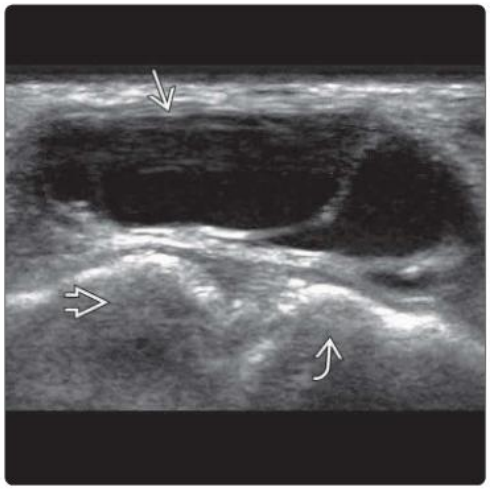

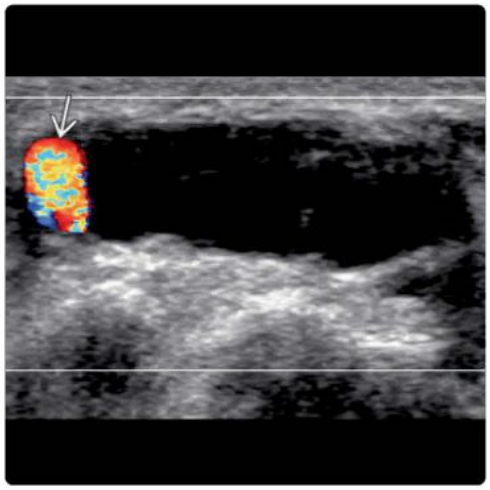

(Left) *Clinical photograph shows a small swelling on the lateral dorsal aspect of the midfoot.* **(Right)** *Longitudinal US in the same patient shows a unilocular ganglion on the lateral dorsum aspect of the midfoot overlying the cuboid bone with a serpiginous neck extending into the articulation between cuboid bone and base of the 4th metatarsal base. Dorsal foot ganglia are much more common than plantar foot ganglia.*

(Left) *Transverse US shows a ganglion on the plantar aspect of the big toe. The ganglion lies medial to the flexor hallucis longus tendon, which lies between the medial and lateral sesamoid bones.* **(Right)** *Oblique US shows a thick-walled ganglion on the dorsal aspect of the navicular /cuneiform joint. This thick wall is most likely the result of repeated leakage and recurrent pericystic inflammation. Excessive transducer pressure may efface the fluid component.*

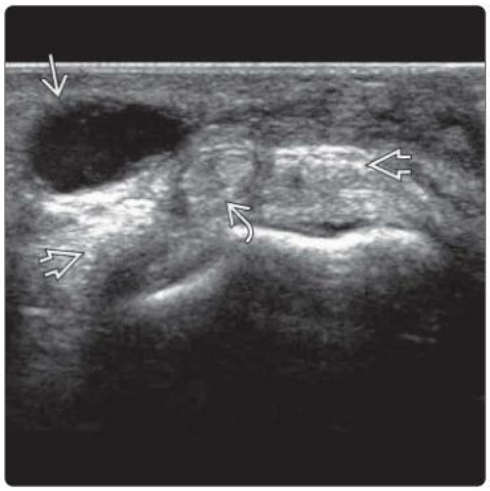

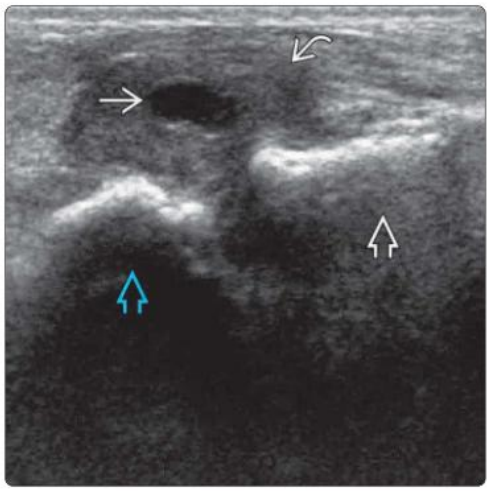

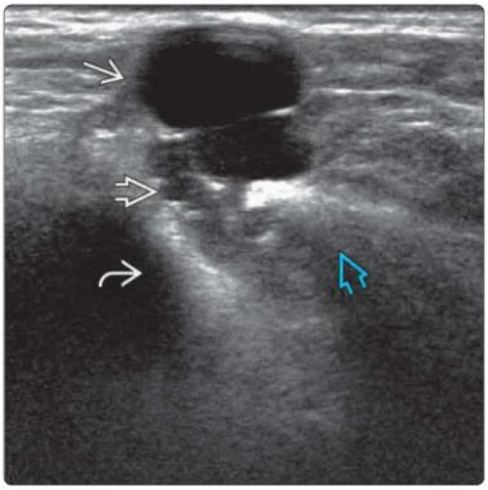

(Left) *Transverse US shows a small, lobulated ganglion ➡ arising from the posterolateral aspect of the ankle joint. The stalk ➡ of the ganglion extends deep to the articulation between the distal fibula ➡ and the talus ➡.* **(Right)** *Axial T2 FS MR in the same patient shows the lobulated ganglion ➡ on the posterolateral aspect of the ankle. The ganglion stalk is not clearly seen. Occasionally, US is superior to MR in this respect.*

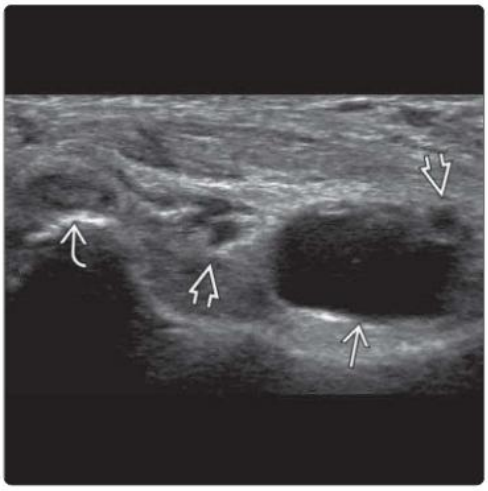

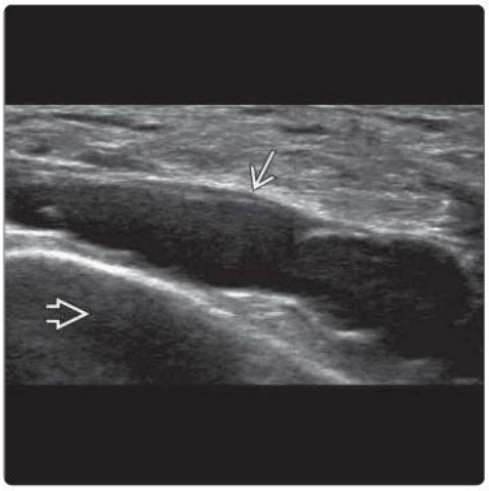

(Left) *Transverse US in a middle-aged man with medial ankle swelling and numbness in the foot shows a ganglion cyst ➡ within the tarsal tunnel. It is located in proximity to the neurovascular bundle ➡ in the tarsal tunnel. The flexor digitorum longus tendon ➡ anteriorly is normal.* **(Right)** *Longitudinal US of the same ganglion ➡ shows that the ganglion extends far into the distal aspect of the tarsal tunnel. The calcaneum ➡ forms the floor of the tarsal tunnel.*

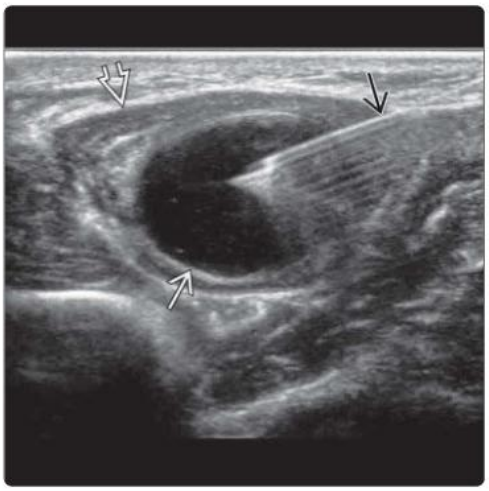

(Left) *Sagittal T2 FS MR of the same area confirms an elongated, multilobulated ganglion cyst ➡ within the tarsal tunnel. Note its proximity to the flexor hallucis longus tendon ➡.* **(Right)** *Longitudinal US shows a unilocular ganglion ➡ within the flexor carpi ulnaris muscle ➡ at the elbow region. Aspiration was performed using a 21-g needle ➡. It is not possible to predict the viscosity of ganglion content on US prior to aspiration.*

KEY FACTS

IMAGING

- Cystic mass in continuity with horizontal meniscal tear
  - Medial parameniscal cyst more common than lateral parameniscal cyst
- Meniscal tear forces synovial fluid or mucoid content into parameniscal cyst
- Cyst is usually well defined & filled with anechoic or hypoechoic, gelatinous-type fluid
  - Meniscal tear does not always have to be present
    - Tear may have healed
  - Especially with anterior horn lateral meniscus
- Cyst may lie in direct continuity with meniscus or connect via serpiginous connecting stalk
- Colloid content of parameniscal cyst similar to that of ganglion & Baker cyst
  - Diagnosis of parameniscal cyst relies on showing continuity between cyst & meniscus
- Pericystic soft tissue inflammation is feature of recent cyst leakage
- Parameniscal cysts, especially medially, can be very large
- Comment on cyst size, loculation, extent, associated meniscal tear, recent cyst leakage ± localized inflammation
  - MR to assess meniscal tear
  - Intracapsular parameniscal cysts may not be visible on US
- US-guided aspiration ± hyaluronidase injection ± steroid injection
  - Provides temporary & often long-term symptom relief
    - Especially for smaller cysts & poor surgical candidates

DIAGNOSTIC CHECKLIST

- Not every paraarticular cyst with pedicle extending to knee joint is parameniscal cyst
  - Need to distinguish from paraarticular ganglion
- Inflammation around parameniscal cyst usually results from recent leakage or extension
  - Cyst content is irritant to paraarticular soft tissues
  - Leakage common cause of symptom exacerbation

(Left) *Clinical photograph shows moderate swelling on the medial aspect of the knee around the medial joint line due to a parameniscal cyst.* **(Right)** *Longitudinal US of the medial aspect of the same knee shows a large parameniscal cyst located superficial to the medial collateral ligament. The cyst is extending proximally toward the knee joint.*

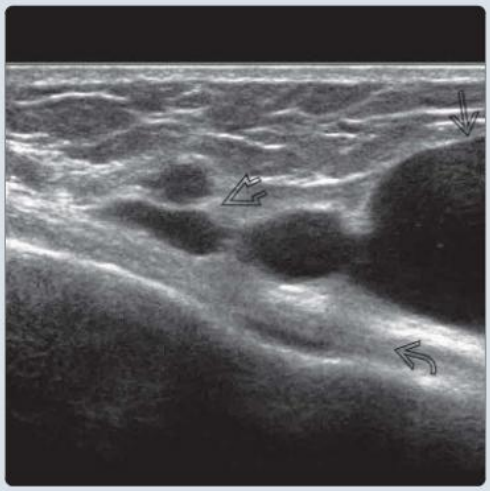

(Left) *Longitudinal US just proximal to the previous image in the same patient shows a thin tract extending through the medial collateral ligament toward the periphery of the thinned degenerate medial meniscus.* **(Right)** *Graphic shows horizontal meniscal tear ("fish mouth" tear) with meniscal mucoid degeneration and a small parameniscal cyst arising from the peripheral aspect of the tear. Meniscal tears are much better depicted on MR than US.*

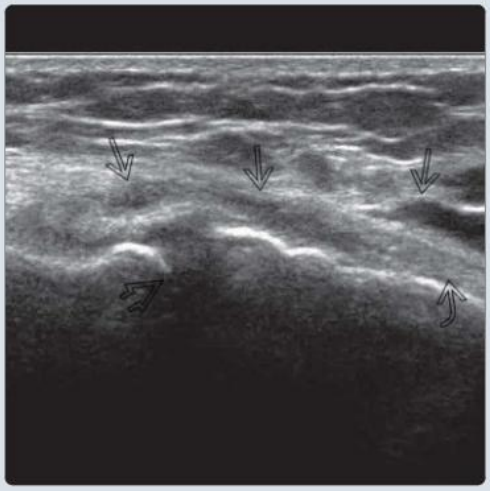

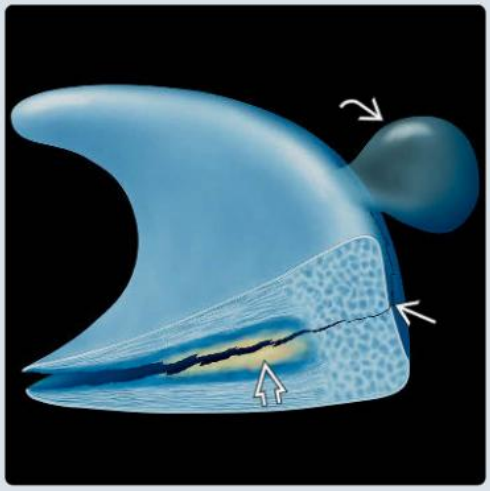

TERMINOLOGY

Synonyms

- Meniscal cyst
  - This term should be reserved for intrameniscal cysts

Definitions

- Cyst extending from meniscal tear
  - Usually horizontal tear (most common) or complex tear (2nd most common)

IMAGING

General Features

- Best diagnostic clue
  - Cystic mass in continuity with meniscal tear
- Location
  - Can arise from any part of meniscus
    - Medial meniscus (60%), lateral meniscus (40%)
  - Most common locations
    - Junction between body & posterior horn medial meniscus (posterior to medial collateral ligament)
    - Junction between body & anterior horn lateral meniscus (anterior to lateral collateral ligament)
- Size
  - Tiny (few mm) to large, extraarticular cyst (> 10 cm)
  - Medial parameniscal cyst usually larger
- Morphology
  - Extension from parameniscal area on medial & lateral aspects of knee
  - Cysts from medial meniscus often extend either
    - Inferiorly deep to semimembranosus & pes anserinus tendons
    - Anteriorly superficial to medial collateral ligament or into Hoffa fat pad
    - Posteriorly toward popliteal fossa
  - Medial parameniscal cysts mainly can extend quite some distance from meniscal tear
  - Cysts from lateral meniscus often extend deep to iliotibial tract or lateral collateral ligament
    - Lateral parameniscal cysts tend to remain more localized

MR Findings

- T1WI
  - Hypointense mass
  - If proteinaceous, may be iso- or hyperintense
- T2WI
  - Rounded, hyperintense mass
    - Lobulation & septation
  - Tear = linear, hyperintense meniscal signal extending to articular surface
    - Peripheral meniscal tear may not visibly connect with meniscal articular surface (noncommunicating tear)

Ultrasonographic Findings

- Parameniscal cyst ± extraarticular component with communicating stalk
  - Meniscal tear does not always have to be present, especially from anterior horn of lateral meniscus
- Meniscus is seen as diffusely echogenic, sharply defined structure within medial & lateral femorotibial compartments
  - Medial meniscus easier to see on US
    - Only peripheral part of menisci seen on US
  - Body of menisci is best seen with limited views of other areas
- Meniscal tear = linear or wedge-shaped hypoechogenicity within meniscus extending to meniscal periphery
  - Be careful because normal meniscus echotexture can mimic horizontal tear
  - Extrusion of medial meniscal body is common accompanying feature
- Parameniscal cyst
  - Usually well-defined & filled with anechoic or hypoechoic gelatinous-type fluid, or, uncommonly, heterogeneous hyperechoic appearance
  - ± multiloculation ± septation ± comet-tail artifacts due to colloid aggregates
  - ± echogenic mass/debris (due to proteinaceous content or previous hemorrhage)
  - Edema, swelling, & hyperemia around cyst indicates recent leakage, which leads to localized inflammation
    - Check for free fluid around cyst (sign of recent cyst leakage)
- Cyst may lie in direct continuity with meniscus or connect via connecting stalk (pedicle)
  - Communicating stalk is usually serpiginous & narrow
  - Cyst may be located some distance from meniscal tear
- Cyst and contents of parameniscal cyst are similar to ganglia and Baker cyst: All 3 contain gelatinous material
  - Main differences
    - Stalk in parameniscal cyst → meniscal tear
    - Stalk in paraarticular ganglion → joint
    - Stalk in Baker cyst → between semimembranosus tendon & medial gastrocnemius muscle → joint
- If meniscal communication is not seen, then parameniscal cyst can only be suggested as diagnosis
  - Sometimes difficult to distinguish parameniscal cyst & paraarticular ganglion
  - Diagnosis relies on seeing continuity between cyst & meniscus

Imaging Recommendations

- Best imaging tool
  - US: 1st line of investigation (accuracy 90%)
    - Very accurate at detecting cystic nature of paraarticular mass
    - Will show meniscal origin in most parameniscal cysts
  - MR: Helpful to fully assess meniscal integrity
    - Best to show meniscal tear, articular surface extension of tear, & degree of meniscal degeneration
- If extraarticular cyst, locate stalk of cyst
  - Trace stalk of cyst to knee joint
  - Determine if stalk originates from meniscal tear
- Note relationship of cyst to adjacent structures
  - Medially: Medial collateral ligament & pes anserinus (sartorius, gracilis, semitendinous) tendons
  - Laterally: Iliotibial band, lateral collateral ligament, & popliteus tendon
- Start examination with knee extended

- Examine with varying degrees of flexion to accentuate visualization of meniscal tear ± stalk (optional)
- Examine anterior horn of menisci with knee flexed

DIFFERENTIAL DIAGNOSIS

Paraarticular Ganglion Cyst

- Can extend from intraarticular to extraarticular compartment
- Does not originate from meniscal tear

Bursitis

- Medial parameniscal cyst mimicked by
  - Semimembranosus bursitis, pes anserinus bursitis, or medial collateral ligament bursitis
- Lateral parameniscal cyst mimicked by
  - Deep infrapatellar bursa (anteriorly located)

Baker Cyst

- Distension of semimembranous-gastrocnemius bursa
  - Popliteal cyst with "talk bubble" configuration
  - Stalk arises through interspace between semimembranous tendon & medial belly gastrocnemius muscle

PATHOLOGY

General Features

- Etiology
  - All have underlying meniscal abnormality
    - > 90% have meniscal tear, invariably with horizontal component ± meniscal degeneration
    - Cysts also arise from complex tears with horizontal component
  - Forcing of synovial joint fluid through horizontal meniscal tear into cyst
    - Compression/decompression of horizontal tear with knee movement forces fluid into cyst
  - 1/3 of tears associated with parameniscal cyst do not extend to meniscal articular surface
    - Articular surface extension too small to see or may have healed
    - Cyst content generated solely from meniscal mucoid degeneration but not synovial fluid
  - Anterior horn of lateral meniscus parameniscal cyst typically not associated with meniscal tear
    - Cyst extends to Hoffa fat pad or into anterior meniscal root
  - More likely when horizontal tear is associated with discoid meniscus or meniscocapsular separation

Gross Pathologic & Surgical Features

- Cyst filled with mucinous-type fluid
  - In continuity with horizontal cleavage meniscal tear or flap (oblique) tear with predominately horizontal component

CLINICAL ISSUES

Presentation

- Most common signs/symptoms
  - Palpable mass ± pain/discomfort near joint line ± limitation of movement
  - Size varies with knee position
    - Palpable lateral cyst at 15-30° of flexion, which disappears at full extension & flexion (Pisani sign)
  - Consistency varies from fluctuant to firm or hard
  - Pain tends to settle, though cyst may remain unchanged
    - Symptom exacerbation usually associated with recent cyst leakage or extension

Demographics

- Age
  - Peak: 20-40 years; mean: 41 years
- Sex
  - M > F
- Epidemiology
  - Relatively common: 2-4% of all knee MR exams

Treatment

- US-guided aspiration of cyst
  - ± intracystic percutaneous steroid injection
    - ± prior hyaluronidase injection if cyst content too viscous to aspirate
  - Cyst tends to recur but seems to provide good temporary relief
    - Efficacy of percutaneous treatment not fully evaluated
  - Sometimes, percutaneous aspiration & steroid injection provides long-term relief
    - Especially helpful in poor surgical candidates
  - Not possible to predict cyst viscosity on US
    - Viscosity determined during attempted aspiration
- Arthroscopic or open cystectomy & repair of tear or decompression of cyst
  - Cysts treated with decompression are 6x more likely to recur than those cysts excised

DIAGNOSTIC CHECKLIST

Consider

- Not every paraarticular cyst with stalk extending to knee joint is parameniscal cyst
  - Intraarticular ganglion cyst with paraarticular extension can look very similar
- Demonstration of meniscal tear extending to articular surface is relevant as this will affect operative approach
  - Arthroscopic if communicating meniscal tear present
  - Open if noncommunicating meniscal tear present

Image Interpretation Pearls

- Cyst alongside meniscus in continuity with meniscal tear = parameniscal cyst
  - Meniscal tear usually has horizontal component

Reporting Tips

- Comment on cyst size, loculation, extent, associated meniscal tear, recent cyst leakage, or localized inflammation

SELECTED REFERENCES

1. Saraiva L et al: Parameniscal cyst: an important differential diagnosis in slow growing masses of the knee. ARP Rheumatol. 2(1):83-4, 2023

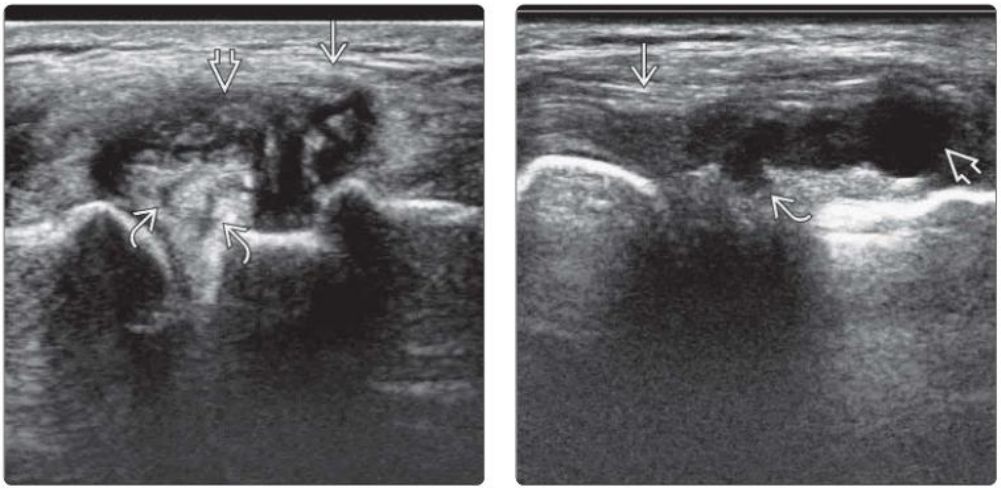

(Left) *Longitudinal US shows a complex tear ⇨ at the periphery of the extruded degenerate medial meniscus. It is associated with a medium-sized paramenisical cyst ⇨ lying deep to the medial collateral ligament ⇨.* **(Right)** *Longitudinal US shows a paramenisical cyst ⇨ deep to the medial collateral ligament ⇨. The cyst connects to a horizontal peripheral tear ⇨ of the medial meniscus.*

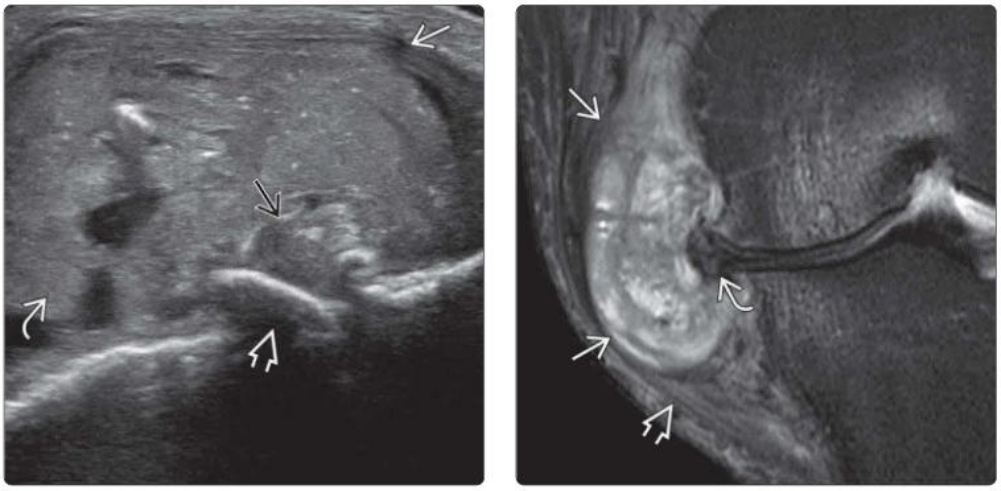

(Left) *Longitudinal US shows a large paramenisical cyst ⇨ with echogenic content displacing the medial collateral ligament ⇨ superficially. The cyst is continuous with a tear ⇨ in the periphery of an extruded, degenerate, flattened medial meniscus with adjacent marginal osteophytosis ⇨.* **(Right)** *Coronal T2 FS MR at the same location shows a large paramenisical cyst ⇨. There is a horizontal tear of the extruded medial meniscus ⇨. The medial collateral ligament is displaced superficially ⇨.*

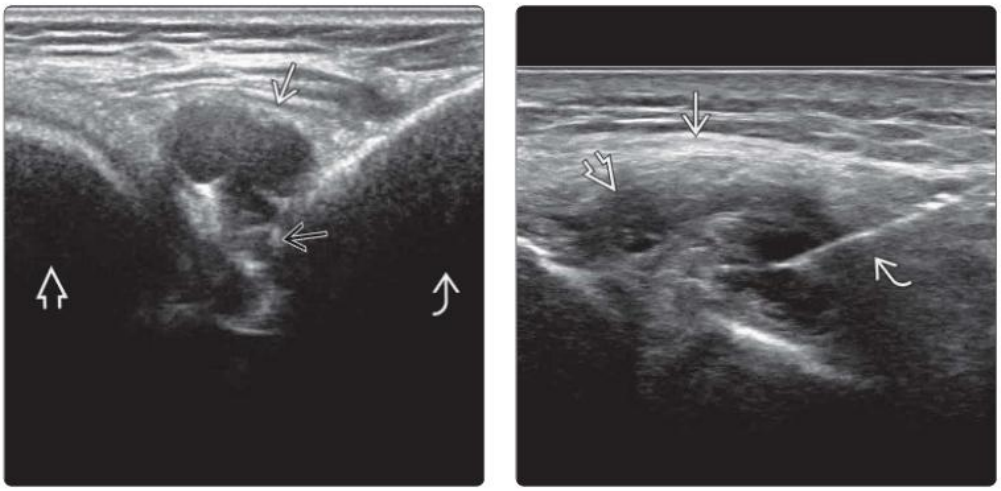

(Left) *Longitudinal US shows a medium-sized paramenisical cyst ⇨ on the anterolateral aspect of the knee between the femoral ⇨ and tibial ⇨ condyles. The tail of the cyst ⇨ extends deeply toward the anterior horn of the lateral meniscus.* **(Right)** *Longitudinal US shows a paramenisical cyst ⇨ deep to the lateral collateral ligament ⇨. US-guided aspiration and steroid injection with the needle tip ⇨ in the cyst is shown. If no fluid can be aspirated, hyaluronidase can be injected and aspiration repeated after 20 minutes.*

KEY FACTS

TERMINOLOGY

- Tenosynovial giant cell tumor (TSGCT)
  - Diffuse intraarticular, localized intraarticular, & tendon sheath forms
- Synovial (osteo)chondromatosis
- Less common synovial tumors
  - Lipoma arborescens, synovial hemangioma, synovial lipoma, synovial fibroma, synovial chondrosarcoma, synovial infiltration (e.g., lymphoma)

IMAGING

- Localized synovial swelling favors tumor over infection or systemic inflammation
- TSGCT: Tumor-like, hypoechoic, hypervascular synovium
  - 95% occur in synovial-lined joints, tendon sheaths, & bursae; multicentric occurrence is rare
  - 5% of extraarticular TSGCT may not have demonstrable connection to joint, tendon sheath, or bursa
  - Knee (60%) > hip > ankle > small joints of hand & foot > shoulder & elbow
- TSGCT (diffuse intraarticular)
  - Lobular thickening of hypoechoic synovium; variable synovial hyperemia; hemosiderin not visible on US; ± intraarticular bony scalloping ± small effusion
- TSGCT (localized intraarticular)
  - Well-defined, hypoechoic, intraarticular nodule
  - ± mild hyperemia ± effusion
- TSGCT (tendon sheath): Eccentric, nodular mass extending along tendon sheath ± hyperemia
  - Hand & wrist (80%) > foot & ankle (20%)
- Synovial osteochondromatosis: Thickened synovium with discrete echogenic foci ± hyperemia
  - No acoustic shadowing if pure cartilage nodules
  - Knee > elbow > hip & shoulder; polyarticular (5%)
- Confirm most synovial tumors with US-guided core biopsy as US appearances are usually not specific enough to make definitive diagnosis

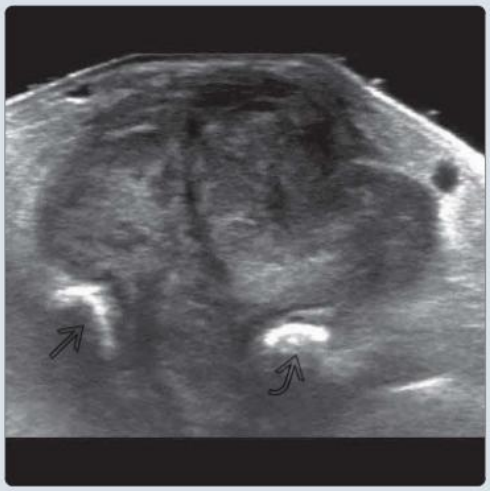

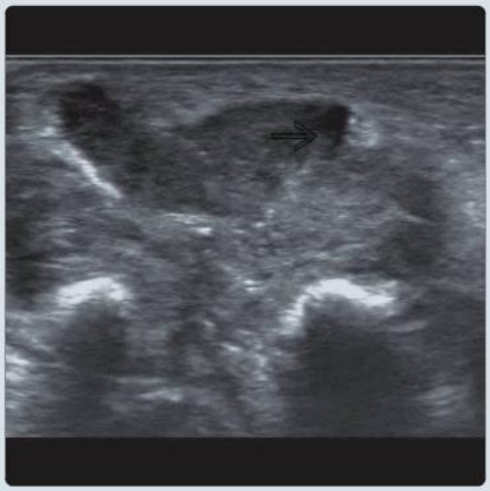

(Left) *Transverse US in a 40-year-old woman presenting with a painless forefoot lump for 6 months shows a lobulated, hypoechoic mass between the shafts of the 2nd ➡ & 3rd ➡ metatarsal bones, bulging dorsally.* **(Right)** *More proximal transverse US in the same patient shows the extensor digitorum longus tendons ➡ to the 2nd & 3rd toes course just superficial to and are partially encased by the mass.*

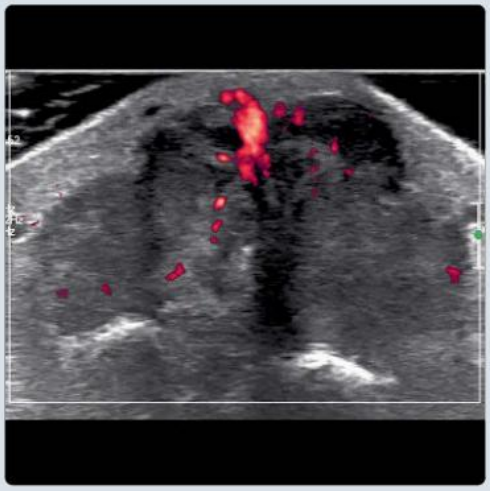

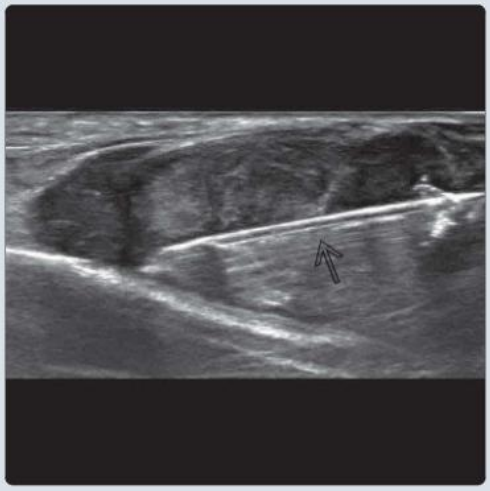

(Left) *Transverse power Doppler US in the same patient shows mild to moderate tumoral hyperemia. Overall appearances favor tenosynovial giant cell tumor (TSGCT).* **(Right)** *Longitudinal US during percutaneous Tru-Cut needle ➡ biopsy is shown. Biopsy revealed cores of fibrous tissue composed of sheets of mononuclear cells with scattered osteoclast-like giant cells and hemosiderin-laden macrophages, consistent with TSGCT.*

TERMINOLOGY

Fibrohistiocytic Synovial Tumors

- **Tenosynovial giant cell tumor** (TSGCT) commonest with 3 manifestations
  - Pigmented villonodular synovitis (PVNS); intraarticular & diffuse
  - Focal nodular synovitis (FNS); intraarticular & localized
  - Giant cell tumor of tendon sheath (GCTTS); arising from tendon sheath

Synovial Osteochondromatosis

- Synovial metaplasia characterized by cartilaginous loose bodies that later ossify
- ~ 2% can undergo malignant transformation to chondrosarcoma

Less Common Synovial Tumors

- **Lipoma arborescens**: Reactive fatty hypertrophy of subsynovial synovial tissue
  - Usually response to chronic synovial irritation from osteoarthritis or inflammatory arthritis
- **Synovial lipoma**: Lipoma in intrasynovial location
- **Synovial hemangioma**: Vascular anomaly involving synovium
  - Misnomer since not true hemangioma; most are slow-flow vascular malformations
- **Synovial sarcoma**: Malignant mesenchymal tumor that usually arises in periarticular tissues of extremities
  - Misnomer since not derived from true synovial cells with only ~ 5% being true intraarticular tumors
- **Synovial chondrosarcoma**: Usually arise de novo
  - Large size, periarticular soft tissue extension, & cortical destruction in older adult patient may suggest malignant transformation
- **Synovial malignant infiltration, e.g., lymphoma**
- Rare synovial tumors: Malignant giant cell tumor, epithelioid sarcoma, metastases

IMAGING

General Features

- Best diagnostic clue
  - **TSGCT**: Tumor-like, hypoechoic, hypervascular synovium or eccentric, nodular mass along tendon sheath ± hyperemia
    - 95% occur in synovial-lined joints, tendon sheaths, & bursae; multicentric occurrence is rare
      - 5% of extraarticular TSGCT show no demonstrable connection to joint, tendon sheath, or bursa
      - Either original connection may have been disrupted or tumor arose de novo in nonsynovial tissue
  - **Synovial (osteo)chondromatosis**: Thickened synovium, often of nodular or lobulated configuration, with small to medium-sized, discrete echogenic foci ± hyperemia
  - **Lipoma arborescens**: Frond-like, nonvascular, fatty proliferation of synovial subintima
  - **Synovial lipoma**: Solitary nonvascular, intraarticular, fatty mass devoid of frond-like projections
  - **Synovial hemangioma**: Most are slow-flow venocapillary or venous vascular malformations
    - ~ 50% are continuous with extraarticular vascular malformation
  - **Synovial sarcoma**: Variable appearances, usually heterogeneous mass with soft tissue, cystic/necrotic, & hemorrhagic areas, periarticular extension & mild to moderate internal vascularity
- Location
  - TSGCT (diffuse & localized) from joint: Knee (60%) > hip > ankle > small joints of hand & foot > shoulder & elbow
  - TSGCT from tendon sheath: Hand & wrist > foot & ankle
    - TSGCT from tendon sheath should occur only where there is synovial-lined tendon sheath
  - Synovial osteochondromatosis: Knee > elbow > hip & shoulder; polyarticular (5%)
  - Lipoma arborescens: Suprapatellar pouch of knee joint
  - Synovial sarcoma: Periarticular in arms & legs, especially near wrists & ankles
- Size
  - Most synovial tumors: Thickened synovial mass ranging from few cm to 20 cm
  - Synovial osteochondromatosis: Nodules ranging from few mm to ~ 20 mm

Radiographic Findings

- Radiography
  - TSGCT
    - Dense soft tissue swelling
      - ± intraarticular erosions with sclerotic margins, especially in hip (tight capsule)
    - Preservation of joint space until late stage
    - No juxtaarticular osteopenia
  - Synovial (osteo)chondromatosis
    - Multiple small, ossified bodies within joint
    - Cartilage nodules not ossified in 20%
      - ± intraarticular erosions, especially in hip
    - Preservation of joint space until late stage
    - No juxtaarticular osteopenia
    - Radiographs can be diagnostic

MR Findings

- T1WI
  - TSGCT
    - Isointense to hypointense mass(es)
  - Lipoma arborescens, synovial lipoma: T1-hyperintense, fatty, intraarticular mass
- T2WI
  - TSGCT
    - Hypointense to isointense synovial mass secondary to paramagnetic effect of hemosiderin
    - ± intermediate-signal erosions with hypointense margins
  - Lipoma arborescens: Pathognomonic frond-like, nonenhancing projections of fat signal protruding into synovium
  - Synovial sarcoma: Classic triple sign with high, intermediate, & low signal intensity areas corresponding to areas of myxoid/necrotic tissue, solid viable tissue, & calcified/hemorrhagic tissue, respectively
- T2* GRE

- Foci of hypointensity due to hemosiderin deposits may be present in TSGCT, synovial sarcoma, & synovial hemangioma
  - Hemosiderin is present in 85% of TSGCT cases, i.e., lack of hemosiderin does not exclude diagnosis
  - Localized TSGCT contains less hemosiderin than diffuse TSGCT

Ultrasonographic Findings

- **TSGCT** (diffuse intraarticular), a.k.a. **PVNS**
  - Lobular thickening of hypoechoic synovium
    - ± focal extracapsular extension with large tumors
    - Can look similar to TB arthritis though TSGCT is more lobulated with no periarticular erosions
    - Usually more hypoechoic than synovial proliferation of inflammatory arthropathy
  - Variable synovial hyperemia
  - Hemosiderin not visible on US
  - ± intracapsular bony erosion ± effusion
- TSGCT (localized intraarticular), a.k.a. **focal nodular synovitis**
  - Well-defined, hypoechoic, intraarticular nodule
- TSGCT (tendon sheath), a.k.a. **GCTTS**
  - Eccentric, hypoechoic mass along tendon sheath
  - ± mild hyperemia
  - Otherwise normal tendon & tendon sheath
- **Synovial (osteo)chondromatosis**
  - Mild to moderate synovial thickening with small effusion
  - Multiple small, echogenic nodules
  - Nonossified, cartilaginous nodules may be difficult to see on US
    - Hypoechoic similar to joint fluid
  - ± mild hyperemia
- **Lipoma arborescens**: Hyperechoic, nonvascular villi that move in real time with joint movement
- **Synovial lipoma**: Well-marginated, lipomatous, intrasynovial mass devoid of villous projections
- **Synovial hemangioma**: Heterogeneously hypoechoic lesion, moderate to large amount of intrinsic vascularity
  - May have phleboliths & venous lakes ± hemarthrosis
  - ~ 50% have accompanying extraarticular vascular malformation
- **Synovial sarcoma**: Variable appearances, usually heterogeneous mass with periarticular extension & mild to moderate intrinsic hyperemia
  - May have anechoic areas of cystic/necrotic change & more echogenic areas from prior hemorrhage
- For all synovial tumors, with exception of synovial osteochondromatosis, lipoma arborescens, & synovial lipoma
  - Have low threshold for US-guided core biopsy for histologic confirmation
  - US appearances are usually not specific enough to make definitive diagnosis

Imaging Recommendations

- Best imaging tool
  - US for initial assessment
    - Most synovial tumors readily seen on US
    - If synovium is clearly seen in full & normal, then no synovial tumor is present
    - Allows US-guided synovial biopsy for definitive histologic confirmation
  - MR for defining extent
    - US can suggest diagnosis of most synovial tumors, though MR is more specific & better defines extent
  - Radiography for synovial osteochondromatosis
- Protocol advice
  - Look carefully for any articular or tendon sheath involvement of extraarticular masses
  - Look for bone erosion or scalloping
  - Always assess with color Doppler imaging
    - Use minimal transducer pressure

DIFFERENTIAL DIAGNOSIS

Hemophilic Arthropathy

- Familial (X-linked)
- ± polyarticular ± hemarthrosis

Synovitis

- Systemic inflammatory disorder
- ± polyarticular + rheumatoid arthritis factor positive

Complicated Ganglion Cyst/Bursitis

- Hyperemia, if present, should only be at periphery of cystic lesion
- Minimal nodular synovial tissue

DIAGNOSTIC CHECKLIST

Consider

- Diffuse & localized intraarticular TSGCT probably represent separate entities

Image Interpretation Pearls

- TSGCT (diffuse intraarticular): Diffuse hypoechoic synovial mass with variable hyperemia
  - T2* GRE identifies hemosiderin (hypointense)
    - Not imperative to see hemosiderin on gradient-echo MR imaging to make diagnosis of diffuse TSGCT
- TSGCT (localized intraarticular): Localized, hypoechoic synovial mass with variable hyperemia
- TSGCT (tendon sheath): Eccentric (rather than concentric) tendon sheath mass
- Synovial osteochondromatosis: Calcified bodies not invariably visible in early stages
- Lipoma arborescens: Presence of fatty, frond-like projections differentiates it from synovial lipoma
- Synovial sarcoma: Variable appearances & can mimic complicated ganglion cyst
  - Heterogeneous periarticular mass with mild to moderate internal vascularity
- Synovial hemangioma: Vascular malformation involving synovium
- US-guided biopsy is necessary to confirm diagnosis of most synovial tumors

SELECTED REFERENCES

1. Cheah AL et al: Pathology of intra-articular tumours and tumour-like lesions: pearls, pitfalls and rarities from a general surgical pathology practice. Skeletal Radiol. 53(9):1909-24, 2024
2. Yip SWY et al: Image-guided synovial biopsy with a focus on neoplastic lesions. Skeletal Radiol. 52(5):817-29, 2023

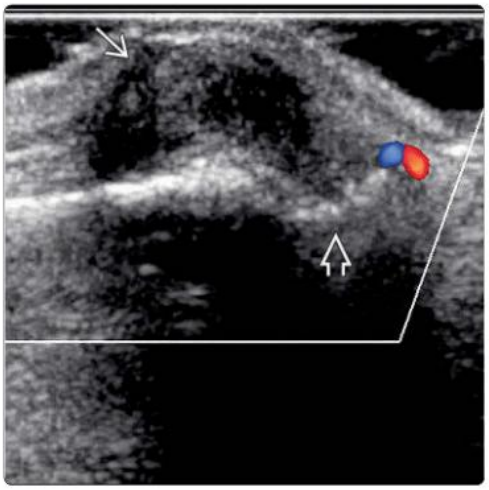

(Left) *Clinical photograph shows a dorsal thumb mass that had been present for 12 months.* **(Right)** *Longitudinal color Doppler US in the same patient shows a medium-sized, hypoechoic, solid mass in contact with the dorsal capsule of the interphalangeal joint (not shown). No demonstrable tumor hyperemia is present. Overall appearances favor TSGCT, which was confirmed by histology. The apparent bone scalloping is spurious due to probe obliquity.*

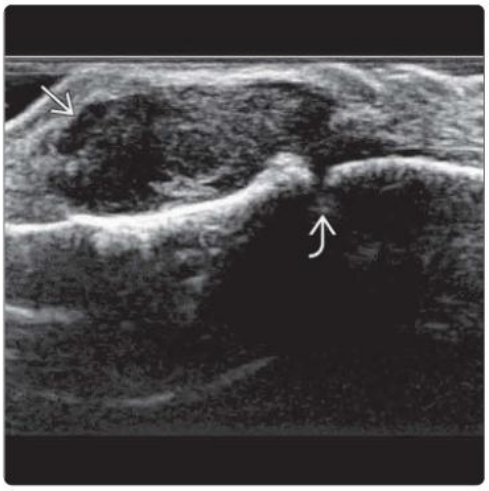

(Left) *Clinical photograph shows a painful middle finger mass that had been slowly growing for 2 years.* **(Right)** *Longitudinal US in the same patient shows a medium-sized mass on the dorsoradial aspect of the middle finger at the level of and distal to the proximal interphalangeal joint . The appearances are consistent with TSGCT arising from the proximal interphalangeal joint.*

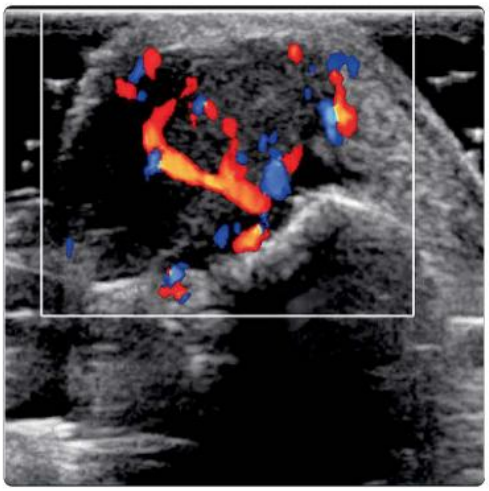

(Left) *Transverse US in the same patient shows the typical hypoechoic appearance of TSGCT with mild scalloping of the underlying middle phalanx .* **(Right)** *Transverse color Doppler US in the same patient shows moderate tumoral hyperemia. This level of hyperemia is quite typical for TSGCT, though some TSGCT tumors may be relatively hypovascular.*

(Left) *Longitudinal US shows a large, lobulated mass on the dorsoulnar aspect of the thumb base. This mass seems to arise from the metacarpophalangeal joint and encases the extensor pollicis longus tendon.* **(Right)** *Transverse US of the same patient shows the hypoechoic tumor mass with moderate scalloping of the underlying dorsal aspect of the proximal phalanx.*

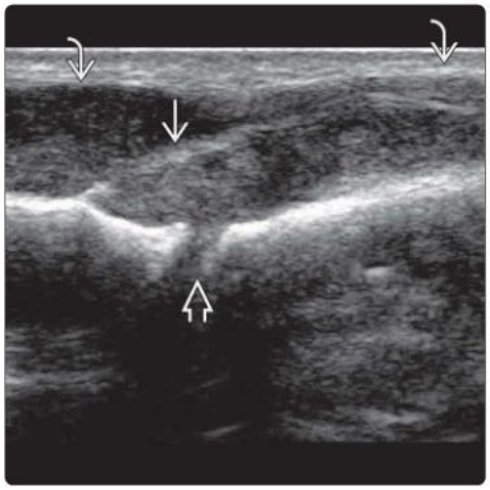

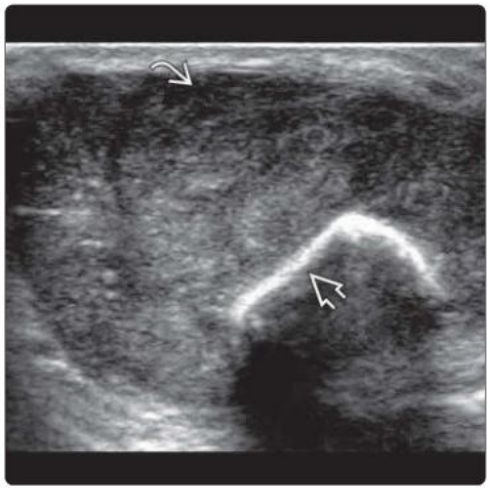

(Left) *Transverse color Doppler US at the same location in the same case shows moderate tumoral hyperemia. The appearances are consistent with TSGCT, which was confirmed by US-guided biopsy for histology. Although this tumor probably arose from the metacarpophalangeal joint, the main tumor bulk is extraarticular.* **(Right)** *3D CT angiography of the same patient shows prominent arterial supply to the tumor mass.*

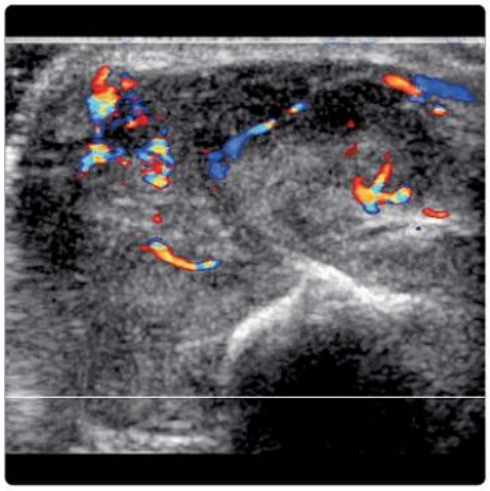

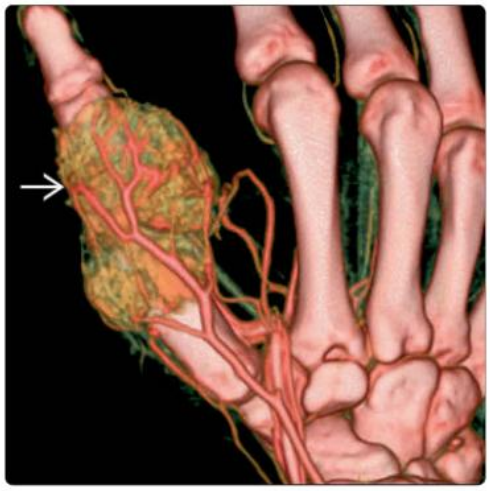

(Left) *Clinical photograph of a 32-year-old woman with a nonpainful dorsal lateral foot mass for 6 months is shown. One can appreciate the slight bluish discoloration of the overlying skin. Both MR and PET/CT performed prior to referral suggested a sarcoma. The standardized uptake value was 15.3.* **(Right)** *Longitudinal US shows a hypoechoic mass arising from the junction between the calcaneum, the cuboid, and the lateral cuneiform. The mass lies deep to the extensor digitorum tendons.*

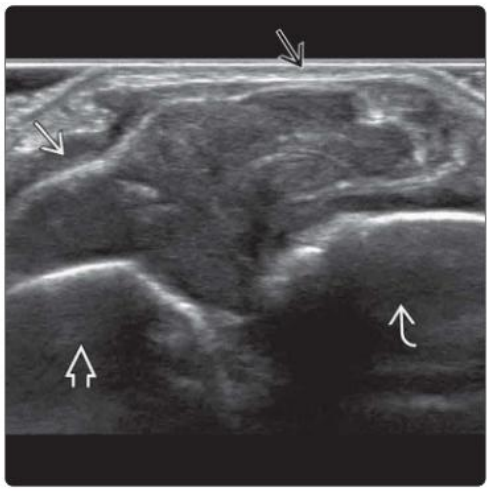

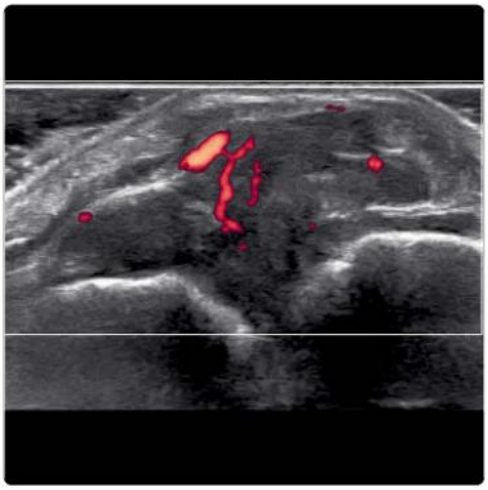

(Left) *Longitudinal power Doppler US shows mild to moderate tumoral hyperemia. The US diagnosis was TSGCT arising from the calcaneo-cuboid-lateral cuneiform articulation.* **(Right)** *Longitudinal US shows percutaneous Tru-Cut needle biopsy ➡, which revealed cores of fibrous tissue mainly composed of sheets of mononuclear cells with scattered osteoclast-like giant cells and hemosiderin-laden macrophages. This was consistent with TSGCT.*

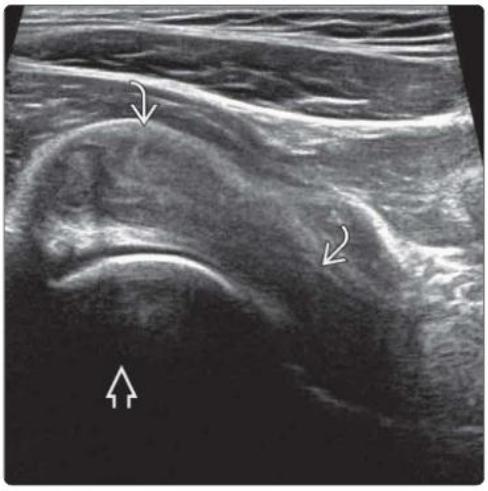

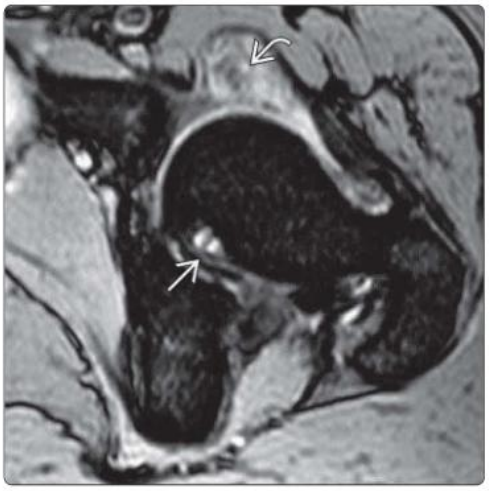

(Left) *Longitudinal US in a patient with hip pain for 15 months shows localized, hypoechoic synovial proliferation ➡ on the anterior aspect of the hip. The femoral head is normal ➡.* **(Right)** *Axial T2* FS GRE MR in the same patient shows minimal hemosiderin deposition within the thickened synovium ➡. This is compatible with localized TSGCT, which was confirmed by US-guided biopsy for histology. There is a small incidental fibrogelatinous cyst posteriorly ➡.*

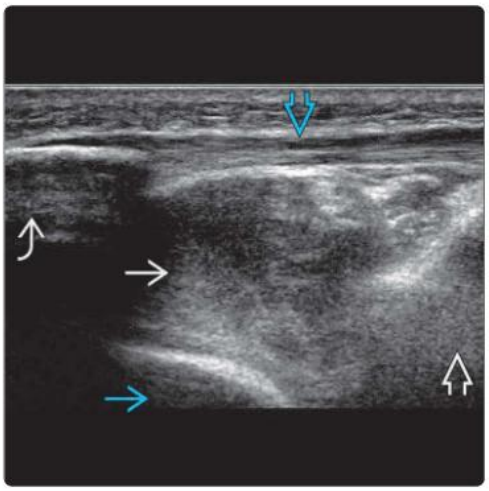

(Left) *Transverse US of the medial patellofemoral recess shows similar severe, hypoechoic synovial proliferation ➡. The femur ➡ is normal.* **(Right)** *Longitudinal US in the same patient shows severe synovial proliferation ➡ bulging into the infrapatellar fat pad. The patella ➡, patellar tendon ➡, distal femur ➡, and proximal tibia ➡ are normal. The appearances are consistent with diffuse intraarticular TSGCT, which was confirmed on percutaneous biopsy.*

(Left) *Lateral radiograph of the knee in a 69-year-old man with suprapatellar swelling shows moderate suprapatellar pouch distention ➡ with severe patellofemoral osteoarthritis ➡.* **(Right)** *Longitudinal US of the suprapatellar recess in the same patient shows severe synovial proliferation ➡ with no effusion. No synovial proliferation was present elsewhere in the knee joint. Biopsy of this synovium revealed TSGCT. Localized synovial swelling favors tumor rather than infection or inflammation.*

(Left) *Longitudinal US in a 37-year-old man with ankle pain for 4 months shows severe, localized synovial thickening ➡ at the anterior ankle recess distending the anterior capsule ➡. No bone erosion is present. The talar dome articular cartilage ➡ is normal.* **(Right)** *Longitudinal color Doppler US shows only minimal tumoral hyperemia. Overall, intraarticular TSGCT was considered most likely, but chronic infection, synovial hemangioma, and lymphoma were also considered. Biopsy confirmed TSGCT.*

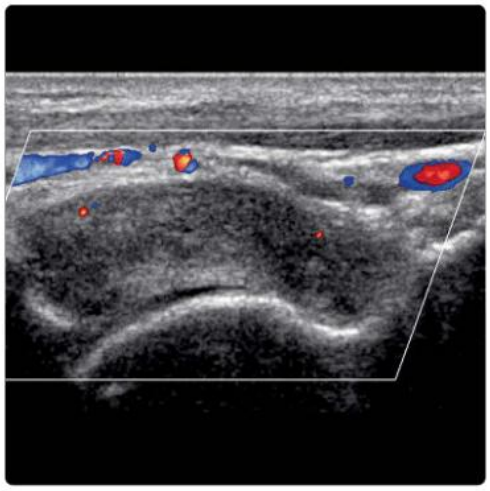

(Left) *Clinical photograph shows a patient with a little toe mass ⇨ enlarging for 4 years. The skin marker represents the planned line of surgical incision.* **(Right)** *Longitudinal US in the same patient shows a hypoechoic dorsal mass ➡ surrounding the extensor digitorum tendon ➡. This tendon does not have a tendon sheath. Histology following percutaneous biopsy revealed TSGCT. This extraarticular TSGCT most likely arose from the metatarsophalangeal joint ➡.*

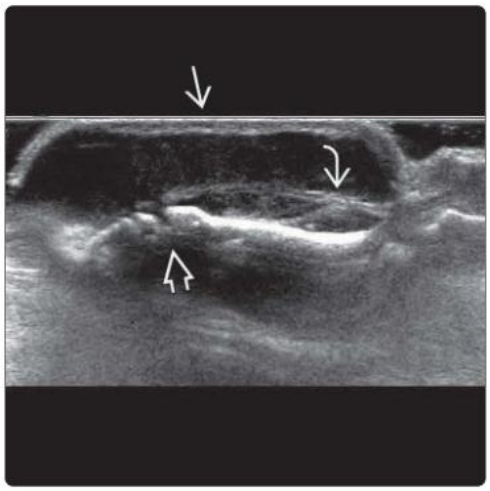

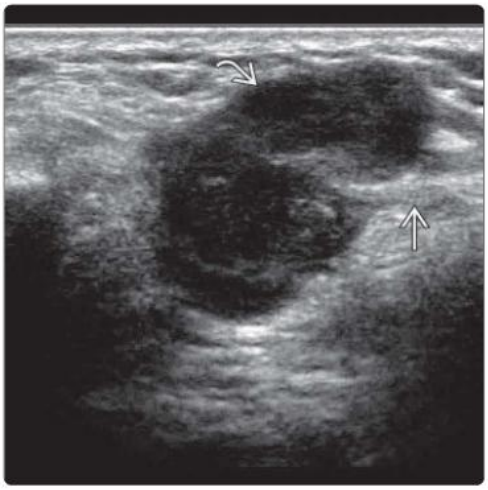

(Left) *Transverse US in a patient with a knee mass present for 6 months shows a medium-sized soft tissue mass ➡ that lies both superficial and deep to the medial patellar retinaculum ➡. Overall appearances favor a focal nodular synovitis.* **(Right)** *Transverse T1 MR in the same patient shows a mass with the characteristic hypointensity of focal nodular synovitis extending through and along the medial retinaculum ➡.*

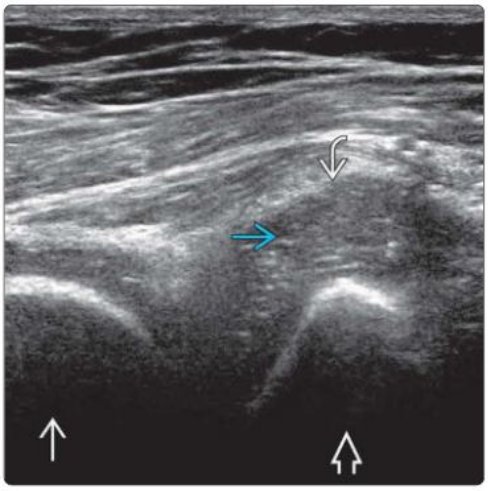

(Left) *Longitudinal US in a patient with knee pain and swelling for 1 year shows thickened, synovial-like tissue ➡ containing small, echogenic, calcific-like foci ➡ anteromedially, suspicious of synovial osteochondromatosis. US-guided biopsy for histology revealed synovial chondromatosis. The medial femoral ➡ and tibial ➡ condyles are normal.* **(Right)** *Frontal radiograph of the knee in the same patient shows no corresponding soft tissue calcification ➡.*

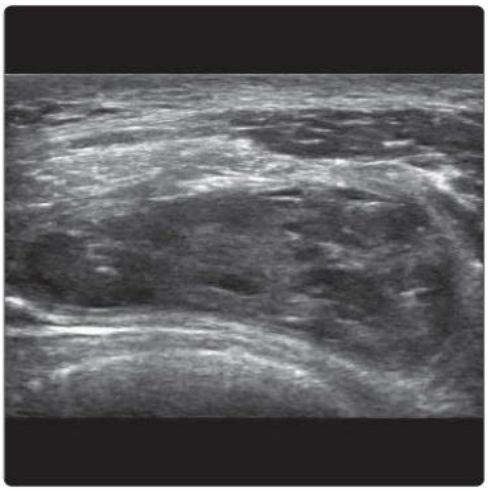

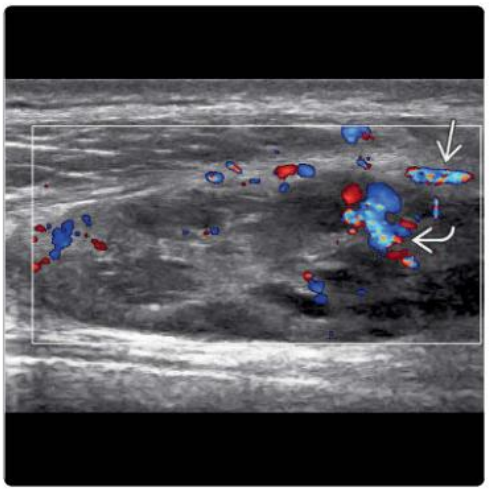

(Left) *Transverse US in a 23-year-old man shows a synovial mass in the suprapatellar pouch. It contains both echogenic foci and linear, hypoechoic areas.* **(Right)** *Color Doppler US shows moderate hyperemia ➡ of the synovial mass with a prominent capsular vein ➡. The hypoechoic areas are compatible with slow-flow vascular channels. This was most likely a synovial vascular malformation, which was confirmed on US-guided biopsy.*

(Left) *Longitudinal US in a patient with elbow pain and limitation of movement for 1 year shows moderate focal synovial proliferation ➡ with early scalloping of the radial neck ➡. There is a suspicion of mild synovial calcification ➡.* **(Right)** *Longitudinal color Doppler US of the same area shows mild synovial hyperemia.*

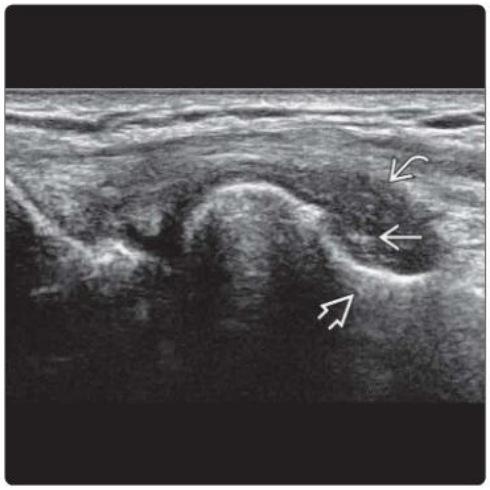

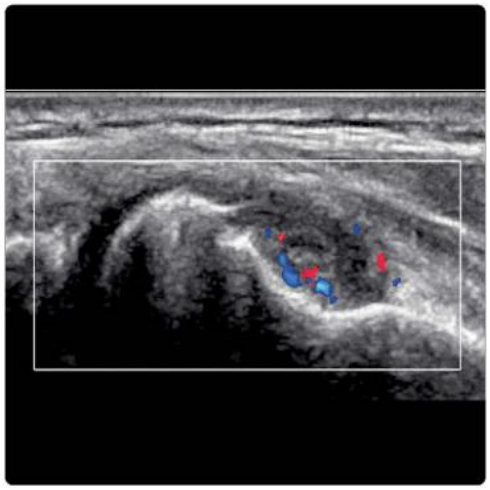

(Left) *Transverse US of the same lesion during US-guided synovial biopsy shows the coaxial needle ➡ at the margin of the tumor ➡ prior to introduction of the Tru-Cut needle. Histology revealed synovial chondromatosis. As the US appearances are not entirely specific, biopsy is indicated to confirm diagnosis in most synovial tumors.* **(Right)** *Coronal T2 FS MR of the same elbow shows the synovial chondromatosis tumor deep to the radial collateral ligament ➡ with moderate scalloping of the radial neck ➡.*

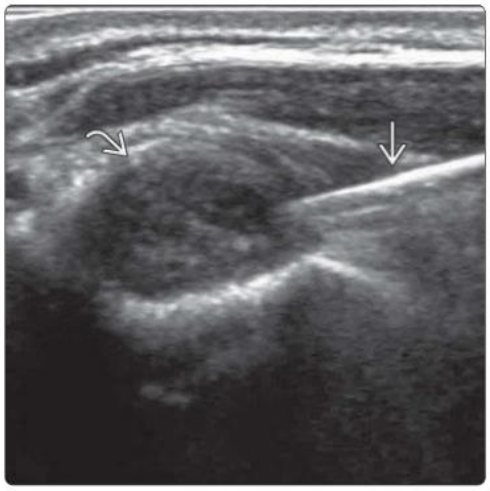

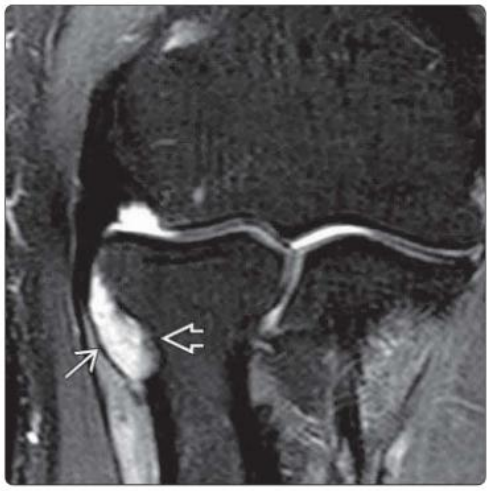

(Left) *Longitudinal US of a patient with chronic knee swelling shows a large effusion ➡ with severe, nodular hyperechoic synovial proliferation ➡ at the posterior aspect of the suprapatellar pouch.* **(Right)** *Axial T1 MR of the same lesion shows frond-like, lipomatous synovial proliferation ➡ involving most of the suprapatellar pouch. Features are indicative of lipoma arborescens. No biopsy is needed as the imaging appearances are characteristic.*

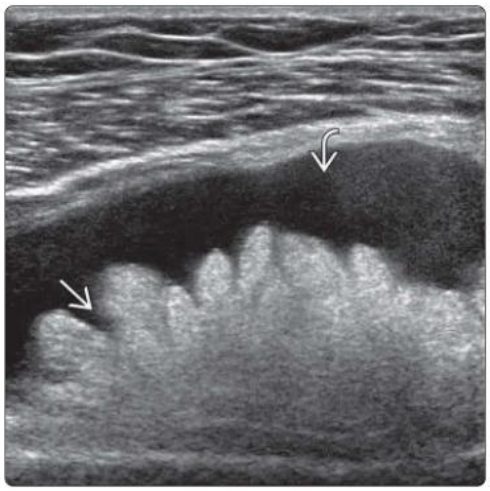

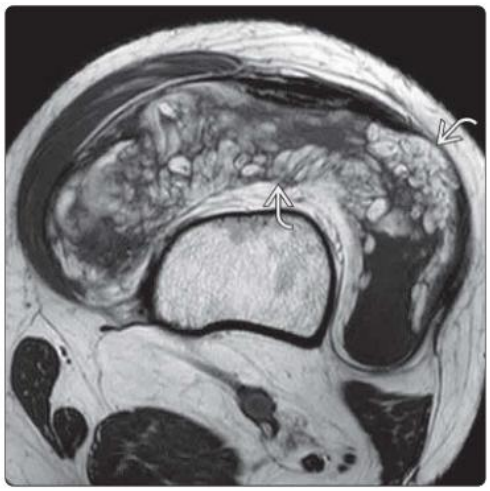

(Left) *Longitudinal US in a 63-year-old man with knee swelling for 4 months is shown. There is a large, intrarticular, synovial-type lipoma ➡ present within the suprapatellar pouch deep to the vastus medialis muscle ➡. The US appearances are similar to those of extraarticular lipoma.* **(Right)** *Sagittal T1 MR shows the synovial lipoma within the suprapatellar recess. Other than the large size and deep location, there are no suspicious features present. In this setting, percutaneous biopsy is not helpful.*

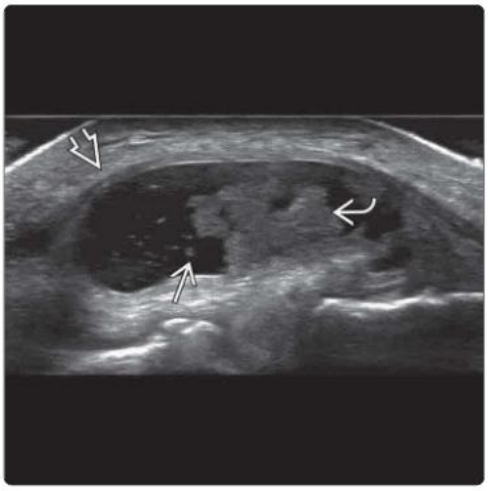

(Left) *Longitudinal US in a 72-year-old man with mechanical knee pain shows a medium-sized medical knee mass ➡ deep to the medial collateral ligament containing fluid, small echogenic foci ➡, and proliferative synovium ➡.* **(Right)** *Corresponding transverse color Doppler US shows no intrinsic hyperemia.*

(Left) *Sagittal radiograph of the knee in the same patient shows mild osteoarthritis with soft tissue swelling in both the suprapatellar ➡ and infrapatellar ➡ recesses. No calcification is present.* **(Right)** *Sagittal T2 FS MR shows a medium-sized, hyperintense intraarticular synovial mass in the suprapatellar ➡ and infrapatellar ➡ fossae. This knee swelling also bulged medially, as seen on US examination. Biopsy confirmed synovial chondromatosis.*

(Left) *Longitudinal US in a 63-year-old woman with a self-palpable knee mass for 2 years shows a lobulated, largely hypoechoic mass on the posteromedial aspect of the knee. Initially, chronic pes anserinus bursitis was considered to be the most likely diagnosis.* **(Right)** *Color Doppler US of the same mass shows mild tumoral hyperemia.*

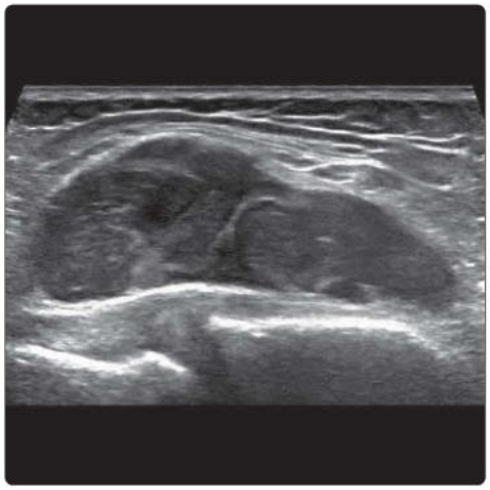

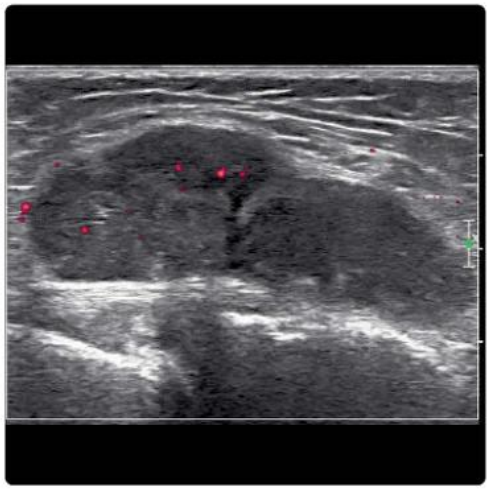

(Left) *Coronal T2 FS MR of the same paraarticular mass shows the classic triple signal sign of soft tissue ➡ and cystic ➡ components with a hemosiderin rim ➡. Mild peritumoral edema is present. The MR appearances were not compatible with bursitis.* **(Right)** *Transverse US during percutaneous Tru-Cut biopsy ➡ of the paraarticular mass is shown. Biopsy yielded tissue cores composed of spindle cells with a biphasic appearance, consistent with synovial sarcoma.*

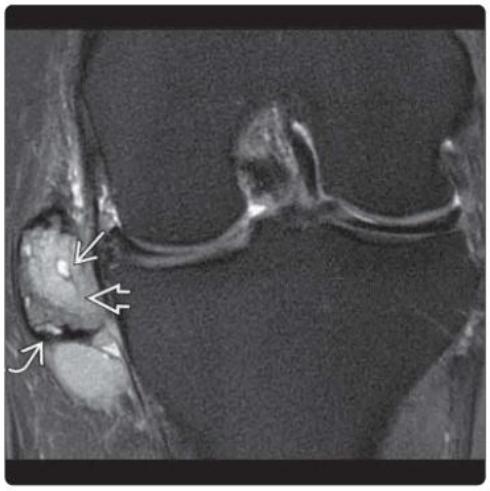

(Left) *Clinical photograph of a 27-year-old woman with progressive knee swelling and pain for a month after a minor sprain shows knee swelling with skin petechiae ⇨.* **(Right)** *Longitudinal US of the medial aspect of the knee in the same patient shows severe, synovial-like thickening ➡ elevating the medial collateral ligament ➡ with moderate cortical resorption of the medial femoral condyle ➡.*

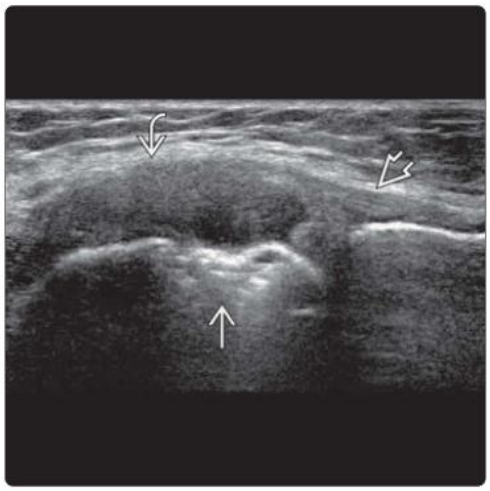

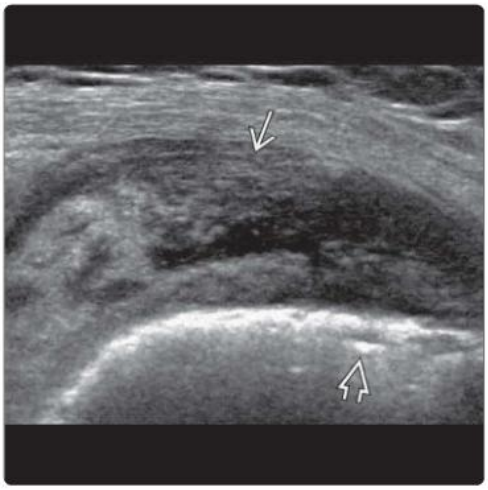

(Left) *Oblique transverse US of medial patellofemoral recess in the same patient shows severe, focal mass-like synovial thickening ➡ with moderate subjacent femoral cortical irregularity/erosions ➡.* **(Right)** *Coronal T2 FS MR shows severe synovial thickening ➡ at the anteromedial aspect of the knee with cortical reabsorption and surface intraosseous infiltration ➡. US-guided synovial biopsy of the synovial thickening revealed non-Hodgkin synovial lymphoma.*

(Left) *Lateral radiograph of the knee in a patient with knee swelling for 20 years shows severe erosion ➡ of the posterior aspect of the lateral femoral condyle and supracondylar area.* **(Right)** *Longitudinal US of the same knee shows a large, lobulated mass ➡ present on the posterior aspect of the knee joint with dorsal bone scalloping ➡. Although some calcific-type foci are present ➡, this was still considered most likely to be pigmented villonodular synovitis (PVNS).*

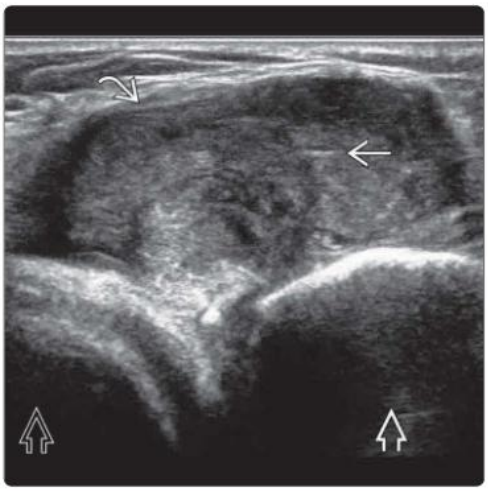

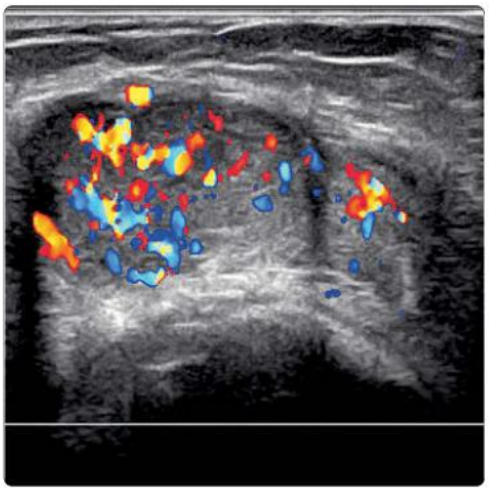

(Left) *Longitudinal US in the same patient shows a separate large, lobulated mass ➡ on the medial aspect of the knee. The medial femoral ➡ and tibial condyles ➡ are normal. There are possibly some calcific foci ➡ within the mass.* **(Right)** *Transverse color Doppler US in the same patient shows moderate tumoral hyperemia. The US diagnosis was PVNS; however, histology following US-guided biopsy revealed synovial chondrosarcoma.*

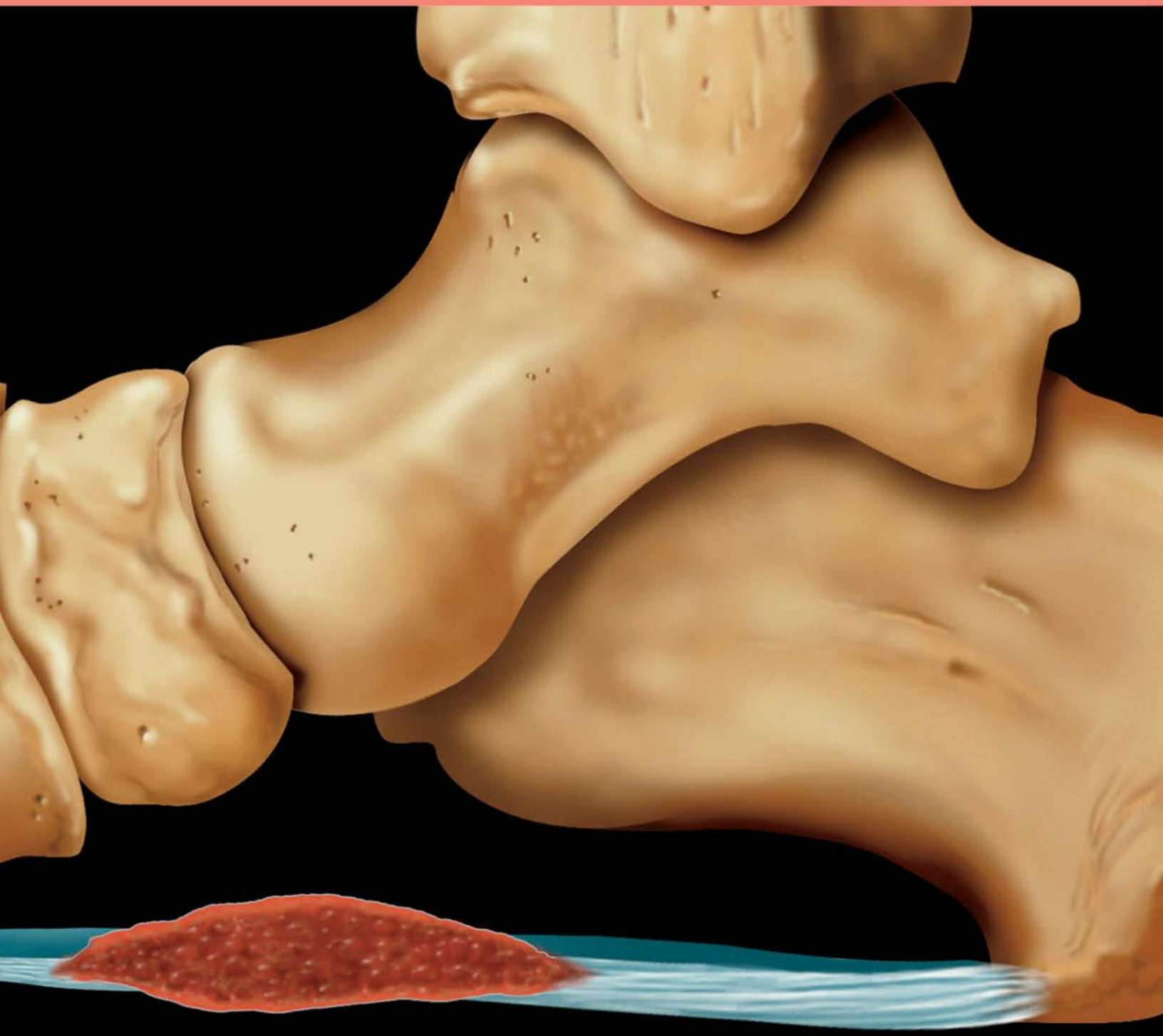

PART III
SECTION 7

Soft Tissue and Bone Tumors

Plantar Fasciitis and Fibromatosis	718
Lipoma	724
Epidermoid Cyst	734
Pilomatricoma	740
Dermatofibrosarcoma Protuberans	744
Vascular Leiomyoma	748
Superficial Metastases, Melanoma, and Lymphoma	752
Vascular Anomaly	758
Foreign Body and Injection Granuloma	766
Lymph Node Abnormality	774
Soft Tissue Sarcoma	780
Bone Tumor	788
Local Tumor Recurrence	800

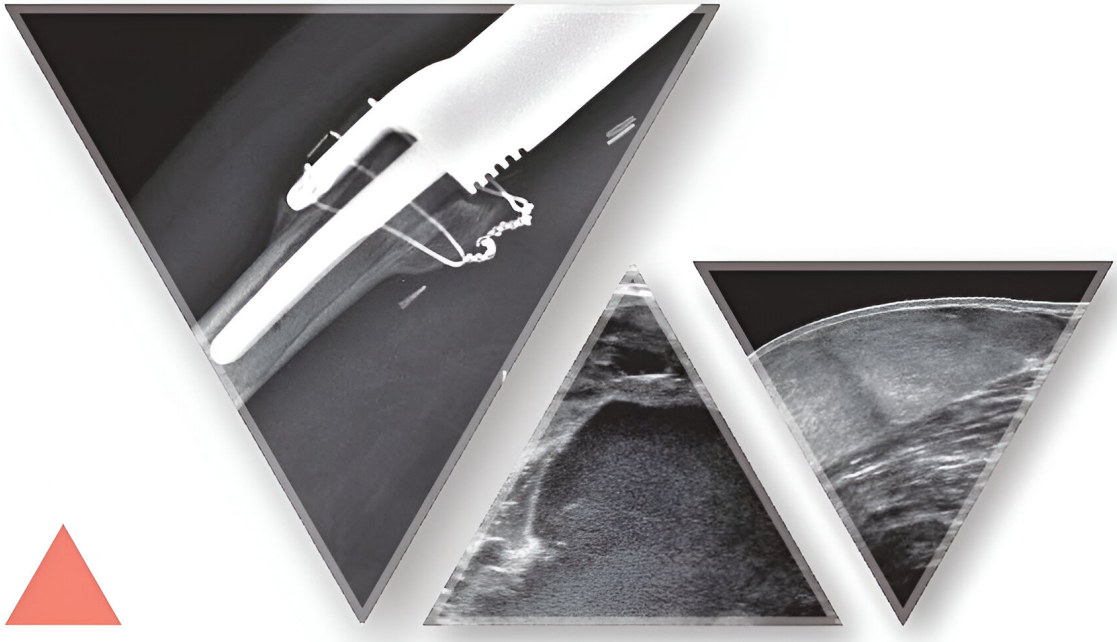

KEY FACTS

TERMINOLOGY

- Plantar fascia = multilayered fibrous aponeurosis, 1-2 mm thick, with medial, central, & lateral bands

IMAGING

- **Plantar fasciitis**
  - Thickened plantar fascial insertion, especially at medial aspect of calcaneum
  - Plantar fascia thickness > 4 mm (most useful sign)
  - ± perifascial edema & edema, atrophy of heel fat pad
  - ± hypoechogenicity or decreased plantar fascial definition
  - Consider enthesitis, if cortical erosions & hyperostosis
    - At calcaneal insertion or base of 5th metatarsal bone
  - Calcaneal spur is located deep to (& not within) fascia
    - Spur may simulate anterior edge of calcaneus
  - Bilateral in 1/3
  - Subclinical disease on contralateral side is not uncommon so do not use as internal normal reference
- **Plantar fibromatosis**
  - Discrete fusiform-shaped nodule of plantar fascia separated from calcaneal insertion
  - Hypoechoic (75%) or isoechoic (25%) to plantar fascia
  - Posterior acoustic enhancement (40%) or shadowing (20%)
  - Intrinsic vascularity (10%)
  - Majority are located within central or medial bands of plantar fascia
  - Bilateral in 1/3 & multiple on symptomatic side in 1/4

DIAGNOSTIC CHECKLIST

- Likelihood of plantar fasciitis increases as plantar fascial thickness at calcaneal insertion increases
  - Heel fat pad atrophy is common accompaniment
- Plantar fibromatosis = distinct plantar fascial nodule separate from calcaneal insertion
  - Main differential diagnosis is uncommon plantar fascial tear

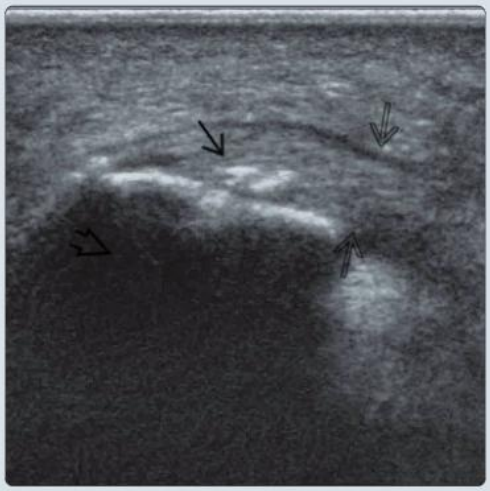

(Left) *Longitudinal US shows a normal central band of the plantar fascia attached to the medial calcaneal tuberosity ⇨. The thickness (3.7 mm) of the plantar fascia is measured at the leading edge of the calcaneum ⇨. Normal plantar fascial thickness is < 4 mm.* **(Right)** *Longitudinal US shows a mildly thickened (5.2-mm) plantar fascia ⇨ at the medial part of the calcaneum. There is moderate localized dystrophic calcification ⇨ within the plantar fascia superficial to the calcaneum ⇨.*

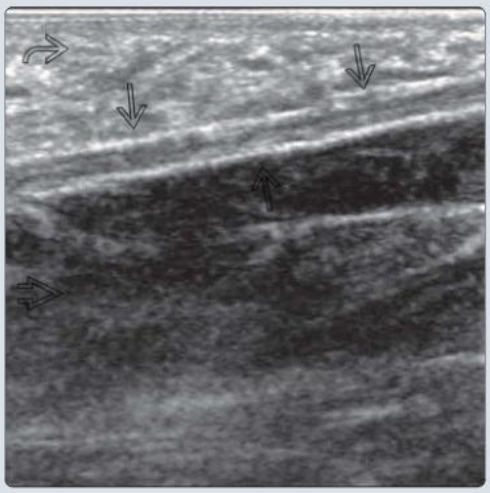

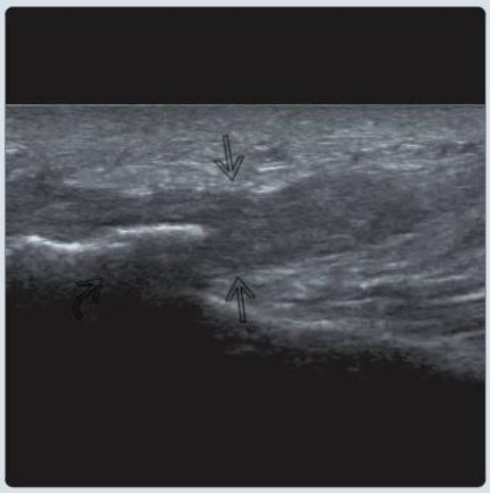

(Left) *Longitudinal US shows a normal plantar fascia ⇨ at the midfoot level. The flexor digitorum brevis muscle ⇨ is attached to the deep surface of the plantar fascia. The subcutaneous fat of the sole ⇨ is superficial.* **(Right)** *Longitudinal US shows a severely thickened (7.2-mm) plantar fascia ⇨ at the medial part of the calcaneum. There is a prominent plantar calcaneal spur ⇨ at the plantar fascia insertion.*

TERMINOLOGY

Synonyms

- Plantar fasciitis: Jogger's heel, tennis heel, policeman's heel, heel spur syndrome, calcaneal spur syndrome, plantar fasciopathy
- Plantar fibromatosis: Ledderhose disease, plantar fibroma

Definitions

- Plantar fascia = multilayered fibrous aponeurosis, 1-2 mm thick, with medial, central, & lateral bands
  - Supports long & short plantar ligaments in maintaining longitudinal arches of foot
    - Innervated by medial calcaneal nerve & 1st branch lateral plantar nerve
      - Entrapment of 1st branch lateral plantar nerve (Baxter neuropathy) can simulate plantar fasciitis
  - Central band is largest
    - Originates from medial tuberosity of calcaneum
    - Divides in midfoot into 5 bands that insert onto plantar plates of each metatarsophalangeal joint
  - Medial band is least significant
    - Arises from midportion of central band
  - Lateral band inserts into base of 5th metatarsal bone
- Plantar fasciitis: Degeneration ± fibroblastic proliferation of plantar fascia insertion at medial tuberosity of calcaneus
  - As there is no clear inflammatory component, plantar fasciopathy may be more favorable term
- Plantar fibromatosis: Nodular fibroblastic proliferation of plantar fascia separate from calcaneus

IMAGING

General Features

- Best diagnostic clue
  - Plantar fasciitis: Thickened plantar fascial insertion
  - Plantar fibromatosis: Nodular thickening of plantar fascia
- Location
  - Plantar fasciitis: Medial tuberosity calcaneus
    - Bilateral in 1/3
  - Plantar fibromatosis: Tends to involve distal 2/3 of plantar fascia
    - Bilateral in 1/3, multiple on symptomatic side in 1/4
- Size
  - Plantar fasciitis: Fascial thickness > 4 mm
  - Plantar fibromatosis
    - Average length: 13 mm (range: 4-17 mm)
    - Average width: 10 mm (range: 4-22 mm)
    - Average depth: 4 mm (range: 2-10 mm)
- Morphology
  - Plantar fasciitis: Fascial thickening at calcaneal insertion
  - Plantar fibromatosis: Discrete plantar fascia nodule

Radiographic Findings

- Radiography
  - Plantar fasciitis: Plantar calcaneal spur present in 50% of patients with plantar fasciitis
    - Also found in asymptomatic subjects
    - Consider enthesopathy when fluffy periostitis, erosions, & sclerosis present

MR Findings

- T1WI
  - Plantar fasciitis: Hypo- or isointense plantar fascial thickening at calcaneal insertion
  - Plantar fibromatosis: Isointense plantar fascial nodule
- T2WI
  - Plantar fibromatosis: Hypo- to isointense nodule along plantar fascia
- STIR
  - Plantar fasciitis
    - Thickness > 4 mm (almost 100%)
    - Subcutaneous or perifascial edema (90%)
    - Insertional bone marrow edema (40%)
    - Pronounced insertional marrow edema, erosions, & hyperostosis are features of enthesitis (peripheral spondyloarthritis)

Ultrasonographic Findings

- **Plantar fasciitis**
  - Plantar fascia thickness > 4 mm (most useful sign)
  - ± hypoechogenicity of plantar fascia & loss of normal fibrillar reflective echotexture
  - ± minor dystrophic calcification of fascia
  - ± perifascial edema, atrophy & edema of overlying heel fat pad
  - ± perifascial & fascial hyperemia
  - ± reduced elasticity on elastography
  - Consider enthesitis, if erosions & hyperostosis
    - At calcaneal insertion or base of 5th metatarsal bone
  - Calcaneal spur
    - Spur is located deep to (& not within) fascia
    - May simulate anterior edge of calcaneus
- **Plantar fibromatosis**
  - Discrete fusiform-shaped nodule of plantar fascia separated from calcaneal insertion
  - Hypoechoic (75%) or isoechoic (25%) to plantar fascia
  - Acoustic enhancement (40%) or shadowing (20%)
  - Usually no vascularity (5%)
  - Majority are located within midsubstance or superficial aspect of plantar fascia
    - If large with infiltrative margins, consider aggressive plantar fibromatosis (relatively rare tumor)
  - Coexistent thickening of ipsilateral plantar fascial calcaneal insertion present in 1/3 of patients often without related symptoms

Imaging Recommendations

- Best imaging tool
  - US as accurate, quick, & accessible
- Protocol advice
  - Examine fascia in longitudinal & transverse planes
    - Routinely examine both sides as subclinical contralateral disease is common in both diseases
  - Measure thickness of fascia at medial leading edge of calcaneum
  - Routinely assess heel fat pad in plantar fasciitis for edema, internal architecture, & atrophy
    - Use minimal transducer pressure as this will compress heel fat pad & efface perifascial edema

DIFFERENTIAL DIAGNOSIS

Heel Fat Pad Atrophy

- Focal edema ± atrophy of heel fat pad
  - Often seen in conjunction with plantar fasciitis

Xanthoma

- Nodule with speckled pattern
- Fusiform enlargement of plantar fascia

Plantar Bursitis

- Fluid-filled bursa or flat, hypoechoic area superficial to plantar fascia
- Typically forefoot region under metatarsal heads

Plantar Fascial Tear

- Trauma history
- Fascial discontinuity ± swelling, edema, or hemorrhage

PATHOLOGY

General Features

- Etiology
  - Plantar fasciitis: Population lifelong risk of 10%
    - Possibly caused by repetitive microtrauma or microvascular injury
  - Plantar fibromatosis: Unknown etiology; not knowingly related to trauma
    - Possibly genetic ± related to collagen profile
- Associated abnormalities
  - May be related to other fibroproliferative diseases (Dupuytren contracture, Peyronie disease, etc.)
    - Onset of other fibromatoses may be delayed for 5-10 years after onset of plantar fibromatosis

Gross Pathologic & Surgical Features

- Plantar fasciitis: Firm thickening of plantar fascia at calcaneal insertion
- Plantar fibromatosis: Firm, whitish nodule

Microscopic Features

- Plantar fasciitis: Degeneration of plantar fascia ± fibroblastic proliferation ± mild chronic inflammation
- Plantar fibromatosis: 3 phases of fibroblastic proliferation within plantar fascia
  - Proliferative phase: Nodular fibroblastic proliferation
  - Active phase: Collagen synthesis & deposition
  - Mature phase: Collagen maturation

CLINICAL ISSUES

Presentation

- Most common signs/symptoms
  - Plantar fasciitis: Heel pain ↑ by weightbearing
    - Pain worse on 1st few steps in morning
  - Plantar fibromatosis: Sole pain ± palpable, firm lump
    - Pain ↑ by prolonged weightbearing
- Clinical profile
  - Plantar fasciitis: Tenderness on deep palpation just anterior to medial calcaneal tuberosity
  - Plantar fibromatosis: Nontender or mildly tender sole lump attached to plantar fascia

Demographics

- Age
  - Plantar fasciitis: 40-60 years
    - Younger in at-risk individuals (runners, military)
  - Plantar fibromatosis: 50 years (range: 30-80 years)
- Sex
  - Plantar fasciitis & fibromatosis: M:F = 1:1
- Epidemiology
  - Plantar fasciitis: Most common cause of heel pain
    - 10% of running injuries
    - Additional risk factors: Mechanical overload, prolonged standing, obesity, pes planus, & tight Achilles tendon
  - Plantar fibromatosis: Less common than plantar fasciitis
    - No specific risk factors identified

Natural History & Prognosis

- Plantar fasciitis
  - Symptoms resolve in 80% within 12 months
- Plantar fibromatosis
  - Similar tendency to improve with time
    - Nodules become smaller & less painful

Treatment

- Plantar fasciitis
  - Conservative: Start treatment soon after onset
    - Rest & analgesia
    - ± orthotics splints & shoe inserts
    - ± stretching of plantar fascia
    - ± night splints to keep ankle in neutral position
  - Steroid ± long-acting local anesthetic injection
    - Usually not possible to inject directly into plantar fascia; instead, inject into perifascial tissues
    - Only temporary relief for ~ 4 weeks
  - Extracorporeal shock wave therapy
  - Surgery (for patients with persistent symptoms)
    - Open or endoscopic release of plantar fascia
- Plantar fibromatosis
  - Conservative
    - Orthotics (shoe inserts)
    - ± steroid ± long-acting local anesthetic injection
  - Surgery (when nonsurgical options exhausted)
    - Recurrence common after surgery

DIAGNOSTIC CHECKLIST

Consider

- Aggressive plantar fibromatosis if plantar fascia nodule has infiltrative superficial or deep margins (rare)

Image Interpretation Pearls

- Likelihood of fasciitis increases with increasing thickness of plantar fascia at calcaneal insertion
- Plantar fibromatosis = distinct plantar fascial nodule separate from calcaneal insertion

SELECTED REFERENCES

1. Flores DV et al: The heel complex: anatomy, imaging, pathologic conditions, and treatment. Radiographics. 44(4):e230163, 2024
2. Khammas ASA et al: An assessment of plantar fascia with ultrasound findings in patients with plantar fasciitis: a systematic review. J Ultrasound. 26:13-38, 2023

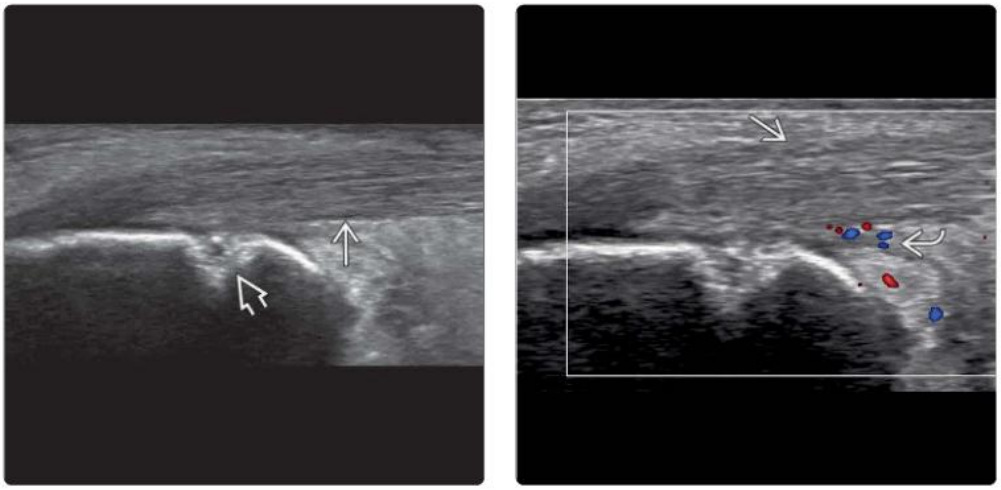

(Left) *Longitudinal US shows a moderately thickened (6-mm) plantar fascia ➡ at the medial tuberosity of the calcaneum in a 30-year-old man. There is a small erosion of the plantar fascia insertion at the calcaneum ➡.* **(Right)** *Longitudinal color Doppler US of the same location shows mild hyperemia ➡ deep to the thickened plantar fascia ➡. Plantar fascial hyperemia is uncommon and may be an indication of more active disease.*

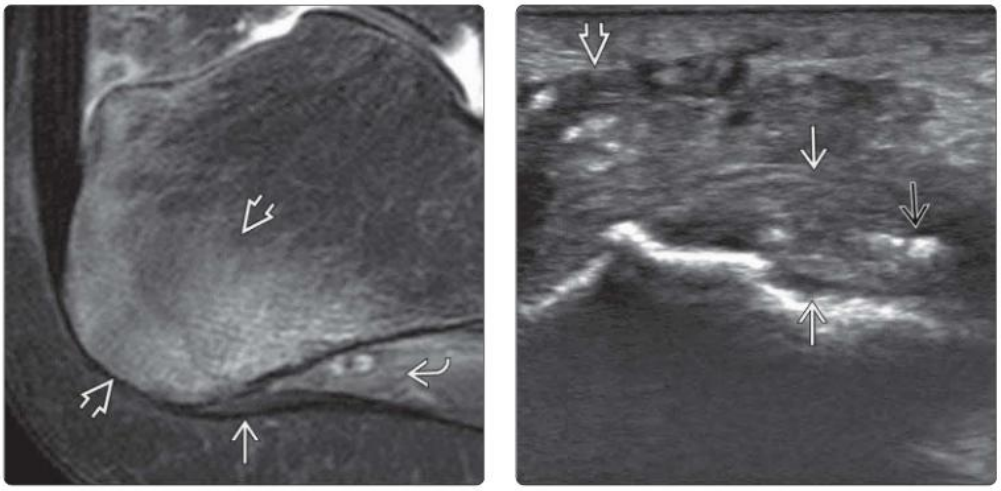

(Left) *Sagittal T2 FS MR in the same patient shows mild thickening of the plantar fascia ➡, moderate subfascial edema ➡, and severe subcortical bone marrow edema ➡. This is indicative of enthesitis associated with peripheral spondyloarthritis.* **(Right)** *Longitudinal US shows severely thickened (7.3-mm) plantar fascia ➡ at the medial part of the calcaneum. Localized dystrophic calcification ➡ is present within the plantar fascia. There is severe edema and dystrophic calcification of the heel fat pad ➡.*

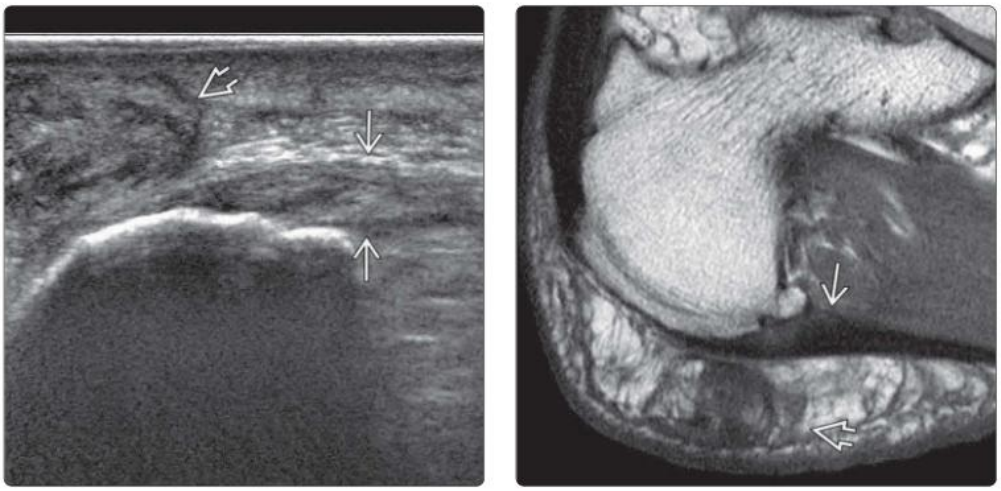

(Left) *Longitudinal US shows a mildly thickened (4.7-mm) plantar fascia ➡ at the medial calcaneal tuberosity. There is a nodular, mass-like area ➡ in the heel fat pad due to fat necrosis and induration. The heel fat pads should also be routinely assessed when examining this area.* **(Right)** *Sagittal T1 MR at almost the same location shows a moderately thickened plantar fascia ➡ with nodular edema and fibrosis of the heel fat pad ➡. The normal thick, lobular septa of the heel fat pad are disrupted.*

(Left) *Longitudinal US of the base of the 5th metatarsal shows bony hyperostosis ⇨ and thickening at the insertion of the normally thin lateral band of the plantar fascia ⇨. This is indicative of an enthesis associated with a peripheral spondyloarthritis.* **(Right)** *Longitudinal color Doppler US at the same location shows moderate hyperemia indicative of high disease activity. The peroneus brevis tendon also inserts separately into the base of the 5th metatarsal bone, though was normal in this patient.*

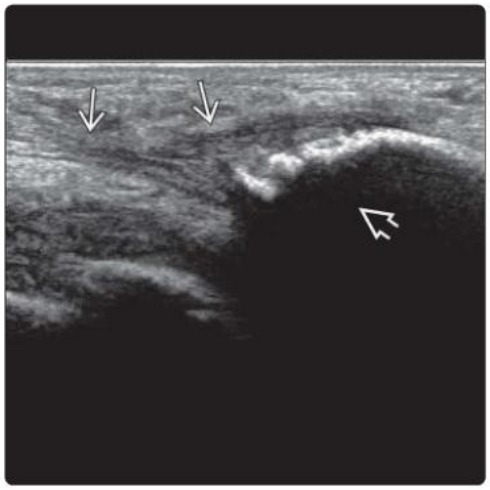

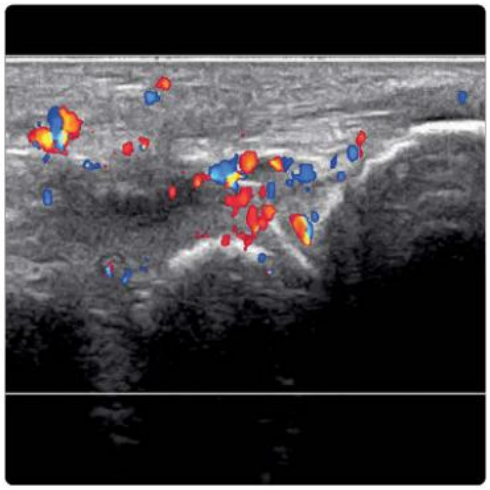

(Left) *Longitudinal graphic shows a large plantar fibroma ⇨ arising from the plantar fascia ⇨.* **(Right)** *Clinical photograph shows a solitary small nodule due to a plantar fibroma ⇨ on the medial aspect of the midsole. Most plantar fibromas occur in the midfoot region and are commonly multiple and bilateral.*

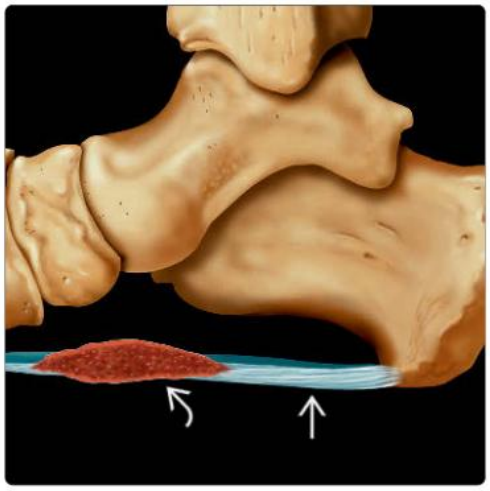

(Left) *Longitudinal US shows a medium-sized (13-mm wide x 3.4-mm deep x 13-mm long) hypoechoic plantar fibroma ⇨ arising from the plantar fascia ⇨ on the medial aspect of the midfoot. No hyperaemia was present.* **(Right)** *Longitudinal US shows a small, hypoechoic plantar fibroma ⇨ arising from the plantar fascia ⇨. This plantar fibroma primarily arises from the more superficial fibers of the plantar fascia.*

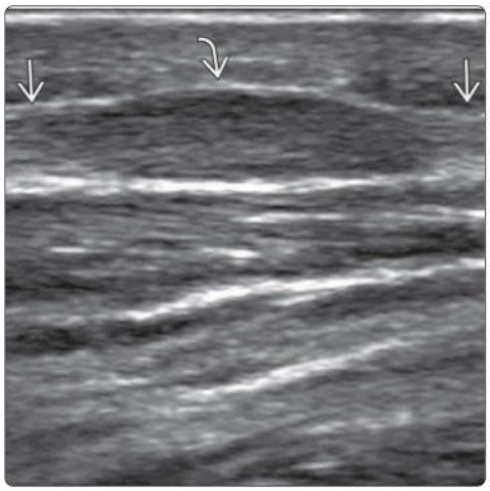

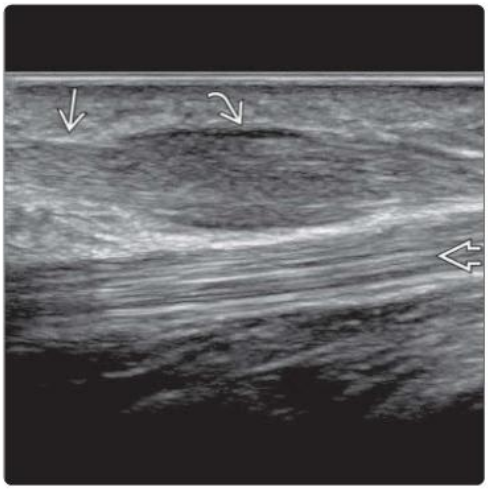

(Left) *Coronal T1 MR shows localized nodular thickening of the medial band of the plantar fascia in the midfoot region, consistent with plantar fibromatosis. The lateral band of the plantar fascia is not thickened.* **(Right)** *Longitudinal US of the midfoot region shows a well-defined, fusiform-shaped, hypoechoic nodule arising from the plantar fascia, consistent with a plantar fibroma. There is mild posterior acoustic enhancement seen in the flexor digitorum longus tendon deep to the fibroma.*

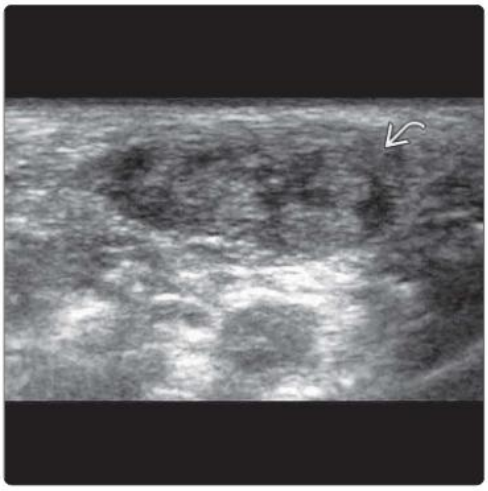

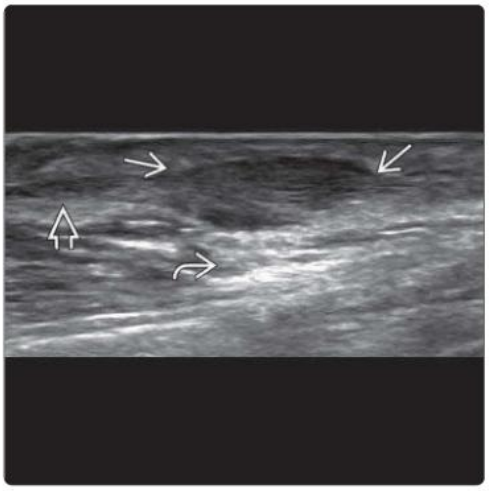

(Left) *Transverse US shows a large, oval-shaped, heterogeneous, echogenic plantar fibroma. Although the fibroma is large, it is still well-defined and not infiltrative.* **(Right)** *Longitudinal US shows a medium-sized (12-mm wide x 4-mm deep x 15-mm long) hypoechoic fibroma within the cental band of the plantar fascia at the midfoot region. Moderate posterior enhancement is present.*

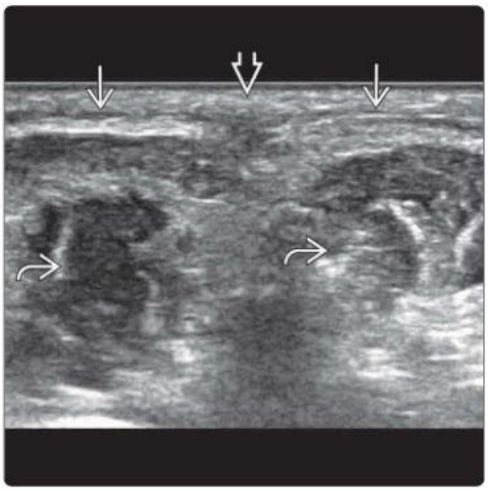

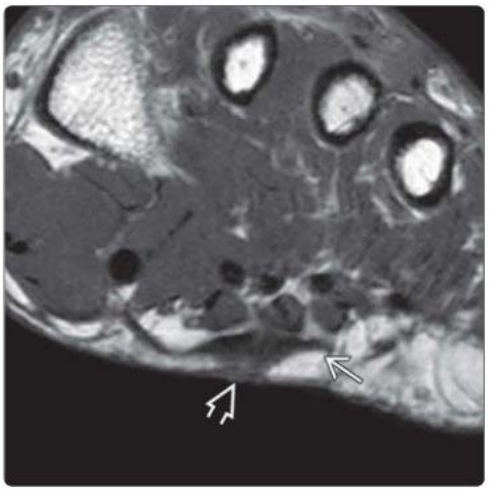

(Left) *Transverse US of the midfoot in a patient with trauma 2 months earlier shows a healing penetrating tear of the midportion of the plantar fascia. This should not be misdiagnosed as a plantar fibroma. The muscle is deep to the plantar fascia.* **(Right)** *Axial T1 MR at the same location shows a healing tear of the midportion of the plantar fascia with reparative fibrous tissue extending from the plantar fascial tear to the skin.*

KEY FACTS

IMAGING

- Subcutaneous most common
  - Well-defined, oblong-shaped encapsulated mass with fine linear striations parallel to long axis of tumor
    - Of variable echogenicity depending on cellularity & fat-water content
  - Absent or minimal internal vascularity on color Doppler
  - Compressible similar to adjacent fat
- Lipomas in patients with multiple lipomas typically appear different from those in patients with 1 or 2
  - Multiple lipomas tend to be more rounded, more echogenic, less well encapsulated, & with fewer striations
  - Tend to be located in trunk & proximal parts of appendicular skeleton
  - Known as Dercum disease if lipomas painful or tender
- Subfascial lipomas are more variable in appearance
  - Nevertheless, appearances usually specific enough to allow confident US diagnosis

CLINICAL ISSUES

- Most common soft tissue tumor
- Soft, well-defined, painless mass enlarging over months, often during period of weight gain

DIAGNOSTIC CHECKLIST

- US findings usually characteristic for both superficial & deep lipomas
  - MR or follow-up US of deep-seated lipoma indicated
- MR useful for assessment of large, deep-seated lipomas
- MR better than US at differentiating between benign & malignant lipomatous masses
  - Large size, deep location, & heterogeneity are best indicators of liposarcoma
  - However, not all heterogeneity within lipoma indicates liposarcoma
  - Calcification, small nonfatty areas, myxoid tissue, & fat necrosis can be features of lipoma variant & not necessarily diagnostic of liposarcoma

(Left) *Clinical photograph shows a large mass on the anterior aspect of the proximal arm.* **(Right)** *Longitudinal US with extended field of view in the same patient shows a large, hyperechoic, subcutaneous lipoma causing focal contour bulging of the skin. The lipoma contains fine linear striation parallel to the skin. The underlying deltoid muscle is normal.*

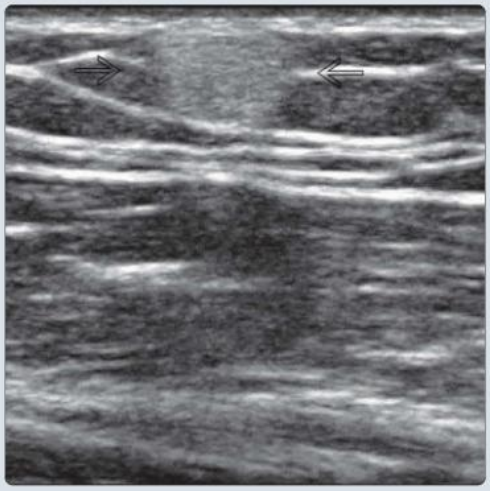

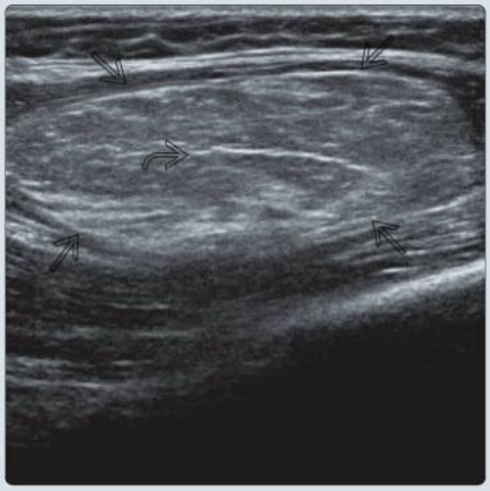

(Left) *Longitudinal US shows a small, well-defined, homogeneously hyperechoic subcutaneous lipoma. The fine striations are barely perceivable. There is no perceivable capsule, The appearances are still characteristic of lipoma. Such lipomas are often multiple and tend to be located more centrally than peripherally.* **(Right)** *Longitudinal US shows a hyperechoic, intramuscular lipoma within the vastus lateralis muscle. Note the well-defined, hyperechoic capsule and the fine linear horizontal striations.*

TERMINOLOGY

Synonyms

- Lipomatous tumor

Definitions

- **Benign**
  - Lipoma: Benign soft tissue tumor composed of mature adipose tissue
  - Angiolipoma: Lipoma in which small, capillary-sized vessels containing microthrombi transverse tumor
  - Lipomatosis: Diffuse, infiltrative overgrowth of mature adipose tissue, completely or partially encapsulated
  - Lipomatosis of nerve: Median > > > other nerves ± localized mesenchymal overgrowth
  - Spindle cell lipoma: Mixture of fat & spindle cells; more common in head & neck subcutaneous tissues & adult males
  - Lipoblastoma: Admixture of mature & immature adipocytes; more common in extremities & children < 3 years old
  - Hibernoma: Tumor of brown (thermogenic) fat; > subcutaneous tissues of adults, especially lower neck, mediastinum, & upper dorsal region
  - Chondroid lipoma: Adult females; shoulder or pelvic girdle; may calcify
  - Myolipoma: Benign tumor exhibiting features of mature smooth muscles & mature adipose tissue
  - Lipoma arborescens: Subsynovial fatty proliferation, knee > > > ankle or hip; may occur in tendon sheath
- Intermediate
  - Well-differentiated liposarcoma (WDL): Slow-growing, usually deep-seated tumor that does not metastasize but prone to local recurrence; dedifferentiation risk 5%
    - a.k.a. atypical lipomatous tumor (ALT)
- Malignant
  - Myxoid liposarcoma: Myxoid tumor either low grade (< 5% round cell component) or high grade (> 5% round cell component)
  - Dedifferentiated liposarcoma: Deep-seated & large with significant (> 25%) nonfatty component; malignant potential
  - Pleomorphic liposarcoma: Large mass with myxoid, necrotic, fatty, & hemorrhagic components

IMAGING

General Features

- Best diagnostic clue
  - Echogenic mass with fine internal echoes aligned parallel to long axis of tumor
- Location
  - Subcutaneous most common
    - Posterior trunk, extremities, neck
    - Multifocal: 10%
  - Subfascial (deep to investing fascia)
    - Intramuscular, intermuscular, supramuscular (i.e., subfascial), & submuscular (i.e., juxtacortical) locations
  - Lipomas do not transverse investing fascia
- Size
  - < 5 cm: 80%; > 10 cm: Uncommon
- Morphology
  - Well-defined, homogeneous, fatty soft tissue mass

Radiographic Findings

- Radiography
  - Hypodense soft tissue mass ± calcification or ossification occasionally

CT Findings

- NECT
  - Well-defined, homogeneous soft tissue mass of low attenuation (-65 to -120 HU)

MR Findings

- T1WI
  - Well-defined mass with high signal intensity & fine septa
  - MR is more reliable than US at depicting features suspicious for malignancy
    - Thick (> 2 mm), irregular septa
    - Nodular or globular areas of nonfatty tissue
    - Well-differentiated liposarcoma usually composed of > 75% fatty component
- T2WI
  - Intermediate signal intensity
- STIR
  - Low signal intensity (fat signal suppressed)
- T1WI C+
  - Intravenous contrast is usually not required if no malignant features on noncontrast imaging

Ultrasonographic Findings

- **Solitary lipoma**
  - Variable echogenicity depending on cellularity & fat-water content
  - Well-defined, encapsulated mass, usually iso- to slightly hyperechoic to adjacent fat
  - Distinctive, fine linear striations parallel to skin
  - Typically fusiform or oblong in shape
  - Encapsulated; helps differentiate lipoma from lipohypertrophy
  - Acoustic enhancement absent
  - Compressible similar to adjacent fat
  - May calcify or ossify infrequently
  - Absent internal vascularity on color Doppler imaging
    - Consider angiolipoma if mild to moderate internal vascularity is present
    - Large lipoma may encase vessels; this feature should not be confused with angiolipoma
- **Multiple lipomas**
  - Lipomas in patients with multiple lipomas typically appear different from those in patients with 1 or 2
  - Multiple lipomas tend to be more rounded, more echogenic, less well encapsulated, & with fewer striations
    - Tend to be located in trunk & proximal parts of appendicular skeleton
    - Known as Dercum disease (adiposis dolorosa) if lipomas painful or tender
  - No need for histological confirmation or further imaging for nearly all superficial lipomas
- Subfascial lipomas are more variable in appearance
  - Still have fine striations parallel to long axis of tumor
  - Iso- or hyperechoic to adjacent muscle

- Usually show acoustic enhancement (acoustic transmission of fat > muscle)
- ± minimal to mild vascularity, more vascular than subcutaneous lipoma
- US can usually indicate diagnosis
  - ± MR to exclude features of liposarcoma
    - MR better at differentiating lipoma from liposarcoma & good baseline test
- Large size, increasing size, deep location, & heterogeneity are best indicators of liposarcoma
  - However, not all heterogeneity within tumor necessarily implies liposarcoma
    - Calcification, small nonfatty areas, myxoid tissue, & fat necrosis can be features of lipoma variant but are not necessarily diagnostic of liposarcoma
    - Lipoma variants include angiolipoma, spindle cell lipoma, hibernoma, chondroid lipoma, osteolipoma, infarcted lipoma
  - WDL/ALT can have homogeneous appearance, indistinguishable from lipoma
  - High-grade liposarcoma can have very little or even no lipomatous component macroscopically

Imaging Recommendations

- Best imaging tool
  - US as diagnostic in most cases
- Protocol advice
  - Avoid transducer pressure but also check compressibility
  - Look for encapsulation & relationship to investing fascia
  - Realize that US appearance of lipomas in patients with multiple lipomas is different
  - Routinely evaluate with color Doppler imaging

DIFFERENTIAL DIAGNOSIS

Lipohypertrophy

- Localized ↑ in subcutaneous fat thickness
- Nonencapsulated, hypertrophied fat gradually merges with normal-thickness surrounding fat
- Similar to lipomatosis except that lipomatosis is more diffuse & ↑ in both superficial & deep fat

Fat Trauma

- Focal subcutaneous fat edema without discrete mass
- Trauma may be trivial (& forgotten) & precede onset of mass by days to weeks

Vascular Malformation

- Often have large fatty stromal component & difficult to distinguish from lipoma, especially angiolipoma
  - Not encapsulated; usually less poorly defined than angiolipomas
  - More vascular than angiolipomas ± phleboliths

Epidermoid Cyst

- Pseudotestis appearance can mimic lipoma
- Posterior acoustic enhancement ± punctum
- ± hyperreflective disc-like foci & cleft-like cystic spaces

PATHOLOGY

General Features

- Etiology
  - Mesenchymal neoplasm
  - More common in overweight & diabetic patients
    - Clinical emergence of lipoma often coincides with period of weight gain
- Associated abnormalities
  - Familial multiple lipomas
    - Autosomal dominant inheritance
- Lipoma fat is similar to normal body fat
  - Sheltered from systemic metabolism; therefore, lipoma does not change size with weight loss

Gross Pathologic & Surgical Features

- Histologic types
  - Benign: Lipoma, angiolipoma, lipoblastoma, hibernoma, spindle cell lipoma, myolipoma, chondroid lipoma, osteolipoma, lipomatosis of nerve, lipoma arborescens, lipomatosis
  - Intermediate: Well-differentiated liposarcoma (WDL)/atypical lipomatous tumor (ALT)
    - Molecular testing of core needle biopsy for amplification of MDM2 gene region via FISH is 100% sensitive & specific in distinguishing lipoma from WDL/ALT
  - Malignant: Differentiated liposarcoma, myxoid liposarcoma, pleomorphic liposarcoma

CLINICAL ISSUES

Presentation

- Most common signs/symptoms
  - Slow-growing, painless, compressible soft mass
- Other signs/symptoms
  - May compress nerves, e.g., carpal tunnel
  - Deep-seated tumors can be firm & simulate sarcoma
    - Can be large at initial clinical presentation

Demographics

- Age
  - Peak: 40-60 years
- Epidemiology
  - Most common soft tissue tumor; 1% of population

Natural History & Prognosis

- Slow-growing mass that becomes latent over time

Treatment

- Excision of large, symptomatic, or suspicious lesions
- Liposuction or lipolysis

DIAGNOSTIC CHECKLIST

Consider

- US usually diagnostic for superficial lipoma
- MR useful for assessment of large, deep-seated lipoma

Image Interpretation Pearls

- Fine internal striations parallel to long axis of tumor = characteristic US finding
- Patients with multiple lipomas may not have this feature

SELECTED REFERENCES

1. Bourgeau M et al: Superficial dedifferentiated liposarcoma: a clinicopathologic study. Hum Pathol. 145:63-70, 2024

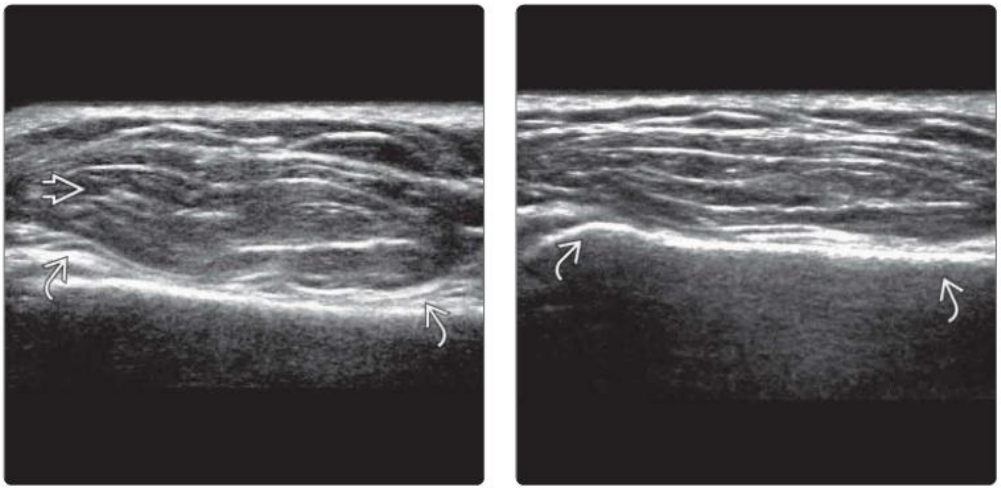

(Left) *Longitudinal US shows a lobulated, oblong-shaped subcutaneous mass ⇨ isoechoic to adjacent fat with distinct internal horizontal striations ⇨ aligned parallel to the skin. These appearances are entirely consistent with a subcutaneous lipoma.* **(Right)** *Longitudinal US of the same lesion ⇨ upon probe compression shows the soft consistency of lipoma, which is easily compressible using mild transducer compression.*

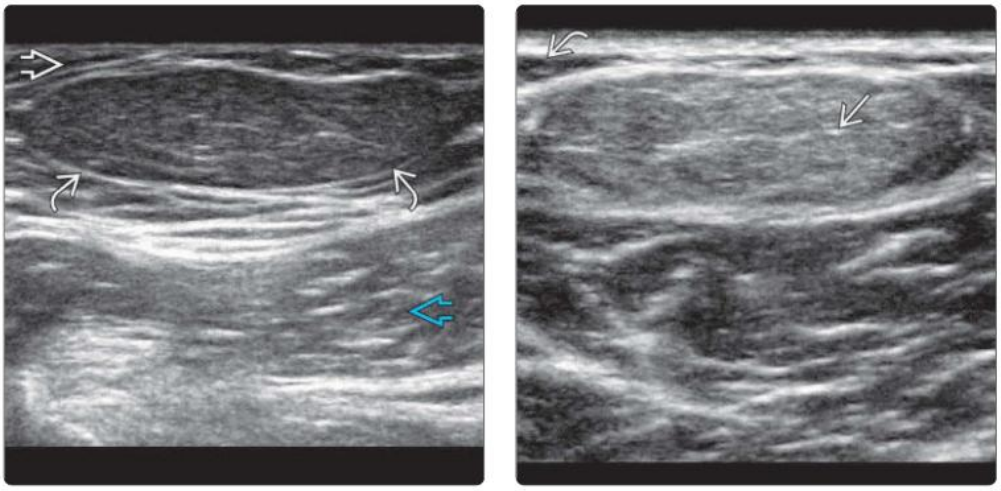

(Left) *Longitudinal US shows a subcutaneous lipoma ⇨ isoechoic to adjacent subcutaneous fat. The echogenicity of lipomas varies and depends on the internal cellularity and fat-water content. Most subcutaneous lipomas tend to be isoechoic to adjacent fat ⇨ and hypoechoic to muscle ⇨.* **(Right)** *Longitudinal US shows another encapsulated lipoma with fine linear internal striations parallel to the long axis of the tumor ⇨. This lipoma is hyperechoic to the surrounding subcutaneous fat ⇨.*

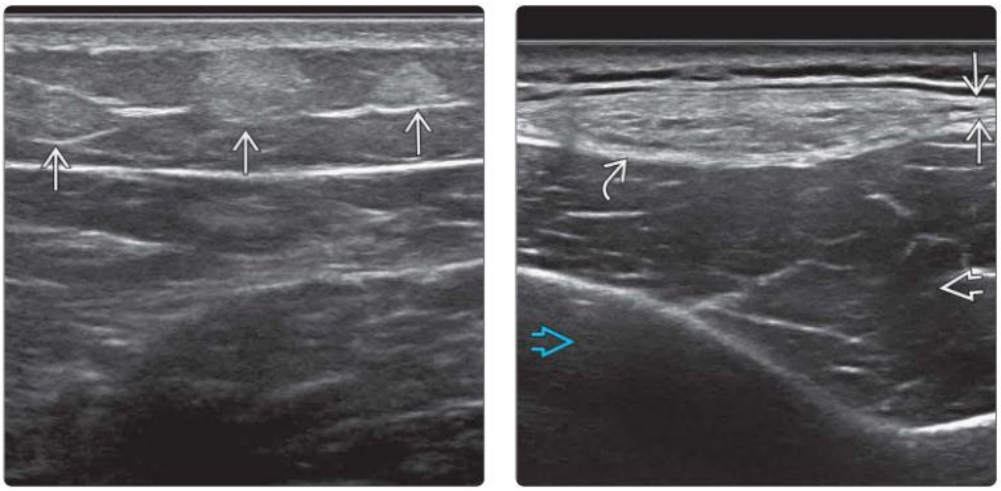

(Left) *Transverse US shows 3 subcutaneous lipomas ⇨ in the forearm. This patient had > 40 lipomas in both upper limbs. Some of these lipomas were tender, compatible with Dercum disease.* **(Right)** *Longitudinal US of another patient shows a hyperechoic lipoma ⇨ at the posterior aspect of the shoulder. The lipoma is located within the investing fascia ⇨ indenting the underlying infraspinatus muscle ⇨. Note the scapula ⇨ deep to the infraspinatus muscle.*

(Left) *Transverse NECT in the same patient shows that the lipoma is located within the investing fascia, splitting the fascial fibers. This is an intrafascial lipoma, an uncommon location for lipoma.* **(Right)** *Longitudinal US of another patient shows a subfascial lipoma in the arm herniating into the subcutaneous fat via a defect in the investing fascia. Note the deltoid muscle. Such a transfascial herniation of lipoma is rare.*

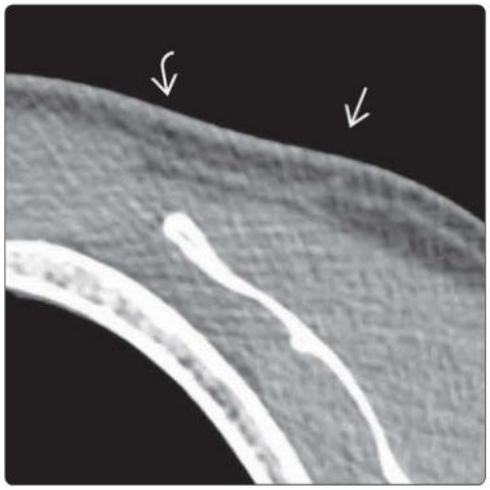

(Left) *Clinical photograph shows a mass in the 2nd web space between the index and middle fingers.* **(Right)** *Transverse US in the same patient shows a well-defined, dumbbell-shaped lipomatous mass in the web space between the 2nd and 3rd metacarpal bones. Note the fine linear striations parallel to the skin within the tumor, which are indicative of a lipoma.*

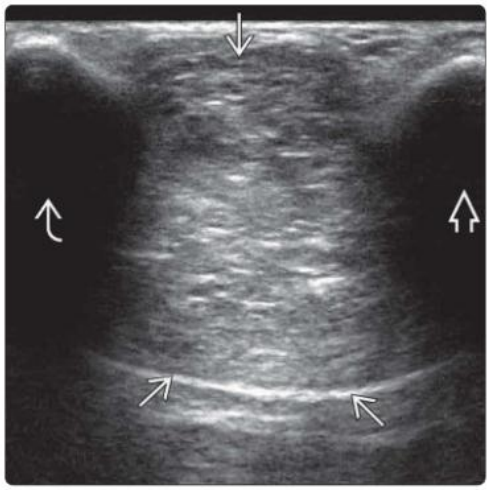

(Left) *Transverse US shows an intramuscular lipoma within the vastus medialis muscle close to the distal femur. The lipoma is slightly hypoechoic to muscle.* **(Right)** *Coronal T1 MR of the same patient shows the well-defined lipoma within the vastus medialis muscle. Note the thin internal septations. The appearances are consistent with an intramuscular lipoma. There are no atypical features.*

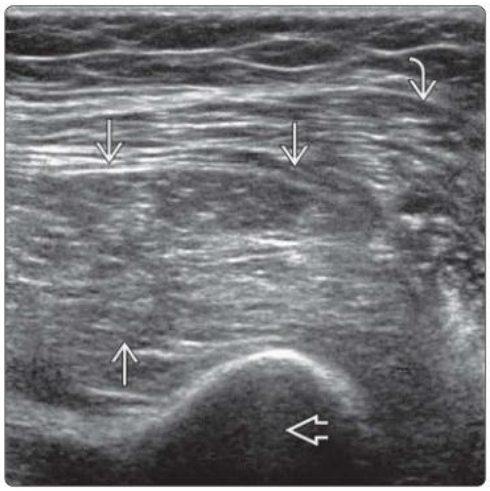

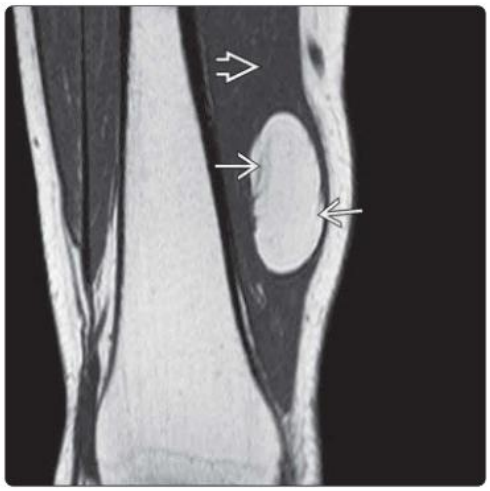

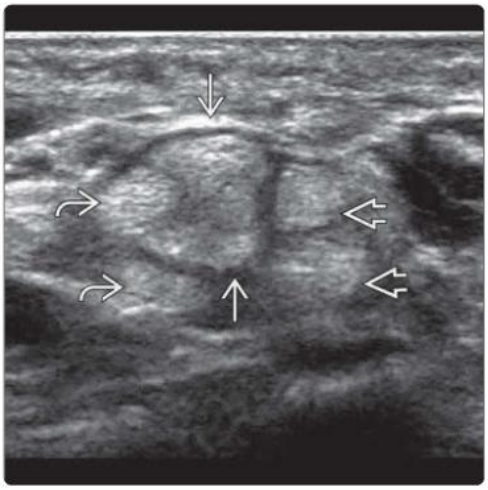

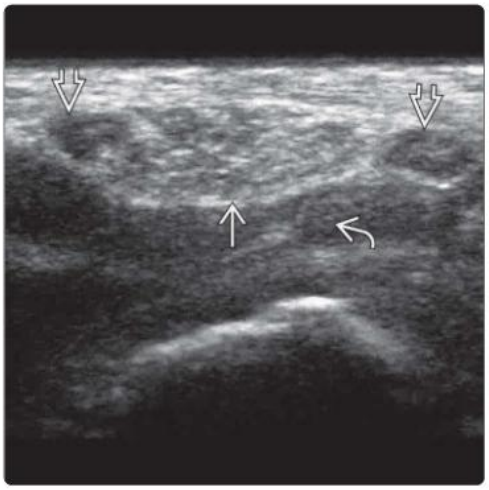

(Left) *Transverse US of the wrist shows a hyperechoic lipoma located between the flexor tendons of the middle finger and the ring finger. The superficial flexor tendon of the middle finger is partially encased.* **(Right)** *Transverse US of the wrist shows a lipoma located between and separating both components of a bifid median nerve. The lipoma lies superficial to the flexor tendons.*

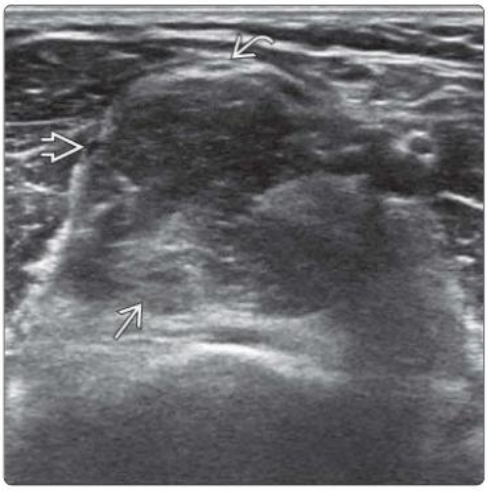

(Left) *Transverse US of a patient with radial nerve palsy shows a hypoechoic mass located in the radial tunnel at the proximal forearm. The mass is displacing both the superficial branch and deep branches of the radial nerve.* **(Right)** *Transverse PD FS MR in the same patient reveals a radial tunnel lipoma. The mass is located deep to the brachioradialis muscle and superficial to the supinator muscle. Note the superficial and deep branches of the radial neurovascular bundle.*

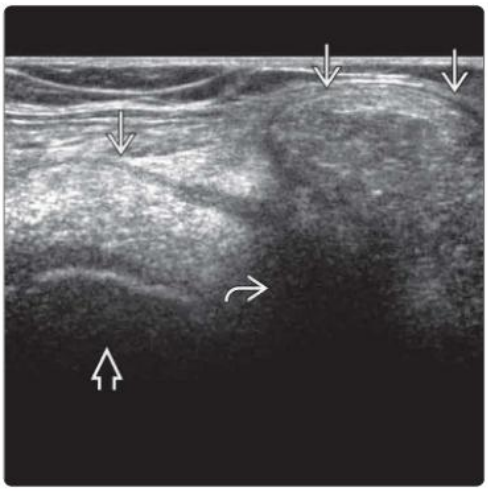

(Left) *Longitudinal US shows a lipomatous-type mass at the posterior aspect of the knee joint. The large size of the mass and the associated acoustic shadowing hinders full assessment of deep or intraarticular involvement. Note the femoral condyle.* **(Right)** *Longitudinal T1 MR of the same lesion shows the mass to be an intraarticular lipoma bulging into the posterior joint capsule. The full extent of this large lipoma is best appreciated on MR.*

(Left) *Transverse US of the shin shows the normal appearance of the subcutaneous fat layer ➡. Note the tibia ➡ and anterior tibialis muscle ➡.* **(Right)** *Transverse US of the contralateral shin in the same patient shows moderate, diffuse thickening of the subcutaneous fat ➡ without a discrete mass being present. This is consistent with localized subcutaneous lipohypertrophy. Comparison with the same area on the contralateral limb is very helpful in such cases.*

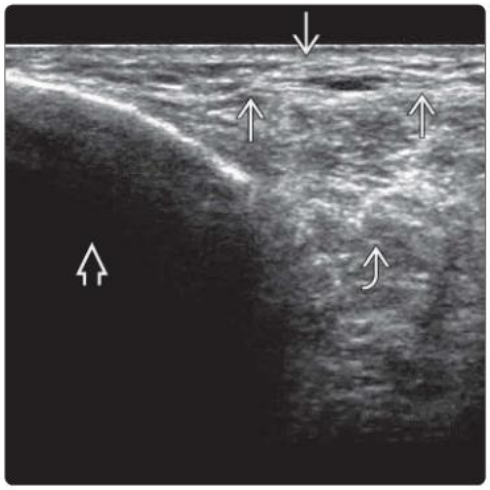

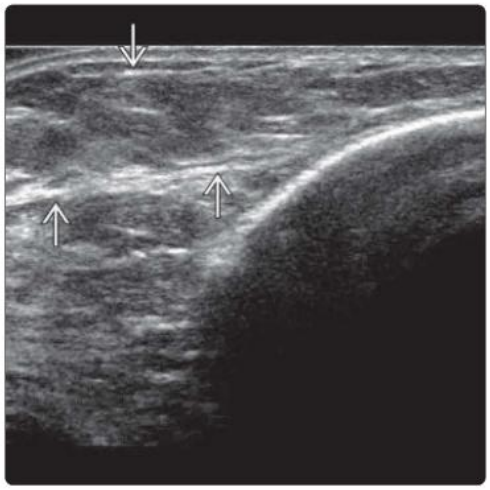

(Left) *Longitudinal US of the hand shows a hyperechoic lipomatous mass ➡ within the first dorsal interosseous muscle ➡ between the thumb and index finger metacarpal bones. Note the fine linear striations, consistent with an intramuscular lipoma.* **(Right)** *Longitudinal US of the same tumor shows multiple small, calcific foci ➡ within the lipoma with posterior shadowing. The appearances are consistent with a calcified intramuscular lipoma.*

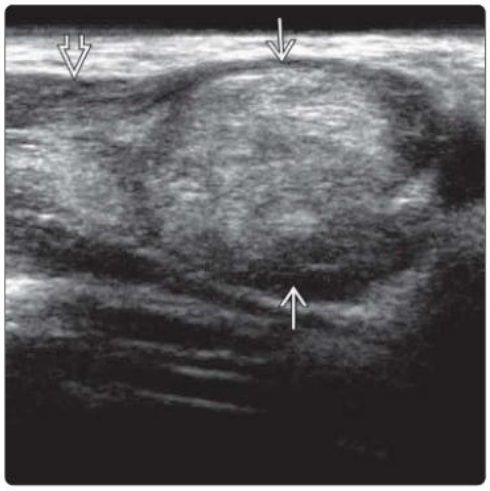

(Left) *Longitudinal color Doppler US shows a subcutaneous hyperechoic mass with moderate intrinsic vascularity. The differential diagnoses include an angiolipoma or vascular malformation with fatty stroma. Angiolipoma was confirmed by pathology following excision.* **(Right)** *Frontal radiograph in a 7-year-old girl with known tuberous sclerosis shows a lucent soft tissue mass ➡ at the medial aspect of the knee.*

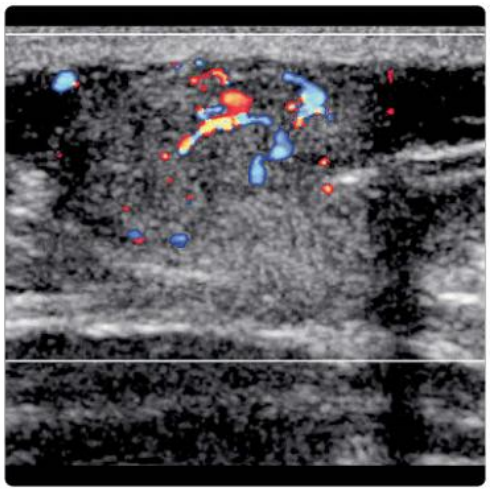

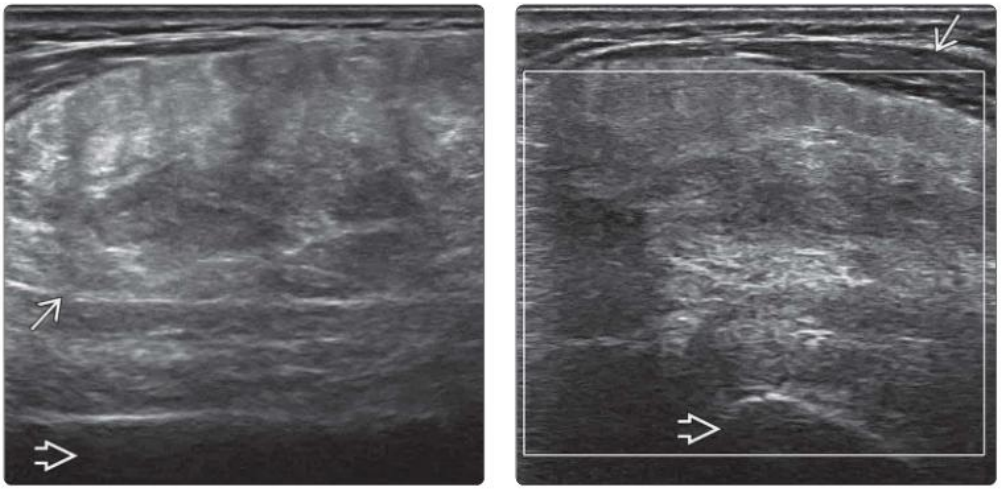

(Left) *Longitudinal US in the same patient shows a large, lipomatous mass ⇨ with heterogeneous echotexture on the anterior aspect of the distal femur ⇨.* **(Right)** *Transverse color Doppler US of the same lesion shows no detectable vascularity. The mass lies deep to quadriceps tendon ⇨, which is displaced laterally and anterior to the distal femur ⇨. The mass was biopsied, and histology revealed benign fibrolipomatous tumor. Nonlipomatous component may indicate lipoma variant.*

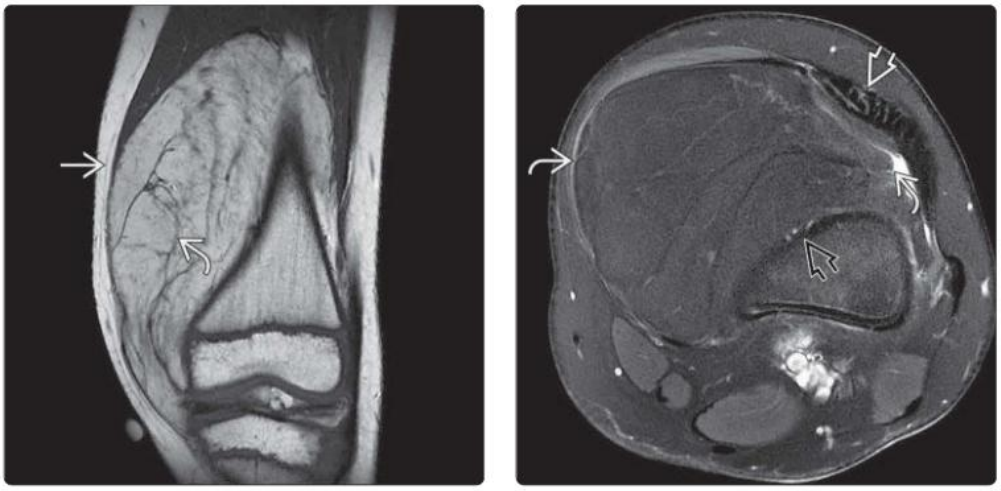

(Left) *Coronal T1 MR in the same patient shows a large, lipomatous mass ⇨ on the anteromedial aspect of the distal thigh. The mass has multiple thin septation strands ⇨.* **(Right)** *Axial T2 FS MR shows complete signal suppression of the lipomatous tumor ⇨ deep to the quadriceps tendon ⇨ and abutting the femoral cortex ⇨. Following excision, a fibrolipomatous tumor with an immunoprofile suggestive of angiomyolipoma was found, known to be associated with tuberous sclerosis.*

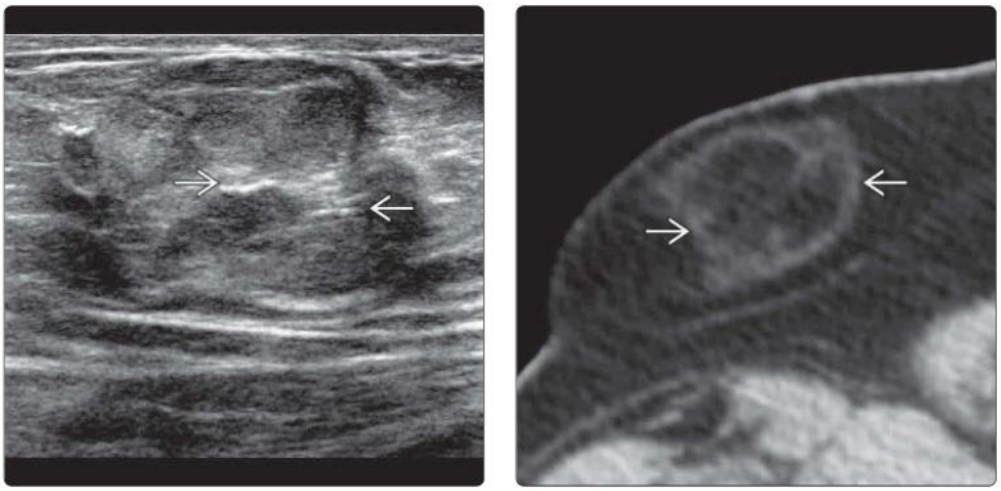

(Left) *Transverse US of the groin region shows a moderately heterogeneous, subcutaneous, lipomatous mass with linear, echogenic foci ⇨. The differential diagnosis is atypical lipoma, fibrolipoma, or slow-flow vascular malformation.* **(Right)** *Transverse CT of the same lesion shows a lipomatous mass with a slightly thickened peripheral rim ⇨, consistent with an atypical lipoma. Histology revealed a lipoma with central fat necrosis, calcification, & fibrinous stranding.*

(Left) *Longitudinal US of the wrist shows a slightly irregular, heterogeneous, subcutaneous mass partially involving the flexor carpi ulnaris muscle. The mass appears lipomatous with irregular areas of hypoechoic nonlipomatous tissue.* **(Right)** *Axial T1 MR of the same mass shows there is intramuscular extension into the flexor carpi ulnaris muscle. Intralesional fat with nonfatty soft tissue component is present. Liposarcoma was suspected. Final histology revealed spindle cell lipoma.*

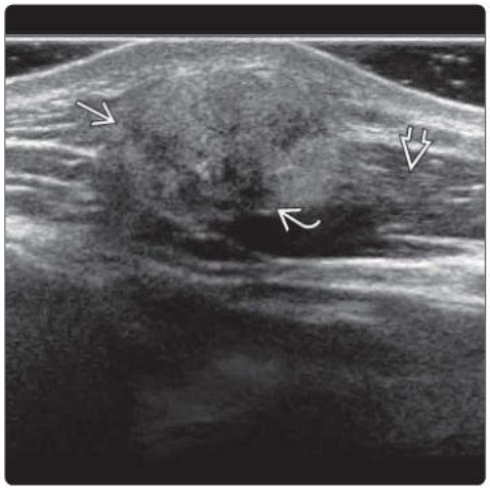

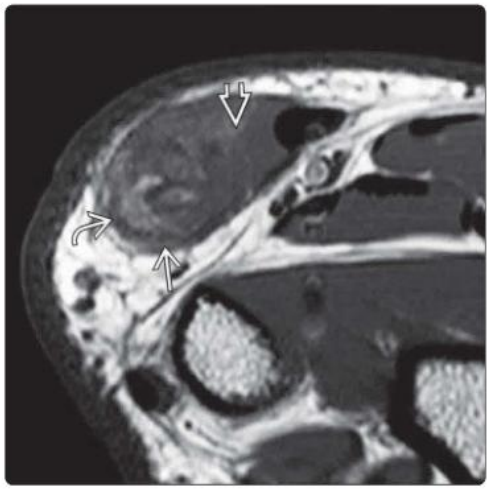

(Left) *Transverse US in a 2-year-old with a 1-month history of posterior thigh swelling shows a large, well-circumscribed, heterogeneous mass in the posterior thigh superficial to the femur. Scattered areas of hyperechoic, lipomatous-type tissue are present.* **(Right)** *Longitudinal color Doppler US of the same lesion shows moderate intratumoral hypervascularity. More foci of echogenic, fatty-type tissue are evident in this scan plan.*

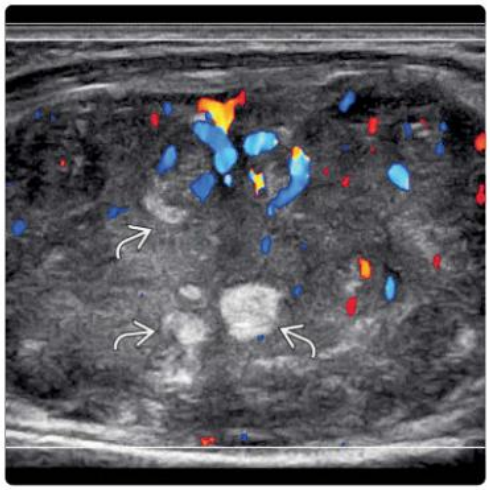

(Left) *Axial T1 MR in the same patient shows a large, well-circumscribed mass in the posterior thigh. The mass is predominantly nonfatty with a small fat component centrally within, corresponding to the US appearances.* **(Right)** *Axial T1 C+ FS MR in the same patient shows heterogeneous enhancement of the mass. Based on the patient's age and the imaging features, the most likely diagnosis was lipoblastoma. This was confirmed on histology.*

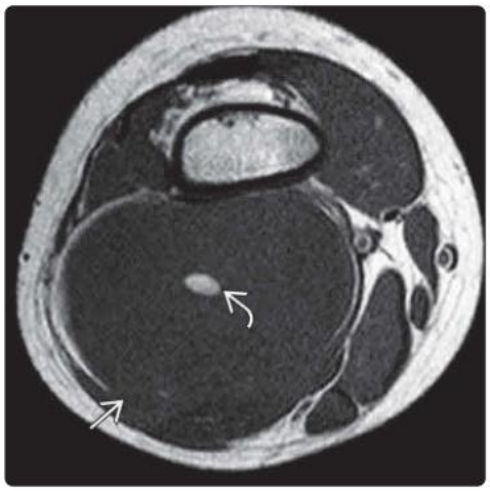

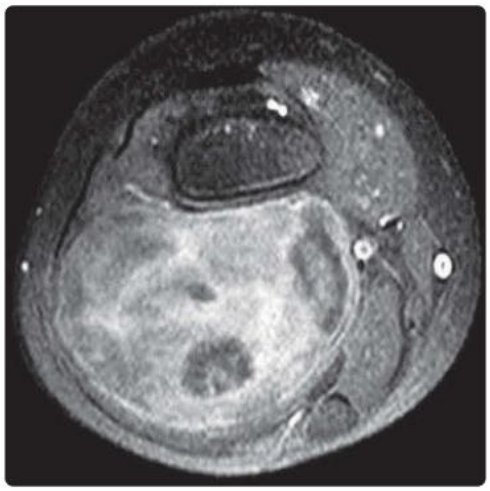

(Left) *Coronal T1 MR shows a large tumor within the triceps brachii muscle. The mass is almost entirely lipomatous with small areas of nonlipomatous component and prominent vessel within the inferior portion of the tumor.* **(Right)** *Transverse US shows subtle heterogeneity of the tumor matrix. Note the prominent vessel again seen in this area. This area was targeted for percutaneous biopsy, and histology revealed well-differentiated liposarcoma. MR is better than US in differentiating lipoma from liposarcoma.*

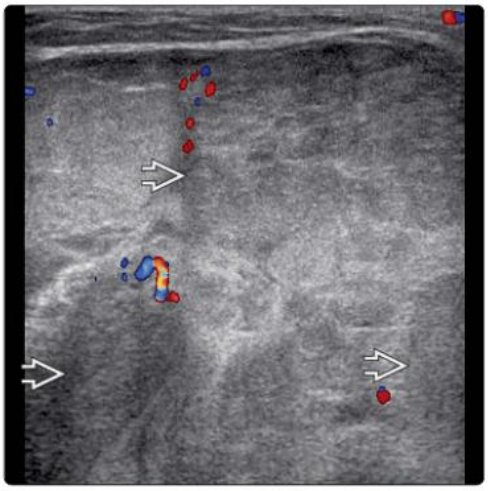

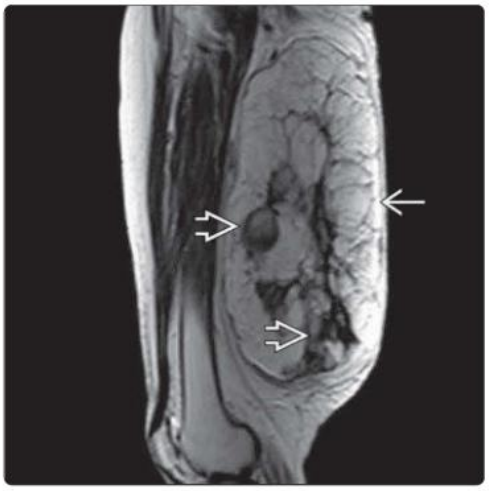

(Left) *Longitudinal US in a patient with pathologically proven myxoid liposarcoma shows a large, intramuscular, heterogeneous, lipomatous mass with moderate intrinsic vascularity & areas of nonlipomatous, hypoechoic tissue. The nonlipomatous components are more obvious than in the previous lesion.* **(Right)** *Longitudinal T1 MR of the same lesion shows a large, heterogeneous, lipomatous mass in the posterior thigh with medium-sized areas of nonfatty tissue and thickened septa.*

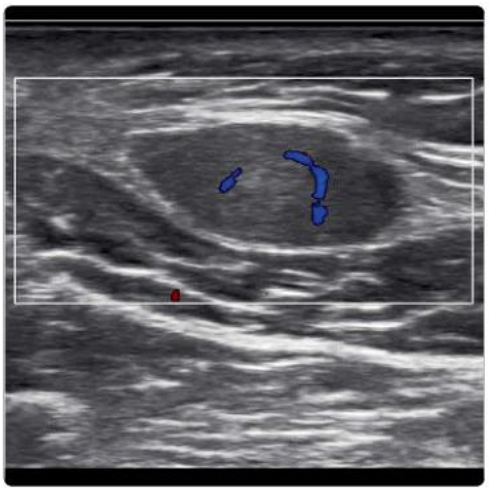

(Left) *Transverse US in a patient with previous resection of myxoid liposarcoma shows an oval, hypoechoic, subcutaneous nodule close to the surgical excision scar.* **(Right)** *Follow-up transverse color Doppler US 2 months later shows interval enlargement and moderately vascularity of the tumor, compatible with tumor recurrence. Myxoid liposarcoma with round cell component (> 20%) was shown histologically following reexcision. Macroscopic fatty component may not be visible in high-grade liposarcoma.*

KEY FACTS

TERMINOLOGY

- Slow-growing subdermal cyst that contains keratin & is lined by stratified squamous epithelium
  - Cyst wall must not contain dermal elements

IMAGING

- US appearances depend on maturation of cyst & amount & compactness of keratin
  - ± presence of cyst rupture & degree of cyst collapse
- Well-circumscribed ovoid (80%), lobulated (19%), or tubular (1%) configuration
- Most are heterogeneous & mildly hyperechoic
- Linear hyperreflective disc-like areas represent layered keratin aggregates ± cholesterol deposition
- Cleft-like or filiform anechoic or hypoechoic areas are due to cyst-like spaces lacking keratin
- Some homogeneous with pseudotestis appearance
- Increased acoustic transmission (96%)
- Calcification is rare
- Thin, hypoechoic cyst wall
  - Hypoechoic tract extending from superficial wall to dermis (10%) (punctum or submarine sign)
- Contained rupture → lobulated configuration of cyst
- Most epidermoid cysts are avascular
  - Peripheral & pericystic vascularity is feature of cyst rupture & inflammation
- Can enlarge up to 10 cm
- Accuracy of US in making diagnosis of epidermoid cyst is 92%

TOP DIFFERENTIAL DIAGNOSES

- Trichilemmal cyst, lipoma, soft tissue abscess, slow-flow vascular malformation, nerve sheath tumor

DIAGNOSTIC CHECKLIST

- Characteristic US appearances in most cases
- Consider localized leakage of cyst content if inflammation is present around epidermoid cyst

(Left) *Longitudinal US shows a hypoechoic epidermoid cyst with dermal attachment ⇨, multiple internal filiform anechoic areas ⇨ due to small cystic spaces, and linear hyperreflective strands ⇨ due to keratin and cholesterol aggregates as well as posterior acoustic enhancement.* **(Right)** *Longitudinal US shows an epidermoid cyst with dermal attachment, internal hyperreflective strands ⇨, small hypoechoic areas ⇨, and hypoechoic tract ⇨ (submarine sign) extending to cutaneous punctum.*

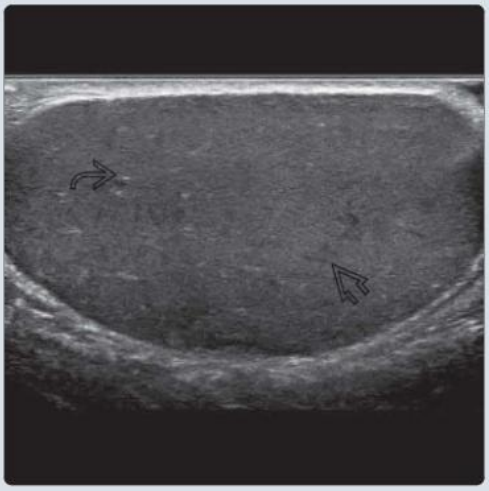

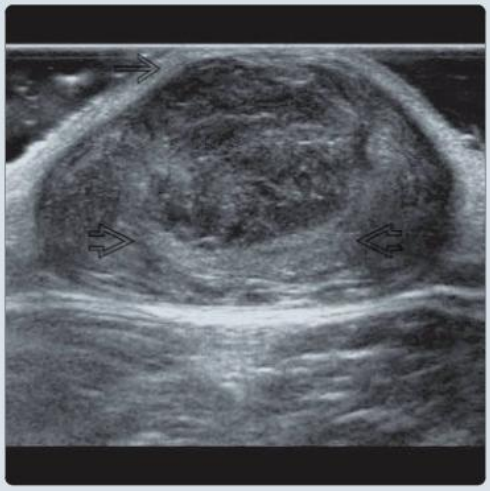

(Left) *Longitudinal US shows another epidermoid cyst with a rather homogeneous internal echotexture and a pseudotestis appearance. The characteristic echogenic foci ⇨ and small cleft-like cystic spaces ⇨ are less obvious than in previous image.* **(Right)** *Longitudinal US shows an epidermoid cyst with heterogeneous echogenic content, alternate layering ⇨, multiple floating echogenic foci, and increased through transmission. The broad dermal contact and dermal protuberance indicate dermal attachment ⇨.*

TERMINOLOGY

Synonyms

- Epidermal inclusion cyst, epidermal cyst, infundibular cyst, sebaceous cyst

Definitions

- Slow-growing subdermal cyst that contains keratin & is lined by stratified squamous epithelium
  - Most cysts are due to ductal blockage of hair follicles with downward rupture of obstructed pilosebaceous unit
  - Some cysts result from traumatic or embryologic subdermal sequestration of epithelial tissue
    - Histologically similar &, hence, grouped under general term epidermoid cyst
  - Wall of cyst must not contain dermal elements
    - Presence of dermal elements → designated as dermoid cyst
  - Epidermis = outer layers of skin
    - Contains keratinocytes, corneocytes, & melanocytes
  - Dermis = inner layers of skin that support epidermis
    - Contains hair follicles, nerves, sweat glands, small blood vessels, & sebaceous glands
  - Subdermal = superficial part of subcutaneous tissues immediately beneath dermis

IMAGING

General Features

- Best diagnostic clue
  - Well-circumscribed, cyst-like mass with thick, linear, seed- or disc-like hyperechoic foci, filiform anechoic areas, & dermal attachment
- Location
  - Predominately in body areas with most hair
  - Most commonly seen in head & neck
  - Trunk & extremities less commonly found
    - Most cysts occurring in relatively hairless areas, such as palm or sole, are implantation epidermoid cysts
    - Trauma → implantation of epidermal elements to dermis or subdermal tissue, which survive, grow, & produce keratin
  - Can rarely occur within tendon or bone
- Size
  - < 1 cm to > 10 cm; usually < 5 cm
- Morphology
  - Well-circumscribed subdermal or dermal mass

Radiographic Findings

- Soft tissue swelling if large size
- Rarely, bony remodeling or lytic bone lesion with sclerotic border

CT Findings

- Noncalcified soft tissue attenuation mass in subdermal layer
  - Low-density, fluid-like attenuation due to high lipid content
- No enhancement or minimal rim enhancement

MR Findings

- T1WI
  - Isointense to slightly hyperintense relative to muscle
- T2WI
  - Hyperintense signal with high- or low-signal intensity content
    - Low-signal debris represents keratin aggregates; high-signal debris represents cholesterol deposition
  - Content may be positionally dependent or layered concentrically
  - T2-hypointense rim due to stratified squamous epithelial wall
- T1WI C+
  - Absent to low level of central enhancement with enhancing capsule

Ultrasonographic Findings

- US appearances depend on maturation of cyst, compactness, & amount of keratin
  - ± presence of cyst rupture & degree of cyst collapse
- Well-circumscribed ovoid (80%), lobulated (19%), or tubular (1%) configuration
- Dermal attachment (i.e., no intervening subcutaneous fat between lesion & dermis)
  - ± broad dermal contact, dermal protrusion
  - ± involvement of > 50% dermal tissue thickness
  - ± focal hypoechoic region extending toward epidermis, i.e., punctum or submarine sign
    - Hypoechoic punctum seen between cyst & dermis in 10% of those referred for US
    - Many epidermoid cysts with clinically obvious punctum may not be referred for US
- Cyst confined to subcutaneous tissue
  - No subfascial extension
- Most are unilocular
- Most cysts are heterogeneous & mildly hyperechoic
  - Linear hyperreflective disc-like areas represent layered keratin aggregates ± cholesterol deposition
  - Cleft-like or filiform anechoic or hypoechoic areas are due to cyst-like spaces lacking keratin
  - ± multilayered appearance with hyperechoic & hypoechoic rings
  - ± target appearance with hyperechoic center surrounded by hypoechoic rim
  - ± "swirling" of mobile cyst contents when compressed
  - Calcification is rare
- Some cysts are homogeneous with pseudotestis appearance
- Increased acoustic transmission (96%)
- Thin, hypoechoic cyst wall
  - Focal discontinuity or irregular cyst contour are indicative of cyst rupture
    - Localized contained rupture may give rise to lobulated configuration
- Most epidermoid cysts are avascular
  - Peripheral vascularity, or occasionally central vascularity, is feature of previously ruptured cysts
  - Leakage of cyst contents → pericystic inflammation
  - Twinkle artifact on color Doppler imaging due to strong reflective interfaces arising from keratin layers within cyst

- Soft on strain elastography
- Accuracy of US for diagnosing epidermoid cyst is 92%
  - Most cysts have distinctive US appearance

Imaging Recommendations

- Best imaging tool
  - US
    - Can make correct diagnosis in majority of cases
- Protocol advice
  - Transverse, longitudinal scans & color Doppler imaging
    - Determine any connection with dermis
    - Ensure continuity of cyst wall
    - Determine any rupture ± surrounding inflammation
    - Minimal transducer pressure during color Doppler imaging

DIFFERENTIAL DIAGNOSIS

Trichilemmal Cyst

- Vast majority arise from scalp
- Heterogeneous subcutaneous nodule with higher prevalence of calcification & cystic areas
- No punctum

Lipoma

- Isoechoic to adjacent subcutaneous fat, compressible
- Fixed linear horizontal echogenic striations parallel to skin
- More homogeneous than epidermoid cysts

Soft Tissue Abscess

- Can be difficult to differentiate from inflamed, infected, or ruptured epidermoid cyst
- Liquefied component of abscess

Slow-Flow Vascular Anomaly

- Vascular anomaly with predominant fatty stroma can mimic epidermoid cyst
- Small vessels may be too small to be resolved by US
- Will have either no or mild acoustic enhancement

Nerve Sheath Tumor

- Tend to occur along neurovascular bundle
- Usually hypoechoic & hypervascular
- Entering & exiting nerves may be seen

PATHOLOGY

General Features

- Etiology
  - Low-grade inflammation → epithelial hyperplasia & obstruction at infundibulum of pilosebaceous unit (composed of hair follicle, sebaceous gland, & arrector pili muscle)
  - Followed by downward rupture of obstructed pilosebaceous unit
  - Alternatively, embryologic or traumatic sequestration of epidermal tissue into subdermal tissues

Gross Pathologic & Surgical Features

- Elastic mass with "butter & cheese" content
- Microscopic features
  - Encapsulated cyst with walls of stratified squamous epithelium
    - Walls do not contain dermal elements, such as sebaceous glands or hair follicles
  - Lumen filled with laminated keratinaceous material
- Additional findings associated with cyst rupture
  - Pericystic granulomatous reaction with inflammation & fibrosis
  - Cyst contents excite foreign body reaction

CLINICAL ISSUES

Presentation

- Most common signs/symptoms
  - Most are incidental finding
- Other signs/symptoms
  - May report history of penetrating trauma many months or years earlier
  - Firm, slowly growing, painless mass
  - Mobile or tethered to skin
  - ± punctum
  - ± symptoms & signs of inflammation

Demographics

- Age
  - Any; more common in 3rd-5th decades
- Sex
  - M > F (slightly)
- Epidemiology
  - 7% of superficial masses referred for US
  - 12% of superficial masses surgically excised

Natural History & Prognosis

- May rupture, become inflamed or infected
  - Infection of epidermoid cyst is probably uncommon
  - No difference in microbiologic milieu of infected & noninfected inflamed cysts
  - Most cyst "infections" probably due to inflammation induced by cyst rupture rather than true infection
- No local recurrence if complete surgical excision
- Rare reports of malignant transformation to squamous cell carcinoma

Treatment

- Antiinflammatory agents & antimicrobial agents
- Incision & expression of cyst contents
  - High rate of recurrence
- Incision & expression of cyst contents & removal of cyst wall through same minimal incision
- Total excision of cyst
- Laser therapy for cysts on face & other sensitive areas
- Surgery for previously ruptured epidermoid cysts associated with pericystic scarring is more complicated than surgery for nonruptured cysts

DIAGNOSTIC CHECKLIST

Consider

- Consider localized leakage of cyst content if inflammation present around epidermoid cyst

SELECTED REFERENCES

1. Ren WW et al: The value of ultrasound for differentiating trichilemmal cysts from epidermoid cysts. J Ultrasound Med. 42(9):1941-50, 2023

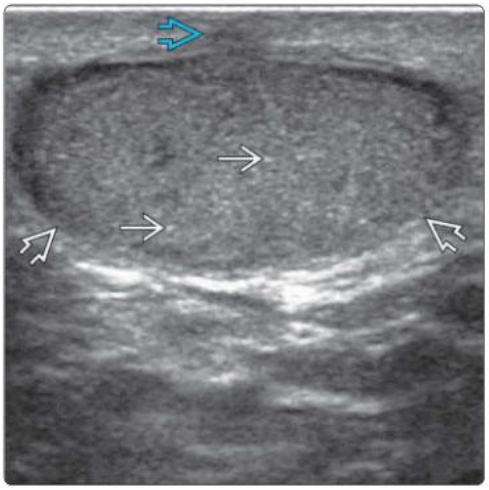

(Left) *Clinical photograph shows mild protuberance and mild bluish discoloration due to a small epidermoid cyst on the posterior aspect of the shoulder. Note the central punctum.* **(Right)** *Longitudinal US in the same patient shows an encapsulated epidermoid cyst with multiple small echogenic foci due to keratin and cholesterol aggregates and posterior acoustic enhancement. There is a focal hypoechoic protrusion toward the dermis, known as the submarine sign.*

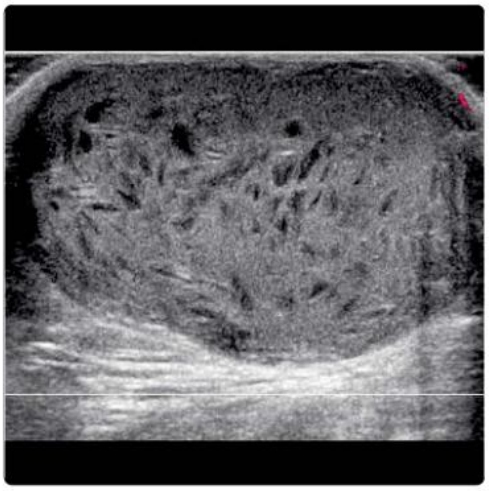

(Left) *Transverse US shows a well-circumscribed epidermoid cyst with increased through transmission, internal cleft-like hypoechoic areas, echogenic strands, and foci due to keratin and cholesterol aggregates.* **(Right)** *Transverse color Doppler US of the same cyst shows absence of central or marginal vascularity, which is a typical finding in an epidermoid cyst without inflammation or rupture.*

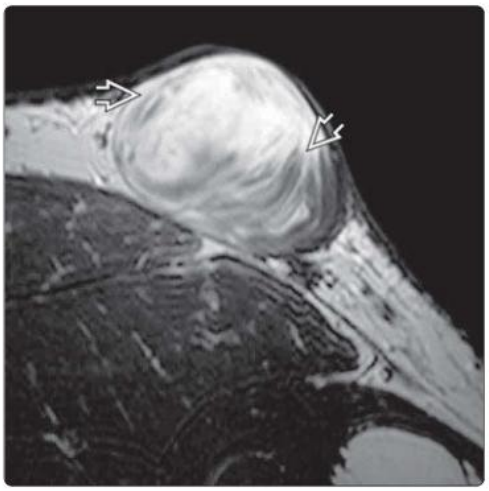

(Left) *Transverse color Doppler US shows an ovoid heterogeneous epidermoid cyst with dermal attachment. Internal filiform hypoechoic areas and a laminated pattern representing compacted keratin layers are seen. There is no intralesional vascularity.* **(Right)** *Axial T2 MR of the same lesion shows hyperintense cyst content with hypointense lamina due to layers of compacted keratin. These features are very typical of an epidermoid cyst.*

(Left) *Transverse US shows an ovoid, mildly hyperechoic epidermoid cyst with a multilayered appearance comprising hyperechoic and hypoechoic rings. Note also the hyperreflective stands and posterior acoustic enhancement.* **(Right)** *Longitudinal US of the buttock shows a large hyperechoic mass with dermal attachment. There is a focal 50% depth involvement of the dermis. The initial US diagnosis was a large epidermoid cyst with atypical lipoma considered as a less likely alternative diagnosis.*

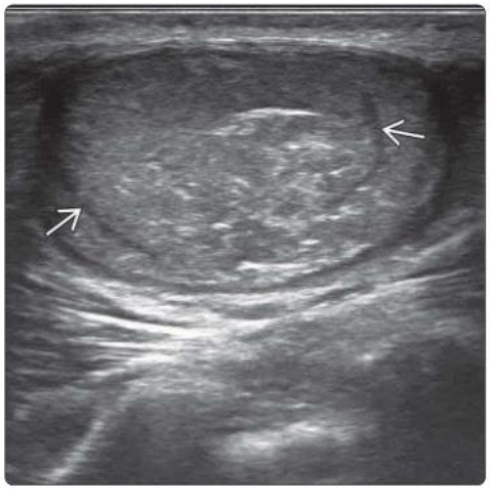

(Left) *Transverse T1 MR of the same lesion shows a large well-circumscribed hypointense subdermal mass. There is a focal dermal attachment corresponding to the US features.* **(Right)** *Transverse T2 MR of the same lesion shows the predominant hyperintense cyst content with multiple disc-like hypointense areas representing keratin aggregates. Both the US and MR findings are consistent with an epidermoid cyst, which was confirmed histologically.*

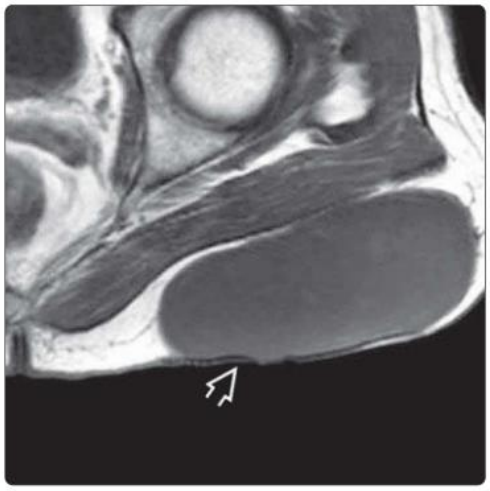

(Left) *Longitudinal US shows a hypoechoic epidermoid cyst with increased acoustic through transmission. No hyperemia is present. The epidermoid cyst is small, superficial, and involving > 50% of dermal depth. Although not all typical features are present, it is still sufficient to make a quite definitive diagnosis based on the US appearances alone.* **(Right)** *Longitudinal US shows a small, hypoechoic epidermoid cyst with increased acoustic through transmission and the characteristic submarine sign.*

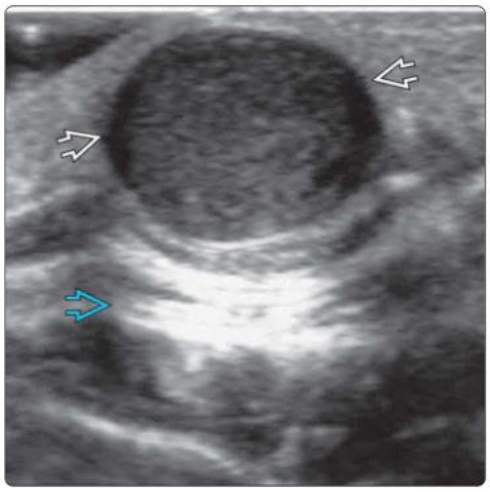

(Left) *Clinical photograph shows a large, protuberant mass ➡ over the posterolateral aspect of midneck region. No visible punctum is present. Most of the epidermoid cysts referred for US examination do not have a visible punctum.* **(Right)** *Transverse US of the same lesion shows a subcutaneous epidermoid cyst with a pseudotestis appearance. The epidermoid is mildly hyperechoic relative to the muscle ➡. There are very small echogenic foci ➡ due to keratin or cholesterol deposits.*

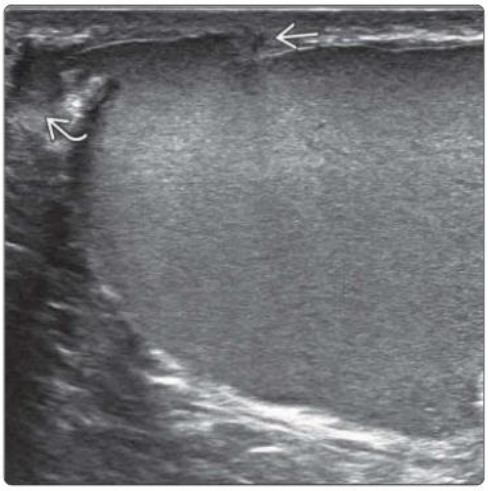

(Left) *Longitudinal US shows a homogeneous epidermoid cyst in the buttock. There is a focal lobulated contour at the superolateral aspect of the epidermoid cyst representing the dermal attachment ➡ and possible early leakage ➡.* **(Right)** *Transverse US of the thumb shows an epidermoid cyst with lobulated contours ➡. Epidermoid cysts are mostly ovoid in configuration. Localized contained rupture of the epidermoid cyst can give rise to a multilobulated appearance.*

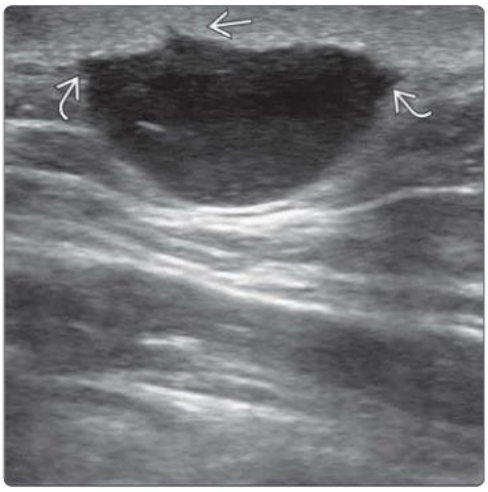

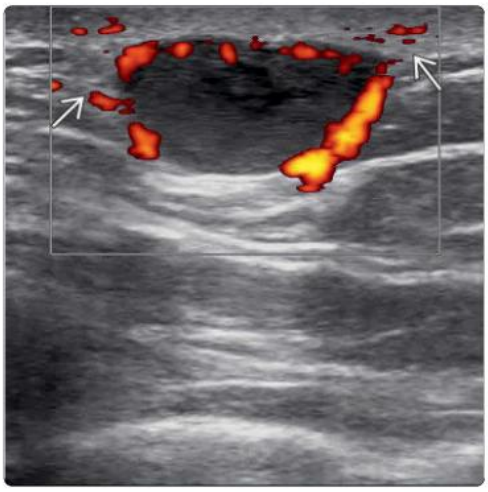

(Left) *Longitudinal US in a patient with an enlarging chest wall lump shows a slightly irregular hypoechoic subdermal mass with mildly angulated borders ➡. There is a small tract extending superficially into the dermis ➡.* **(Right)** *Transverse power Doppler US of the same lesion shows moderate peripheral and perilesional hyperemia. The overlying dermal tissue is echogenic due to edema ➡. Biopsy revealed features consistent with a ruptured epidermoid cyst and adjacent soft tissue inflammation.*

KEY FACTS

TERMINOLOGY

- Synonym: Calcifying epithelioma of Malherbe, pilomatrixoma, trichomatricoma
- Definition: Benign skin tumor arising from cells of hair matrix

IMAGING

- Head & neck most common (60%), followed by upper extremities (25%), trunk (10%), & lower extremities (5%)
- Well-circumscribed, ovoid, heterogeneous, solid subdermal mass containing matrix calcification, intrinsic vascularity, & peripheral hypoechoic rim
- Mass extending from dermal to subcutaneous tissues
- Ovoid (80%), round (10%), or irregular (10%)
- Hypoechoic (70%), isoechoic (15%), or hyperechoic (5%) to subcutaneous fat, heterogeneous (10%)
- Internal hyperechoic foci/reticulation due to matrix calcification (93%)
- Scattered dots (most common), lump- or arc-like calcific deposits (less common), may be completely calcified (uncommon)
- Hypoechoic peripheral rim due to connective tissue capsule (80%)
- Intrinsic vascularity (60%)
- Capsular rupture can lead to peritumoral inflammation
- US appearances are sufficiently specific to make diagnosis in majority of cases

TOP DIFFERENTIAL DIAGNOSES

- Epidermoid cyst
- Hemangioma

CLINICAL ISSUES

- Most present in children but can present at any age
  - 2nd most commonly excised superficial tumor after epidermoid cyst in children
- Treatment is surgical excision

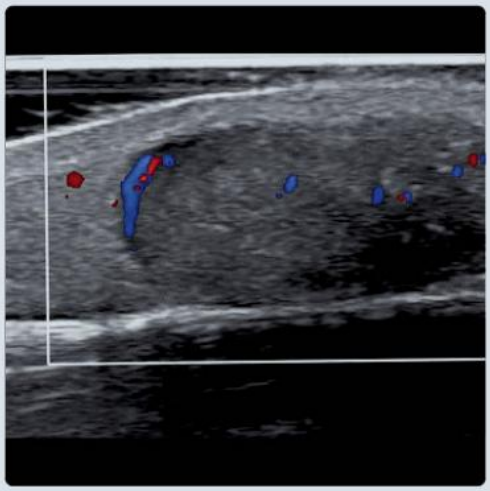

(Left) *Longitudinal US shows a well-defined, ovoid hypoechoic pilomatricoma in the subcutaneous tissue of the forearm in an adult patient. There are multiple scattered fine echogenic dots ⇨ within the lesion. Note the peripheral hypoechoic rim representing connective tissue capsule ⇨ and minimal to mild posterior acoustic shadowing ⇨.* **(Right)** *Longitudinal color Doppler US of the same lesion shows combined peripheral and central vascularity.*

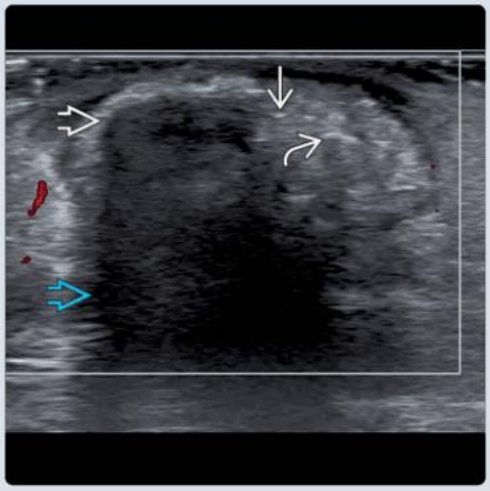

(Left) *Transverse US shows a pilomatricoma in the subdermal tissue of the posterior arm region in a 10-year-old girl. The mass contains multiple fine echogenic dots ⇨ and slightly larger arc calcifications ⇨. Note mild posterior shadowing ⇨.* **(Right)** *Transverse color Doppler US shows a pilomatricoma in a 9-year-old girl. The mass is heterogeneous with mixed areas of fine ⇨, clump ⇨, and arc ⇨ calcifications. No intrinsic hyperemia is present. Note strong posterior acoustic shadowing ⇨.*

TERMINOLOGY

Synonyms

- Calcifying epithelioma of Malherbe
- Pilomatrixoma
- Trichomatricoma

Definitions

- Benign skin tumor arising from cells of hair matrix

IMAGING

General Features

- Best diagnostic clue
  - Well-circumscribed subdermal mass lesion with heterogeneous echotexture, internal calcification, vascularity, & peripheral hypoechoic rim
- Location
  - Head & neck, especially cheek (60%), upper extremities (25%), trunk (10%), lower extremities (5%)
- Size
  - < 1 cm to 5 cm; mean diameter: 1.4 cm
- Morphology
  - Well-circumscribed, partially calcified mass located between deep dermis & subcutaneous tissues

Radiographic Findings

- Visibility dependent on degree of tumoral calcification

CT Findings

- Nonspecific soft tissue attenuation mass in subcutaneous tissue ± calcification ± mild to moderate enhancement

MR Findings

- T1WI intermediate to low, T2WI heterogeneously hyperintense, no restricted diffusion
- Calcification → low-signal foci
- Mild to moderate contrast enhancement

Ultrasonographic Findings

- Well-circumscribed mass extending from deep dermis to subcutaneous tissues
- Ovoid (80%), round (10%), or irregular (10%) in shape
- Hypoechoic (70%), isoechoic (15%), or hyperechoic (5%) to subcutaneous fat, heterogeneous (10%)
- Internal hyperechoic calcific foci (95%)
  - Scattered dots (most common), clump- or arc-like calcific deposits or complete calcification
  - Scattered dots more common in more recent lesions; arcs & clumps more common in chronic lesions
- Hypoechoic peripheral rim (80%) due to capsule
- Intrinsic vascularity (60%): Peripheral, central, or combined peripheral & central
- ± posterior shadowing (60%)
  - Severity depends on calcification & chronicity
- ± surrounding hyperechogenicity due to peritumoral inflammation from capsular rupture

Imaging Recommendations

- Best imaging tool
  - US
- Protocol advice
  - Assess shape, echotexture, calcification, rim, margin, posterior shadowing, & vascularity

DIFFERENTIAL DIAGNOSIS

Epidermoid Cyst

- Linear seed-like internal echogenic strands ± posterior enhancement
- No intrinsic vascularity unless ruptured

Hemangioma

- Fatty stroma with vascular channels ± phleboliths

Trichilemmal Cyst

- Posterior enhancement, less calcification & hypoechoic rim

PATHOLOGY

General Features

- Etiology
  - Usually sporadic, not familial
- Genetics
  - 75% with mutations in β-catenin gene (*CTNNB1*)
  - Associations: Gardner syndrome, familial adenomatous polyposis, & Turner syndrome

Gross Pathologic & Surgical Features

- Basaloid proliferation of hair matrix cells
- Maturation to structureless anucleate eosinophilic cells called shadow cells in differentiation toward hair cortex
- Calcification occurs in shadow cells or stroma
- ± histiocytic multinucleate infiltrate at site of rupture

CLINICAL ISSUES

Presentation

- Most common signs/symptoms
  - Slow-growing, hard, subcutaneous mass ± localized inflammation ± skin discoloration
- Other signs/symptoms
  - Usually solitary, though multiple in up to 10%

Demographics

- Age
  - Particularly prevalent in children, typically first 2 years of life, though can present at any age
- Sex
  - Slight female predominance (F:M = 1.6:1)
- Epidemiology
  - 2nd most commonly excised superficial lump after epidermoid cyst in children

Natural History & Prognosis

- Spontaneous regression does not occur
- Malignant pilomatricoma (seen in adults) is exceedingly rare

Treatment

- Surgical excision

SELECTED REFERENCES

1. Zhu H et al: Integrating vascularity into the pattern classification of pilomatricomas on ultrasound provides a more competent approach for discriminative evaluation. Skin Res Technol. 30(2):e13585, 2024

(Left) *Transverse graphic shows the epidermis, dermis, and subcutaneous fat. The hair follicle, sebaceous gland, and matrix of the hair follicle bulb from which pilomatricoma arise are shown. A sweat gland is also depicted.* **(Right)** *Longitudinal US shows a pilomatricoma, which is iso- to slightly hypoechoic to the surrounding subcutaneous tissue with scattered dots and arcs representing calcifications and mild posterior shadowing. A hypoechoic peripheral rim is faintly visible.*

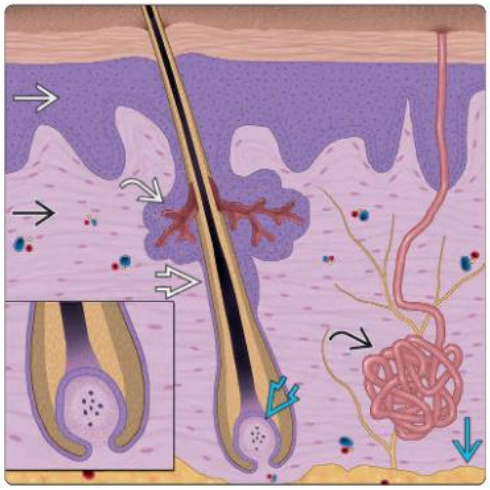

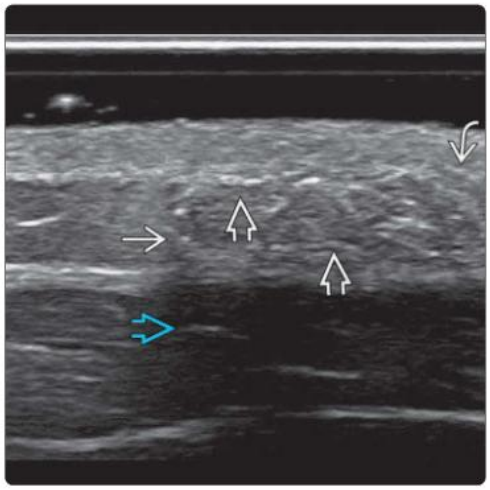

(Left) *Longitudinal US shows a slightly lobulated hypoechoic pilomatricoma in the leg. The mass has a discrete peripheral hypoechoic rim and strong posterior shadowing due to more severe internal matrix calcification when compared to the previous image.* **(Right)** *Transverse color Doppler US of the same lesion shows mild capsular vascularity. The mass is in close contact with the dermis and is causing mild dermal bulging.*

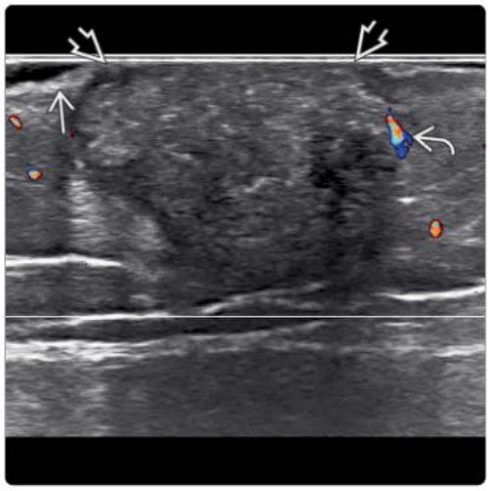

(Left) *Transverse US in a 13-year-old boy shows a well-defined, ovoid pilomatricoma in the cheek. The mass is hypoechoic to subcutaneous fat and contains areas of both arc- and clump-like calcification. Dense posterior acoustic shadowing is present.* **(Right)** *Longitudinal US shows an ill-defined pilomatricoma slightly hyperechoic to the adjacent subcutaneous. It contains fine internal calcification, moderate intrinsic vascularity, and mild posterior shadowing. Pilomatricoma with an ill-defined border is uncommon.*

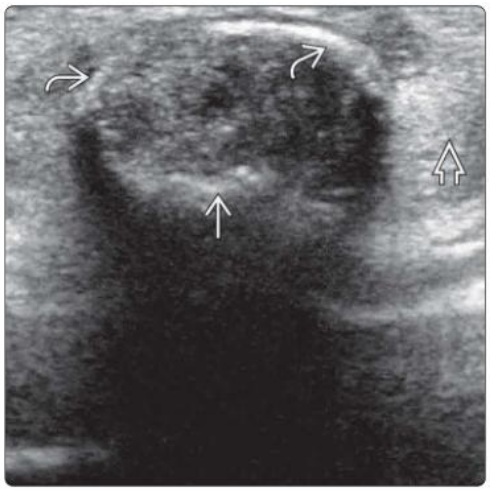

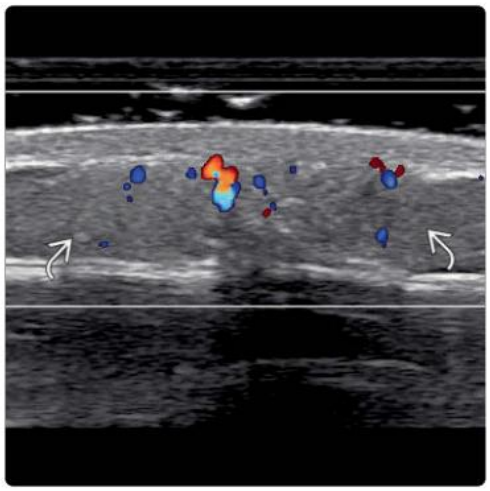

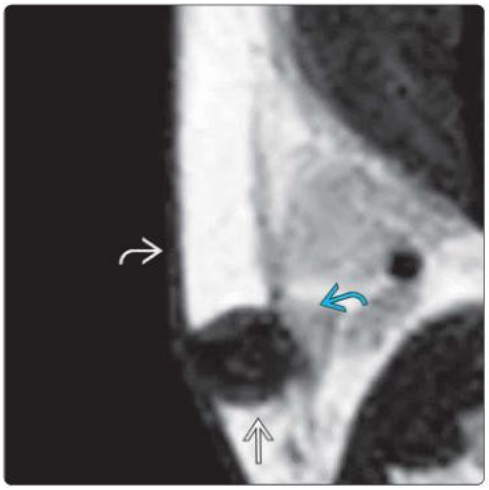

(Left) *Transverse US in a 14-year-old boy who presented with a hard retroauricular mass shows a densely calcified nodule in the subcutaneous tissue casting dense posterior shadowing.* **(Right)** *Axial T2 MR in the same patient shows a round, markedly hypointense nodule in the subcutaneous tissue. The mass is in contact with the dermis and parotid gland. The diffuse low signal intensity is due to internal calcification. Pathology revealed a pilomatricoma comprising mainly shadow cells with dystrophic calcification.*

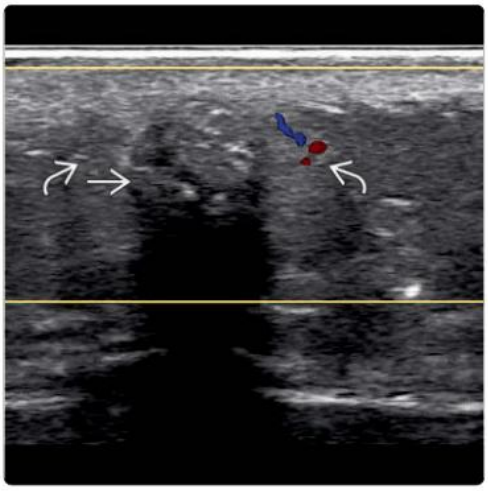

(Left) *Transverse US shows a rounded, calcified mass with posterior shadowing in the shoulder of a 9-year-old girl. The subcutaneous fat adjacent to the tumor is slightly more hyperechoic with hyperemia. Histology revealed pilomatricoma with peripheral foreign body reaction.* **(Right)** *Longitudinal US in 10-year-old boy with an enlarging protuberant arm mass shows a lobulated tumor with internal calcification, peripheral hypoechoic rim, and peritumoral hyperechogenicity.*

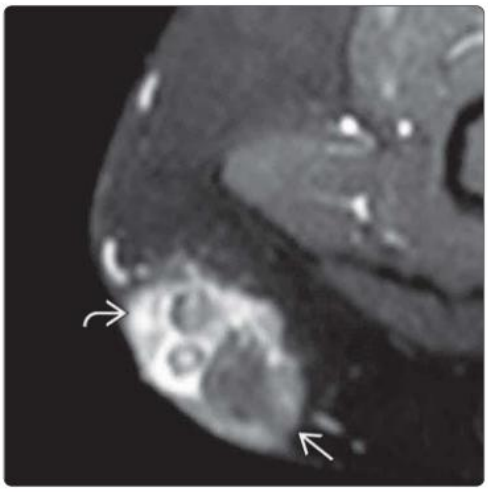

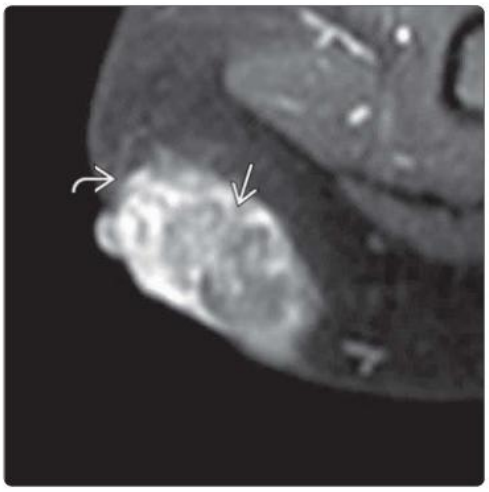

(Left) *Axial T2 FS MR of the same lesion shows a predominantly hypointense subdermal mass. There is a T2-hyperintense rim in the soft tissues on the lateral aspect of the lesion.* **(Right)** *Axial T1 C+ FS MR of the same lesion shows mild tumoral enhancement and moderate peritumoral enhancement. The peritumoral T2 hyperintensity and enhancement represent peritumoral inflammation related to foreign body reaction or capsular leakage.*

KEY FACTS

TERMINOLOGY

- Low-grade spindle cell mesenchymal sarcoma of dermis & subcutaneous tissues

IMAGING

- Most common site is trunk (60%) followed by limbs (30%)
- Dermal-subcutaneous location more common (90%) than dermal (5%)
  - Uncommonly, primary subfascial location
- Protruding mass arising from skin with bluish or reddish discoloration
- Hypoechoic (70%), mixed (30%)
  - Deep tentacles or jellyfish pattern (55%)
  - Lobulated (20%)
  - Irregular (20%)
  - Plaque-like (5%)
- Variable morphologies may represent progressive growth stages with coalescence of jellyfish-like tentacles or, alternatively, different growth patterns
- Fine echogenic speckles & posterior enhancement (100%)
- ± hypoechoic extension along dermal-subdermal interface (claw sign)
- Usually mild to moderate peripheral > central hyperemia (60%) but may have no hyperemia (30%) or severe hyperemia (10%)
- Local recurrence may need to be differentiated from postresection scar
  - Scar tends to be more well defined & more homogeneously hypoechoic with little or no hyperemia
- If suspected on clinical & US grounds → biopsy to confirm

TOP DIFFERENTIAL DIAGNOSES

- Malignant skin lesions: Metastasis or cutaneous lymphoma

CLINICAL ISSUES

- Slowly growing, evolving dermal-subcutaneous mass
  - Nononcological initial excision not uncommon
- Uncommonly (10%) separated & synchronous

(Left) *Clinical photograph shows a mass protruding from the skin ⇨ through a narrower stalk with red skin discoloration ⇨. This is typical of a dermatofibrosarcoma protuberans (DFSP). No ulceration is present.* **(Right)** *Transverse US of the same lesion shows the typical DFSP as a well-defined hypoechoic nodule arising from dermis. Small hyperechoic speckles ⇨ and posterior acoustic enhancement ⇨ are seen. An eccentric hypoechoic area ⇨ and a claw-like extension are seen at the dermal-subdermal interface ⇨.*

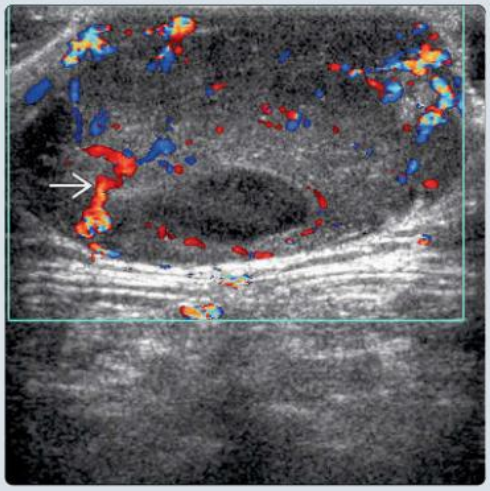

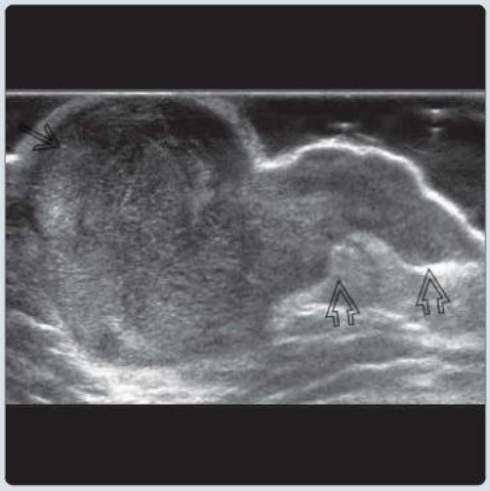

(Left) *Transverse color Doppler US of the same lesion shows moderate central and peripheral vascularity ⇨.* **(Right)** *Transverse US of a histologically proven DFSP ⇨ of the anterior abdominal wall in a middle-aged woman shows thick, finger-like tumoral extensions ⇨ at the dermal-subdermal interface.*

TERMINOLOGY

Abbreviations

- Dermatofibrosarcoma protuberans (DFSP)

Definitions

- Low-grade spindle cell mesenchymal sarcoma of dermis & subdermis

IMAGING

General Features

- Best diagnostic clue
  - Nearly always arises in dermis, then infiltrates subcutaneous tissue
- Location
  - 60% trunk
  - 30% limbs, > proximal part of limbs, > lower limb
  - 10% head & neck
  - Synchronous tumors can occur uncommonly (10%)
- Size
  - Ranges from 1 cm to > 25 cm; averages 3 cm at time of excision
- Morphology
  - Protruding mass arising from skin with bluish or reddish discoloration

Ultrasonographic Findings

- Dermal-subcutaneous (90%)
  - Dermal (5%)
  - Uncommonly arise in deep subfascial tissues (< 5%)
- Hypoechoic (70%), mixed (30%)
  - 4 patterns
    - Deep tentacles or jellyfish pattern (55%)
    - Lobulated (20%)
    - Irregular (20%)
    - Plaque-like (5%)
  - Variable morphologies may represent progressive growth stages with coalescence of jellyfish-like tentacles or, alternatively, different growth patterns
- Fine echogenic speckles (80%) & posterior enhancement (100%)
- ± hypoechoic extension along dermal-subdermal interface (claw sign)
- Color Doppler findings variable
  - Usually mild to moderate peripheral > central hyperemia (60%) but may have no hyperemia (30%) or severe hyperemia (10%)
- Local recurrence may need to be differentiated from postresection scar
  - Scar tends to be more well defined & homogeneously hypoechoic with little or no hyperemia

CT Findings

- Usually well defined with distinct lobular or nodular architecture
- Attenuation equal to or slightly higher than that of skeletal muscle
- Central cystic component (myxoid degeneration, necrosis, or hemorrhage) uncommon
- No calcification, moderate contrast enhancement

MR Findings

- Isointense to hyperintense relative to muscle on T1WI
- Hyperintense relative to muscle on T2WI

Imaging Recommendations

- Best imaging tool
  - US is helpful to characterize tumor type as well as assess degree of local infiltration

DIFFERENTIAL DIAGNOSIS

Malignant Skin Lesions

- Metastasis or cutaneous lymphoma
  - More infiltrative appearance

PATHOLOGY

Gross Pathologic & Surgical Features

- Indurated plaque or nodule involving dermis & subcutaneous layers with firm, gray-white cut surface
  - Tumor infiltration from dermis tends to be asymmetrical with frond-like horizontal or vertical extensions into subcutaneous fat

Microscopic Features

- Uniform, spindle-shaped cells arranged in storiform pattern
- Morphologic variants: Pigmented, myxoid, granular cell, sclerosing, atrophic
- Fibrosarcomatous differentiation: ~ 10%

CLINICAL ISSUES

Presentation

- Most common signs/symptoms
  - Slowly growing, evolving cutaneous mass
    - Starts as small nodule, grows into medium-sized erythematous or bluish lesion
    - Ulceration & satellite nodules in advanced lesions
    - Occasionally, plaque-like indurated region progressing to single or multiple protuberant nodules

Demographics

- Age
  - Infancy → middle-aged adults; peak in 3rd-5th decades
- Sex
  - Female predominance
- Epidemiology
  - Most common primary cutaneous-subcutaneous sarcoma

Natural History & Prognosis

- Local recurrence in 10-50%, depending on completeness of initial excision & fibrosarcomatous transformation
- Metastases is rare

Treatment

- En bloc resection with wide local excision (≥ 3-cm margin)

SELECTED REFERENCES

1. Gong X et al: Conventional and contrast-enhanced ultrasound in the differential diagnosis of recurrent dermatofibrosarcoma protuberans and postoperative scar. BMC Cancer. 24(1):285, 2024
2. Whittle C et al: Different sonographic presentations of dermatofibrosarcoma protuberans. J Ultrasound. 27(1):61-5, 2024

(Left) *Transverse US of a histologically proven DFSP shows a quite well-defined protruding nodule ➡ from the umbilicus with peripheral extension at the dermal-subdermal interface ➡ as well as at the linea alba ⇨.* **(Right)** *Transverse US of the shoulder of a middle-aged woman shows a quite well-defined hypoechoic mass ➡ with an irregular border arising in the subcutaneous layer in contact with the dermis. This histologically proven DFSP is atypical with small, central punctate calcific foci ⇨.*

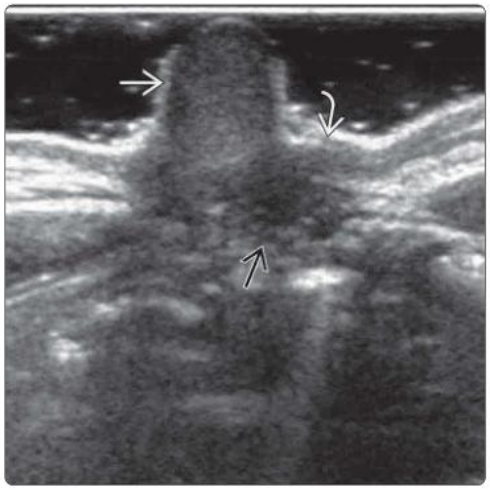

(Left) *Transverse US of the chest wall of a middle-aged man shows a dermal-subdermal mass typical of DFSP with tiny hyperechoic foci ➡ and central, small, irregular, cleft-like hypoechoic areas ➡.* **(Right)** *Transverse color Doppler US of the same tumor shows both peripheral vascularity ➡ and inwardly radiating central vascularity ➡.*

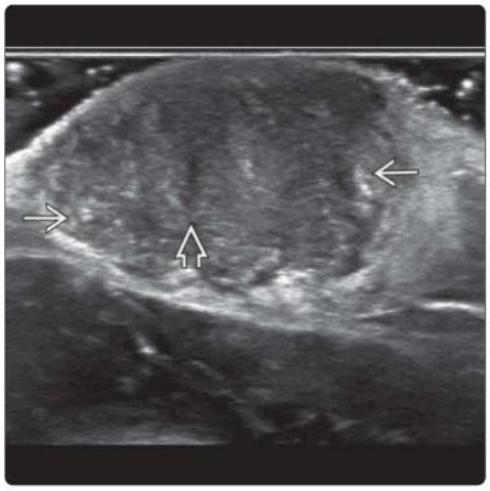

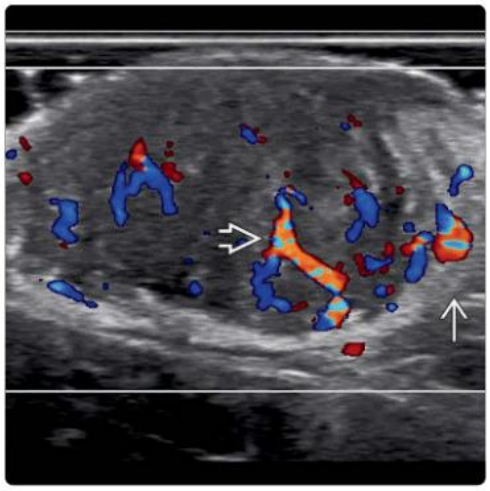

(Left) *Transverse US of a DFSP ➡ involving the dermal and subcutaneous regions is shown. The hypoechoic lesion is ill defined with posterior acoustic enhancement ⇨. There are small speckles ➡ with a hypoechoic cleft ➡.* **(Right)** *Transverse color Doppler US of the same lesion shows quite high, predominantly peripheral vascularity ➡.*

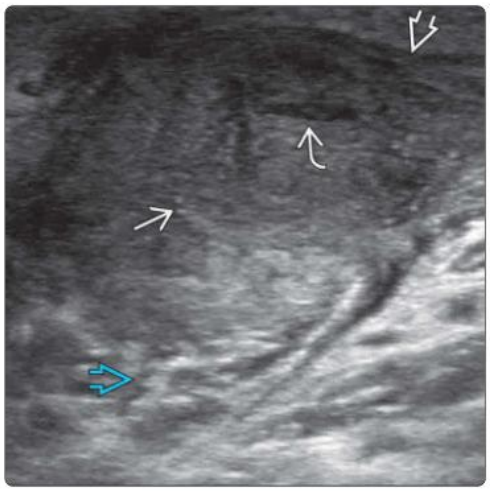

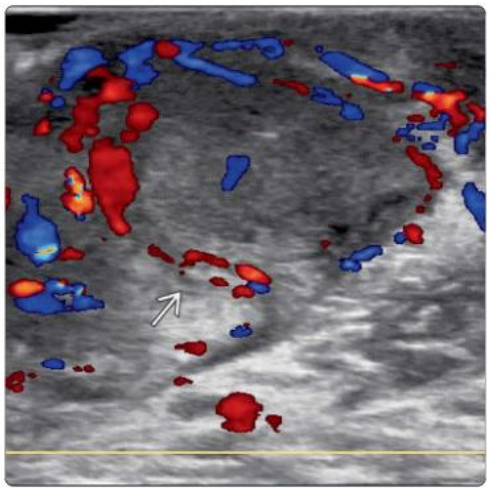

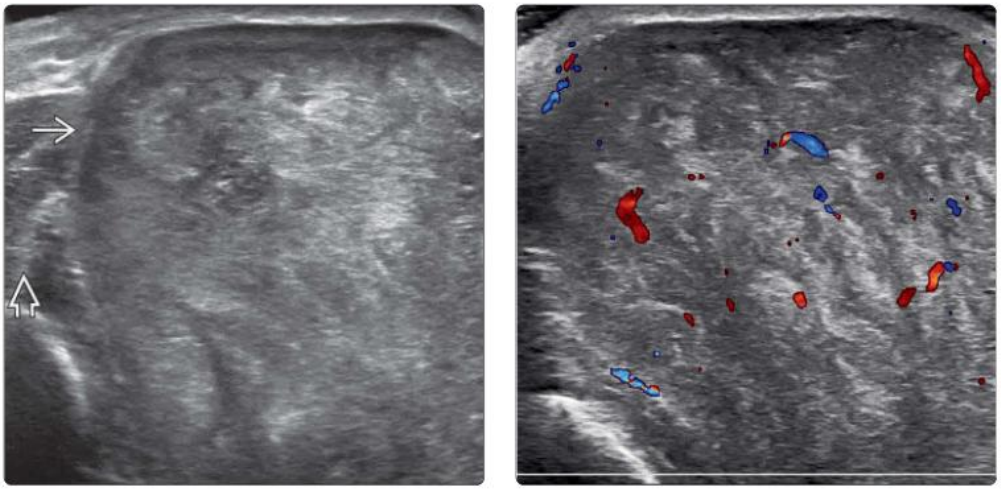

(Left) *Transverse US of a middle-aged male patient shows a large (8.4 cm wide x 5.3 cm deep x 8.5 cm long) mildly heterogeneous subcutaneous tumor ➡ on the anteromedial medial aspect of the arm. The biceps brachii muscle ➡ is displaced medially. Histology from a US-guided percutaneous biopsy revealed a DFSP.* **(Right)** *Color Doppler US of the same lesion shows mild to moderate central vascularity. These US appearances with a very large mass are atypical for a DFSP.*

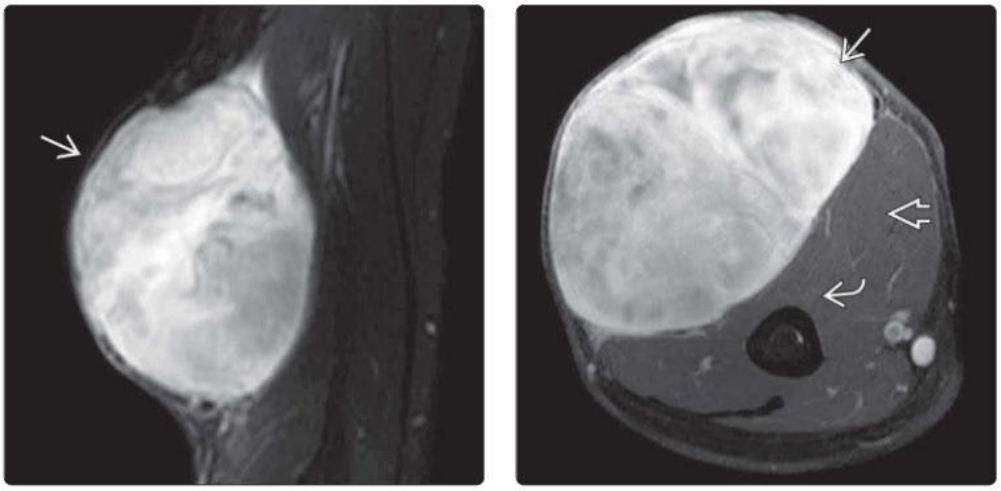

(Left) *Sagittal T2 FS MR in the same patient shows the large tumor ➡ to be well defined with heterogeneous T2-hyperintense signal. The tumor is confined to the subcutaneous tissue indenting the underlying muscles.* **(Right)** *Axial T1 C+ FS MR in the same patient shows the tumor to be avidly enhancing ➡. The biceps brachii ➡ and brachialis ➡ muscles are displaced medially with loss of intervening fat plane but no definite intramuscular extension. The tumor was completely excised with no recurrence within 5 years.*

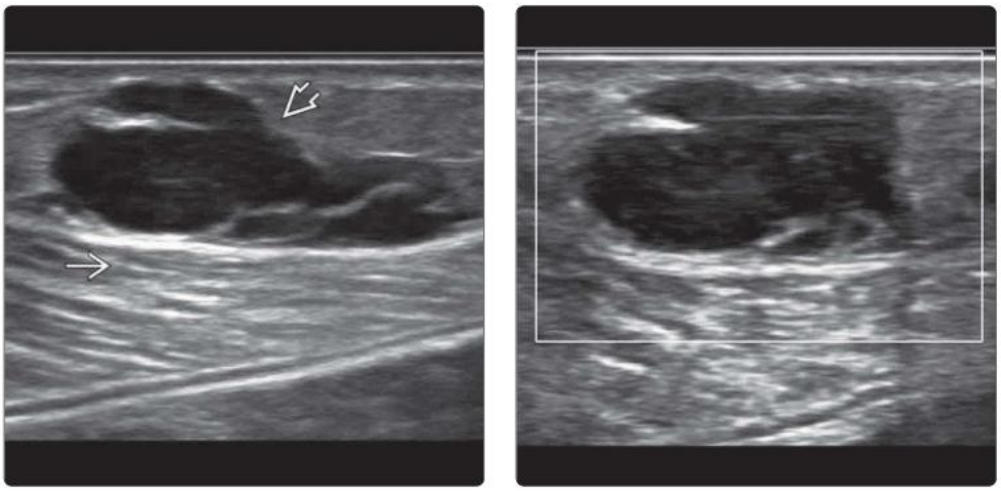

(Left) *Transverse US shows an atypical appearance of a DFSP ➡ in a 76-year-old woman with calf swelling. The lesion is very hypoechoic, well defined, and lobulated with moderate posterior acoustic enhancement ➡. Initially, this was considered to be a fibrous tumor, plexiform neurofibroma, or thrombosed venous-type malformation. Histology following US-guided biopsy revealed a rare myxoid variant of a DFSP.* **(Right)** *Transverse color Doppler US of the same tumor shows absence of vascularity.*

KEY FACTS

TERMINOLOGY

- Benign solitary smooth muscle neoplasm that most commonly occurs in subcutaneous tissues of lower extremities

IMAGING

- 2/3 located at lower leg or ankle
- Majority are < 2 cm in diameter & subcutaneous
- Well defined & ovoid or roundish
- Hypoechoic with no perceivable capsule
- Mild to moderate posterior enhancement
- Occurs in close proximity to artery or vein
- Moderate > poor > rich vascularity
  - Peripheral vascular convergence (60%)
- Capillary-type most likely to be isoechoic with poor vascularity
- Atypical features are calcification, fat, myxoid area, & hemorrhage

TOP DIFFERENTIAL DIAGNOSES

- Peripheral nerve sheath tumor

PATHOLOGY

- Arises from tunica media of small arteries or veins
  - Capillary, venous > cavernous-type

CLINICAL ISSUES

- Often painful or tender
- Most commonly present in middle age
- Slight female predominance

DIAGNOSTIC CHECKLIST

- Very similar to small peripheral nerve sheath tumors, which do not necessarily possess thickened entering or exiting nerves
  - If it looks like nerve sheath tumor, but does not have entering or exiting nerve, consider vascular leiomyoma, particularly if located in lower leg or ankle

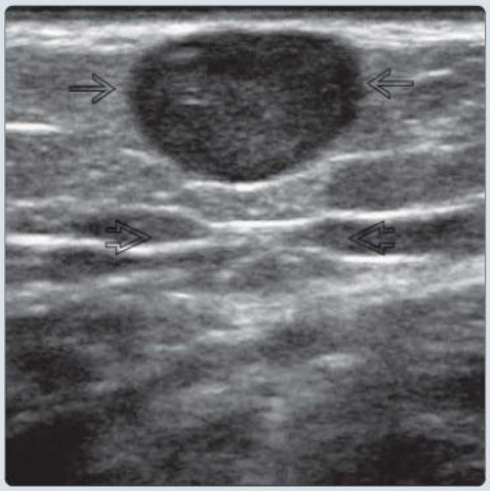

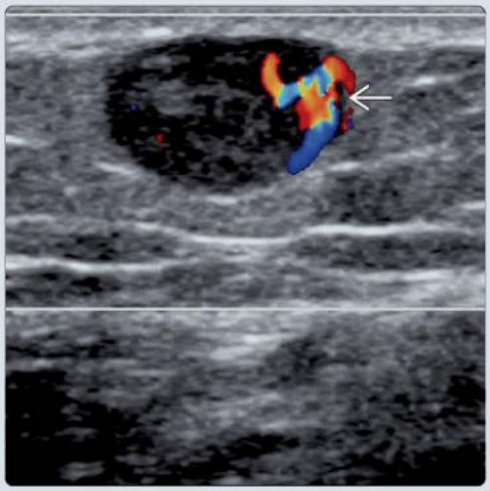

(Left) *Transverse US of the thigh shows the typical appearance of a vascular leiomyoma* ⇨ *with a well-defined, hypoechoic, oval-shaped mass located in the superficial subcutaneous and deep dermal layers of the lower limb. There is mild posterior acoustic enhancement* ⇨. **(Right)** *Transverse color Doppler US of the same lesion shows peripheral vascularity* ⇨ *within the lesion with vessels converging to a single point (vascular convergence).*

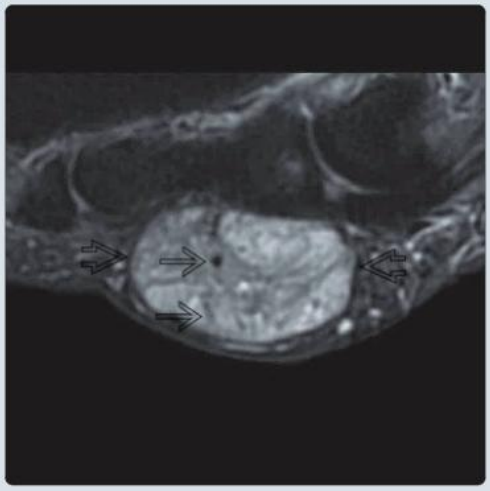

(Left) *Longitudinal US of the plantar aspect of the big toe shows a histologically confirmed vascular leiomyoma* ⇨ *with moderate posterior acoustic enhancement* ⇨. *Central hypoechoic foci* ⇨ *correspond to vascular channels, which is a feature of vascular leiomyoma.* **(Right)** *Sagittal T2 FS MR of the same lesion* ⇨ *shows intratumoral hypointense areas* ⇨ *corresponding to the US findings due to vascular channels. Vascular leiomyomas are typically T1 hypointense & T2 hyperintense with marked enhancement.*

TERMINOLOGY

Synonyms

- Angioleiomyoma, angiomyoma

Definitions

- Well-circumscribed tumor composed of cytologically bland smooth muscle cells showing concentric growth around vascular channels of varying caliber

IMAGING

General Features

- Location
  - Any location; 2/3 occur around lower leg or ankle
  - Lower leg & ankle > thigh > upper extremity > head & neck > trunk
  - Subcutaneous > dermal, rarely in deep soft tissue
- Size
  - Majority < 2 cm in diameter
- Morphology
  - Usually roundish or ovoid in shape

Ultrasonographic Findings

- Grayscale ultrasound
  - Most have well-defined margin
  - Long axis parallel to extremity axis
  - Hypoechoic, majority homogeneous
  - No perceivable capsule
  - Mild to moderate posterior acoustic enhancement
  - Close proximity to vessels
  - ± calcification
- Color Doppler
  - Moderate vascularity 40%; poor vascularity (35%); rich vascularity (25%)
    - Peripheral vascular convergence (60%)
      - Alternatively, scattered vessels or single vessel transgressing tumor

CT Findings

- Well-defined mass with similar attenuation to muscle
- ± calcification

MR Findings

- T1WI
  - Isointense to mildly hyperintense to muscle
- T2WI
  - Heterogeneously hyperintense to muscle
- T1WI C+
  - Variable enhancement depending on subtype

Imaging Recommendations

- Best imaging tool
  - US: Can usually either allow specific diagnosis or at least limit list of differential diagnoses

DIFFERENTIAL DIAGNOSIS

Benign Peripheral Nerve Sheath Tumor

- Neural continuity in 50%
- More prominent myxoid areas, chaotic vascular pattern

PATHOLOGY

General Features

- Etiology
  - Benign smooth muscle neoplasm that arises from tunica media of arteries or veins
- Genetics
  - No consistent chromosomal abnormality

Gross Pathologic & Surgical Features

- Solitary, pseudoencapsulated, gray-white to brown mass

Microscopic Features

- Mass composed of medium-sized, thin-walled, venous-like vessels & thick-walled, arterial-like vessels that lack most typical features of veins or arteries
  - Walls of these tumoral vessels merge imperceptibly with proliferative mass of benign smooth muscle
- Absent or infrequent mitoses
- 3 broad histologic subtypes (capillary, venous > cavernous)
  - Capillary type most likely to be isoechoic with poor vascularity
- ± myxoid areas, calcification, hemorrhage, or fat

CLINICAL ISSUES

Presentation

- Most common signs/symptoms
  - Often (> 50%) painful or tender
    - Symptoms are affected by light touch, temperature, or hormonal change
    - Upper extremity lesions less likely to be painful than lower extremity lesions
  - Grows slowly over several years

Demographics

- Age
  - Any but most common in middle-aged adults
- Sex
  - F:M = 1.7:1
- Epidemiology
  - Uncommon, ~ 5% of benign soft tissue tumors

Natural History & Prognosis

- No spontaneous regression

Treatment

- Complete marginal surgical excision

DIAGNOSTIC CHECKLIST

Image Interpretation Pearls

- Well-defined, small, hypoechoic vascular mass within subcutaneous tissue of lower extremity
  - Consider in same differential as small peripheral nerve sheath tumor without visible neural continuity

SELECTED REFERENCES

1. Göktürk Ş et al: Rapidly growing leiomyoma mimicking schwannoma of the saphenous nerve in the lower extremity: an unusual case report. J Musculoskelet Neuronal Interact. 24(3):325-9, 2024
2. Kulkarni A et al: Vascular leiomyoma of the thigh: classic presentation of a rare tumor with imaging and pathology correlation. Radiol Case Rep. 18(11):4071-5, 2023

(Left) *Longitudinal US in a 53-year-old man shows a medium-sized subcutaneous mass ⇨ superficial to the Achilles tendon. The mass is mildly hyperechoic with a central hypoechoic area ⇨ and prominent acoustic enhancement ⇨. No adjacent neural thickening is present.* **(Right)** *Color Doppler US of the same lesion shows moderate hyperemia. US diagnosis was either a vascular leiomyoma or nerve sheath tumor. Histologic diagnosis was a vascular leiomyoma.*

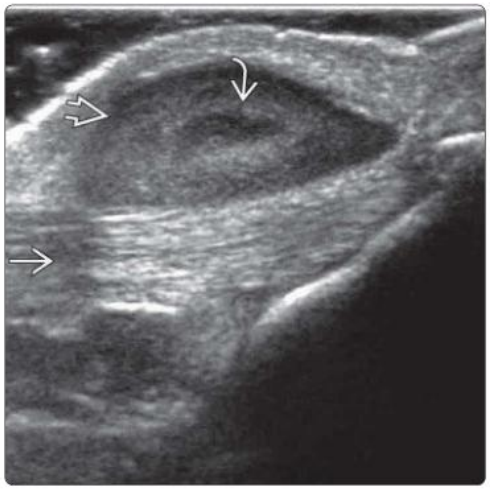

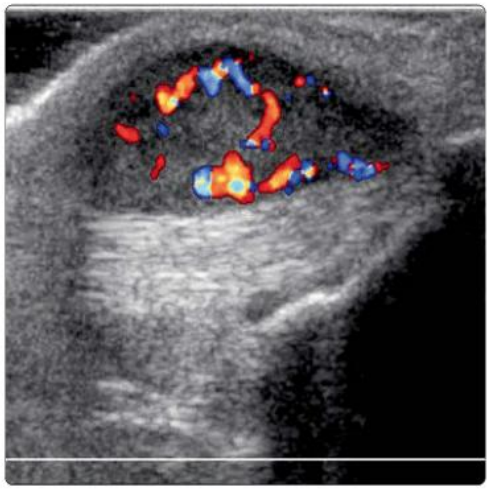

(Left) *Longitudinal US of the foot in a 51-year-old woman shows a medium-sized subcutaneous mass ⇨. The mass is hypoechoic with a central more hyperechoic area ⇨ with moderate acoustic enhancement ⇨.* **(Right)** *Color Doppler US of the same lesion shows moderate central hyperemia ⇨. US diagnosis was either vascular leiomyoma, nerve sheath tumor, or glomus tumor. Histologic diagnosis was vascular leiomyoma.*

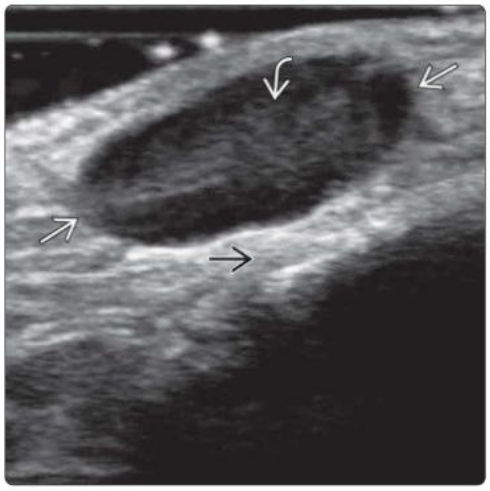

(Left) *Longitudinal US shows a subcutaneous vascular leiomyoma ⇨ in the forefoot with a typical hypoechoic echotexture, no visible capsule, and moderate posterior acoustic enhancement ⇨. The head of the 1st metatarsal bone ⇨ and flexor hallucis longus tendon ⇨ are shown.* **(Right)** *Longitudinal color Doppler US of the same lesion reveals mild vascularity with vessels tending to converge toward the periphery ⇨.*

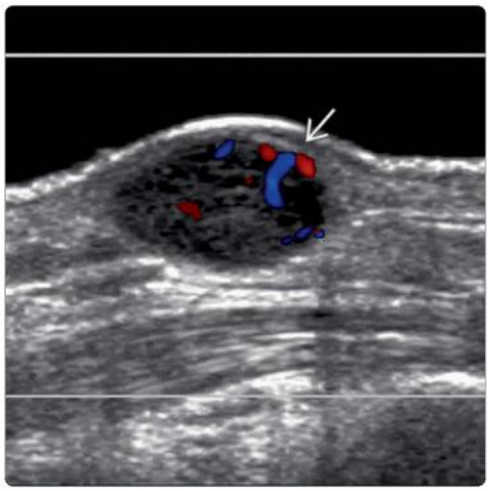

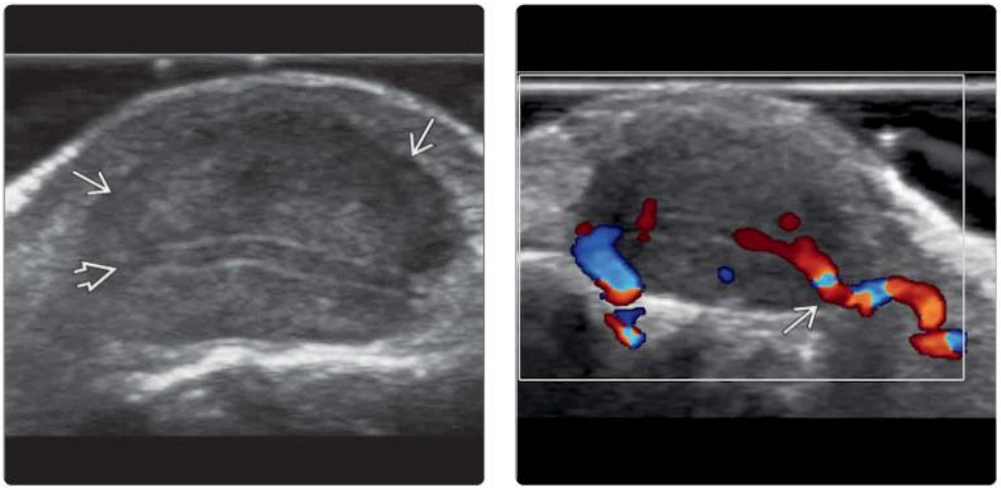

(Left) *Longitudinal US shows a well-defined subcutaneous mass on the dorsal aspect of the 4th toe ➡. The medial digital artery is seen as a tubular hypoechoic structure ➡ coursing through the center of the tumor.* **(Right)** *Longitudinal color Doppler US of the same lesion confirms the central tubular hypoechoic structure is the medial digital artery ➡. Histologic diagnosis was vascular leiomyoma.*

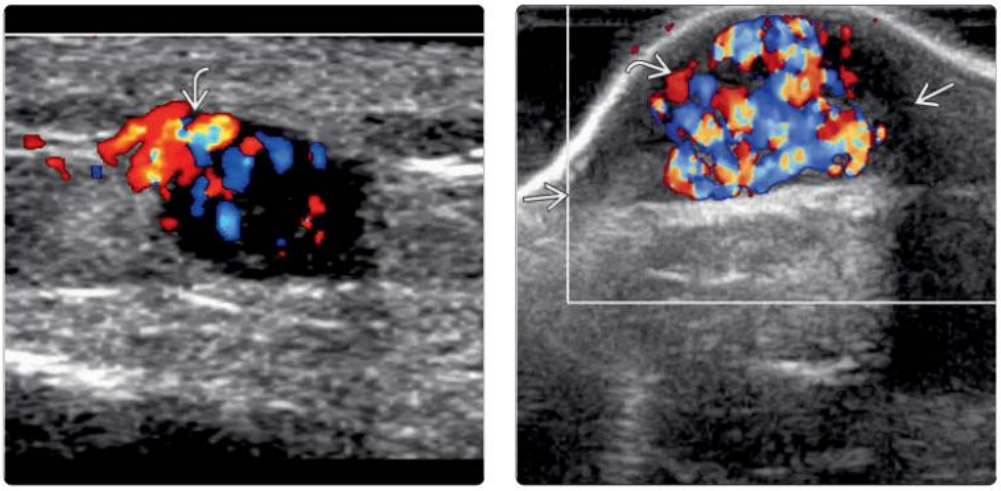

(Left) *Transverse color Doppler US of a subcutaneous vascular leiomyoma at the ankle reveals moderate peripheral and central vascularity and vascular convergence ➡ to a peripheral area.* **(Right)** *Transverse color Doppler US shows a subcutaneous vascular leiomyoma ➡ in the ankle region. It shows very high central and peripheral vascularity ➡.*

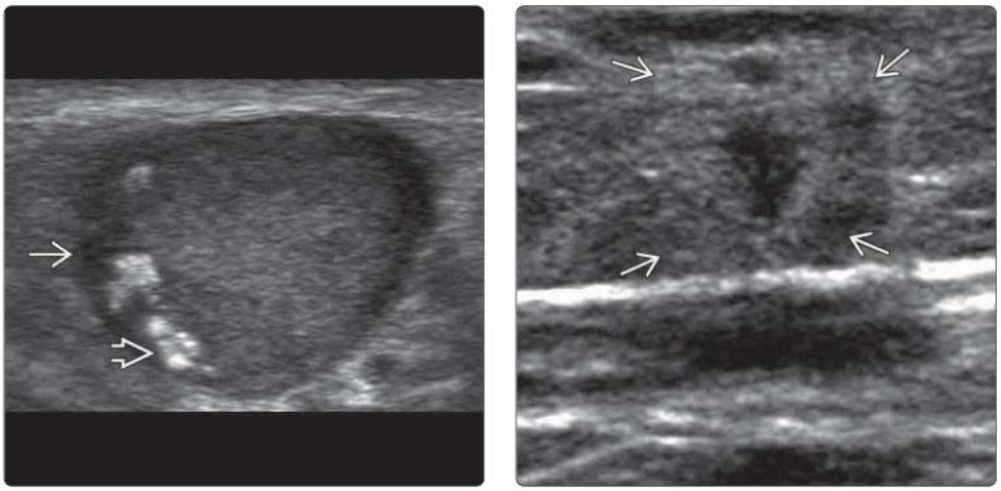

(Left) *Transverse US shows a 4.3-cm mass due to vascular leiomyoma ➡ within the subcutaneous tissues of the ankle. There is eccentric calcification ➡, which is an uncommon, though recognized, feature of vascular leiomyoma.* **(Right)** *Transverse US shows an atypical subcutaneous vascular leiomyoma ➡ in the ankle region. This histologically proven tumor has an ill-defined border with an echogenic lipomatous-like periphery.*

KEY FACTS

TERMINOLOGY

- "Superficial" refers to tissues above investing fascia

IMAGING

- Familiarity with imaging characteristics of recognizable superficial soft tissue tumors is key to recognizing malignant tumor
  - Best criterion of malignant superficial tumor (metastases, lymphoma, melanoma, etc.) is that appearance does not conform to recognized appearance of benign superficial tumor (lipoma, vascular anomaly, epidermoid cyst, etc.)
- Usually oval or round nodule with well-demarcated, irregular margin
- Melanoma metastases are often severely hypoechoic ± tail sign ± string sign
  - Melanoma metastases may be satellite, in-transit, interval nodal, regional nodal, or distant
- Peritumoral edema & intrinsic vascularity usually present
- Ill-defined thickening of dermis and subcutaneous tissue, cobblestone appearance, & hypervascularity in panniculitis-like T-cell lymphoma

PATHOLOGY

- 1.5% of superficial tumors are malignant
- 50% of these are metastatic
  - Most common (> 50%) from breast, lung, & melanoma
  - Adenocarcinoma (40%) > squamous cell carcinoma > melanoma
- Remaining 50% are lymphoma, primary sarcoma of superficial tissues
- 30% of lymphomas are extranodal
  - Involvement of superficial tissues is uncommon

CLINICAL ISSUES

- Superficial mass in patient with known malignancy is still more commonly benign than malignant
  - Superficial metastasis is 1st manifestation of malignancy in 0.8%

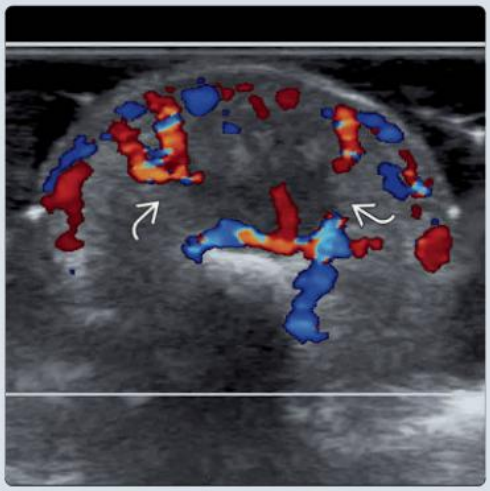

(Left) *Transverse US of the abdominal wall shows an irregular, hypoechoic, subcutaneous, metastatic deposit ⇨ in a patient with metastatic carcinoma of unknown primary. Note the surrounding soft tissue edema and posterior acoustic enhancement ⇨.* **(Right)** *Transverse US in a patient with known lung cancer and a painful lump in the index finger shows an irregular, hypoechoic mass ⇨ with hypervascularity in distal pulp of the index finger. Histology from excision biopsy revealed metastatic adenocarcinoma.*

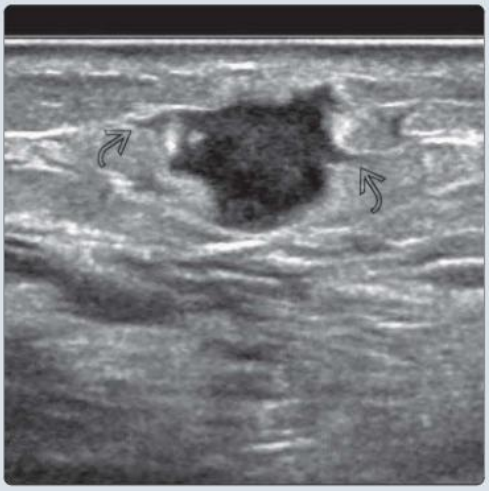

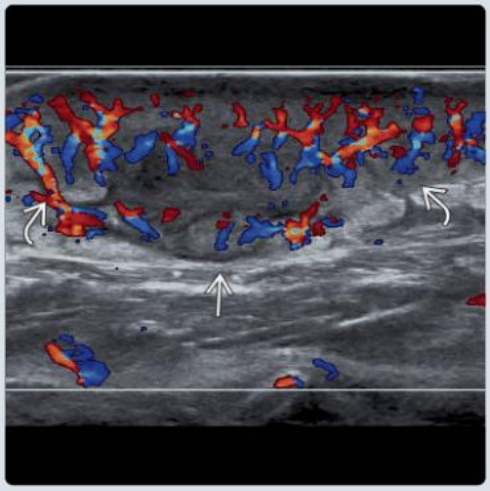

(Left) *Longitudinal US shows an in-transit, subcutaneous metastasis in the medial thigh region of a patient with melanoma in the ipsilateral foot. The tumor is irregular with hypoechoic tails ⇨ extending from the tumor ends, representing tumor spread along adjacent lymphatic channels (tail sign).* **(Right)** *Longitudinal US in a patient with primary B-cell lymphoma of the leg shows a localized area of dermal and subcutaneous tissue thickening ⇨ with severe organized hypervascularity. Note the investing fascia ⇨.*

TERMINOLOGY

Synonyms

- Superficial metastasis, skin metastasis, subcutaneous metastasis, secondary deposits, metastatic tumor

Definitions

- Spread of tumor from its primary site to skin or subcutaneous tissues
- "Superficial" refers to tissues above investing fascia (subcutaneous & cutaneous tissues)

IMAGING

General Features

- Best diagnostic clue
  - Hypoechoic, superficial soft tissue mass with intrinsic vascularity
- Location
  - Trunk (> 50%) > > head & neck > extremities
  - Melanoma metastasis within 2 cm of primary tumor = satellite metastasis
  - Melanoma metastasis at extranodal site > 2 cm from primary tumor = in-transit metastasis
- Size
  - Variable; mean: ~ 2 cm
- Morphology
  - Well-defined to infiltrative mass

Radiographic Findings

- Soft tissue swelling if large size or mass protuberant

CT Findings

- Isodense to hypodense to muscle; variable enhancement

MR Findings

- T1WI
  - Usually isointense to hypointense to muscle
    - Areas of T1 hyperintensity may be seen in melanoma due to paramagnetic effect of melanin & hemorrhage
- T2WI
  - Variable; homogeneous to heterogeneously hyperintense to hypointense to skeletal muscle
- T1WI C+
  - Variable enhancement; homogeneous, heterogeneous, nodular, or ring enhancement

Ultrasonographic Findings

- US appearance does not conform with known appearances of benign superficial tumors (e.g., lipoma, vascular anomaly, nerve sheath tumor, epidermoid cyst, etc.)
- Usually round or oval in shape
  - ± elongated tubular shape in melanoma due to tumor spreading along lymphatic channels
  - ± tail sign (2.5%) = thin, hypoechoic propagation from 1 or both poles of superficial melanoma metastasis
  - ± string sign (1%) = multiple in-transit lesions connected to each other like string of rosary beads
- Usually well-demarcated, irregular margin
- Most are hypoechoic
  - Severe hypoechogenicity is feature of melanoma due to poor beam reflectivity of melanotic tissue
- Can be homogeneous or heterogeneous in internal architecture
  - Similar to internal architecture of primary tumor
  - Cystic areas seen in melanoma, squamous cell metastases, other necrotic lesions, or myxoid deposits
  - Calcification from calcified or ossified primary tumor, such as osteosarcoma, medullary carcinoma of thyroid, or mucinous adenocarcinoma
- Mild to moderate intrinsic vascularity is usually present
  - Moderate to high intrinsic vascularity seen in metastases from hypervascular primary tumors, such as melanoma & renal cell carcinoma
- Mild to moderate peritumoral edema usually present
  - ± posterior enhancement or shadowing
- US is useful in assessing locoregional spread of melanoma
  - Primary melanoma tumors are uncommonly imaged
  - Satellite tumor: Tumor arising ≤ 2 cm from primary tumor or its scar
  - In-transit tumor: Tumor arising ≥ 2 cm from primary tumor or scar along lymphatic course toward regional lymphatic nodes
  - Interval lymph node metastases: Metastasis of lymph node along path from primary tumor to regional lymph node station, e.g., epitrochlear node or popliteal node
  - Regional lymph node metastasis: Ipsilateral inguinal group for lower limb melanoma, ipsilateral axillary group for upper limb melanoma
  - Distant cutaneous metastasis: Hematogenous metastasis to cutaneous or subcutaneous tissues
- Primary cutaneous lymphoma
  - 4 sonographic types: Nodular, pseudonodular, focal, & diffuse infiltrative
  - Thick dermis with no calcification, posterior artifact, or necrosis in most cases
  - Hypervascularity is usually present; more prominent in nodular & pseudonodular types
    - Degree of hypervascularity correlates positively with disease severity
  - Cutaneous T-cell lymphoma
    - Subepidermal low-echogenic band (SLEB), thickened dermis & epidermis, especially in mycosis fungoides
      - Disease severity → SLEB thickness ↑
    - Panniculitis-like T-cell lymphoma: Poorly defined, thickening of dermis & subcutaneous tissues, cobblestone appearance, & hypervascularity
  - Cutaneous B-cell lymphoma
    - Mostly nodular or pseudonodular appearances & hypervascular

Imaging Recommendations

- Best imaging tool
  - US
    - All superficial tumors are readily accessible to high-resolution US
    - Allows good definition of tumor characteristics
    - Most superficial soft tissue tumors can be diagnosed on imaging characteristics alone without need for histological confirmation
      - Suspected malignant tumor needs histological confirmation

  - Familiarity with imaging characteristics of recognizable superficial soft tissue tumors is key to recognizing malignant tumor
    - Best criterion of malignant superficial tumor is that appearance does not conform to recognized appearances of any benign tumor
  - US diagnosis is based not on 1 or 2 US signs, but on relative strength of multiple recognized US signs interpreted in conjunction with clinical presentation
- Protocol advice
  - US for assessment of superficial masses
    - Apply light transducer pressure to avoid compression or distortion of mass
      - Especially for color Doppler imaging to avoid blanching of tumoral vascularity
    - For melanoma, assess primary tumor site as well as for satellite tumor, in-transit tumor, regional nodes, & (when clinically suspect) distant cutaneous metastases
      - For primary in trunk, examine axillary, supraclavicular, infraclavicular, & deep pectoral nodes bilaterally
      - For primary in upper limb, examine ipsilateral epitrochlear, axillary, supraclavicular, infraclavicular, & deep pectoral nodes
      - For primary in lower limb, examine ipsilateral popliteal & bilateral groin & external iliac nodes
  - US-guided biopsy for histology
  - CT, PET/CT, or whole-body MR for systemic staging

DIFFERENTIAL DIAGNOSIS

Soft Tissue Sarcoma

- Uncommon in superficial tissues
- Usually > 5 cm
- Can look very similar to metastases
  - Epithelioid sarcoma mimics metastatic carcinoma histologically

Nerve Sheath Tumor

- Often visible entering & exiting nerve
  - Fusiform or oblong-shaped
  - Smooth border
- Plexiform neurofibroma can mimic panniculitis-like lymphoma

Reactive Lymph Node

- Fatty hilum, hilar vascularity

Hematoma

- Organizing hematoma can have variable hyperemia
- Interval resolution rather than progression

PATHOLOGY

General Features

- 1.5% of superficial soft tissue tumors referred for US examination are malignant
  - 50% of these are metastatic
  - Metastatic tumor cell type
    - Adenocarcinoma (40%) > squamous cell carcinoma & melanoma > sarcoma or carcinosarcoma
    - Primary tumor: Breast (> 50%) > lung > melanoma
  - 50% are nonmetastatic
    - Lymphoma, primary sarcoma of superficial tissues, such as dermatofibrosarcoma protuberans
  - Lymphoid malignancies are classified as T-cell neoplasms, B-cell neoplasms, & Hodgkin disease
    - Cutaneous lymphomas are B-cell & T-cell neoplasms that originate in skin
    - T-cell neoplasms are divided into precursor T-cell neoplasms & peripheral T-cell neoplasms
    - Subcutaneous panniculitis-like T-cell lymphoma is uncommon type of peripheral T-cell lymphoma
      - Can simulate severe focal subcutaneous cellulitis or autoimmune panniculitis
  - 30% of lymphomas are extranodal
    - Most common musculoskeletal involvement is to bone & muscle
    - Involvement of superficial tissues is uncommon
    - Most cases of superficial lymphoma have known systemic lymphoma
      - Rarely, lymphoma of superficial tissues may precede diagnosis of systemic lymphoma

CLINICAL ISSUES

Presentation

- Most common signs/symptoms
  - Superficial nodule
  - Often have history of known malignancy
    - Superficial mass in patient with known malignancy is still most commonly benign
    - Superficial metastases is 1st manifestation of occult malignancy in 0.8%
  - Superficial metastases are generally more painful than primary soft tissue sarcoma

Demographics

- Age
  - Any; mean: 53 years

Natural History & Prognosis

- Superficial metastases indicate stage IV disease regardless of primary tumor or location
  - 80% have metastatic deposits in other organs

Treatment

- Highly variable depending on site of primary tumor & degree of metastatic spread
- Wide local excision for surgical resection

DIAGNOSTIC CHECKLIST

Consider

- Superficial malignant tumor if US appearances do not conform to recognized appearances of benign tumor (e.g., lipoma, vascular anomaly, epidermoid cyst)
- Superficial mass in patient with known malignancy is still more commonly benign rather than malignant

SELECTED REFERENCES

1. Taleb E et al: Non-invasive skin imaging in cutaneous lymphomas. Am J Clin Dermatol. 25(1):79-89, 2024
2. Souza BCE et al: Cutaneous metastases from solid neoplasms - literature review. An Bras Dermatol. 98(5):571-9, 2023

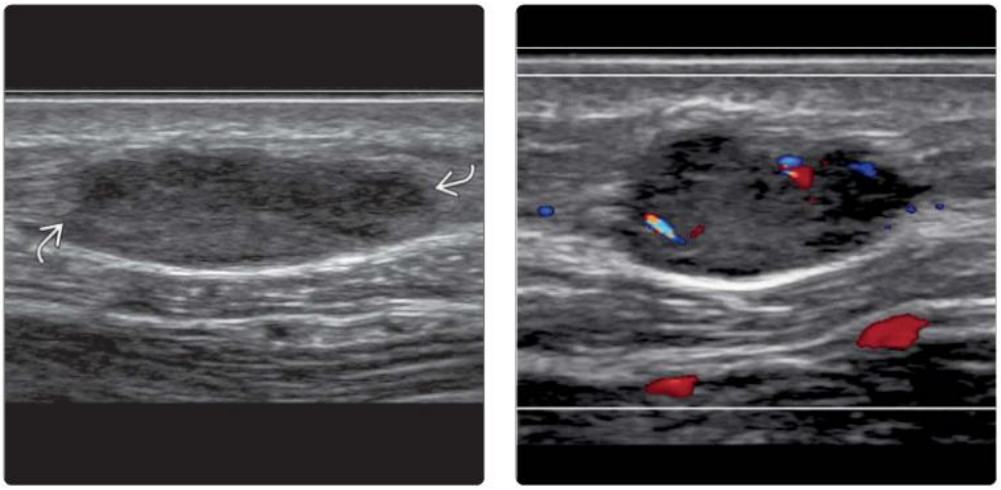

(Left) *Longitudinal US shows a slightly irregular, fusiform-shaped mass* ➡ *in the deep subcutaneous tissue of the chest wall in a patient with primary lung cancer.* **(Right)** *Transverse US of the same lesion shows mild intratumoral hypervascularity. The appearances do not conform to any specific benign entity. Histology from US-guided biopsy revealed metastatic adenocarcinoma from lung primary. Subcutaneous metastasis is most commonly of adenocarcinoma-cell type.*

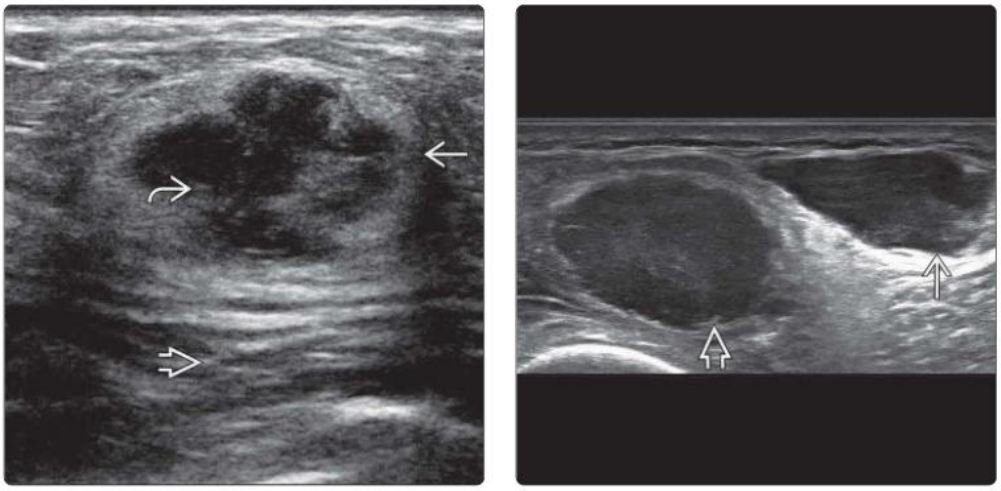

(Left) *Longitudinal US of the chest wall in a patient with high-grade conventional osteosarcoma of the distal femur shows an irregular, biopsy-proven, subcutaneous metastasis* ➡*. Note the anechoic cystic component* ➡ *and moderate posterior acoustic enhancement* ➡*.* **(Right)** *Transverse US of the thigh in a patient with known leg sarcoma shows slightly irregular, hypoechoic masses in the subcutaneous tissue* ➡ *and vastus medialis muscle* ➡ *of thigh. Most subcutaneous metastases are associated with metastasis elsewhere.*

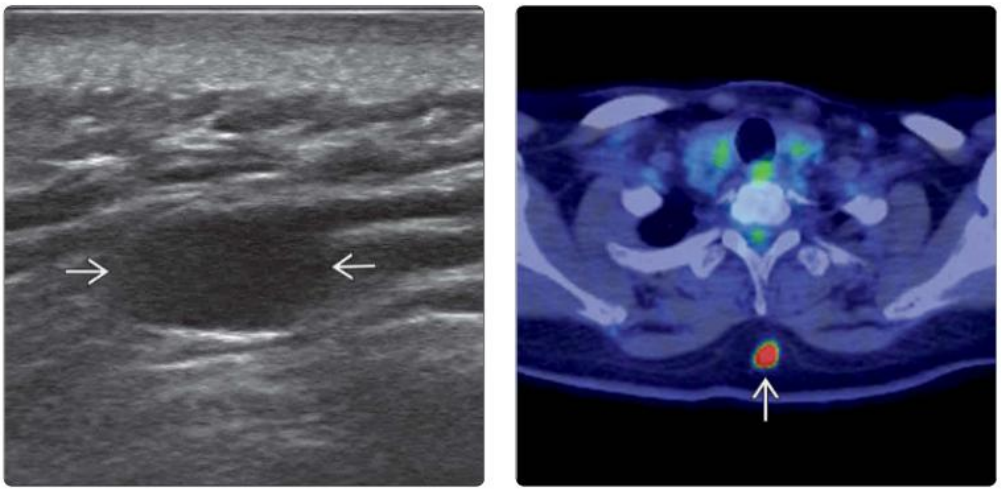

(Left) *Transverse US of the upper back region in a patient with previous wide local excision for foot melanoma shows a hypoechoic mass* ➡ *in the deep subcutaneous soft tissue.* **(Right)** *Transverse axial fusion FDG PET/CT of the same lesion shows hypermetabolic activity* ➡ *of the mass. Histology from US-guided biopsy confirmed metastatic melanoma. Melanoma is one of the primary tumors most commonly metastasizing to superficial soft tissues.*

(Left) *Longitudinal US of the leg in a patient with leg melanoma shows an in-transit melanoma metastasis ➡ in the subcutaneous tissue of shin. The tumor is lobulated in contour with a small cystic component ⇨.* **(Right)** *Longitudinal color Doppler US of another melanoma metastasis shows moderate intratumoral hypervascularity with a chaotic, mainly peripheral vascular pattern ➡. Melanoma metastasis is usually hypervascular.*

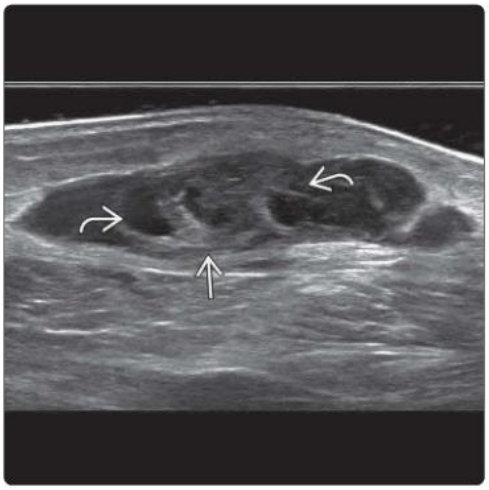

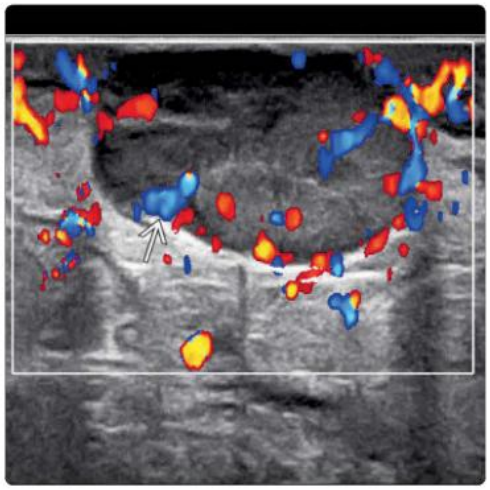

(Left) *Transverse US in a patient with melanoma of the ipsilateral index finger shows an in-transit subcutaneous lesion ➡ in the forearm. There is a hypoechoic tail sign ⇨ at both the proximal and distal ends of the tumor.* **(Right)** *Longitudinal US in the same patient shows another much longer in-transit lesion ➡. The elongated, hypoechoic mass is due to melanotic tumor filling and distending a lymphatic channel between the primary tumor and the regional lymph nodes, giving rise to the string sign.*

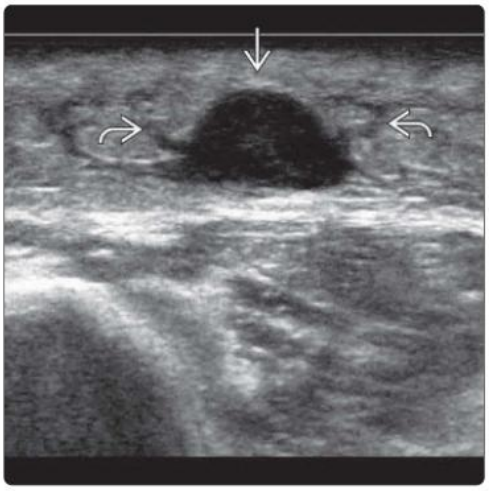

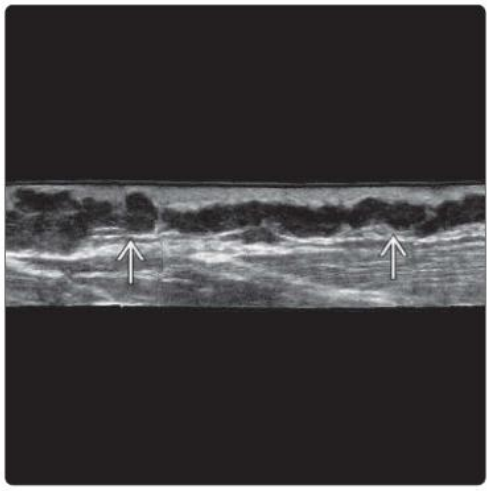

(Left) *Longitudinal US of the hand in a patient with mycosis fungoides shows a localized area of dermal thickening with subepithelial low-echogenic band (SLEB) ⇨ and moderate hypervascularity. Mycosis fungoides is one type of cutaneous T-cell lymphoma. SLEB thickness correlates with disease severity.* **(Right)** *Clinical photograph of a patient with increasing calf swelling and erythema ⇨ for 1 month is shown. The patient was otherwise healthy.*

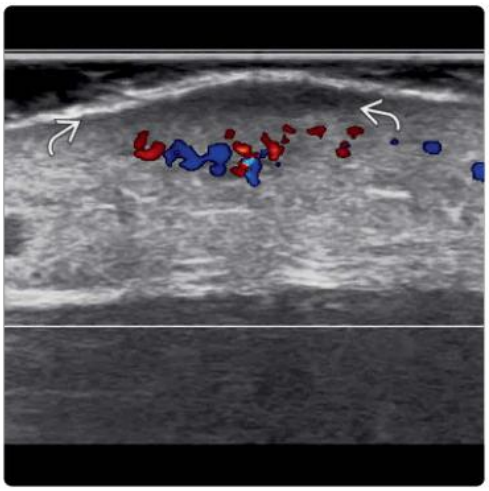

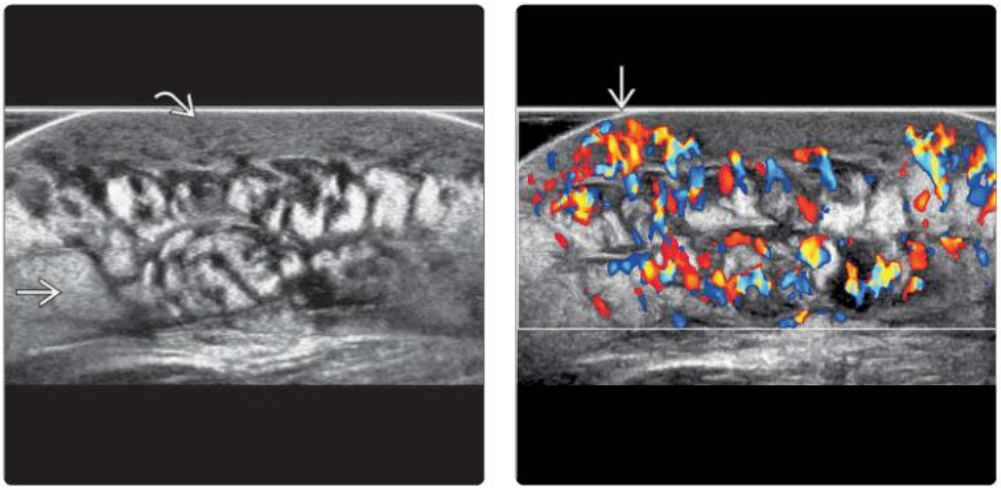

(Left) *Longitudinal US in the same patient shows a large, quite well-defined area of severe cutaneous ⇄ and subcutaneous ⇄ edema. No discrete tumor mass is present. The edematous, swollen, subcutaneous tissue has a cobblestone appearance, while the subdermal tissue is diffusely thickened without lobulation.* **(Right)** *Longitudinal color Doppler US in the same patient shows severe lesional hyperemia ⇄. US-guided biopsy revealed panniculitis-like T-cell lymphoma.*

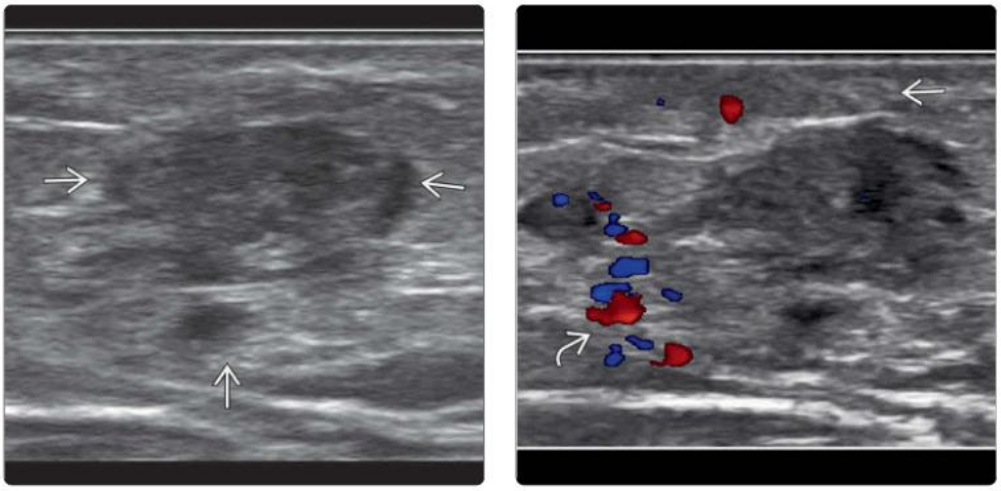

(Left) *Transverse US in a patient with a slowly enlarging mass on the medial thigh shows a fairly well-defined, lobulated, nodular, hypoechoic area ⇄ in the subcutaneous tissue.* **(Right)** *Transverse color Doppler US of the same lesion shows mild hyperemia ⇄ in the surrounding soft tissue. There is mild thickening of the dermis ⇄. Histology from US-guided biopsy revealed a low-grade B-cell lymphoma. The degree of intratumoral vascularity correlates with disease severity.*

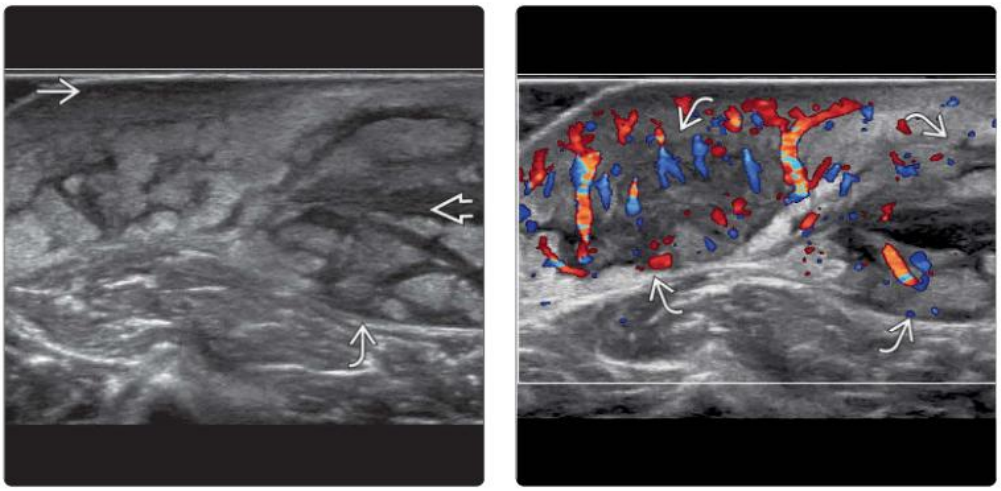

(Left) *Transverse US in a patient with a rapidly enlarging leg mass shows a large area of severe cutaneous ⇄ and subcutaneous ⇄ infiltration. The lesion is lobulated and indents the investing fascia ⇄ without transfascial extension.* **(Right)** *Transverse color Doppler US of the same lesion shows severe, intratumoral hypervascularity. Ill-defined, hypoechoic nodular areas ⇄ are present. Histology from US-guided biopsy revealed a malignant B-cell neoplasm, compatible with B-lymphoblastic leukemia/lymphoma.*

KEY FACTS

TERMINOLOGY

- "Vascular anomaly" includes both vascular tumors & vascular malformation
- Hemangioma is benign & most common vascular tumor
  - Grows after birth → proliferates → involutes
  - Most are low flow
- Vascular malformation is vascular dysplastic lesion
  - Present at birth → grows commensurately with child with no proliferation or involution
  - Low flow: Venous, capillary, lymphatic, or capillary/venous
  - High flow: Arteriovenous malformation, arteriovenous fistula

IMAGING

- Fairly discrete, usually hypervascular mass ± phleboliths ± medium to large vascular channels
- Variable amount of stromal connective tissue component
  - Stromal component may contain vessels too small to resolve with US
  - Especially in children, assess all lipoma-like masses with color Doppler
- Variable color depending on speed of flow
  - Grayscale better at detecting very slow flow
- Use US to make diagnosis & assess flow
  - Histologic confirmation is usually not necessary
- Use MR to define extent of large lesions

DIAGNOSTIC CHECKLIST

- Consider age at onset, behavior, size, location & extent, vascular vs. connective tissue stromal component, high flow vs. low flow
- Differentiation between hemangioma & vascular malformation is not always clear-cut despite imaging, clinical, & even histologic evaluation
- Chronologic behavior is best way of differentiating hemangioma from vascular malformation

(Left) *Clinical photograph of a 7-month-old baby shows a protuberant mass ⇨ on the posterior chest wall with bluish discoloration of the overlying skin.* **(Right)** *Transverse color Doppler US of the same lesion shows a quite discrete mass containing dilated venous vascular spaces ⇨. No deep extension is present. The lesion reduced in size on subsequent follow-up. The imaging features & clinical course were consistent with an infantile hemangioma.*

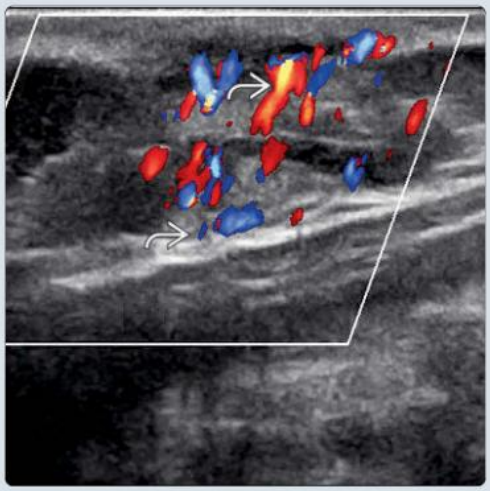

(Left) *Longitudinal US shows an arteriovenous malformation composed mainly of dilated vascular channels ⇨ & only a relatively small amount of supporting stroma ⇨. Pulsation was visible on grayscale imaging.* **(Right)** *Color Doppler US of the same lesion shows mainly arterial channels indicative of a high-flow arteriovenous malformation rather than a hemangioma. Hemangiomas generally tend not to have such high flow.*

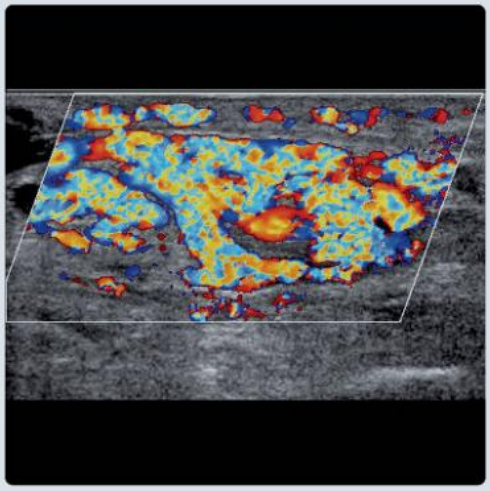

TERMINOLOGY

Definitions

- Vascular anomaly comprises both vascular tumors & vascular malformation
  - Differentiation based on natural history, clinical, imaging findings, cellular turnover, & histology
- Vascular tumors
  - Neoplasms feature cellular proliferation & hyperplasia
  - Classified as benign (most common), locally aggressive, & malignant
  - Benign: Infantile hemangioma, congenital hemangioma, tufted angioma, spindle cell hemangioma, epithelioid hemangioma, & pyogenic granuloma ("lobular capillary hemangioma")
    - Infantile hemangioma = most common childhood vascular tumor
      - Grows after birth → early proliferative stage → later involuntary stage
  - Local aggressive: Kaposiform/retiform/composite/pseudomyogenic/polymorphous hemangioendothelioma, papillary intralymphatic angioendothelioma, & Kaposi sarcoma
  - Malignant: Angiosarcoma & epithelioid hemangioendothelioma
- Vascular malformation
  - Vascular dysplasia rather than true neoplasm
    - Dysplastic vascular channels with normal endothelial turnover
  - Present at birth → grows commensurately with child without proliferation or involution
    - Never regresses spontaneously
  - Subdivided into simple or combined type, or associated with other anomalies
    - Simple type is based on predominant vessel type affected, e.g., capillary, venous, arteriovenous, or lymphatic
      - Venous malformation = most common vascular malformation
    - Combined type: Arteriovenous fistula, capillary/venous, lymphatic/venous, etc.
  - Classified as low flow or high flow depending on color Doppler flow dynamics
    - Low-flow vascular malformations: Venous, capillary, lymphatic, or capillary/venous
    - High-flow vascular malformations: Arteriovenous malformation, arteriovenous fistula

IMAGING

General Features

- Best diagnostic clue
  - ↑ vascular channels ± fairly discrete mass ± phleboliths
- Location
  - Head & neck (including intracranial) (40%), trunk (20%), & extremities (40%)
  - Unifocal (97%) or multifocal (3%)
- Morphology
  - Single-vessel ectasia → well-defined mass → large, ill-defined, advancing collection of anomalous vessels

Radiographic Findings

- Soft tissue mass ± phleboliths ± reactive, mature, periosteal new bone formation

MR Findings

- T2WI FS
  - Best at demonstrating extent of vascular anomaly
  - Low flow: No signal voids or large feeding arteries
  - High flow: Signal voids ± large feeding arteries
- MRA
  - Better at revealing nidus, feeding artery, & draining vein of arteriovenous malformation than US or MR

Ultrasonographic Findings

- Vary greatly, but vascular anomaly can still be reliably diagnosed on US in most cases
  - Diagnosis is based on compendium of signs rather than only 1 or 2 signs
  - Differentiation between hemangioma & vascular malformation is difficult based on imaging alone
- Abnormal vascular spaces may appear as vascular channels or large cystic spaces
- Variable stromal connective tissue component but usually has fatty-type background
  - Stromal component often contains vessels too small to be resolved with US
- Acoustic shadowing from phleboliths
- Color Doppler imaging varies depending on speed of flow
  - Slow blood flow shows moving echoes on real-time grayscale US often with little or no flow on color Doppler imaging
- Infantile hemangioma
  - Solid, usually hyperechoic mass ± lobulation ± intralesional vessels (occasionally)
  - Usually high vascular density, low-flow pattern on color Doppler but occasionally high-flow pattern seen
- Congenital hemangioma
  - Similar to infantile hemangioma
- Venous malformation
  - Very similar to hemangioma
    - Slow or no flow on color Doppler imaging
    - Expect to see arterial supply in venous malformation
      - 1 or 2 arteries do not imply high-flow lesion
- Capillary malformation
  - Localized skin & subcutaneous, echogenic mass
    - Usually minimal or no flow evident
- Lymphatic malformation
  - Largely avascular
  - Macrocystic: Thin-walled, septated, fluid-filled cystic spaces ± internal echoes (hemorrhage or infection)
  - Microcystic: Multiple tiny cysts within echogenic connective tissue matrix
    - Cysts may be too small to be resolved with US
- Arteriovenous malformation
  - Pulsatile mass on grayscale imaging
  - High-velocity flow on color & spectral Doppler imaging
  - Only type of vascular malformation to possess nidus
    - Nidus: Nest of abnormal vessels that directly connect arteries to veins, bypassing normal capillary bed

Angiographic Findings

- Prelude to sclerotherapy or embolization

Imaging Recommendations

- Best imaging tool
  - US to make diagnosis & assess flow
  - MR to define extent of large lesions
  - Angiography for preoperative planning & embolization in high-flow lesions
- Protocol advice
  - Use minimal transducer pressure to avoid compression
  - Determine location, size, extent, multiplicity, type of vessels, amount of connective tissue stroma vs. vascular component
  - Assess flow: High flow or low flow depending on predominant flow pattern
  - Especially in children, assess all lipoma-like masses with color Doppler

DIFFERENTIAL DIAGNOSIS

Alveolar Soft Part Sarcoma

- 2nd or 3rd decade, particularly lower limbs
- Typical intramuscular, hypervascular mass similar to high-flow vascular malformation
- Rapid growth with metastases (nodal, lung) in 20% at presentation

PATHOLOGY

General Features

- Associated abnormalities
  - Maffucci syndrome: Enchondromas & low-flow vascular malformation
  - Osler-Weber-Rendu syndrome: Arteriovenous malformations in skin, mucosa, lung, & brain
  - Klippel-Trenaunay-Weber syndrome: Low-flow vascular malformation ± large aberrant lateral vein ± limb hypertrophy
  - Gorham-Scott syndrome: Low-flow vascular malformation ± large aberrant lateral vein ± limb hypertrophy

Microscopic Features

- Hemangioma: Plump endothelial cells with hypercellularity, especially during proliferative phase
  - Extracellular matrix contains growth-promoting proteins
- Vascular malformation: Flat endothelial cells with normal cell turnover
  - Patchy deficiency of smooth muscle in wall → dilatation
  - No growth-promoting proteins in extracellular matrix
- Distinguishing vascular anomalies can be difficult

CLINICAL ISSUES

Presentation

- Most common signs/symptoms
  - Pain, swelling
- Other signs/symptoms
  - Bluish discoloration, mass ± engorgement with gravity
  - Discomfort after exercise, edema, hemorrhage, local hypertrophy, ulceration, contractures

Demographics

- Age
  - Congenital hemangioma: Present at birth
  - Infantile hemangioma: Present in early infancy
  - Venous malformation: Birth to early adulthood
  - Capillary or lymphatic malformation: First 2 years of life
  - Arteriovenous malformation: Early teens
- Epidemiology
  - Prevalence: 1.5% of general population
  - Hemangioma: Most common tumor of childhood
  - Vascular malformation: Venous (60%), lymphatic (25%), arteriovenous (10%), mixed (10%), & capillary (5%)

Natural History & Prognosis

- Infantile hemangioma
  - Proliferation (months) → stabilization (months to years) → spontaneous involution
  - Residual cosmetic deformity in ~ 50%
    - Later involution → greater cosmetic deformity
- Congenital hemangioma
  - Rapidly involuting congenital hemangioma (RICH) → involute by 14 months
  - Noninvoluting congenital hemangioma (NICH) → commensurate growth
    - Uncommon; need to see soft tissue mass as well as vessels & GLUT1 antigen positivity
  - Partially involuting congenital hemangioma (PICH) → rapid involution → stabilization → commensurate growth
- Vascular malformation
  - Slow commensurate growth
    - ± more rapid growth precipitated by puberty, pregnancy, infection, trauma, or unknown factor
    - Arteriovenous malformation is unpredictable

Treatment

- Medical: Observation, compression garments, pain control, propranolol or sirolimus
- Laser therapy, especially for superficial anomalies, including port wine stain
- Sclerotherapy done under angiographic, venographic, or US guidance
  - Ethanol most commonly used sclerosing agent
    - Contraindicated if high flow (risk of systemic shunting)
- Coil embolization for high-flow malformation
- Wide surgical excision as adjunct therapy following embolization

DIAGNOSTIC CHECKLIST

Consider

- Treatment based on clinical & imaging features
  - Classification is not always clear-cut despite imaging, clinical, & even histologic evaluation

Image Interpretation Pearls

- Important parameters to assess: Age at onset, behavior, site, size, margination, vascular vs. stromal component, & high flow vs. low flow

SELECTED REFERENCES

1. Shelar SS et al: A comprehensive review of sonographic assessment of peripheral slow-flow vascular malformations. Cureus. 16(2):e54099, 2024

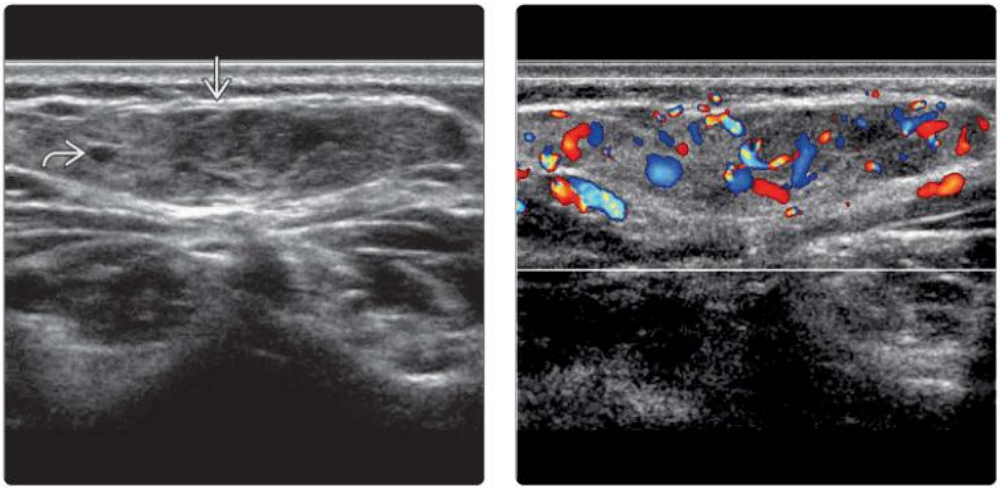

(Left) *Transverse US of the upper back in a 1-year-old child shows a well-defined, hyperechoic, fatty-type subcutaneous mass ⇨. Multiple small, hypoechoic vascular channels ⇨ are present within the mass. The mass vaguely resembles a lipoma.* **(Right)** *Color Doppler US of the same lesion shows multiple dilated, venous-type vascular channels within the mass, indicative of a slow-flow infantile hemangioma. These lesions are usually followed up by serial US examination.*

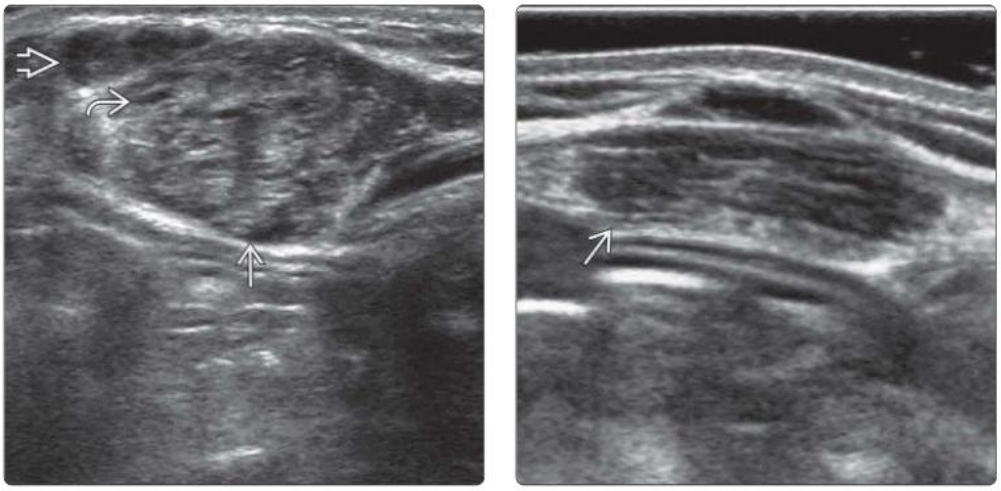

(Left) *Transverse US of a 1-year-old infant with an anterior abdominal mass that had enlarged over a few months shows a well-defined, fatty-type mass ⇨, which contains multiple small vascular channels ⇨, within the rectus abdominis muscle. There is limited subcutaneous extension ⇨.* **(Right)** *Follow-up transverse US of the same lesion 2 years later shows notable reduction in size ⇨. Infantile hemangioma typically presents & proliferates in infancy followed by stabilization & involution.*

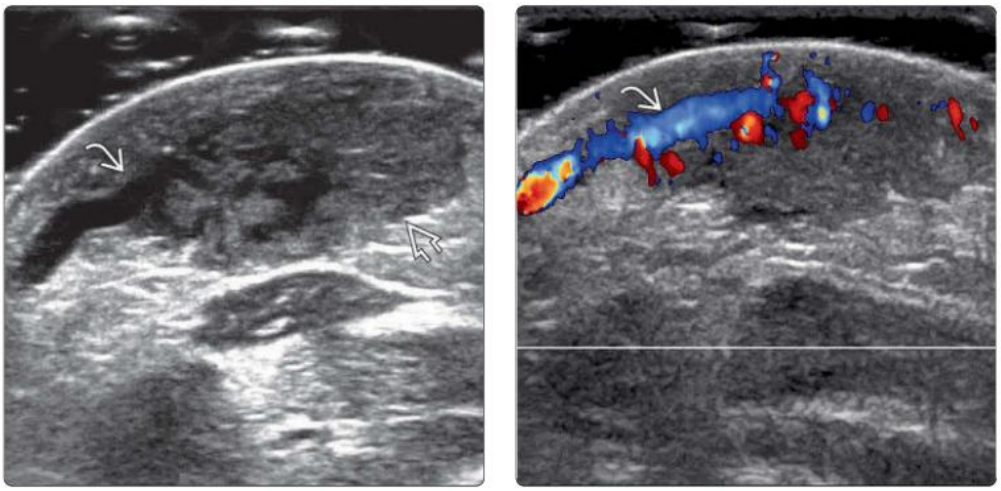

(Left) *Transverse US of a 21-day-old baby with a mass in the anterior thigh since birth shows a congenital hemangioma with a large amount of supporting stroma ⇨ & a prominent central vascular channel ⇨.* **(Right)** *Longitudinal color Doppler US of the same lesions shows venous signal ⇨ within the central vessel. The lesion rapidly decreased in size in the 1st month of life. This clinical course is in keeping with a rapidly involuting congenital hemangioma (RICH).*

(Left) *Transverse US of a 17-year-old patient with a pulsatile thigh mass for years shows a discrete mass ⇨ in the rectus femoris muscle ⇨. Several small vascular channels ⇨ are present in the more solid background stroma of the mass.* **(Right)** *Transverse color Doppler US of the same lesion shows that the mass is highly vascular. This vascular component is mainly composed of arterial flow, though small areas of venous flow are also present.*

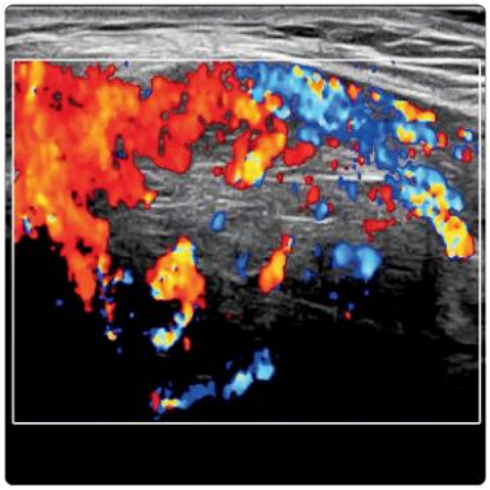

(Left) *Longitudinal spectral Doppler analysis of the same lesion shows a large arterial vascular channel ⇨ supplying the lesion. Features are indicative of a high-flow noninvoluting hemangioma or high-flow vascular malformation.* **(Right)** *DSA of the common femoral artery shows that the rectus femoris hypervascular mass ⇨ is supplied by the profundus femoral artery ⇨. Absence of any discrete nidus or early draining vein favors a high-flow noninvoluting hemangioma rather than an arteriovenous malformation.*

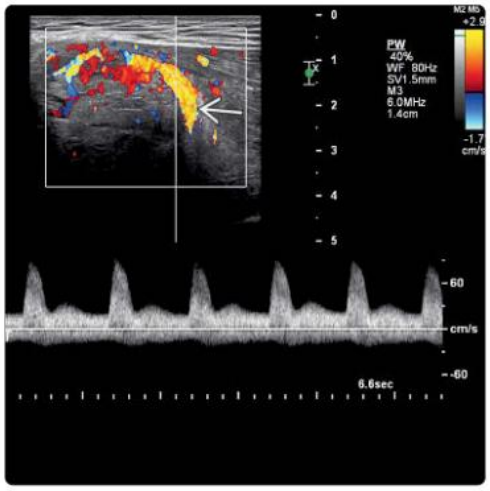

(Left) *Longitudinal US of an adult with an enlarging finger nodule a few weeks after injury shows a well-defined, hypoechoic, subcutaneous nodule ⇨ on the volar aspect of the finger close to the proximal interphalangeal joint.* **(Right)** *Longitudinal color Doppler US of the same lesion shows marked hypervascularity within the nodule & adjacent soft tissues consistent with a pyogenic granuloma. This type of vascular tumor occurs as an overgrowth to irritation, trauma, or hormonal stimulus.*

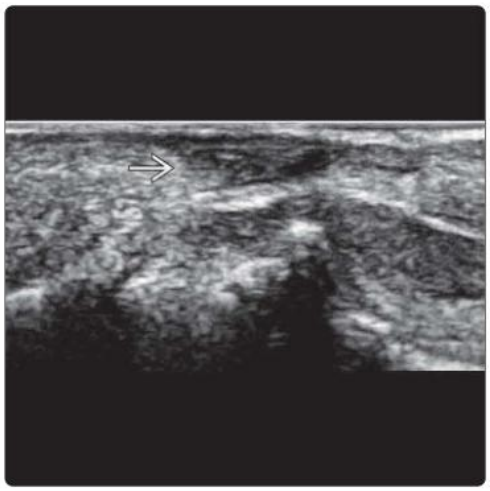

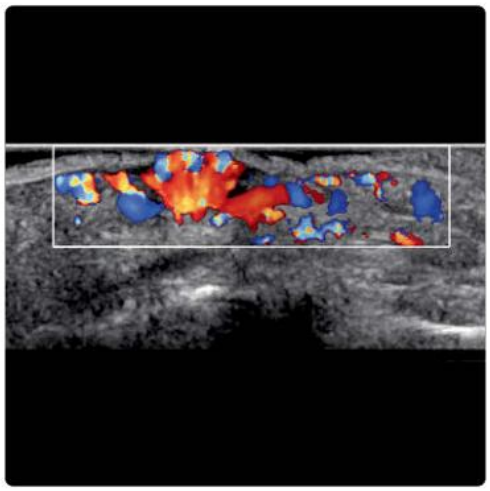

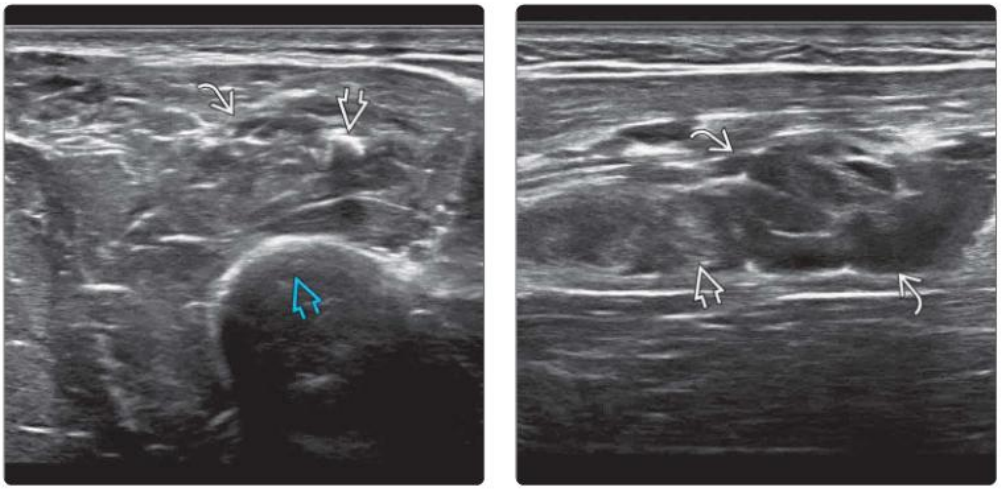

(Left) *Transverse US of the arm in an 18-year-old man with a 3-year history of arm swelling shows an ill-defined mass in the brachialis muscle alongside the humeral shaft ⇨. This venous vascular malformation contains dilated vascular channels ⇨ & a phlebolith ⇨.* **(Right)** *Longitudinal US of the same area shows that the lesion is composed of ~ 70% dilated vascular channels ⇨ & ~ 30% echogenic-supporting stroma ⇨. The appearances favor a venous vascular malformation.*

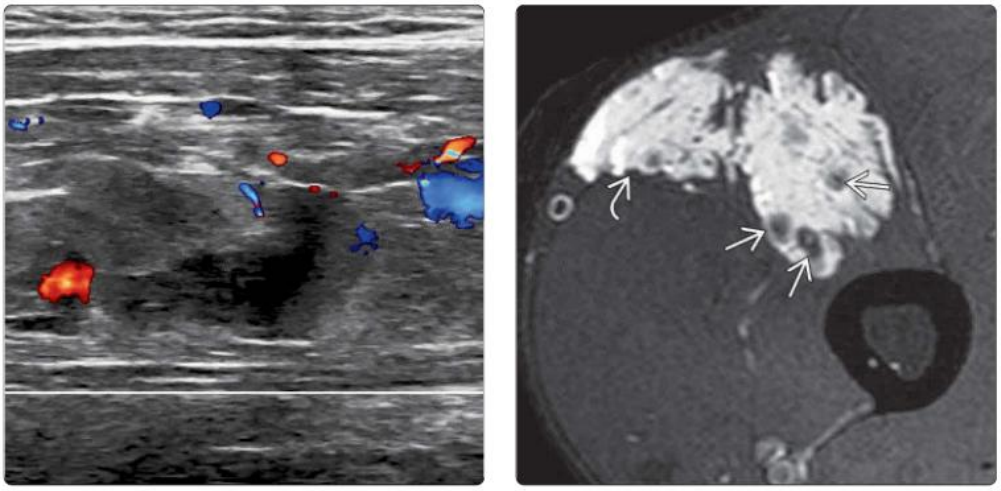

(Left) *Longitudinal color Doppler US of the same lesion shows little vascular flow present in the lesion. Flow within many of the dilated venous channels is too slow to be depicted on color Doppler US.* **(Right)** *Axial T2 FS MR of the same lesion shows a well-defined, lobulated hyperintense mass ⇨ within the brachialis muscle. The extent of the venous malformation is more readily appreciated on MR imaging. Multiple hypointense foci representing phleboliths ⇨ are present within the mass.*

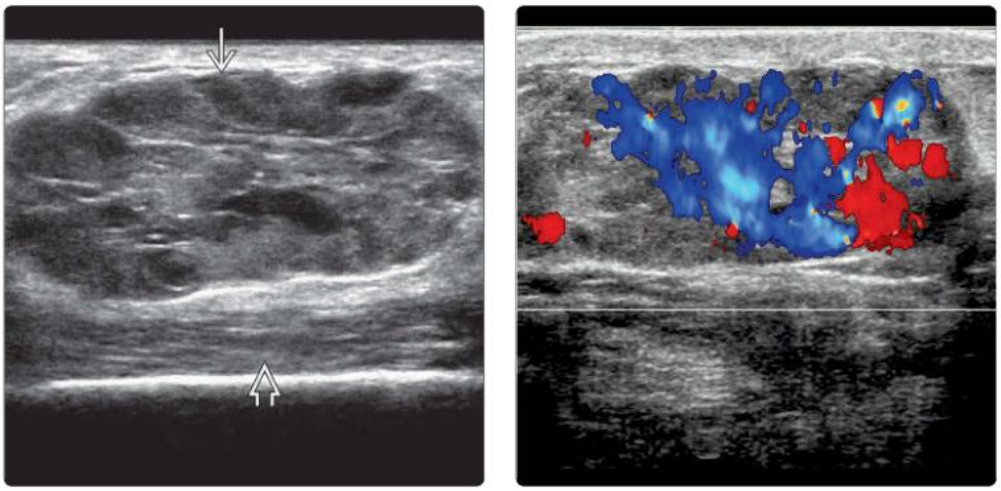

(Left) *Longitudinal US in a 71-year-old patient with a long history of forearm swelling that recently increased in size shows a well-defined, subcutaneous lobulated mass ⇨ without subfascial extension. The muscle layer ⇨ is intact.* **(Right)** *Longitudinal color Doppler US of the same lesion shows the presence of ~ 60% mainly venous-type vascular channels & ~ 40% supporting connective tissue stroma.*

(Left) *Longitudinal spectral Doppler analysis of the same lesion shows a large venous vascular channel supplying the lesion. Features are indicative of a venous vascular malformation. This was confirmed by histology. Change in size of a vascular malformation is usually due to altered consistency & size secondary to thrombosis.* **(Right)** *Clinical photograph of a 41-year-old man shows a cystic-type mass ➡ on the dorsum of the hand with bluish discoloration & telangiectasia of the overlying skin.*

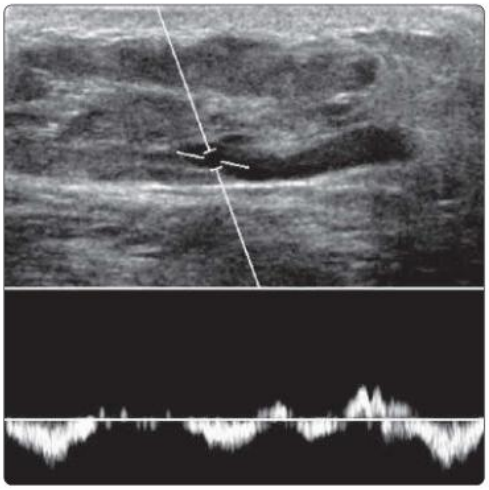

(Left) *Transverse US of the same lesion shows a venous vascular lesion overlying the metacarpal bones ➡. The fluid-fluid interface ⇨ indicates sedimentation of blood product in a slow-flow distended venous channel.* **(Right)** *Longitudinal color Doppler US shows another venous vascular malformation ➡ filled with moving echoes on real-time grayscale imaging. There is proximal & distal vascular supply & drainage evident ➡. Slow flow is better depicted on grayscale US imaging.*

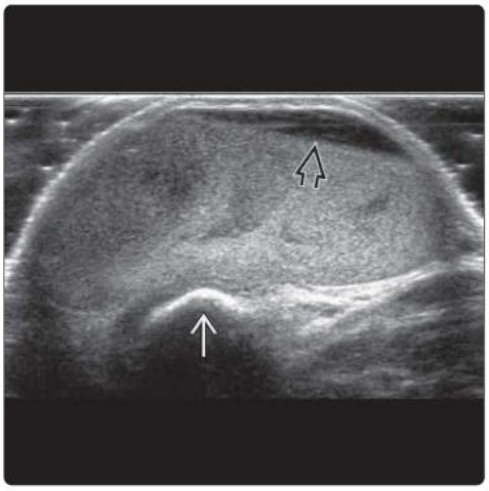

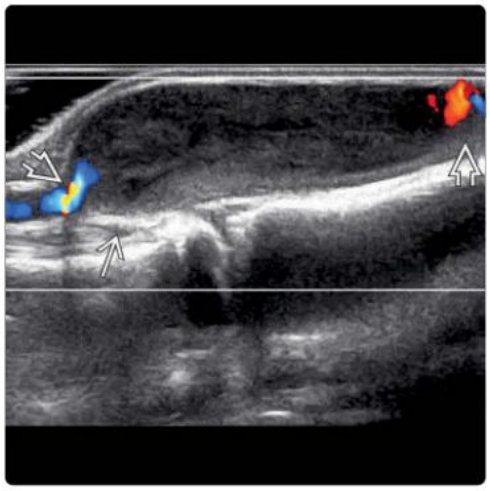

(Left) *Transverse US shows a fairly well-defined, hyperechoic mass ➡ of the cutaneous & subcutaneous tissues of the anterior abdominal wall overlying the rectus abdominis muscle ➡. The mass is lipomatous in type & partially compressible.* **(Right)** *Longitudinal color Doppler US of the same lesion shows small, low-flow vascular channels ➡. Both clinical & US follow-up reveal reduction of the lesion size. The overall appearances are suggestive of a capillary or venocapillary hemangioma.*

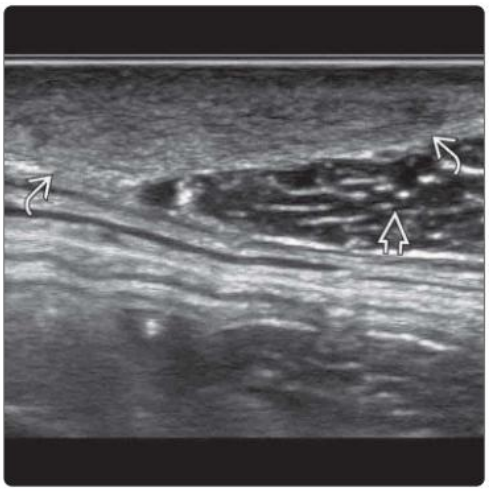

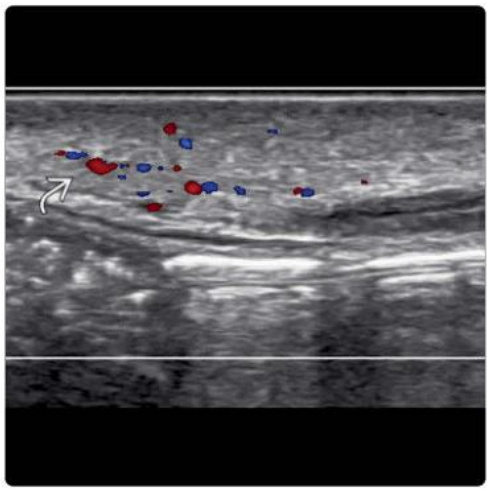

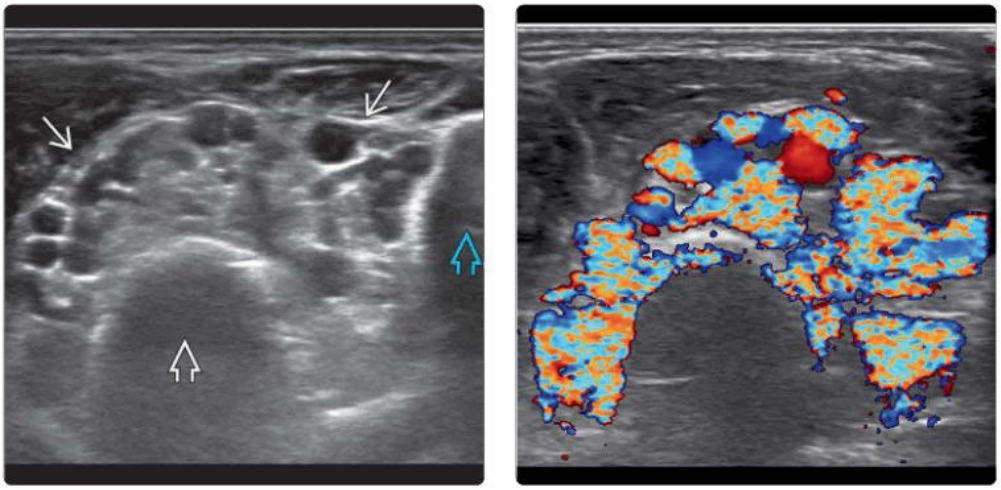

(Left) *Transverse US in a 15-year-old patient with a pulsatile forearm mass shows a nest of dilated, serpiginous vessels in the extensor compartment closely abutting the radius & ulna. This vascular lesion predominantly consists of dilated vascular channels with small volume of supporting stroma.* **(Right)** *Transverse color Doppler US of the same lesion shows turbulent, multidirectional flow characteristic of the nidus flow of an arteriovenous malformation.*

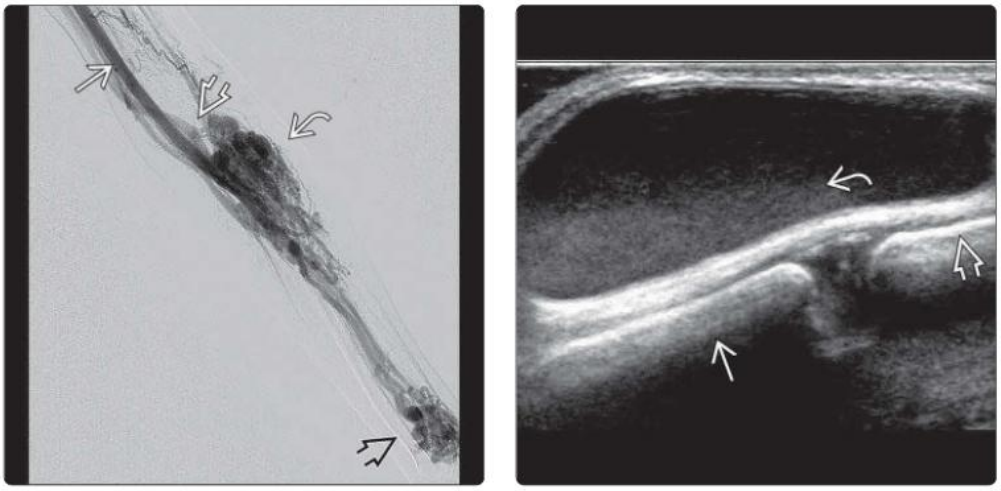

(Left) *DSA of the same lesion shows a nest of abnormal vessels (nidus) with feeding arteries from brachial artery & draining veins to brachial vein. There is another similar arteriovenous malformation more distally in the forearm.* **(Right)** *Longitudinal US of a young boy shows a well-defined, uniloculated lymphatic malformation overlying the manubrium, sternal body junction. Partially layered cystic contents are mildly echogenic. There was no flow on color Doppler imaging.*

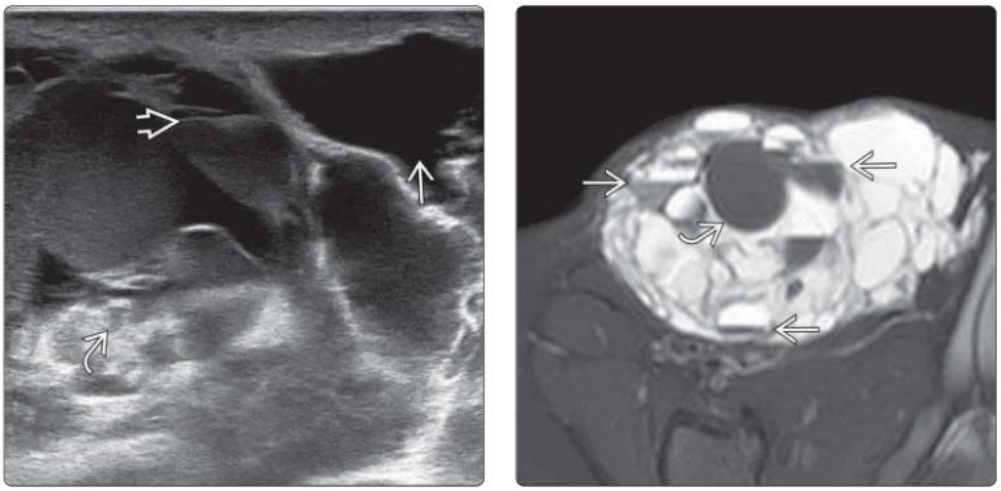

(Left) *Transverse US in a 21-month-old boy with a painful groin mass shows a multicystic mass with a combination of large & small cystic areas. Some of the locules show internal echoes & fluid-fluid levels.* **(Right)** *Axial T2 FS MR of the same lesion shows a hemorrhagic complication of this multiloculated lymphatic malformation. Some of the cystic locules show evidence of previous hemorrhage with T2-hypointense content & fluid-fluid levels.*

KEY FACTS

TERMINOLOGY

- Foreign body (FB) granuloma: Localized tissue reaction to retained FB following penetrating skin trauma
- Injection granuloma (IG): Localized tissue reaction to material injected into tissues

IMAGING

- US: Modality of choice to detect radiolucent FBs & diagnose IGs
  - Nearly all foreign body material should be detectable on US, with sensitivity & specificity > 95%
- FB: Echogenic FB with posterior acoustic shadowing ± surrounding hypoechoic rim, which represents inflammatory reaction comprising edema, hemorrhage, granulation tissue, or fibrosis
  - Reflectivity of some objects (wood, metal, glass, plastic) exceeds that of others (bamboo)
  - Align probe as parallel to FB as possible; FB may be located some distance from entry wound
  - False-positive US with gas or calcification in soft tissues; correlate with radiographs if necessary
  - Repeat US in 2-10 days if clinical history suspicious & US findings negative or equivocal
    - Bamboo splints may not be visible initially; air entrapment in soft tissues may resolve after trauma
  - Depth may be limiting factor: Most FBs difficult to visualize if located > 4 cm from skin surface
- IG: Focal, hypoechoic, subcutaneous mass with variable calcification & posterior acoustic shadowing
  - Especially in buttock & lateral aspect of arm

CLINICAL ISSUES

- Almost 90% of FBs can be successfully removed under US guidance
  - Particularly if injury is recent
  - Chronically retained FB can be firmly adherent
- Hypoechoic rim can be breached by local anesthetic dissection, hydrodissection, or blunt forceps dissection

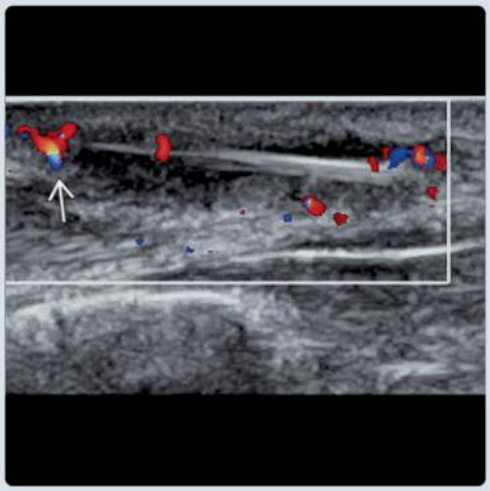

(Left) *Longitudinal oblique US shows an echogenic wooden splinter ➡ in the subcutaneous tissues of the hand 7 days after penetrating skin injury. A rim of hypoechoic granulation tissue ➡ surrounds the wood splinter.* **(Right)** *Oblique color Doppler US in the same patient shows moderate hypervascularity ➡ in the adjacent granulation tissue and subcutaneous tissues. This foreign body (FB) was successfully removed under US guidance.*



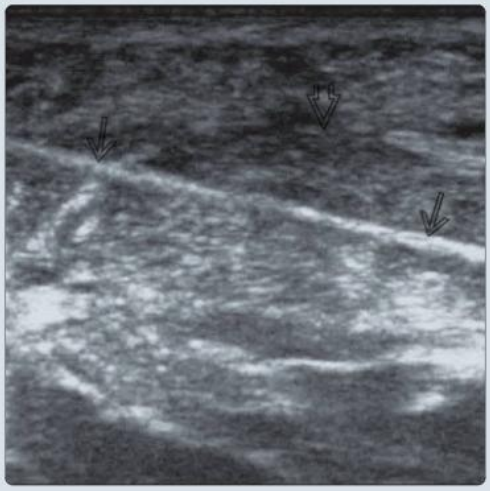

(Left) *Oblique US shows a barely visible bamboo splinter ➡ within the edematous thenar muscle ➡ 1 day after penetrating injury.* **(Right)** *Oblique US of the same area 4 days later shows that the bamboo splinter is now clearly visible as an echogenic FB ➡. The thenar musculature ➡ is also less hypoechoic than previously. Follow-up US is particularly useful for suspected organic FBs not visible on initial US examination.*

TERMINOLOGY

Abbreviations

- Foreign body (FB)
- Injection granuloma (IG)

Definitions

- FB granuloma: Localized tissue reaction to retained FB following penetrating skin trauma
- IG: Localized chronic granulomatous tissue reaction to injected material

IMAGING

General Features

- Best diagnostic clue
  - FB: Echogenic material with posterior acoustic shadowing ± surrounding hypoechoic rim
  - IG: Localized hypoechoic swelling of subcutaneous tissues → ill-defined mass with peripheral hyperemia → well-defined mass ± calcification
- Location
  - FB: Subcutaneous tissues > > deep tissues, particularly in forearms, hands & wrists > feet
  - IG: Subcutaneous tissue, particularly superolateral aspect of gluteal region & lateral aspect of proximal arm
- Size
  - FB: Usually small (1-3 cm) but can be large (≥ 10 cm)
  - IG: Usually small (2-5 cm); dependent on amount & dispersion of injected material
- Morphology
  - FB: Depends on size & shape of FB & inflammatory response
    - Wood (45%), glass (25%), needle (10%), metal (10%), & others (e.g., gravel, fish fin, pencil lead) (10%)
      - Often, nature of FB is not known
  - IG: Firm to hard subcutaneous nodule

Radiographic Findings

- FB: Only detects radiopaque FBs, such as metal, glass, gravel, & some plastics
  - ≤ 15% wood FBs are radiopaque
  - Limited information on exact location of FB & associated soft tissue response
- IG: ± calcified subcutaneous mass

CT Findings

- NECT
  - FB granuloma
    - Typically seen as hyperdense object with variable surrounding inflammation or fibrosis
    - Wood may appear hypodense & simulate air
  - IG: Well-defined, subcutaneous mass ± lobulated or rim calcification (often dense)

MR Findings

- Less accurate than US at detecting FBs
  - Good visualization of inflammatory response

Ultrasonographic Findings

- FB
  - Echogenic object with posterior acoustic shadowing ± reverberation/comet-tail artifact
  - Echogenicity is dependent on acoustic impedance between retained FB & surrounding tissue
    - Reflectivity of some objects (wood, metal, glass, plastic) exceeds that of others (bamboo)
    - Reflectivity also dependent on smoothness of FB & alignment to US beam
    - Type of posterior shadowing depends on curvature of foreign body: Objects with rough/sharp surface &/or small curvature (toothpick, wood, pencil) produce clean-type shadowing, whereas objects with smooth surface &/or large curvature (metal, glass, plastic) produce dirty-type shadowing & reverberation artifact
  - ± surrounding hypoechoic halo of inflammatory edematous tissue, granulation tissue, or fibrosis
    - Presence of halo depends on intensity of inflammatory response & duration of retention of FB
      - May be apparent within 24 hours of retention
    - Improves sensitivity & specificity of US detection
    - Variable hyperemia of hypoechoic rim
  - Determines relationship to nerves, vessels, & tendons facilitating safe US-guided FB extraction
- IG
  - Focal swelling & disruption of subcutaneous fat
    - Similar to early stages of fat necrosis
    - ± small areas of liquefaction
    - ± mild peripheral hyperemia
  - Swelling may progress to ill- or well-defined, hypoechoic mass
    - ± mild peripheral hyperemia
    - ± dense calcification
      - Limits visibility of deep margin of mass

Nuclear Medicine Findings

- IG may accumulate tracer on FDG PET imaging
  - False-positive for subcutaneous metastatic deposit

Imaging Recommendations

- Best imaging tool
  - US: Modality of choice to detect radiolucent FBs & diagnose IGs
- Protocol advice
  - FB
    - First, check with patient regarding type & size of FB, direction of implantation, & likelihood of FB retention
    - Align probe as parallel to FB as possible
    - Examine beyond entry wound as FB may be located some distance from entry wound
    - Note size, shape, location, & orientation of FB in relation to patient history
    - Assess presence, thickness, & vascularity of hypoechoic rim
    - Assess adjacent critical structures (neurovascular bundles, tendons, & joints)
    - False-positive US can occur due to gas or calcification in soft tissues, particularly if FB is small, e.g., glass fragment
      - Correlate with radiographs
    - Repeat US in 2-10 days if history suspicious & US findings equivocal, e.g., bamboo splits may not be seen initially

- Meticulous scanning with high-resolution linear transducer is key when there is relevant clinical history
- IG
  - Assess location, size, & margination of granuloma
  - Assess vascularity & present of calcification

DIFFERENTIAL DIAGNOSIS

Subcutaneous Fat Necrosis

- Localized swelling, ↑ echogenicity & disruption of subcutaneous fat; usually less well-marginated
- ± history of prior blunt trauma

Subcutaneous Fibroma

- Hypoechoic, well-defined, subcutaneous nodule
  - No history of injection or injury

Subcutaneous Metastasis

- Hypoechoic, usually noncalcified, vascular nodule
- Usually known disseminated malignancy

PATHOLOGY

General Features

- Etiology
  - FB granuloma
    - Penetrating FB (wood, glass, needle, bamboo, etc.)
    - Retained FB (gauze, cotton swab, etc.)
  - IG
    - Injection of drug into subcutaneous fat
    - Usually occurs when injection occurs in subcutaneous tissue instead of within musculature
      - Granulomas are much less frequent with intramuscular injection
    - Tissue reaction is dependent on site, composition, & amount of injected material

Gross Pathologic & Surgical Features

- FB: Variable rim of inflammatory or fibrous tissue
- IG: Tissue necrosis with mass composed of inflammatory or fibrous tissue

Microscopic Features

- IG
  - Necrosis of fat cells
  - Dense, fibrous tissue reaction with inflammation
    - Inflammation may persist > 1 year after injection

CLINICAL ISSUES

Presentation

- Most common signs/symptoms
  - FB
    - History of penetrating injury
    - Palpable mass, initially tender but becomes less tender over ensuing weeks
  - IG
    - History of injection
    - Tender area → palpable mass
- Other signs/symptoms
  - Original trauma or injection may be forgotten; may present as unexplained mass

Demographics

- Age
  - FB: Young or middle-aged patients
  - IG: Older patients

Natural History & Prognosis

- FB
  - Inert material leads to nontender mass
  - Noninert material leads to continuing tissue reaction, which persists as tender FB granuloma
    - Chronic inflammatory reaction ± sinus tract to skin
  - IG
    - Mass becomes less tender, smaller, & harder
    - Usually persists as small, hard nodule

Treatment

- FB
  - Percutaneous US-guided removal
    - ~ 90% of FB can be successfully removed, particularly if injury is recent
      - Chronically retained FBs can be firmly tethered
      - US retrieval may not be feasible if high risk of adjacent nerve or vascular injury
    - Superficial FB: Localization → 2- to 3-mm skin incision usually sufficient, though can be up to 10 mm
      - Remove under US guidance or mark skin location & remove directly after skin incision
      - Use either small needle as lever placed under FB, or, for larger FB, grasp FB with forceps
    - Deep FB: Localization → incision → blunt forceps dissection → removal using US guidance
      - Removal along long axis of FB minimizes likelihood of FB breaking during retrieval
      - Use transducer pressure to fix FB
      - Crocodile or mosquito forceps opened along FB, which is pushed into jaws of forceps with transducer pressure
      - Hard materials are generally easier to remove (positive feedback on contact)
      - Lignocaine dissection, hydrodissection or needle bevel can be used to free up FB bound by granulation tissue
  - Cutaneous or needle localization aids surgical excision
- IG: Treatment usually not necessary

DIAGNOSTIC CHECKLIST

Consider

- US has dramatically ↑ detection rate & image-guided recovery rate of FBs
- Minimal transducer pressure & copious acoustic jelly increases sensitivity of FB detection
- Be careful about diagnosing small, thin (< 1 mm) FBs on US
  - Fine, echogenic lines masquerading as thin FBs are seen in almost any tissue
- US appearances of IGs are specific enough not to warrant further investigation

SELECTED REFERENCES

1. Grocutt H et al: Ultrasound compared with projection radiography for the detection of soft tissue foreign bodies - A technical note. Radiography (Lond). 29(6):1007-10, 2023

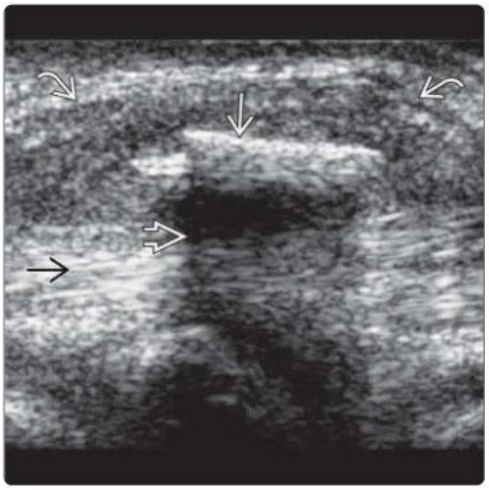

(Left) *Clinical photograph shows an almost healed entry site ⇨ of a wood splinter in a patient who presented with a palpable mass in the midpalm region ⇨ 4 weeks after initial injury.* **(Right)** *Oblique US of the palm in the same patient shows the wood splinter ⇨ with posterior acoustic shadowing ⇨ on the volar aspect of the carpus, superficial to a flexor tendon ⇨. A thick rim of reparative granulation tissue ⇨ surrounds the FB.*

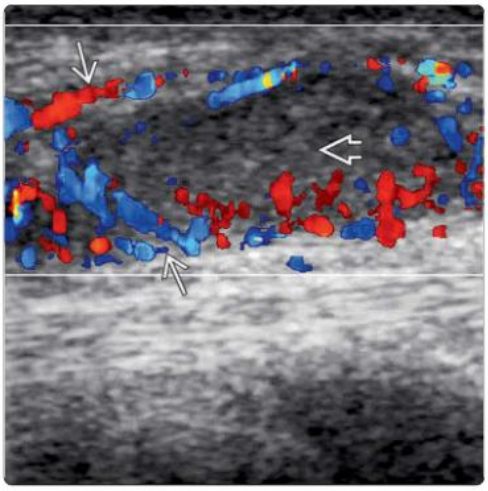

(Left) *Oblique US in the same patient shows marked hypervascularity ⇨ of the surrounding hypoechoic rim ⇨, compatible with immature granulation tissue.* **(Right)** *Transverse US of the distal pulp big toe in a man with penetrating injury by bamboo splint shows a 1-mm linear echogenicity representing a retained FB ⇨. Mild surrounding hypoechogenic rim ⇨ of reactive soft tissue is present. US can localize even tiny FBs; note the minimal transducer pressure used.*

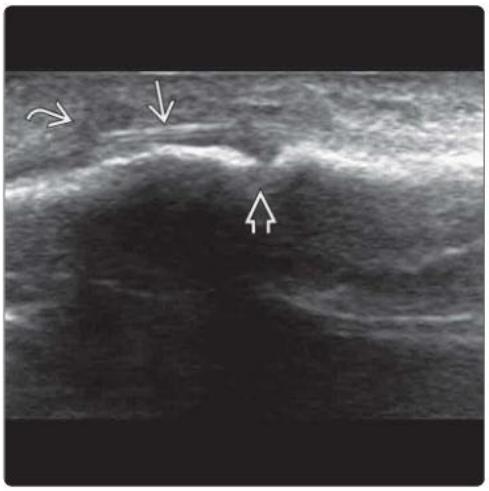

(Left) *AP radiograph in the same patient shows a tiny fleck of radiopaque density ⇨ at the lateral aspect of the distal phalanx big toe, corresponding to the US-detected FB. Subsequent surgical removal confirmed a retained bamboo splint fragment.* **(Right)** *Longitudinal US shows an echogenic wood splinter ⇨ on the radial aspect of the proximal interphalangeal joint ⇨ with a thin, hypoechoic halo of granulation tissue ⇨. Corresponding radiograph did not show any radiopaque FB.*

(Left) *Transverse US shows multiple bamboo splinters* ➡ *with surrounding granulation tissue* ➡ *anterior to the tibia. The anterior tibial artery* ➡ *is just deep to this area.* **(Right)** *Clinical photograph of the same patient shows an open entry wound* ➡ *over the anteromedial aspect of the mid leg. The site of FBs and surrounding granulation tissue is marked* ➡ *for surgical localization. Note how the FBs are located far from the entry site. The path of the anterior tibial artery* ➡ *is also marked to aid surgical planning.*

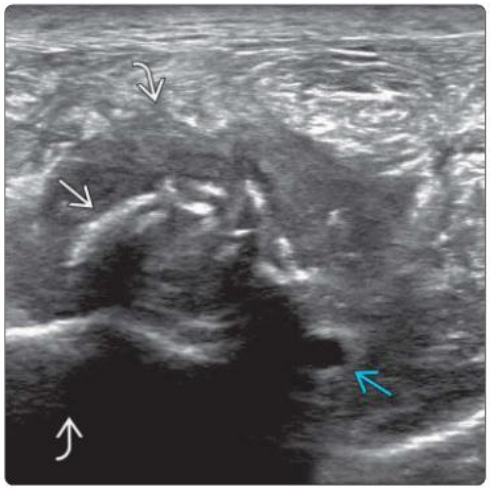

(Left) *Oblique US shows a wood splinter* ➡ *within the thenar muscle* ➡. *There is a small, hypoechoic area* ➡ *(most likely due to a small fluid collection) at the proximal tip of the splinter.* **(Right)** *Lateral radiograph in the same patient shows only mild soft tissue swelling* ➡ *in the thenar region. No visible radiopaque FB is seen.*

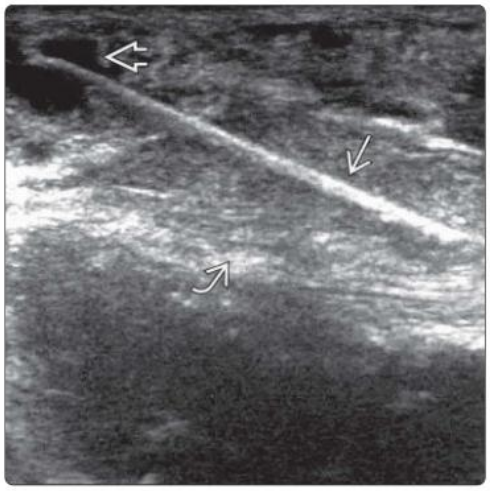

(Left) *Longitudinal US of the arm shows 2 thin, curvilinear subdermal glass fragments* ➡ *with edematous inflammatory tissue* ➡. *These linear echoes did not move with transducer pressure, helping to distinguish them from air locules.* **(Right)** *Longitudinal US shows a wooden splinter* ➡ *on the dorsum of the finger with surrounding fluid and inflammatory tissue. Minimal hyperemia was present. The nail base* ➡, *distal interphalangeal joint* ➡, *and extensor tendon* ➡ *are normal.*

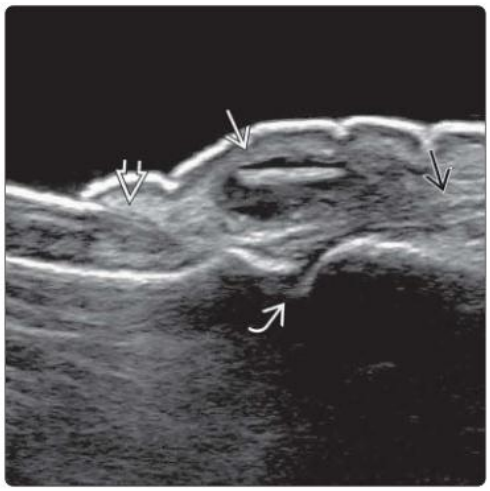

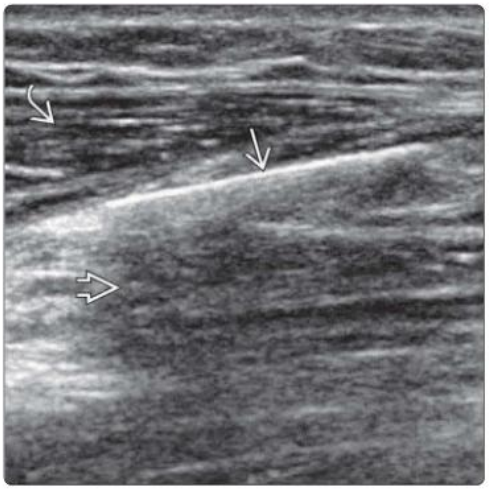

(Left) *AP radiograph in a 38-year-old construction worker several hours after a penetrating injury shows a metallic FB (needle) in the proximal aspect of the leg.* **(Right)** *Oblique US in the same patient shows how the echogenic needle is located within the superficial fibers of the soleus muscle. There is mild posterior acoustic shadowing. The overlying gastrocnemius muscle is normal. US allows precise FB localization. This FB was removed under US guidance.*

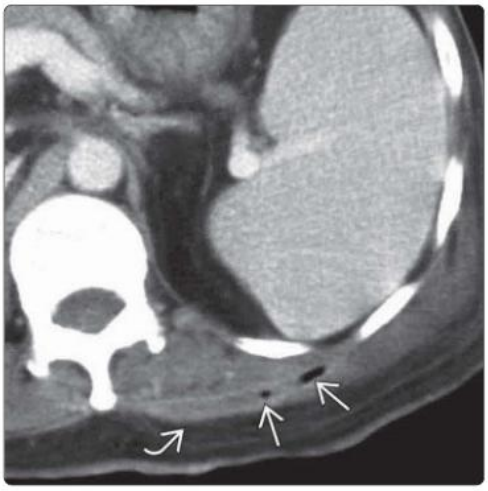

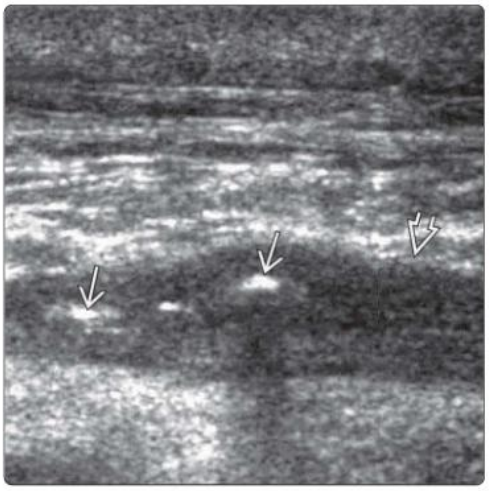

(Left) *Transverse CECT in a patient with penetrating chest trauma shows 2 radiolucent wood splinters in the posterior chest wall with a medium-sized, isodense halo of rim-enhancing granulation tissue.* **(Right)** *Oblique US in the same patient shows the 2 echogenic wood splinters with a thick, hypoechoic halo of fibrous tissue. Wooden FBs can mimic air, being hypodense on CT and echogenic on US.*

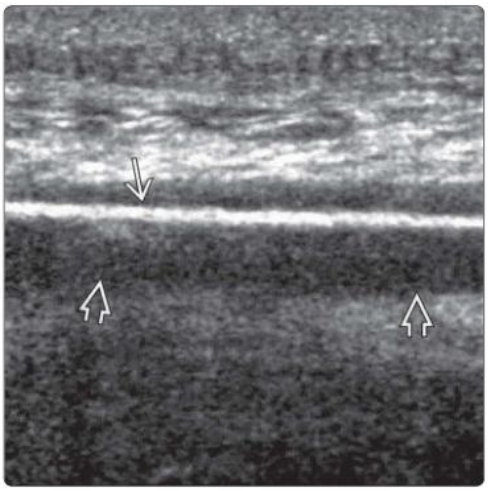

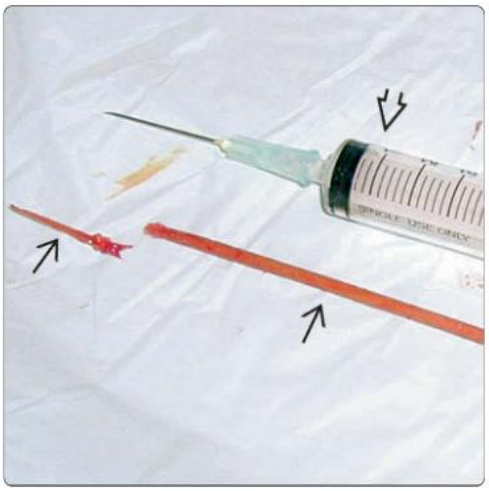

(Left) *Oblique US in the same patient clearly shows an echogenic wood splinter against a hypoechoic halo of granulomatous-type tissue.* **(Right)** *Clinical photograph shows the 2 wood splinters removed using forceps and blunt dissection under US guidance and local anesthesia. A rim of granulation tissue does not preclude image-guided removal as it can be breached by local anesthetic dissection, hydrodissection, or blunt dissection.*

(Left) *Transverse US shows a toothpick ➡ overlying the proximal interphalangeal joint of the middle finger with an entry site on the dorsal aspect of the finger ➡. The surrounding tissue is edematous ➡. No abscess or discrete granulation tissue are evident.* **(Right)** *Longitudinal US of the volar aspect of the finger shows a 3-mm subcutaneous metallic FB ➡ superficial to the flexor tendons ➡. This FB was removed under US guidance.*

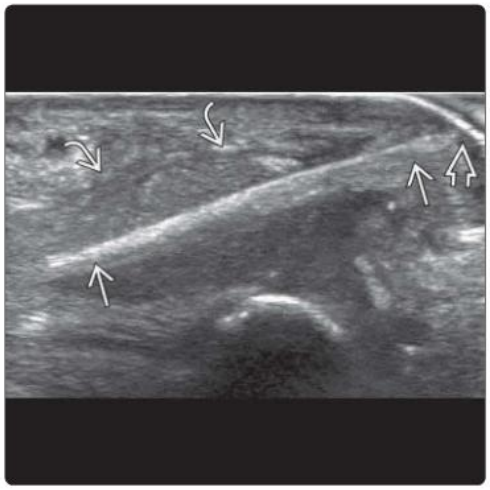

(Left) *Frontal radiograph in a 43-year-old man who underwent acupuncture during which the acupuncture needle broke shows a retained needle ➡ in the lateral suprapatellar soft tissues.* **(Right)** *Transverse US in the same patient confirms a 2-cm, linear, echogenic foreign body ➡ in the subcutaneous tissues of the posteromedial thigh, compatible with retained needle. This needle was puncturing through the great saphenous vein ➡. No associated hematoma or granulation tissue is present.*

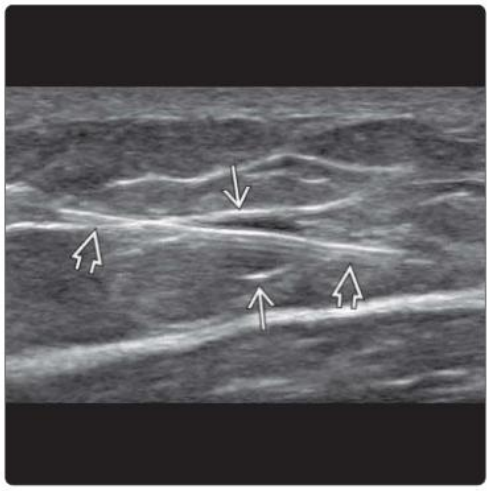

(Left) *Longitudinal US of the thigh shows a small chopstick splinter ➡ measuring 10 mm long x 1.5 mm deep x 2 mm wide. There is no surrounding granulation tissue. The splinter lies immediately deep to the skin, just lateral to the cutaneous wound. This was retrieved with US guidance.* **(Right)** *Transverse US shows a medium-sized granuloma ➡ in the subcutaneous region of the upper outer quadrant of the buttock. Although the granuloma is not calcified, its fibrotic nature still leads to moderate acoustic shadowing ➡.*

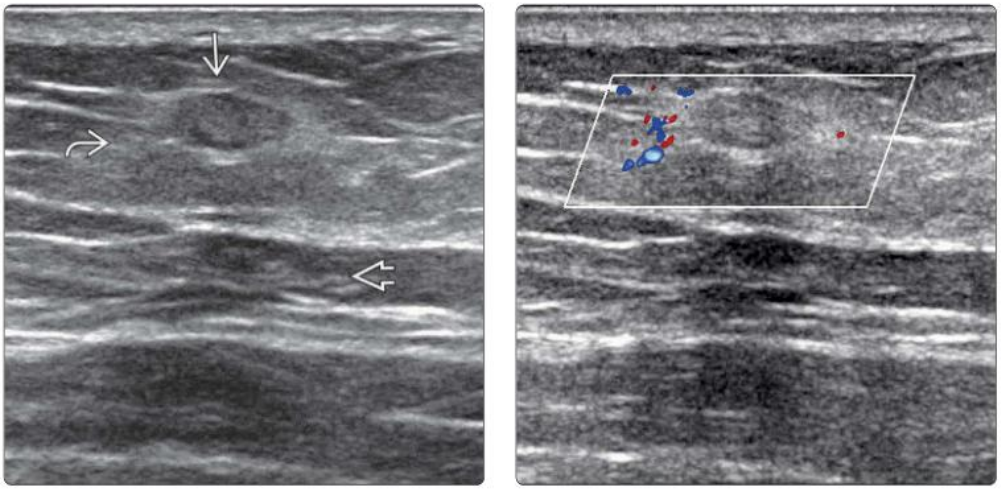

(Left) *Transverse US of the buttock shows a small, subcutaneous granuloma* ➡ *with surrounding soft tissue edema* ⇨. *This edema may be a feature of immature granulomas, probably related to ongoing tissue reaction to the subcutaneous injectate. Mild acoustic shadowing is present* ⇨. **(Right)** *Transverse color Doppler US of the same area shows mild surrounding tissue hyperemia, indicative of low-grade inflammation or active tissue repair.*

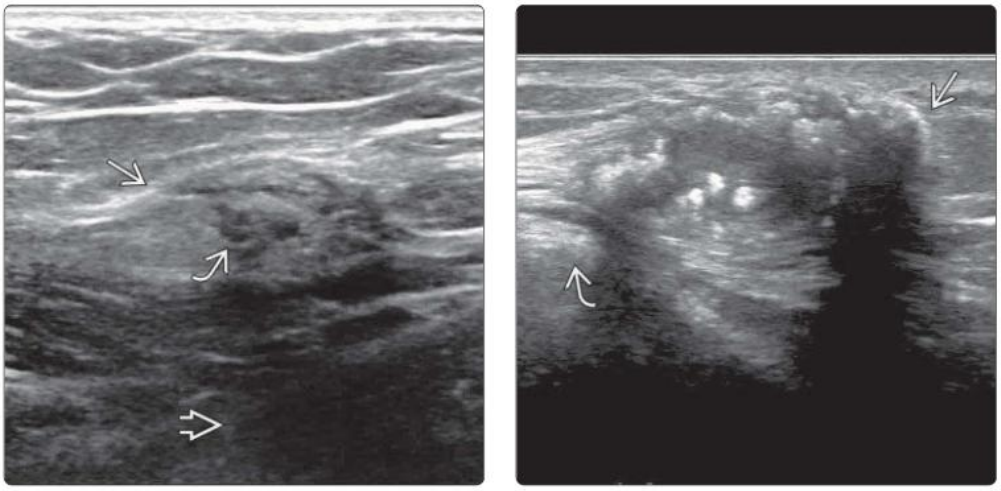

(Left) *Transverse US of the buttock shows a medium-sized, subcutaneous granuloma* ➡. *Hypoechoic areas* ⇨ *within granuloma most likely represent areas of more mature fibrous tissue. Mild acoustic shadowing* ⇨ *is present.* **(Right)** *Transverse US shows a medium-sized, partially calcified subcutaneous granuloma* ➡ *overlying the iliac crest* ⇨. *Calcification in injection granulomas is both peripheral and central, initially often punctate but tends to become coarser and more solid with increasing chronicity.*

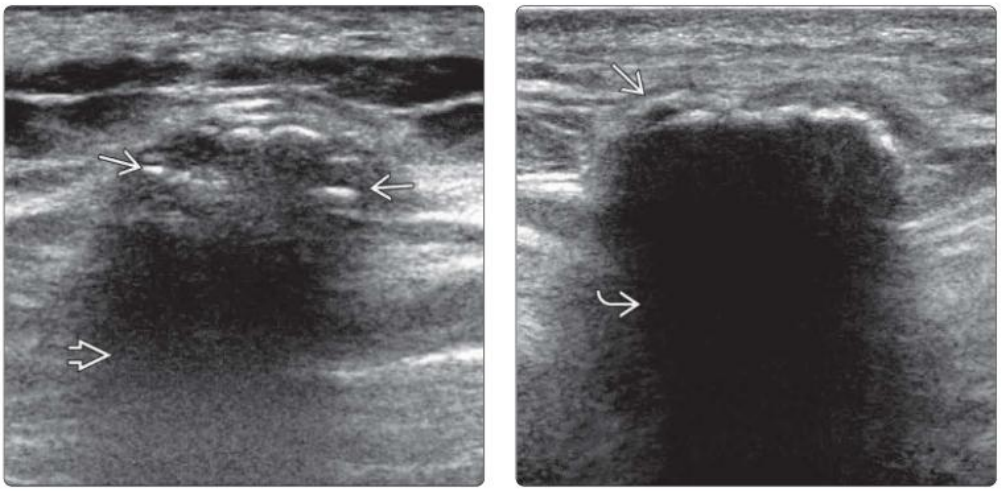

(Left) *Transverse US shows an injection granuloma of the buttock with several medium-sized, calcific foci* ➡ *and strong posterior acoustic shadowing* ⇨. *Injection granulomas show either no hyperemia or only minimal hyperemia on color Doppler imaging (not shown).* **(Right)** *Transverse US shows a rather large, heavily calcified granuloma* ➡ *in the upper outer quadrant of the buttock. There is dense acoustic shadowing* ⇨.

KEY FACTS

IMAGING

- Ultrasound
  - Accurate at differentiating between benign and malignant nodes
  - More accurate than CT and MR, provided that nodes are accessible to US assessment
  - Can guide percutaneous biopsy or FNA cytology (FNAC)
  - Appearances vary depending on whether node is normal, reactive, metastatic, lymphomatous, or infected (tuberculous or nontuberculous infection)
  - Important discriminatory criteria: Size, cortical thickness, nodal configuration, internal architecture, calcification, necrosis, vascular pattern, matting, and perinodal edema
  - Color Doppler to assess vascular pattern
  - Spectral analysis not usually helpful
  - US-guided core biopsy is preferable to FNAC for histologic or microbiologic assessment

TOP DIFFERENTIAL DIAGNOSES

- Nerve sheath tumor
- Vascular leiomyoma
- Vascular anomaly

CLINICAL ISSUES

- Reactive adenopathy: Mildly tender
- Metastatic, lymphomatous, and tuberculous nodes: Nontender
- Lymphadenitis: Very tender

DIAGNOSTIC CHECKLIST

- US nodal diagnosis formulated on relative strength of various US signs in conjunction with clinical presentation
  - US is accurate at determining presence and likely etiology of nodal pathology as well as need for biopsy, which is preferable to FNA
    - Biopsy nodal cortex and not fatty hilum

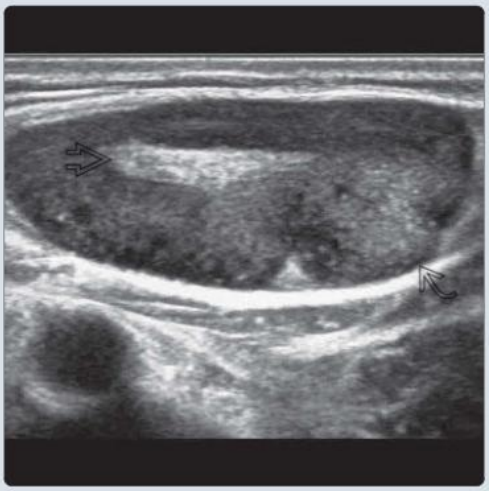

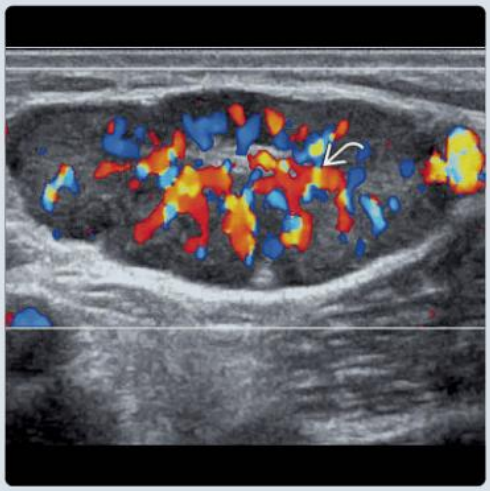

(Left) *Longitudinal US shows a reactive groin node in a patient with ipsilateral calcaneal osteomyelitis. The lymph node is elliptical in shape with moderate cortical thickening ⇨ and a distinctive central echogenic fatty hilum ⇨.* **(Right)** *Longitudinal color Doppler US of the same lymph node shows a normal hilar vascular flow pattern with branching intranodal vessels ⇨ extending from the hilum into the hypoechoic cortical parenchyma.*

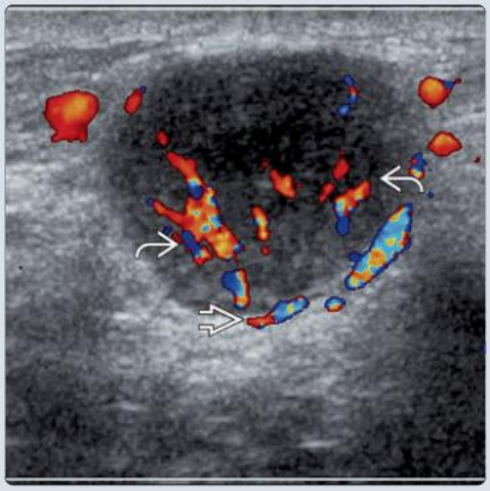

(Left) *Transverse US shows a diffusely hypoechoic malignant groin lymph node with complete loss of central fatty hilum. Note its focal irregular ill-defined borders, suggestive of extracapsular spread ⇨.* **(Right)** *Transverse color Doppler US of the same node shows chaotic capsular ⇨ and cortical parenchymal ⇨ vascular flow pattern. US-guided Franseen biopsy confirmed metastatic adenocarcinoma.*

TERMINOLOGY

Synonyms

- Lymphadenopathy, adenopathy, lymph node enlargement, lymphadenitis

Definitions

- Reactive node
  - Benign enlargement of node in response to antigenic stimuli, including infection and inflammation
- Metastatic node
  - Enlargement of node due to metastatic infiltration
- Lymphomatous node
  - Enlargement of node due to lymphoma infiltration
- Tuberculous node
  - Enlargement of node due to tuberculous infection
- Lymphadenitis
  - Inflamed node irrespective of etiology

IMAGING

General Features

- Best diagnostic clue
  - Enlargement of lymph node with thickened cortex ± altered nodal architecture
- Location
  - Any sites along lymphatic drainage
  - Head and neck > groin > axillae > elbow
- Size
  - ~ 3 mm to > 10 cm
- Morphology
  - Elliptical, oval, or rounded shape

CT Findings

- Reactive node: Central fatty hilum with hypodense peripheral cortex of variable thickness
- Malignant node: Solid soft tissue nodule with no identifiable fatty hilum
- ± intranodal cystic change, calcification, matting, or perinodal soft tissue inflammation
- Irregular cortical border indicates extranodal spread

Ultrasonographic Findings

- Accurate at differentiating between benign and malignant nodes
  - Reasonably accurate at identifying other nodal pathologies
  - More accurate than CT and MR, if nodes are accessible
  - Facilitates US-guided core biopsy (Tru-Cut or Franseen), which is preferable to FNA
- Size is important, but also consider
  - Nodal configuration, cortical thickness, internal architecture, calcification, necrosis, vascular pattern, matting, and perinodal edema
- **Reactive lymph node**
  - Normal node: Long axis < 8 mm
  - Reactive node: Long axis usually > 8 mm
  - Elliptical or ovoid in shape
    - Long- to short-axis length ratio > 2
  - Hypoechoic cortex compared with adjacent muscle
    - Variable cortical hyperplasia (thickening)
      - Leading to lobulated cortical contour
  - Preserved echogenic fatty hilum
  - Hilar vascularity on color Doppler imaging
    - Central hilar vessels branch radially into cortical parenchyma of node
- **Metastatic lymph node**
  - Effacement or replacement of echogenic fatty hilum
  - Thickened, hypoechoic cortex, typically > 1 cm thick
  - Long axis > 8 mm
    - Some malignant nodes have long axes of only 6-8 mm
  - Rounded shape
    - Long- to short-axis length ratio < 2
  - Usually well-demarcated border
    - Irregular, blurred contour suggests extranodal spread
  - ± punctate calcification depending on primary tumor
    - Calcification can be feature of chondroid, osteosarcoma metastases, papillary, or medullary thyroid carcinoma metastases
  - ± intranodal cystic change
    - Seen with squamous cell carcinoma and melanoma
    - Coagulative necrosis seen as echogenic foci/area
  - ± matting of adjacent nodes
    - Seen in malignancy > tuberculosis > lymphoma
  - Peripheral capsular vascularity or mixed hilar and peripheral vascularity
    - Presence of peripheral vascularity only is highly suspicious of metastases
    - Chaotic rather than regular vascular pattern
    - Impedance values (resistive index, pulsatility index) of limited value due to large overlap with reactive values
  - Shear wave elastography can aid differentiation between malignant and benign lymph nodes
    - Sensitivity 82%; specificity 80%; accuracy 81%
- **Lymphoma node**
  - Usually > 8 cm
    - Can be very large
  - Rounded in shape
    - Focal cortical infiltration → focal cortical thickening
  - Usually sharp border without extracapsular spread
    - Unsharp border suggestive of extracapsular spread and aggressive disease
  - Loss of normal echogenic hilum (75%), with exception of follicular lymphoma
    - Follicular lymphoma can have preserved fatty hilum but with prominent cortical thickening
  - Usually very hypoechoic
    - Uniform cellular infiltration within node produces few interfaces → good acoustic transmission → posterior acoustic enhancement
  - Intranodal reticular pattern with pseudocystic appearance
    - Thin, echogenic lines traversing hypoechoic node
      - More common in lymphoma than metastatic nodes
  - Calcification is rare; may be present after treatment
  - Cystic necrosis is uncommon
  - Chaotic mixed capsular and cortical hypervascularity
    - Peripheral vascularity alone is rare
  - Nodal size ↓ with treatment indicates good response
- **Tuberculous node**
  - Enlarged > 8 cm
  - Oval or rounded

- Hypoechoic nodes with intranodal necrosis
  - Posterior acoustic enhancement
- Matting of multiple nodes
- Perinodal soft tissue inflammation (periadenitis)
- Calcification
  - Seen after treatment, usually not seen in acute phase
- Variable vascular pattern
  - Preserved but displaced hilar vascularity (50%)
  - Absent hilar vascularity (20%)
  - Perinodal inflammation → capsular vascularity (12%)
- **Lymphadenitis**
  - Enlarged tender node with preservation of nodal architecture, hyperemia, ± liquefaction and prominent periadenitis

Imaging Recommendations

- Best imaging tool
  - High-resolution US
    - Nodes in neck, supraclavicular fossa, axilla, elbow, groin, and popliteal fossa are all accessible to examination by US
- Protocol advice
  - Grayscale to assess nodal size, shape, border, and internal architecture
    - Ensure all aspects of concerned location (e.g., axilla, groin) are examined
      - Normal nodes have predominant fatty hilum with thin cortex and are thus inconspicuous against axillary fat
    - Routinely examine external iliac nodes when examining inguinal nodes
      - Large elliptical subcutaneous node in proximal medial thigh (Cloquet node) is normal finding
    - Normal elbow (epitrochlear) and popliteal fossa nodes are not routinely visible
  - Color Doppler to assess pattern of vascularity
    - Use minimal transducer pressure
    - Spectral analysis not usually helpful
  - US-guided core biopsy preferable to FNA in obtaining microbiologic or histologic diagnosis
    - Enables assessment of nodal architecture rather than cellular content
    - Can use side-cutting or end-cutting needle

DIFFERENTIAL DIAGNOSIS

Nerve Sheath Tumor

- ± thickened entering and exiting nerve
- No echogenic fatty hilum

Vascular Leiomyoma

- ± peripheral converging vascularity
- No echogenic fatty hilum

Vascular Anomaly

- Irregular border
- Intrinsic variable vascular mesh

PATHOLOGY

General Features

- Etiology
  - Reactive node
    - Inflammation, infection, allergy, hemorrhage, inflammatory arthropathy, sarcoidosis
    - Castleman disease: Hypervascular lymphoid hyperplasia involving multinucleated giant cells
    - Kikuchi disease: Occurs in neck; histiocytic necrotizing lymphadenitis
    - Rosai-Dorfman disease: Typically occurs in neck; sinus histiocytosis
    - Kimura disease: Eosinophilic hyperplastic lymphogranuloma
  - Infection
    - Bacterial > viral > fungal or parasitic
      - *Mycobacterium avium-intracellulare*, *Mycobacterium scrofulaceum*, *Mycobacterium bovis*, and *Mycobacterium kansasii*
    - Cat-scratch disease: Regional adenopathy 7-14 days after cat scratch or bite; infection by *Bartonella henselae*
    - Bacille Calmette-Guérin (BCG) adenitis: Exaggeration of expected nodal response → regional lymphadenitis 2 weeks to 2 years after BCG vaccination
      - Most common complication of BCG vaccination
  - Metastases
  - Hematologic
    - Lymphoma (non-Hodgkin > Hodgkin) > leukemia

CLINICAL ISSUES

Presentation

- Most common signs/symptoms
  - Local swelling, tenderness, ± pain
  - Reactive adenopathy: Mildly tender
  - Metastatic, lymphomatous, and most tuberculous nodes: Nontender
  - Lymphadenitis: Very tender

Treatment

- Antiinflammatory agents or antibiotics (including antituberculous therapy) dependent on etiology
- Lymphoma: Systemic chemotherapy
- Metastatic: Surgery ± chemotherapy or irradiation

DIAGNOSTIC CHECKLIST

Consider

- US diagnosis should be based on conglomeration of several recognized US signs in conjunction with clinical presentation
  - US is overall accurate at determining presence and likely etiology of nodal pathology
- US-guided core biopsy is very helpful
  - More accurate than FNA
  - Biopsy nodal cortex and not fatty hilum

SELECTED REFERENCES

1. Chudobiński C et al: Enhancements in radiological detection of metastatic lymph nodes utilizing AI-assisted ultrasound imaging data and the Lymph Node Reporting and Data System Scale. Cancers (Basel). 16(8):1564, 2024
2. Yip SWY et al: Ultrasound-guided lymph node sampling: accuracy of FNAC, end-cutting (Franseen), and side-cutting (Temno) needle biopsy techniques. Clin Radiol. 77(6):466-73, 2022

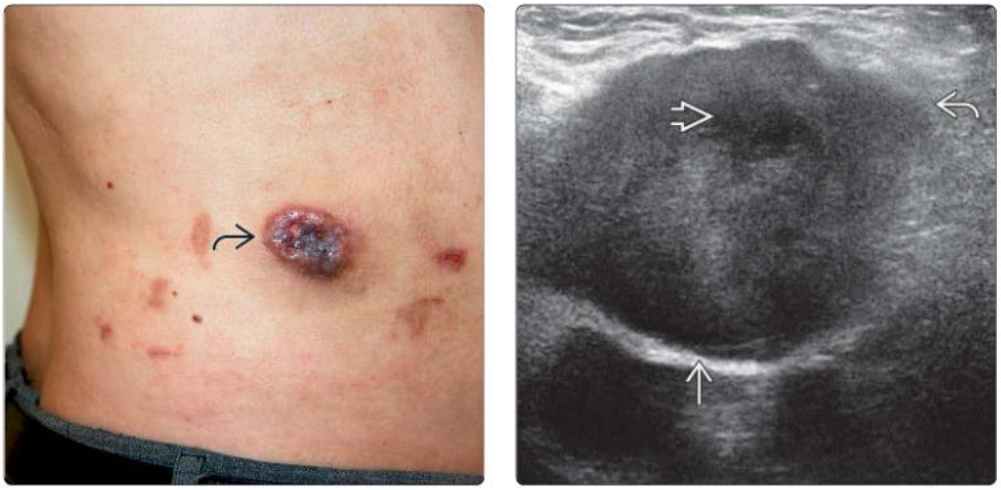

(Left) *Clinical photograph of flank region shows a malignant-looking skin lesion in a patient with a chronic, nonhealing skin ulcer. Histology revealed a high-grade adenocarcinoma with foci of sweat gland myoepithelial differentiation.* **(Right)** *Longitudinal US in the same patient shows an enlarged metastatic axillary node. The node is round with complete loss of the central fatty hilum. Note the mild intranodal necrosis and localized extracapsular spread.*

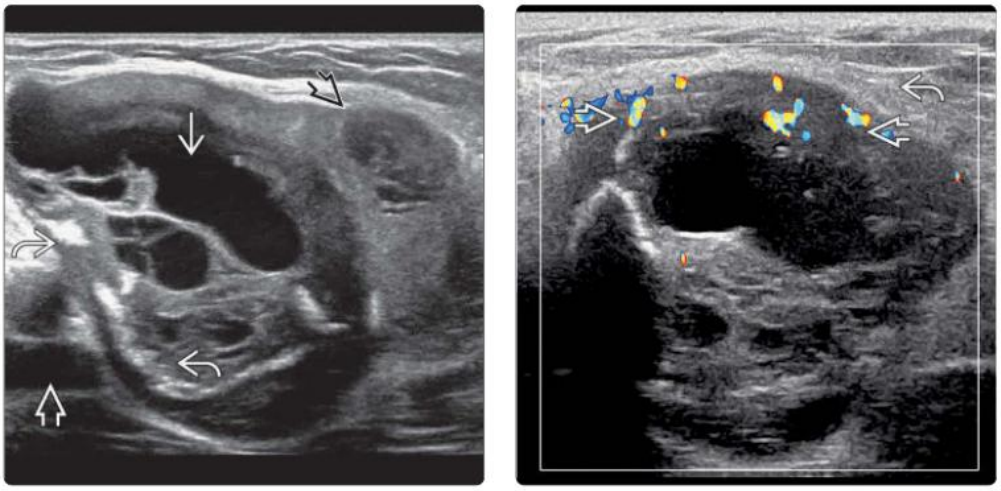

(Left) *Longitudinal US in a patient with telangiectatic-type osteosarcoma shows a metastatic groin node lateral to the femoral neurovascular bundle. There is a large cystic element with areas of mineralization and a 2nd discrete metastatic cortical focus.* **(Right)** *Transverse color Doppler US of the same node shows mild to moderate peripheral nodal vascularity. Mild perinodal soft tissue edema is present.*

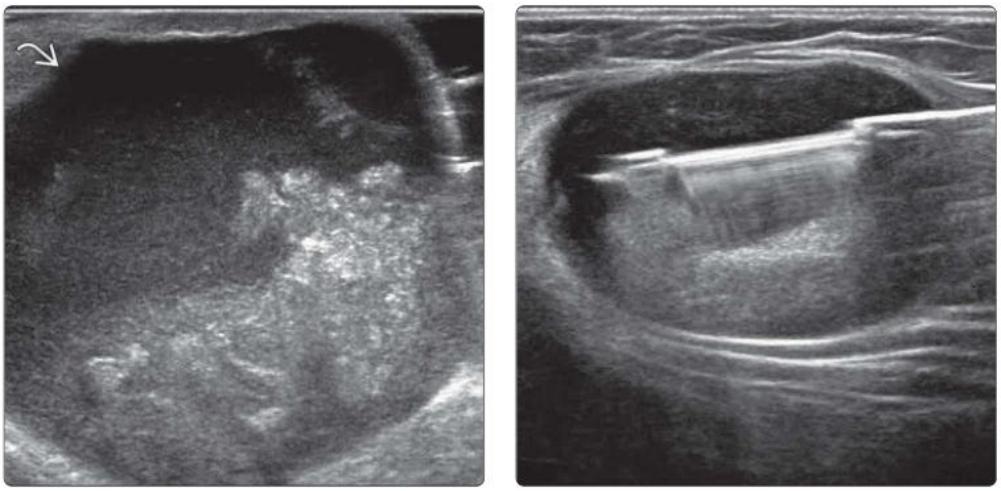

(Left) *Transverse US of the groin in a patient with vulval carcinoma shows a partially cystic metastatic lymph node. Intranodal cystic change is seen in metastases from squamous cell carcinoma or melanoma.* **(Right)** *Transverse US during US-guided core biopsy of a groin lymph node in a patient with a suspicious ovarian mass. Histology revealed metastatic adenocarcinoma consistent with an ovarian primary. If feasible, biopsy targeting the cortex is preferred over FNA cytology.*

(Left) *Transverse US of a non-Hodgkin lymphoma groin node shows a thickened cortex with many fine reticulations, moderate posterior acoustic enhancement, and a partially effaced fatty hilum, all of which are features of lymphomatous nodes.* **(Right)** *Doppler US of the same node shows a prominent hilar vascular flow pattern with branching vessels extending into the thickened cortical parenchyma. Lymphoma nodes can have a preserved normal pattern of hypervascularity.*

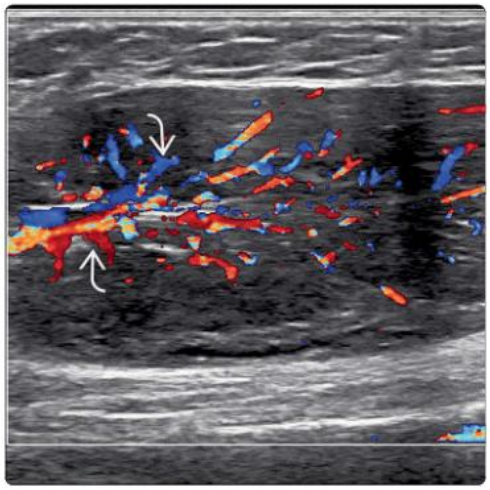

(Left) *Longitudinal US of an enlarged groin lymph node in Hodgkin lymphoma is shown. Hodgkin lymphoma nodes are often well-defined, rounded, and have internal reticulations. Unlike metastatic nodes, internal cystic or calcific components are rare in treatment-naive lymphoma nodes.* **(Right)** *Longitudinal power Doppler US in a patient with non-Hodgkin lymphoma shows a reticulated thickened cortex with moderate central and peripheral vascularity. Note the extracapsular extension, which indicates aggressive disease.*

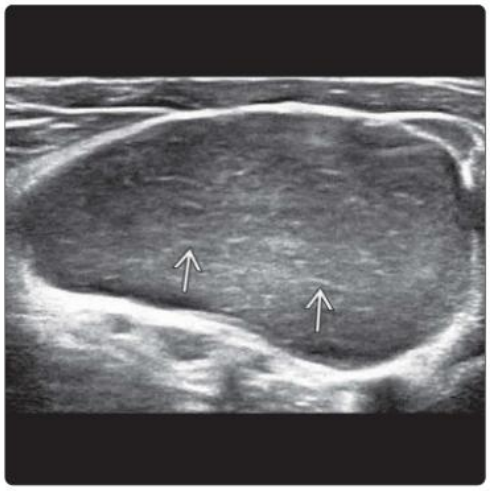

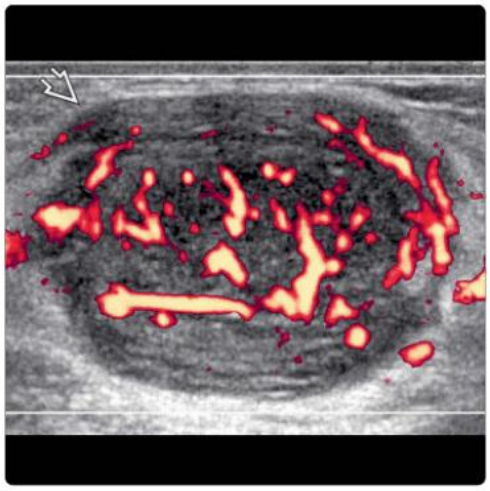

(Left) *Longitudinal US in a 70-year-old woman shows an enlarged axillary lymph node with markedly thickened cortex and a preserved though eccentrically displaced fatty hilum.* **(Right)** *Color Doppler US of same node shows moderate increased vascularity that still follows a preserved radiating pattern. US-guided biopsy revealed follicular lymphoma. Follicular lymphoma nodes can mimic reactive nodes. Radiologists should have a low threshold for biopsy of nodes with prominent cortical thickening, particularly if > 1 cm.*

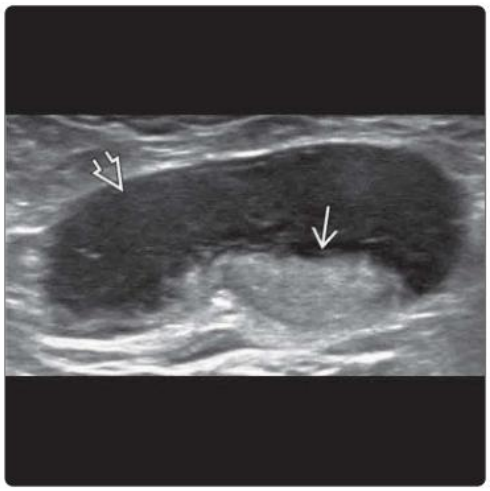

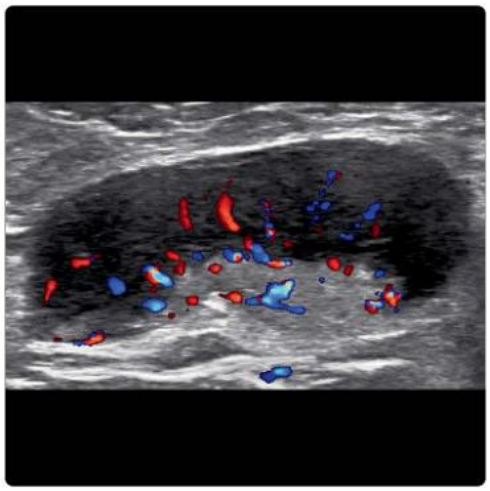

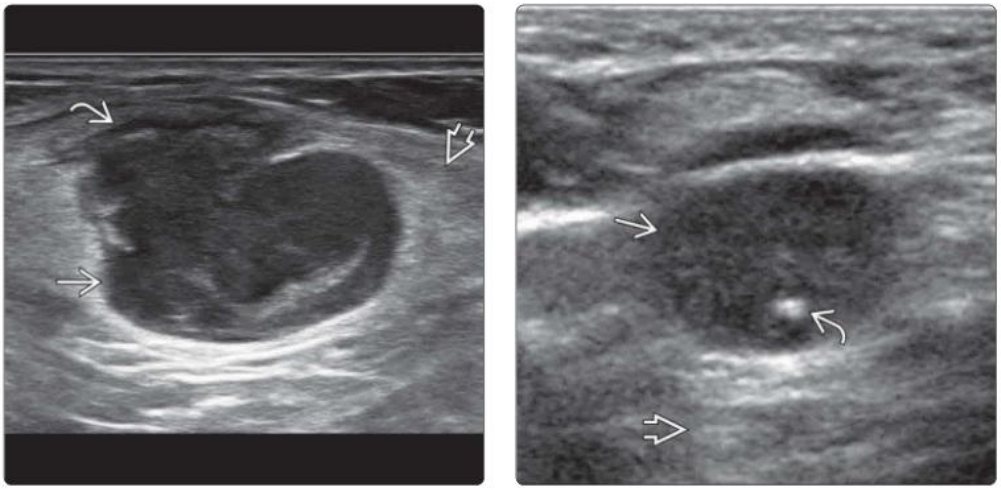

(Left) *Longitudinal US shows an active tuberculous groin lymph node ➡ with eccentric cortical thickening and irregular extracapsular soft tissue ➡ due to previous rupture of an intranodal abscess. Moderate perinodal soft tissue edema ➡ is present.* **(Right)** *Transverse US shows an enlarged roundish node ➡ with a small focus of eccentric calcification ➡ in a 4-year-old boy. Mild posterior acoustic enhancement ➡ is present. This is due to healing tuberculous adenitis. Nodal calcification is not seen in acute tuberculous adenitis.*

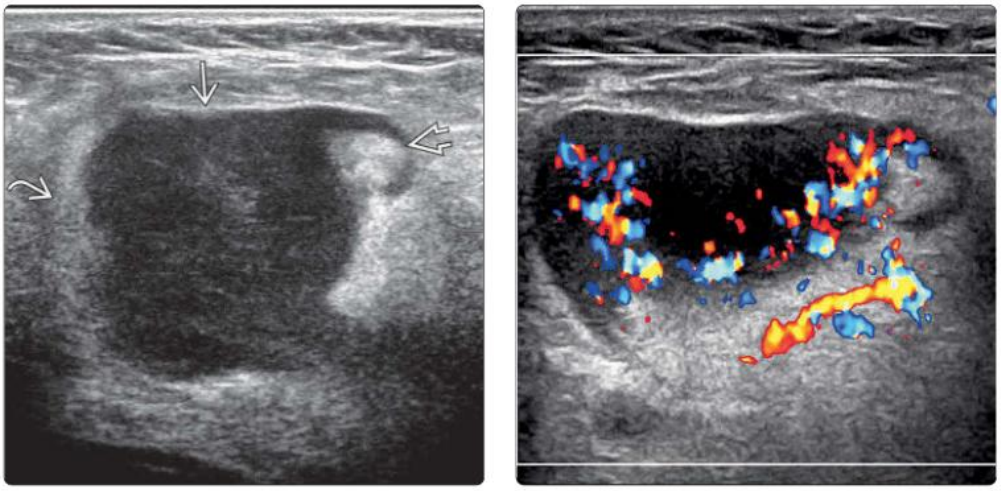

(Left) *Transverse US of the axilla in a patient with ipsilateral soft tissue infection shows a solitary enlarged lymph node ➡ in the central part of the axilla. The lymph node is diffusely enlarged with marked cortical hyperplasia and eccentric displacement of fatty hilum ➡. Severe perinodal soft tissue inflammation ➡ is present.* **(Right)** *Transverse color Doppler US of the same lymph node shows marked intranodal hyperemia consistent with lymphadenitis. No liquefaction or abscess formation is present.*

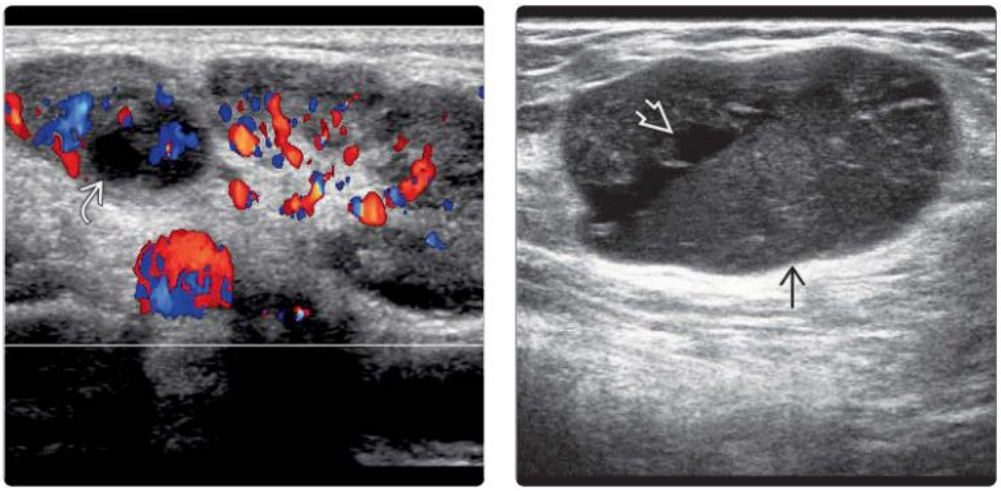

(Left) *Longitudinal color Doppler US shows groin lymphadenitis. A small cortical cystic component ➡ consistent with focal suppuration is present. Mild perinodal soft tissue edema is present.* **(Right)** *Longitudinal US shows a metastatic groin lymph node ➡ in a patient with squamous cell carcinoma of the vulva. Moderate intranodal cystic component ➡ is present. Nodal cystic degeneration is a common feature in squamous cell metastases.*

KEY FACTS

TERMINOLOGY

- Malignant tumor arising from connective (mesenchymal) tissue other than bone

IMAGING

- Of patients referred for US, 1.5% of superficial & 7% of deep tumors are malignant
- Large well-defined mass
  - Determine presence of tumor, characteristics, & extent
  - ± myxoid tissue, necrosis, hemorrhage, or calcification
  - Neurovascular encasement
- Mostly hypervascular though may be hypovascular or avascular
- Utilize specific US criteria to recognize malignancy
  - Tumor growth
  - Older patient
  - > 2 cm if superficial, > 3 cm if deep
  - Roundish shape
  - Hyperemia with chaotic vascular pattern
  - Lack of similarity with known US appearances of particular benign soft tissue masses
- Can recognize malignancy with
  - 93% sensitivity, 98% specificity for superficial masses
  - 97% sensitivity, 58% specificity for deep masses
- MR better than US at defining extent of large tumors, particularly neurovascular involvement & deep extent
- Perform US-guided biopsy of all suspicious masses
  - Biopsy subcapsular & vascularized areas

TOP DIFFERENTIAL DIAGNOSES

- Benign soft tissue tumor
- Muscle hematoma

DIAGNOSTIC CHECKLIST

- Consider STS in all growing, soft tissue tumors with appearances not typical of any known benign tumor
- Do not label any tumor as definitively benign unless confident diagnosis can be made based on US appearances

(Left) *Clinical photograph of an adult patient shows an arm mass ⇨ that had been slowly growing for 2 years.* **(Right)** *Transverse US in the same patient shows a large, well-defined, mixed cystic/solid tumor within the biceps brachii muscle. Low-level echoes ⇨ consistent with hemorrhage are present within the large cystic area with some additional anechoic cystic spaces ⇨. Unlike a bone tumor, a well-defined border in a soft tissue tumor does not favor benignity.*

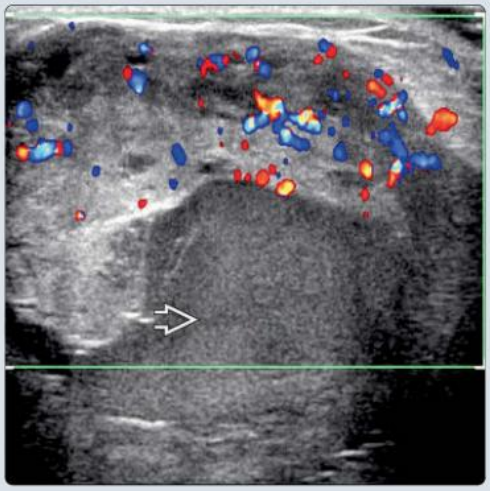

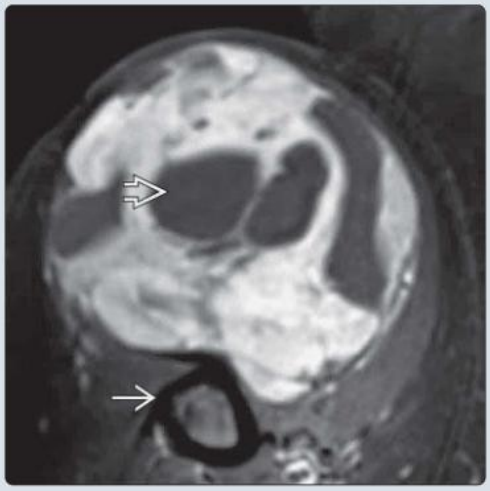

(Left) *Transverse color Doppler US of the same tumor shows moderate hypervascularity in the solid component of the tumor. The cystic area ⇨ is avascular. US-guided biopsy was performed.* **(Right)** *Transverse T1 C+ FS MR of the same tumor shows avid tumoral enhancement with nonenhancing cystic areas ⇨. The tumor contacts the humerus ⇨. No cortical erosion or intramedullary extension is evident. Histology revealed a synovial sarcoma.*

TERMINOLOGY

Abbreviations

- Soft tissue sarcoma (STS)

Synonyms

- Malignant soft tissue tumor

Definitions

- Malignant tumor arising from connective (mesenchymal) tissue other than bone

IMAGING

General Features

- Best diagnostic clue
  - Large, deep soft tissue mass
- Location
  - Lower extremity (45%) > trunk (30%) > upper extremity (20%) > head & neck (5%)
    - Of patients referred for US assessment, 1.5% of superficial & 7% of deep tumors are malignant
- Size
  - Variable
- Morphology
  - Heterogeneous, usually encapsulated mass

Ultrasonographic Findings

- Large, heterogeneous, hypoechoic mass
  - Usually located in deep (subfascial) tissues
  - Well encapsulated, though pseudocapsule is not usually seen as distinct structure
- Margin: Most STSs will have well-defined margins; infiltrative margins suggest aggressive fibromatosis, lymphoma, & inflammatory masses
- Myxoid tissue: Well-defined, intratumoral anechoic or hypoechoic areas
- Necrosis: Poorly defined, more centralized anechoic or hypoechoic areas
- Calcification: Discrete, echogenic foci with posterior acoustic shadowing
  - e.g., liposarcoma (5%), pleomorphic undifferentiated sarcoma (10%), synovial sarcoma (30%)
- Hemorrhage: Ill-defined, intratumoral, echogenic areas without acoustic shadowing; fluid levels
- Usually hypervascular with disorganized vascular pattern on color Doppler imaging
  - May be hypovascular or avascular
    - Large, deep-seated sarcomas often show minimal or no vascularity on color Doppler imaging
- Well-differentiated liposarcoma has US characteristics similar to superficial lipoma though it tends to be larger, deep (subfascial), & growing clinically
  - Perform MR in all deep-seated lipomatous masses to help characterization, delineate extent, & act as baseline for follow-up
- Myxoid liposarcoma can resemble cysts & should not be confused with paraarticular ganglia, myxoma, or bursae
- US features of malignancy
  - Progressive tumor growth clinically, particularly if rapid growth & patient has known malignancy
  - Middle-aged or older patient
  - Medium-sized or larger tumor (> 2 cm if superficial, > 3 cm if deep)
  - More rounded, rather than elongated tumor shape
  - Moderate to severe hyperemia if superficial, mild to moderate hyperemia if deep
  - Chaotic, rather than organized, vascular pattern
  - Lack of similarity with known US appearances of particular benign soft tissue masses
- These US criteria can help recognize malignancy with
  - 93% sensitivity, 98% specificity for superficial soft tissue masses
  - 97% sensitivity, 58% specificity for deep soft tissue masses
  - Sensitivity more relevant than specificity in this context
- If possibility of malignancy, proceed to percutaneous biopsy
- Currently, elastography, spectral analysis, or CEUS not particularly helpful in STS assessment

MR Findings

- Large, well-defined soft tissue mass
- Other than liposarcoma, fat within tumor indicates benignity
- MR better than US at defining extent of large tumors, particularly neurovascular involvement & deep extent

Imaging Recommendations

- Best imaging tool
  - US followed by MR
- Protocol advice
  - Determine presence of tumor, characteristics, & extent
    - Identify which compartment is involved
  - Determine relationship to neurovascular bundle & bone
    - Neurovascular bundle may be either separate from, in contact with, or encased (partially or completely) by tumor
  - Evaluate regional nodes
    - Undertake biopsy, if suspicious
  - MR is better than US at defining extent of large, deep tumors & at characterizing malignant features in large lipomatous masses
  - Final diagnosis depends on histology of biopsy tissue
    - Perform US-guided biopsy of all suspected STSs, including well-differentiated liposarcoma
      - Molecular testing for amplification of *MDM2* gene region via FISH is 100% sensitive & specific on core needle biopsy sample at differentiating well-differentiated liposarcoma
  - US-guided biopsy for histology
    - Try not to transgress nonaffected compartment with biopsy needle
    - 16-g Tru-Cut core biopsy needle with 15-g coaxial system suitable for tissue typing & histologic staging
      - Coaxial needle tip placed just deep to tumor margin facilitates directional change
    - Obtain at least 3 good cores from solid areas of tumor
      - Obtain some samples from immediate subcapsular areas, as many STSs have central necrosis
      - Hyperemia on color Doppler imaging helps to identify viable tumor areas
      - FNAC is not sufficient for diagnosis, detecting residual disease, or recurrence

DIFFERENTIAL DIAGNOSIS

Benign Soft Tissue Tumor

- Most benign soft tissue tumors have characteristic appearance on US

Muscle Hematoma

- History of trauma/anticoagulant medication/bleeding tendency
  - Some tumors may bleed & present as muscle injury
  - Undertake further investigation (MR or PET imaging), follow-up, or biopsy if suspicious

Fibromatosis

- Soft tissue mass of variable echogenicity, though usually hypoechoic with absent or mild vascularity on color Doppler imaging
- Irregular margins

Muscle Metastasis

- Uncommon
- Smaller & less well-defined than STS ± more peritumoral edema
- Majority will have known primary tumor

Abscess or Inflammatory Mass

- WCC increased, fever

PATHOLOGY

General Features

- Etiology
  - Idiopathic
  - Radiation induced
- Classified according to tissue type rather than anatomical origin
- Most STSs are histologically high grade
- Grow centrifugally from single focus
  - Pseudocapsule formed by compression of adjacent connective tissues
  - Reactive zone peripheral to pseudocapsule may contain tiny tumor extensions ("pseudopods")
    - May detach to give satellite nodules
- STS respects fascial & anatomical boundaries
  - Usually grows within compartment of origin
  - Involvement of > 1 compartment & bone/neurovascular bundle invasion indicative of aggressive tumor

Staging, Grading, & Classification

- Histological grading (as high, intermediate, or low grade) depends on
  - Degree of cellularity, cellular pleomorphism & level of dedifferentiation, mitotic activity, degree of necrosis, & infiltrative growth

Gross Pathologic & Surgical Features

- Myxoid accumulation, hemorrhage, necrosis, pseudocapsule

Microscopic Features

- Liposarcoma
  - Well-differentiated variety: 40%
    - Thick (> 2 mm) septations, nodular areas of nonlipomatous tissue
  - Myxoid variety (40%), round cell variety (10%), pleomorphic variety (5%), dedifferentiated variety (5%)
- Synovial sarcoma
  - Monophasic: 60%; mesenchymal spindle cell predominates
  - Biphasic: 20%; mesenchymal spindle cell & epithelial components
  - Poorly differentiated: 20%; high mitotic activity with necrosis
- Lack of calcification on CT is poor prognostic sign along with increased patient age, higher tumor grade, & large tumor size

CLINICAL ISSUES

Presentation

- Most common signs/symptoms
  - Painless soft tissue mass enlarging over several months
- Clinical profile
  - Often indistinguishable from benign tumor

Demographics

- Age
  - Peak: 50 years
- Epidemiology
  - < 1% of adult cancer; 6% of childhood cancer
  - 50 different soft tissue sarcomas
    - Liposarcoma, undifferentiated pleomorphic sarcoma, leiomyosarcoma, myxofibrosarcoma & synovial sarcoma account for 75% of cases
    - Malignant nonsarcomatous tumors are metastases & lymphoma

Natural History & Prognosis

- Depends on histological grade & surgical resectability
  - 50% of high-grade tumors develop metastases despite adequate treatment
    - < 10% of patients with metastases survive > 2 years
- Local recurrence rate: ~ 10% for limb or limb-girdle STS
  - 80% of recurrences occur within 2 years of surgery

Treatment

- ~ 80% of adult STSs are chemoresistant
- Surgical resection with wide margin
- ± adjuvant radiotherapy to tumor bed

DIAGNOSTIC CHECKLIST

Consider

- STS in any rapidly growing soft tissue mass that does not conform to known benign characteristics

Image Interpretation Pearls

- Nearly all STSs are well defined (i.e., sharp border does not equate to benign tumor)
- Do not label any tumor as benign based on US appearances unless confident about diagnosis

SELECTED REFERENCES

1. Griffith JF: Practical approach to ultrasound of soft tissue tumors and the added value of MRI: how I do it. J Ultrason. 23(95):e299-312, 2023

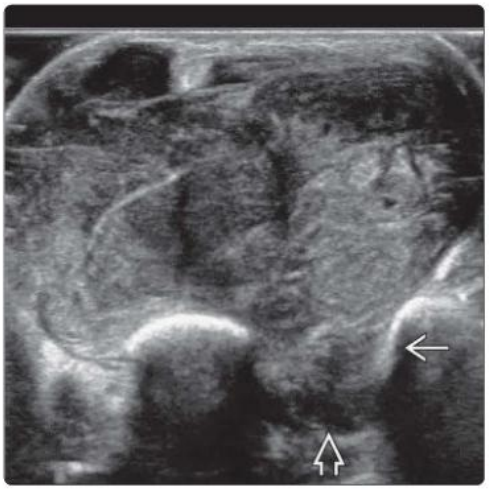

(Left) *Clinical photograph shows a large mass on the dorsum of the hand. The mass had grown rapidly over the past year.* **(Right)** *Transverse US in the same patient shows a large soft tissue mass on the dorsum of the hand extending deep between the 4th and 5th metacarpal bones. Smooth bony scalloping is present on the ulnar side of the 4th metacarpal shaft. This scalloping may be due to pressure remodeling or bony resorption. It does not necessarily imply malignancy.*

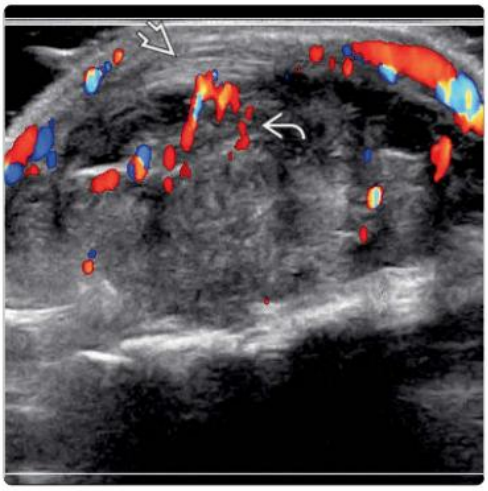

(Left) *Longitudinal color Doppler US of the same mass shows moderate hyperemia. The mass has arisen deep to the extensor tendons, which are displaced superficially.* **(Right)** *Frontal radiograph in the same patient shows a large soft tissue mass with a long area of smooth, bony scalloping with cortical thinning of the 4th metacarpal bone deep to the large soft tissue mass. Radiographs show the degree and type of bony erosion better than US.*

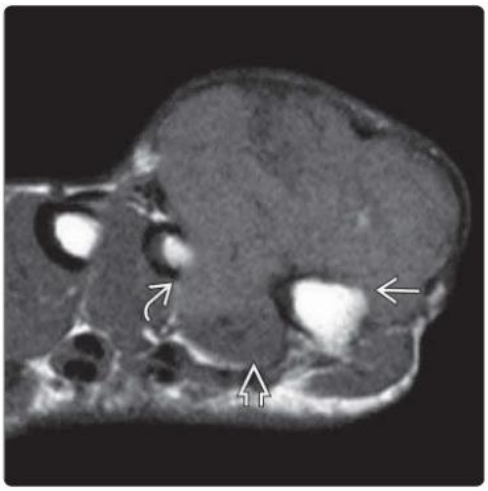

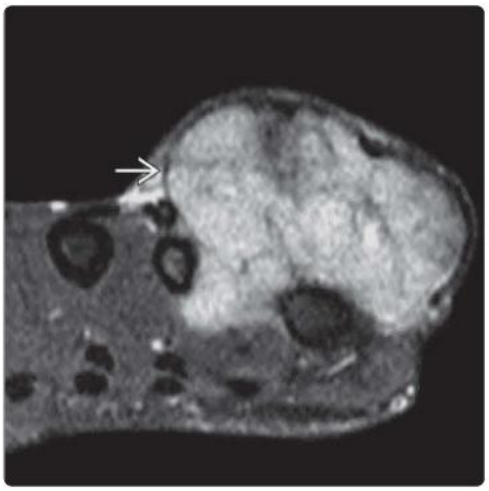

(Left) *Transverse T1 FS MR of the same tumor shows the soft tissue mass extending deeply between the 4th and 5th metacarpal bones. Note how the bony scalloping or erosion of the 4th and 5th metacarpal bones is more apparent than on US.* **(Right)** *Transverse T1 C+ FS MR of the same tumor shows significant enhancement. Percutaneous biopsy for histology revealed a clear cell sarcoma.*

(Left) *Longitudinal US of a young adult patient with a painless thigh swelling for 1 month shows a well-defined, oval-shaped, homogeneous, hypoechoic soft tissue mass* ➡ *within the vastus intermedius muscle. No calcification or cystic change is present. The underlying femoral shaft* ➡ *is normal.* **(Right)** *Longitudinal color Doppler US of the same tumor shows mild, intratumoral hyperemia* ➡.

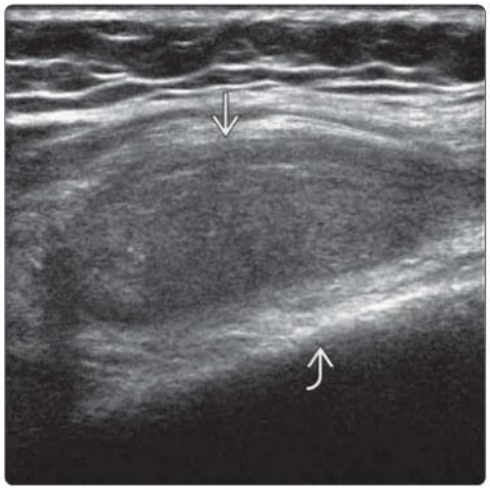

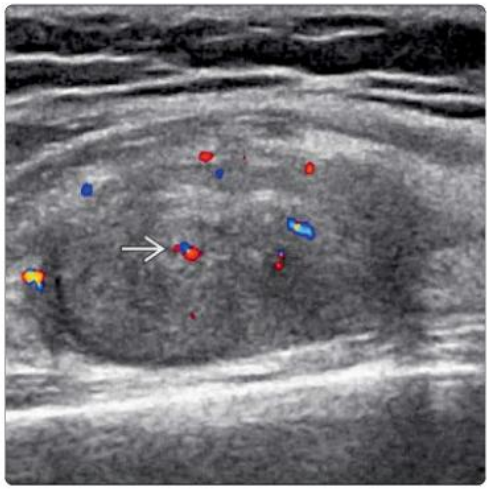

(Left) *Longitudinal US elastography of the same tumor shows variable tumoral elasticity. Red color represents stiff tissue, while blue color represents normal soft tissue. Elastography for soft tissue tumor currently does not appreciably help over standard US assessment. Histology revealed a fibromyxoid tumor of intermediate malignancy.* **(Right)** *Transverse US in a 60-year-old man with a popliteal mass shows a homogeneous echogenic mass* ➡ *deep to the biceps femoris muscle* ⇨ *and superficial to the popliteal vessels* ➡.

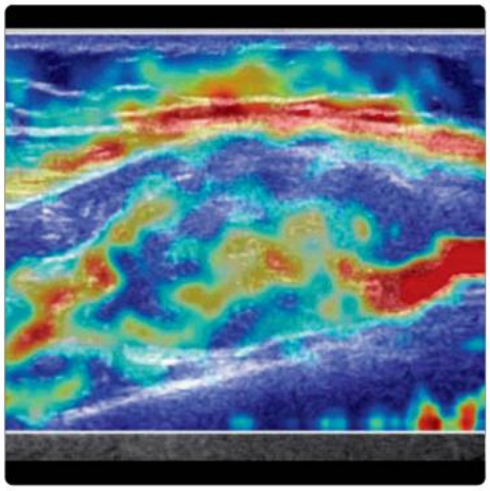

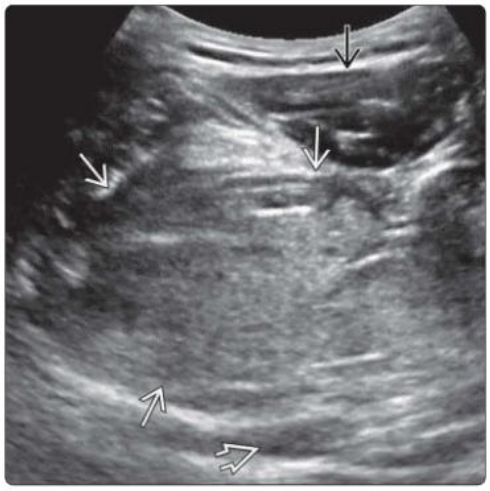

(Left) *Longitudinal US in the same patient shows a largely echogenic lipomatous-type mass* ➡, *though without the typical US appearances of a lipoma. The mass is large and deep with infiltrative margins* ➡ *and is suspicious of liposarcoma.* **(Right)** *MR shows the lipomatous tumor* ➡ *is situated alongside the popliteal vessels* ➡ *and deep to the biceps femoris muscle* ➡. *The mass has a large nonlipomatous component* ⇨. *Pathology revealed a liposarcoma (F = femur).*

(Left) *Clinical photograph of a patient with known neurofibromatosis shows several small cutaneous neurofibromas. There is a large plantar swelling that had been growing for 6 months.* **(Right)** *Transverse US of the same swelling shows a large, heterogeneous soft tissue tumor mass on the plantar aspect of the foot extending dorsally between the metatarsal bones. Small intratumoral cystic spaces are present.*

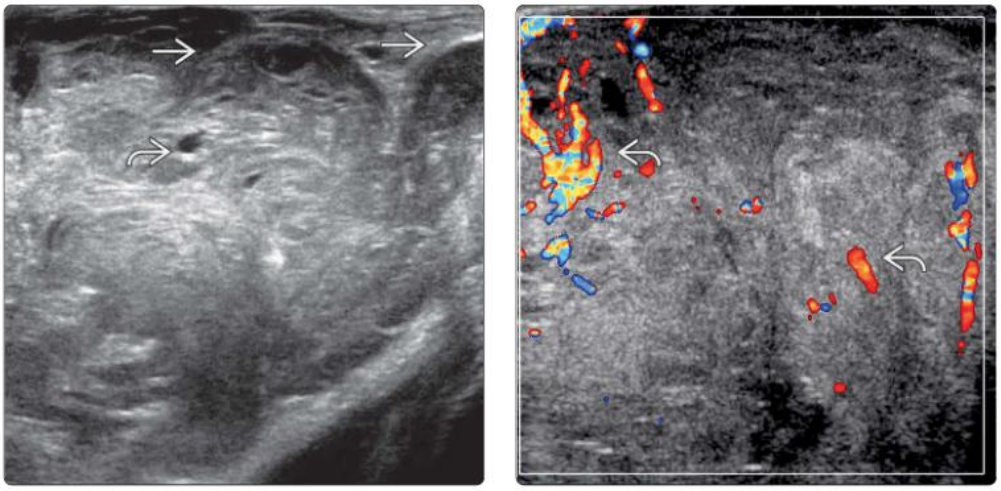

(Left) *Longitudinal US of the same tumor shows the lobulated tumor margin with small intratumoral cystic areas.* **(Right)** *Transverse color Doppler US of the same tumor shows moderate hypervascularity throughout the mass. Percutaneous biopsy for histology revealed a malignant peripheral nerve sheath tumor (MPNST).*

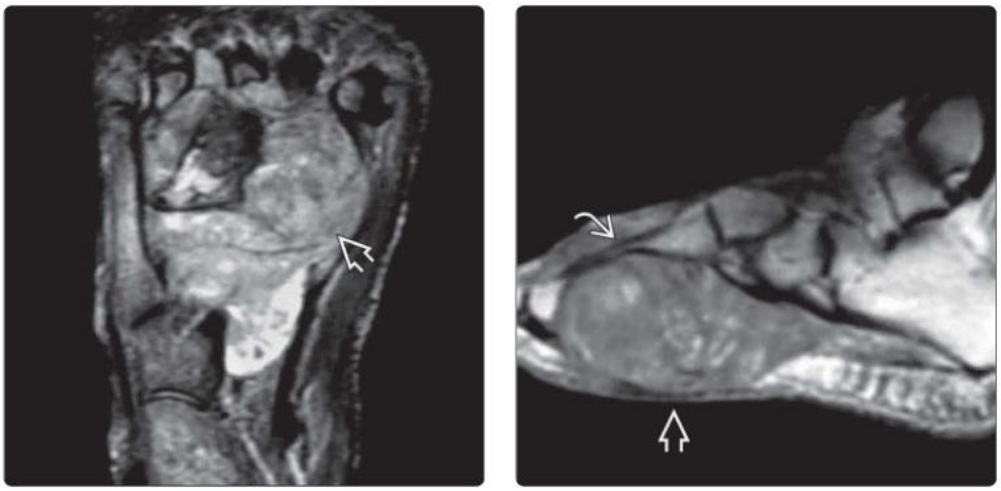

(Left) *Axial T2 FS MR of the same tumor clearly shows the extent of this large tumor on the plantar aspect of the forefoot and midfoot.* **(Right)** *Sagittal T1 MR of the same tumor shows the large plantar mass indenting the 4th metatarsal bone. MR is better than US at showing the extent of large tumors, particularly in complex anatomical areas, such as the foot. The subcutaneous tissue is infiltrated by tumor.*

(Left) *Clinical photograph shows a 3-cm mass on the radial aspect of the wrist that had been growing slowly for 3 years. Clinically, the mass was suspected to be a soft tissue neoplasm.* **(Right)** *Longitudinal US of the same swelling shows a well-circumscribed oval-shaped soft tissue mass with homogeneous hypoechoic echogenicity inseparable from the extensor pollicis longus (EPL) deep to the tumor. No calcification or cystic component is present. This was suspicious of a giant cell tumor of tendon sheath (GCTTS).*

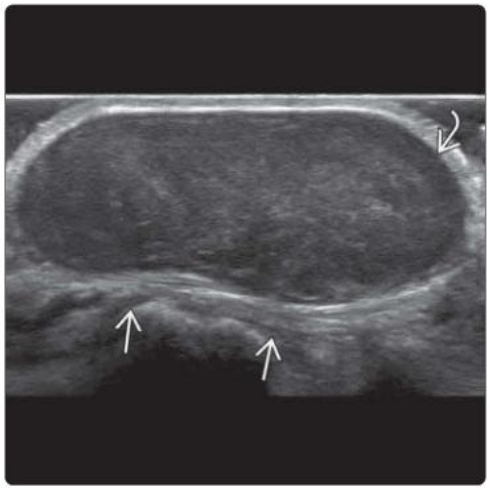

(Left) *Longitudinal color Doppler US of the same tumor shows moderate tumoral hypervascularity.* **(Right)** *Longitudinal US-guided needle biopsy was performed. Histology revealed fascicles of spindle cells and immunostaining positive for SMA, desmin, calponin, and caldesmon, compatible with smooth muscle neoplasm leiomyosarcoma.*

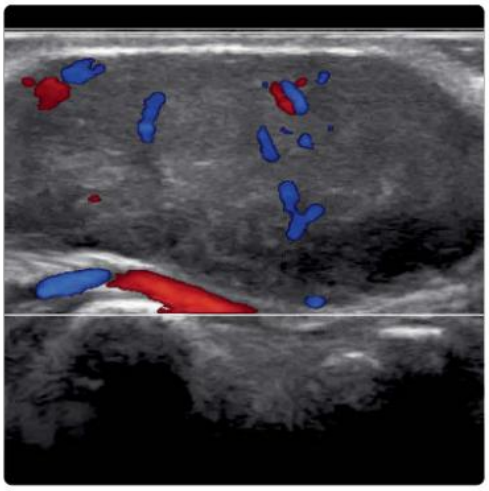

(Left) *Clinical photograph shows a nodule present on the dorsum of the 2nd toe growing slowly for 6 months.* **(Right)** *Longitudinal US of the same mass shows a hypervascular hypoechoic mass over the proximal phalanx extending from the skin to the extensor digitorum tendon. Possibilities were dermatofibrosarcoma protuberans (DFSP) or GCTTS. Biopsy sample confirmed DFSP.*

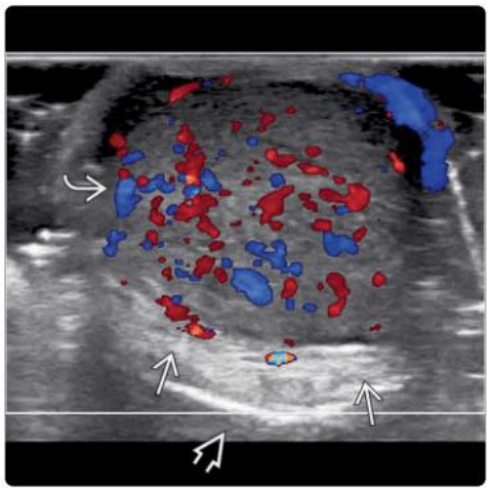

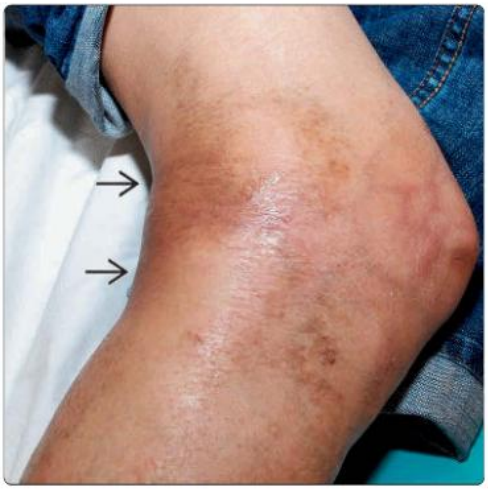

(Left) *Clinical photograph shows a large popliteal fossa swelling ⇨ that had been growing rapidly for 3 months.* **(Right)** *Transverse US of the same swelling shows a large, heterogeneous tumor mass ⇨ partially encasing the popliteal artery ⇨. The popliteal vein overlying the artery is compressed by the tumor and is not seen. US-guided biopsy for histology revealed a leiomyosarcoma.*

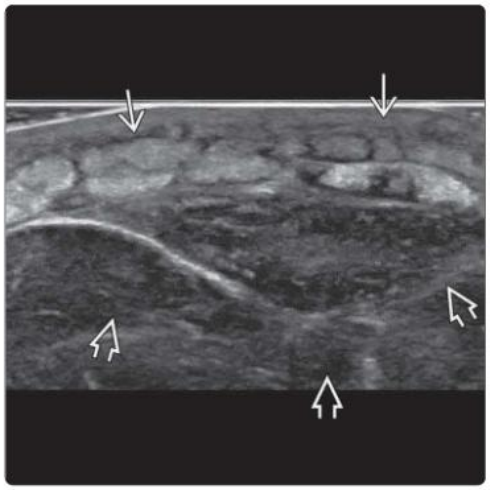

(Left) *Clinical photograph of the ankle region in a patient with history of nasal lymphoma and breast carcinoma shows bilateral tender ankle masses ⇨ that had been present for 5 months. Metastases were suspected clinically.* **(Right)** *Transverse US of one ankle shows an ill-defined infiltrative lesion mainly within the subcutaneous tissue ⇨ but also involving the underlying muscle layer ⇨. The US appearances favored lymphoma.*

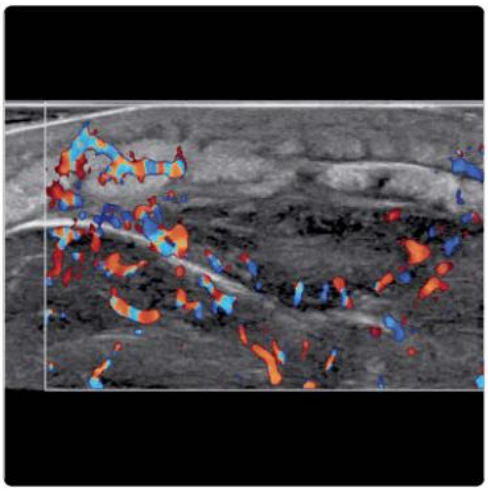

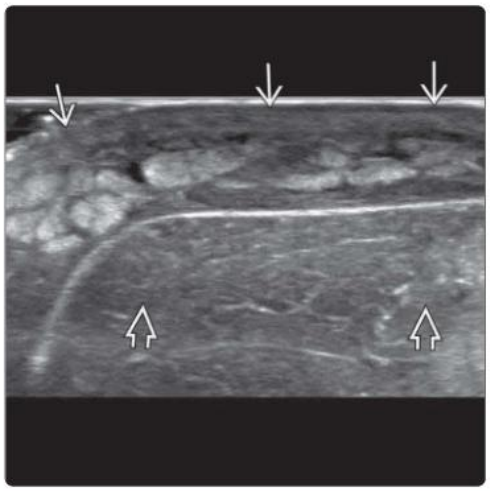

(Left) *Transverse color Doppler US of the same region shows moderate to severe hyperemia of the muscle more than the subcutaneous tissues.* **(Right)** *Transverse US of the contralateral ankle shows an infiltrative subcutaneous lesion ⇨ sparing the underlying muscle ⇨. Overall appearances favored lymphomatous infiltration rather than metastatic carcinoma. Biopsy revealed atypical lymphoid cells, positive for B-cell marker, CD20 and BCL2, compatible with diffuse large B-cell lymphoma.*

KEY FACTS

TERMINOLOGY

- Bone tumor: Neoplastic growth of tissue in bone
- Benign tumor: Tumor that does not metastasize
- Malignant tumor: Tumor that does metastasize
- Primary bone tumor: Tumor arising de novo in bone
- Secondary bone tumor: Tumor spreading to bone from malignant primary tumor located elsewhere

IMAGING

- US is not routinely used in standard work-up of bone tumors
  - Helpful as problem solver in particular instances
  - Used to guide biopsy of accessible bone tumors
- US can assess
  - Nature of juxtacortical soft tissue
  - Extraosseous component, cortical surface osteolysis, or intramedullary tumor if breached cortex
  - Tumor matrix (if cortex is breached)
  - Lymph node metastases (rare)
  - Bone tumor recurrence
- Radiography is most useful 1st-line investigation
  - Radiographic abnormality apparent in nearly all symptomatic bone tumors
  - Used to characterize tumor type & broadly grade aggressiveness of bone tumors
- MR used for
  - Local staging of bone sarcoma ± assessing treatment response
  - Characterizing & further evaluating benign bone tumors

TOP DIFFERENTIAL DIAGNOSES

- Osteomyelitis
- Healing insufficiency fracture

DIAGNOSTIC CHECKLIST

- Consider bone origin in any juxtacortical soft tissue mass
- Particularly in pelvis, scan symptomatic bone areas for unsuspected pathology

(Left) *Frontal radiograph in a skeletally immature child with a 4-week history of wrist pain and swelling shows mild permeative osteolysis ⇨ of the distal radial metaphysis, indicative of an aggressive bone lesion. There is a faint periosteal reaction ⇨.* **(Right)** *Sagittal T2* GRE MR in the same patient the following day shows an aggressive bone tumor ⇨ of the distal radial metaphysis with a surprisingly large, extraosseous component. The tumor clearly extends beyond the physis.*

(Left) *Longitudinal US of the same lesion shows hypoechoic tumor matrix with radiating spicules ⇨ of new bone, suggestive of an osteogenic tumor. There is an ultrasonic Codman triangle ⇨ at the proximal end of the tumor.* **(Right)** *Longitudinal color Doppler US shows mild marginal hyperemia. Note the radiating spicules of bone ⇨. This finding is seen in various bone tumors and is not unique for osteosarcoma, though US-guided biopsy (not shown) did reveal osteosarcoma in this case.*

TERMINOLOGY

Definitions

- Bone tumor: Neoplastic growth of tissue in bone
- Benign tumor: Tumor that does not metastasize
- Malignant tumor: Tumor that does metastasize
- Primary bone tumor: Tumor arising de novo in bone
- Secondary bone tumor: Tumor spreading to bone from malignant primary tumor located elsewhere (= bone metastasis)
  - Secondary chondrosarcoma/osteosarcoma refers to sarcoma arising from preexisting benign bone lesion, such as osteochondroma, Paget disease, or irradiation-associated

IMAGING

General Features

- Best diagnostic clue
  - Irregular bony destruction with soft tissue mass originating from bone
- Location
  - Any bone or bone area, though most commonly involves distal ends of long bones

Radiographic Findings

- Variable radiographic appearances
  - Centrally or eccentrically located within bone
  - Expansile or nonexpansile
  - Osteolytic, osteosclerotic, or mixed pattern
    - ± ground-glass opacification of matrix (fibrous tumor)
    - ± matrix mineralization
      - Chondroid-type mineralization (whorls, rings-and-arcs, popcorn-like)
      - Osteoid-type mineralization (hazy, cloud-like, solid)
  - Well-defined margin (narrow zone of transition)
    - Sclerotic or nonsclerotic rim
    - Favors nonaggressive tumor
  - Ill-defined margin (wide zone of transition)
    - Favors aggressive tumor
  - ± cortical breach
  - ± extraosseous tumor extension
  - ± periosteal ± tumoral new bone formation
    - Periosteal new bone formation: Periosteum elevated or stimulated by tumor forms osteoid matrix
    - Tumoral new bone formation: Tumor cells → form osteoid matrix
  - Types of periosteal or tumoral new bone formation
    - Lamellated: Single or multilayered (onion skin)
    - Spiculated, sunburst, or hair-on-end patterns (represent tumoral rather than periosteal new bone)
    - Codman triangle (located at edge of extraosseous tumor extension)
    - Solid (mature)
  - Type of periosteal reaction not very reliable discriminator of tumor aggressiveness
    - Aggressive tumors may have no periosteal reaction, or, occasionally, relatively benign-type periosteal reaction
  - Spiculated, sunburst, or hair-on-end tumoral new bone highly specific for aggressive tumor

CT Findings

- Very specific for some tumors (e.g., intraosseous lipoma, osteoid osteoma)
- Used to guide biopsy for bone tumor with intact cortex & no extraosseous component

MR Findings

- Helps define local extent & often helps characterize both malignant & benign bone tumors
- For bone sarcoma, MR used to specifically define
  - Intramedullary tumor extent
  - Extramedullary/extraosseous tumor extent
  - Physeal involvement
  - Joint involvement
  - Neurovascular bundle involvement
  - Skip metastases

Ultrasonographic Findings

- US is not routinely used in standard work-up of bone tumors
  - Helpful as problem solver in particular instances
- Bone tumor may be unexpected finding in patient undergoing US for nonspecific pain, discomfort, or mass
- US can assess extraosseous component, cortical surface osteolysis, or intramedullary tumor if breached cortex
- Whenever possible, US-guided biopsy is both accurate & safe
- Osteochondroma
  - Pedunculated or sessile & metaphyseal in location
  - ± overlying hypoechoic cartilage cap
  - ± complication of osteochondroma, such as
    - Adjacent traumatic myositis, bursitis, or fat, nerve, vascular injury (→ hemorrhage, pseudoaneurysm)
    - Fracture of pedunculated osteochondroma
    - Malignant transformation
      - Affects < 1% of solitary osteochondromas
      - Cartilage cap > 2 cm thick has high sensitivity & specificity for secondary chondrosarcoma
      - This diagnostic criterion is established on CT & MR but not validated for US
- US appearances generally mirror radiographic appearances
  - Tumor matrix
    - Usually hypoechoic with cortical destruction
      - Irregular cortical osteolysis suggestive of aggressive tumor
    - ± thin, hyperechoic, radiating intratumoral spiculated lines representing matrix ossification
      - Indicative of aggressive tumor
    - ± irregular, hyperechoic matrix mineralization
      - Retained osseous fragments can simulate matrix mineralization
    - ± cystic, hemorrhagic areas or fluid-fluid levels
    - ± pulsatile tumoral mass on real-time imaging
    - Variable hyperemia
      - Chaotic vessel distribution in aggressive tumors
  - Periosteal reaction
    - Normal periosteal lining is thin & echogenic, & usually indistinguishable from normal bone cortex
    - Aggressive-type periosteal reactions have high specificity for aggressive bone tumor

- Separation of periosteum with subperiosteal tumor matrix (Codman triangle)
- Spiculated periosteal reaction

- Bone metastases are most common bone tumor encountered in everyday clinical practice
  - Particularly in older patients
  - Aggressive US appearance mimics bone sarcoma
  - Primary tumors that commonly metastasize to bone
    - Breast, lung, prostate, uterus, thyroid, bladder, kidney, pancreas, liver, & bowel
- US is used to guide biopsy when extraosseous soft tissue mass is present or cortex is breached
  - Hyperemic areas on color Doppler imaging reflect areas of viable tumor
    - These areas should be targeted for biopsy
- Assessment of flow in large feeding artery (femoral, popliteal, subclavian, brachial) by spectral Doppler analysis
  - Can be done for all tumors irrespective of whether primary tumor is visible on US
  - Flow velocities can be calculated
  - Normal arterial flow is triphasic with reversal of flow in early diastole
  - Metabolically active tumors may show substantial ↑ in antegrade diastolic flow
    - Generally accompanied by ↓ resistive indices
  - Change in flow dynamics can give indication of chemotherapy response
  - Assessment of intratumoral vessels usually not helpful
    - Too variable; some deep-seated sarcomas may not have demonstrable vascularity on color Doppler imaging
- Elastography: Highly stiff for malignant tumor
  - Areas with greater mineralization appear more stiff
- US is very useful for assessing bone tumor recurrence
  - Recurrence of resected bone sarcoma often occurs in juxtacortical soft tissues
    - Recurrence usually seen as discrete mass in soft tissues close to resection site
  - US is very useful when metallic prosthesis or fixation device in situ
    - US assessment of juxtacortical tissues not affected by metallic artifact as in CT or MR
- US is used to assess lymph node metastases
  - Nodal metastases are rare with primary bone tumor
  - More common with bone tumor recurrence
  - Can guide biopsy of node to confirm metastatic status

Imaging Recommendations

- Best imaging tool
  - Radiography
    - Abnormality apparent in nearly all symptomatic benign & malignant bone tumors
    - Abnormality may be absent in asymptomatic benign & malignant bone tumors
    - Used to characterize tumor type & grade tumor aggressiveness
  - MR
    - Local staging of malignant primary bone tumors ± assessing treatment response
    - Characterizing, assessing extent & complications of benign bone tumors

DIFFERENTIAL DIAGNOSIS

Osteomyelitis

- Acute osteomyelitis & acute exacerbation of chronic osteomyelitis can simulate aggressive bone tumor on US
- Generally, acute osteomyelitis is associated with more pronounced inflammation than sarcoma
- Clinical & hematological parameters also help distinguish between infection & tumor
- Rapidly progressive symptoms, severe local tenderness, fever, other constitutional symptoms, & leucocytosis favor infection over tumor
- Biopsy may be necessary
- Quiescent chronic osteomyelitis may simulate nonaggressive bone tumor

Healing Insufficiency Fracture

- Bone osteolysis & poorly mineralized callus can simulate bone tumor

PATHOLOGY

Staging, Grading, & Classification

- WHO classification of bone tumors
- Grading & staging according to level of cellular differentiation, mitotic activity, & degree of tumor spread

CLINICAL ISSUES

Presentation

- Most common signs/symptoms
  - Progressive, increasing pain over weeks to months
- Other signs/symptoms
  - Enlarging, palpable mass
  - Pain on weight bearing ± limp
  - Localized, mild or moderate-severity deep tenderness
  - May present with pathological fracture

Natural History & Prognosis

- Quite rapid, progressive deterioration if aggressive tumor
- Slow deterioration or quiescent symptoms if nonaggressive

Treatment

- Nonaggressive
  - Largely related to symptoms & likelihood of sequelae
- Aggressive
  - Resection ± limb-sparing surgery ± amputation
  - ± reconstruction with metallic prosthesis or allograft
  - ± neoadjuvant & postoperative radiotherapy & chemotherapy for sarcoma

DIAGNOSTIC CHECKLIST

Consider

- Tumor arising from bone in any deep-seated soft tissue mass
  - Ensure that deep margin of any soft tissue tumor is seen
- US has limited but occasionally very useful role in management of bone tumors

SELECTED REFERENCES

1. Debs P et al: Bone tumors: state-of-the-art imaging. Skeletal Radiol. 53(9): 1783-98, 2024

(Left) *Clinical photograph of the medial forefoot shows a seemingly fleshy mass protruding from the undersurface of the big toenail laterally. The lateral aspect of the nail is elevated as a result.* **(Right)** *Transverse US shows an echogenic, protuberant, subungual mass on the lateral side of the big toe. The mass is lifting the nail upward. Continuity with the underlying distal phalanx cannot be fully assessed with US due to acoustic shadowing.*

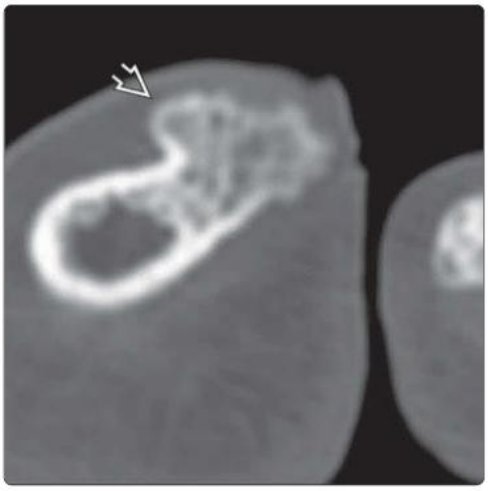

(Left) *Coronal CT with bone window shows an exostosis arising from the medial aspect of the distal phalanx. Continuity with the medullary canal is not as distinct as that of nonsubungual osteochondromas. This is a feature of subungual exostoses, which are radiologically similar though pathologically distinct from other osteochondromas.* **(Right)** *3D CT reconstruction shows the subungual exostosis. These nearly always occur on the medial aspect of the big toe and may be induced by trauma.*

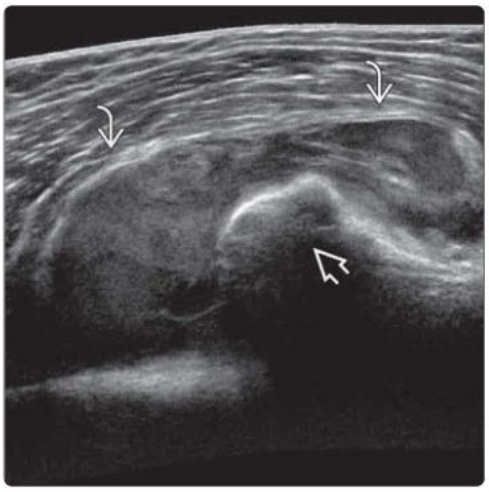

(Left) *Frontal radiograph shows a large, pedunculated osteochondroma on the medial side of the distal femoral metaphysis. This lesion was symptomatic and referred for US examination.* **(Right)** *Longitudinal US with extended field of view of the same lesion shows a bursa distended with hemorrhage overlying the femoral osteochondroma. Both chronic bursitis and hemorrhagic bursitis are not uncommon causes of osteochondroma-related pain.*

(Left) *More coned-down longitudinal US of the same lesion shows a thin, hypoechoic cartilage cap ➡ overlying the osteochondroma. There is some dependent sedimentation ➡ of the hemorrhagic bursal content. The thin bursal wall is visible ➡. No osteochondroma fracture was evident on US.* **(Right)** *Transverse color Doppler US shows mild hyperemia ➡ around the hemorrhagic bursitis ➡, which helps confirm the nonsolid nature of the bursal content.*

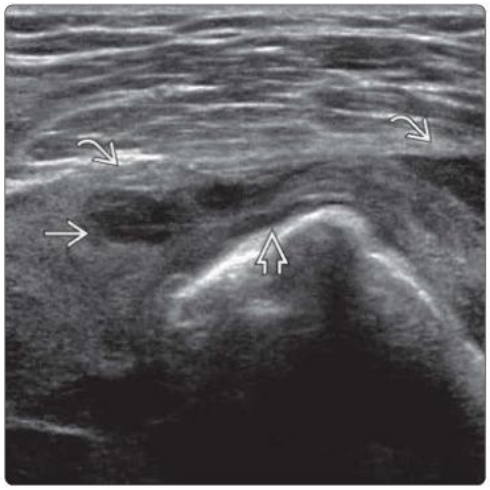

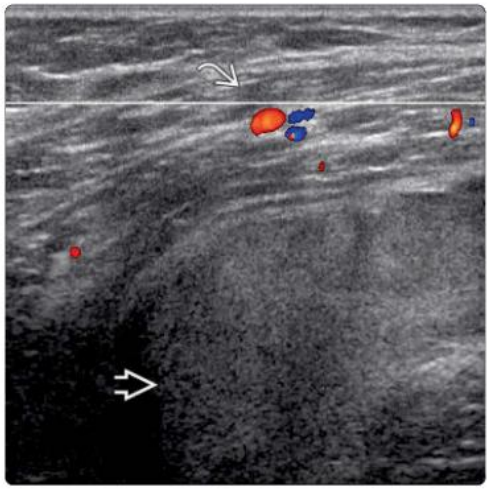

(Left) *Frontal radiograph in a young, skeletally mature patient shows a moderately expansile, lytic, subarticular tumor with a well-defined, nonsclerotic margin ➡, thinned cortex, and traversing septa ➡, consistent with a giant cell tumor of bone ± secondary aneurysmal bone cyst (ABC) features, or a primary ABC.* **(Right)** *Transverse US shows the same distal radius expansile lesion ➡. The cystic components with fluid levels ➡ can be seen through the thinned cortex. No extraosseous component was present.*

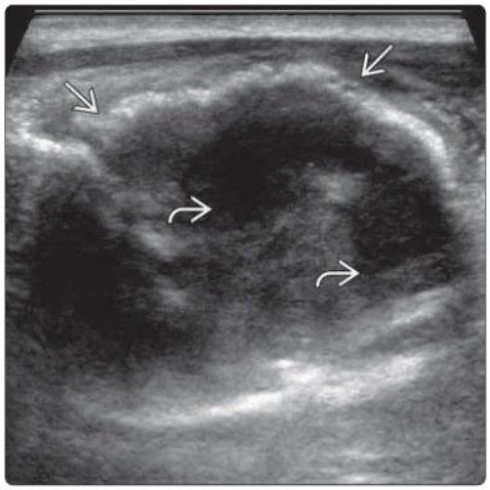

(Left) *Frontal radiograph shows a moderately expansile, partially sclerotic ➡, partially osteolytic ➡, subarticular tumor of the distal radius with a narrow zone of transition. Giant cell tumor of bone was a consideration, but the appearances are atypical.* **(Right)** *Longitudinal US of the same lesion shows the breached dorsal cortex ➡, allowing appreciation of the homogeneous, almost fluid-like content of the tumor matrix ➡. Note the residual, irregular, interrupted expanded cortex ➡.*

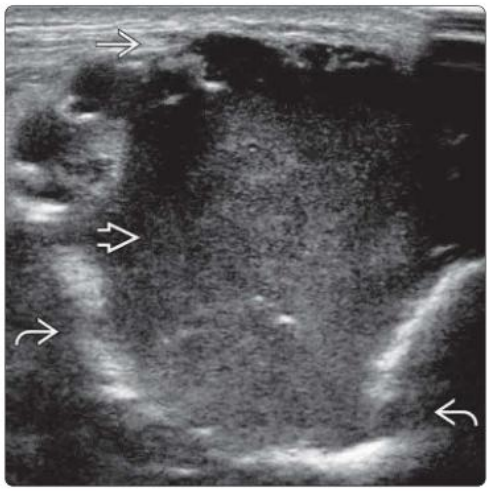

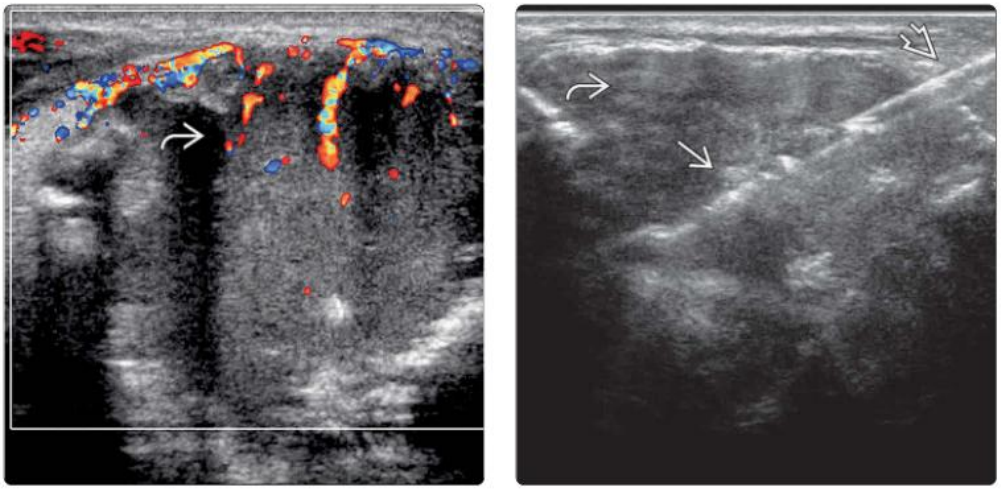

(Left) *Longitudinal color Doppler US of the same tumor shows moderate marginal hyperemia extending into the tumor matrix. Tumoral hyperemia is a reliable indicator of viable tumor tissue.* **(Right)** *Longitudinal US shows core biopsy of the bone tumor using a coaxial system with a 15-g coaxial needle transmitting a 16-g Temno core biopsy needle. Multiple biopsies can be taken with minimal disruption of extratumoral tissue. Histology revealed giant cell tumor of bone.*

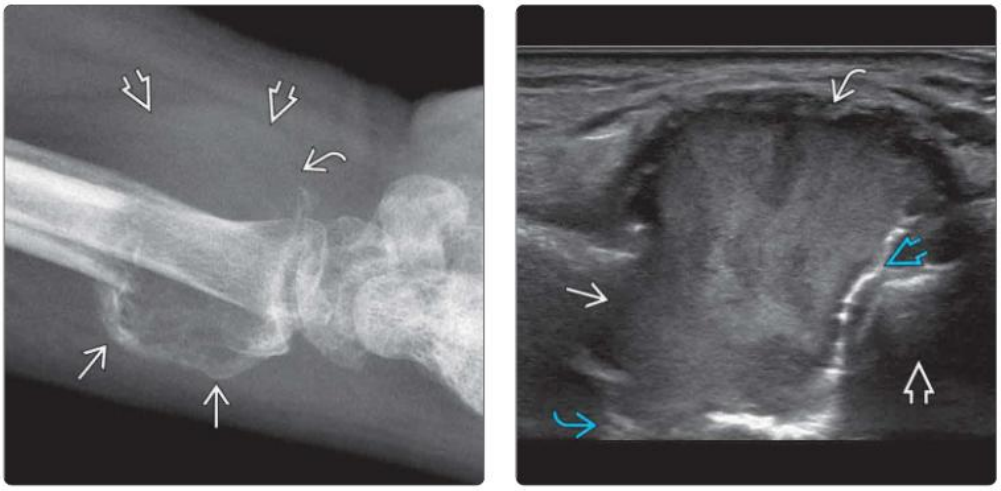

(Left) *Lateral radiograph shows a severely expansile, lytic lesion in the subarticular distal radius. The volar cortex is completely disrupted with adjacent soft tissue swelling.* **(Right)** *Longitudinal US of the volar distal forearm in the same patient shows a corresponding expansile, hypoechoic tumor in the distal radius. The volar cortex is completely breached with extraosseous tumor extension. The thinned dorsal and articular cortices remain largely intact. The normal lunate is shown.*

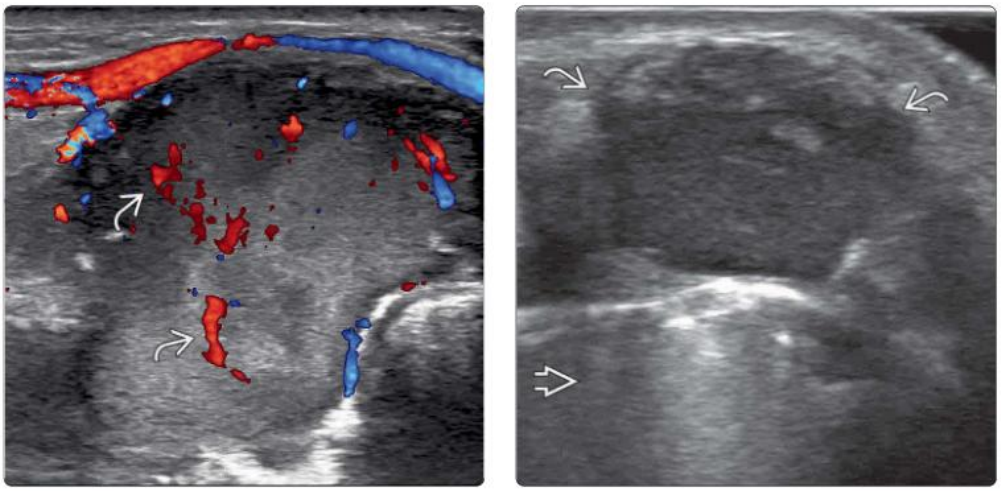

(Left) *Longitudinal color Doppler US of the same lesion shows moderate hyperemia. US-guided biopsy (not shown) confirmed giant cell tumor of bone. Patient was given upfront denosumab followed by tumor curettage.* **(Right)** *Transverse US of the volar distal forearm in the same patient 1 year later shows a new juxtacortical hypoechoic mass, volar to the distal radius, compatible with recurrent tumor. These commonly occur within juxtacortical soft tissues, which are readily evaluated on US.*

(Left) *Sagittal CT of the tibia in a patient with previously resected adamantinoma shows a new lytic lesion ➡ at the distal resection margin, compatible with recurrent tumor. The iliac crest graft ➡ for reconstruction and fixation screws ⇨ are shown.* **(Right)** *Longitudinal US at the same site shows a mildly expansile, intramedullary, hypoechoic tumor ➡ with scalloping and thinning of overlying cortex ➡. Histology confirmed recurrent adamantinoma. Iliac crest graft ➡ and lower 2 fixation screws ⇨ are shown.*

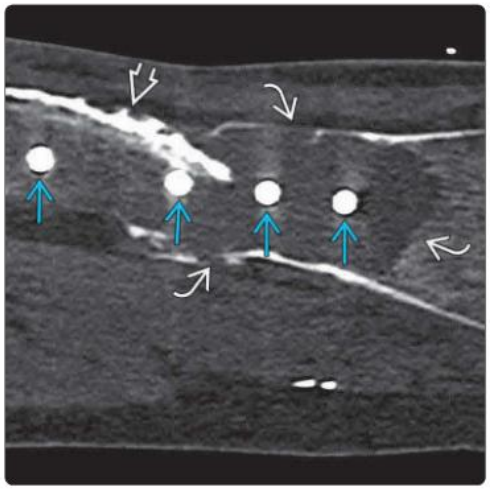

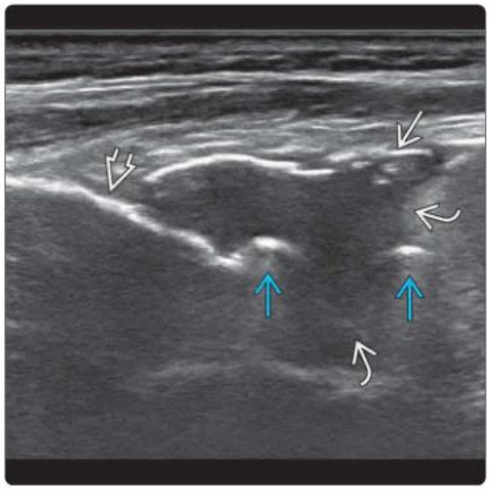

(Left) *Axial CECT shows a slightly hypodense mass ➡ anterior to the right pubic bone ➡. Rings-and-arcs calcification favors a chondroid matrix. Cortical thickening and irregularity ⇨ on the lateral aspect of the pubic bone are suggestive of periosteal chondroid lesion.* **(Right)** *Transverse US of the same location shows a well-defined, hypoechoic mass ➡ containing curvilinear, echogenic areas ⇨. Some of these echogenicities have a rings-and-arcs appearance, compatible with chondroid matrix.*

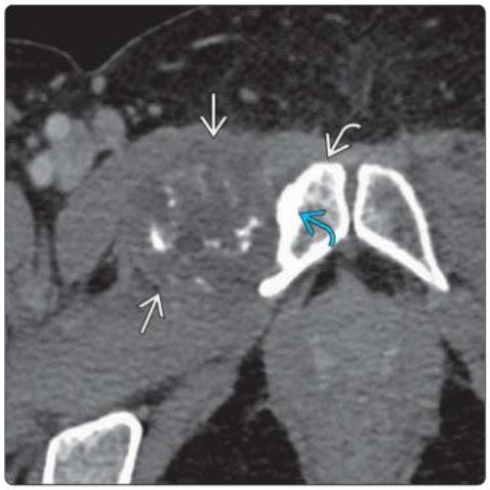

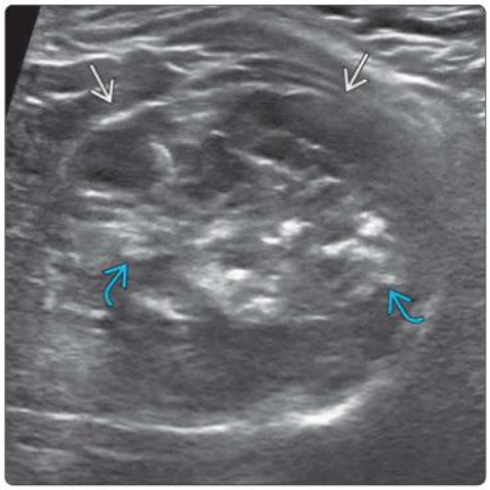

(Left) *Longitudinal US of the same lesion better demonstrates its smooth, lobulated contour ➡. Internal echogenicities representing matrix calcification ➡ are present, with the larger ones ⇨ showing posterior acoustic shadowing. The adjacent pubic bone with mild cortical irregularity ➡ is shown.* **(Right)** *Transverse color Doppler US of the same lesion ➡ shows mild peripheral vascularity ➡. Histology revealed periosteal chondrosarcoma. Periosteal and other bone surface lesions can be readily assessed on US.*

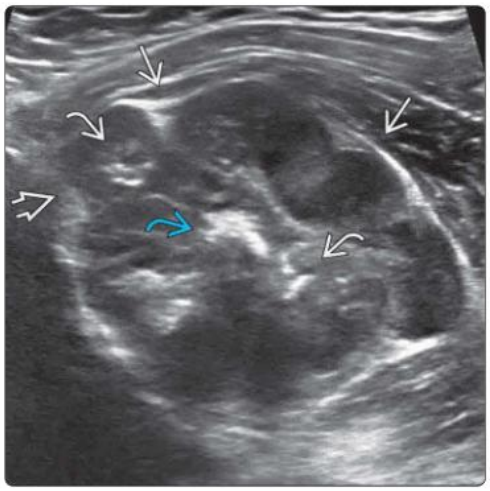

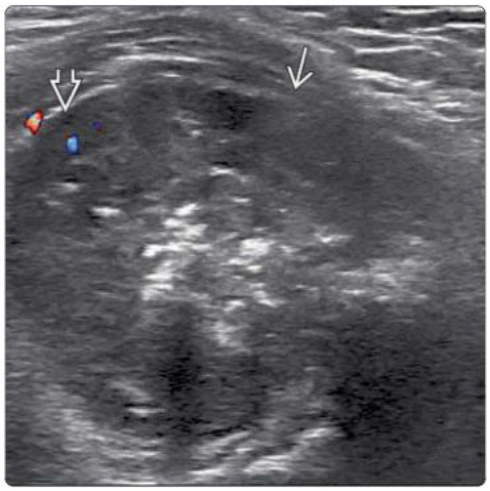

(Left) *Frontal radiograph of the distal femoral diaphysis shows altered bone texture associated with dense, spiculated new bone formation medially with lamellar new bone formation laterally.* **(Right)** *Lateral radiograph of the same lesion shows dense, spiculated new bone posteriorly and anteriorly with Codman triangle proximally. All of these appearances are consistent with osteosarcoma. Most bone tumors are diagnosed and characterized radiographically.*

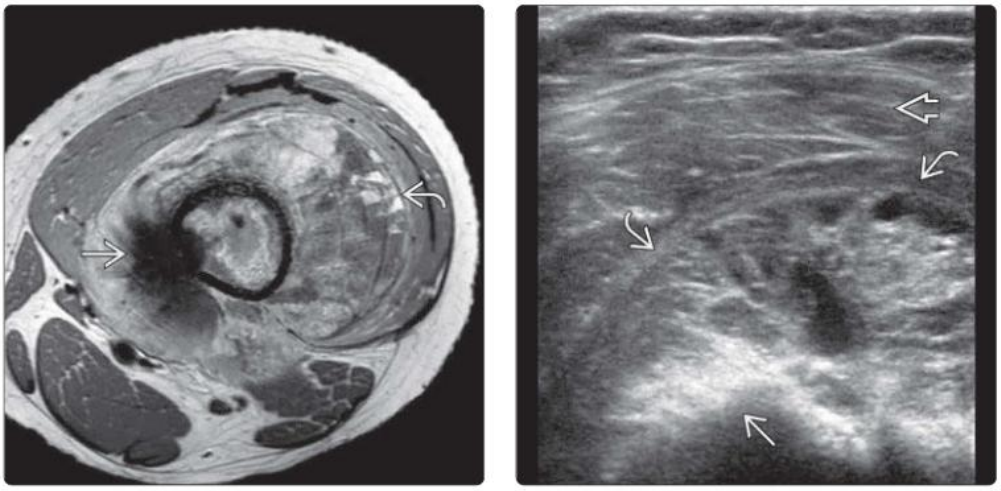

(Left) *Axial PD FSE MR of the same lesion shows a large, extraosseous soft tissue tumor with some fluid-fluid levels anteriorly and a dense, spiculated new bone tumor posteromedially.* **(Right)** *Transverse US of the anteromedial aspect of the same tumor shows dense, spiculated, tumoral new bone formation and a large, extraosseous soft tissue component displacing the vastus medialis muscle anteriorly.*

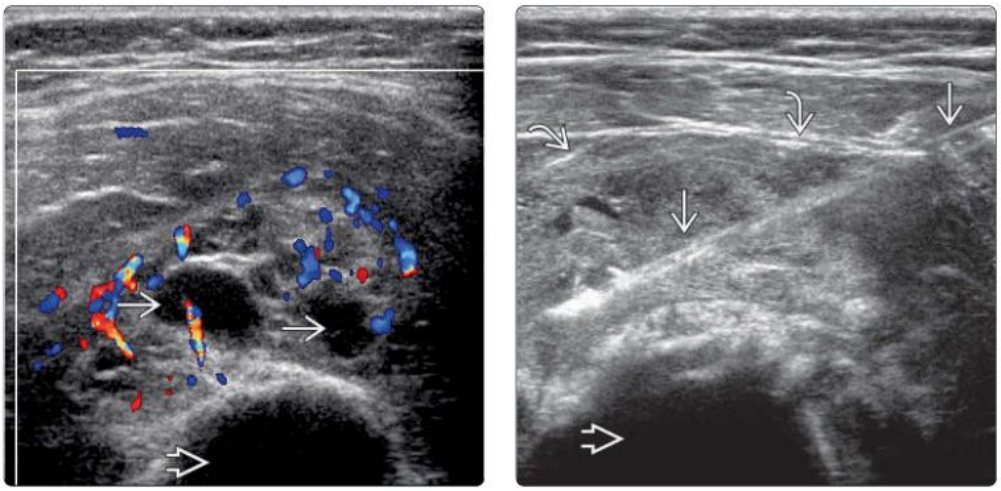

(Left) *Transverse color Doppler US shows moderate hyperemia of the extraosseous soft tissue component interspersed with some cystic areas. Hyperemia is a reliable sign of viable tumor that will usually provide a good yield with biopsy. Note the femur.* **(Right)** *Transverse US shows the biopsy needle located within the extraosseous tumor mass alongside the femur. US-guided biopsy is possible in 40% of bone tumors that require biopsy. Histology revealed osteosarcoma.*

(Left) *Lateral radiograph of the proximal leg in a young patient shows a sclerotic tumor ⇨ of the proximal tibia with a large, densely mineralized extraosseous component posteriorly ⇨.* **(Right)** *Longitudinal US of the same lesion shows a quite densely echogenic, extraosseous soft tissue component ⇨. This cloud-like echogenicity is suggestive of osteogenic tumor. US-guided percutaneous biopsy (not shown) revealed osteosarcoma. Note the indistinct tibial cortical outline ⇨.*

(Left) *Frontal radiograph in an 82-year-old woman shows a mildly expansile tumor of the proximal tibia, consistent with fibrous dysplasia. Other than a lucent area in the medial tibial condyle ⇨, no particularly suspicious features are present.* **(Right)** *Frontal radiograph of the same lesion 12 months later shows a large, osteolytic component ⇨ with a moderate compression fracture ⇨ of the proximal tibia. These appearances are compatible with malignant transformation of fibrous dysplasia.*

(Left) *Longitudinal US of the same tumor shows osteolysis of the proximal tibial cortex ⇨. This allows visibility of the large, hypoechoic tumor filling the medullary canal ⇨.* **(Right)** *Longitudinal US shows a cystic area ⇨ within the hypoechoic tumor matrix ⇨ with a fluid-fluid level ⇨. The tumor matrix was moderately hypervascular on color Doppler imaging (not shown). US-guided biopsy revealed high-grade osteosarcoma. An above-knee amputation was performed.*

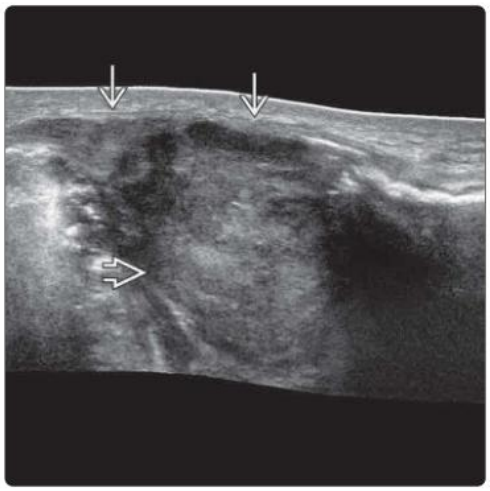

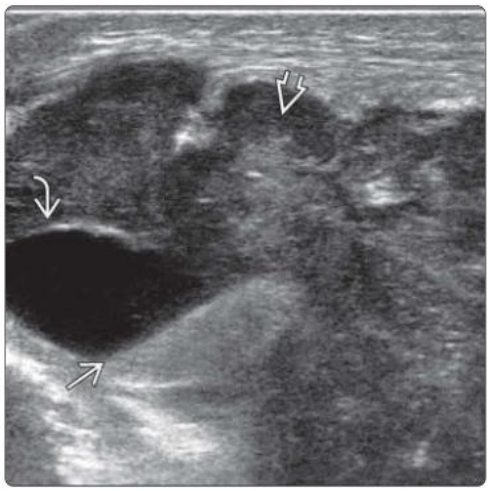

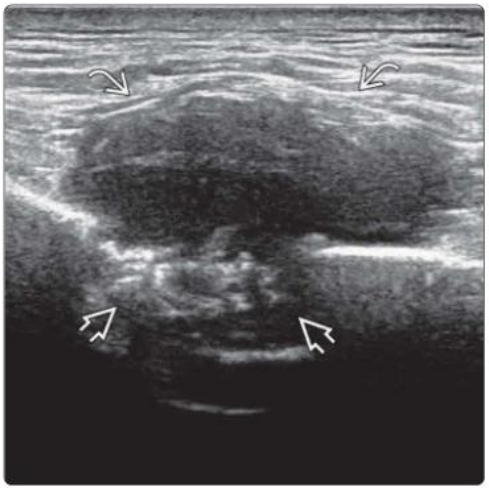

(Left) *Frontal radiograph of the pelvis in a 52-year-old man with myelodysplastic syndrome and recent onset of right hip pain is unremarkable. The patient was referred for US examination.* **(Right)** *Longitudinal oblique US of the gluteal region, following normal US examination of the hip region, shows focal, irregular osteolysis of the ilium ➡ with a large, hypoechoic extraosseous soft tissue component ➡ bulging into the gluteal muscle.*

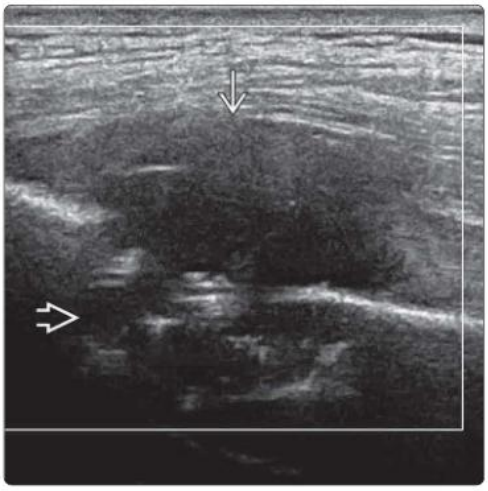

(Left) *Longitudinal oblique color Doppler US of the same lesion ➡ reveals no detectable tumoral or peritumoral hyperemia ➡. This does not preclude the presence of viable tumor tissue. US-guided biopsy (not shown) revealed blastic transformation of preexisting myelodysplastic syndrome.* **(Right)** *Axial CECT following US and biopsy shows the osteolytic tumor ➡ in the medial aspect of the right iliac bone adjacent to the sacroiliac joint.*

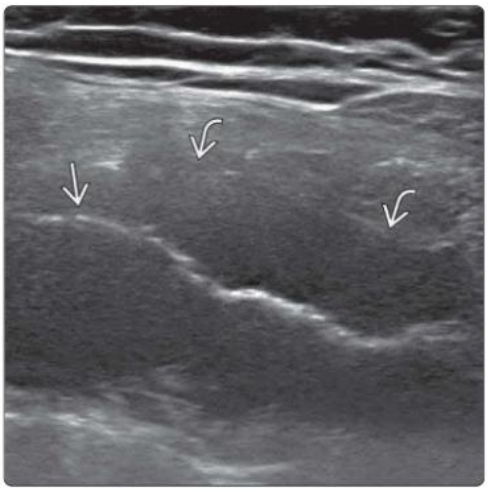

(Left) *Longitudinal US shows a lobulated 8th rib in a patient with low-grade B-cell lymphoma. The rib is expanded with irregular cortical thinning ➡ and osteolysis with a medium-sized extraosseous soft tissue component ➡.* **(Right)** *Transverse US of the same rib lesion shows cortical irregularity with focal breaching ➡. Intramedullary tumor has circumferentially permeated through the cortex with an eccentric extraosseous component ➡. US-guided biopsy (not shown) revealed high-grade transformation of the lymphoma.*

(Left) *Frontal radiograph of the right hemipelvis region in a child shows a large, irregular, osteolytic area ➡ in the supraacetabular portion of the ilium, partially obscured by bowel gas.* **(Right)** *Axial T1 C+ FS MR of the same area shows a large, irregular, mildly expansile, moderately enhancing mass ➡ in the right ilium extending into the iliacus and gluteal muscles. Another smaller, similar lesion was present in the posterior elements of L5 (not shown).*

(Left) *Transverse oblique US in the same patient shows irregular osteolysis ➡ of the iliac bone with a large, hypoechoic tumor ➡ deep to the gluteal musculature ➡.* **(Right)** *Longitudinal oblique color Doppler US shows irregular iliac bone osteolysis ➡ surrounded by hypoechoic tumor matrix ➡. Mild tumor hyperemia ➡ was present on color Doppler imaging. US-guided biopsy (not shown) revealed Langerhans cell histiocytosis of bone.*

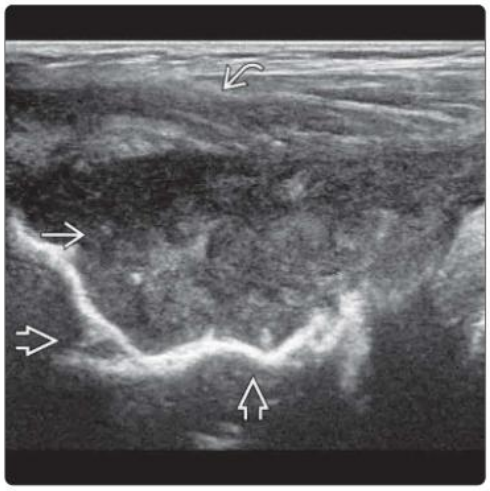

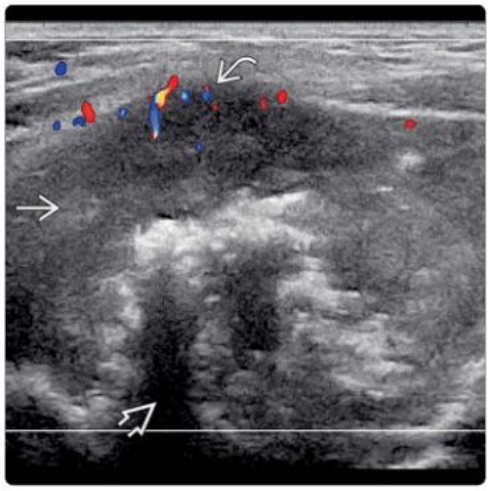

(Left) *Transverse color Doppler US in a patient with clinically suspected buttock sarcoma shows a large soft tissue mass with radiating echogenic spicules ➡. These spicules suggest a bony origin, which was confirmed by 7.5-MHz US (not shown). Minimal demonstrable tumoral hyperemia ➡ is present.* **(Right)** *Axial NECT shows a large tumor mass arising from the iliac ➡ and sacral ➡ bones. Histology revealed primitive neuroectodermal tumor.*

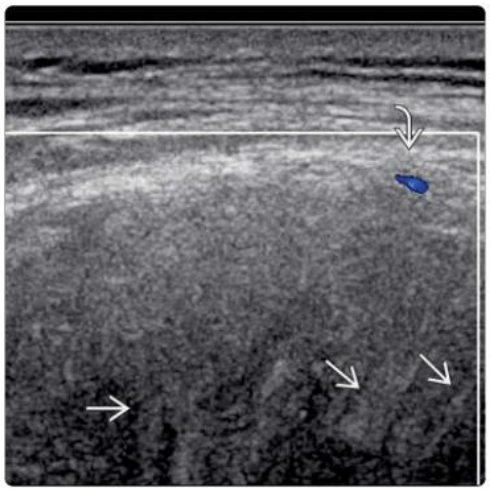

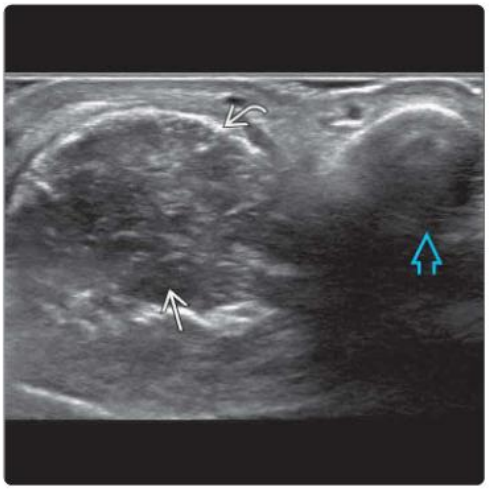

(Left) *Frontal radiograph in a patient with a painful index finger mass shows an expansile, lytic lesion ➡ at the proximal phalangeal base with extraosseous soft tissue extension ➡, indicative of aggressive bone tumor.* **(Right)** *Transverse US of the dorsal aspect of the proximal phalanx of the index finger in the same patient shows an expansile, heterogeneously hypoechoic intramedullary lesion ➡ with cortical thinning and irregularity ➡. The normal caliber and smooth, intact cortex of the proximal phalanx ➡ is shown.*

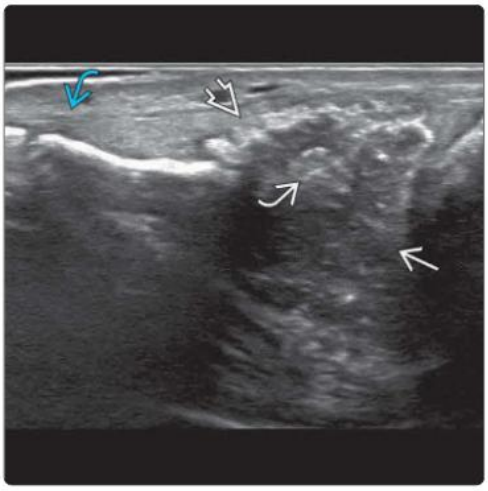

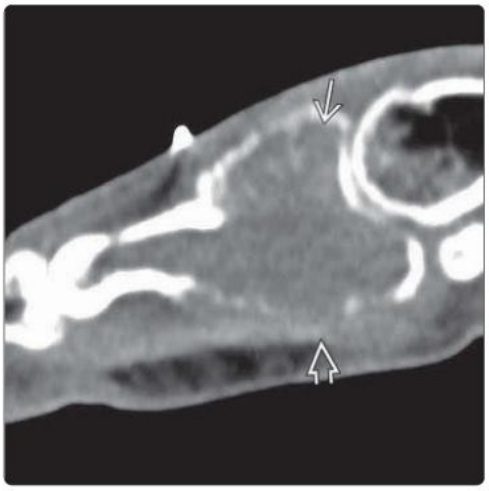

(Left) *Longitudinal US of the same proximal phalanx shows an expansile, destructive lesion ➡ with echogenic bony debris ➡ and dorsal cortical irregularity ➡. The overlying extensor tendon ➡ is normal.* **(Right)** *Sagittal CT of the same proximal phalanx shows the expansile lytic tumor ➡ mirroring previous US image. The volar cortex is breached with small, extraosseous tumor extension ➡. Histology from CT-guided biopsy confirmed metastatic adenocarcinoma of lung origin.*

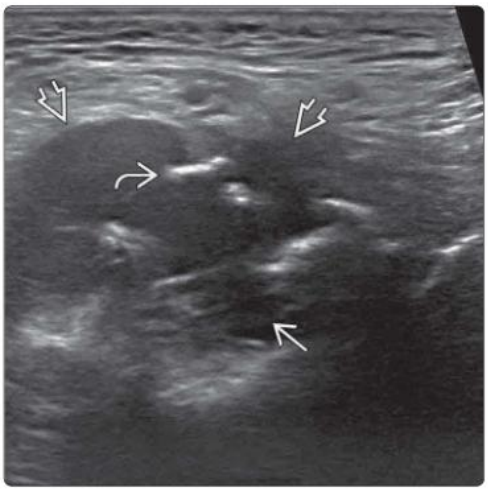

(Left) *Transverse US of the right pubic region in a patient with primary lung carcinoma and right hip pain shows a destructive, hypoechoic right pubic bone lesion ➡ with extraosseous soft tissue extension ➡ and bony debris ➡, suggestive of bone metastasis. Hip joint was normal on US.* **(Right)** *Frontal pelvic radiograph in the same patient 1 week earlier, zoomed to the pubic bones, shows subtle osteolysis ➡ of the right pubic bone, which was overlooked. US enables real-time correlation with the symptomatic site.*

KEY FACTS

TERMINOLOGY

- Local recurrence of tumor following initial planned complete tumor resection
  - If original tumor was not completely resected, this is residual tumor rather than recurrence

IMAGING

- US is as sensitive/specific as MR for detecting bone or soft tissue recurrence
- Examine entire section of limb from which primary tumor was resected
  - Most common reason to miss recurrence is nonexamination of that area
- Presence of discrete soft tissue mass is best diagnostic clue
  - Appearances mirror that of primary tumor
  - Multiple synchronous tumor recurrences may occur
    - Examine carefully for additional recurrences, especially with melanoma recurrence
- Consider likelihood of postoperative, nontumoral mass
- For bone tumor, correlate with radiographs if any bone abnormality detected on US
- Routinely examine regional lymph nodes
- Arrange either US-guided biopsy or US follow-up of any suspicious mass lesion

TOP DIFFERENTIAL DIAGNOSES

- Postoperative seroma/hematoma
- Postoperative fibrosis/granulation tissue
- Reactive bone change at resection margin

PATHOLOGY

- Several factors may govern risk of recurrence
  - Positive surgical margins, tumor depth, size, & grade

CLINICAL ISSUES

- Most local recurrences occur in first 3 years after diagnosis
- Early detection of local recurrence improves prognosis & morbidity

(Left) *Clinical photograph shows leiomyosarcoma of the ankle treated with excision several years prior with skin flap. A medium-sized nodule at the posterior aspect of the flap was slowly increasing in size.* **(Right)** *Longitudinal US of the corresponding region shows a heterogeneous, predominantly hypoechoic soft tissue mass at the site of the clinically palpable nodule. The margins are slightly irregular. Features are highly suspicious for local recurrence.*

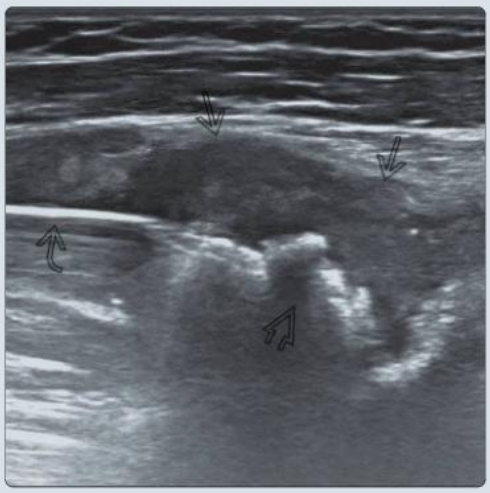

(Left) *Lateral radiograph in a middle-aged patient with a humeral prosthesis for fibrosarcoma resected 3 years prior shows localized osteolysis suggestive of tumor recurrence.* **(Right)** *Longitudinal US of corresponding site shows a soft tissue mass at the anteromedial aspect of the prosthetic bone junction with irregular underlying osteolysis. Percutaneous biopsy confirmed local recurrence. MR and CT would have been limited by metallic artifact while US clearly shows recurrence.*

TERMINOLOGY

Definitions

- Local recurrence of tumor following initial planned complete tumor resection
  - If original tumor was not completely resected, this is residual tumor rather than recurrence

IMAGING

General Features

- Best diagnostic clue
  - Presence of discrete soft tissue mass
- Location
  - Most common along tract of tumor excision
    - Anywhere under surgical scar area
  - Local recurrences from superficial tumor commonly occur in muscle layer exposed at time of initial tumor resection
  - Multiple synchronous recurrences may occur
    - Examine carefully for other recurrences, especially in melanoma
  - Superficial recurrences from deep tumors generally due to tumor contamination of surgical tract
    - Seeding along tract was much more common with open biopsy
    - Extremely uncommon with closed image-guided percutaneous biopsy
- Size
  - Larger in deeper lesions due to later presentation
- Morphology
  - Generally, mirrors that of primary tumor
    - All malignant bone & soft tissue tumors have propensity for recurrence
    - Some benign bone & soft tissue tumors have propensity for recurrence
      - Desmoid tumor
      - Tenosynovial giant cell tumor

Ultrasonographic Findings

- **Soft tissue recurrence**
  - Presence of discrete soft tissue mass at surgical site is best diagnostic clue
    - Hampered by postsurgical or irradiation fibrosis, & disruption of normal anatomical planes
    - Alongside surgical scar & along open biopsy tract are most common sites for recurrence
      - Rare following image-guided percutaneous biopsy
  - Variable echogenicity & vascularity of recurrent tumor but generally mirrors that of primary tumor
    - Hypoechoic, hyperemic mass with foci of mineralization for osteosarcoma primary
    - Hyperechoic, nonhyperemic tumor without mineralization for liposarcoma primary
    - Myxoid tissue: Well-defined, intratumoral anechoic or hypoechoic areas
    - Calcification: Discrete intratumoral echogenic foci with acoustic shadowing
    - Hemorrhage: Ill-defined intratumoral echogenic areas with acoustic enhancement; fluid levels
    - Usually hypervascular with disorganized vascular pattern on color Doppler US imaging
      - However, if primary tumor is hypovascular, such as fibrosarcoma or myxoid chondrosarcoma, recurrence will be hypovascular
  - Associated abnormality
    - Adjacent bone erosion or periosteal reaction
    - ± regional nodal metastasis (not uncommon with recurrent tumor)
- **Bone tumor recurrence**
  - US useful at detecting bone tumor recurrence
  - Most bone tumor recurrences occur in soft tissue & not in bone
  - Most recurrences lie close to prosthetic or allograft implant
    - US is not affected by metallic artifact
  - Discrete soft tissue mass is best diagnostic clue
    - ± association with underlying bony erosion
    - Echogenicity & matrix tumor characteristics generally mirror those of primary tumor
      - Same characteristics of primary bone tumor (e.g., matrix mineralization in osteosarcoma)
    - Regional metastatic lymphadenopathy is much more common than with primary bone tumor
    - If tumor clearly originates from bone, metachronous malignancy should be considered, especially for osteosarcoma

MR Findings

- T1WI
  - Presence of discrete, enhancing soft tissue mass
  - Signal intensity pattern of recurrence is similar to that of primary tumor
  - Sensitivity 83%; specificity 93%
- T2WI FS
  - Discrete high signal intensity lesion with mass effect
  - Moderate perilesional edema

Imaging Recommendations

- Best imaging tool
  - US, as it is easily available, does not require contrast injection & is not subject to metallic artifact
    - As accurate as MR for detecting bone or soft tissue recurrence
    - Allows ready assessment of regional lymph nodes
    - US-guided biopsy feasible of any suspicious mass
  - For high-grade bone or soft tissue sarcoma (STS), follow-up at 3 months after surgery, then every 6 months for 2 years, then yearly thereafter for 5 years
  - For low-grade bone or STS, follow-up at 6 months after surgery, then yearly thereafter for 3 years
  - However, it is still not clear whether routine surveillance actually improves survival
- Protocol advice
  - Same protocol is used for both bone & soft tissue recurrence
  - First review any preoperative imaging
  - Examine entire section of limb from which primary tumor was resected (e.g., thigh, leg, arm, or forearm)

- Use parallel series of longitudinal sweeps (with transducer aligned transversely) from proximal to distal along affected limb segment
- Examine patient in both supine & prone positions to ensure that entire circumference of operated segment of limb is examined
- Look for any discrete soft tissue mass, particularly along scar
- Consider likelihood of postoperative, nontumoral masses
  - Chronic collection
  - Organizing hematoma
  - Postoperative fibrosis
  - Localized fat hypertrophy to replace resected muscle
  - Retracted transected muscle belly
  - Reactive changes at bone resection margin
- For bone tumor, correlate with radiographs if any bone abnormality is detected
- Routinely examine regional lymph nodes
  - Biopsy suspicious lymph nodes
- Either US-guided biopsy or US follow-up of suspicious mass lesion
  - Sample solid component of suspicious tissue
  - 16-g Tru-Cut core biopsy with coaxial system is excellent for tissue typing & histologic grading

DIFFERENTIAL DIAGNOSIS

Postoperative Seroma/Hematoma

- Usually more cystic in appearance, avascular
- Less mass effect
- Tends to remain static or regress on serial imaging

Postoperative Fibrosis/Granulation Tissue

- No mass effect; usually less well defined & more irregular
- Occurs at & tracks along surgical tract
- Does not progress on serial follow-up

Reactive Bone Change at Resection Margin

- Occurs at prosthetic/native bone, allograft/native bone
- New bone formation & localized soft tissue thickening
- Little, if any, mass effect
- Correlate any abnormal US appearances with radiograph
  - Radiography is very helpful in sorting out suspicious bone areas seen on US

PATHOLOGY

General Features

- Etiology
  - Several factors likely to be contributory
    - Unplanned resection
    - Histologic grade of tumor
    - Close tumor resection margin
    - Open biopsy with contaminated field

Gross Pathologic & Surgical Features

- Pathology mirrors that of primary tumor
  - Usually similar grade to primary tumor
  - Infrequently, recurrence may have more aggressive histologic features than primary tumor

CLINICAL ISSUES

Presentation

- Most common signs/symptoms
  - New lump at site of previous surgery
    - Clinical detection of recurrence can be hampered by scar tissue or deep location of recurrence
      - Especially true for irradiated surgical beds as soft tissue may be scarred & indurated
- Other signs/symptoms
  - Pain from bone tumor recurrence
  - Weight loss & other constitutional symptoms probably reflect systemic metastatic disease

Demographics

- Epidemiology
  - 6-14% of patients develop local recurrence after STS treatment
  - Greater risk of recurrence for
    - High-grade > low-grade tumors
    - Larger size of primary tumor
    - Unplanned surgery
    - Positive histologic margins with postoperative radiotherapy associated with risk of recurrence is 5.9x that of tumor with clear resection margins
    - Patients with treated local recurrence have higher likelihood of subsequent local recurrence

Natural History & Prognosis

- Most local recurrences occur in first 3 years after diagnosis
- Local recurrence requires additional surgery, radiotherapy, or amputation
  - Early detection of local recurrence helps avoid extensive surgery or amputation
- Local recurrence of malignant tumors is associated with overall poor prognosis (2-year survival rate: 50-70%)

Treatment

- Well-planned reresection in specialized tumor center
  - ± adjuvant radiotherapy ± chemotherapy
- Radiotherapy helpful for resected tumor with positive margins
  - Likelihood of radioresistance is high in patients with recurrence & prior radiotherapy treatment
  - Rate of wound complications ↑ with radiotherapy
- Amputation

DIAGNOSTIC CHECKLIST

Consider

- Regional nodal involvement

Image Interpretation Pearls

- Look for discrete soft tissue mass
- Generally, mirrors primary lesion

SELECTED REFERENCES

1. Park HY et al: Enhancing local recurrence detection in patients with high-grade soft tissue sarcoma: value of short-term Ultrasonography added to post-operative MRI surveillance. Cancer Imaging. 24(1):12, 2024

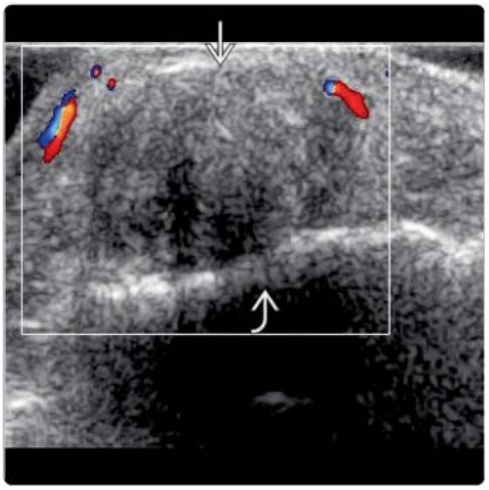

(Left) *Clinical photograph shows a patient with swelling ➡ at the tip of the little finger, which had been slowly growing for 1 year.* **(Right)** *Longitudinal color Doppler US in the same patient shows a well-defined, hypovascular mass ➡ at the tip of the distal phalanx with mild, posterior bony scalloping ➡. Histology revealed a giant cell tumor tendon sheath (GCTTS). The tumor was excised.*

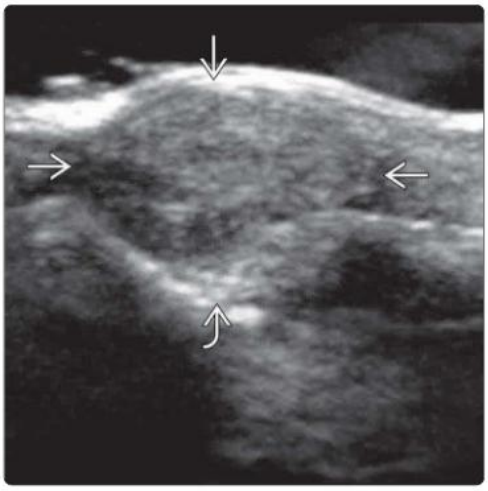

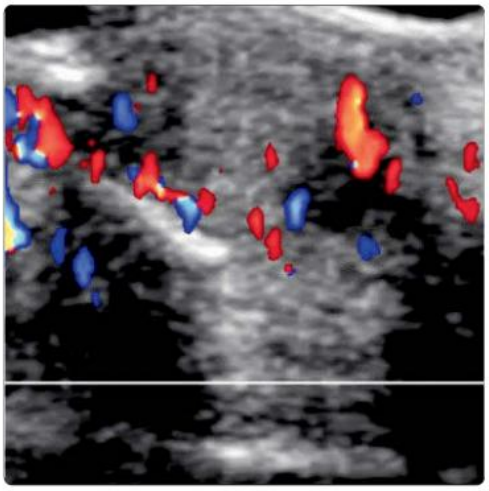

(Left) *Longitudinal US of the same finger 3 years later shows a locally recurrent tumor ➡ with more severe bony scalloping ➡. Bony scalloping was most likely the result of previous surgery rather than progressive, tumor-related osteolysis.* **(Right)** *Longitudinal color Doppler US of the same tumor shows moderate hyperemia. In most cases, local recurrence will have similar US characteristics to the original tumor, but this tumor is more hypervascular than the original primary tumor.*

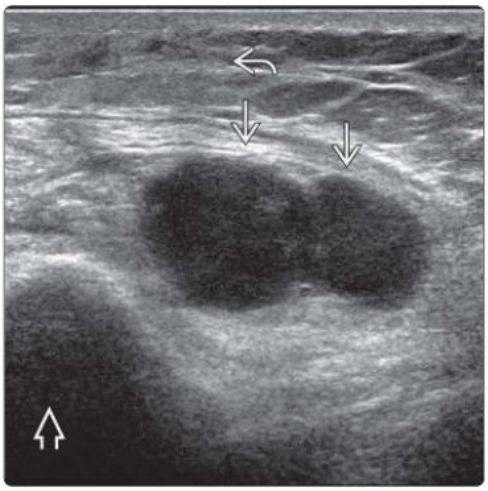

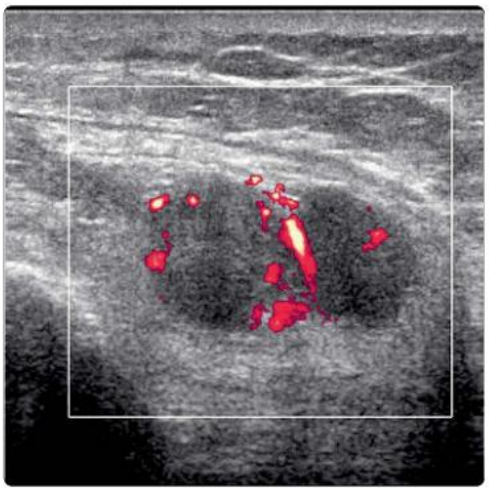

(Left) *Transverse US in a patient with undifferentiated pleomorphic sarcoma of the thigh excised 1 year prior shows a well-defined, hypoechoic mass ➡ deep to the surgical scar ➡ compatible with local recurrence. The femur is shown ➡. Area of scar is seen as echogenic subcutaneous fat rather than hypoechoic fibrous tissue.* **(Right)** *Transverse power Doppler US of the same tumor shows moderate hyperemia. A discrete mass is the most convincing sign of local recurrence.*

(Left) *Longitudinal US shows quite a large, well-defined, slightly irregular, predominantly echogenic mass ➡ in the vastus medialis muscle, which is highly suspicious for an intramuscular liposarcoma. This was confirmed by histology.* **(Right)** *Longitudinal US of the same region 5 years later shows a discrete, largely echogenic mass with a well-defined border ➡. This fatty tumor developing at the site of previous excision is highly suspicious for recurrent liposarcoma.*

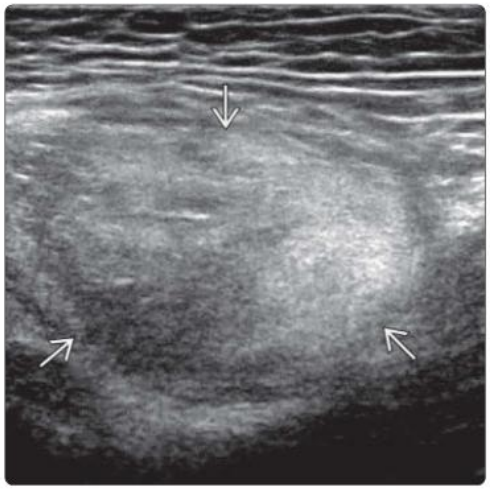

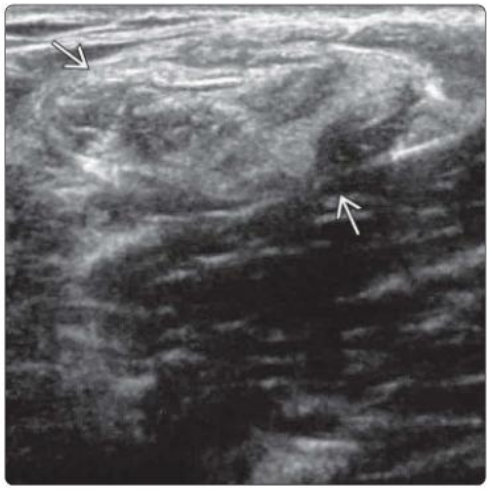

(Left) *Transverse T1 MR in the same patient shows a fatty tumor ➡ on the medial aspect of the thigh just deep to the surgical scar ⇨. Histology confirmed liposarcoma recurrence.* **(Right)** *Transverse US in a patient with an inflammatory myxohyaline tumor excised years ago shows a well-defined, hypoechoic mass with irregular, lobulated contour ➡ in the lateral aspect of the soleus, suspicious for an intramuscular local recurrence.*

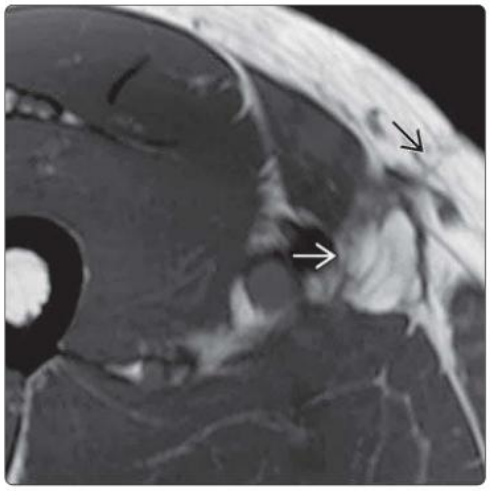

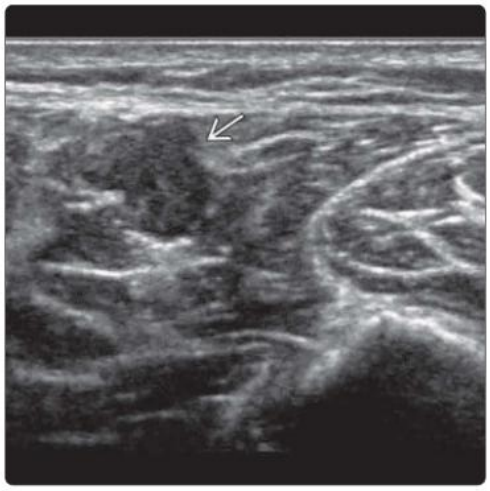

(Left) *Transverse color Doppler US of the same lesion shows severe marginal and intralesional hypervascularity, corresponding to the inflammatory characteristic of the original primary tumor.* **(Right)** *Transverse US in the same patient during needle biopsy is shown. A Tru-Cut biopsy needle was inserted through a coaxial needle ➡. The specimen slot ⇨ is present at the center of the lesion ⇨ just prior to biopsy. Histology confirmed local recurrence.*

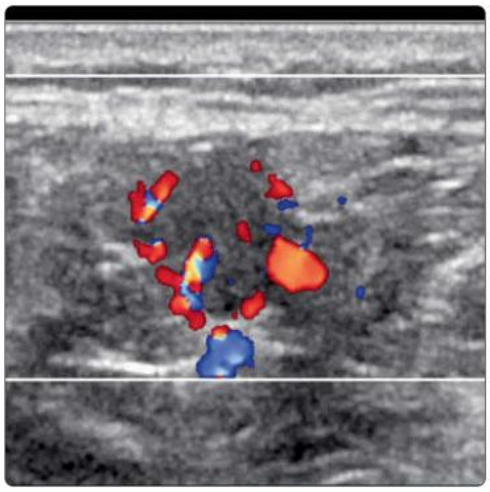

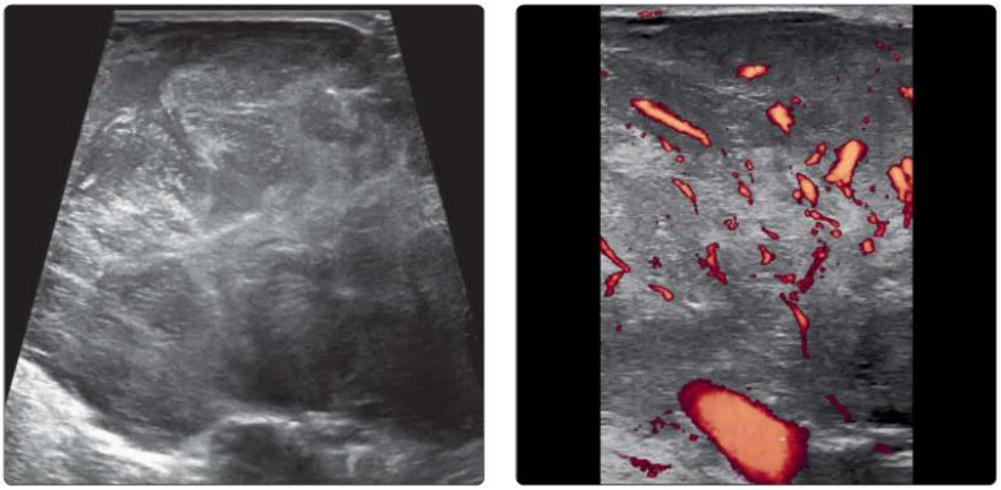

(Left) *Transverse US of the groin in a patient with subcutaneous dermatofibrosarcoma protuberans (DSFP) resected a few years ago shows a large lobulated heterogeneous subcutaneous exophytic mass. Features are suggestive of a recurrent DSFP.* **(Right)** *Transverse color Doppler US of the same tumor shows moderate intralesional hyperemia. Histology confirmed recurrence. Recurrences from subcutaneous tumors may also occur within muscle.*

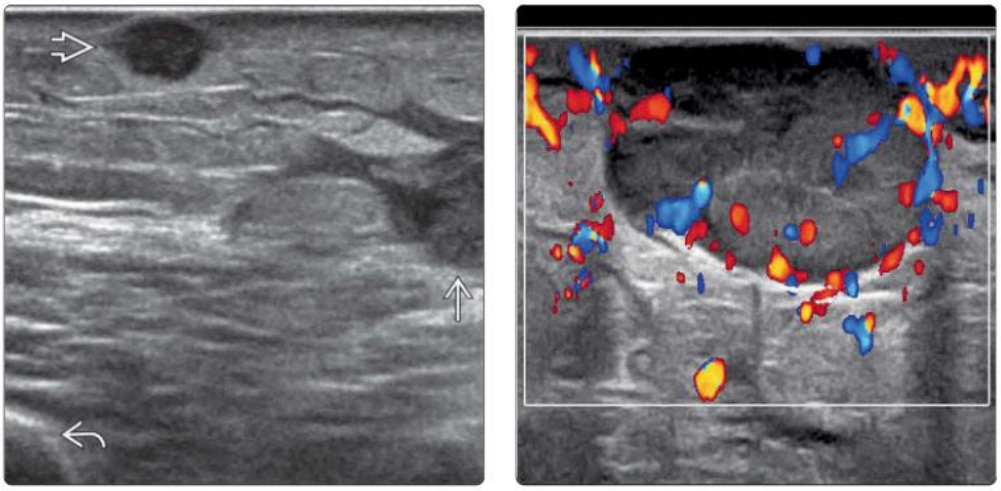

(Left) *Transverse US of the thigh in a patient with heel melanoma and wide local excision 2 years prior shows a discrete hypoechoic nodule ⇨ in the superficial subcutaneous layer, suspicious for recurrence. Postsurgical scar ⇨ is visible at the more lateral aspect. Part of the femur ⇨ is also shown.* **(Right)** *Transverse color Doppler US of a 2nd nodule at the more medial aspect of the thigh shows severe intralesional and peripheral hyperemia, characteristic of melanoma and melanoma recurrence.*

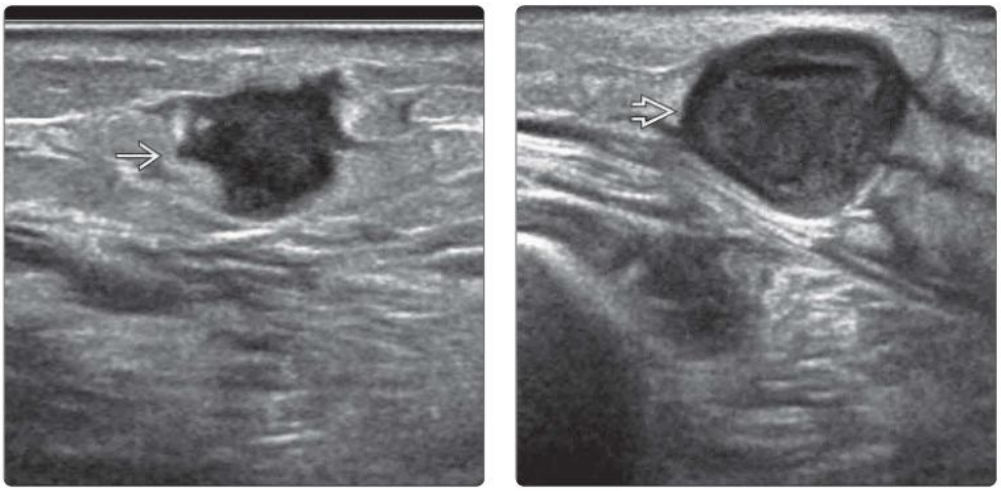

(Left) *Transverse US in the same patient shows a 3rd lesion in the subcutaneous tissue of the thigh ⇨, which is again suspicious for recurrence.* **(Right)** *Transverse US in the same patient shows a 4th lesion ⇨ in the superficial subcutaneous layer closer to the femur. All 4 lesions were local recurrent tumors from melanoma. When one recurrence is detected, search carefully for other sites of recurrence.*

(Left) *Clinical photograph shows surgical scar ➡ in a patient with synovial sarcoma of the palm resected several years prior. There was a thenar eminence swelling ➡ increasing in size.* **(Right)** *Transverse US of the corresponding region shows a heterogeneous, predominantly hypoechoic soft tissue mass with a mildly irregular border at the site of swelling ➡. Features are highly suspicious for local recurrence.*

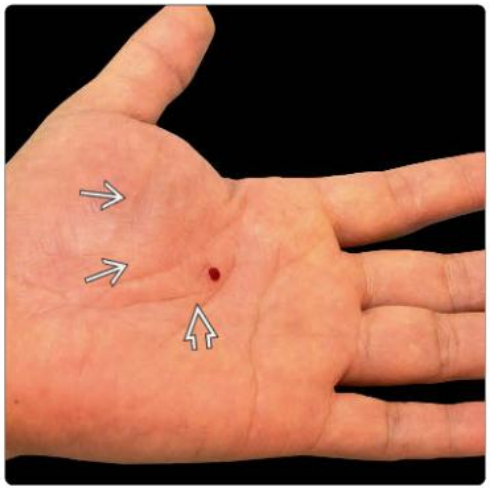

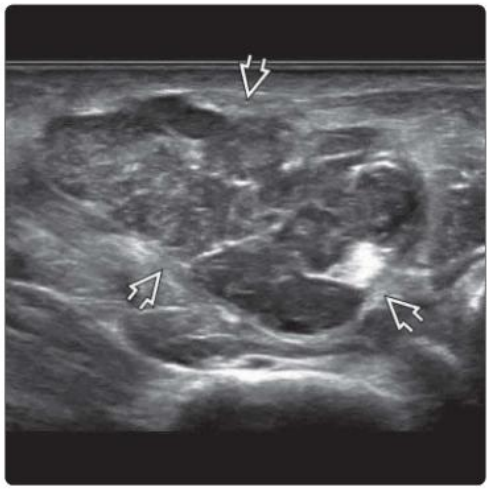

(Left) *Color Doppler US of the same tumor shows severe hyperemia, which is a feature of most, but not all, local recurrences.* **(Right)** *Percutaneous US-guided biopsy shows the suspected recurrence within the sample slot ➡ of the biopsy needle. Histology confirmed local recurrence.*

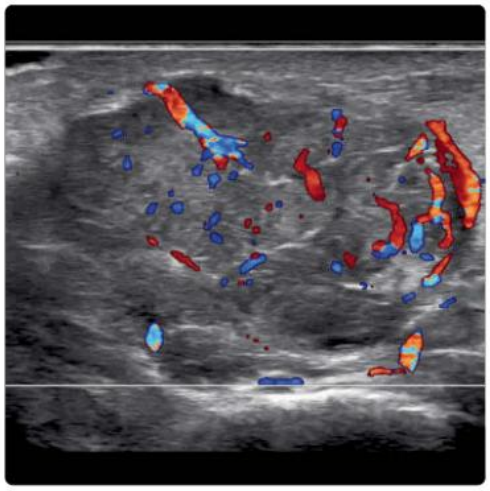

(Left) *Transverse US of thigh posterior to the surgical scar ➡ in a patient with subfascial liposarcoma resected a few years prior shows a small discrete subcutaneous hypoechoic nodule ➡ under the scar, consistent with recurrence.* **(Right)** *Longitudinal color Doppler US of the same tumor shows no significant hyperemia, which is a characteristic of low-grade liposarcoma recurrence. Histology confirmed recurrence.*

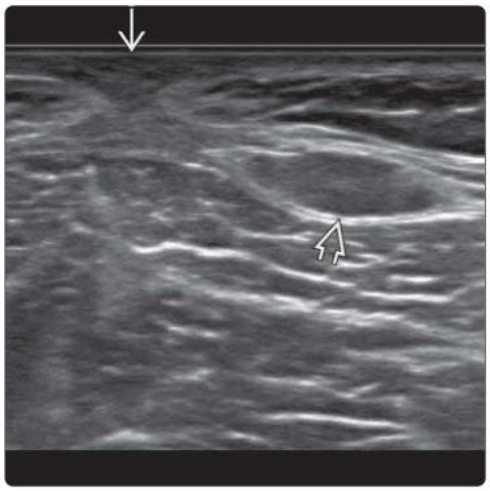

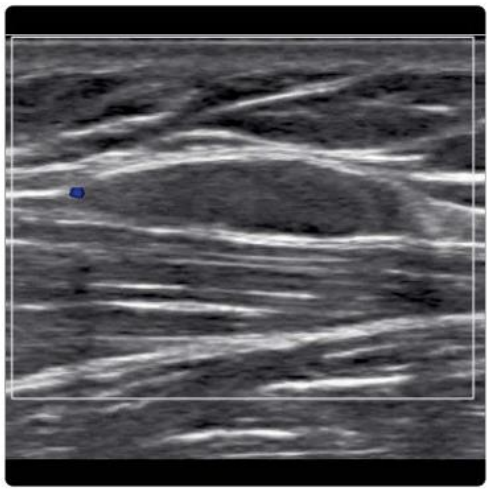

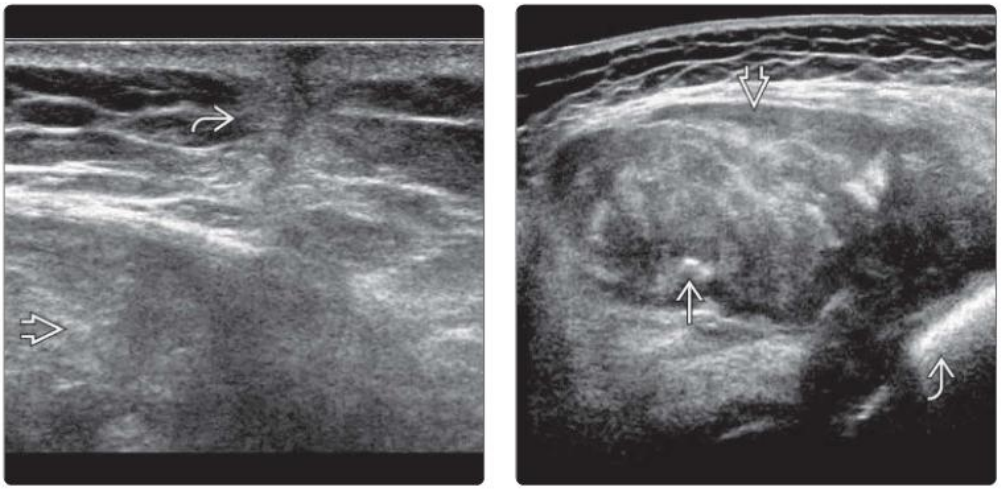

(Left) *Transverse US of the buttock in a patient with proximal femoral chondrosarcoma resected 1 year prior shows a large, hypoechoic tumor recurrence ⇨ deep to the surgical scar ⇨.* **(Right)** *Transverse extended field-of-view US of the same tumor shows the large, slightly heterogeneous tumor recurrence ⇨ just above the trochanteric region of the prosthesis ⇨. There is some echogenic matrix calcification ⇨. A low-frequency probe is necessary for better delineation of deeper masses.*

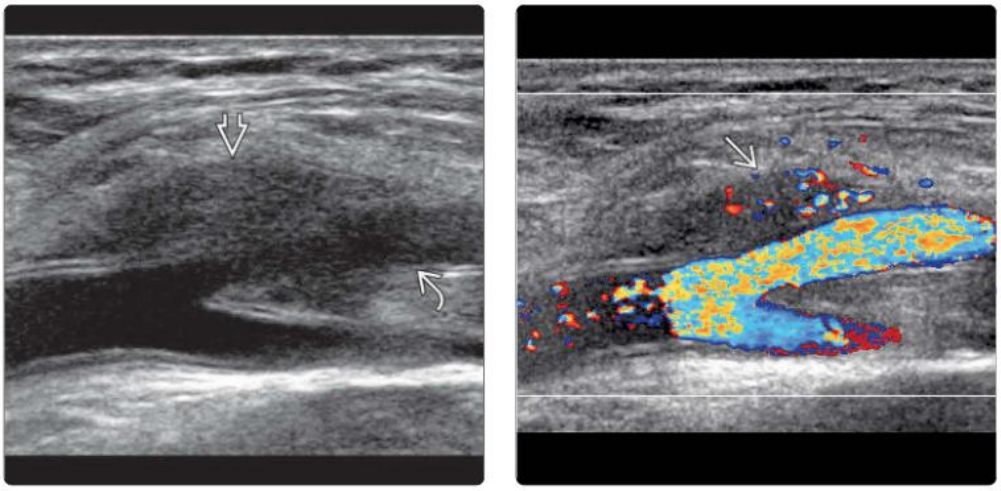

(Left) *Longitudinal US of the anterior groin in the same patient shows regional adenopathy with metastatic infiltration ⇨ of the superficial femoral artery ⇨ close to the bifurcation.* **(Right)** *Longitudinal color Doppler US of the same tumor shows mild tumoral hyperemia ⇨ and arterial patency. As regional lymphadenopathy is quite common in tumor recurrence, the regional nodes should be routinely examined.*

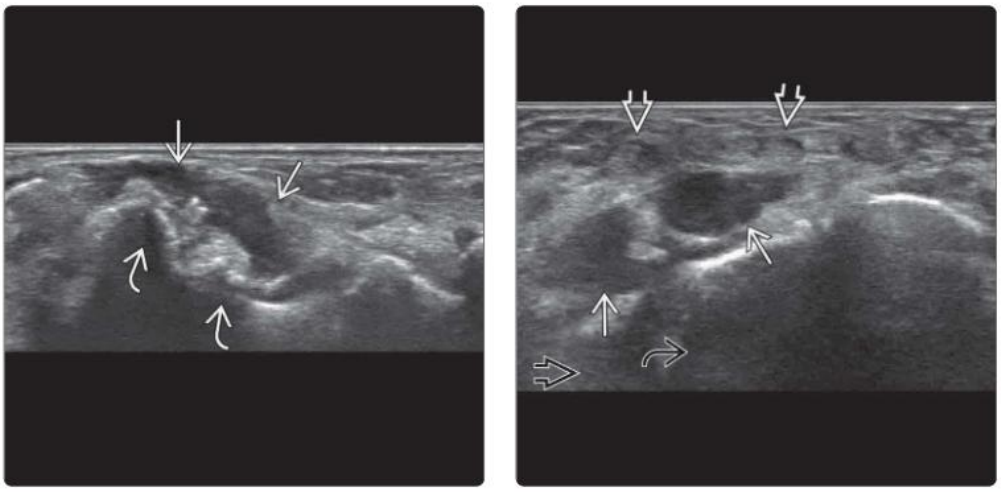

(Left) *Longitudinal US of the wrist in a patient with resected tenosynovial giant cell tumor (TSGCT) shows a hypoechoic soft tissue mass ⇨ on the volar aspect of the midcarpus region at resection site with bone erosion ⇨ characteristic of TSGCT recurrence, confirmed by histology.* **(Right)** *Transverse US of the dorsal aspect of the same wrist shows hypoechoic soft tissue masses ⇨ compatible with further recurrence overlying scaphoid ⇨ and lunate ⇨ bones with extensor tendons ⇨ displaced dorsally.*

(Left) *Longitudinal US in a patient with osteosarcoma of the humerus excised 10 years prior shows a large, osteosarcoma-like mass ➔ with new bone formation ➔ arising from the ipsilateral radial diaphysis. Severe periosteal thickening ➔ extends well beyond the tumor margin.* **(Right)** *Longitudinal US of the same tumor shows sunburst-like new bone formation ➔ within the tumor ➔. This tumor is due to metachronous osteosarcoma rather than local recurrence.*

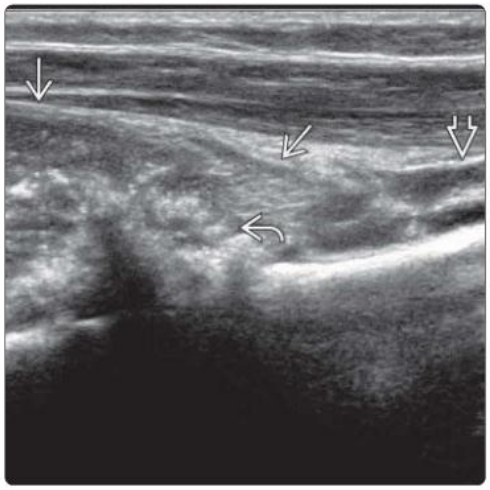

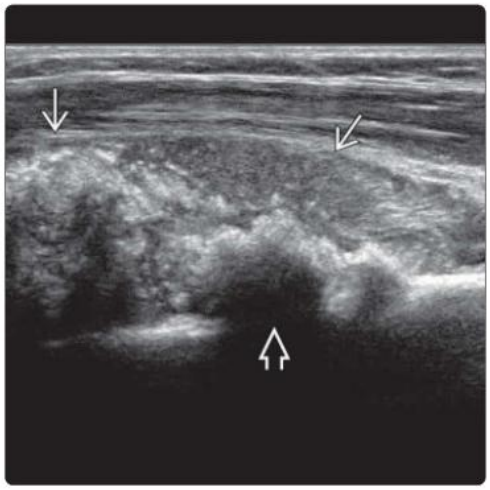

(Left) *Frontal radiograph in a patient with osteosarcoma resected 3 years prior and increasing knee swelling for 2 months shows permeative osteolysis of both the medial ➔ and lateral ➔ femoral condyles, highly suspicious for tumor recurrence.* **(Right)** *Transverse US in the same patient shows a large tumor recurrence alongside the medial femoral condyle ➔ with matrix mineralization ➔, consistent with osteosarcoma recurrence.*

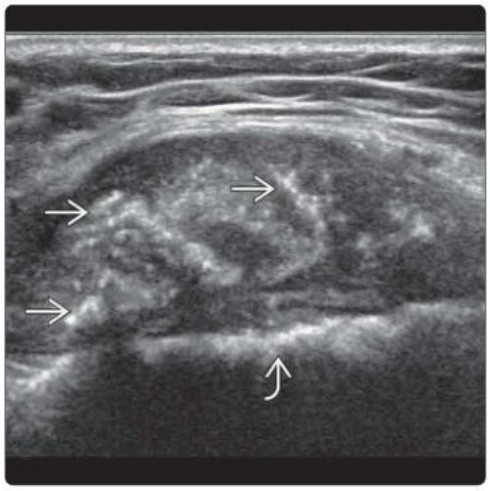

(Left) *Transverse color Doppler US of the same area shows mild peripheral hyperemia of the recurrent tumor ➔.* **(Right)** *Transverse US of the ipsilateral groin in the same patient shows a soft tissue mass with cystic ➔ and calcific ➔ changes compatible with a metastatic node. Mineralization is common in metastatic osteosarcoma. Nodal metastases in bone sarcoma recurrence are not uncommon but are rare at initial presentation.*

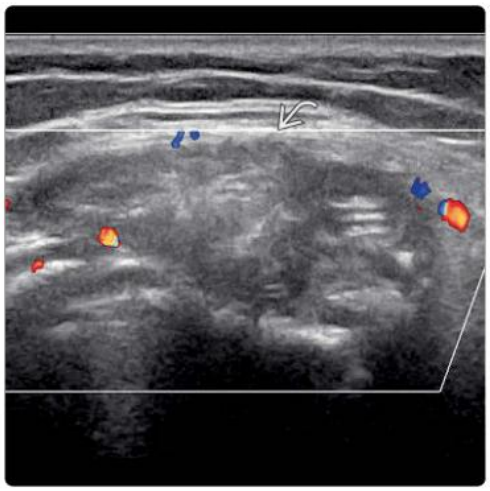

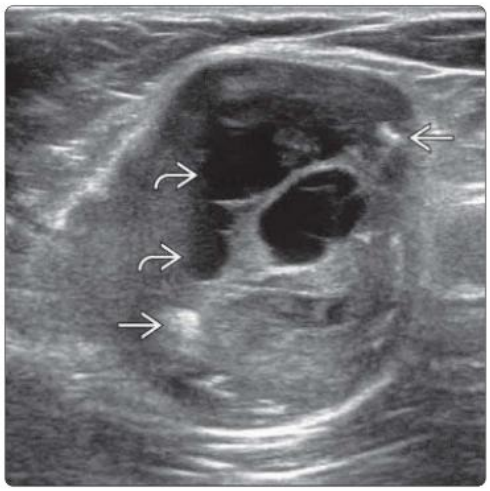

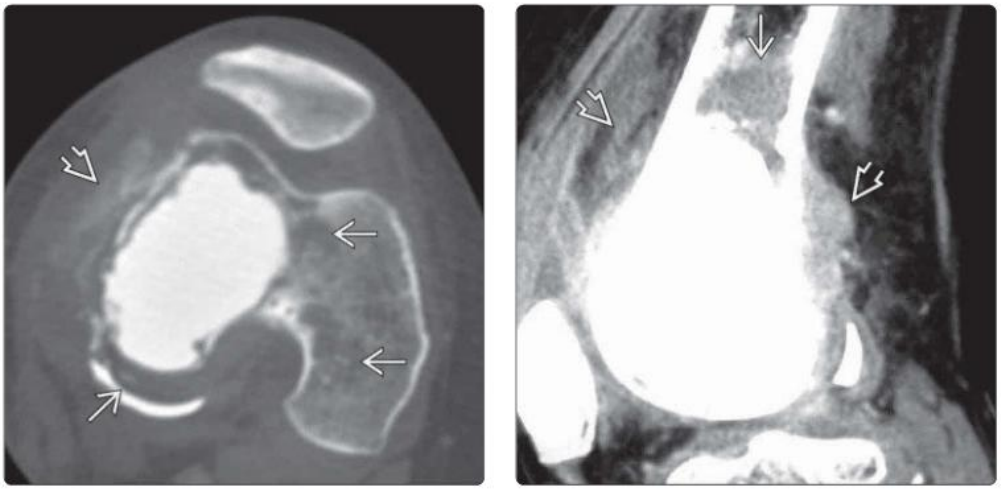

(Left) *Axial NECT in a patient 1 year following resection of initially suspected giant cell tumor shows osteolysis due to tumor recurrence around the bone cement ⇨ with new bone formation ⇨ in the soft tissue alongside the lateral femoral condyle.* **(Right)** *Sagittal CT reconstruction in the same patient shows severe intramedullary ⇨ and juxtacortical ⇨ tumor recurrence.*

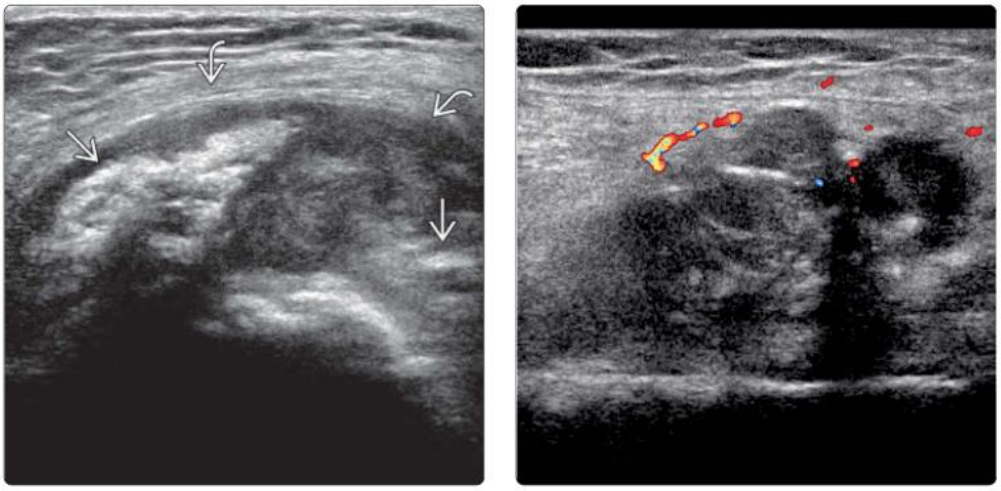

(Left) *Transverse US in the same patient shows prominent new bone formation ⇨ within the large, hypoechoic area of extraosseous tumor recurrence ⇨.* **(Right)** *Longitudinal color Doppler US in the same patient shows mild hyperemia of this tissue with additional small areas of calcification. This aggressive recurrence along with new bone formation prompted review and reclassification of the initial histology from giant cell tumor to giant cell tumor variant of osteosarcoma.*

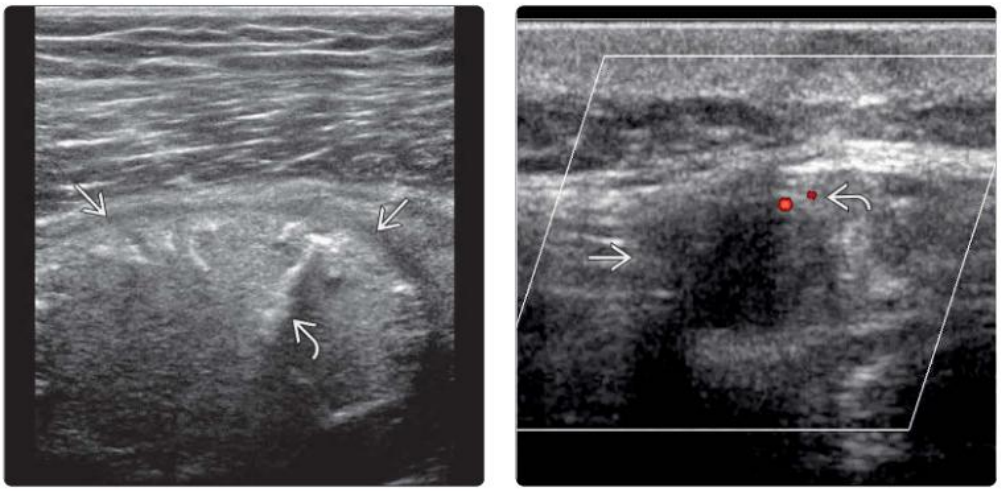

(Left) *Longitudinal US shows a large soft tissue osteosarcoma recurrence ⇨ with matrix mineralization ⇨, which is a characteristic feature of local recurrence of osteosarcoma.* **(Right)** *Transverse color Doppler US of the paraspinal region in a patient with myxoid chondrosarcoma resected 3 years prior shows an ill-defined, hypoechoic mass ⇨ at the resection site with minimal vascularity ⇨, consistent with a myxoid-type tumor recurrence. This was confirmed histologically.*

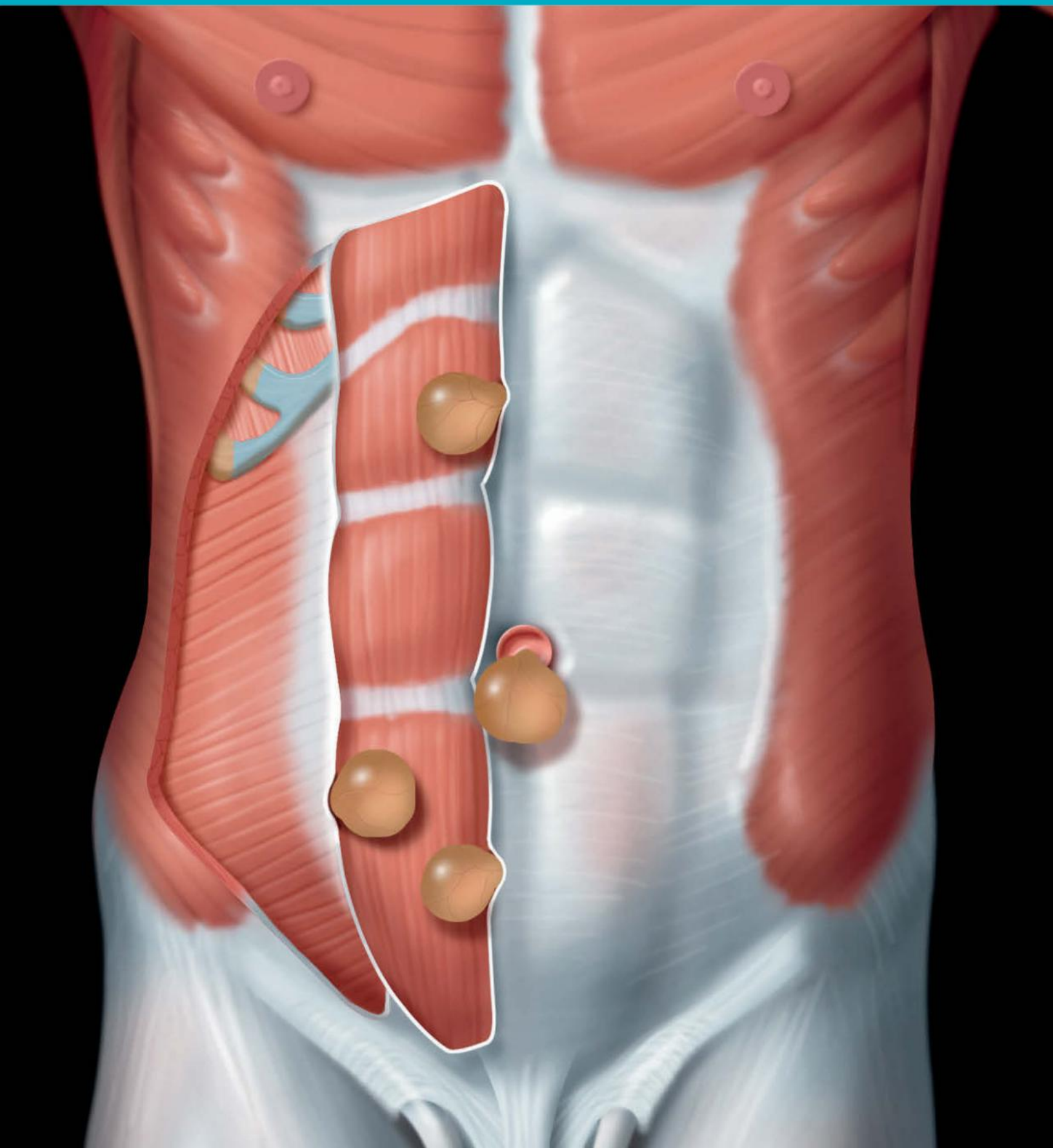

PART III
SECTION 8

Hernia

Abdominal Wall Hernia 812
Groin Hernia 820

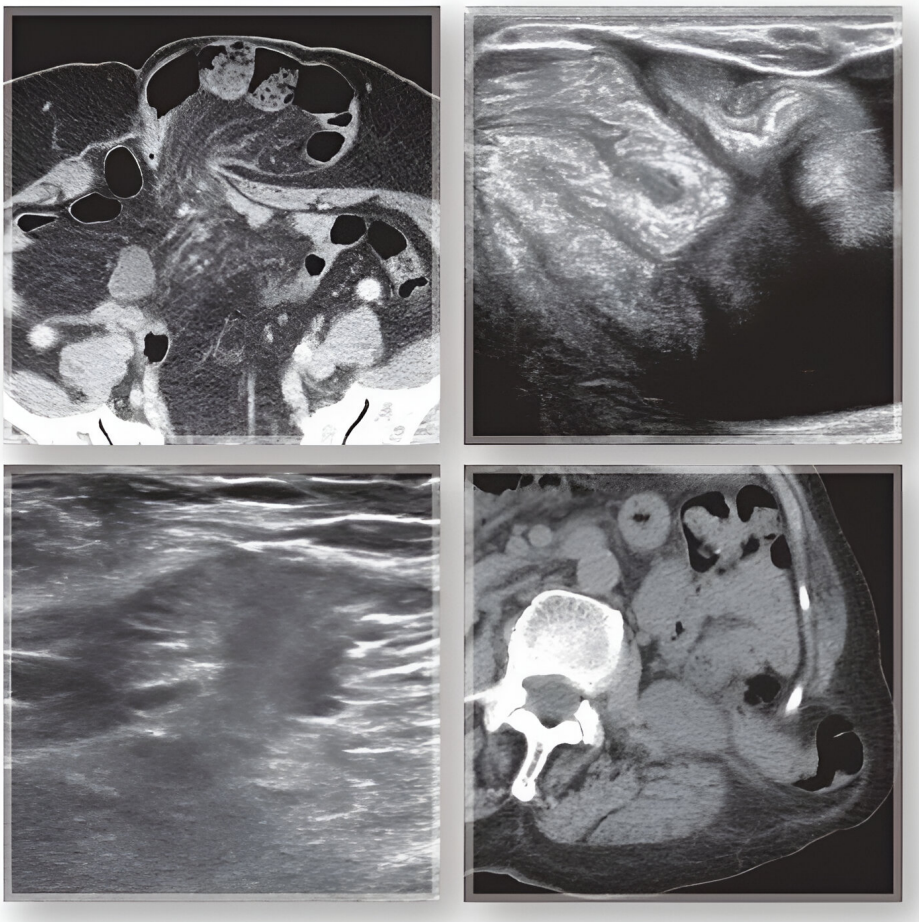

KEY FACTS

CLINICAL ISSUES

- Tissue protruding through defect in abdominal wall
  - Most abdominal wall hernias are point specific
- Midline hernias
  - Epigastric: Usually small
  - Umbilical: In children
  - Paraumbilical: In adults
  - Hypogastric: Rare
- Lateral hernias
  - Spigelian: Defect in transversus abdominis aponeurosis between its myoaponeurotic junction (linea semilunaris) & lateral border of rectus abdominis muscle
  - Lumbar: Occur in 2 areas of potential weakness in flank
  - Superior lumbar triangle (Grynfeltt hernia) with erector spinae medially, 12th rib superiorly, & internal oblique muscle laterally
  - Inferior lumbar triangle (Petit hernia) with latissimus dorsi muscle medially, iliac crest inferiorly, & external oblique muscle laterally

DIAGNOSTIC CHECKLIST

- For all abdominal wall masses, exclude presence of hernia
- If hernia confirmed, determine nature of herniated content (extraperitoneal/peritoneal fat, bowel) as well as site & size of abdominal wall defect
  - Routinely use Valsalva maneuver ± examination in standing position if symptoms exacerbated by standing
    - Can perform Valsalva maneuver by asking patient to blow against back of hand
- Observe for reducibility & consider whether bowel, if present, is obstructed or strangulated
  - Such complications are uncommon in noninguinal abdominal wall hernias
    - These hernias have either wide neck or, if neck is narrow, rarely contain bowel

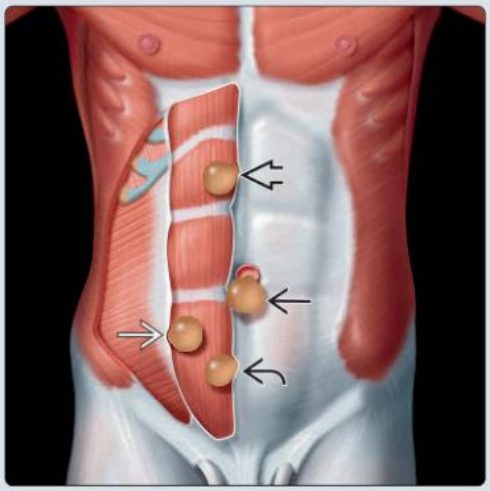

(Left) *Graphic shows a paraumbilical hernia ⇨ arising from the umbilicus area. The locations of the epigastric ⇨, Spigelian ⇨, and hypogastric ⇨ hernias are also shown for reference.* **(Right)** *Clinical photograph shows the typical appearance of a paraumbilical hernia in an adult with swelling ⇨ at the left paraumbilical region.*

(Left) *Transverse US in the same patient shows a paraumbilical hernia. There is a defect ⇨ in the linea alba with herniation of echogenic fat ⇨ and no bowel.* **(Right)** *Transverse US shows a medium-sized paraumbilical hernia ⇨ extending through a defect ⇨ in the linea alba at the umbilicus. The sac contains both echogenic peritoneal fat ⇨ and hypoechoic peritoneal fluid ⇨. No bowel content is present.*

TERMINOLOGY

Definitions

- Hernia: Abnormal protrusion of organ or part of organ out of the cavity in which it is normally contained
  - Reducible: Hernia that can reduce completely either spontaneously or with external pressure
  - Obstructed: Hernia leading to mechanical bowel obstruction
  - Strangulated: Hernia causing mechanical constriction of arterial supply to hernia content
  - Incarcerated: Hernia that cannot be reduced
- Types of abdominal wall hernia: Midline (epigastric, umbilical, hypogastric), lateral (Spigelian, lumbar), & incisional

IMAGING

General Features

- Best diagnostic clue
  - Abdominal wall lump due to tissue protruding through defect in abdominal wall
- Location
  - Most abdominal hernias are point specific
  - Midline hernias
    - Epigastric: Between xiphisternum & umbilicus
    - Umbilical: Umbilical or immediate paraumbilical region
    - Hypogastric: Between umbilicus & pubic symphysis
  - Lateral hernias
    - Spigelian
      - Defect along linea semilunaris in transversus abdominis aponeurosis, just lateral to rectus sheath
      - Most commonly located near arcuate line
    - Lumbar: Occur in 2 potentially weak areas of flank
      - Superior lumbar triangle (Grynfeltt hernia) bounded by erector spinae medially, 12th rib superiorly, & internal oblique muscle laterally
      - Inferior lumbar triangle (Petit hernia) bounded by latissimus dorsi muscle medially, iliac crest inferiorly, & external oblique muscle laterally
      - Superior more common than inferior
  - Incisional hernia: Located at surgical incisional site
- Morphology
  - Abdominal wall; anatomy
    - Layers: Skin, subcutaneous fat, musculofascial layer, transversalis fascia, & extraperitoneal fat
    - Musculofascial layer
      - Anterior wall: Paired rectus muscles enclosed by rectus sheath (aponeurosis of internal oblique, external oblique, & transversus abdominis muscles), which laterally forms linea semilunaris & centrally fuses to form linea alba
      - Anterolateral-lateral wall: External oblique, internal oblique, & transversus abdominis
      - Posterior wall: Quadratus lumborum & erector spinae muscles
    - Arcuate line: Lower margin of posterior rectus sheath ends at arcuate line, midway between umbilicus & pubic symphysis
    - Distal to arcuate line, rectus muscle is separated from peritoneum only by transversalis fascia, as aponeuroses of internal oblique, external oblique, & transversus abdominis pass anterior to rectus muscle
  - Epigastric hernia
    - Usually small with extraperitoneal fat protruding through linea alba ("fatty hernia of linea alba")
    - May occasionally be large & contain bowel
  - Umbilical hernia
    - Umbilical in children
      - Peritoneal content protrudes through patent umbilical ring
    - Paraumbilical in adults
      - Extraperitoneal fat ± peritoneal contents protrude at side of umbilical ring
  - Hypogastric hernia
    - Very uncommon
  - Spigelian hernia
    - Defect in transversus abdominis aponeurosis between myoaponeurotic junction (linea semilunaris) & lateral border of rectus abdominis (Spigelian fascia)
    - Tends to occur within 6 cm above imaginary line connecting both anterior superior iliac spines
    - Usually extends deep to the intact external oblique muscle & fascia or may extend into rectus sheath ("interparietal hernia")
      - Very rarely extends to subcutaneous layer
      - Can present as flank lump if extends laterally
  - Lumbar hernia
    - Usually painless due to wide hernial neck
  - Incisional hernia
    - Occurs in 0.5-14.0% of postoperative patients
    - May occur years after surgery, though usually occurs within 1st year
    - May go unnoticed by patient & be incidentally detected on imaging
      - Can be very large

CT Findings

- Accurate at assessing presence of site & size of hernia & identifying sac contents
  - Useful for assessing larger deep-seated hernias
  - Prone position ± Valsalva maneuver may help if equivocal

Ultrasonographic Findings

- Grayscale ultrasound
  - Identifies location/size of abdominal wall defect, herniated content (extraperitoneal/peritoneal fat, bowel), & complications
    - Extraperitoneal or peritoneal fat: Echogenic/hypoechoic tissue without peristalsis
    - Bowel: "Target" echo pattern with strong central echoes due to air in lumen & visible peristalsis
      - May see valvulae conniventes (small bowel) or feculent content (large bowel)
      - Variable appearances due to air-fluid content
  - Reducibility
    - Reduction in hernia size with ↓ in intraabdominal pressure or application of transducer pressure onto hernial sac

- Irreducible (incarcerated) hernia may proceed to become obstructed or strangulated
  - These complications are uncommon in noninguinal abdominal wall hernias due to wide neck & infrequent bowel content
- Obstruction
  - Nonobstructed hernia: Shows active peristalsis & movement of intestinal contents
  - Obstructed hernia: Irreducible hernia with narrow neck & features of bowel obstruction
    - Not easy to diagnose with US; better appreciated with radiography or CT
- Strangulation
  - No flow on color Doppler imaging within bowel wall or mesentery, swollen bowel wall, aperistalsis, gas within or outside of bowel wall
    - Color Doppler imaging not reliable as many nonstrangulated hernias do not show color flow
    - Other signs are also unreliable, making it difficult to assess strangulation on US

Imaging Recommendations

- Best imaging tool
  - US is accurate & allows dynamic assessment
    - CT or MR ± performed with Valsalva maneuver
- Protocol advice
  - Identify anatomical layers, localize focal abdominal wall defect, compare with opposite side (if possible), & identify hernial contents
    - Use light transducer pressure to avoid inhibition of herniation
    - Valsalva maneuver is used routinely
    - Examine in standing position if supine position negative or equivocal, particularly if standing clinically accentuates hernia
    - Measure size of hernial sac as well as size of fascial defect
    - If bowel content, check for complications (irreducibility/obstruction/strangulation)

DIFFERENTIAL DIAGNOSIS

Divarication of Rectus Abdominis Muscles

- Pseudoherniation due to stretching & thinning of linea alba with wide separation of rectus abdominis muscles
- Also known as "diastasis recti"

Abdominal Wall Muscle Atrophy

- Pseudoherniation due to abdominal wall muscle atrophy/weakness from denervation

Abdominal Wall Tumor

- Primary (lipoma, desmoid tumor, endometriosis) or metastatic (scar metastasis, umbilical metastasis)

Abdominal Wall Abscess or Seroma

- No fascial defect present

Rectus Sheath Hematoma

- Posttraumatic or spontaneous: Bleeding of epigastric vessels ± muscle tear
- No fascial defect present

PATHOLOGY

General Features

- Etiology
  - Chronic increased intraabdominal pressure, abdominal distension (ascites) ± muscle laxity (obesity, old age)
    - Weak abdominal wall musculature
    - Physical exertion, chronic cough, prostatism, or constipation
  - Trauma: Blunt force or hyperextension strain
    - Insufficient to penetrate skin but strong enough to disrupt muscle & fascia
    - Sudden ↑ in intraabdominal pressure
  - Postoperative abdominal wall weakness, surgical scar, suture dehiscence
  - Epigastric hernia may be related to anomalous slips from diaphragm to linea alba region

CLINICAL ISSUES

Presentation

- Most common signs/symptoms
  - Abdominal lump increasing in size with ↑ in intraabdominal pressure
  - Reducible swelling with positive cough impulse
  - Intermittent intestinal obstruction

Demographics

- Age
  - Umbilical hernia: Young children. Paraumbilical hernia: Adults
  - Epigastric hernia: 20-50 years
  - Incisional hernia: More frequent in older adults
- Gender
  - Epigastric hernia is 2x as common in males
- Epidemiology
  - Most common abdominal wall lesion in US practice

Natural History & Prognosis

- 1/3 of umbilical hernias close within 1 month of birth & rarely persist beyond 3-4 years
- All other hernias persist & frequently enlarge with time

Treatment

- Repair of muscle/fascial defect: Open or laparoscopic technique, meshplasty
- Intestinal obstruction/strangulated hernia; urgent exploratory laparotomy

DIAGNOSTIC CHECKLIST

Consider

- Abdominal wall hernia if posterior margin of any abdominal wall mass cannot be seen on US

Image Interpretation Pearls

- Check for abdominal wall defect, hernial sac contents, peristaltic bowel movement, & vascularity

SELECTED REFERENCES

1. Petr L et al: Spigelian hernia. Rozhl Chir. 103(3):96-9, 2024
2. Read JW et al: Imaging insights into abdominal wall function. Front Surg. 9:799277, 2022

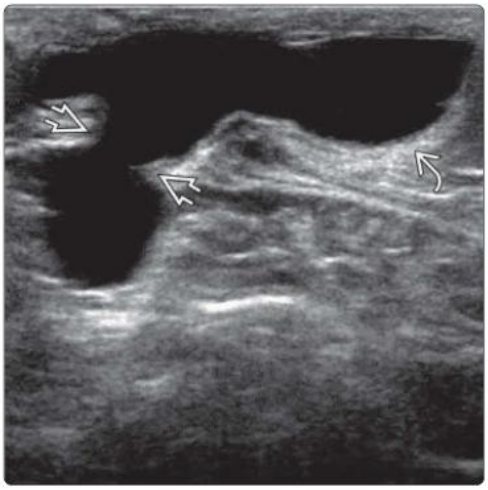

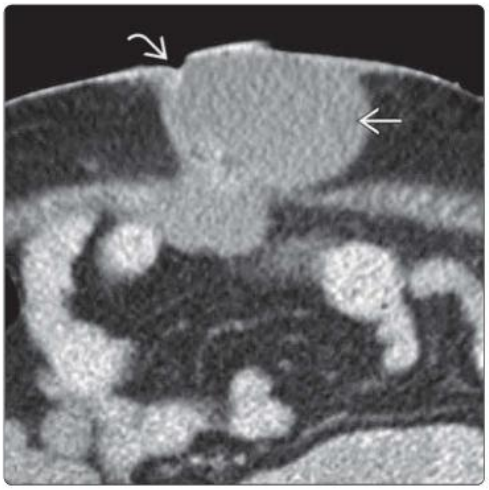

(Left) *Transverse US shows a large paraumbilical hernia ⇨ protruding through a defect in the linea alba at the umbilicus ⇨. The sac contains peritoneal fluid. This seemed to be encysted, as it was not readily reducible. No bowel content is present.* **(Right)** *Axial NECT in the same patient shows a large paraumbilical hernia. The sac ⇨ content is made up entirely of encysted peritoneal fluid. No bowel content is present. The hernia bulges to the side of the umbilicus ⇨.*

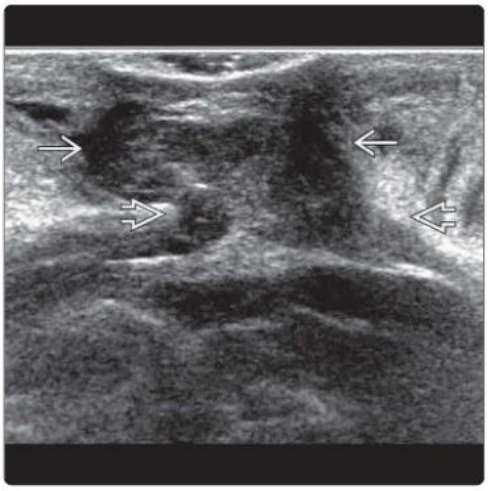

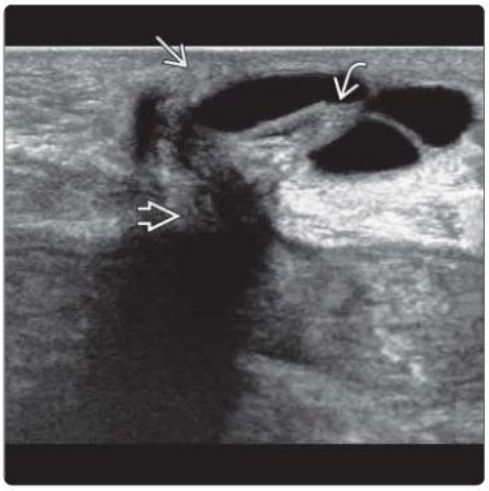

(Left) *Transverse US shows a medium-sized umbilical hernia ⇨. The hernial sac is filled with peritoneal fat. The defect ⇨ in the linea alba at the umbilicus is wide.* **(Right)** *Transverse US shows a medium-sized umbilical hernia ⇨. The hernial sac contains peritoneal fat ⇨ as well as encysted peritoneal fluid. No bowel content is present. The hernial neck often shows acoustic shadowing ⇨ despite the absence of bowel content due to a compactness of tissues in this area.*

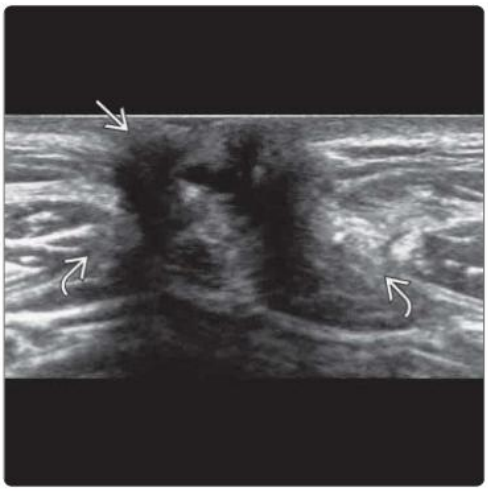

(Left) *Transverse US shows a small umbilical hernia ⇨ extending though a wide defect ⇨ in the linea alba.* **(Right)** *Longitudinal US in the same patient shows that the umbilical hernia contains bowel and extends cephalad ⇨ from the umbilicus ⇨ within the subcutaneous fat. Umbilical hernias in adults are more common in overweight subjects and following pregnancy.*

(Left) *Transverse US shows a medium-sized epigastric hernia in the supraumbilical region (also called linea alba hernia). A small defect ➡ is present in the linea alba with herniation of hypoechoic extraperitoneal fat ⇄.* **(Right)** *Longitudinal US in the same patient shows a small defect ➡ through the linea alba ➡ with herniation of extraperitoneal fat ⇄. Without identification of the small fascial defect, an epigastric hernia may be misdiagnosed as a lipoma.*

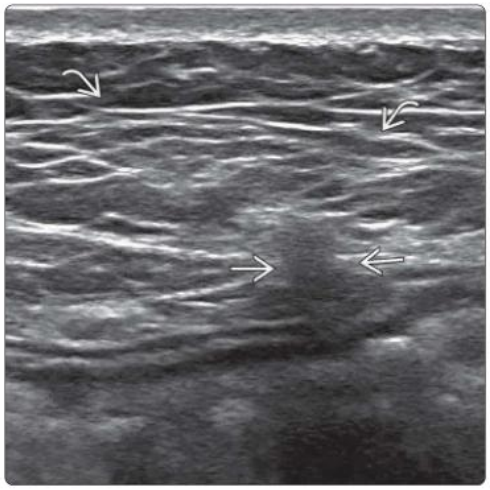

(Left) *Transverse US shows a small epigastric hernia ➡ containing hypoechoic extraperitoneal fat. Fat may appear as either hyperechoic or hypoechoic on US. The defect ➡ in the linea alba is clearly seen.* **(Right)** *Axial CECT in the same patient obtained several weeks after US examination shows how the wall of the epigastric hernia ➡ is very thin. The hernial sac is larger than on US. This may be due to interim increase in hernial sac size or due to the effect of transducer pressure on sac size.*

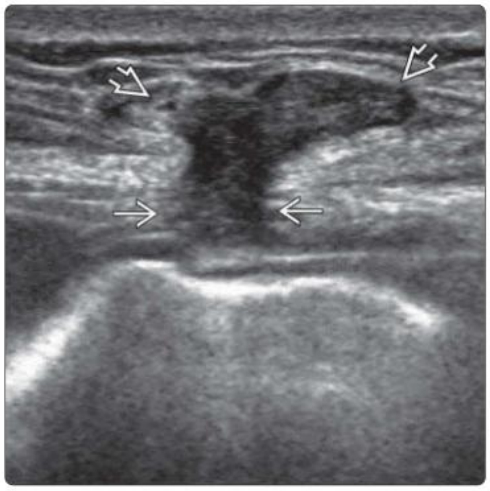

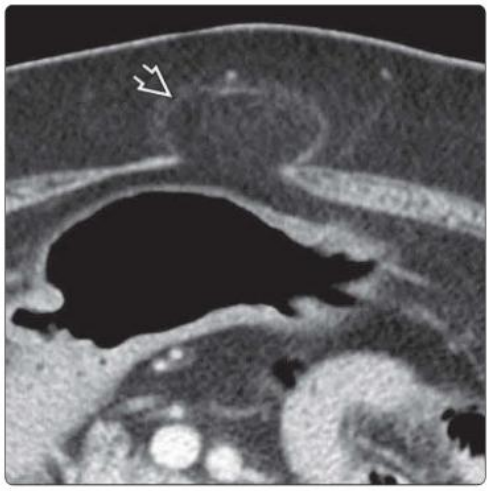

(Left) *Transverse US shows an unusually large epigastric hernia ➡ containing hyperechoic peritoneal fat and a small amount of peritoneal fluid ⇄. No bowel is present.* **(Right)** *Transverse US shows another unusually large epigastric hernia ➡ containing peritoneal fat. There is acoustic shadowing present at the hernial neck ➡. This is a common feature of hernias and does not imply bowel content in the hernial sac.*

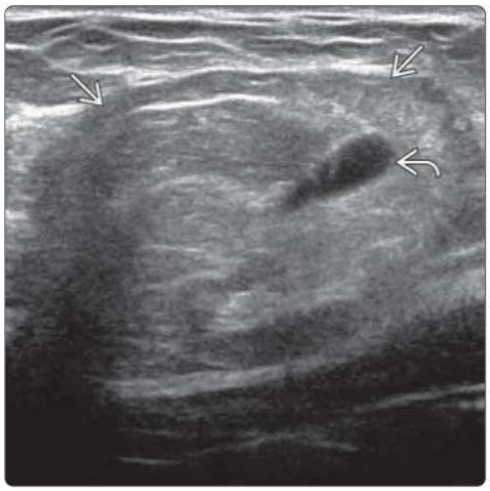

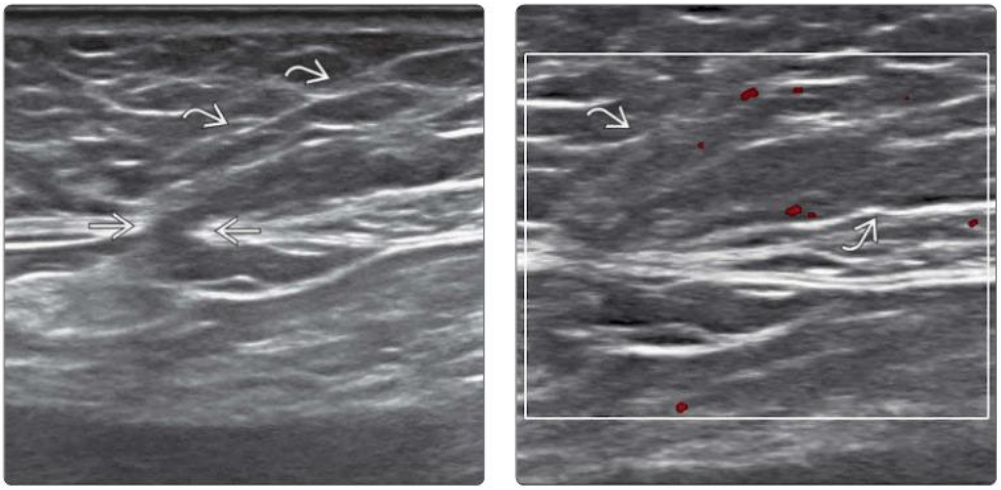

(Left) *Transverse US shows an epigastric hernia. There is a small defect ➡ in the linea alba with herniation of extraperitoneal fat ⇨. No herniation of peritoneal contents is present.* **(Right)** *Transverse color Doppler US in the same patient shows mild internal vascularity in the herniated extraperitoneal fat ⇨.*

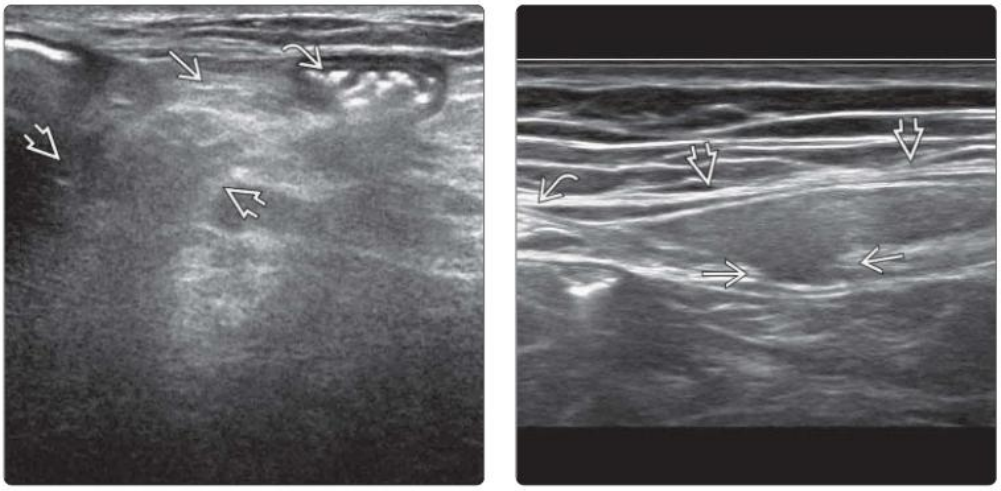

(Left) *Longitudinal US shows a large hypogastric hernia ➡ at the infraumbilical region. The sac contains both bowel ⇨ and peritoneal fat ➡.* **(Right)** *Transverse US shows a small Spigelian hernia in the left lower abdomen. A fascial defect ➡ is present in the transversus abdominis aponeurosis. There is fat herniation through the defect, but the hernia sac stays deep to the external oblique aponeurosis ➡. The lateral edge of the left rectus abdominis ➡ muscle is shown.*

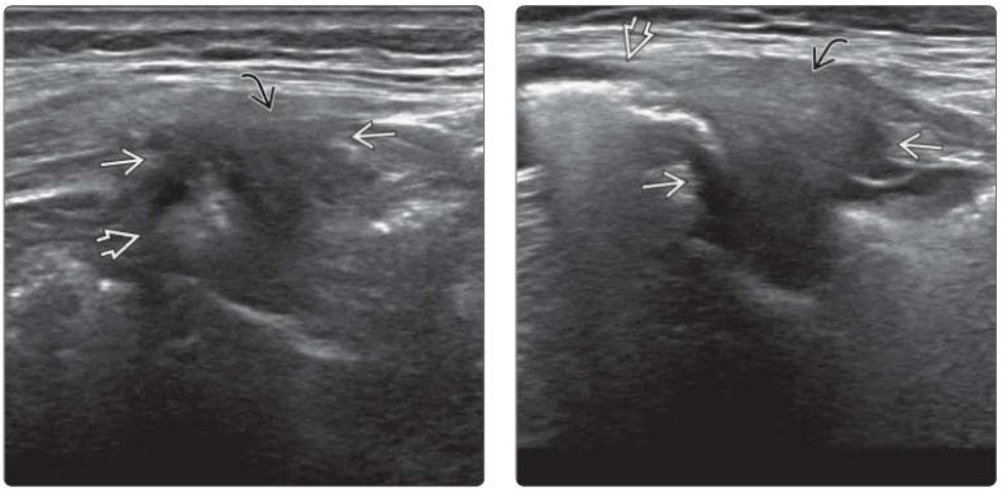

(Left) *Transverse US shows a Spigelian hernia in the right lower abdomen. There is a defect ➡ in the Spigelian fascia with herniation of bowel ➡ and peritoneal fat ⇨.* **(Right)** *Transverse US of the same patient performed with Valsalva maneuver shows obvious increased herniation of bowel ➡ and peritoneal fat ⇨ through the fascial defect ➡ into the hernial sac. Valsalva maneuver should be part of a standard assessment for hernia.*

(Left) *Graphic shows a superior lumbar hernia (Grynfeltt hernia) arising from the superior lumbar triangle bounded by the erector spinae muscle medially ⇨, the 12th rib superiorly ⇨, and the internal oblique muscle laterally ⇨.* **(Right)** *Graphic shows an inferior lumbar hernia (Petit hernia) arising from the inferior lumbar triangle bounded by the latissimus dorsi muscle medially ⇨, the iliac crest inferiorly ⇨, and the external oblique muscle laterally ⇨.*

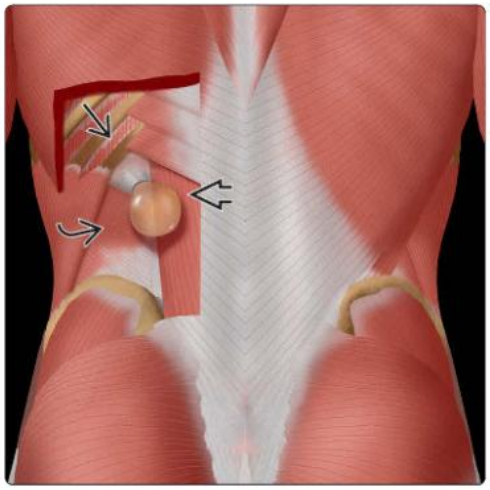

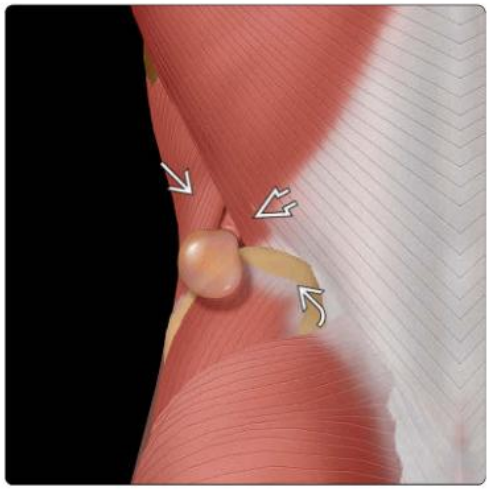

(Left) *Transverse US shows a large lumbar hernia ⇨ extending through a defect ⇨ in the superior lumbar triangle. The sac contains both bowel ⇨ and peritoneal fat ⇨.* **(Right)** *Axial NECT in the same patient shows the large lumbar hernia ⇨ extending through the superior lumbar triangle and containing bowel ⇨ and intraperitoneal fat. The 12th rib is shown ⇨. Lumbar hernias may contain intra- or extraperitoneal contents and therefore benefit from CT examination.*

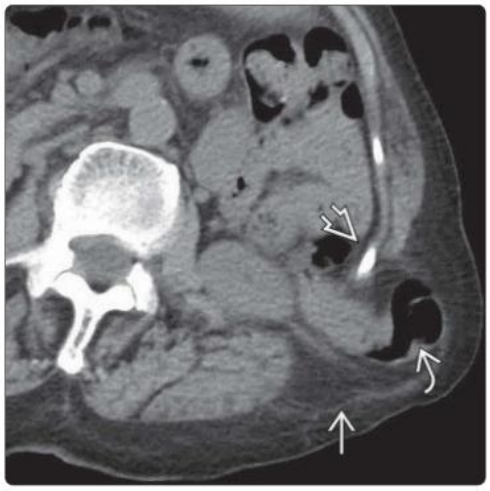

(Left) *Oblique US shows a large lumbar hernia ⇨ extending through a wide defect ⇨ in the superior lumbar triangle. The hernia contains hypoechoic fat, but it is not clear on US whether this fat is intraperitoneal or extraperitoneal in origin.* **(Right)** *Axial NECT in the same patient shows the large lumbar hernia ⇨ containing retroperitoneal fat. The colon, spleen, liver, and kidney may all herniate through either superior or inferior lumbar triangle defects.*

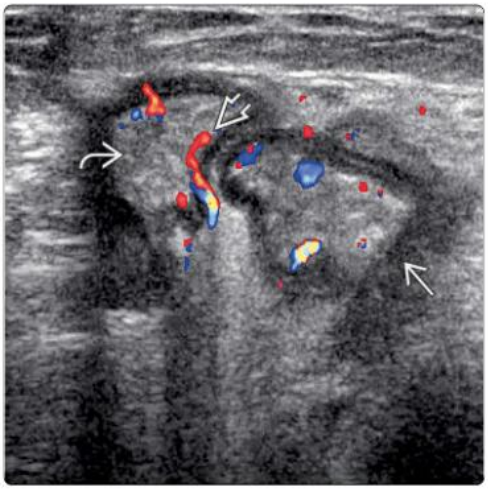

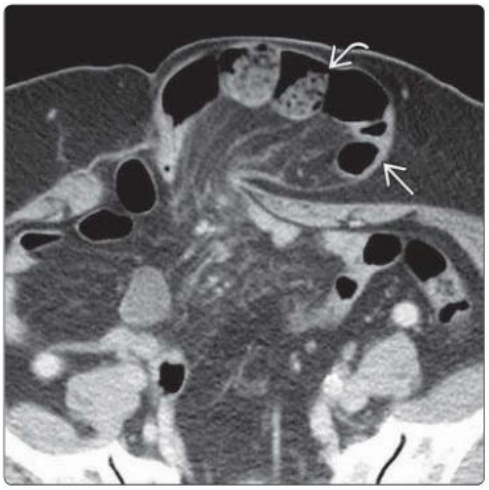

(Left) *Transverse color Doppler US shows a large incisional hernia* ➡ *extending through a midline abdominal incision. The sac contains mainly bowel* ➡. *This bowel is well vascularized* ➡, *but the absence of vascularity on color Doppler imaging does not necessarily imply ischemia.* **(Right)** *Axial NECT in the same patient shows the large incisional hernia* ➡ *extending through a defect in the anterior abdominal wall. The bowel* ➡ *within the hernia sac is normal in appearance.*

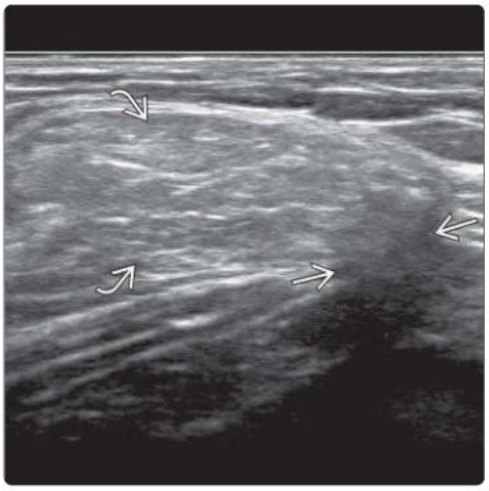

(Left) *Transverse US shows an incisional hernia in the right lower abdomen at previous laparoscopy port site. At supine position, there is herniation of small amount of peritoneal fat* ➡ *through a small fascial defect* ➡. **(Right)** *Transverse US in the same patient performed in standing position shows obvious increased herniation of peritoneal fat* ➡ *through the fascial defect* ➡. *No bowel herniation is present.*

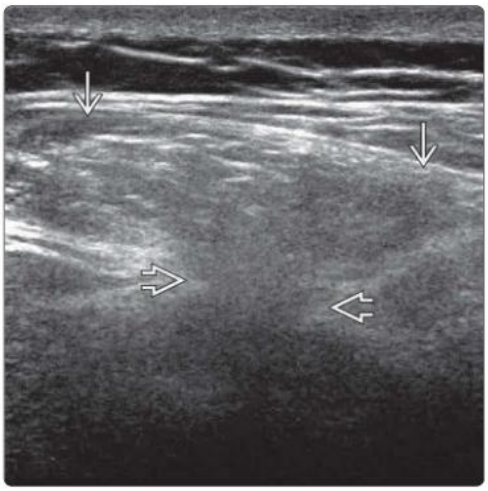

(Left) *Transverse US shows a large incisional hernia* ➡ *at the site of prior percutaneous nephrostomy* ➡. *The sac contains the retroperitoneal fat.* **(Right)** *Axial NECT in the same patient shows the large incisional hernia* ➡. *The sac contains retroperitoneal fat. The site of the hernia is similar to the site of the superior lumbar hernia; however, in this situation, the hernia followed a percutaneous procedure at this site and is therefore deemed an incisional hernia.*

KEY FACTS

TERMINOLOGY

- Hernia: Abnormal protrusion of organ or part of organ out of cavity in which it is normally contained
- Indirect inguinal hernia, direct inguinal hernia, femoral hernia

IMAGING

- **Indirect inguinal hernia**: Passes through deep inguinal ring, extends along inguinal canal, & emerges at superficial inguinal ring
- **Direct inguinal hernia**: Passes through transversalis fascia in Hesselbach triangle
- **Femoral hernia**: Passes through femoral canal
- Identify inguinal ligament, inferior epigastric artery, & spermatic cord
- Trace spermatic cord in transverse plane retrogradely from high scrotal area to deep inguinal ring
- Specifically examine deep inguinal ring, Hesselbach triangle, & femoral canal areas
- Examine each area at rest & during Valsalva maneuver
  - For Valsalva, ask patient to blow onto back of hand
- Determine presence of hernia ± laxity of fascia
- Also assess relaxation phase of Valsalva
- ± Reexamine with patient standing erect
- US: 97% sensitivity, 86% specificity, & 93% positive predictive value for diagnosis of groin hernia
  - Pure fatty hernia is most difficult to diagnose
  - Slightly lower accuracy for specific hernia type
- CT or MR: Useful if US is equivocal

DIAGNOSTIC CHECKLIST

- Indirect inguinal hernia neck: Above inguinal ligament & lateral to inferior epigastric artery
- Direct inguinal hernia neck: Above inguinal ligament & medial to inferior epigastric artery
- Femoral hernia: Below inguinal ligament
- Routinely examine all 3 sites

(Left) *Graphic shows a direct inguinal hernia ⇨. Note that the neck of a direct inguinal hernia is medial to the inferior epigastric vessels ⇨. A direct inguinal hernia passes through the transversalis fascial defect in the Hesselbach triangle.* **(Right)** *Transverse US shows a right direct inguinal hernia ⇨ containing hypoechoic peritoneal fat. The neck ⇨ of the hernia lies medial to the inferior epigastric vessels ⇨.*

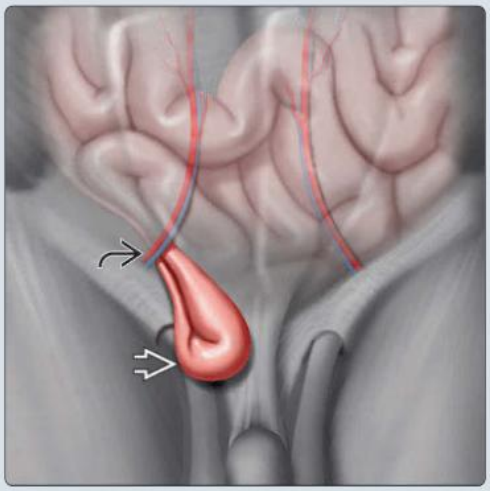

(Left) *Transverse US shows a left direct inguinal hernia ⇨ containing the bowel ⇨. The neck ⇨ of the hernia is wide and lies medial to the inferior epigastric vessels ⇨. Obstruction is rare in direct inguinal hernias, as they usually have wide necks.* **(Right)** *Longitudinal US of the same direct inguinal hernia ⇨ shows that it arises cephalad to the inguinal ligament ⇨. The inguinal ligament is difficult to appreciate on still images but is more readily appreciable in real time.*

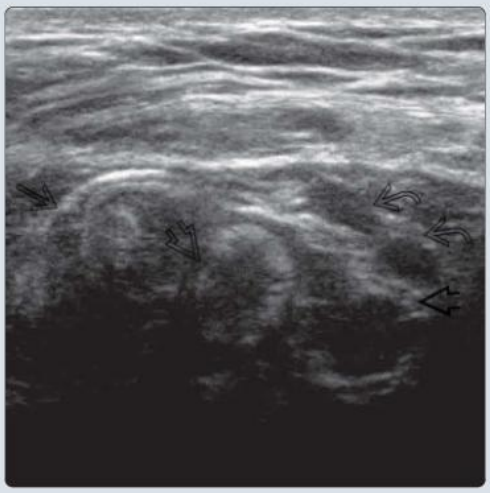

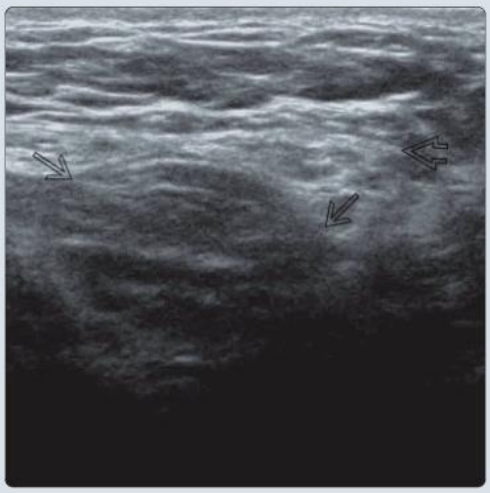

TERMINOLOGY

Synonyms

- Inguinal hernia, indirect inguinal hernia, direct inguinal hernia, femoral hernia

Definitions

- Abnormal protrusion of organ or part of organ out of cavity in which it is normally contained

IMAGING

General Features

- Location
  - **Inguinal canal**
    - ~ 4.0 cm long, ~ 1.2 cm above inguinal ligament
      - Contains ilioinguinal nerve, genital branch of genitofemoral nerve, spermatic cord in males, & round ligament of uterus in female patients
    - Floor: Inguinal ligament formed from thickened, free, lowermost border of external oblique aponeurosis
      - Runs from anterior superior iliac spine to pubic tubercle
    - Anterior wall: External oblique aponeurosis
      - Triangular defect medially forms superficial inguinal ring
    - Roof: Internal oblique & transversus abdominis aponeurosis
      - Attached to lateral part of inguinal ligament
      - Medially arches over superficial inguinal ring as conjoint tendon
    - Posterior wall: Transversalis fascia
      - Contains rounded defect midway between anterior superior iliac spine & pubic tubercle, known as deep inguinal ring
    - Inferior epigastric artery from external iliac artery runs just medial to deep inguinal ring on way to rectus sheath
    - Hesselbach triangle located between inferior epigastric artery laterally, rectus sheath medially, & inguinal ligament inferiorly
  - **Femoral canal**
    - ~ 2 cm long, just medial to femoral vein, deep & distal to inguinal ligament
    - Anterosuperior border: Inguinal ligament
    - Medial border: Lacunar ligament (reflection of inguinal ligament to pectineal line)
    - Floor: Pectineal ligament (reflection of inguinal ligament over superior pubic ramus) & pectineus muscle
    - Lateral border: Femoral vein
  - **Indirect inguinal hernia**
    - Passes through deep inguinal ring, extends along inguinal canal, & emerges at superficial inguinal ring
    - Neck is lateral to inferior epigastric artery & above inguinal ligament
    - In males, usually extends along spermatic cord to scrotum
    - In female patients, may extend along round ligament to labia majora
  - **Direct inguinal hernia**
    - Passes through transversalis fascial defect in Hesselbach triangle
    - Wide neck medial to inferior epigastric artery & above inguinal ligament
    - Generally does not extend to scrotum
  - **Femoral hernia**
    - Passes through femoral canal
    - Narrow neck medial to femoral vein & below inguinal ligament
  - **Double hernia** (a.k.a. saddlebag or pantaloon hernia)
    - Simultaneous occurrence of direct & indirect inguinal hernia in same groin

Radiographic Findings

- Radiography
  - ± small or large bowel obstruction
  - Herniography: Injection of soluble, low osmolar contrast medium into peritoneal cavity

Ultrasonographic Findings

- Grayscale ultrasound
  - Accurate at identifying presence & site of hernia as well as contents of hernial sac (bowel or peritoneal fat)
    - Peritoneal fat: Echogenic tissue without peristalsis
    - Bowel: Intestinal loops; target echo pattern with strong central echoes representing air or fluid in lumen ± peristalsis
      - Nonobstructed hernia: Active peristalsis ± movement of intestinal contents
      - Obstructed hernia: No movement of intestinal content in hernia & dilated bowel loops in abdomen, may have peristalsis
  - Reducible hernia
    - Decrease in hernia size with decrease in intraabdominal pressure or application of external pressure to hernial sac with transducer
    - Increase in hernia size during coughing, Valsalva maneuver, or standing
    - Femoral hernia: Extrusion of hernia during Valsalva maneuver can cause transient collapse of femoral vein
- Color Doppler
  - Useful to identify inferior epigastric artery
  - Strangulated hernia; absence of vascularity within bowel wall & mesentery but not reliable sign

Imaging Recommendations

- Best imaging tool
  - US is accurate if strict systematic approach is used
    - 97% sensitivity, 86% specificity, & 93% positive predictive value for diagnosis of groin hernia
    - Slightly lower accuracy for determining type of hernia (indirect inguinal, direct inguinal, femoral)
  - CT or MR is useful if US is equivocal
    - Use low-dose CT technique
    - Prone position ± Valsalva maneuver may help if equivocal
- Protocol advice
  - 1st identify inferior epigastric artery, spermatic cord (or round ligament), & inguinal ligament
    - Inferior epigastric vessels identified at lateral margin of rectus femoris muscle & traced inferiorly

- Trace spermatic cord in transverse plane retrogradely from high scrotal area to deep inguinal ring
- Specifically examine deep inguinal ring, Hesselbach triangle area, & femoral canal
- At each area, examine at rest, & ask patient to perform Valsalva maneuver
  - For Valsalva, ask patient to blow onto back of hand
  - Look for presence of hernia or laxity (bulging) of fascia (on Valsalva maneuver)
  - Also assess relaxation phase of Valsalva
  - Reexamine specific areas with patient standing if standing accentuates symptoms and supine examination negative
- Routinely examine all 3 hernia areas
  - 2 or more hernias can coexist

DIFFERENTIAL DIAGNOSIS

Lipoma of Spermatic Cord

- No change with Valsalva maneuver, not reducible
- Usually no deep extension into peritoneal cavity

Spermatid Cord/Canal of Nuck Encysted Hydrocele

- Embryologically, processus vaginalis extends from peritoneal cavity to scrotum in males
  - Normally obliterates in cord (canal of Nuck in female patients), while scrotal component persists as tunica vaginalis
  - Failure of obliteration leads to fluid distention within cord/canal of Nuck, known as encysted hydrocele
    - Filled with anechoic fluid, no change with Valsalva maneuver, not reducible
    - No deep extension into peritoneal cavity

PATHOLOGY

General Features

- Etiology
  - Chronic increased intraabdominal pressure, abdominal distention (ascites) ± muscle laxity
    - Obesity, chronic cough, prostatism, constipation, heavy weightlifting
  - Indirect inguinal hernia: Usually congenital due to persistence of processus vaginalis
  - Direct inguinal hernia: Acquired due to weakness of transversalis fascia in Hesselbach triangle
  - Femoral hernia: Weakness of femoral canal

Gross Pathologic & Surgical Features

- Sac contents: Commonly peritoneal fat, less commonly small bowel, or uncommonly mobile colon segments (sigmoid, cecum, appendix)
  - Incarcerated hernia: Irreducible hernias
  - Strangulated hernia: Ischemic → infarcted hernia
  - Sliding hernia: Sac contains retroperitoneal organs
    - Urinary bladder, distal ureters, or ascending/descending colon
  - Littre hernia: Meckel diverticulum in sac
  - Amyand hernia: Appendix vermiformis in sac
  - Richter hernia: Only portion of bowel circumference (antimesenteric portion) in sac

CLINICAL ISSUES

Presentation

- Most common signs/symptoms
  - Groin lump or discomfort (continuous or intermittent)
- Other signs/symptoms
  - Features of intestinal obstruction

Demographics

- Age
  - Indirect inguinal hernia tends to occur in young to middle-aged individuals
  - Prevalence of direct inguinal hernia increases with increasing age
  - Femoral hernia is more common in middle-aged to older adults
- Sex
  - Indirect inguinal hernia is 5-10x more common in males
  - Direct inguinal hernia nearly always occurs in males
  - Femoral hernia is more common in female patients
    - However, indirect inguinal hernia is most common hernia in female patients
- Epidemiology
  - 5% of males develop groin hernia
  - 75% of all hernias occur in inguinal region
  - Indirect inguinal hernias are 5x more common than direct inguinal hernias
    - Femoral hernia is much less common
  - Inguinal hernia in children is always result of patent processus vaginalis & is thus indirect hernia extending to scrotal sac
    - Affects 2% of all children
    - Most often seen in premature infants, particularly on right side (75%), bilateral (10%)

Natural History & Prognosis

- Hernias recur after hernia repair in 20% of patients
- Complications: Obstruction, strangulation
  - Indirect inguinal hernia accounts for 15% of intestinal obstruction cases
  - Obstruction or strangulation is rare with direct inguinal hernia (wide neck) & more common with femoral hernia (narrow neck)

Treatment

- Laparoscopic or open hernia repair

DIAGNOSTIC CHECKLIST

Consider

- Indirect inguinal hernia neck: Above inguinal ligament & lateral to inferior epigastric artery
- Direct inguinal hernia neck: Above inguinal ligament & medial to inferior epigastric artery
- Femoral hernia: Below inguinal ligament

SELECTED REFERENCES

1. Karatay E et al: Diagnostic impact of using the semi-erect position in the evaluation of inguinal hernia with superficial sonography. Pol Przegl Chir. 96(4):9-14, 2024
2. Vassalou EE et al: The role of imaging in the pre- and postoperative evaluation of inguinal hernia. J Ultrasound Med. 42(10):2425-38, 2023

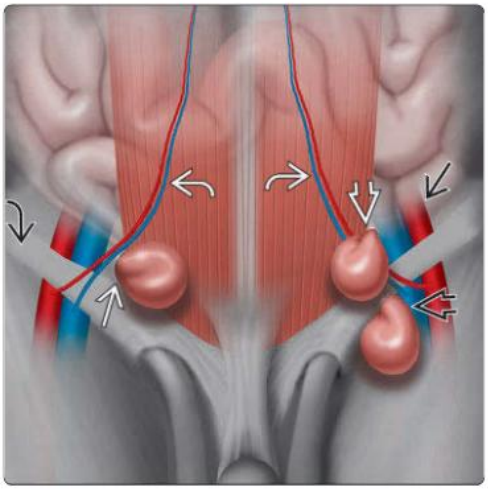

(Left) *Graphic shows 3 types of groin hernias. Direct ➡ and indirect ➡ inguinal hernias arise above the inguinal ligament ⇨ and medial and lateral to the inferior epigastric vessels ➡ respectively. Femoral hernias ⇨ arise below the inguinal ligament and medial to the femoral vessels ⇨.* **(Right)** *Graphic shows an indirect inguinal hernia entering the right scrotal sac. Note that the neck ➡ of an indirect inguinal hernia lies lateral to the inferior epigastric vessels ➡.*

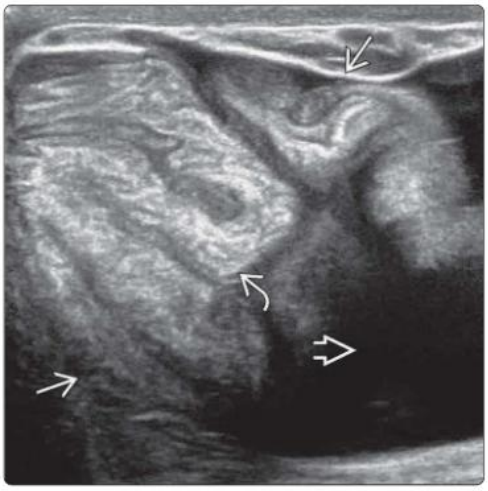

(Left) *Transverse US shows a large indirect inguinal hernia ➡ extending into the upper scrotal region. There is fluid ➡ and bowel ➡ within the hernia sac.* **(Right)** *Transverse US shows a left indirect inguinal hernia with herniation of peritoneal fat ➡ and bowel ⇨. The neck ➡ of the hernia lies lateral to the inferior epigastric vessels ➡.*

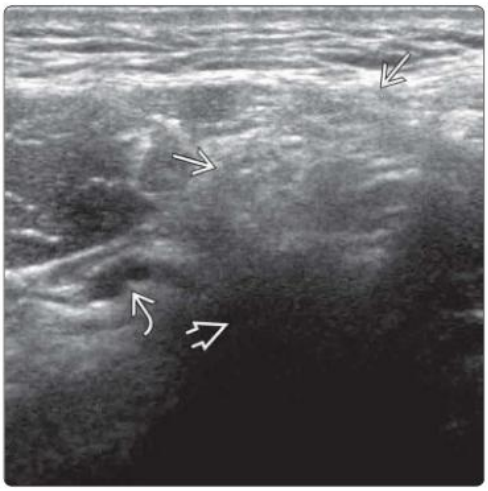

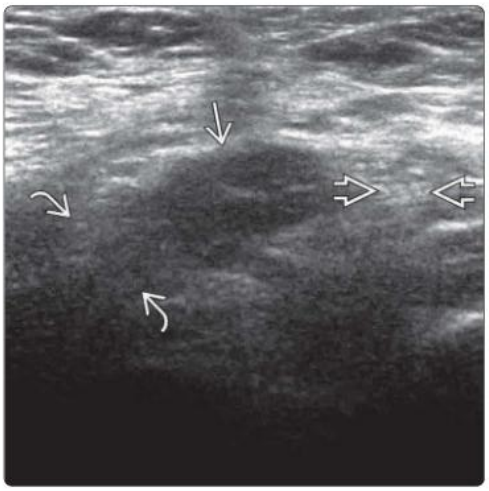

(Left) *Transverse US shows a left indirect inguinal hernia ➡ containing peritoneal fat and no bowel. The neck ➡ of the hernia lies lateral to the inferior epigastric vessels ➡. Place the transducer over the deep inguinal ring before Valsalva maneuver. To-and-fro movement of the hernial sac can usually be observed on real-time imaging.* **(Right)** *Longitudinal US of the same hernia ➡ shows that the hernia neck ➡ lies cephalad to the inguinal ligament ➡.*

(Left) *Transverse US shows a left inguinal hernia with a small amount of fat ⇄ herniation at rest in the supine position. The hernial neck ➡ lies lateral to the inferior epigastric vessels ➡.* **(Right)** *Transverse US of the same left inguinal hernia with Valsalva maneuver shows increased herniation of peritoneal fat ⇄. The hernial neck ➡ lies lateral to the inferior epigastric vessels ➡. Valsalva maneuver should be part of a standard assessment for hernia.*

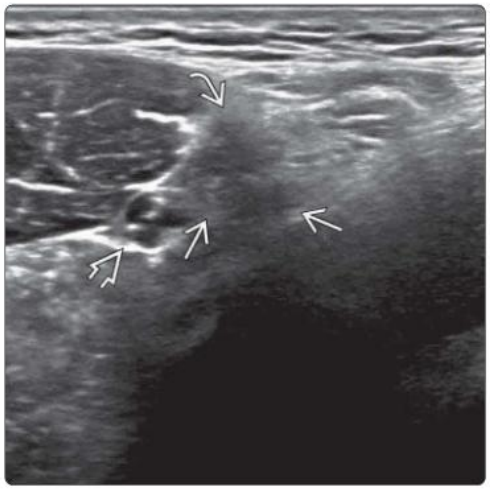

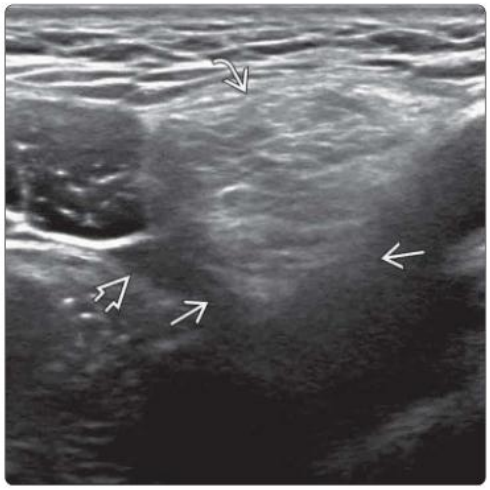

(Left) *Longitudinal US of the same indirect inguinal hernia shows that the herniated peritoneal fat ⇄ lies alongside the spermatid cord ➡ within the inguinal canal ⇄, which is located cephalad to the inguinal ligament ➡.* **(Right)** *Transverse US shows a left indirect inguinal hernia ➡ containing peritoneal fat. The hernia neck ➡ lies lateral to the inferior epigastric veins and artery ⇄. Indirect inguinal hernias are related to persistence of the processus vaginalis.*

(Left) *Transverse US shows a right indirect inguinal hernia with herniation of peritoneal fluid ⇄ only. The hernial neck ➡ lies lateral to the inferior epigastric vessels ➡.* **(Right)** *Transverse US shows concurrent left direct ➡ and indirect ⇨ inguinal hernias, both containing peritoneal fat. The necks of the indirect ⇨ and direct ➡ hernias lie lateral and medial to the epigastric vessels ⇄ respectively. This is known as a saddlebag hernia.*

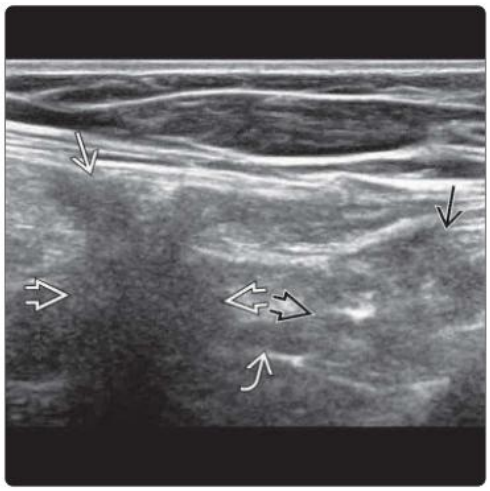

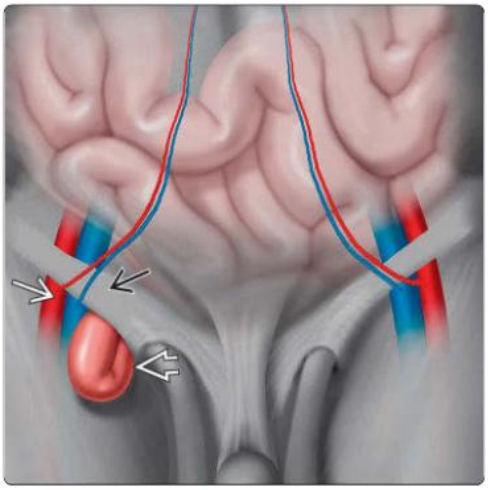

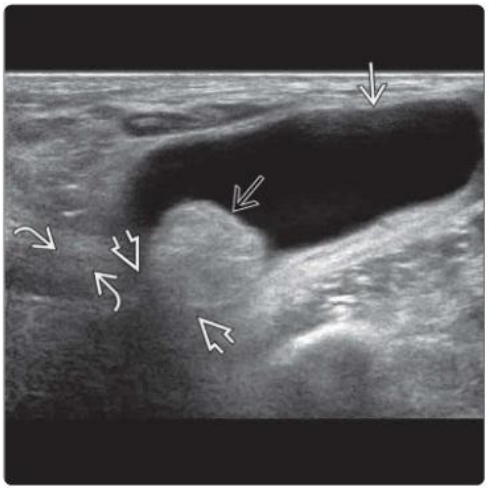

(Left) *Graphic shows a femoral hernia. Note that the neck of a femoral hernia lies medial to the femoral vein and inferior to the inguinal ligament.* **(Right)** *Longitudinal US of a femoral hernia containing fluid and peritoneal fat shows that the neck of the hernia lies inferior to the inguinal ligament. The relationship to the inguinal ligament helps mainly to discriminate between direct inguinal and femoral hernias, which may otherwise appear similar.*

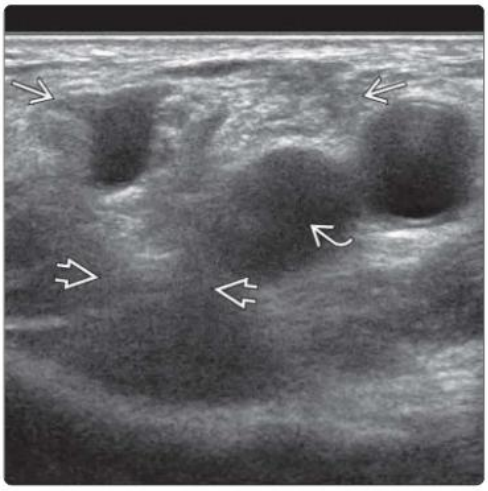

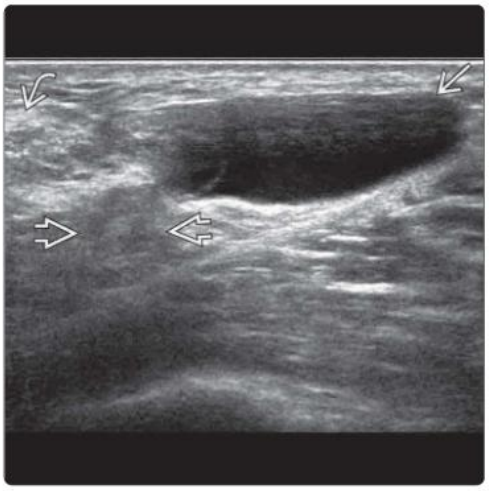

(Left) *Transverse US shows a left femoral hernia containing peritoneal fat and fluid. The neck of the hernia lies medial to the femoral vein and artery.* **(Right)** *Longitudinal US of the same femoral hernia shows that the hernia neck lies inferior to the inguinal ligament. The narrow neck of femoral hernias makes them more prone to obstruction than inguinal hernias. If clinically suspicious of a hernia, always check the femoral canal medial to the femoral vein as well as the inguinal sites.*

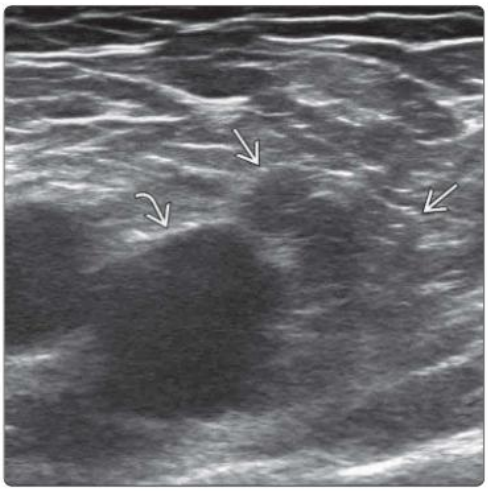

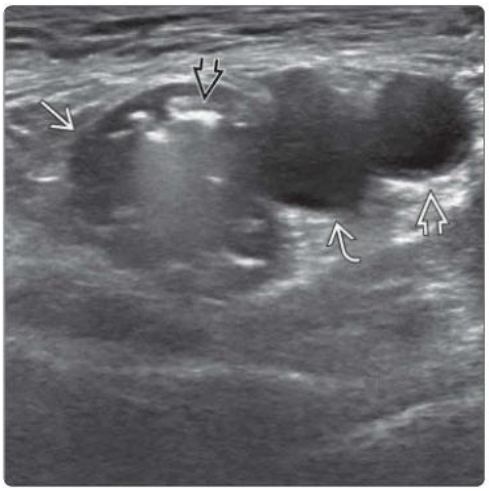

(Left) *Transverse US of a right femoral hernia shows herniated peritoneal fat lying medial to the right femoral vein.* **(Right)** *Transverse US shows a left femoral hernia with bowel herniation. Note the echogenic gas within the bowel lumen. The hernial sac lies medial to the femoral vein, which is medial to the femoral artery. Femoral hernias are more common in older female patients; however, the most common hernia in female patients is still an indirect inguinal hernia.*

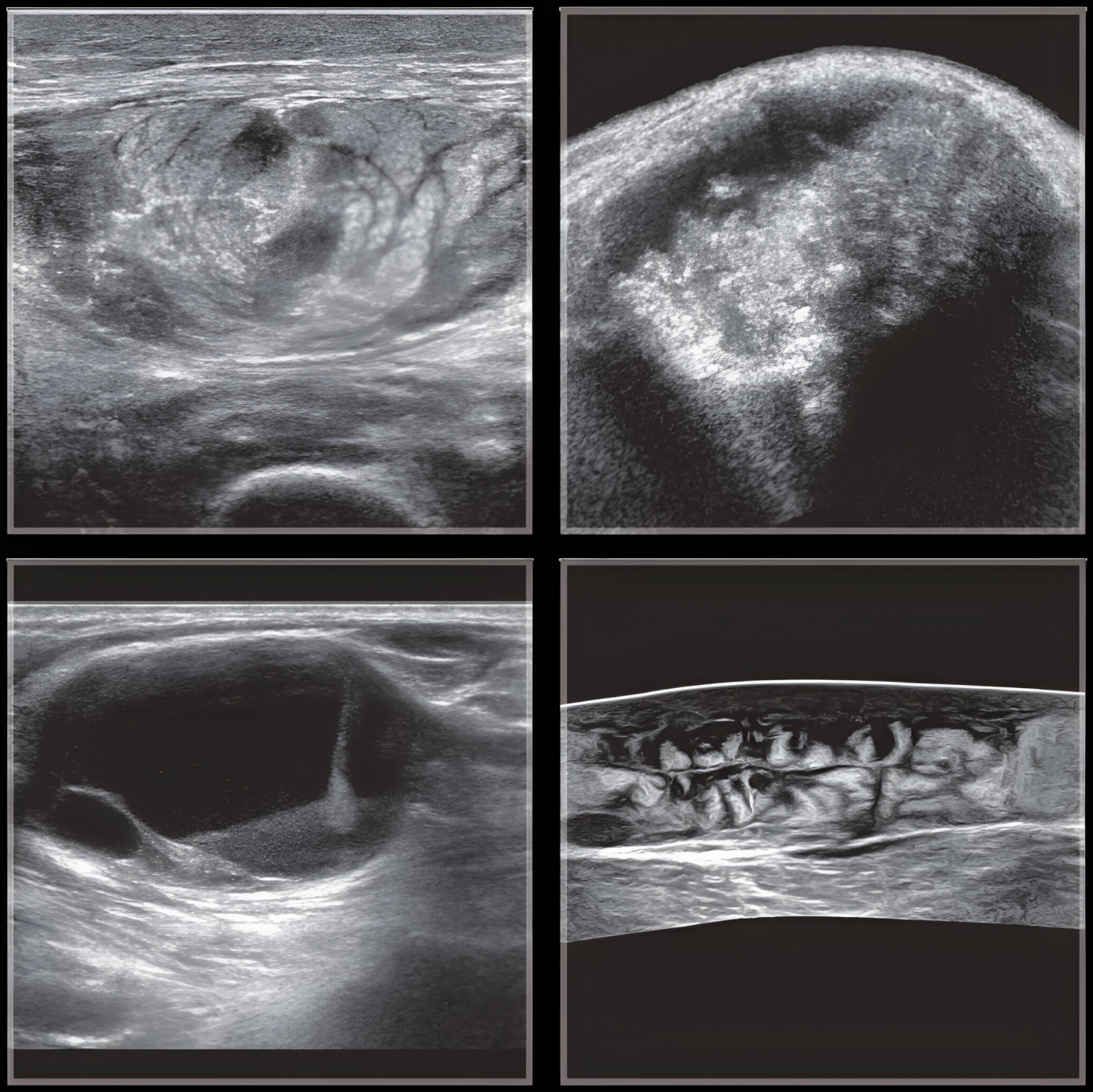

PART IV
SECTION 1

General Lumps and Bumps

Hypoechoic Subcutaneous Mass	828
Hyperechoic Subcutaneous Mass	834
Hypoechoic Muscle Mass	840
Hyperechoic Muscle Mass	846
Cystic Soft Tissue Mass	852
Calcified Soft Tissue Mass	858
Hypervascular Soft Tissue Mass	862

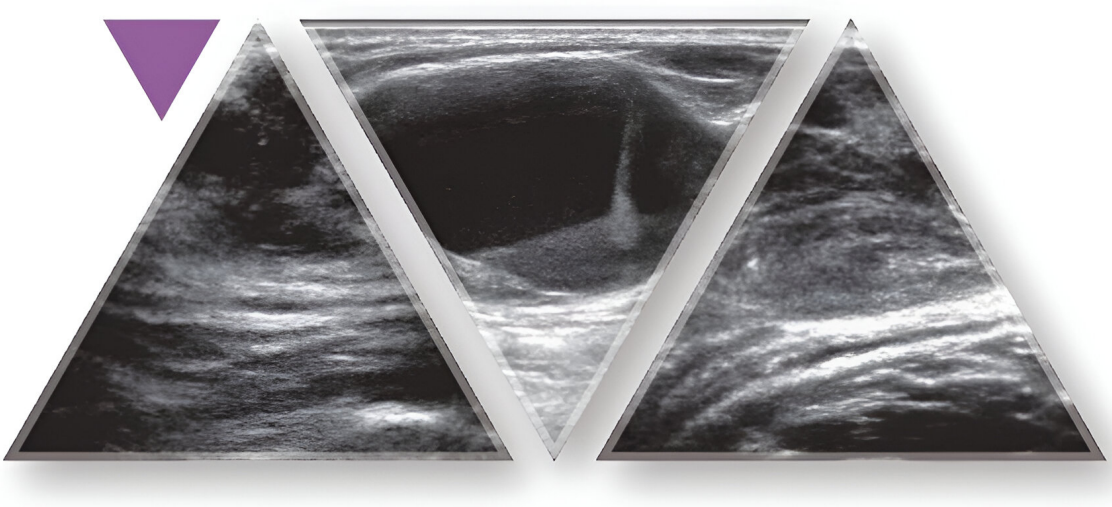

DIFFERENTIAL DIAGNOSIS

Common

- Lipoma
- Vascular Anomaly
- Epidermoid Cyst
- Peripheral Nerve Sheath Tumor

Less Common

- Vascular Leiomyoma
- Pilomatricoma
- Fibroma
- Glomus Tumor
- Lymph Node
- Hematoma
- Abscess
- Fat Necrosis
- Rheumatoid Nodule
- Foreign Body Granuloma
- Sweat Gland Tumor
- Metastasis
- Lymphoma
- Sarcoma
  - Dermatofibrosarcoma Protuberans

ESSENTIAL INFORMATION

Key Differential Diagnosis Issues

- Ensure lesion is confined to subcutaneous tissues
  - Lesion location has important implications for diagnosis & treatment
- Use minimal transducer pressure to avoid distorting lesion
  - Copious skin gel will allow stand-off effect for superficial lesions
    - This is better than using gel pad, which will exert pressure on subcutaneous tissues
- Compressibility assessed by transducer pressure
  - Gives indication of firmness of mass, which is useful when distinguishing fatty from nonfatty tissue or inflammatory from noninflammatory tissue

Helpful Clues for Common Diagnoses

- **Lipoma**
  - Variable echogenicity depending on cellularity & fat-water content
    - Usually are mildly hyperechoic or isoechoic to subcutaneous fat
    - Subcutaneous fat usually hypoechoic, but echogenicity can vary for different locations
  - Diagnosis (as always) depends on constellation of findings rather than single feature
    - Well-marginated, encapsulated, compressible mass with multiple fine, distinctive echogenic lines parallel to skin surface
    - Usually no vascularity on color Doppler imaging
- **Vascular Anomaly**
  - Comprises both vascular tumor (hemangioma) & vascular malformation
    - Differentiation based on cellular turnover, histologic features, & natural history
  - Variable US appearances
    - Mixed echogenicity depending on relative amount of fatty stroma or dilated vascular channels
    - Dilated vascular or lymphatic spaces may appear as hypoechoic vascular channels or cystic spaces
    - Vascular anomalies with prominent vascular components appear hypoechoic
    - Vascularity varies from no detectable flow to very hypervascular depending on vessel type, size, & flow
      - Slow venous flow best seen on real-time grayscale imaging
    - Moderately compressible ± phleboliths
- **Epidermoid Cyst**
  - Appearances depend on degree of cyst maturation & compactness of keratin ± presence of cyst rupture
  - Well-circumscribed, ovoid or lobulated mass with increased acoustic transmission & dermal attachment
  - Most are heterogeneous
    - Layered keratin aggregates ± cholesterol deposition → linear, hyperreflective, disc-like areas
    - Less compact keratin → increased hypoechogenicity
    - Areas lacking keratin → cleft-like or filiform anechoic or hypoechoic areas
  - Most epidermoid cysts are avascular
    - Peripheral & pericystic vascularity is feature of cyst rupture → pericystic inflammation
- **Peripheral Nerve Sheath Tumor**
  - Well-defined homogeneous hypoechoic mass
  - Occasionally heterogeneous
    - Heterogenicity due to areas of myxoid tissue, hemorrhage, fibrosis, or calcification
  - Fusiform or oblong-shaped along course of nerve
    - Entering or exiting nerve seen in 50% cases
    - Entering/exiting nerves may not be seen if arising from small nerve
  - Posterior acoustic enhancement is common
  - Usually mild to moderate vascularity

Helpful Clues for Less Common Diagnoses

- **Vascular Leiomyoma**
  - Benign, solitary smooth muscle neoplasm most commonly occurs in subcutaneous soft tissues of lower limb
  - Usually round or ovoid in shape with long axis parallel to extremity axis
  - Smooth-bordered, homogeneous, hypoechoic mass without perceivable capsule
  - Occurs in close proximity to artery or vein
  - Often hypervascular ± vascular convergence (60%)
- **Pilomatricoma**
  - Benign skin tumor arising from cells of hair matrix; more commonly seen in children
  - Well-circumscribed, ovoid, heterogeneous, solid subdermal mass with matrix calcification, vascularity, & peripheral hypoechoic capsular rim
  - Intrinsic vascularity may be peripheral, central, or mixed
- **Fibroma**
  - Localized tumorous collection of collagen with sparse number of fibroblasts
  - Well-defined to irregular hypoechoic mass
  - Minimal to mild intrinsic vascularity
- **Glomus Tumor**

- Arises from glomus body, which is arteriovenous shunt in dermis that contributes to temperature regulation
- Most common location: Distal extremities, especially subungual areas
- Small, well-defined, hypoechoic, hypervascular mass

- **Lymph Node**
  - Enlarged subcutaneous nodes can be reactive, infective, metastatic, or lymphomatous
  - Preserved central echogenic fatty hilum & hilar vascularity in reactive, infective, & many lymphoma nodes
    - Mixed hilar or mixed hilar & peripheral flow pattern
  - Typical metastatic nodes have thickened cortices, obliterated echogenic fatty hilum with capsular & pericapsular hyperemia
- **Hematoma**
  - Usually echogenic in acute stages; becomes hypoechoic after several days to weeks due to liquification
  - Often occurs near bony prominence
- **Abscess**
  - Usually hypoechoic but may be echogenic due to aggregates of inflammatory debris
  - Surrounding edema & hyperemia
  - Moving echoes on real-time imaging
- **Fat Necrosis**
  - Swelling & increased echogenicity of subcutaneous fat in early stages, which becomes more hypoechoic with increasing chronicity
  - ± liquefaction with discrete, irregular hypoechoic areas ± calcification ± fat atrophy in later stages
- **Rheumatoid Nodule**
  - Extraarticular manifestation occurring in 2% of rheumatoid arthritis patients
  - Most common in subcutaneous tissue subjected to pressure with deep bony surface
    - Extensor surface forearms, olecranon, & finger knuckles
  - Well-defined, homogeneous, hypoechoic mass with no posterior shadowing
  - Minimal or mild intrinsic vascularity
- **Foreign Body Granuloma**
  - Variable thickness rim of hyperemic & hypoechoic granulation tissue forms around foreign body
    - Makes echogenic foreign body more conspicuous
- **Sweat Gland Tumor**
  - Tumor arises from eccrine or apocrine sweat glands
  - Hypoechoic, heterogeneous nodule of low vascularity ± cystic areas
- **Metastasis**
  - 2.0% of superficial soft tissue masses referred for US are metastases
  - Most common (> 50%) primaries: Breast, bronchus, & melanoma
  - Well-demarcated, irregular or roundish hypoechoic mass
    - Melanoma metastases tend to be distinctly hypoechoic & may be elongated due to spread along lymphatic channels (tail & string signs)
  - Mild to moderate intrinsic vascularity usually present
  - ± features of primary tumor (e.g., myxoid, calcification)
- **Lymphoma**
  - Involvement of superficial tissues uncommon
  - Subcutaneous panniculitis-like T-cell lymphoma is uncommon type of peripheral T-cell lymphoma
- **Sarcoma**
  - 2.5% of superficial soft tissue masses referred for US are sarcoma
  - Large (> 5 cm), heterogeneous, hypoechoic mass
  - Usually hypervascular with disorganized vascular pattern on color Doppler imaging
  - Appearance unlike known subcutaneous benign tumor
  - **Dermatofibrosarcoma Protuberans**
    - Low-grade spindle cell mesenchymal sarcoma of dermis & subcutis
    - Trunk > proximal part of limbs, especially lower
    - Well-marginated, lobulated, hypoechoic mass
      - Jelly fish tentacle pattern ± claw sign
    - Small, echogenic speckles within mass
    - Posterior enhancement
    - Peripheral > central vascularity, no vascularity (30%), severe vascularity (10%)

Lipoma

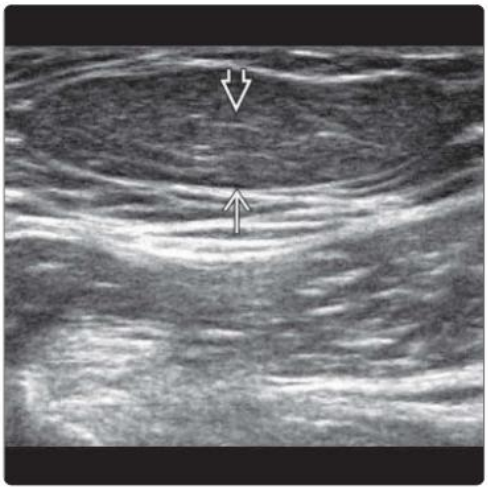

Lipoma

(Left) *Longitudinal US shows an encapsulated ➡, subcutaneous lipoma isoechoic to adjacent subcutaneous fat with fine internal echogenic striations ➡ parallel to the long axis of tumor.* **(Right)** *Extended longitudinal view US of a subcutaneous lipoma shows prominent horizontal striations ➡ aligned parallel to the surrounding skin. The echogenicity of the lipoma is similar to the hypoechoic subcutaneous fat ➡ & hypoechoic to the dermis ➡.*

Vascular Anomaly

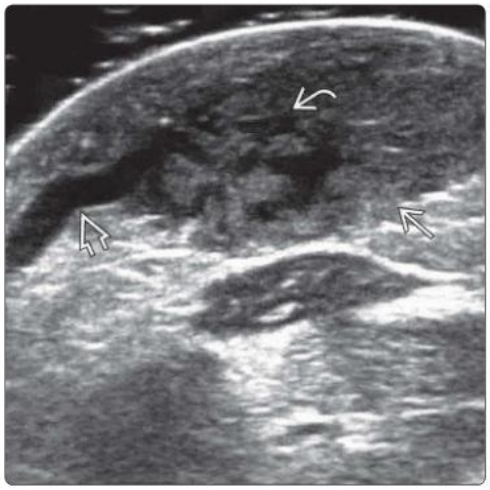

Vascular Anomaly

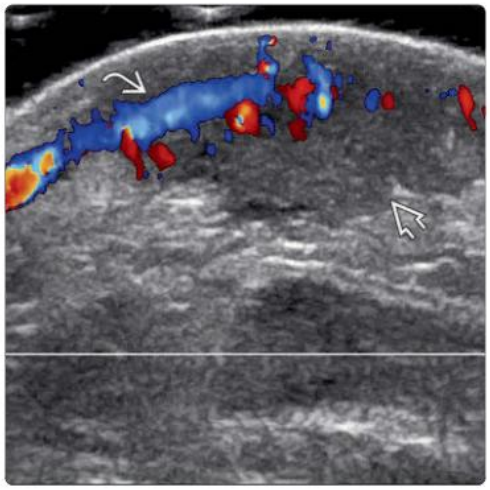

(Left) *Longitudinal US shows a well-defined, lobulated, hypoechoic mass lesion within the subcutaneous tissue. There are tubular hypoechoic areas connected to the prominent central vessel within the mass.* **(Right)** *Longitudinal color Doppler US of the same lesion shows predominant intralesional venous vascular flow indicative of a venous vascular malformation. The supporting stroma most likely contains many small vessels too small to be resolved by US.*

Epidermoid Cyst

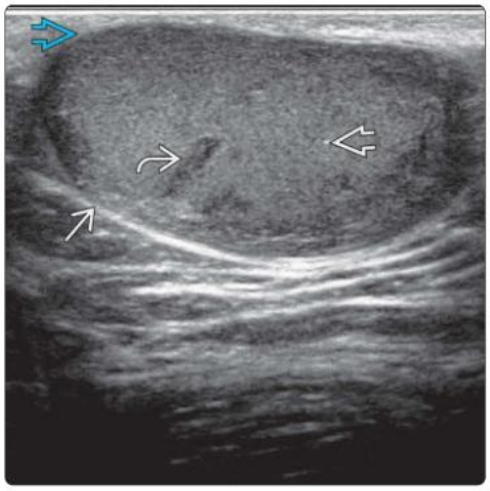

Epidermoid Cyst

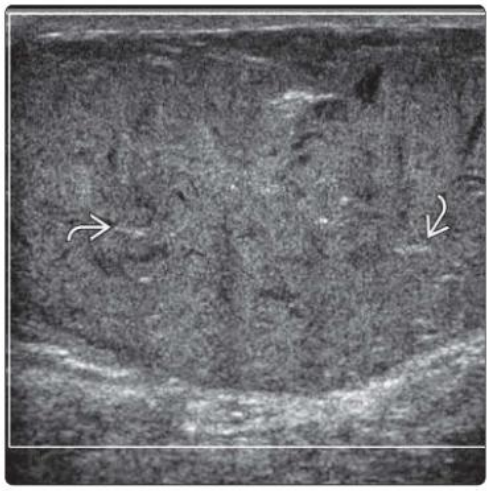

(Left) *Longitudinal US of an epidermoid cyst shows a fairly homogeneous, hypoechoic, well-defined mass with a few small, anechoic, cystic-like areas lacking keratin as well as small hyperechoic foci representing cholesterol deposits. Dermal attachment & posterior acoustic enhancement are present.* **(Right)** *Longitudinal US of an epidermoid cyst shows a more heterogeneous appearance. There are some small, echogenic disc-like areas due to layered keratin. No intrinsic vascularity is present.*

Peripheral Nerve Sheath Tumor

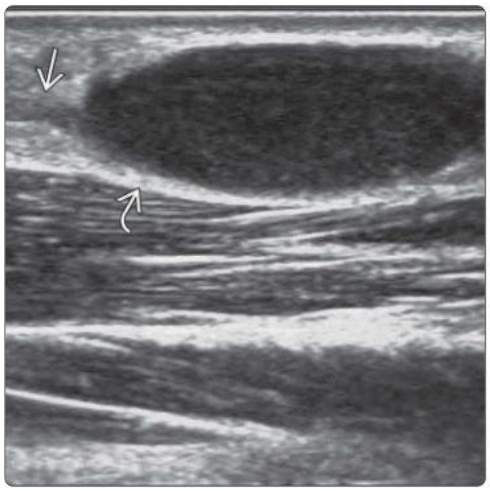

Peripheral Nerve Sheath Tumor

(Left) *Longitudinal US shows a well-defined, subcutaneous, hypoechoic mass with mild posterior acoustic enhancement & a thickened nerve end in keeping with a nerve sheath tumor arising from a subcutaneous nerve.* **(Right)** *Transverse color Doppler US of a nerve sheath tumor arising from a dorsal digital nerve overlying the metacarpal bone shows moderate disorganized vascularity & an eccentric cystic component.*

Vascular Leiomyoma

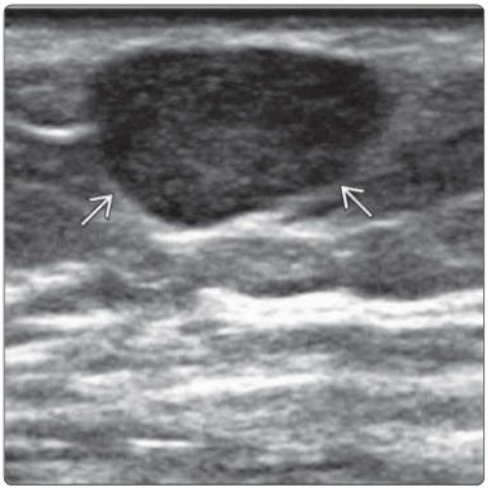

Vascular Leiomyoma

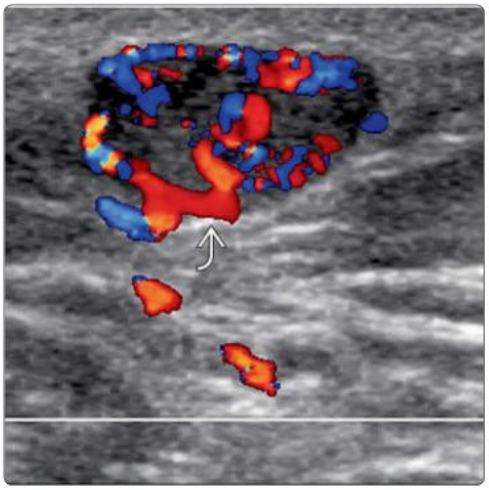

(Left) *Longitudinal US shows a well-defined, smooth, homogeneous, hypoechoic mass in the subcutaneous tissues of the thigh. The long axis of the tumor is parallel to the axis of the lower limb.* **(Right)** *Longitudinal color Doppler US shows a moderate degree of organized hyperemia with peripheral vascular convergence to a point. This peripheral vascular convergence pattern is seen in some, but not all, vascular leiomyomas.*

Pilomatricoma

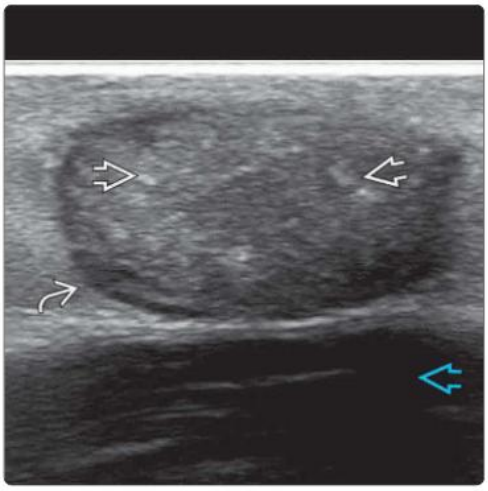

Pilomatricoma

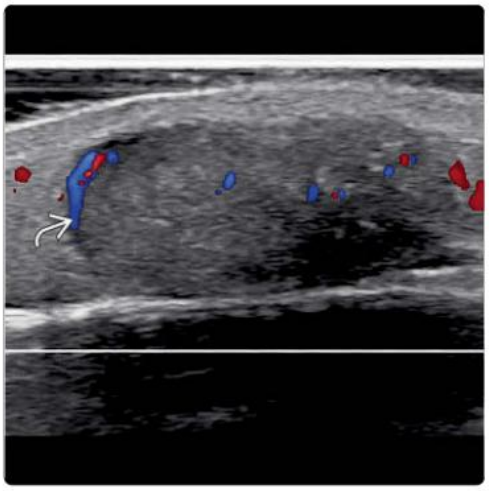

(Left) *Longitudinal US shows a heterogeneous, hypoechoic pilomatricoma with multiple small calcific-like foci. There is a thin, hypoechoic capsule & posterior acoustic shadowing.* **(Right)** *Longitudinal color Doppler US of the same pilomatricoma shows mild to moderate mixed central & peripheral vascularity. Pilomatricoma is a benign tumor arising from the hair matrix & is more commonly seen in children.*

Glomus Tumor

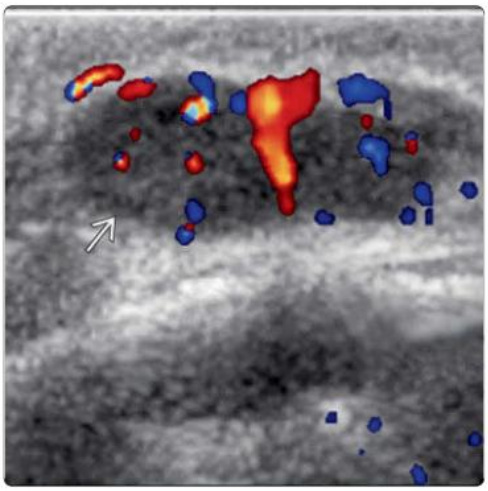

Lymph Node

(Left) *Longitudinal color Doppler US of a patient with a painful glomus tumor in the upper limb shows a well-defined, hypoechoic, subcutaneous mass with a moderate degree of intratumoral hyperemia.* **(Right)** *Longitudinal US of a patient with known foot melanoma shows an enlarged subcutaneous lymph node on the medial groin region. There is marked eccentric cortical hypertrophy. The central fatty hilum & vessels are effaced. US-guided biopsy confirmed melanoma metastasis.*

(Left) *Longitudinal US shows a subcutaneous hematoma with a large, liquefied component & a small, peripheral echogenic component. No intrinsic vascularity is evident.* **(Right)** *Transverse US shows a large, irregular subcutaneous abscess containing a moderate amount of echogenic internal debris. There is severe edema of the adjacent subcutaneous fat.*

Hematoma

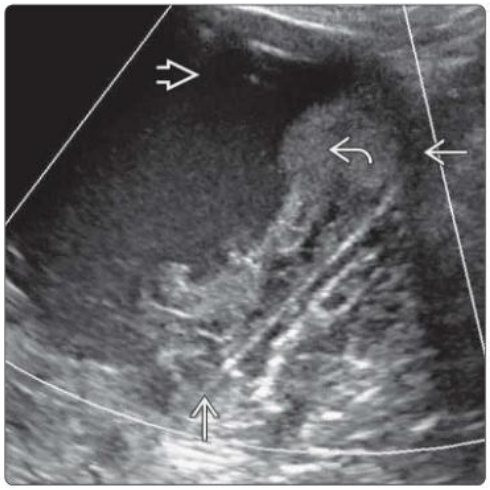

Abscess

(Left) *Transverse US of posttraumatic fat necrosis shows a heterogeneous, subcutaneous mass. The mass is ill-defined with a hyperechoic rim of edematous fat & a central hypoechoic component due to liquefaction or fibrosis. Areas of subcutaneous fat necrosis become better defined & more hypoechoic with increasing chronicity.* **(Right)** *Longitudinal US shows an elliptical, hypoechoic rheumatoid nodule superficial to the Achilles tendon in a patient with rheumatoid arthritis.*

Fat Necrosis

Rheumatoid Nodule

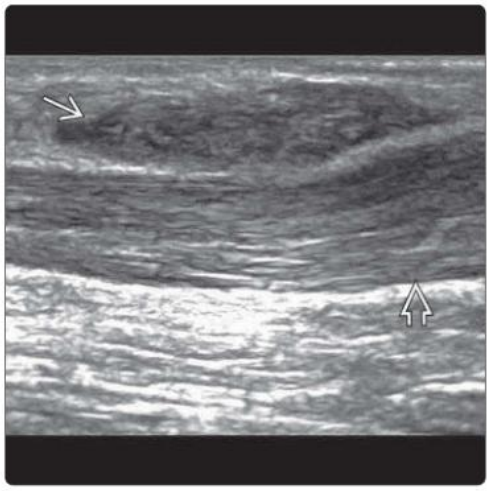

(Left) *Longitudinal US shows a subcutaneous foreign body granuloma of the forearm. The hyperechoic retained wooden fragment is surrounded by a thick, hypoechoic rim of granulation tissue. The mass was moderately vascular on color Doppler imaging (not shown).* **(Right)** *Longitudinal power Doppler US shows a well-defined, ovoid, hypoechoic cystic mass with an eccentric soft tissue nodule & mild intrinsic vascularity. Fluid-fluid level is present. Excision revealed hidradenomatous neoplasm.*

Foreign Body Granuloma

Sweat Gland Tumor

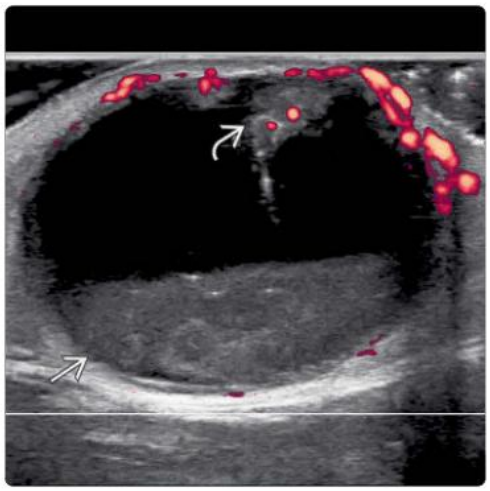

Metastasis

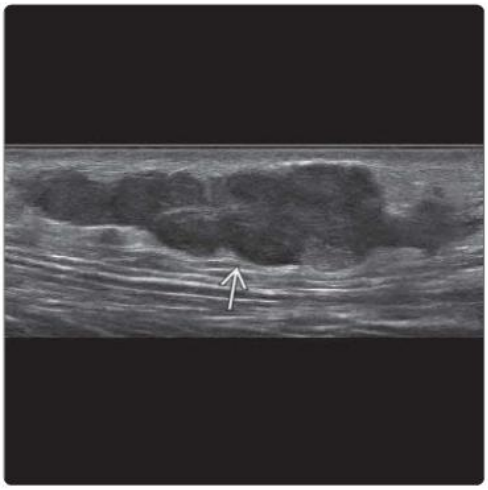

Metastasis

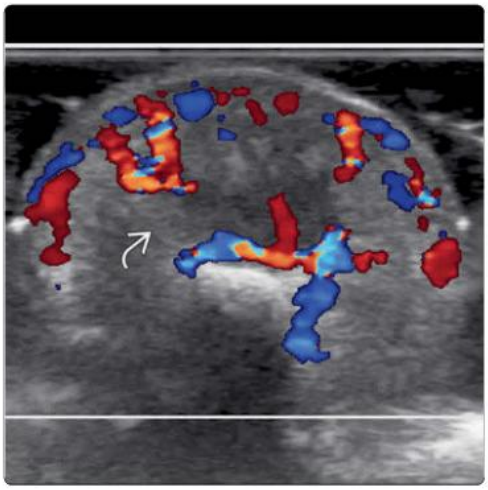

(Left) *Longitudinal US in a patient with foot melanoma shows an in-transit melanoma deposit ⇨ in the subcutaneous tissue of the thigh. The elongated, hypoechoic mass is due to melanotic tumor filling & distending a lymphatic channel between the primary tumor & the regional lymph nodes.* **(Right)** *Transverse color Doppler US in a patient with known lung cancer shows an irregular, hypoechoic mass ⇨ with hypervascularity in the apical pulp of the index finger. US-guided biopsy revealed metastatic adenocarcinoma.*

Sarcoma

Sarcoma

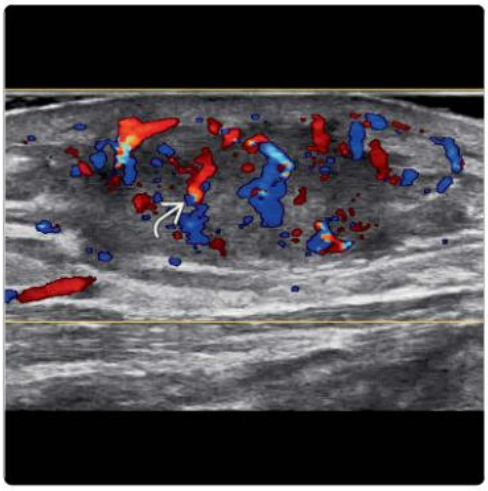

(Left) *Longitudinal US shows a moderate-sized, irregular, hypoechoic subcutaneous mass ⇨ in the calf. The adjacent subcutaneous tissues are moderately edematous ⇨.* **(Right)** *Transverse color Doppler US of the same lesion shows moderate to high intrinsic disorganized vascularity ⇨. US-guided biopsy for histology revealed a myxoid sarcoma. The absence of recognizable features of known benign superficial tumors should make one suspicious of malignancy.*

Dermatofibrosarcoma Protuberans

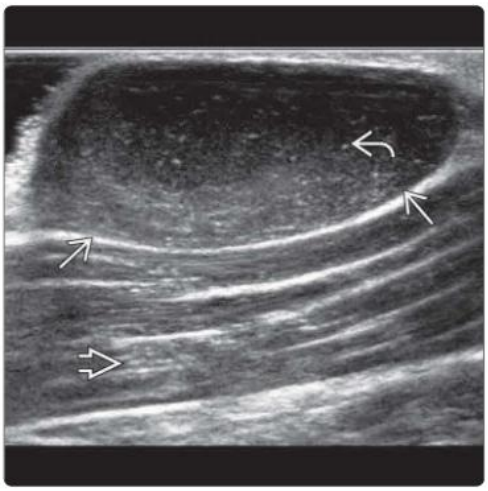

Dermatofibrosarcoma Protuberans

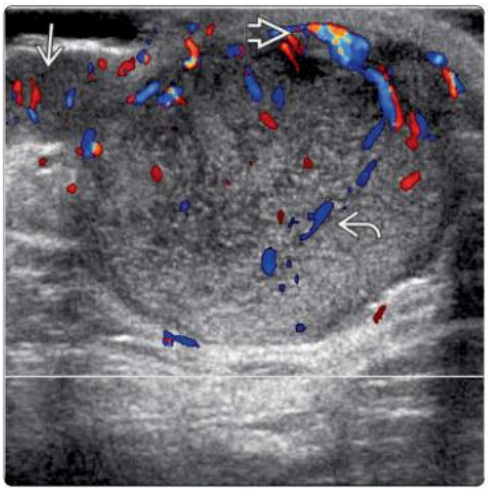

(Left) *Longitudinal US shows a well-defined hypoechoic mass ⇨ causing focal skin protuberance. It contains multiple fine echogenic foci ⇨ & shows mild increase in posterior acoustic transmission ⇨. These appearances are suggestive of dermatofibrosarcoma protuberans.* **(Right)** *Transverse color Doppler US of dermatofibrosarcoma protuberans shows a moderate degree of organized central ⇨ & peripheral ⇨ vascularity. There is a claw sign at the dermal-subcutaneous interface ⇨.*

DIFFERENTIAL DIAGNOSIS

Common

- Lipoma
- Vascular Anomaly
- Epidermoid Cysts

Less Common

- Cellulitis
- Fat Necrosis
- Hematoma
- Panniculitis
- Pilomatricoma
- Abscess
- Gouty Tophus
- Granuloma & Fibroma
- Normal Lymph Node
- Fibrous Hamartoma of Infancy

ESSENTIAL INFORMATION

Key Differential Diagnosis Issues

- Use light transducer pressure
  - Any compression of subcutaneous fat will usually tend to make soft subcutaneous masses less conspicuous
- Subcutaneous fat may vary from hyperechoic to hypoechoic depending on location
- In some regions, particularly gluteal region, subcutaneous fat looks similar to muscle
  - Take care in defining correct layer as this has important diagnostic & surgical implications

Helpful Clues for Common Diagnoses

- **Lipoma**
  - Variable echogenicity depending on cellularity & fat-water content, but, in general, isoechoic to fat & hyperechoic to muscle
  - Well-marginated, encapsulated, compressible, fusiform-shaped mass
    - Multiple fine, distinctive echogenic lines parallel to skin surface
    - Usually no detectable vascularity
    - Consider angiolipoma if intrinsic vascularity detected
    - If multiple lipomas present, these tend to be more rounded, more echogenic, with less striation, encapsulation, & compressibility
  - Lipohypertrophy = localized increase in fat accumulation, subcutaneous > > intermuscular
    - Increase in size of fat lobules & depth of subcutaneous fat
    - Usually affects middle-aged women
    - Absence of distinct border or capsule allows distinction of lipohypertrophy from lipoma
- **Vascular Anomaly**
  - Comprises both vascular tumor (hemangioma) & vascular malformation
    - Differentiation based on cellular turnover, histologic features, & natural history
  - Hemangioma
    - Benign vascular tumors of infancy & childhood with cellular proliferation & hyperplasia
    - Grows after birth, proliferates, & then involutes
  - Vascular malformation
    - Due to vascular dysplasia rather than actual tumor with normal endothelial turnover
    - Present at birth & grows commensurately with child without proliferation or involution
    - Classified according to predominant vessel type as either venous, capillary, arterial, lymphatic, or combined type
  - Variable US appearances
    - Mixed echogenicity depending on relative fatty stromal or vascular components
    - Dilated vascular spaces may appear as hypoechoic vascular channels or large, hypoechoic, cystic spaces (venous lakes)
    - Variable stromal connective tissue component with predominant fatty-type background → appears hyperechoic
    - This echogenic stroma component may contain numerous capillaries too small to be resolved with US
    - Vascularity of vascular anomaly varies from no detectable flow → very hypervascular
    - Moderately compressible ± phleboliths
- **Epidermoid Cysts**
  - Slow-growing subdermal cyst that contains keratin & is lined by stratified squamous epithelium but does not contain dermal elements
  - US appearances depend on cyst maturation & compactness of keratin ± presence of cyst rupture
  - Most are well circumscribed, ovoid, or lobulated with increased acoustic transmission
  - Most are heterogeneous & mildly hyperechoic
  - Linear, hyperreflective, disc-like areas represent layered keratin aggregates ± cholesterol deposition
  - Cleft-like or filiform anechoic or hypoechoic areas are due to cyst-like spaces lacking keratin
  - Dermal attachment
    - ± broad dermal contact ± dermal protrusion ± focal hypoechoic region extending toward epidermis, i.e., punctum or submarine sign
    - Punctum is only seen in 10% of those referred for US examination; most cysts with clinically apparent puncta are not referred for US examination
  - Most epidermoid cysts are avascular
    - Peripheral & pericystic vascularity is feature of cyst rupture with pericystic inflammation

Helpful Clues for Less Common Diagnoses

- **Cellulitis**
  - Infection of subcutaneous fat
    - Characterized by edema and hyperemia
  - Group A *Streptococcus* & *Staphylococcus aureus* organisms are usually responsible
  - Subcutaneous fat is more echogenic when edematous
  - Subcutaneous edema = nonspecific finding seen with many conditions, e.g., heart failure, venous insufficiency, immobility, & dependency
  - Cellulitis should have combination of edema & hyperemia
    - Thickened interlobular septa
    - ± periseptal fluid or fluid above investing fascia

- **Fat Necrosis**
  - Swelling of subcutaneous fat in early stages
    - Hyperechoic edematous fat with loss of normal echogenic striation
    - Majority are due to previous trauma
  - Subcutaneous fat becomes more hypoechoic with increasing chronicity
    - ± liquefaction with discrete, irregular hypoechoic areas ± calcification ± fat atrophy in later stages
    - Investing fascia & muscle is usually unaffected
- **Hematoma**
  - Echogenic in acute stages
  - ± circular echogenic layering due to sequential deposition of hemorrhage
  - ± linear layering due to separation of cellular & serous components
  - ± moving echoes on real-time imaging
  - ± liquefaction after several days to weeks
  - ± calcification as late feature
- **Panniculitis**
  - Localized inflammation of subcutaneous fat; has many causes
    - Idiopathic, infection, systemic inflammatory disorder, pancreatic disease, drug hypersensitivity, Weber-Christian disease, or myeloproliferative disorder (panniculitis-like T-cell lymphoma)
  - Active stage: Localized area of increased echogenicity & thickness of subcutaneous fat with mild to moderate hyperemia
  - Inactive stage: Atrophy & hypoechogenicity of subcutaneous fat with little or no hyperemia
- **Pilomatricoma**
  - Benign skin tumor arising from cells of hair matrix
  - Mass extending from dermal to subdermal tissues
  - Well-circumscribed, ovoid, heterogeneous, solid subdermal mass with matrix calcification & peripheral hypoechoic rim (due to connective tissue capsule)
  - Intrinsic vascularity is usually present (peripheral, central, or combined peripheral & central)
  - More common in children; head & neck region
- **Abscess**
  - May be echogenic due to aggregates of inflammatory debris
  - Surrounding edema & hyperemia
  - ± moving echoes on real-time imaging
- **Gouty Tophus**
  - Soft or hard tophi depending on concentration of crystals deposited
    - Soft tophi: Echogenic with mild to moderate posterior acoustic shadowing
    - Hard tophi: Echogenic with strong posterior acoustic shadowing
- **Granuloma and Fibroma**
  - Common in gluteal region
    - Frequently follow subcutaneous injection
  - May also occur elsewhere without any recognizable cause
  - Usually hypoechoic, though occasionally hyperechoic
    - Often calcified
- **Normal Lymph Node**
  - May appear echogenic if large, central fatty hilum & thin, hypoechoic cortex present
    - Particularly in axillary nodes & subcutaneous lymph node on medial aspect of proximal thigh
- **Fibrous Hamartoma of Infancy**
  - Uncommon benign superficial fibrous tumor found in early childhood (< 2 years)
  - More common in boys; mainly affects trunk, axilla, & upper extremities
  - Associated with skin pigmentation, hypertrichosis, and eccrine gland hyperplasia
  - Consists of mixture of fibrocollagenous tissue, primitive mesenchymal cells, and mature fat
    - US appearances depend on proportion of these 3 components
  - Ill-defined, heterogeneous, predominantly hyperechoic, subcutaneous mass
  - Usually no significant intrinsic vascularity
  - May involve investing fascia, though subfascial extension is rare

Lipoma

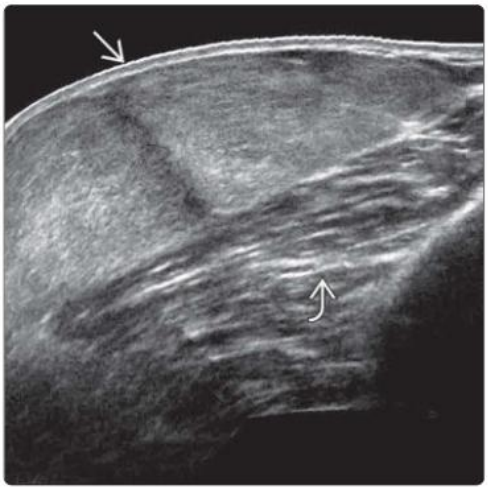

Lipoma

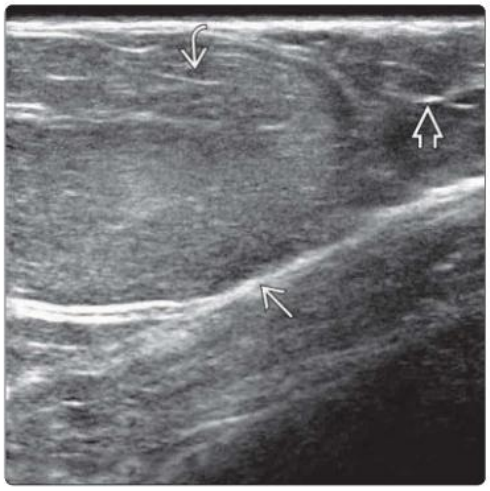

(Left) *Longitudinal US with extended field of view shows a large, hyperechoic, subcutaneous lipoma causing bulging of the skin contour. The underlying deltoid muscle is normal.* **(Right)** *Longitudinal US shows an encapsulated, subcutaneous lipoma abutting the investing fascia. The lipoma is hyperechoic to adjacent subcutaneous fat with fine linear horizontal striations.*

Lipoma

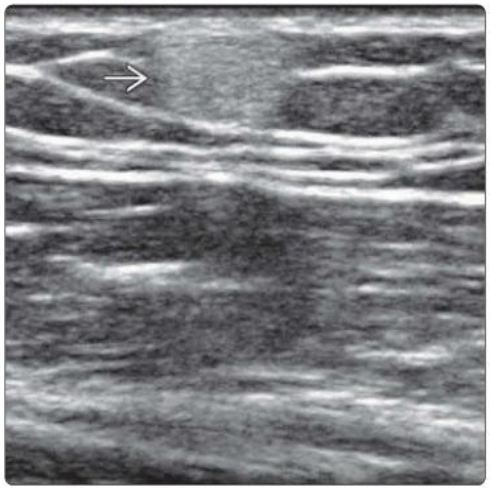

Vascular Anomaly

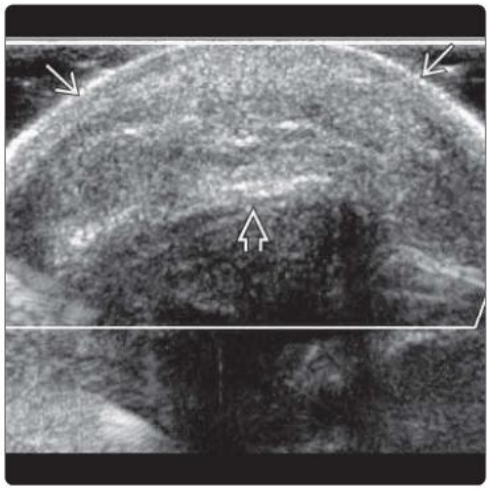

(Left) *Longitudinal US shows a small, rounded, well-defined, hyperechoic subcutaneous lipoma without perceivable linear striation. Such lipomas are often multiple and tend to be located more in the trunk region than in the limbs.* **(Right)** *Transverse color Doppler US in a child with prepatellar port-wine discoloration shows an echogenic, subcutaneous mass without detectable intrinsic vascularity, consistent with a slow-flow, capillary-type vascular malformation.*

Vascular Anomaly

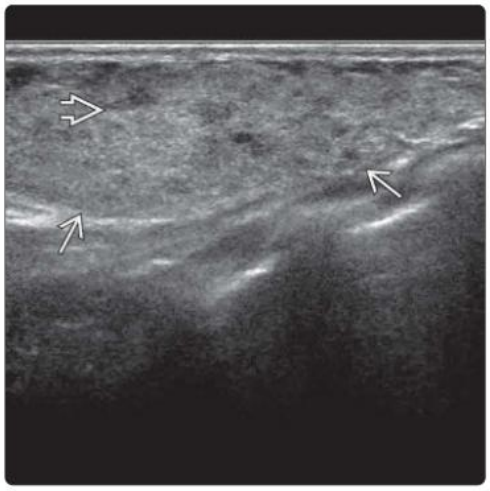

Vascular Anomaly

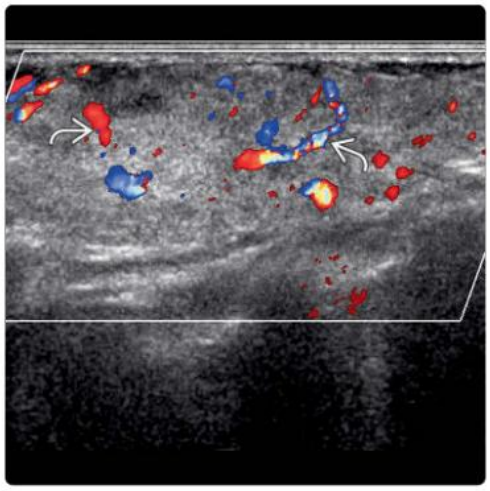

(Left) *Transverse color Doppler US in a 6-month-old infant shows a subcutaneous hemangioma in the chest wall. The hemangioma contains an echogenic, fatty stroma and small, hypoechoic vascular channels.* **(Right)** *Transverse color Doppler US of the same lesion shows multiple arterial and venous vascular channels embedded within the fatty stroma. This fatty stroma may contain capillaries too small to be resolved on US and only seen on histologic analysis.*

Epidermoid Cysts

Epidermoid Cysts

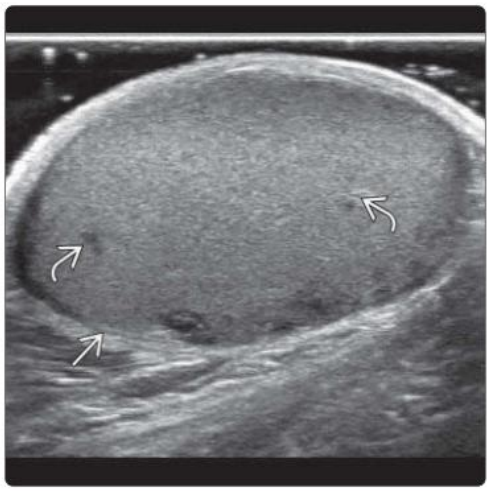

(Left) *Longitudinal US shows typical appearances of an epidermoid cyst with heterogeneous echotexture, dermal attachment, internal floating hyperreflective strands, small hypoechoic areas, and a hypoechoic track extending to a cutaneous punctum.* **(Right)** *Longitudinal US shows a hyperechoic epidermoid cyst with a pseudotestis appearance. The mass is homogeneous with scattered cyst-like spaces lacking keratin. Dermal attachment with broad dermal contact is present.*

Cellulitis

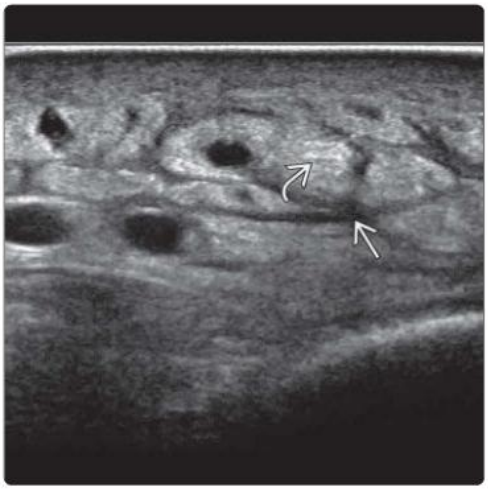

Cellulitis

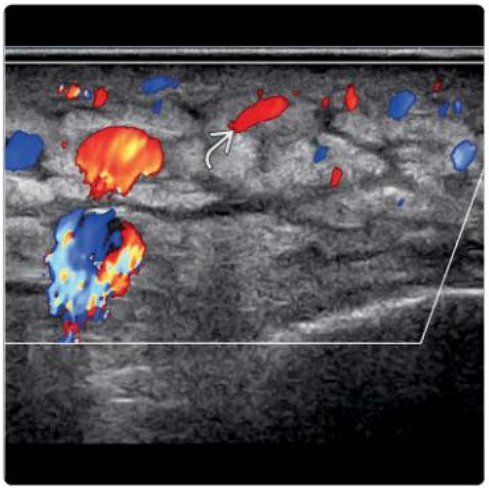

(Left) *Transverse US of the dorsal hand region shows severe subcutaneous edema with diffuse increased echogenicity of the subcutaneous fat lobules ⇨, interspersed between thickened, hypoechoic septa ⇨.* **(Right)** *Transverse color Doppler US in the same patient shows moderate hyperemia ⇨ of the subcutaneous tissues overall, consistent with moderate-severity cellulitis. Hyperemia helps differentiate cellulitis from noninfective causes of subcutaneous edema.*

Fat Necrosis

Fat Necrosis

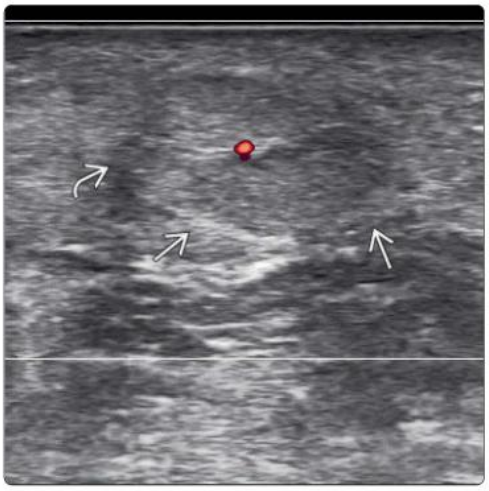

(Left) *Longitudinal US shows an area of hyperechogenicity ⇨, consistent with posttraumatic subcutaneous edema. There is no mass effect. As the lesion becomes more chronic, the echogenicity will decrease and the subcutaneous fat may atrophy to a variable degree, all consistent with subcutaneous fat necrosis.* **(Right)** *Transverse power Doppler US of another fat necrosis shows a localized area of swollen, hyperechoic subcutaneous fat ⇨ associated with a vague, hypoechoic pseudocapsule ⇨ and mild central vascularity.*

Hematoma

Hematoma

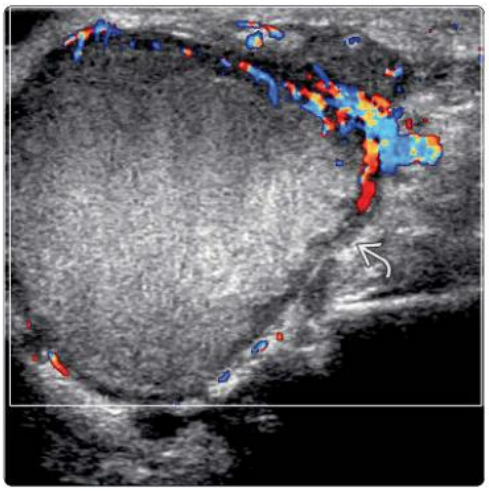

(Left) *Transverse US shows an organizing hematoma in the subcutaneous tissue superficial to the patella. The lesion is marginated and echogenic with intrinsic whorl-like patterns ⇨ and echogenic strands ⇨. Subcutaneous hematoma tends to occur over bony prominences.* **(Right)** *Transverse color Doppler US shows a subcutaneous organizing hematoma in the forearm. The mass is homogeneous with a peripheral, hypoechoic, moderately vascularized fibrous-type capsule ⇨.*

Panniculitis

Panniculitis

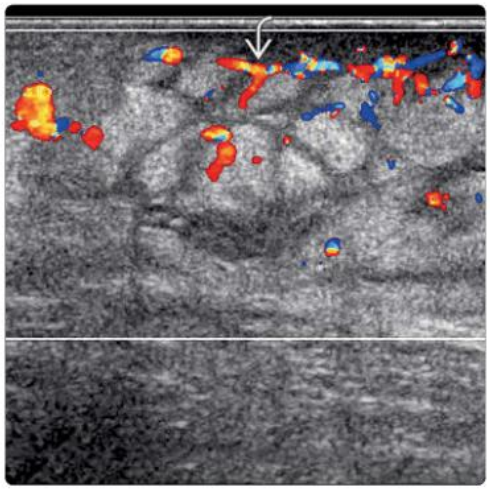

(Left) *Longitudinal US of an immunocompromised patient with fever and leg swelling shows focal subcutaneous edema with multiple prominent echogenic fat lobules separated by hypoechoic septi.* **(Right)** *Transverse color Doppler US shows moderate hyperemia of the inflamed subcutaneous fat due to infective panniculitis. The focal nature of panniculitis distinguishes it from more diffuse cellulitis. In another clinical context, panniculitis-like T-cell lymphoma should be considered.*

Pilomatricoma

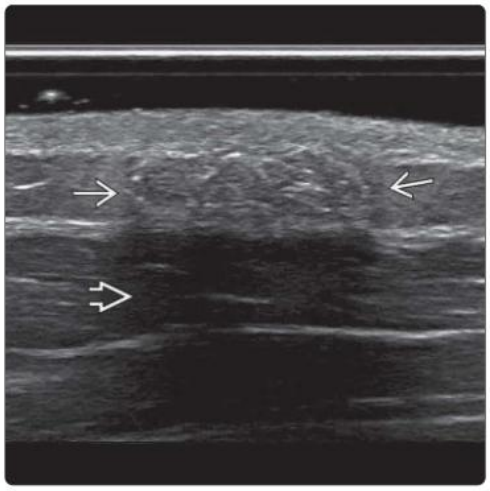

Pilomatricoma

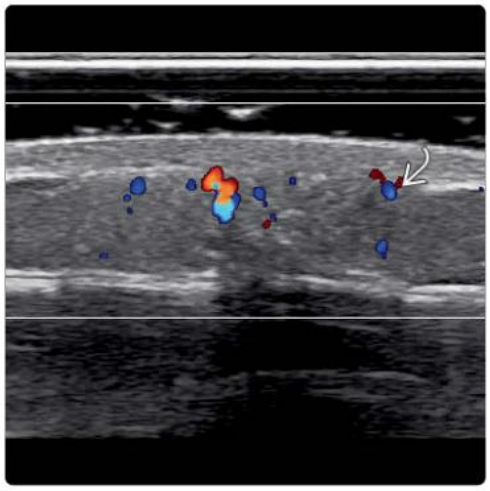

(Left) *Longitudinal US shows a fairly well-defined pilomatricoma in the subcutaneous tissue. The tumor is more echogenic than the adjacent subcutaneous fat. There are multiple scattered, echogenic foci with mild posterior shadowing due to matrix calcification.* **(Right)** *Longitudinal color Doppler US of the same lesion shows mild, central, and peripheral hyperemia of the tumor. Mild to moderate intrinsic vascularity is usually present in pilomatricoma.*

Abscess

Abscess

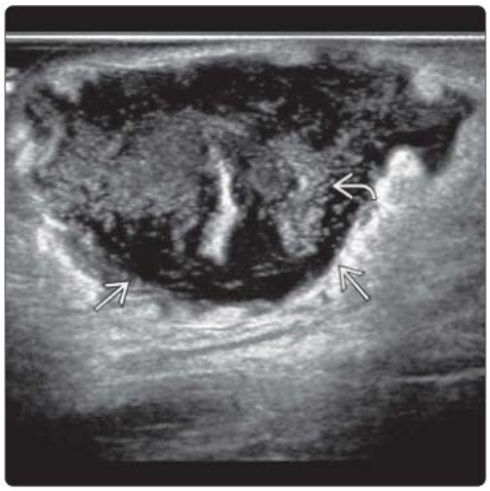

(Left) *Longitudinal US of the finger shows a large, heterogeneous tuberculous cold abscess with internal calcification and moving echoes on real-time imaging. This abscess extends from the metacarpophalangeal joint into the subcutaneous tissues.* **(Right)** *Transverse US of the arm shows an irregular pyogenic abscess with internal echogenic debris seen to move on real-time imaging. Microbiology grew Enterococcus and Acinetobacter species.*

Gouty Tophus

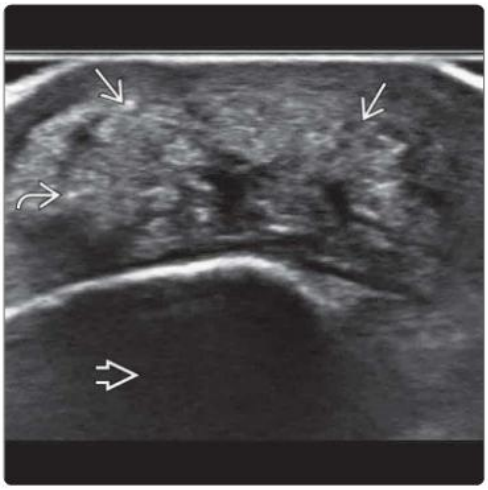

Gouty Tophus

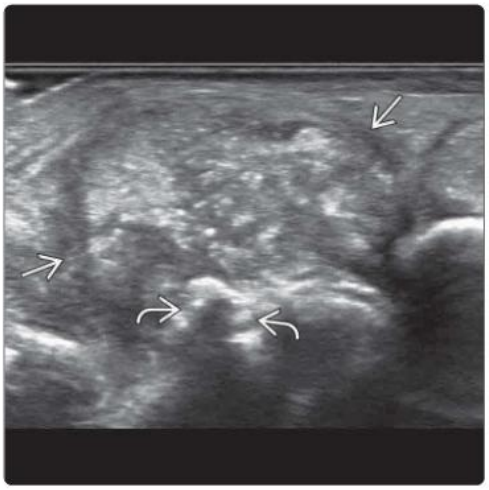

(Left) *Longitudinal US shows a subcutaneous gouty tophus ➡ superficial to the lateral malleolus ➡. The gouty tophus contains multiple echogenic gouty crystal aggregates ➡.* **(Right)** *Longitudinal US of another patient shows a soft tophus ➡ without posterior shadowing over the dorsal aspect of the radiocarpal articulation extending into the subcutaneous tissue. There are associated small erosions ➡ in the carpal bones.*

Granuloma & Fibroma

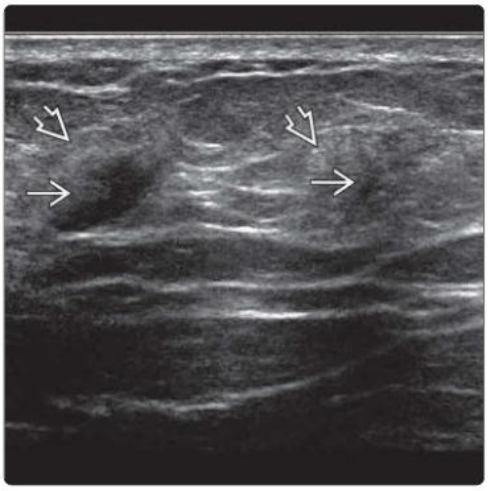

Normal Lymph Node

(Left) *Transverse US of the buttock shows 2 subcutaneous injection granulomas, each with a central hypoechoic area ➡ and a surrounding hyperechoic area ➡. The different appearances are due to varying amounts of mature (hypoechoic) and immature (hyperechoic) granulation tissue.* **(Right)** *Longitudinal US shows a normal inguinal lymph node with a large, central, fatty hilum ➡ and a thin, peripheral, hypoechoic cortex ➡. Such subcutaneous nodes are common in the medial proximal thigh.*

Fibrous Hamartoma of Infancy

Fibrous Hamartoma of Infancy

(Left) *Longitudinal US with extended field of view of the anterior thigh mass in an infant shows an ill-defined, hyperechoic, heterogeneous, subcutaneous mass ➡ abutting but not traversing the investing fascia ➡. The varying echogenicity represents mature (hypoechoic) and immature (hyperechoic) fibrous tissue components.* **(Right)** *Transverse localized color Doppler US of the same lesion ➡ shows no intrinsic vascularity.*

DIFFERENTIAL DIAGNOSIS

Common

- Hematoma
- Muscle Tear
- Nerve Sheath Tumor

Less Common

- Soft Tissue Sarcoma
- Myxoma
- Fibromatosis
- Abscess
- Metastases
- Myositis Ossificans
- Lymphangioma
- Intramuscular Extension of Baker Cyst
- Vascular Malformation
- Local Tumor Recurrence
- Intramuscular Ganglion Cyst
- Granuloma
- Diabetic Muscle Infarction

Rare but Important

- Parasitic Infection

ESSENTIAL INFORMATION

Key Differential Diagnosis Issues

- Clinical history is important for differentiating any muscle mass
- Acute hematoma & infection are usually readily distinguishable from other muscle masses
- Make every effort to reach diagnosis before resorting to percutaneous biopsy or aspiration
  - Often percutaneous biopsy is not necessary
  - However, if unsure regarding nature of mass, arrange either follow-up or biopsy or request alternative investigation (usually MR)

Helpful Clues for Common Diagnoses

- **Hematoma**
  - Due to trauma, anticoagulation, or vascular malformation
  - Anterior thigh & calf are most common as susceptible to both compression injury & muscle contraction injury
  - Initially hyperechoic or isoechoic
    - Becomes more hypoechoic with increasing liquefaction after several days to weeks
    - ± layering or whorled pattern due to sequential episodes of bleeding (expanding hematoma)
  - Mild intramuscular hemorrhage may not be apparent on US since ill-defined, hyperechoic areas of blood blend with hyperechoic muscle
- **Muscle Tear**
  - Discontinuity ± retraction of muscle fibers within muscle bulk or at myofascial junction
    - Myofascial junction most common site of tear
  - ± tear filled with hematoma or fluid
  - ± surrounding muscle & subcutaneous edema
  - Do not confuse with muscle contusion
    - Contusion shows no fiber discontinuity
    - May cross muscle fascial boundaries
    - Ill-defined hyperechogenicity of muscle due to edema ± blood
    - Hyperemia during reparative stage
- **Nerve Sheath Tumor**
  - Arises along course of peripheral nerve
  - Well-defined, fusiform-shaped, hypoechoic mass
    - Anechoic areas due to myxoid accumulation (common)
    - ± additional areas of hyperechogenicity due to hemorrhage, calcification, or fibrosis
  - Posterior acoustic enhancement (mild to moderate)
  - Thickened entering or exiting nerve; evident in 50%
    - Entering or exiting nerve may not be visible if tumor arises from small peripheral nerve
    - Report whether nerve is centrally or eccentrically placed relative to parent nerve
  - Split-fat sign due to separation of muscle fibers with enhanced visibility of fat at edge of tumor
  - Mild to moderate hyperemia on color Doppler imaging
    - Very occasionally, minimal demonstrable vascularity

Helpful Clues for Less Common Diagnoses

- **Soft Tissue Sarcoma**
  - Usually seen as large, well-defined, hypoechoic mass within muscle layer
    - Moderately to highly vascular
    - Occasionally, hypovascular or even avascular on color Doppler imaging
    - Hypovascularity does not exclude malignancy
  - Any large (> 5-cm), solid, nonfatty soft tissue tumor should be considered sarcoma unless proven otherwise by biopsy
    - Most large, intramuscular masses require biopsy
    - *MDM2* gene amplification of core needle biopsy highly sensitive & specific at distinguishing well-differentiated liposarcoma from lipoma
- **Myxoma**
  - Composed of few spindle-shaped cells within mucoid material supported by loose collagen framework
  - Hypoechoic, cystic-type, intramuscular mass ± comet-tail artifacts
    - Peripheral rim of increased echogenicity (bright rim sign) due to myxoid tissue leakage
    - Triangular hyperechoic area adjacent to mass (bright cap sign) due to muscle atrophy
    - No communication with adjacent joint
    - Main differential diagnosis is myxoid liposarcoma
- **Fibromatosis**
  - a.k.a. desmoid tumor
  - Locally aggressive overgrowth of fibrous tissue with well-defined or infiltrative border
    - Typically absent or minimal vascularity on color Doppler imaging
- **Abscess**
  - More frequent in immunosuppressed patients
  - Many variable appearances
  - Thick-walled, irregular hypervascular outline with hypoechoic, avascular necrotic center is most typical
    - ± edema & hyperemia of adjacent inflamed tissues
    - ± intralesional gas locules moving in real-time
    - ± enlarged regional lymph nodes

- US-guided aspiration of liquefied content helps to identify infective organism

- **Metastases**
  - Usually seen with widely disseminated metastatic disease
  - Most common muscle metastasis is adenocarcinoma of lung
  - Similar in appearance to soft tissue sarcoma, though metastases tends to be smaller than primary sarcoma
- **Myositis Ossificans**
  - Focal hypoechoic area of circumferential heterotopic calcifications within muscle
    - Peripheral distribution of calcification with lucent center distinguishes it from parosteal osteosarcoma
  - Usually seen in younger patients at site of previous trauma, though can occur without trauma
  - Radiographs or CT very helpful; biopsy not indicated when typical imaging features are present
- **Lymphangioma**
  - More common in subcutaneous tissues though often multicompartmental
  - Thin-walled, multiloculated, septated mass
  - Thick walled with debris if complicated by infection or hemorrhage
  - Absence of grayscale fluid flow (as in venous vascular malformation)
- **Intramuscular Extension of Baker Cyst**
  - Occasionally extend into calf or distal thigh muscles
    - ± pericystic leakage or intracystic hemorrhage
- **Vascular Malformation**
  - Either low flow (common) or high flow (uncommon)
  - Often multicompartment involvement
  - Ill-defined with serpiginous cystic spaces ± phleboliths (characteristic)
  - Variable hypo- or hyperechoic stromal component
  - Slow venous flow may be seen only on grayscale imaging, as too slow to be detected by color Doppler imaging
- **Local Tumor Recurrence**
  - Discrete, rounded mass at site of primary tumor excision
  - Need to differentiate from more linear, irregular hypoechoic scar tissue
  - US appearances of recurrence usually mimic those of primary tumor
- **Intramuscular Ganglion Cyst**
  - Extension of ganglion cyst from joint into muscle
  - Similar US appearances to ganglion cyst elsewhere
  - Hypoechoic ± echogenic comet-tail artifacts
  - ± intracystic hemorrhage or pericystic leakage
    - Pericystic leakage usually associated with pericystic inflammation
- **Granuloma**
  - Much more common in subcutaneous tissues, especially gluteal region
  - Usually following injection
    - Occasionally following trauma or foreign body implantation
  - Majority have calcified rim
- **Diabetic Muscle Infarction**
  - Occurs in diabetics with established vasculopathy
  - Ill-defined, hypoechoic area becoming better defined after 1 week
    - Muscle architecture remains vaguely detectable within hypoechoic area
    - No necrosis
    - No detectable vascularity at onset → mild to moderate hyperemia after ~ 1 week

Helpful Clues for Rare Diagnoses

- **Parasitic Infection**
  - Cysticercosis: Commonest soft tissue parasitic infection
    - Well-defined, small, hypoechoic mass with eccentric echogenic nidus representing scolex
    - Diagnosis confirmed by therapeutic response or surgical excision
  - Hydatid; rare, multicystic mass, little or no hyperemia

SELECTED REFERENCES

1. Mohanan K et al: Primary hydatidosis of the thigh involving the vastus lateralis muscle: a case report. Cureus. 16(3):e56683, 2024

Hematoma

Hematoma

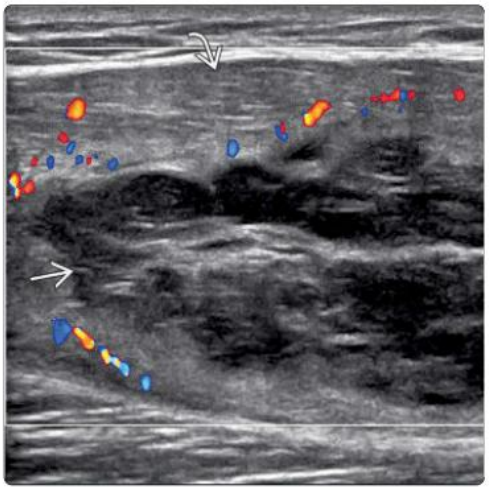

(Left) *Transverse US of 78-year-old man who was overanticoagulated with warfarin shows a large hematoma ⇨ within the biceps femoris muscle ⇨. There is early rim calcification ⇨. No hyperemia was present.* **(Right)** *Longitudinal US of a 38-year-old man with thigh swelling following a football injury shows a healing hematoma ⇨ in the rectus femoris muscle ⇨. There is moderate reparative marginal hyperemia.*

(Left) *Transverse US shows a liquefied calf muscle hematoma ➡ following trauma 2 months earlier. Note the fine echogenic content ➡, suggestive of hemorrhage, and the entrapped fluid ➡. Aspiration yielded old blood.* **(Right)** *Transverse US of a man with slowly enlarging distal triceps ➡ swelling for 4 years shows a well-defined, partially cystic mass ➡ with a softish-solid component. Mild marginal hyperemia was present. Biopsy revealed hemorrhage and fibrous organization, consistent with a chronic expanding hematoma.*

Hematoma

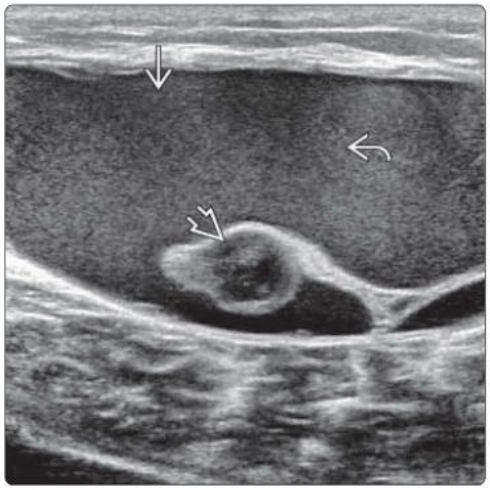

Hematoma

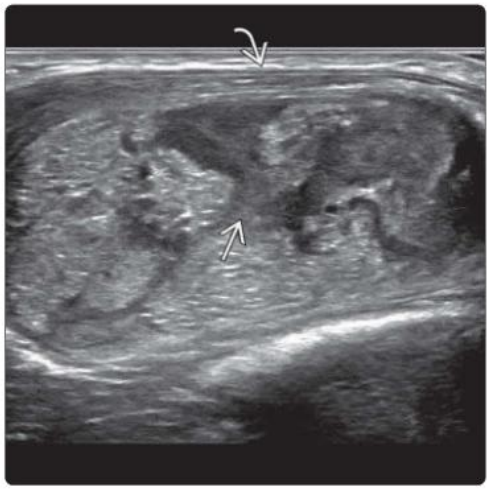

(Left) *Longitudinal US shows a large, healing myofascial tear between the medial belly of the gastrocnemius ➡ and the soleus ➡ muscles with a liquefied hematoma ➡ partially filling the gap of this tear.* **(Right)** *Transverse US of the anterior abdominal wall of a 74-year-old man on anticoagulation shows a localized tear ➡ within the swollen internal oblique muscle at the midaxillary line. There is a small hematoma ➡ within this muscle tear. The external oblique ➡ and transversus abdominis ➡ muscles are normal.*

Muscle Tear

Muscle Tear

(Left) *Longitudinal US shows a nerve sheath tumor ➡ within the sartorius muscle. The adjacent increased echogenicity ➡ is due to muscle fiber splaying leading to exaggeration of intramuscular fat (split-fat sign). There is characteristic mild acoustic enhancement ➡.* **(Right)** *Transverse US shows a large intramuscular myxomatous-type mass ➡ in the midthigh region. This may represent either a myxoma or, less likely, a myxoid-type "ancient" schwannoma. Histology confirmed muscle myxoma.*

Nerve Sheath Tumor

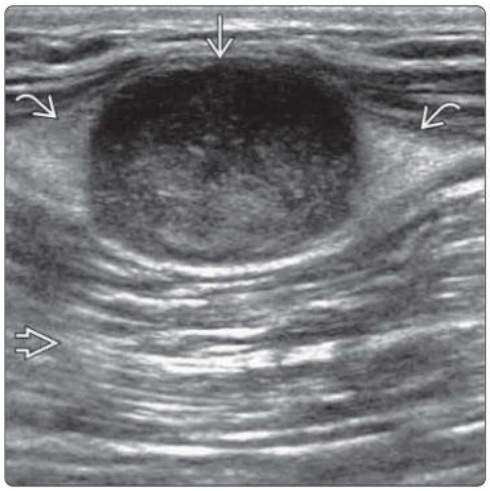

Myxoma

Fibromatosis

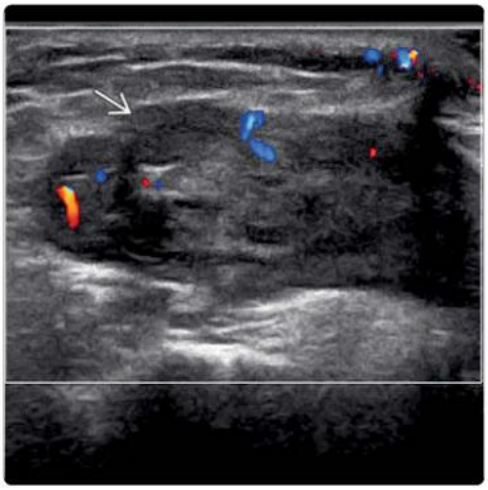

Fibromatosis

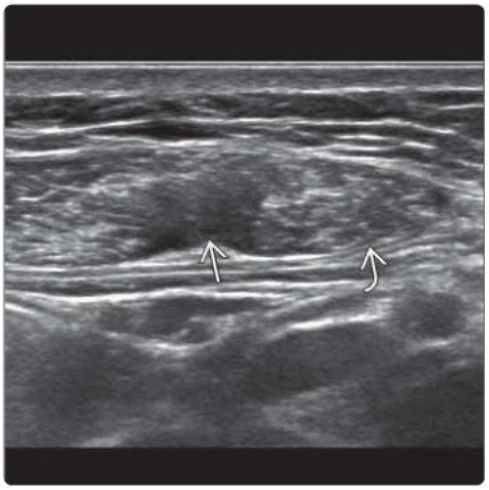

(Left) *Transverse US of the arm shows an area of fibromatosis (desmoid tumor) ➡ in the triceps muscle. This tumor remained unchanged for many years. Mild hyperemia is present.* **(Right)** *Transverse US of 38-year-old woman shows fibromatosis (desmoid tumor) ➡ in the rectus abdominis muscle ➡. The surrounding muscle has moderate fatty atrophy. This fibromatosis reduced slightly in size over a 3-year period. Fibromatosis has a variable US appearance, depending on tumor maturity.*

Abscess

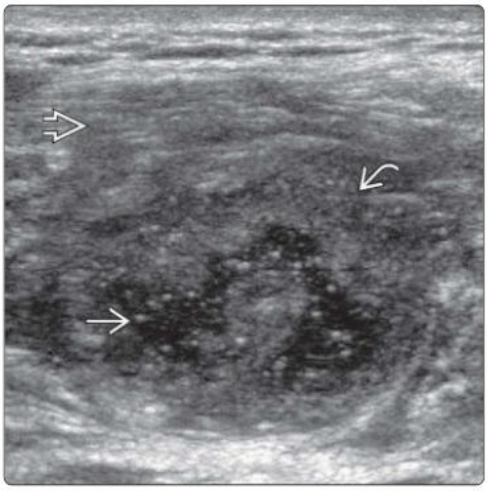

Abscess

(Left) *Longitudinal US shows an intramuscular abscess ➡. Many small echogenic foci ➡, due to proteinaceous aggregates or gas, are present and seen to move on real-time imaging. The margin is ill defined with moderate edema of the surrounding muscle ➡.* **(Right)** *Longitudinal US shows a large, irregular fluid collection ➡ present on the posteromedial aspect of the distal femur. Aspiration yielded purulent fluid, which grew Staphylococcus aureus.*

Abscess

Metastases

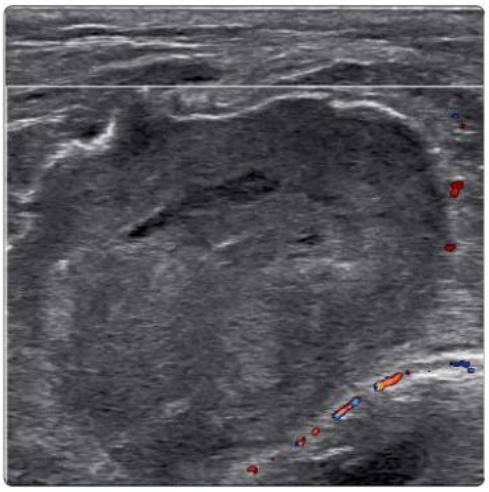

(Left) *Transverse US of a patient with acute myeloid leukemia, pancytopenia, and fever shows a medium-sized abscess ➡ present within a moderately edematous rectus femoris muscle ➡. Aspiration yielded Pseudomonas aeruginosa.* **(Right)** *Transverse US of the proximal thigh of a 68-year-old man with lung carcinoma shows a large, partially necrotic mass within the obturator externus muscle. Despite lack of intrinsic hyperemia, this was still most likely a metastatic deposit, which was confirmed by US-guided biopsy.*

(Left) *Longitudinal US of a middle-aged man with a known lung malignancy shows a small, hypoechoic nodule ➡ with irregular, ill-defined borders ➡ within the gluteus maximus muscle in favor of an intramuscular metastatic deposit. Franseen biopsy confirmed metastatic adenocarcinoma from a lung primary.* **(Right)** *Transverse US of the posterior knee shows a focal area of dense ossification ➡ within the medial aspect of the popliteus muscle.*

Metastases

Myositis Ossificans

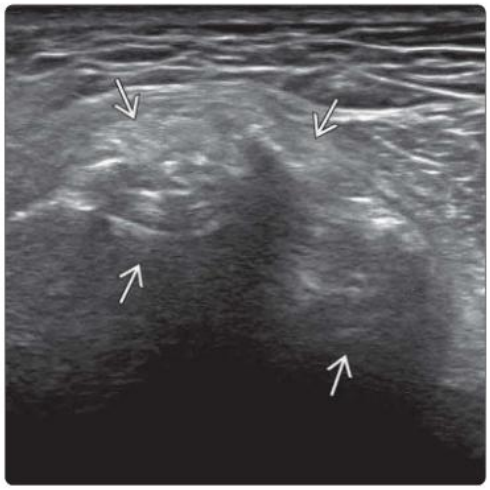

(Left) *Axial CT of the same patient confirms the diagnosis of myositis ossificans ➡, showing circumferential calcification with a lucent center within the popliteus muscle. This is a "no-touch" lesion, where diagnosis does not require biopsy when typical imaging features are present.* **(Right)** *Longitudinal US shows the distal end of a large Baker cyst ➡ that has leaked into the medial belly of gastrocnemius muscle ➡. This leakage is chronic, as shown by the lack of free fluid and absence of soft tissue edema.*

Myositis Ossificans

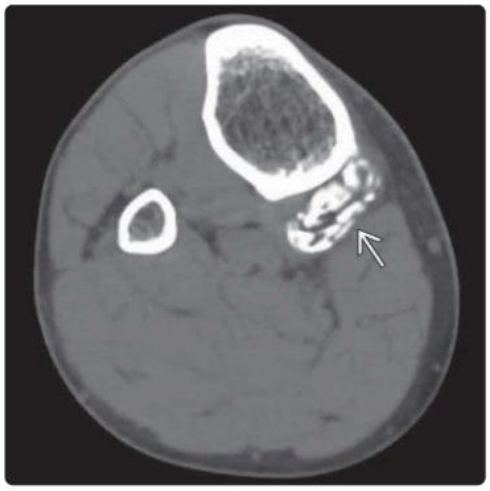

Intramuscular Extension of Baker Cyst

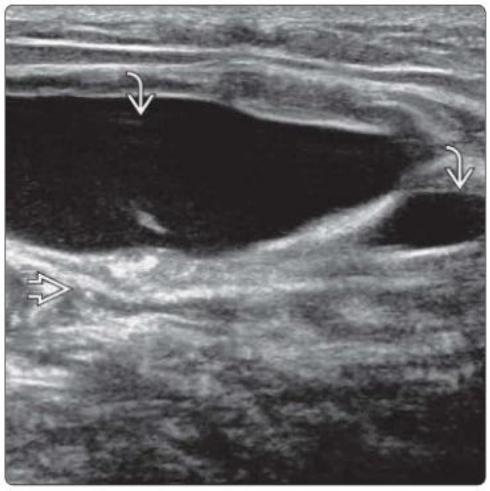

(Left) *Transverse US of 42-year-old woman with localized calf swelling shows an irregular, hypoechoic mass ➡ within the soleus muscle containing small calcific foci ⇨ and focal anechoic compressible areas ➡. Prominent surrounding vessels ➡ are present.* **(Right)** *Color Doppler US of the same lesion shows moderate intrinsic and surrounding vascularity. Features are in favor of a venous-type vascular malformation, which was confirmed on subsequent US-guided core needle biopsy.*

Vascular Malformation

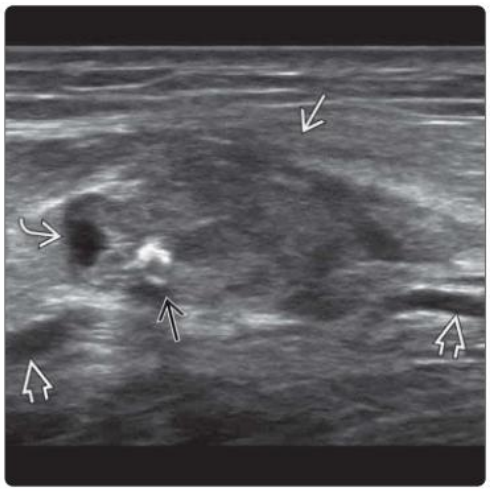

Vascular Malformation

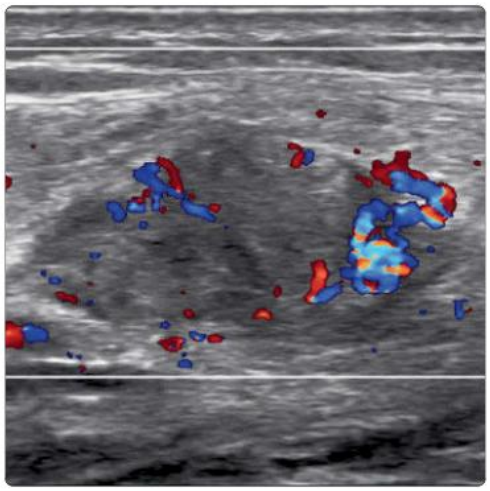

Local Tumor Recurrence

Local Tumor Recurrence

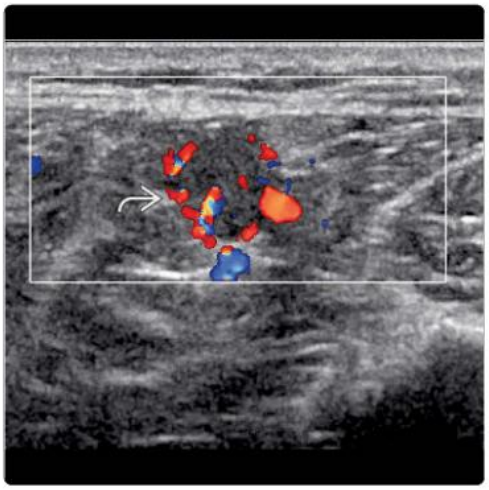

(Left) *Transverse US of a patient with resection of a soleus muscle inflammatory myxohyaline tumor 18 months earlier shows a small, hypoechoic intramuscular nodule ➡. US-guided biopsy confirmed local tumor recurrence.* **(Right)** *Transverse color Doppler US of the same tumor shows moderate marginal hyperemia ➡.*

Intramuscular Ganglion Cyst

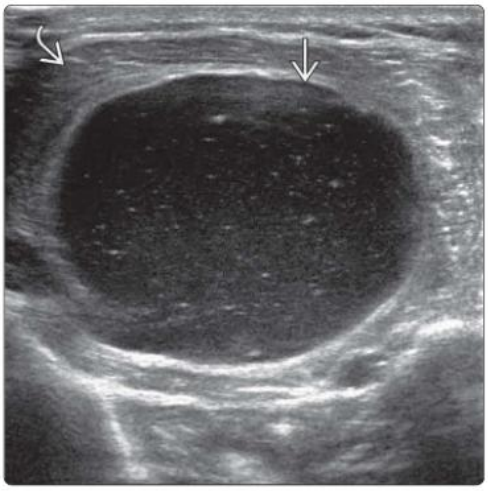

Intramuscular Ganglion Cyst

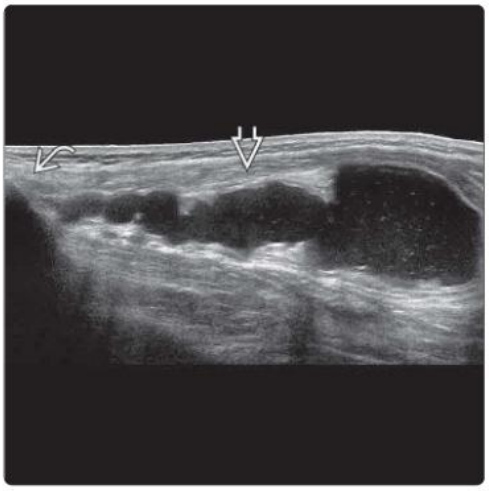

(Left) *Transverse US shows a hypoechoic cystic-type mass ➡ with small echogenic foci within the tibialis anterior muscle ➡.* **(Right)** *Longitudinal US of the same tumor shows a wide hypoechoic tract ➡ connecting the proximal end of the cyst to the proximal tibiofibular joint ➡. This represents a paraarticular ganglion cyst, which has extended into the tibialis anterior muscle.*

Parasitic Infection

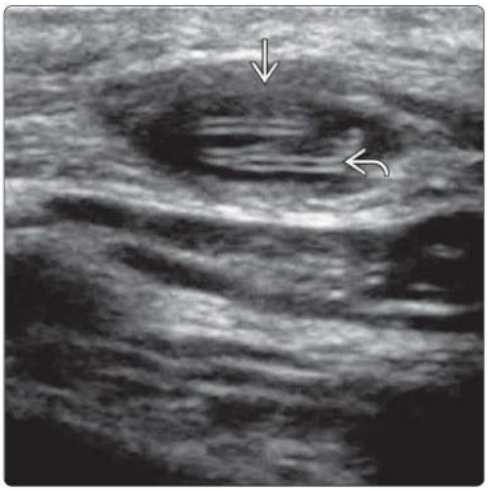

Parasitic Infection

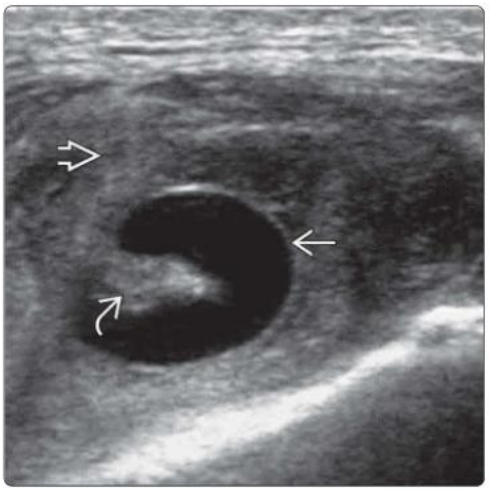

(Left) *Longitudinal US of the hand shows cysticercosis infestation of the thenar muscle with a hypoechoic cyst ➡ containing an echogenic tapeworm ➡. (Courtesy V. Hardas, MD.)* **(Right)** *Transverse US shows an intramuscular cysticercosis infestation as a small, hypoechoic intramuscular mass ➡ with an eccentric echogenic nidus ➡ representing the scolex. The surrounding arm musculature is edematous ➡. (Courtesy V. Hardas, MD.)*

DIFFERENTIAL DIAGNOSIS

Common

- Intermuscular Lipoma
- Intramuscular Lipoma
- Muscle Edema
- Hematoma
- Vascular Malformation
- Fatty Replacement

Less Common

- Foreign Body
- Soft Tissue Sarcoma
- Local Recurrence
- Muscle Metastases
- Fibromatosis
- Hibernoma
- Peripheral Nerve Sheath Tumor
- Myositis
- Rhabdomyolysis
- Venous Dilatation/Thrombosis

ESSENTIAL INFORMATION

Key Differential Diagnosis Issues

- Muscle echogenicity varies according to orientation of muscle fiber & transducer & amount of lean or fatty tissue
  - Lean muscle tends to be more hypoechoic
  - Fatty muscle tends to be more hyperechoic
- As muscle fibers are aligned in different directions, anisotropy can be used to demarcate apposing muscles

Helpful Clues for Common Diagnoses

- **Inter- or Intramuscular Lipoma**
  - Located deep to investing fascia
  - May be classified as subfascial, intermuscular, intramuscular, or submuscular in location
    - Subfascial: Between investing fascia & muscle
    - Intermuscular: Between muscles (most common)
    - Intramuscular: Within muscle
    - Submuscular: Beneath muscle (least common)
  - US appearances of deep lipomas are similar to subcutaneous lipomas but more variable
    - Usually larger than subcutaneous lipomas at presentation
    - Less compressible
    - Occasional vessels detected (vs. subcutaneous lipomas, which are nearly always avascular)
  - Discrete noninfiltrative mass with well-defined convex margins
  - Fusiform or oblong in shape with long axis parallel to skin
  - May be hypoechoic (infrequent)
    - Usually hyperechoic to muscle
  - Fine linear echogenic striations running parallel to long axis of tumor in both transverse & longitudinal planes
  - May show mild acoustic enhancement
  - No vascularity in or around lipoma on color Doppler
    - Occasional intralesional vessels may be visible
  - Consider liposarcoma if following features are present
    - Large mass (> 5 cm)
    - Thick (> 2 mm) septations
    - Nodular areas of nonlipomatous tissue
    - Cyst-like or myxoid areas within tumor
    - Majority of tumor is nonlipomatous
  - MR is helpful for characterization, surgical planning, & establishing baseline for all suspected deep lipomas
- **Muscle Edema**
  - From inflammation, infection, venous congestion, trauma, denervation
  - Muscle becomes hyperechoic (although intense edema can be hypoechoic)
  - Diffuse or patchy hyperechogenicity depending on cause
  - Variable hyperemia
  - Concomitant subcutaneous/perifascial edema common in infection, inflammation, & trauma
- **Hematoma**
  - Intramuscular hematoma may occur due to trauma, anticoagulation, vascular malformation, or sarcoma
    - Common at anterior thigh as prone to contusion
  - Acute hematoma is usually iso- or hyperechoic to muscle
    - ± layering due to repeated hemorrhage
    - Becomes more hypoechoic with increasing liquefaction after several days
    - ± sedimentation present after few minutes of rest
  - Mild, diffuse intramuscular hemorrhage may be overlooked on US as it blends with muscle
    - For mild muscle injury, MR more sensitive than US
  - If no trauma history, always consider likelihood of underlying precipitating condition, e.g., intramuscular sarcomas or vascular malformations may bleed spontaneously or during exercise
- **Vascular Malformation**
  - Vascular malformation & hemangioma indistinguishable on US
  - Hemangioma
    - Vascular tumor of childhood: Progressive → regressive
    - Regresses usually by puberty
  - Vascular malformation
    - Vascular dysmorphogenesis
    - Enlarges in line with skeletal development
    - May change shape in adulthood due to thrombosis & revascularization
  - 5 different subtypes of vascular malformation depending on predominant vascular component
    - Capillary, venous, arteriovenous, lymphatic, or mixed
  - US is helpful in establishing diagnosis, assessing flow, & relative amount of stroma vs. vascular component
- **Fatty Replacement**
  - Diffuse fatty replacement
    - Due to disuse, denervation, neuromuscular disorder, chronic myositis (± atrophy)
    - Also in pseudohypertrophy
  - Focal fatty replacement
    - Often associated with adjacent old muscle tears
  - Non-mass-like echogenicity blends into echo-bright perimysium, causing reduced pennate muscle appearance

Helpful Clues for Less Common Diagnoses

- **Foreign Body**
  - Lodges in subcutaneous tissues much more commonly than in muscle

- Nearly all foreign bodies are echogenic
- ± reverberation artifact or acoustic shadowing
- Bamboo & noncompact wood may be inconspicuous as they absorb fluid & have echogenicity similar to soft tissue
  - Consider repeat US after 1-3 days if foreign body is not detected initially
- Missed foreign bodies often develop hypoechoic rim
  - Rim is composed of hyperemic granulation & fibrous tissue
  - Makes foreign body more conspicuous

- **Soft Tissue Sarcoma**
  - Occurs most frequently in muscle layer
    - Majority are hypoechoic
    - Occasionally hyperechoic due to fat, immature fibrosis, or hemorrhage
    - US appearances do not conform to recognized tumor (e.g., nerve sheath tumor, lipoma, vascular malformation, fibromatosis, etc.)
    - If suspected, usually requires percutaneous biopsy
- **Local Recurrence**
  - Discrete mass at site of primary tumor excision
  - US appearances similar to those of primary tumor
  - Must be distinguished from reparative postoperative nodular fibrosis
    - Follow-up ± biopsy if in doubt
  - Serial MR examination often better than US in this context
- **Muscle Metastases**
  - Most patients have known primary tumor with disseminated metastases
  - Adenocarcinoma > squamous cell carcinoma
  - Breast, lung, & upper aerodigestive tract are common primary sites
  - Ill-defined, hypoechoic muscle mass aligned along long axis of muscle (typical)
    - US appearances similar to those of primary tumor
  - Often, several muscle metastases occur within same area
  - Biopsy is diagnostic & indicated if confirmation required
- **Fibromatosis**
  - May appear echogenic if fibrous tissue component is not fully mature
  - Usually hypoechoic or mixed hypo-/hyperechoic tumor
  - Usually well defined without undue tethering or infiltrative element
  - Minimal or no tumoral hyperemia
  - Evolves slowly on serial imaging
- **Hibernoma**
  - Rare benign tumor consists of vestigial brown fat
  - Most are intramuscular in contrast to lipoma
  - Indistinguishable from intramuscular lipoma/atypical lipomatous tumor on US
    - Similarly hyperechoic ± mild intralesional vascularity
  - Requires tissue sample for definitive diagnosis
- **Peripheral Nerve Sheath Tumor**
  - Most are hypoechoic
    - Similar appearance to subcutaneous type
    - ± neural continuity
    - Tumoral hyperechogenicity indicates internal hemorrhage
- **Myositis**
  - Increased ill-defined muscle hyperechogenicity & swelling
  - Decreased muscle architecture definition ± focal hyperemia
    - Inflammatory myositis is often symmetric
  - MR is more sensitive than US at detecting mild myositis
- **Rhabdomyolysis**
  - Necrosis of skeletal muscle
    - Contents of injured muscle cells leak into circulation
    - If severe, → electrolyte imbalance, acidosis, coagulopathy, hypovolemia, & acute renal failure
  - Many causes, including trauma, strenuous muscle exercise, & prolonged muscle compression
  - Diffusely echogenic muscle or muscles
- **Venous Dilatation/Thrombosis**
  - Dilatation: Slow-moving blood → red cell clumping → vascular hyperechogenicity
    - Sedimentation effect may be visible if vein at rest
  - Thrombosis: Incompressible intraluminal echogenicity

Intermuscular Lipoma

Intermuscular Lipoma

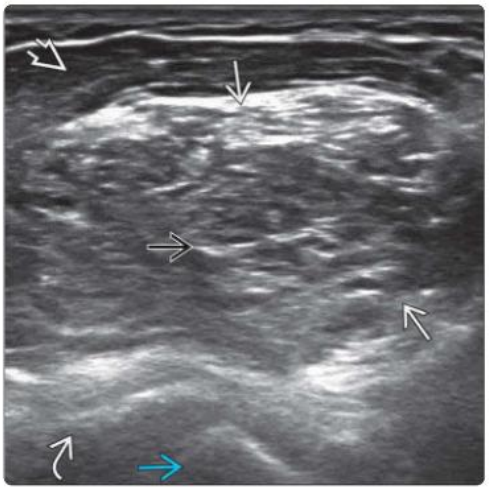

(Left) *Longitudinal US of a large, midarm intermuscular lipoma sited deep to the biceps muscle, shows typical US appearances without untoward features.* **(Right)** *Transverse US shows an intermuscular lipoma at the anterior cubital fossa sited in the intermuscular fat plane between the brachioradialis & supinator. On transverse view, the striations within the lipoma often appear less organized than in longitudinal view but should remain horizontal. Note the radius.*

(Left) *Longitudinal US shows a large shoulder intramuscular lipoma ➡ sited within the deltoid muscle, sandwiched between the superficial ➡ & deep ➡ muscle fibers. Note the typical horizontal striations present throughout the tumor. The biceps muscle ⇨ is shown.* **(Right)** *Transverse US shows a medium-sized intramuscular lipoma ➡ within the midportion of the deltoid muscle ➡. The deltoid is a common site for intramuscular lipoma. Note the humeral head ➡.*

Intramuscular Lipoma

Intramuscular Lipoma

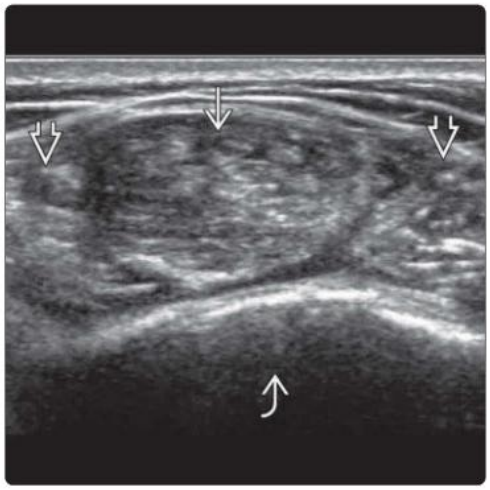

(Left) *Longitudinal US of the same deltoid intramuscular lipoma ➡ is shown. In contrast to the intermuscular type, the intralesional striations can be thicker & more continuous throughout the tumor ➡, reflecting the embedded & stretched muscle fibers.* **(Right)** *Longitudinal US shows moderate edema of the calf subcutaneous tissues ➡ as well as the gastrocnemius ➡ & soleus muscles ⇨. Edematous muscle is diffusely hyperechoic with preservation of muscle architecture.*

Intramuscular Lipoma

Muscle Edema

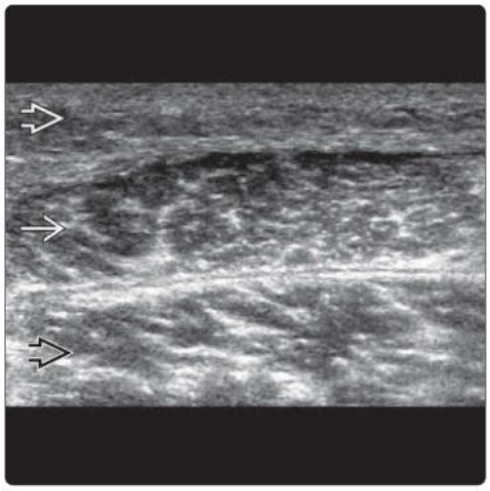

(Left) *Transverse US of anterior elbow following direct blunt trauma shows severe pronator teres muscle edema ➡ with diffuse & hyperechoic change ➡ & a broadly preserved muscle architecture. There is mild subcutaneous edema ➡ with a normal brachialis muscle ⇨.* **(Right)** *Longitudinal US shows mild muscle contusion in the brachialis muscle. Note the diffuse hyperechogenicity & slightly swollen muscle belly, indicating edema ➡. Muscle architecture is generally well preserved.*

Muscle Edema

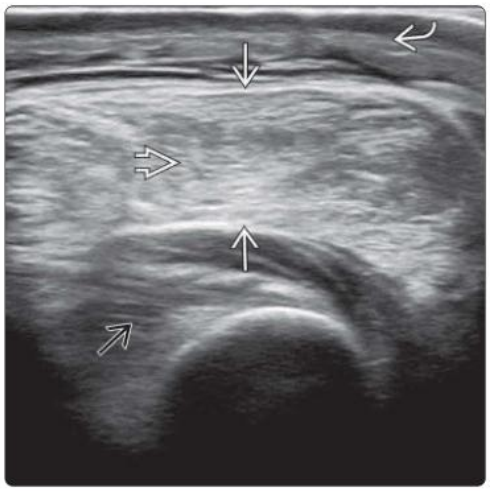

Muscle Edema

Hematoma

Hematoma

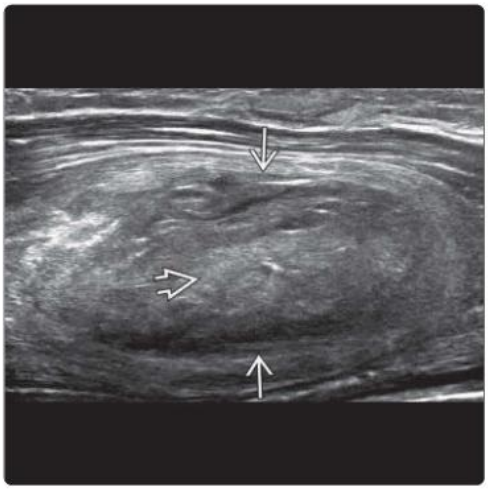

(Left) *Longitudinal US shows the anterior aspect of the distal upper arm after blunt trauma. In contrast to the previous case, in addition to diffuse muscle edema, there are discrete irregular hyperechoic areas, muscle fiber disruption, & a hypoechoic border, indicating mild muscle hemorrhage & an evolving hematoma.* **(Right)** *Longitudinal US of a deltoid hematoma. Compared to the previous case, this is a solid-looking, discrete hematoma with defined margins & total fiber disruption.*

Vascular Malformation

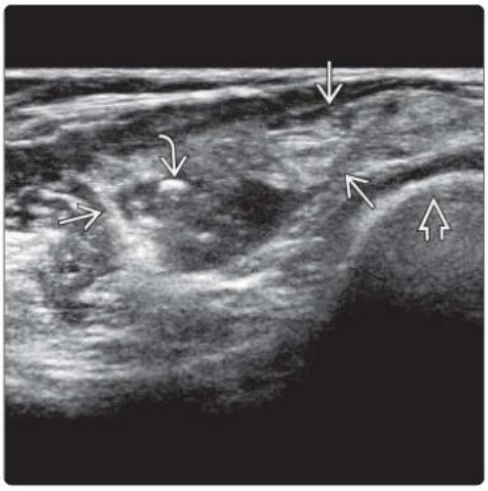

Vascular Malformation

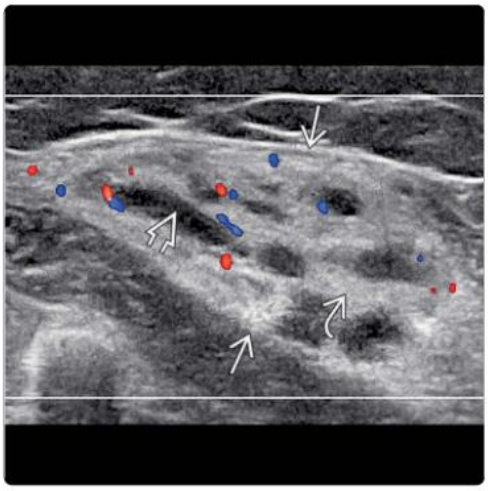

(Left) *Transverse US shows a hyperechoic vascular malformation within the distal triceps alongside the olecranon. The lesion is mainly composed of large vessels. A single phlebolith is present.* **(Right)** *Longitudinal US shows a well-defined, gastrocnemius intramuscular vascular malformation. It is composed of 25% venous-type channels & 75% echogenic/mildly hyperemic stroma. Venous channels often lack Doppler signal due to slow flow, which may become apparent with augmentation.*

Fatty Replacement

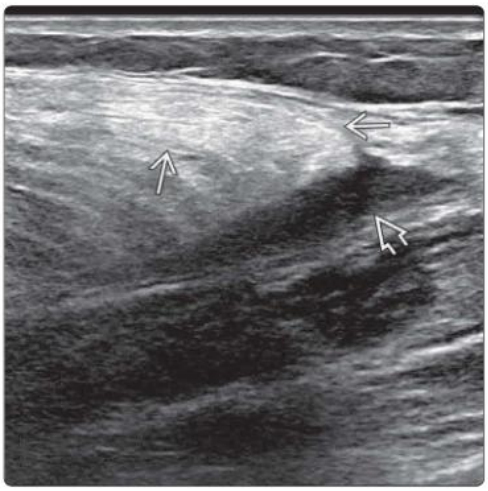

Fatty Replacement

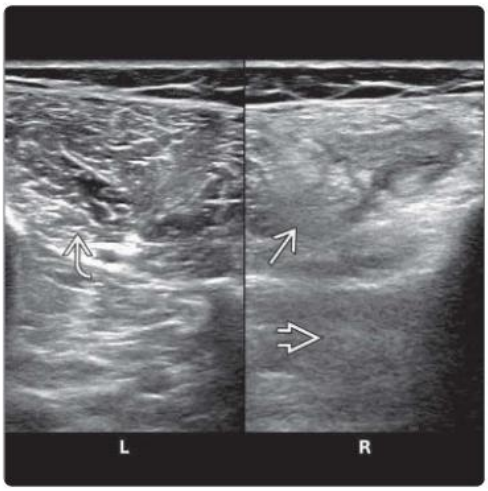

(Left) *Longitudinal US 7 months after a medial gastrocnemius myofascial tear shows fatty change of the torn muscle with localized muscle hyperechogenicity. There is a small residual liquified hematoma.* **(Right)** *Transverse US of anterior tibialis muscles shows unilateral, diabetes-related pseudohypertrophy. The affected muscle is slightly larger with fatty replacement seen as patchy hyperechogenicity & reduced acoustic transmission. The contralateral side is normal.*

(Left) *Longitudinal US of the thenar muscle with a small discharging sinus shows a 33-mm-long bamboo splinter ➡ embedded in the thenar muscle with a hypoechoic rim ➡ due, in this case, to inflamed tissue rather than granulation tissue.* **(Right)** *Transverse US of the volar aspect of the middle finger shows both a chevron-shaped ➡ & a dot-like ➡, subcutaneous echogenic foreign body with a small surrounding abscess ➡ draping the flexor tendon ⇨. 3 small wood splinters with pus were found surgically.*

Foreign Body

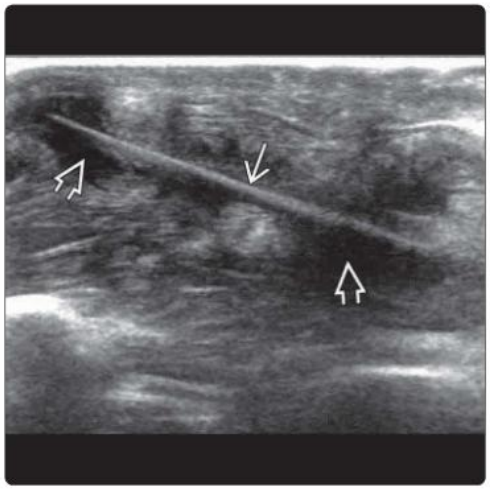

Foreign Body

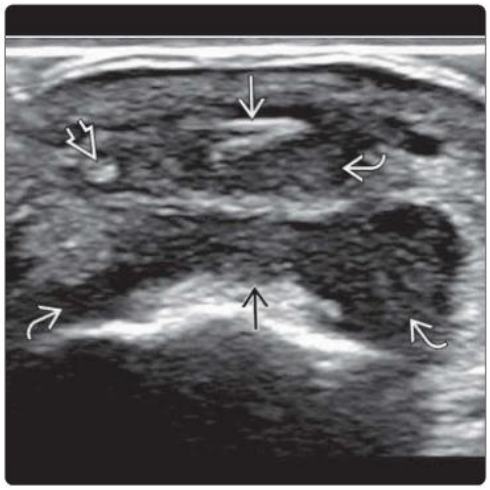

(Left) *Longitudinal US shows a large hyperechoic tumor ➡ within the calf musculature. US-guided biopsy for histology revealed a liposarcoma.* **(Right)** *Transverse US shows a histology-proven myxoid liposarcoma ➡ in the posterior thigh arising in the intermuscular plane between the semimembranosus & semitendinosus muscles. On MR, the tumor was found to be mainly myxoid with little fat content.*

Soft Tissue Sarcoma

Soft Tissue Sarcoma

(Left) *Transverse US shows an ill-defined, echogenic metastasis ➡ within the teres major muscle ➡. This patient had disseminated shoulder metastases from a nasopharyngeal primary tumor.* **(Right)** *Transverse US of calf fibromatosis, seen as a medium-sized avascular mass ➡ at the superficial gastrocnemius myotendinous junction with spiculated muscular interdigitation ➡, is shown. Fibromatosis is usually hypoechoic, though immature proliferative fibrosis may appear hyperechoic, as in this case.*

Muscle Metastases

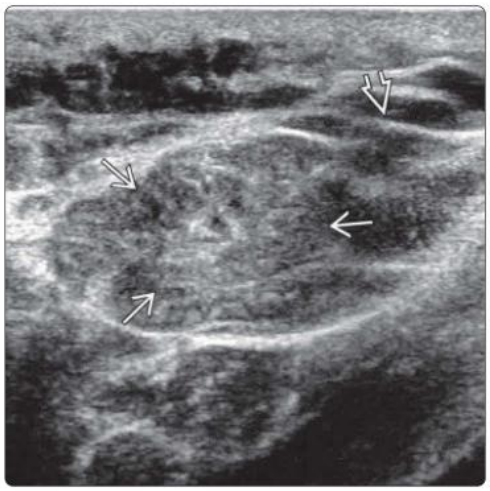

Fibromatosis

Peripheral Nerve Sheath Tumor

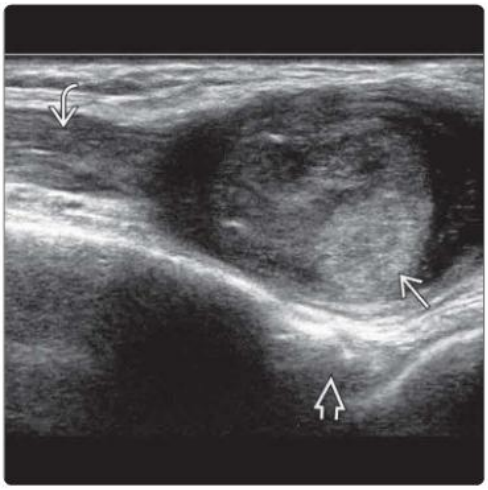

Myositis

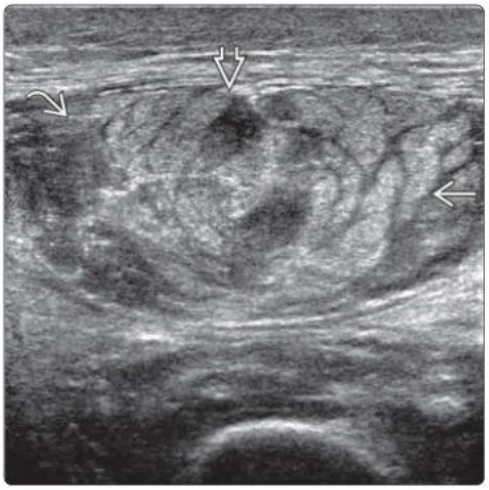

(Left) *Longitudinal US shows a partly hyperechoic nerve sheath tumor ➡ of the deep peroneal nerve anterior to the ankle ➡. Hyperechogenicity within this tumor generally indicates intratumoral hemorrhage. The nerve is thickened ➡ proximally.* **(Right)** *Transverse US shows diffuse edema & swelling of the rectus femoris muscle ➡. Linear muscle striations ➡ are still preserved with more edematous hypoechoic areas ➡. Similar changes affected vastus medialis & lateralis muscles & contralateral thigh.*

Myositis

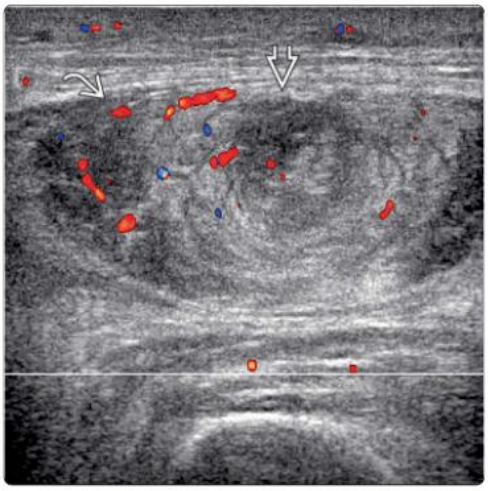

Rhabdomyolysis

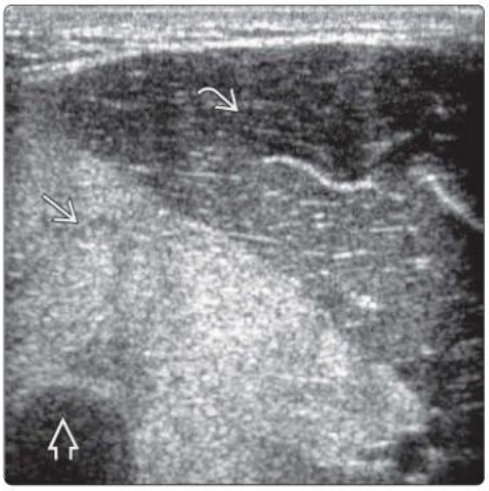

(Left) *Transverse color Doppler US of the same muscle shows moderate hyperemia ➡. The hypoechoic edematous area is less hyperemic ➡. Overall appearances indicate an inflammatory myositis.* **(Right)** *Transverse US shows a hyperechoic brachialis muscle ➡ following unaccustomed exertion on a rowing machine, indicative of delayed-onset muscle soreness with rhabdomyolysis. The biceps brachii muscle ➡ is normal. Humeral shaft is shown as a landmark ➡.*

Venous Dilatation/Thrombosis

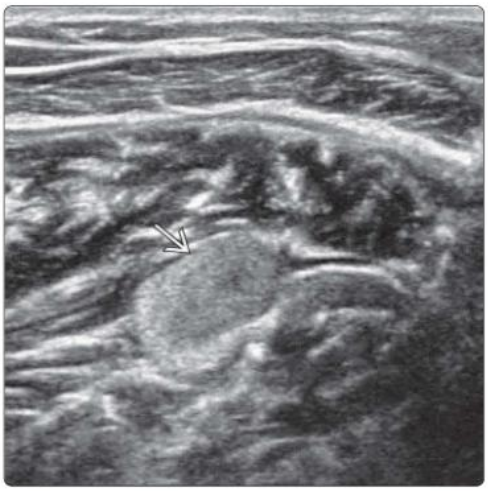

Venous Dilatation/Thrombosis

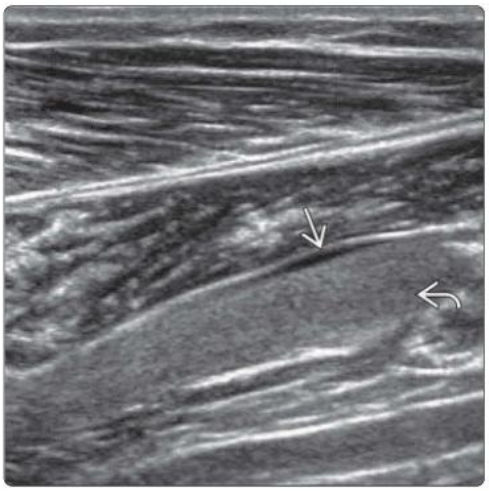

(Left) *Transverse US shows a rounded echogenic structure ➡ within the soleus muscle.* **(Right)** *Longitudinal US of the same area shows that this echogenic structure ➡ is a dilated deep vein with slow flow. The echogenic content is caused by clumping ("rouleaux") of slow-moving red blood cells. These intravascular red cell aggregates show early sedimentation superficially ➡. Compression US can help to exclude thrombus.*

DIFFERENTIAL DIAGNOSIS

Common

- Ganglion Cyst
- Bursal Distention

Less Common

- Abscess
- Hematoma
- Seroma
- Baker Cyst
- Dermoid/Implantation Dermoid
- Parameniscal Cyst
- Metastasis
- Vascular Anomaly
- Lymphatic Malformation
- Fat Necrosis
- Schwannoma
- Intramuscular Myxoma
- Sarcoma
- Lymph Node
- Venous Varix
- Aneurysm
- Pseudoaneurysm
- Geyser Lesion

ESSENTIAL INFORMATION

Key Differential Diagnosis Issues

- Adjust gain setting to optimize visualization of internal contents
  - Cystic-type mass is not necessarily anechoic
  - Many cystic lesions contain hyperechoic fluid or echogenic foci
- Look for posterior acoustic enhancement
- All cystic-type masses should be evaluated with color Doppler imaging
  - May reveal internal vascularity in hypoechoic lesion initially considered to be cystic
  - May reveal previously unrecognized vascular structures alongside cystic-type mass

Helpful Clues for Common Diagnoses

- **Ganglion Cyst**
  - Most common cystic-type mass
  - Filled with gelatinous material of variable viscosity
  - Occurs alongside joints: Synovial fluid squeezed out from joint through capsular defect
  - Increase in extent through process of cyst enlargement → rupture → consolidation
    - Some can be extensive, serpiginous, multiloculated, & quite remote from joint of origin
    - May extend into muscle & simulate myxoma
  - Fluid-filled ovoid or irregular lesion with stalk connecting to or extending toward joint of origin
    - Locate stalk & trace toward joint of origin, though communication with joint is not always apparent
  - No hyperemia except with recent leakage when surrounding tissues may be mildly inflamed
- **Bursal Distention**
  - Inflammation of lining of bursae
  - Synovial bursae: Constant synovial-lined bursae, which occur in defined anatomic locations
  - Adventitial bursae: Non-synovial-lined bursae that are acquired due to friction between opposing parts
  - Bursae not seen on US unless distended with fluid
  - Most bursae are accessible to US
  - US facilitates image-guided aspiration or injection
  - Bursitis is common, but infective bursitis is uncommon
  - Chronic bursitis is usually associated with wall thickening & internal debris
  - Hemorrhagic bursitis can occur after trauma or due to underlying coagulopathy
  - Baker cyst = distended semimembranous-gastrocnemius bursa

Helpful Clues for Less Common Diagnoses

- **Abscess**
  - Usually in immunosuppressed or at-risk patients
  - Majority are hypoechoic; some are hyperechoic if content is viscous
    - Look for mobile echoes within lesion on real-time imaging
    - Surrounding edema or inflammation with peripheral hyperemia
  - Posterior enhancement is characteristic
- **Hematoma**
  - Start to visibly liquefy after 1 week
    - Can be complicated by superimposed infection & show hyperemia
    - Organizing hematoma may also show internal vascularity
- **Seroma**
  - Occurs following tissue disruption due to surgery or trauma
  - Do not occur spontaneously
- **Baker Cyst**
  - Fluid-filled sac with neck arising through interspace between medial belly gastrocnemius & semimembranosus tendon
  - Speech-bubble configuration
- **Dermoid/Implantation Dermoid**
  - Implantation of epidermal fragments into subdermal tissues by penetrating injury
  - Epidermis continues to grow & forms cyst lined with stratified squamous epithelium & filled with keratin
- **Parameniscal Cyst**
  - Fluid squeezed from peripheral part of meniscus
  - Usually well defined & filled with hypoechoic, gelatinous-type fluid
  - Normally associated with meniscal tear, nearly always horizontal tear
  - Meniscal tear may not be seen occasionally
- **Metastasis**
  - Metastasis can be cystic or necrotic
- **Vascular Anomaly**
  - Vascular tumor (neoplastic)
    - Benign: e.g., hemangioma (proliferation → stabilization → involution)
    - Locally aggressive or borderline: e.g., kaposiform hemangioendothelioma
    - Malignant: e.g., angiosarcoma

- Vascular malformation (nonneoplastic)
  - Capillary, venous, lymphatic, arteriovenous, or combined depending on predominant vascular pattern
  - Best assessed with color & pulsed Doppler US
  - Can change shape & size due to thrombosis, hemorrhage, or infection
  - Microvasculature looks like supporting stroma as US cannot resolve microvessels
- Each vascular malformation type may be focal or diffuse, ± ectatic vessels, & ± variable microvascular component

- **Lymphatic Malformation**
  - Uni-/multilocular, anechoic, compressible cystic lesion with thin walls & intervening septa
  - No vascularity demonstrated
- **Fat Necrosis**
  - Fat trauma → fat inflammation → fat necrosis → liquefaction
    - Liquefaction occurs with large areas of fat necrosis
  - ± calcification due to fatty acids combining with calcium to form calcium soap
- **Schwannoma**
  - Most peripheral schwannomas have small amount (≤ 10%) of myxoid tissue or fluid component
    - Minority of peripheral schwannomas have larger (> 30%) myxoid tissue or fluid component
    - Cystic component due to necrosis, hemorrhage, or fluid accumulation
  - Cystic schwannoma tends to be larger & more compressive with shorter duration of neurologic symptoms
  - 50% have visible neural continuity
  - Nerve often shows slight enlargement just proximal & distal to tumor
- **Intramuscular Myxoma**
  - Occurs in muscle
  - Well-defined, roundish, hypoechoic mass ± surrounding muscle compression or atrophy ± echogenic colloid aggregates in tumor matrix
  - ± myxoid material leakage proximally & distally
- **Sarcoma**
  - Appear cystic if fluid, hemorrhagic, necrotic, or myxoid component
    - Myxoid sarcomas include myxoid liposarcoma, myxofibrosarcoma, myxoid chondrosarcoma, myxoid leiomyosarcoma
- **Lymph Node**
  - Cystic nodes are most commonly due to tumor necrosis or tuberculosis
  - Lymphoma nodes may also appear cystic
- **Venous Varix**
  - Focal dilatation of vein
- **Aneurysm**
  - Popliteal aneurysm is most common appendicular aneurysm
    - Associated with older age, male sex, & atherosclerosis
- **Pseudoaneurysm**
  - Associated with trauma, vascular surgery, or impingement from adjacent structure, e.g., pedunculated osteochondroma
  - Usually hypoechoic or anechoic structure
  - Thrombus may be seen in lumen
  - Neck connects pseudoaneurysm to artery
  - Characteristic to-&-fro spectral pattern at narrow aneurysm neck
  - Characteristic yin-yang sign on color Doppler imaging
    - Swirling flow seen as different color signals within lesion
  - Lumen may not be fully filled with color due to partial thrombosis
- **Geyser Lesion**
  - Cystic lesion overlying degenerated acromioclavicular joint with underlying chronic massive rotator cuff tear → "rotator cuff arthropathy"
  - Fluoroscopic arthrography: Glenohumeral joint fluid → subacromial-subdeltoid bursa → erupts through acromioclavicular joint (geyser sign)
  - Mimics ganglion cyst if not aware of underlying pathology

Ganglion Cyst

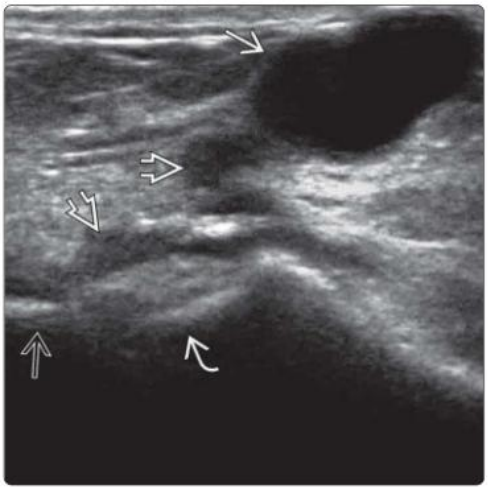

Ganglion Cyst

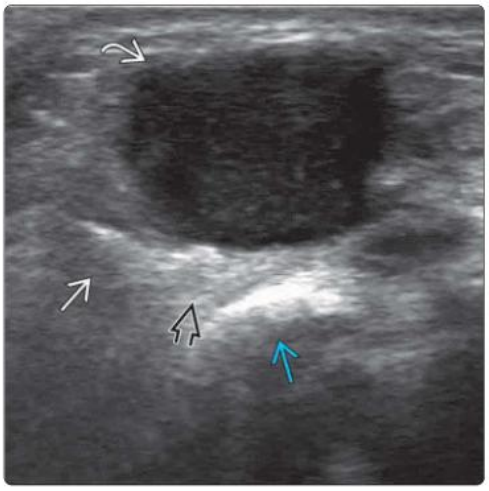

(Left) *Longitudinal US shows a ganglion cyst on dorsum of radioscaphoid articulation. The tortuous stalk extends deeply toward the radioscaphoid articulation. The distal radius and scaphoid are normal.* **(Right)** *Transverse US shows a more atypical, mildly echogenic ganglion cyst over dorsoradial wrist. It overlies intact dorsal component of scapholunate ligament, compatible with a dorsal capsuloligamentous scapholunate septum (DCSS) cyst. The normal scaphoid and lunate are shown.*

Bursal Distention

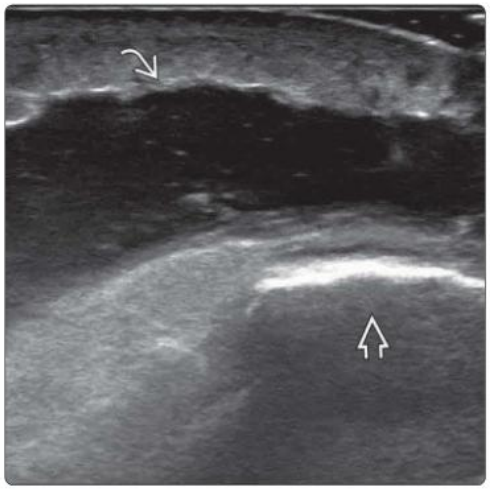

Bursal Distention

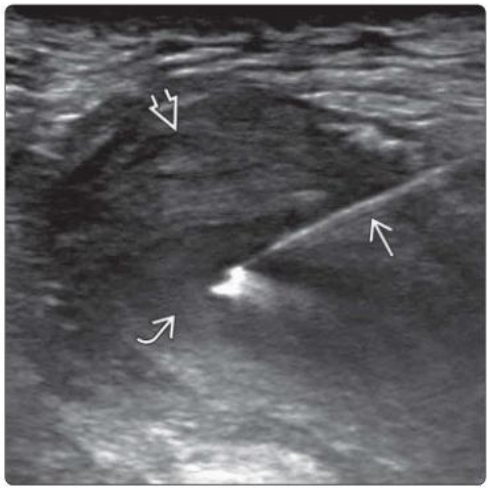

(Left) *Transverse US of the knee shows distention of the prepatellar bursa. US-guided aspiration yielded pustular fluid, compatible with infective bursitis. The normal patella is shown.* **(Right)** *Transverse US at the buttock shows fluid distention of the ischial bursa. The bursal wall is severely thickened with no increased vascularity on color Doppler, compatible with a chronic bursitis. US-guided aspiration followed by steroid injection was performed. Patient's symptoms largely resolved subsequently.*

Abscess

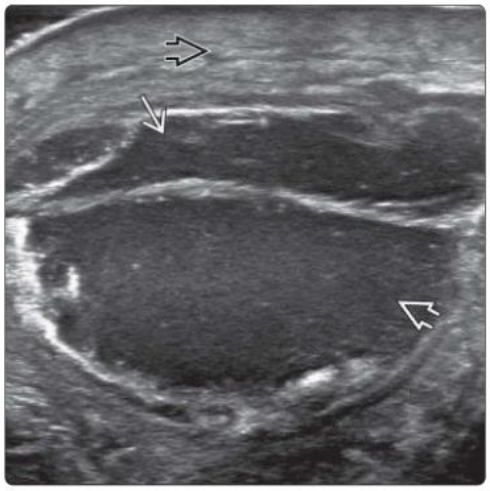

Hematoma

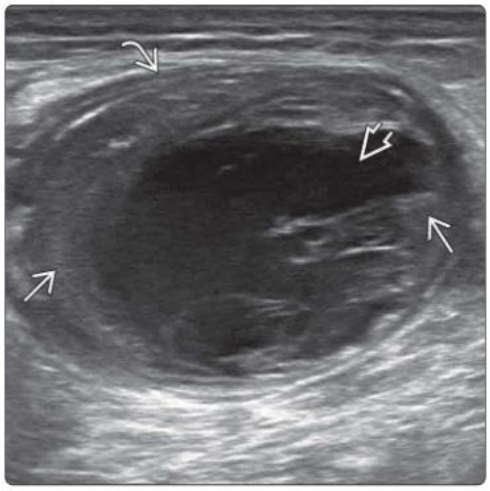

(Left) *Transverse US of midshin in a diabetic patient shows a deep subcutaneous and subfascial abscess collection containing low-level echoes. Moderate subcutaneous edema is present with increased vascularity on color Doppler US (not shown), compatible with acute cellulitis.* **(Right)** *Transverse US of posterior thigh shows an intramuscular hematoma in a patient on anticoagulation for atrial fibrillation. Organized echogenic clot, septations, and liquefied hypoechoic areas are present.*

Seroma

Baker Cyst

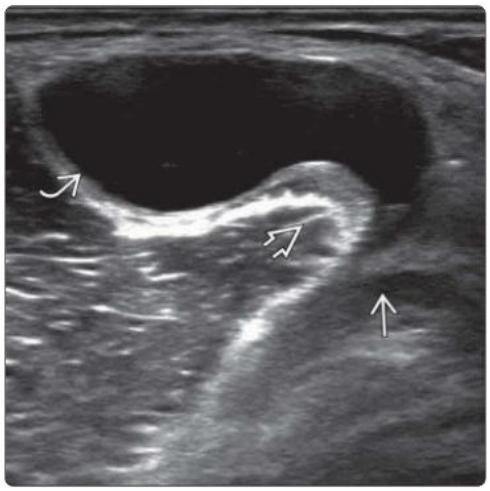

(Left) *Transverse US of the proximal thigh in a patient 1 month following hip replacement shows a large, cystic collection located in the deep subcutaneous region. Aspiration confirmed sterile fluid.* **(Right)** *Transverse US at the medial popliteal fossa shows a typical Baker cyst with a speech-bubble configuration. The neck of the cyst extends between the medial belly of the gastrocnemius muscle and the semimembranosus tendon.*

Dermoid/Implantation Dermoid

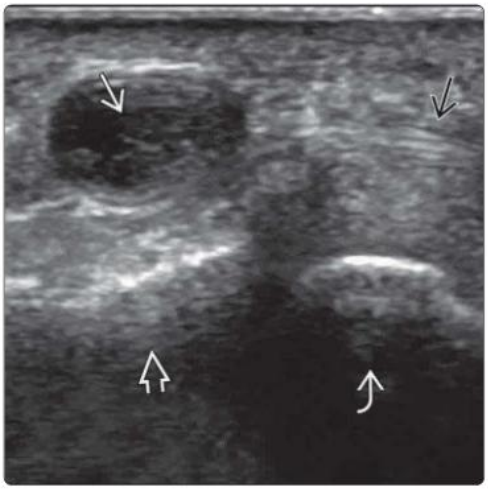

Parameniscal Cyst

(Left) *Longitudinal US shows a cystic implantation dermoid ⇨ in the finger pulp. The lesion lies superficial to the flexor digitorum profundus tendon ⇨. Note the base of the distal phalanx ⇨ and the head of the middle phalanx ⇨.* **(Right)** *Longitudinal US shows a medium-sized parameniscal cyst ⇨ between the distal femur ⇨ and the proximal tibia ⇨ at the anterolateral aspect of the knee joint. The communication of the cyst with a meniscal tear is not seen on this US, though it was apparent on other images and on MR.*

Parameniscal Cyst

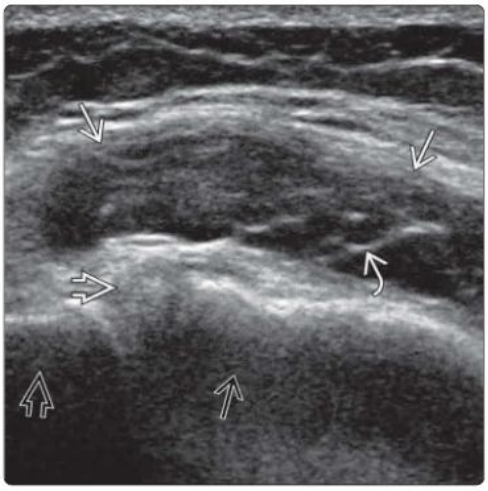

Metastasis

(Left) *Longitudinal US shows a large parameniscal cyst ⇨ on the medial side of the knee. There is septation ⇨ within the cyst. Note the periphery of the medial meniscus ⇨ between the distal femur ⇨ and the proximal tibia ⇨.* **(Right)** *Longitudinal US of the chest wall in a patient with high-grade conventional osteosarcoma of the knee shows an irregular, biopsy-proven, subcutaneous, cystic metastatic nodule ⇨.*

Vascular Anomaly

Lymphatic Malformation

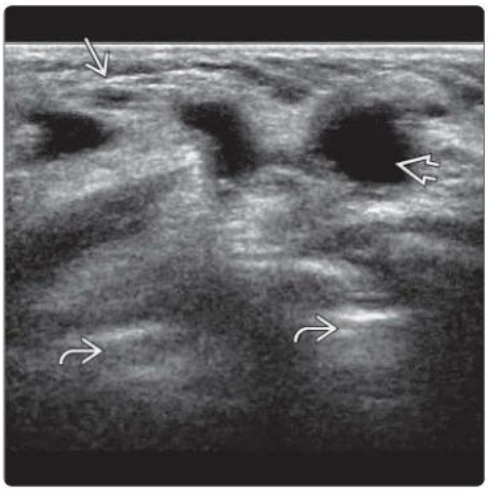

(Left) *Transverse US shows subcutaneous, tortuous, hypoechoic, distended vascular channels ⇨, which were compressible. Minimal internal vascularity was present on color Doppler US (not shown). Features are compatible with a slow-flow vascular malformation.* **(Right)** *Longitudinal US of the chest wall shows a poorly defined lymphatic malformation ⇨ with a cystic component ⇨ and poorly defined supporting stroma. The underlying ribs ⇨ are normal.*

(Left) *Longitudinal US of the buttock 1 month following blunt trauma shows a well-defined, largely cystic, subcutaneous mass ➔ with early calcification ➔, consistent with liquefied fat necrosis.* **(Right)** *Longitudinal US of the supraclavicular region shows a medium-sized cystic schwannoma ➔ of the C7 nerve root ➔. Layered hemorrhage ➔ and fibrous septi ➔ are present within the tumor. A cystic component is a common feature of nerve sheath tumors. Cystic schwannomas are also known as ancient schwannomas.*

Fat Necrosis

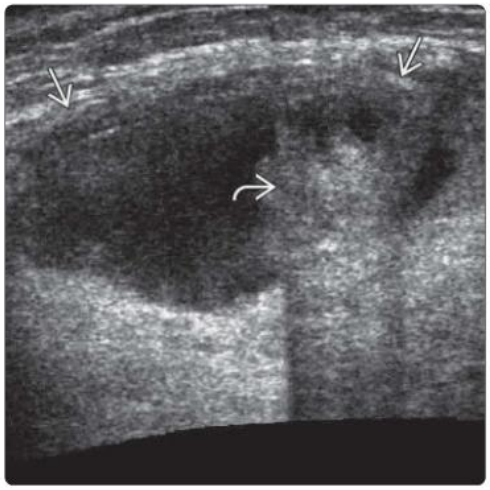

Schwannoma

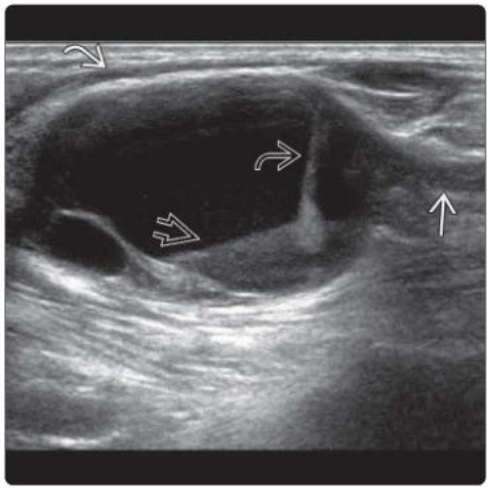

(Left) *Transverse US shows a well-defined myxoid tumor ➔ within the thigh muscle. Many small, fine, internal echoes due to colloid aggregates ➔ are present. Histology confirmed a myxoma.* **(Right)** *Longitudinal US shows a large subfascial mass ➔ on the medial aspect of the knee alongside the proximal tibia ➔. There are cystic areas ➔ present within the tumor. US-guided biopsy revealed an undifferentiated sarcoma.*

Intramuscular Myxoma

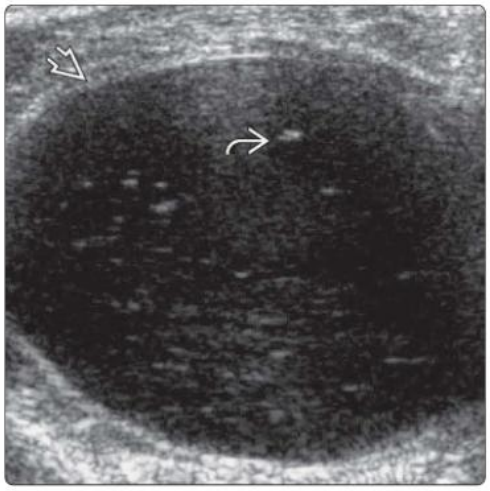

Sarcoma

(Left) *Transverse US of the groin region shows a large, metastatic, inguinal node ➔ with a central, cystic, necrotic area ➔ from an alveolar soft part sarcoma of the thigh.* **(Right)** *Longitudinal US shows a venous varix ➔ on the dorsal aspect of the wrist. There is partially stagnant flow ➔ within the varix, which mimics a hypoechoic mass. Dynamic US with compression/decompression revealed movement within this stagnant flow area. The distal radius ➔ is normal.*

Lymph Node

Venous Varix

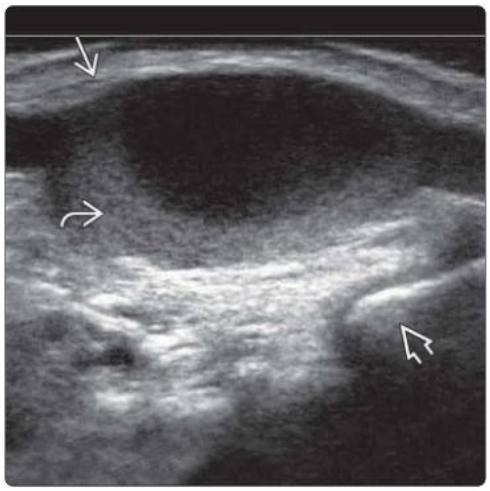

Pseudoaneurysm

Pseudoaneurysm

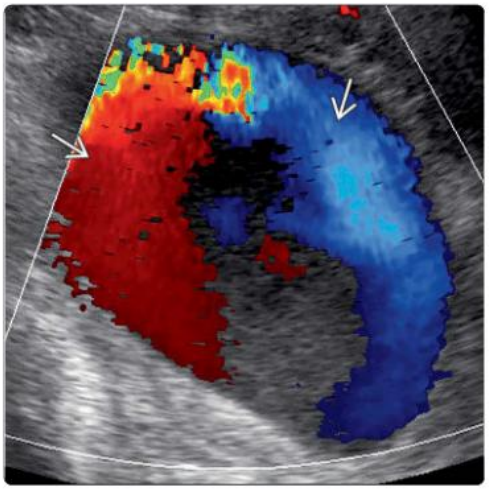

(Left) *Transverse US shows a large, cystic lesion along the path of the superficial femoral artery in the distal thigh medially.* **(Right)** *Transverse US of the same patient shows a typical yin-yang sign. Features are compatible with a pseudoaneurysm of the superficial femoral artery. A to-and-fro spectral pattern was present at the pseudoaneurysm neck (not shown).*

Geyser Lesion

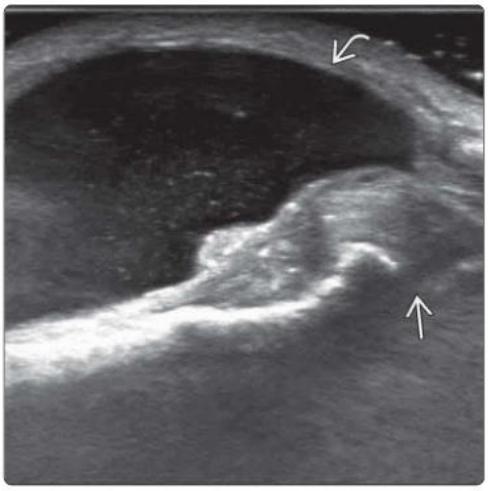

Geyser Lesion

(Left) *Transverse US shows a well-defined, cystic lesion superior to the acromioclavicular joint, mimicking a ganglion cyst.* **(Right)** *Clinical photograph of the same patient shows a corresponding lump superior to the acromioclavicular joint. This patient also has severe muscle wasting at the supraspinatus and infraspinatus fossae (not shown). This should raise the suspicion of a geyser lesion and prompt scanning of the rotator cuff tendons to look for a massive tear, which was present in this patient.*

Geyser Lesion

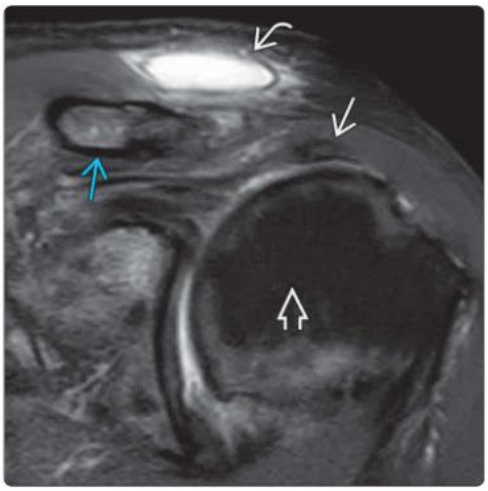

Geyser Lesion

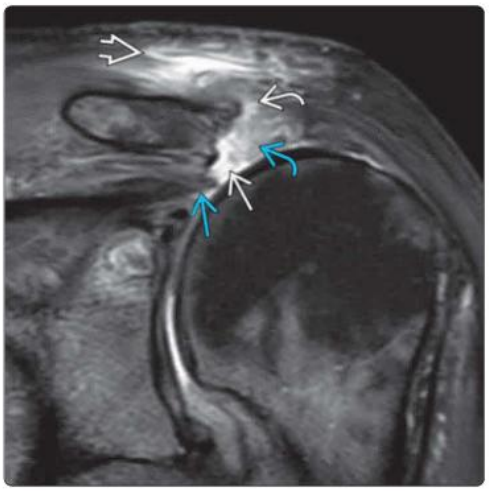

(Left) *Coronal PD FS MR shows the geyser lesion as a well-defined, cystic mass superior to the acromioclavicular joint. The humeral head is superiorly migrated, abutting an "acetabulized" acromion process. The clavicle is normal.* **(Right)** *Coronal PD FS MR more posteriorly shows a retracted torn supraspinatus tendon. The acromioclavicular joint capsule is disrupted with fluid tracking superiorly from the glenohumeral joint, through the acromioclavicular joint, into the geyser lesion.*

DIFFERENTIAL DIAGNOSIS

Common

- Granuloma
- Venous Vascular Malformation
- Gout or Pseudogout

Less Common

- Neoplastic Cause
  - Pilomatricoma
  - Sarcoma
  - Soft Tissue Metastases
  - Nerve Sheath Tumor
  - Fibroma
  - Soft Tissue Chondroma
  - Calcifying Aponeurotic Fibroma
- Traumatic Cause
  - Fat Necrosis
  - Myositis Ossificans
  - Hematoma
  - Heterotopic Ossification
- Inflammatory or Infective Cause
  - Panniculitis
  - Dermatomyositis
  - Tuberculosis Abscess
  - Parasitic Infestation
  - Sclerodactyly
- Metabolic Cause
  - Tumoral Calcinosis
  - Calcific Myonecrosis

ESSENTIAL INFORMATION

Key Differential Diagnosis Issues

- Align transducer obliquely to obtain views not obscured by calcification
- Differential diagnoses
  - Clinical history, e.g., trauma would favor fat necrosis or myositis ossificans (MO)
  - Radiographs ± CT findings are helpful for assessing morphology of calcification
  - US features, e.g., size & location of soft tissue component, hard or soft calcification, vascularity

Helpful Clues for Common Diagnoses

- **Granuloma**
  - Most commonly located in subcutaneous tissues of buttock; frequently multiple
    - Often have previous subcutaneous injection at this site
  - Variable rim calcification → posterior acoustic shadowing
  - Well-defined, rounded, hypoechoic mass
    - Deep margin often not seen due to dense posterior acoustic shadowing
    - Width dimension is similar to depth dimension as lesion is rounded in appearance
    - Small to medium-sized (typically < 3 cm)
      - Adjacent granulomas may coalesce, leading to large, more lobulated appearance
  - Typically no hyperemia on color Doppler imaging
  - ± indentation of adjacent investing fascia or muscle when large
- **Venous Vascular Malformation**
  - Calcified phleboliths common but not invariable feature
    - Generally indicate slow-flow vascular malformation
    - Represent calcified thrombi
    - Small- to medium-sized phleboliths, depending on size of vein
      - Echogenic with acoustic shadowing
      - US more sensitive than radiographs
  - Typical features include vascular channels, compressibility, venous flow ± ill-defined margin
- **Gout or Pseudogout**
  - Located around joints, ligament, & fascial insertions
    - Gout → monosodium urate crystal deposits (tophi)
    - Pseudogout → hydroxyapatite crystal deposits
  - Soft tophi contain little mineralized component
    - Comet-tail artifacts due to crystal aggregates
  - Hard tophi are usually heavily mineralized
    - Dense posterior acoustic shadowing limits deep US assessment

Helpful Clues for Less Common Diagnoses

- **Pilomatricoma**
  - Benign skin neoplasm with differentiation towards hair matrix
  - Round, well-defined, heterogeneous, hypoechoic mass with partially calcified rim & posterior acoustic shadowing
    - Some lesions may be completely calcified
    - ± peripheral hypoechoic halo ± mild peripheral hyperemia on color Doppler
- **Sarcoma**
  - Benign & malignant soft tissue tumors may calcify
  - Calcification usually intrinsic to tumor, occasionally from bone infiltration
  - Synovial sarcoma is most common malignant soft tissue tumor to calcify; 50% calcify
  - Other sarcomas that contain foci of calcification include
    - Liposarcoma, undifferentiated pleomorphic sarcoma, extraskeletal osteosarcoma, leiomyosarcoma, alveolar soft part sarcoma
- **Soft Tissue Metastases**
  - Soft tissue metastases that contain foci of calcification usually arise from
    - Adenocarcinoma of colon, stomach, breast, or pancreas
    - Medullary carcinoma of thyroid & ovarian carcinoma
- **Nerve Sheath Tumor**
  - Calcification uncommon though more frequent in ancient schwannoma
- **Fibroma**
  - Discrete subcutaneous fibrous nodules may calcify or ossify
- **Soft Tissue Chondroma**
  - Often quite heavily calcified at periphery
    - Well-defined hypoechoic rim of cartilage visible beyond echogenic calcified front
- **Calcifying Aponeurotic Fibroma**
  - a.k.a. juvenile aponeurotic fibroma

- Locally aggressive fibroblastic tumor of children & young adults, usually located in hands & feet
  - Occur alongside dense fibrous connective tissue (fascia or periosteum)
  - May erode bone
- Nodular or ill-defined, infiltrating mass with fine, stippled calcification
  - ~ 50% recur after resection

- **Fat Necrosis**
  - Subcutaneous fat is prone to trauma, particularly on anterolateral aspect of thigh, lateral aspect of arm, & gluteal region
  - Blunt subcutaneous trauma → injury & necrosis of fat cells
    - → focal swelling & edema of subcutaneous tissues
    - → reparative change with mild localized hyperemia on color Doppler imaging
    - → encapsulated fat necrosis ± heterotopic ossification ± fibrosis
  - More severe forms of fat necrosis tend to undergo calcification & ossification
  - Other typical features: Hyperechoic fat containing hypoechoic spaces (infarcted fat)
- **Myositis Ossificans**
  - Pseudoinflammatory tumor of muscle; 3 types
    - MO progressiva due to hereditary disorder in children
    - Traumatic MO circumscripta seen in young patients following trauma
    - Nontraumatic MO circumscripta also in young patients, though no trauma history
      - Sometimes following burns with cerebrospinal disorder or hemophilia
  - Muscle tear with hemorrhage, then cystic transformation
    - 1st week: Heterogeneous, hypoechoic, irregular focus within muscle
    - 2-6 weeks: Peripheral echogenic rim
    - 2 months: Hyperechoic band adjacent & parallel to cortex or irregular echogenic foci
- **Hematoma**
  - Minority will show peripheral rim-like calcification
    - Feature of chronic hematoma
- **Heterotopic Ossification**
  - More common around hips or elbows, following trauma or joint replacement
- **Panniculitis**
  - Calcification or ossification of fat occurs following panniculitis (panniculitis ossificans)
    - Difficult to distinguish from fat necrosis
- **Dermatomyositis**
  - Especially large muscle groups, upper > lower limbs
  - Typical feature is diffuse calcification of symptomatic muscles
- **Tuberculosis Abscess**
  - "Cold abscess" with insidious onset
  - Contains calcifying caseating granulomatous material
- **Parasitic Infestation**
  - Cysticercosis
    - Multiple intermuscular "rice grain" calcifications oriented along direction of muscle fibers
  - Dracunculiasis (Guinea worm)
    - Small, crescentic calcifications in feet, hands, groin
- **Sclerodactyly**
  - Subcutaneous & periarticular calcification, skin tightening, subcutaneous atrophy, acroosteolysis
  - Associated with scleroderma, graft-vs.-host & Raynaud disease
- **Tumoral Calcinosis**
  - Calcium deposits in periarticular (> shoulder, hip, & elbow) soft tissues
  - Lobulated, well-defined, calcified mass along extensor surfaces of large joints
  - Seen in renal failure ± familial component
- **Calcific Myonecrosis**
  - Posttraumatic condition in which single muscle is replaced by enlarging mass with central liquefaction & peripheral calcification
  - ± decades between trauma & symptom onset
  - Typical feature is muscle calcification at anterior compartment of leg

Granuloma

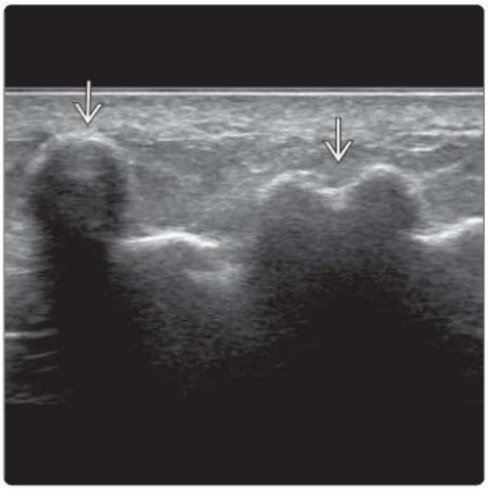

Venous Vascular Malformation

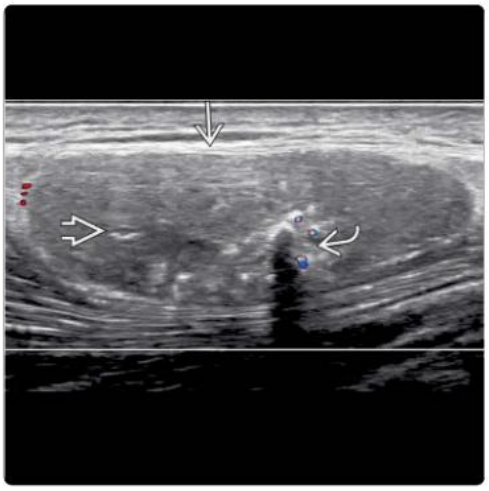

(Left) *Longitudinal oblique US of buttock shows 2 small, subcutaneous injection granulomas ⇨. They are heavily calcified with posterior acoustic shadowing obscuring the internal detail of the lesion.* **(Right)** *Longitudinal US shows an oval mass in the superficial aspect of the rectus femoris muscle ⇨. Scattered echogenic foci, consistent with phleboliths ⇨, and mild posterior acoustic shadowing are present. Mild color Doppler flow ⇨ was present, compatible with a slow-flow venous vascular malformation.*

Gout or Pseudogout

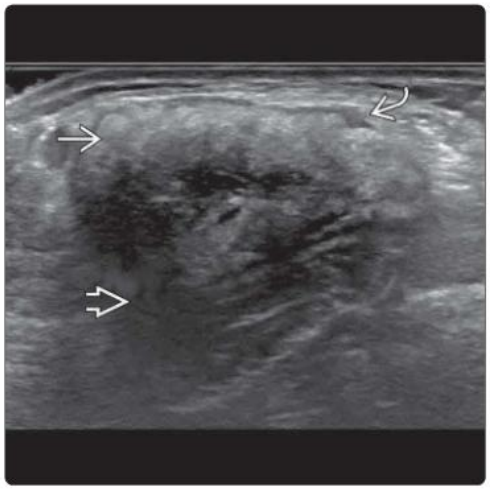

Sarcoma

(Left) *Longitudinal oblique US of popliteal fossa shows lobulated, echogenic gouty tophus due to crystal aggregates with thin, hypoechoic rim (wet lump of sugar appearance). There is only mild posterior acoustic shadowing. This is soft tophus. Hard tophi show more severe acoustic shadowing.* **(Right)** *US shows a large tumor mass on lateral aspect of knee. Multiple foci of calcification are present within mass with severe posterior acoustic shadowing. Biopsy confirmed parosteal osteosarcoma.*

Soft Tissue Metastases

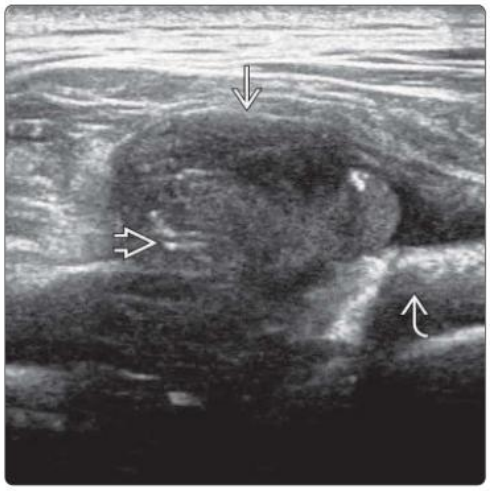

Nerve Sheath Tumor

(Left) *Transverse US of a paraspinal mass shows a discrete hypoechoic mass with several small, calcific foci adjacent to the transverse process. Biopsy showed metastatic squamous cell carcinoma from a known lung primary.* **(Right)** *Longitudinal US of a mass on the lateral aspect of the leg, which had been slowly growing for 10 years, shows a large peroneal nerve sheath tumor with small foci of calcification. The fibula is deep to the tumor.*

Soft Tissue Chondroma

Fat Necrosis

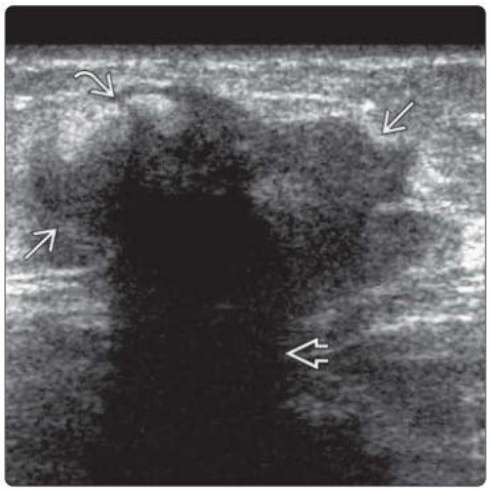

(Left) *Transverse US of the wrist shows a large, heavily calcified mass with severe posterior acoustic shadow. Biopsy confirmed a chondroma.* **(Right)** *Transverse US of a buttock shows an area of fat necrosis seen as a well-defined, subcutaneous, hypoechoic mass. There is prominent calcification with dense acoustic shadowing.*

Fat Necrosis

Myositis Ossificans

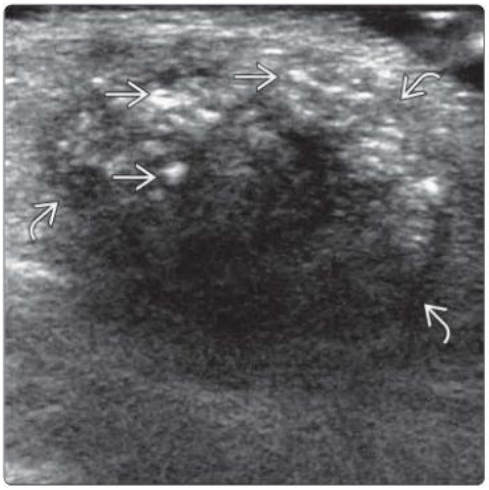

(Left) *Longitudinal US of a nontraumatic, tender leg nodule shows a hypoechoic, heavily calcified ➡, subcutaneous nodule. Color Doppler imaging (not shown) showed minimal perilesional hyperemia. Histology was compatible with panniculitis ossificans.* **(Right)** *Transverse US of pilomatricoma shows a heterogeneous subcutaneous mass containing multiple lumpy calcifications ➡ associated with moderate posterior shadowing. There is a thin, hypoechoic peripheral rim ➡.*

Myositis Ossificans

Hematoma

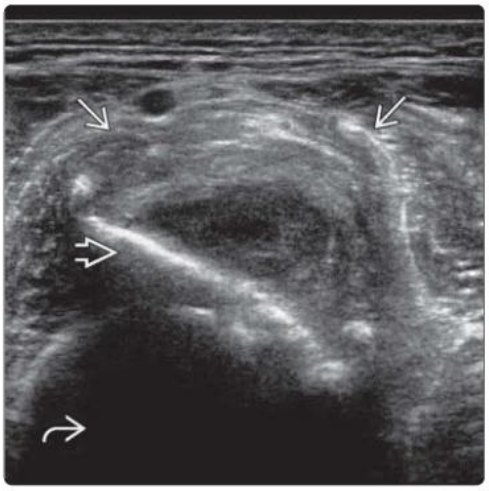

(Left) *Transverse US shows a well-calcified mass ➡ within the brachialis muscle ➡. Features were suspicious of myositis ossificans. CT-guided biopsy revealed benign skeletal muscle with fibrosis and ossification, with both lamellar and wavy bony components. Features are compatible with myositis ossificans.* **(Right)** *Transverse US of the midfemur shows a moderate-sized chronic hematoma ➡ with dystrophic calcification ➡ adjacent to the femur ➡. The center of the hematoma seems partially liquefied.*

Tuberculosis Abscess

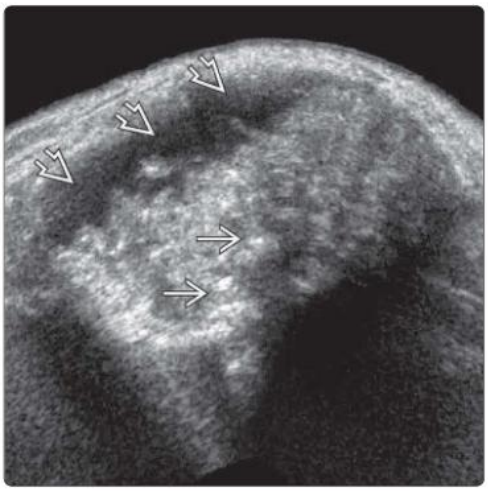

Tumoral Calcinosis

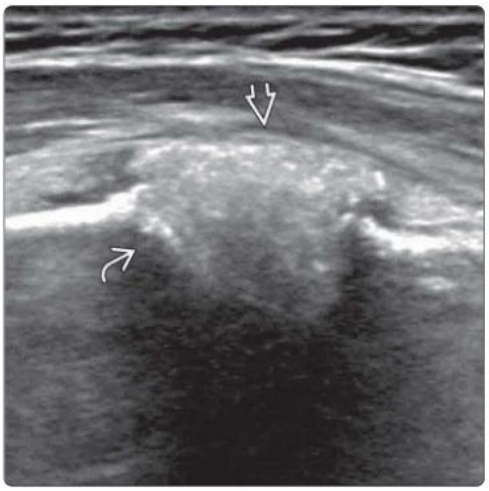

(Left) *Transverse US shows a large, partially liquefied ➡ soft tissue mass in the thigh with dependent echogenic debris ➡. US-guided aspiration for culture confirmed a TB abscess.* **(Right)** *Longitudinal US shows the edge of a larger calcified mass in an older woman with renal osteodystrophy and proximal arm swelling. Note tumoral calcinosis ➡ with cortical erosion ➡. Bone erosion can occur with tumoral calcinosis at nutrient artery sites.*

DIFFERENTIAL DIAGNOSIS

Common

- Vascular Anomaly
- Nerve Sheath Tumor
- Soft Tissue Sarcoma

Less Common

- Glomus Tumor
- Granulation Tissue or Inflammatory Mass
- Vascular Leiomyoma
- Pilomatricoma
- Soft Tissue Metastases
- Fibromatosis
- Giant Cell Tumor of Tendon Sheath
- Panniculitis
- Focal Myositis
- Lymph Nodes
- Lymphoma
- Organizing Hematoma

ESSENTIAL INFORMATION

Key Differential Diagnosis Issues

- Vascularity can be assessed on grayscale, color Doppler, & power Doppler imaging
  - Grayscale useful for assessing slow venous flow
  - Color Doppler can assess flow direction but is less sensitive than power Doppler in detection of flow
    - Power Doppler does not assess flow direction
  - Spectral analysis analyzes flow pattern
- Minimal transducer pressure avoids effacing vasculature
- Note whether vascularity pattern is predominantly central or peripheral, organized or chaotic, or mixed pattern
- Color Doppler reflects blood flow (intravascular flow)
  - Contrast enhancement on MR or CT reflects tissue perfusion, which is dependent on blood flow, permeability, & interstitial flow

Helpful Clues for Common Diagnoses

- **Vascular Anomaly**
  - For all vascular anomalies, determine
    - Size & location of lesion
    - Predominant vascular type (arterial/venous/capillary)
    - Relative amount of vascular vs. stromal tissue
    - Presence of clots or phleboliths
    - Flow characteristics
    - Multiplicity of lesions
  - There are 2 main types of vascular anomaly: Vascular tumor & vascular malformation
  - Vascular tumor
    - Infantile hemangioma (presents after birth)
      - → proliferation → stabilization → involution
    - Congenital hemangioma (present at birth)
      - Rapidly involuting congenital hemangioma
      - Noninvoluting congenital hemangioma
      - Partially involuting congenital hemangioma
    - Tufted angioma & kaposiform hemangioendothelioma
    - Angiosarcoma
  - Vascular malformation (congenital but most are not evident at birth)
    - Growth is commensurate with patient growth
    - More rapid growth precipitated by puberty, pregnancy, trauma
    - 4 main types of vascular malformation with considerable overlap: Capillary, venous, lymphatic, & arteriovenous
- **Nerve Sheath Tumor**
  - Hypoechoic, typically fusiform-shaped
  - ± anechoic areas due to myxoid deposition
  - ± hyperechoic areas due to hemorrhage, calcification, or fibrosis
  - Posterior acoustic enhancement
  - Mild to moderate vascularity, which blanches with transducer pressure
    - Infrequently, no detectable vascularity
- **Soft Tissue Sarcoma**
  - Usually hypervascular & large
    - ± central necrosis ± hemorrhage
  - Occasionally hypo- or avascular
    - Particularly fibrosarcoma or liposarcoma
  - Alveolar soft part sarcoma may mimic vascular malformation on imaging

Helpful Clues for Less Common Diagnoses

- **Glomus Tumor**
  - Most common location: Distal extremities, especially subungual areas
    - Hypoechoic, hypervascular nodule between nail & cortex of distal phalanx
  - Arises from glomus body, which is arteriovenous shunt in dermis that contributes to temperature regulation
  - Glomus tumors arising outside of dermis that do not normally contain glomus cells
    - May arise from perivascular cells that can differentiate into glomus cells
    - Small, well-defined, hypoechoic, hypervascular mass
- **Granulation Tissue or Inflammatory Mass**
  - Hypoechoic, irregular tissue
  - Seen in low-grade infection, reparative scar tissue, or around foreign body
  - Usually moderately to highly vascularized
- **Vascular Leiomyoma**
  - Benign solitary smooth muscle neoplasm that most commonly occurs in subcutaneous soft tissues of lower extremity
    - 2/3 involve lower leg or ankle in close proximity to artery or vein
  - Well-defined smooth margin
  - Usually round or ovoid in shape with long axis parallel to extremity axis
  - Hypoechoic, homogeneous without perceivable capsule
  - Mild to moderate posterior enhancement
  - Hypervascular ± peripheral vascular convergence
- **Pilomatricoma**
  - Benign skin tumor arising from cells of hair matrix
  - Mass extending from dermal to subcutaneous tissues
  - Well-circumscribed, ovoid, heterogeneous, solid subdermal mass containing matrix calcification, intrinsic vascularity, & peripheral hypoechoic rim

  - Hypoechoic peripheral rim due to capsule
  - Intrinsic vascularity that may be peripheral, central, or mixed
- US appearances usually sufficiently characteristic to make diagnosis

- **Soft Tissue Metastases**
  - Manifestation of end-stage metastatic disease
  - US appearances are similar to soft tissue sarcoma, but metastases usually smaller than sarcoma
    - Metastases more painful than sarcomas
  - Adenocarcinoma is most common cell type
    - Carcinoma of breast & lungs most common primaries
  - Most common site: Lower limb muscles
    - Biopsy necessary to confirm diagnosis
- **Fibromatosis**
  - Localized infiltrative fibroproliferative tumor
    - a.k.a. desmoid tumor or aggressive fibromatosis
    - Proliferative fibroblastic & mature stages
    - Usually mildly hyperemic
- **Giant Cell Tumor of Tendon Sheath**
  - Most are eccentrically located to tendon & grow along tendon sheath
  - Hypoechoic, peritendinous in location
  - Moderately to highly vascular
- **Panniculitis**
  - Localized inflammation of subcutaneous fat due to infection, systemic inflammatory disorder, myeloproliferative disorder, pancreatic disease, drug hypersensitivity, or Weber-Christian disease
  - Localized area of altered echogenicity & thickening of subcutaneous fat
    - Early/active stage: Thickening & hyperechogenicity of subcutaneous fat with mild to moderate hyperemia
    - Chronic/inactive stage: Atrophy & hypoechogenicity of subcutaneous fat with little or no hyperemia
- **Focal Myositis**
  - Ill-defined hyper- or hypoechoic area in muscle with focal hyperemia
    - Underlying muscle architecture visible in early stages
  - Manifestation of generalized inflammatory arthropathy, such as Behçet disease
  - MR is more sensitive than US for diagnosis
- **Lymph Nodes**
  - Lymph node enlargement seen with reactive, infective, metastatic, or lymphomatous nodes
  - Degree & pattern of hypervascularity depends on etiology of nodal enlargement
  - Reactive, infective, & many lymphoma nodes show moderately increased hilar flow pattern
    - Elongated shape, preservation of central fatty hilum, smooth border with absence of matting or necrosis
    - Tuberculous nodes may show necrosis, calcification, ± capsular vascularity
  - Malignant nodes show rounded shape, obliteration of central fatty hilum ± necrosis ± extracapsular spread with matting
    - Variable capsular vascularity or mixed hilar & capsular flow pattern
- **Lymphoma**
  - Classified as Hodgkin or non-Hodgkin lymphoma
    - Non-Hodgkin lymphoma classified as T-cell or B-cell neoplasms
  - 30% of lymphoma is extranodal with most common musculoskeletal involvement being bone & muscle
  - Involvement of superficial tissues uncommon
    - Subcutaneous panniculitis-like T-cell lymphoma is uncommon type of peripheral T-cell lymphoma
  - Moderate to high vascularity
- **Organizing Hematoma**
  - Hematoma organizes through fibroblastic proliferation, endothelial ingrowth, phagocytosis, & reabsorption
  - Imaging appearances vary with chronicity
    - History of trauma, bleeding diathesis, involvement of superficial tissue or overlying bony prominence
    - Acute: Well-defined, hyperechoic mass with multilaminated whorled appearance, small cystic areas, minimal or no hyperemia
    - Chronic: Fibrous capsule with variable peripheral & central vascularity, may grow

Vascular Anomaly

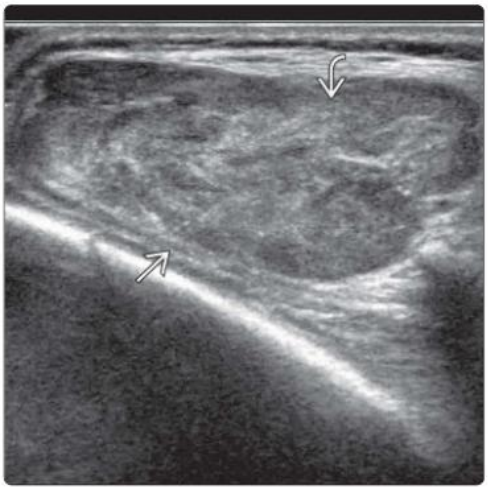

Vascular Anomaly

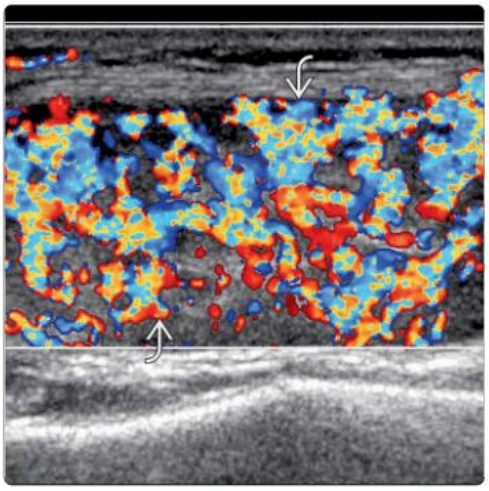

(Left) *Transverse US shows a well-defined, lobulated soft tissue mass ⇨ with predominant fatty stroma ⇨ in the cheek of an infant. There are only a few visible vascular channels evident.* **(Right)** *Longitudinal color Doppler US of the same lesion shows a high-flow vascular anomaly ⇨. Clinical course was consistent with a high-flow infantile hemangioma. Most of the arteries are too small to be resolved on grayscale US.*

Nerve Sheath Tumor

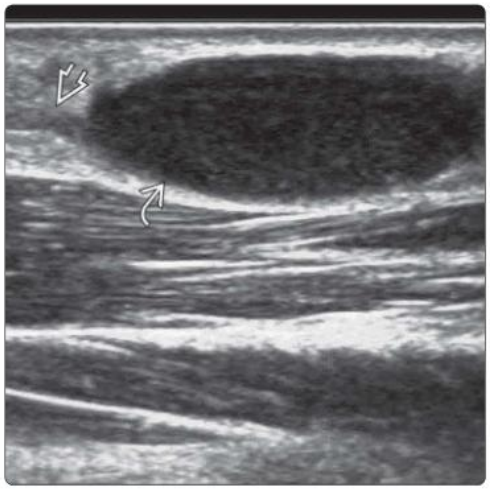

Nerve Sheath Tumor

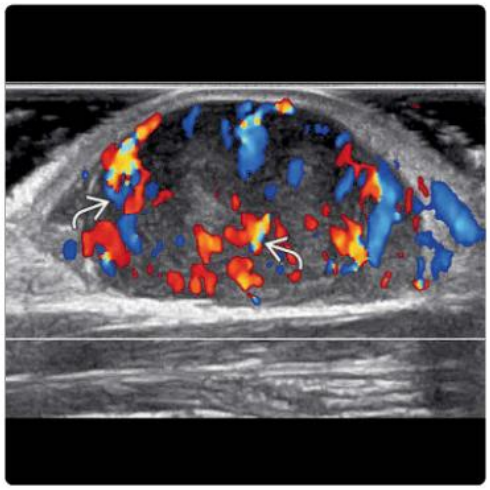

(Left) *Longitudinal US shows a well-defined, subcutaneous hypoechoic mass ⇨ with mild posterior acoustic enhancement and thickened nerve end ⇨, in keeping with a nerve sheath tumor arising from a subcutaneous nerve. Only 50% of nerve sheath tumors have demonstrable neural continuity.* **(Right)** *Transverse color Doppler US of a nerve sheath tumor shows a high degree of disorganized vascularity ⇨.*

Soft Tissue Sarcoma

Soft Tissue Sarcoma

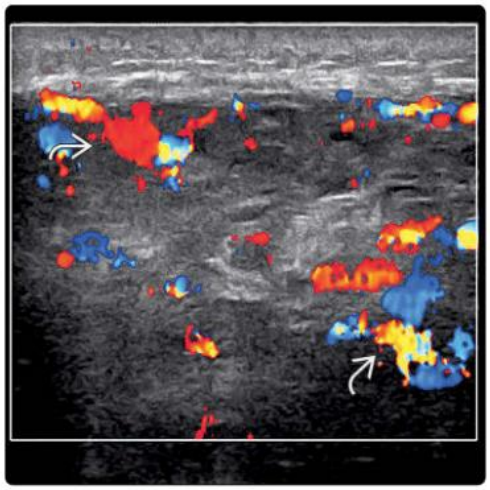

(Left) *Transverse US using a 7.5-MHz transducer shows a large soft tissue mass ⇨ with multiple cystic spaces ⇨ in the anterior muscle compartment of the thigh, closely abutting the femur ⇨.* **(Right)** *Transverse color Doppler US of the same tumor using a high-frequency transducer shows moderate intratumoral hyperemia ⇨. This solid component was targeted for percutaneous biopsy. Histology revealed a high-grade pleomorphic spindle cell sarcoma.*

Glomus Tumor

Glomus Tumor

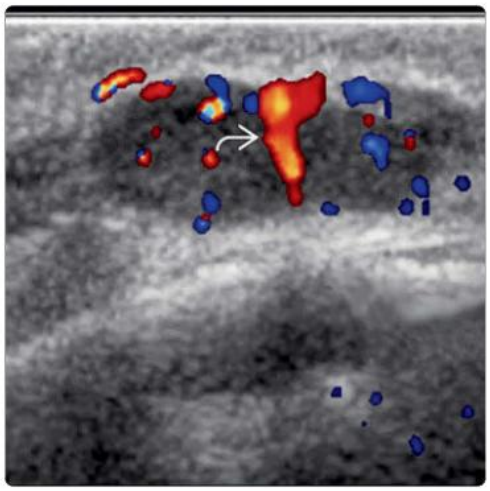

(Left) *Longitudinal US of a patient with a painful nodule in the upper limb shows a well-defined, hypoechoic mass ⇨ in the subcutaneous soft tissue.* **(Right)** *Longitudinal color Doppler US of the same patient shows moderate intratumoral hyperemia ⇨. The lesion was excised, and histology revealed a glomus tumor.*

Granulation Tissue or Inflammatory Mass

Granulation Tissue or Inflammatory Mass

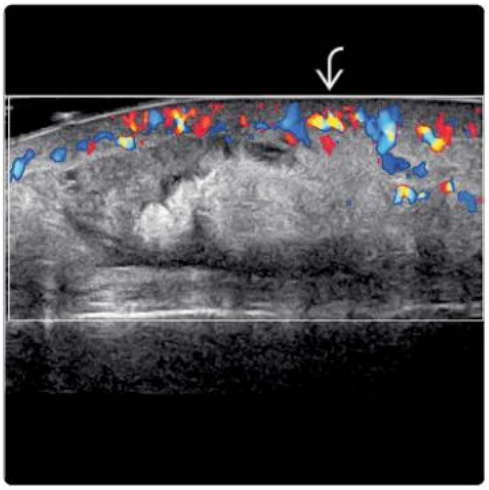

(Left) *Longitudinal US of the leg in a patient with clinically suspected shin infection shows a large, subcutaneous mass ⇨ with marked surrounding edema. There are hypoechoic areas ⇨ within the affected area, but no discrete liquefaction is present.* **(Right)** *Longitudinal color Doppler US of the same lesion shows a moderate degree of marginal hyperemia ⇨ due to active soft tissue inflammation. Percutaneous biopsy revealed a chronic inflammatory granulomatous mass, most likely due to tuberculosis.*

Vascular Leiomyoma

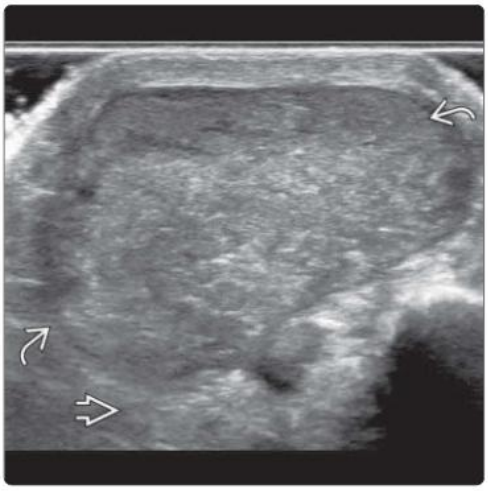

Vascular Leiomyoma

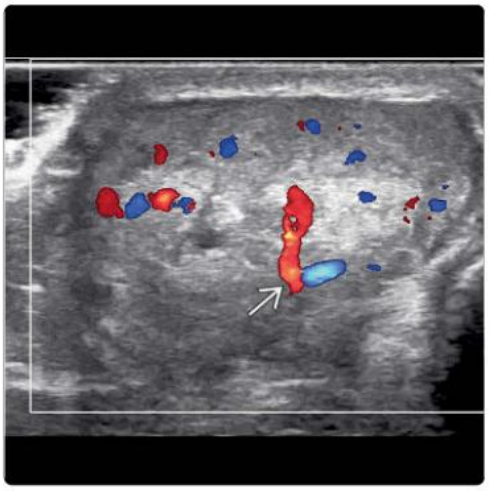

(Left) *Transverse US of the medial aspect of the big toe shows a well-defined, hypoechoic, subcutaneous mass ⇨ with mild posterior enhancement ⇨.* **(Right)** *Transverse color Doppler US of the same tumor shows mild to moderate central vascularity. A few vessels converge to a point at the tumor periphery ⇨. US-guided biopsy was performed. Histology revealed vascular leiomyoma. Vascular convergence is an infrequent, only moderately specific, sign of vascular leiomyoma.*

Pilomatricoma

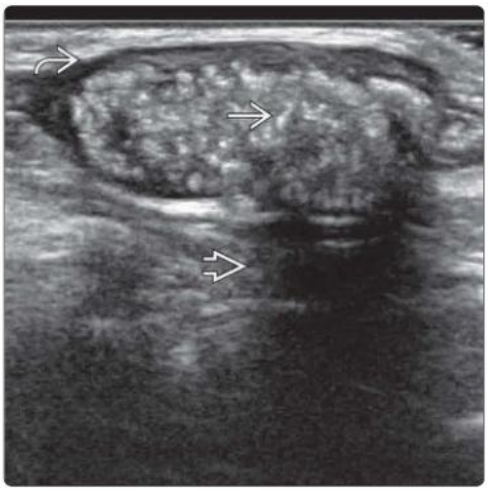

Pilomatricoma

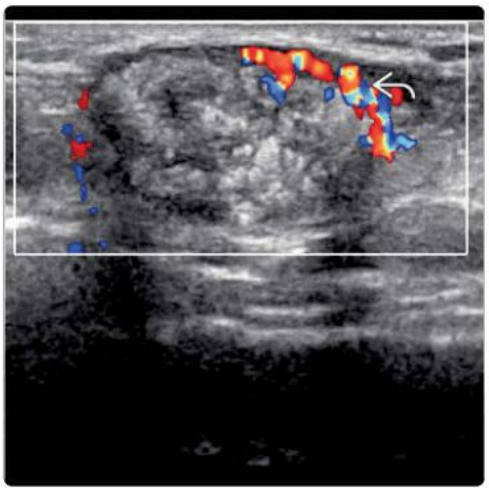

(Left) *Longitudinal US shows a well-defined, hypoechoic pilomatricoma with foci of matrix calcification ⇨, mild posterior shadowing ⇨, and a hypoechoic peripheral rim ⇨. Pilomatricoma are more common in children.* **(Right)** *Longitudinal color Doppler US of the same tumor shows mild to moderate peripheral vascularity ⇨.*

Soft Tissue Metastases

Soft Tissue Metastases

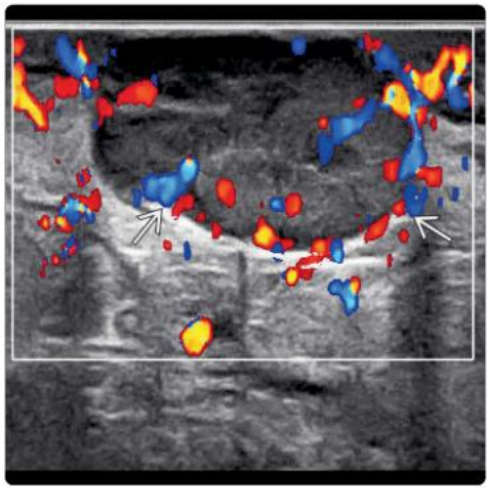

(Left) *Longitudinal US shows a well-defined, oval, subcutaneous metastasis in the thigh region in a patient with heel melanoma. Melanoma metastases are typically markedly hypoechoic and associated with moderate posterior acoustic enhancement. Note the small, cystic areas within the mass. There is no tail or string sign.* **(Right)** *Longitudinal power Doppler US of the same tumor shows moderate to high intratumoral hyperemia with a chaotic, mainly peripheral vascular pattern.*

Fibromatosis

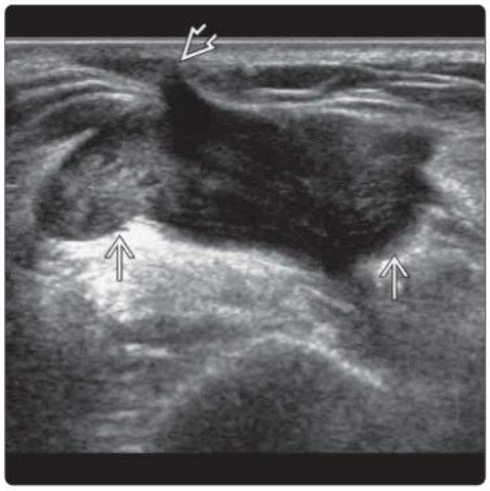

Fibromatosis

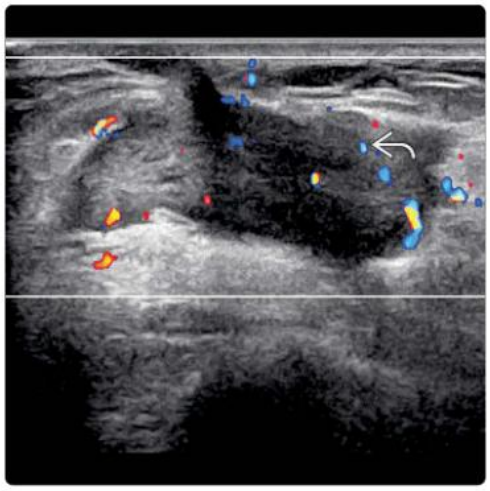

(Left) *Transverse US shows an irregular, hypoechoic, intramuscular soft tissue mass in the arm region due to fibromatosis. There is a band of tumor extending toward the skin.* **(Right)** *Transverse color Doppler US shows a mild degree of hyperemia within this area of fibromatosis. Note characteristic hypoechoic appearance and irregular configuration of fibromatosis. Most fibromatosis tumors show minimal to mild hyperemia on color Doppler imaging. Vascularity reflects proliferation while lack of vascularity reflects inactivity.*

Giant Cell Tumor of Tendon Sheath

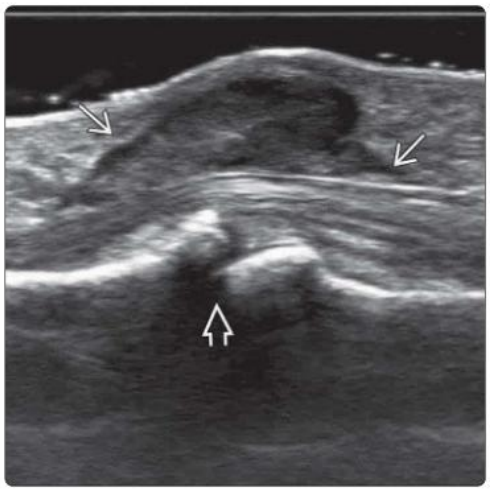

Giant Cell Tumor of Tendon Sheath

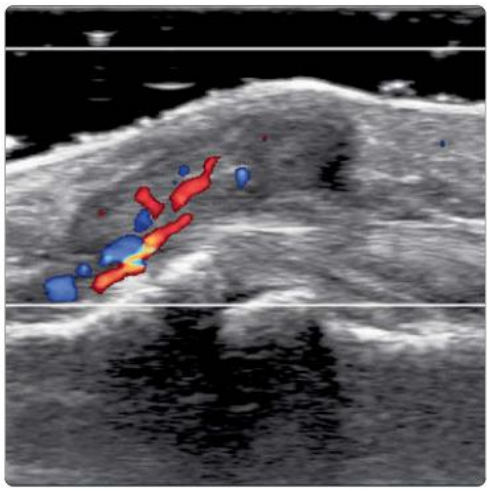

(Left) *Longitudinal US shows a lobulated, hypoechoic soft tissue mass closely abutting the flexor tendons overlying the proximal interphalangeal joint of the middle finger. Flexor tendons were partially encased by the tumor (not shown).* **(Right)** *Longitudinal color Doppler US of the same tumor shows moderate intrinsic tumoral vascularity. The tumor was excised. Histology revealed giant cell tumor of tendon sheath. This tumor is usually moderately to highly vascular though occasionally may be avascular.*

Focal Myositis

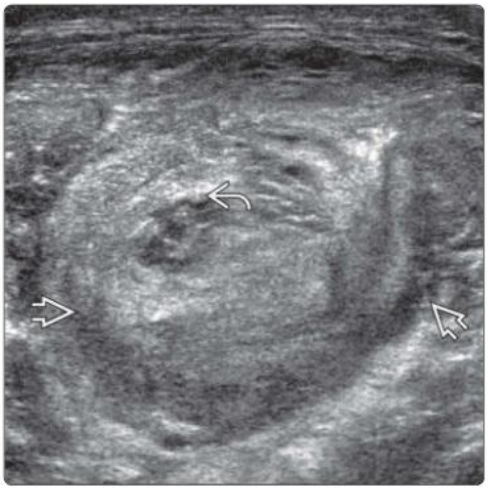

Focal Myositis

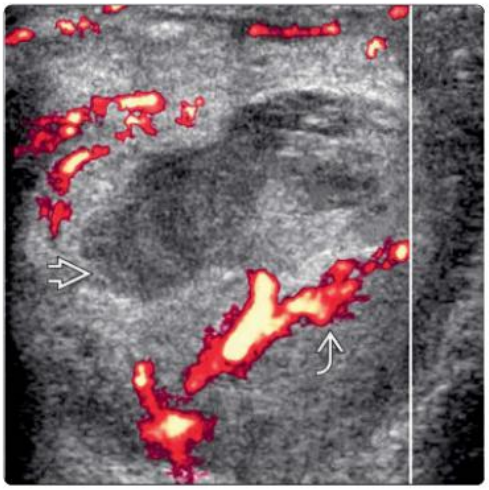

(Left) *Transverse US in an immunocompromised patient shows intense semimembranosus muscle edema ⇨ with focal liquefaction ⇨ due to infective myositis. There is moderate surrounding muscle and subcutaneous edema.* **(Right)** *Transverse power Doppler US of the same lesion shows moderate hyperemia ⇨ of the infected area. There is a hypoechoic, avascular area ⇨ centrally due to early abscess formation.*

Lymphoma

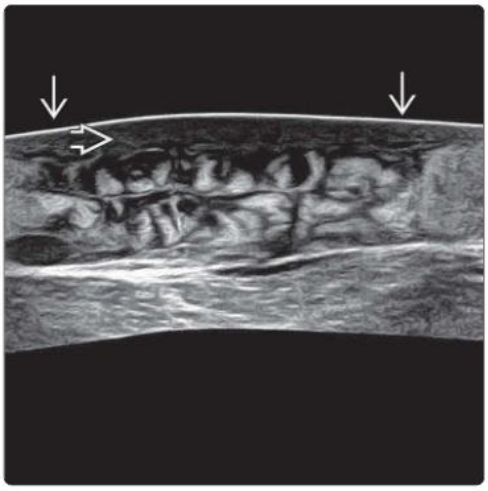

Lymphoma

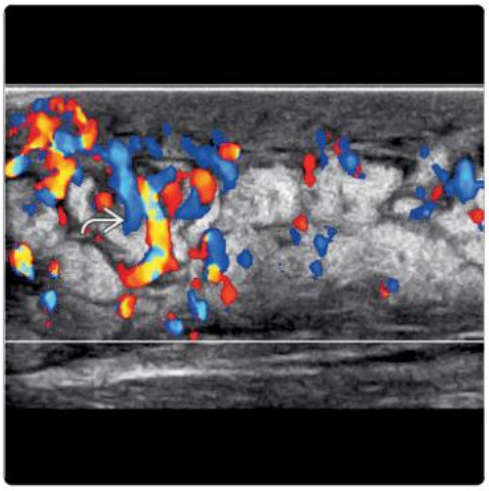

(Left) *Extended view-of-field US shows a poorly defined area of quite intense subcutaneous edema and swelling ⇨. No fluid collection is present, and there is no extension deep to the investing fascia. Moderate perilesional subcutaneous edema ⇨ is present. The US diagnosis was an atypical subcutaneous infection.* **(Right)** *Transverse color Doppler US shows intense intratumoral hypervascularity ⇨. Biopsy revealed peripheral T-cell lymphoma. This can masquerade as an infection.*

Organizing Hematoma

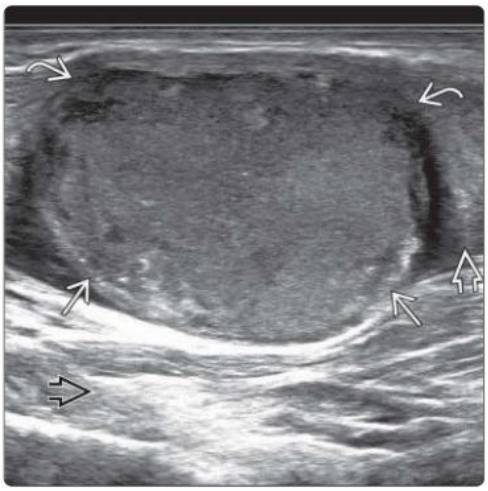

Organizing Hematoma

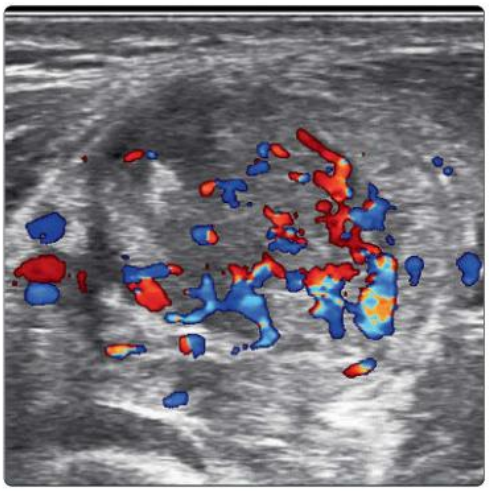

(Left) *Longitudinal US of an enlarging forearm mass ⇨ following sprain injury to the pronator teres ⇨ 3 months previously is shown. There is a largely solid-looking intramuscular mass with a hypoechoic, fibrous capsule ⇨ and posterior acoustic enhancement ⇨.* **(Right)** *Transverse color Doppler US of the same tumor shows a high degree of intratumoral vascularity. Biopsy was performed to exclude sarcoma. Histology revealed an organizing hematoma with reactive fibrosis and inflammation.*

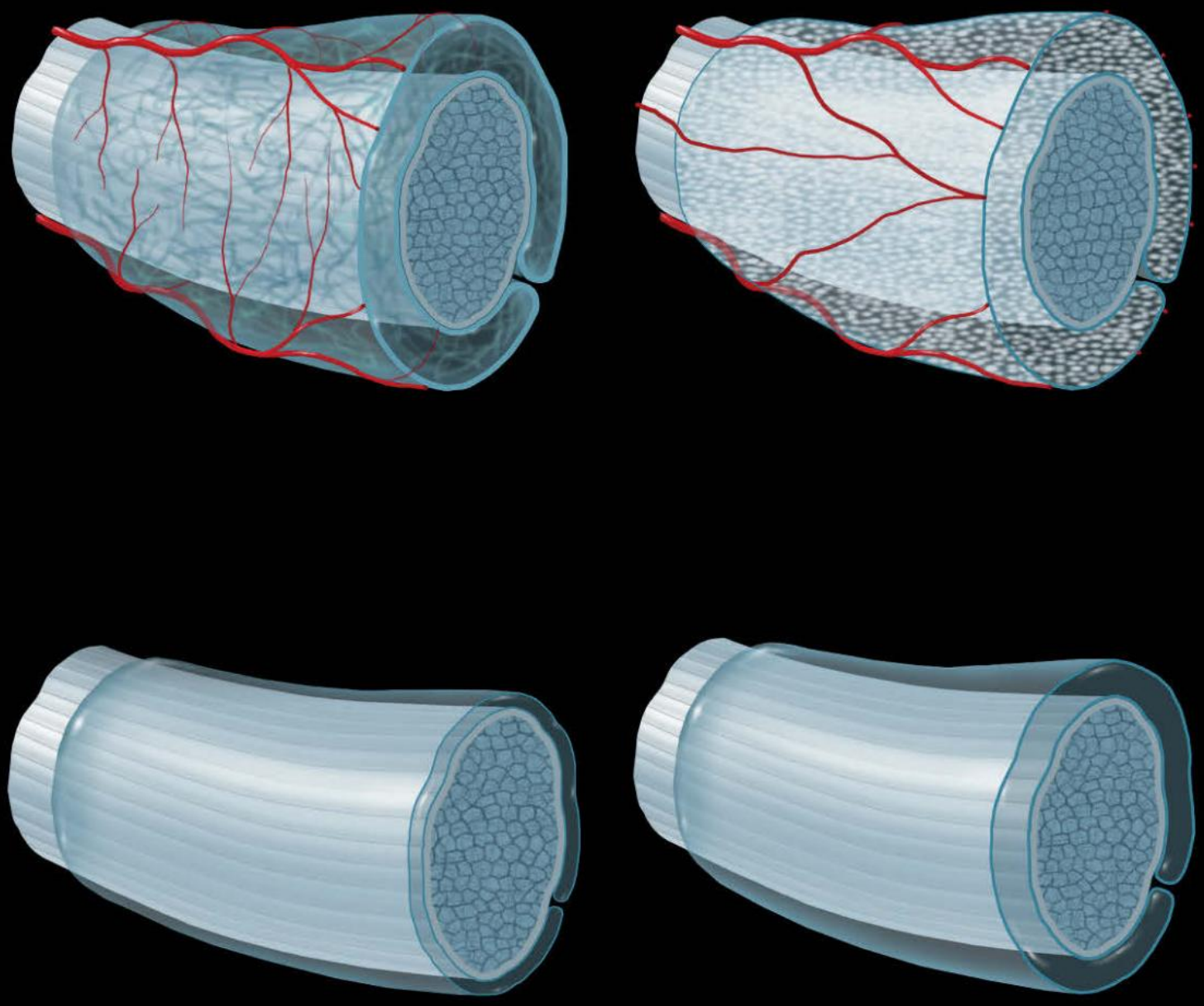

PART IV
SECTION 2

Tendon Abnormalities

Peritendinous Mass	870
Tendon Hypoechogenicity	874
Tendon Hyperechogenicity	878
Tendon Swelling	882

DIFFERENTIAL DIAGNOSIS

Common

- Ganglion Cyst
- Giant Cell Tumor of Tendon Sheath
- Tenosynovitis
- Annular Pulley Thickening
- Gouty Tophus

Less Common

- Nerve Sheath Tumor
- Extensor Retinaculum Thickening
- Bursitis
- Synovial Sarcoma

ESSENTIAL INFORMATION

Key Differential Diagnosis Issues

- Consider whether affected tendon has tendon sheath
  - Only some tendons, notably those around wrist & ankle, have tendon sheaths
  - Some tendon areas, such as patellar & Achilles tendons, have incomplete tendon sheaths, known as paratenons
  - Some tendon areas, such as extensor tendons at fingers & flexor capri ulnaris tendon, do not have tendon sheaths
  - Tenosynovitis & giant cell tumor of tendon sheath (GCTTS) can only occur in tendons with tendon sheath or paratenon
- Relationship of mass to tendon ± tendon sheath important
  - Dynamic assessment by tendon movement is helpful
- Demonstration of color flow can help differentiate vascular hypoechoic synovial proliferation from avascular hypoechoic tendon sheath fluid
  - Use minimal transducer pressure

Helpful Clues for Common Diagnoses

- **Ganglion Cyst**
  - Filled with gelatinous-type material of variable consistency
  - Anechoic, cystic-like structure closely related to joint
    - Common sites are wrist, metacarpophalangeal area, & tarsus
  - Usually originates from joint & may extend to peritendinous location
    - Usually points toward or is closely related to adjacent joint
    - Usually, tract of ganglion cyst is too small to be followed into joint (MR is better)
    - Try to identify joint of origin, as tract should be excised to prevent recurrence
  - If originating from tendon sheath, has no extension to adjacent joint
  - ± comet-tail artifacts within cyst due to colloid aggregates
  - ± leakage of cyst content or hemorrhage within cyst
    - Recent leakage of cyst content leads to localized pericystic inflammation
- **Giant Cell Tumor of Tendon Sheath**
  - Composed of multinucleated cells & fibroblast-like cells that may have hemosiderin deposits
    - Pathologically, GCTTS identical to pigmented villonodular synovitis
  - Occurs mainly in hand, wrist, & foot
    - Though may occur anywhere tendon sheaths exist
  - All GCTTSs contact or partially encase tendon
    - Complete encasement less common
    - Tendon movement not affected since tumor expands on outer margin of tendon sheath
  - Hypoechoic tumor, which may be irregular, fusiform, or rounded in outline
    - Tends to extend along long axis of tendon sheath
    - No posterior acoustic enhancement, cystic areas, or Ca^{++}
  - Usually moderately vascular, though, infrequently, no demonstrable flow on color Doppler imaging
  - May be multifocal
  - High recurrence rate
  - Can mimic ganglion cyst; ↑ US gain to review subtle internal echoes present in GCTTS; use minimal or no transducer pressure to detect subtle vascularity in GCTTS
- **Tenosynovitis**
  - Inflammation or infection of tendon sheath with secondary, less severe, inflammation of tendon
  - Acute exudative tenosynovitis
    - Usually due to acute infection
    - Fluid with low-level echoes within tendon sheath
    - Echogenic speckles within fluid due to aggregates of purulent debris
    - Compression & release useful to see movement of pus
    - Hyperemia around > within tendon sheath
    - Tendon sheath often ruptures with spread of infection into peritendinous tissues
    - Tendon usually only mildly thickened ± indistinct margins
  - Acute nonexudative tenosynovitis
    - Due to inflammation or infection
    - Synovial proliferation predominates over tendon sheath effusion
    - Hyperemia around > within sheath
  - Chronic active tenosynovitis
    - Due to inflammation or infection
    - Hyperemia within & around sheath
  - Chronic inactive tenosynovitis
    - Mild thickening of tendon sheath with clear tendon sheath effusion
    - ± tendon sheath adhesions with entrapped, noncompressible fluid ("stenosing tenosynovitis")
    - No hyperemia
- **Annular Pulley Thickening**
  - Pulleys are series of fibrous slings that maintain flexor tendons in close proximity to fingers during flexion
  - Pulley thickening usually affects A1 pulley, which is located at metacarpophalangeal joint level
    - Leads to restriction of flexor tendon movement known as "trigger finger"
  - Normal pulley seen as thin, hypoechoic band looping over tendon from bony attachment
    - Normally ~ 0.5 mm thick at area most distant from bone

- In "trigger finger," A1 pulley thickens to 1-2 mm
  - ± hyperemia of pulley
  - ± tendinosis or tenosynovitis of flexor tendons
  - ± nodular thickening/ganglion cyst
- Dynamic imaging allows depiction of flexor tendon movement restriction
  - Tendon movement may be clearly restricted, have passive movement, or have fairly normal passive movement with lifting up of pulley
  - Superficialis restricted more than profundus tendon
    - This distinction not usually possible on US

- **Gouty Tophus**
  - Crystal deposition in & around tendons is common
    - Crystal aggregates → comet-tail artifacts
    - Soft or hard tophi depending on level of crystal deposition
  - Usually large, irregular, heterogeneous, hypoechoic mass with calcified foci & hyperemia
  - Calcified foci within mass is quite characteristic
    - GCTTS does not calcify, as it is osteoclastic tumor
  - ± intratendinous crystal deposition
  - Joint involvement
  - Typical clinical history
  - ± raised serum urate

Helpful Clues for Less Common Diagnoses

- **Nerve Sheath Tumor**
  - Often occurs in proximity to tendons, particularly at wrist & ankle
  - Arises from any nerve, even small cutaneous nerve
  - Fusiform-shaped, hypoechoic with posterior acoustic enhancement, moderate vascularity, & nerve continuity
    - ± visible entering or exiting parent nerve (50%)
    - If tumor arises from small peripheral nerve, entering or exiting nerve may not be visible
    - ± areas of myxoid accumulation (common)
    - ± areas of hemorrhage or Ca^{++} (less common)
    - Schwannoma tends to be more eccentrically located to main parent nerve than neurofibroma
- **Extensor Retinaculum Thickening**
  - Most common at 1st extensor compartment of wrist (de Quervain disease, "baby wrist")
  - Associated with postpartum status, aromatase inhibitors, tamoxifen ingestion, & diabetes
  - Thickening (1-1.5 mm) of extensor retinaculum; normal < 0.5 mm thick
    - ± variable peritendinitis with hyperemia & edema of adjacent tissues
    - ± tendon sheath effusion
  - Associated with variable tendinosis of abductor pollicis longus & extensor pollicis brevis
    - Leads to restriction of tendon movement; demonstrable on real-time US
    - de Quervain disease is stenosing tendinosis rather than tenosynovitis
- **Bursitis**
  - Chronic frictional trauma or overuse
    - Subacromial, bicipitoradial, olecranon, ischial, trochanteric, prepatellar, semimembranosus, pes anserinus, retrocalcaneal
  - Bursa usually located alongside tendons
    - Distended hypoechoic bursa ± echogenic fluid
    - Thickened wall ± internal septations ± hemorrhage
    - Soft tissue/subcutaneous tissue inflammation with hyperemia
    - Acute: Hyperemia of peribursal soft tissue on color Doppler imaging
    - Chronic: ± Ca^{++} ± intrabursal hyperemia, which may mimic mass
- **Synovial Sarcoma**
  - May occur in proximity to tendons, particularly in wrist & hand
  - Large, heterogeneous, hypoechoic mass with well-defined margin
  - Usually located in paraarticular region, sometimes surrounding tendon
  - Usually hypervascular
  - Posterior acoustic enhancement, cystic areas, or Ca^{++} may be seen

Ganglion Cyst

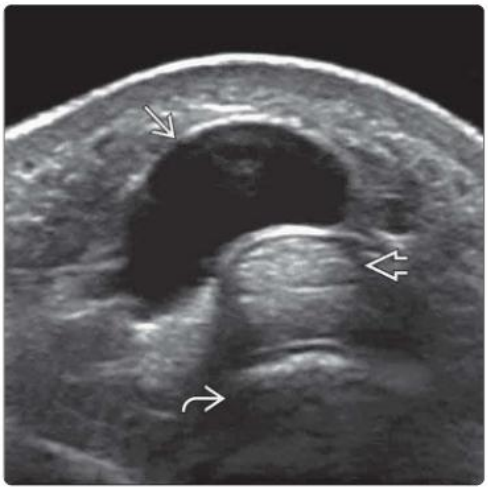

Ganglion Cyst

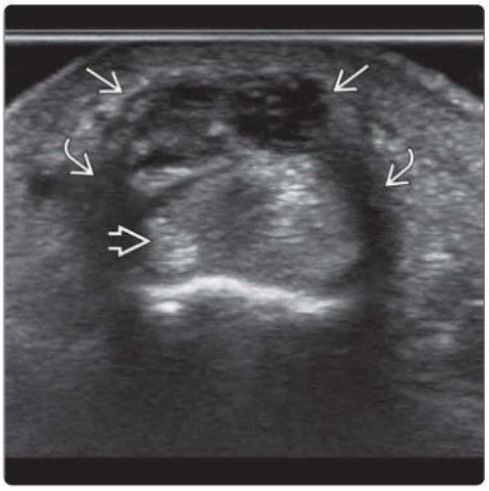

(Left) *Transverse US shows a subcutaneous unilocular ganglion ➡ located volar to the flexor digitorum tendon ➡ of the middle finger close to the metacarpophalangeal joint ➡ and A1 pulley. Such "retinacular ganglia" typically do not communicate with a joint.* **(Right)** *Tranverse US in another patient shows a cystic lesion ➡ overlying the extensor pollicis brevis tendon ➡ with thickening of retinaculum ➡, features compatible with de Quervain disease and complicated ganglion cyst.*

Giant Cell Tumor of Tendon Sheath

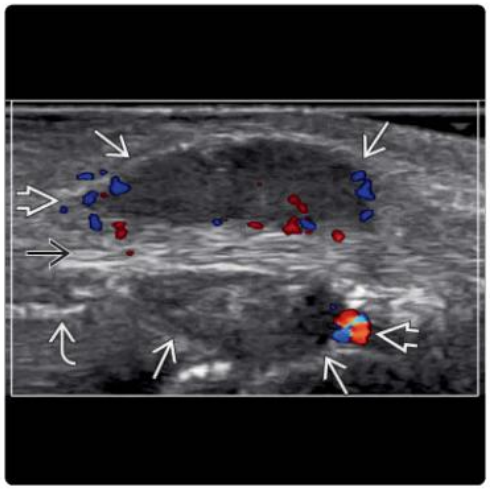

Giant Cell Tumor of Tendon Sheath

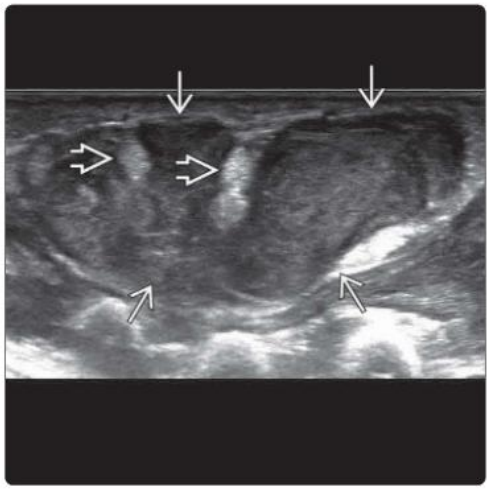

(Left) *Longitudinal US of radial side of wrist shows an oval, hypoechoic, solid soft tissue mass ➡ with mild vascularity ➡ located just distal to the radius ➡ encasing the abductor pollicis longus tendon ➡. Histology confirmed giant cell tumor.* **(Right)** *Transverse US shows a giant cell tumor of tendon sheath (GCTTS) ➡ almost filling the carpal tunnel with encasement (> 180° of circumference) of the flexor digitorum tendons ➡. Moderate hyperemia was present on color Doppler imaging (not shown).*

Tenosynovitis

Tenosynovitis

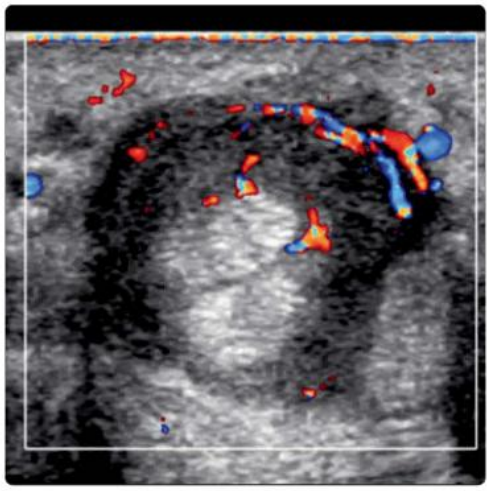

(Left) *Transverse US of flexor pollicis longus tendon shows severe synovial thickening ➡ surrounding the mildly swollen tendons, indicative of chronic tenosynovitis.* **(Right)** *Transverse color Doppler US at the same level as previous image shows moderate peritendinous hyperemia, indicative of chronic active tenosynovitis. Color Doppler helps in differentiating between synovial proliferation and echogenic synovial fluid, as the latter is not vascular.*

Tenosynovitis

Tenosynovitis

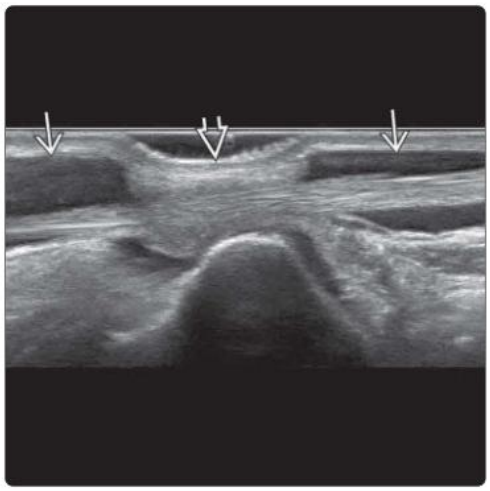

(Left) *Longitudinal US of dorsum of wrist shows severe extensor carpi radialis brevis gouty tenosynovitis ➡. The tendon sheath is distended with echogenic proteinaceous fluid ➡ containing many small crystal aggregates ➡.* **(Right)** *Longitudinal US of the ankle region in a 44-year-old woman shows extensor digitorum tendon sheath ➡ distended with anechoic fluid due to stenosing tenosynovitis. No hyperemia was present. Tenosynovial distention in this case is limited, restrained by the inferior extensor retinaculum ➡.*

Annular Pulley Thickening

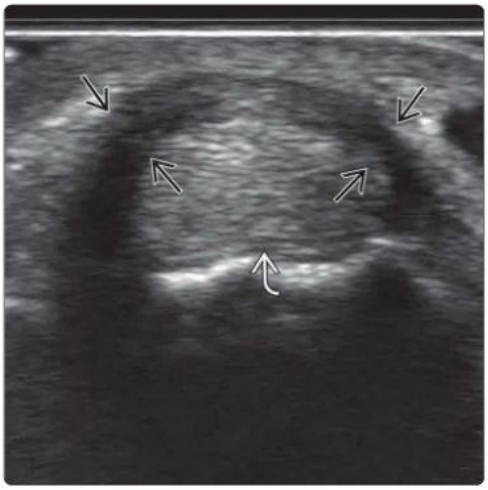

Annular Pulley Thickening

(Left) *Transverse US shows diffuse thickening ⇨ (1.2 mm) of the A1 annular pulley surrounding the flexor digitorum tendon of the ring finger ⇨ in a patient with trigger finger. The normal thickness of the A1 pulley, which is measured at 10 or 2 o'clock, is < 0.5 mm.* **(Right)** *Longitudinal US of the same patient shows thickening of A1 pulley ⇨. Pulley thickening is less easily appreciated on longitudinal than on transverse US. Passive movement of the tendon ⇨ may show movement restriction deep to the pulley.*

Nerve Sheath Tumor

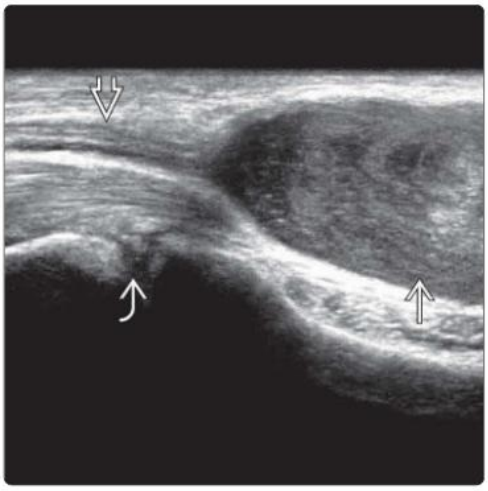

Extensor Retinaculum Thickening

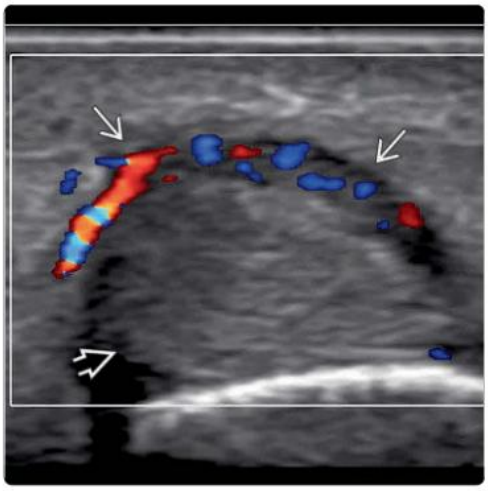

(Left) *Longitudinal US of wrist shows mass ⇨ arising from median nerve ⇨ proximal to the carpal tunnel and anterior to the radiocarpal articulation ⇨. Histology confirmed a schwannoma.* **(Right)** *Transverse US of 1st extensor compartment shows moderately thickened hyperemic extensor retinaculum ⇨, consistent with de Quervain disease. This can be considered a stenosing tendinosis. The 2 first compartment tendons ⇨ cannot be individually resolved.*

Bursitis

Bursitis

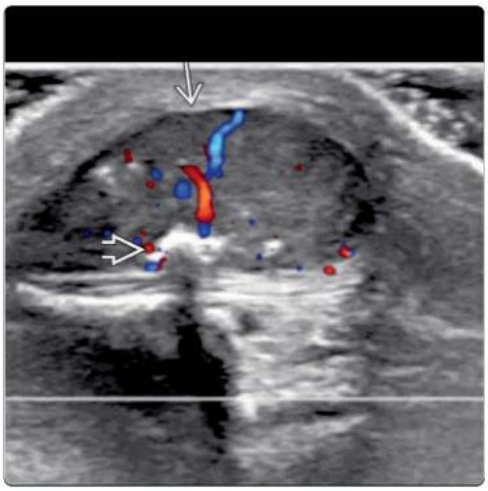

(Left) *Longitudinal US shows a heavily calcified mass ⇨ with posterior acoustic shadowing ⇨ in the anterior cubital fossa surrounding the distal bicep tendon ⇨. This is compatible with calcified radiobicipital bursitis due to the known chronic renal failure and secondary hyperparathyroidism.* **(Right)** *Longitudinal US shows a soft tissue mass in the prepatellar bursa ⇨ with small clumps of Ca^{++} ⇨ and moderate hypervascularity, compatible with a chronic prepatellar gouty bursitis. This was confirmed histologically.*

DIFFERENTIAL DIAGNOSIS

Common

- Anisotropy
- Tendinosis
- Tendon Tear

Less Common

- Intratendinous Vessel
- Xanthomatosis
- Amyloidosis

ESSENTIAL INFORMATION

Key Differential Diagnosis Issues

- Be familiar with normal appearances of tendon & insertion before commenting on abnormality
  - Avoid anisotropy by tilting transducer slightly in different angles
- Changing position of limb can also optimize tendon visibility
- Confirm any abnormality on 2 orthogonal views
- Dynamic assessment to view tendon movement is useful
- Scan only 1 tendon at a time
- Color Doppler is useful to assess tendon vascularity & distinguish between tears & vascular channels
  - Normal tendons show no internal vascularity on color Doppler imaging
  - Stretching tendon may efface vascularity
  - Minimize transducer pressure on tendon
- Some tendons more prone to neovascularization than others
  - Achilles, posterior tibialis, patellar tendons, & tendons of common extensor or flexor tendon origins are susceptible to vascular ingrowth
  - Rotator cuff tendons rarely show vascular ingrowth

Helpful Clues for Common Diagnoses

- **Anisotropy**
  - Reflectivity of normal tendon, nerve, & muscle is dependent on angle of transducer
  - Tendon best seen when incident beam is perpendicular to tendon
  - Any alteration from perpendicular irrespective of direction can lead to loss of reflectivity (anisotropy)
    - Tendinosis & tears also lead to loss of echogenicity, so ensure that US beam is maintained at right angles to tendon
    - Tilt probe at different angles to confirm whether abnormality is real or not
    - Dynamic scan with tendon movement can also help to confirm abnormality
- **Tendinosis**
  - Failed wound healing cascade after microtear due to either specific injury or repetitive microtrauma
  - Pathologically represents degenerative process
    - Hypercellularity & irregular vascular ingrowth
    - Collagen fiber disorganization & thinning
    - ↑ interfibrillar glycosaminoglycan deposition
    - Inflammatory cell infiltrate is not feature of tendinosis
  - Tendons more prone to tendinosis in upper limb
    - Supraspinatus, infraspinatus, subscapularis, & long head of biceps
    - Common tendon extensor origin, extensor carpi ulnaris, abductor pollicis longus, & extensor pollicis brevis
  - Tendons more prone to tendinosis in lower limb
    - Hamstrings at ischial tuberosity attachment, gluteus minimus & medius at greater trochanteric insertion
    - Quadriceps, patellar, Achilles, peroneal, & posterior tibialis tendons
  - Seen on US as tendon thickening, hypoechogenicity, & loss of normal fibrillar pattern ± focal hyperemia
  - May affect tendon segmentally (more common) or diffusely
    - Grade as mild, moderate, or severe
  - Tendon thickening
    - Tendon size larger than expected
    - Can compare with contralateral asymptomatic side; though, remember that subclinical tendinosis is common
  - Loss of normal fibrillar pattern & hypoechogenicity
    - Due to proteoglycan matrix deposition between tendon fibrils
  - Hyperemia
    - Vessels not present within normal tendons
    - Level of hyperemia is proportional to level of tendinosis disease activity
    - May be related to disease progression or repair; reduction in hyperemia correlates with decrease in symptoms
    - Subjectively graded as mild, moderate, or severe
  - Secondary signs of tendinosis
    - More common in severe tendinosis
    - Tendon sheath effusion (if tendon sheath present)
    - Adjacent bursitis (Achilles, hip adductors)
    - Cortical irregularity ± hyperostosis at insertional area
    - Intratendinous dystrophic calcification
    - Variable degree of peritendinitis
      - Edema & hyperemia of peritendinous tissues
      - Important feature of tendinosis to note, as it will respond to antiinflammatory medication
- **Tendon Tear**
  - US accurately detects macroscopic tendon tears
  - May occur at insertion (avulsive type), tendon surface (surface tear or fraying), or within tendon substance (intrasubstance)
  - Tendon tears are strongly associated with tendinosis
    - Likelihood of tendon tear increases with increasing severity of tendinosis
    - Tendon tears occur in those areas where tendinosis occurs
    - Tears are uncommon in normal tendons
  - Tears tend to happen at specific sites for each tendon
    - Supraspinatus is most frequently torn tendon with avulsive-type tear anterior fibers being most common
    - Achilles tendon tears occur at junction of proximal & middle 1/3 of tendon
    - Common extensor tendon tears are intrasubstance or deep avulsive-type tears
    - Biceps tendon tears are often longitudinal (split) tears at proximal aspect of bicipital groove

  - Peroneal & posterior tibialis tendon tears typically located at retromalleolar & inframalleolar regions
- Partial-thickness tear
  - Focal discontinuity of tendon not involving all tendon fibers
  - Sharp, linear, hypoechoic defect within area of tendinosis
  - Lack of tendon retraction is most important feature to distinguish partial from complete tear
  - Do not confuse with dilated vascular channels within hyperemic tendon; color Doppler imaging is helpful
  - Do not confuse with focal proteoglycan accumulation seen as focal hypoechoic area ± bulging tendon contour
  - ± dystrophic calcification, adjacent bursitis, reactive bone changes
- Full-thickness tear
  - Tendon discontinuity with anechoic or hypoechoic area in gap between proximal & distal stumps
  - Retraction gap may be filled with echogenic blood, making tear less conspicuous
  - Often swollen tendon ends, especially for small finger tendons
  - Collapsed synovial sheath may be mistaken for attenuated tendon (applies to smaller tendons, e.g., finger flexors & biceps tendon)
  - Proximal & distal stumps may show severe tendinosis with dystrophic calcification
  - Measure gap & mark position of proximal & distal tendon stumps; helpful for surgery

Helpful Clues for Less Common Diagnoses

- **Intratendinous Vessel**
  - Should not be confused with partial intrasubstance tear
  - Dilated vascular channels within hyperemic tendon due to tendinosis
  - Vessels normally not present within tendons
  - Level of hyperemia is proportional to level of tendinosis disease activity
  - May be related to reparative process
  - Color Doppler imaging is diagnostic
- **Xanthomatosis**
  - Tendon xanthomas are manifestation of familial hyperlipidemia
    - Xanthomas composed of lipid-laden foamy histiocytes, cholesterol ester, & giant cells
  - Appear most commonly as fusiform, hypoechoic enlargement of tendon
    - Less commonly, discrete, hypoechoic areas (due to more concentrated cholesterol deposition)
  - Achilles tendon > > patellar tendon > extensor tendons of hands & feet
    - In Achilles tendon, discrete, small, calcific foci may also be seen along length of tendon
    - Hyperemia on color Doppler imaging is not feature
  - Xanthoma may regress with lipid-lowering treatment
  - Useful marker given its specific relationship to atherosclerosis
    - Lipid composition of xanthoma is similar to atherosclerotic plaques
    - Some patients with dyslipidemia may present with xanthoma
  - Xanthoma may be difficult to distinguish from tendinosis; helpful, though not very specific, distinguishing US features of xanthomatosis are
    - Symmetrical appearances
    - Very enlarged tendon
    - More discrete areas of tendon hypoechogenicity
    - No hyperemia on color Doppler imaging
    - Known hypercholesterolemia
- **Amyloidosis**
  - Inherited or secondary (chronic renal failure, multiple myeloma, chronic inflammation)
  - Overproduction of fibrous protein aggregates, which become insoluble & deposit in tissues
  - Heart, lungs, kidneys, spleen, gastrointestinal tract, nerves, & tendons
  - → tendon thickening & hypoechogenicity
    - Supraspinatus > biceps > hand & wrist tendons
    - ± nodular tendon sheath or bursal thickening
    - Predisposes to tendon tears

Anisotropy

Anisotropy

(Left) *Transverse US of carpal tunnel shows normal echogenicity of flexor tendons ⇨. The flexor pollicis longus tendon ⇨ is less well defined at this insonation angle.* **(Right)** *Transverse US at the same level shows that tendon echogenicity changes from hyperechoic to hypoechoic in almost all the tendons ⇨ when the transducer is not aligned at a right angle to the tendon. The flexor pollicis longus tendon ⇨ is more well defined at this angle.*

Tendinosis

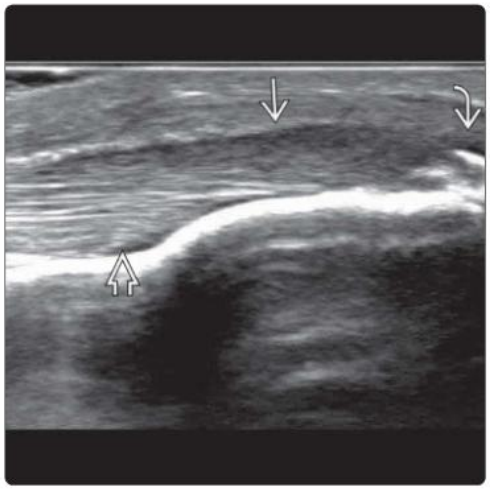

Tendinosis

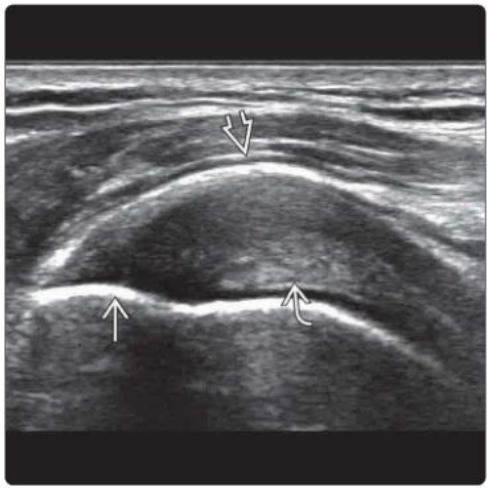

(Left) *Longitudinal US of distal patellar tendon shows a focal, thickened, hypoechoic tendon near the anterior tibial tuberosity with tendinosis mainly involving the superficial fibers. Note insertional cortical hyperostosis and normal deeper tendon fibers.* **(Right)** *Longitudinal US shows severe supraspinatus tendinosis at the greater tuberosity insertion. The more superficial supraspinatus tendon fibers are hypoechoic, while the deeper fibers, representing the rotator cable, are hyperechoic.*

Tendinosis

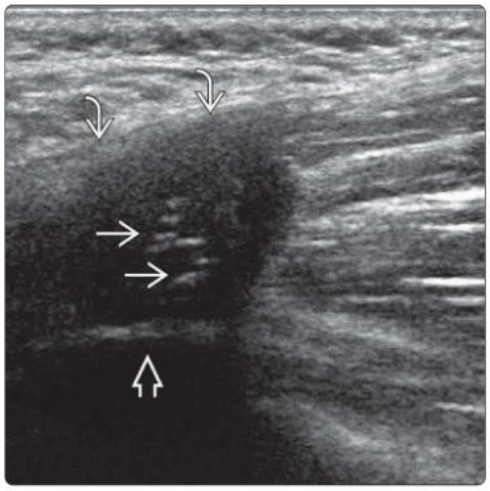

Tendinosis

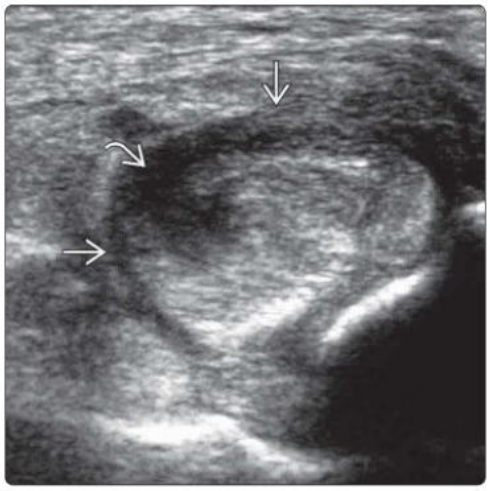

(Left) *Longitudinal US of the adductor longus tendon shows multiple foci of calcification close to the adductor longus origin at the pubic ramus. The tendon is moderately swollen and hypoechoic, consistent with tendinosis.* **(Right)** *Transverse US of the retromalleolar tibialis posterior tendon shows severe tendinosis with a thickened, heterogeneous tendon. The small, hypoechoic area with an ill-defined margin within the tendon is consistent with localized proteoglycan accumulation.*

Tendon Tear

Tendon Tear

(Left) *Transverse US shows tendinosis with partial tears within the swollen abductor pollicis longus (APL) tendon. Normal extensor pollicis brevis is located medial to it for comparison. Features are compatible with de Quervain disease.* **(Right)** *Longitudinal US of the quadriceps tendon shows a complete tear at the distal 1/3 of the tendon. The proximal and distal tendon ends are mildly retracted. A thin rim of fluid is filling up the gap of the tear.*

Intratendinous Vessel

Intratendinous Vessel

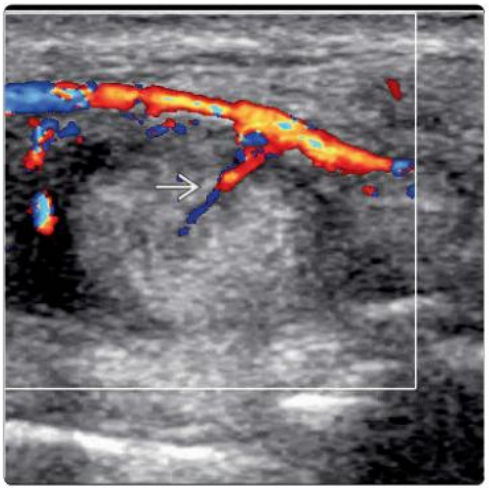

(Left) *Transverse US of the posterior tibialis tendon shows a linear, discrete, hypoechoic line extending from the surface to the center of the tendon ➡, suspicious of a partial-thickness tear.* **(Right)** *Transverse color Doppler US of the corresponding region shows that the linear, discrete, hypoechoic line represents a vascular channel ➡. Always check any suspected partial tears with color Doppler US.*

Xanthomatosis

Xanthomatosis

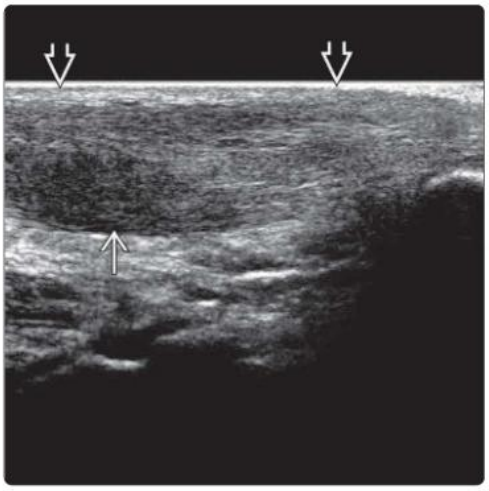

(Left) *Transverse US of the distal 1/3 of the Achilles tendon in a patient with familial hypercholesterolemia shows a focal, round, hypoechoic area ⇨ in a normal-appearing tendon, suggestive of a xanthoma.* **(Right)** *Longitudinal US of the Achilles tendon in another patient with familial hypercholesterolemia shows that the tendon ➡ is diffusely thickened with a more focal, hypoechoic area ➡ on the deeper aspect of the tendon due to a localized cholesterol deposition (xanthoma).*

Xanthomatosis

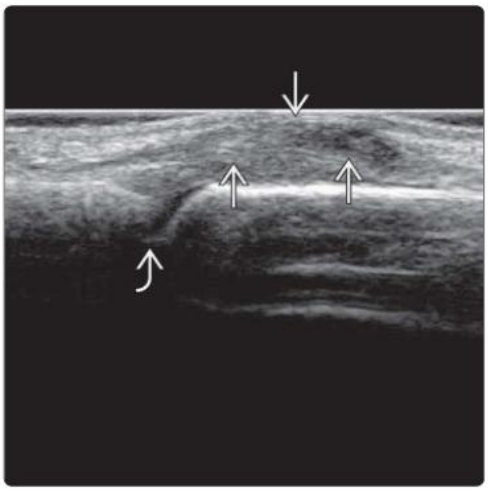

Xanthomatosis

(Left) *Longitudinal US in the same patient shows moderate, hypoechoic thickening ➡ of the extensor tendon hood over the metacarpophalangeal joint ➡ due to a tendon xanthoma.* **(Right)** *Clinical photograph of the same patient shows xanthomas overlying the metacarpophalangeal joints ➡.*

DIFFERENTIAL DIAGNOSIS

Common

- Calcific Tendinitis
- Calcification Within Tendinosis
- Gout

Less Common

- Tendon Tear
- Avulsion Injury of Tendon
- Accessory Ossicle
- Suture Material Within Tendon
- Foreign Body Within Tendon

ESSENTIAL INFORMATION

Key Differential Diagnosis Issues

- Areas of tendon hyperechogenicity are usually due to calcification or crystal deposition within tendon substance
  - Alternatively gas, blood, or foreign body (e.g., sutures)
- US is more sensitive than radiography or MR at detecting calcification or crystal deposition within tendon
- Calcification or crystal deposition varies from small, hyperechoic foci with comet-tail artifacts to large, confluent areas of hyperechogenicity with dense acoustic shadowing
  - Small crystal aggregates not visible radiographically

Helpful Clues for Common Diagnoses

- **Calcific Tendinitis**
  - Due to deposition of hydroxyapatite crystal within tendon substance
  - Leads to severe pain & restriction of movement
    - Can affect any tendon, though some tendons are particularly prone to calcific tendinitis
    - Age: 40-60 years
    - Formative, latent (resting), & resorptive phases
      - Pain, particularly during resorptive phase
  - Rotator cuff tendons are most commonly affected
    - Supraspinatus > infraspinatus > subscapularis tendon
  - Other less commonly affected tendons are
    - Hamstring tendons at ischial tuberosity
    - Rectus femoris tendon near iliac attachment
    - Adductor tendons near pelvic attachment
    - Gluteus medius & minimus tendons at greater trochanteric insertion
    - Quadriceps tendon at insertion
    - Flexor hallucis longus tendon
    - Flexor carpi ulnaris tendon
  - Focal, hyperechoic area of varying size & shape
    - Arch-shaped (most common)
    - Punctuate or fragmented
    - Nodular
    - Cystic type (uncommon)
  - ± acoustic shadowing depending on size
  - ± associated tendinosis (mild, moderate, or severe)
  - ± tendon tear
  - ± pericalcific hyperemia on color Doppler imaging
    - Doppler color flow suggests resorptive phase & good response to needling
  - ± intrabursal, intramuscular, intraosseous, or intraarticular crystal deposition
  - Several tendons may be affected simultaneously
  - Associated with increased risk of diabetes, nephrolithiasis, & choledocholithiasis
  - Treatment
    - Analgesia & local heat (self-limiting condition)
    - US-guided needling for both hard & soft calcification
    - Aspiration ± lavage, especially for soft calcification
    - ± US-guided steroid or long-acting local anesthetic to bursa alongside tendon
    - Extracorporeal shock wave therapy
    - Acetic acid iontophoresis; applying direct current to drive ions through tissues; injection without needle
- **Calcification Within Tendinosis**
  - Dystrophic calcification seen in Achilles tendon > > quadriceps & patellar tendons > posterior tibialis tendon
    - Site specificity allows easy differentiation from calcific tendinitis, which mainly affects rotator cuff tendons
  - Affects tendons close to insertional area
  - Usually associated with background tendinosis
  - Discrete areas of calcification within tendon from few mm to few cm
    - Mature, solid-appearing with well-defined margins & little, if any, associated pain or tenderness
    - Strong propensity to ossify
    - Not possible to aspirate, unlike calcific tendinitis
  - Strong posterior acoustic shadowing
  - Color Doppler flow is feature of tendinosis rather than calcific deposition
  - Usually associated with reactive bony changes at insertional area
    - Cortical irregularity
    - Cortical hyperostosis & spur formation
  - May occur in asymptomatic subjects with no other US features of tendinosis
    - Particularly in Achilles & quadriceps tendons
- **Gout**
  - Crystal deposition within tendon substance or alongside tendon
  - Usually associated with gouty tophi within tendon sheath & tendon sheath effusion
  - Most crystal deposition tends to be around tendons, ligaments, & joints
    - Intratendinous deposition is common feature of chronic gouty arthropathy
    - Rare feature of calcium pyrophosphate crystal deposition
  - Focal tendon thickening
    - Loss of normal fibrillar pattern
  - Small, intratendinous crystal aggregates seen as comet-tail artifacts within tendon
    - ± posterior acoustic shadowing depending on severity of crystal deposition
    - ± mild peritendinous or intratendinous hyperemia
  - Normally affects tendons of smaller joints, including wrist/hand or ankle/foot
    - Less common in larger tendons
    - Typical clinical history ± raised plasma urate
  - Usually associated with gouty tophi
    - Extraarticular gouty tophi, depending on level of crystal deposition

- Usually large, irregular, heterogeneous, hypoechoic mass with calcified foci & hyperemia
- Soft tophi: Hyperechoic mass with no acoustic shadowing
- Hard tophi: Hyperechoic with intense acoustic shadowing
  - Quite well-defined, irregular margins with variable hypoechoic halo ("clump of wet sugar")
- Groups of tophi at single site common
- Erosions in adjacent bone is common

- Usually associated with gouty arthropathy
  - Variable appearance of joint fluid
  - Hyperechoic aggregates in synovial fluid
    - Fine, punctate echogenicity ("urate sand") or large, echogenic aggregates (snowstorm appearance)
  - "Urate icing" or "double contour" of urate deposition on articular cartilage surface

Helpful Clues for Less Common Diagnoses

- **Tendon Tear**
  - Often associated with hemorrhage
    - Acute hemorrhage may be echogenic on US
    - Makes tear less readily visible on US
  - May occur at insertion (avulsive type), at tendon surface, or within tendon substance (intrasubstance)
  - Look for associated secondary signs of tear
    - Flattening or indentation of tendon surface
    - Loss of continuity of tendon fibrillar pattern
    - Widening of gap on dynamic movement
    - ± compression of hematoma in gap on dynamic scanning
  - Chronic tears may also fill with echogenic herniated fat from, for example, Kager fat pad in Achilles tendon tear
  - Partial-thickness tear
    - Focal discontinuity of tendon not involving all tendon fibers
    - Incomplete tendon retraction
    - Occurs with moderate to severe tendinosis
    - ± dystrophic calcification
    - ± bursitis
    - ± reactive bony changes
  - Full-thickness tear
    - Collapsed synovial sheath may be mistaken for attenuated tendon, particularly in smaller tendons (e.g., finger flexors & biceps tendon)
  - Peritendinitis
    - Edema & hyperemia of peritendinous tissues
- **Avulsion Injury of Tendon**
  - Commonly at extensor digitorum of fingers, Achilles tendon, tibialis posterior tendon
  - Ossified fragment can be seen at distal end of tendon, mimicking ossification within tendon
  - Look for loss of normal fibrillation distal to ossified fragment (dynamic scan can help)
  - Look for bone irregularity at insertional area
- **Accessory Ossicle**
  - Most common accessory ossicles within tendon are accessory navicular bone (within posterior tibialis tendon) & os peroneum (within peroneus longus)
  - May be confused with dystrophic ossification
    - Accessory ossicle has smooth convex superficial border, while dystrophic ossification is more irregular
    - Occurrence at typical locations diagnostic
  - Fractures or displacement of os peroneum are clue to peroneus longus tendon tear
- **Suture Material Within Tendon**
  - Nonabsorbable material remains visible many years after tendon repair
    - Easily recognized as tubular echogenic material within tendon substance
- **Foreign Body Within Tendon**
  - US is excellent at detecting foreign bodies
  - Foreign body echogenicity depends on composition (e.g., wood, glass, metal) & shape
    - Most foreign bodies are hyperreflective with posterior acoustic shadowing or reverberation artifact
  - If US is negative in suspicious acute clinical setting, repeat US 1 week later, as hypoechoic inflammatory response or granulation tissue may develop around foreign body, making it more conspicuous

Calcific Tendinitis

Calcific Tendinitis

(Left) *Longitudinal US shows moderate calcific tendinitis ⇨ with crystal deposition just distal to the origin of the direct head of rectus femoris tendon ⇨ on the anterior inferior iliac spine ⇨.* **(Right)** *Transverse US of the same area as previous image shows the focus of calcification ⇨ within the rectus femoris tendon ⇨ close to the origin, compatible with calcific tendinitis.*

Calcific Tendinitis

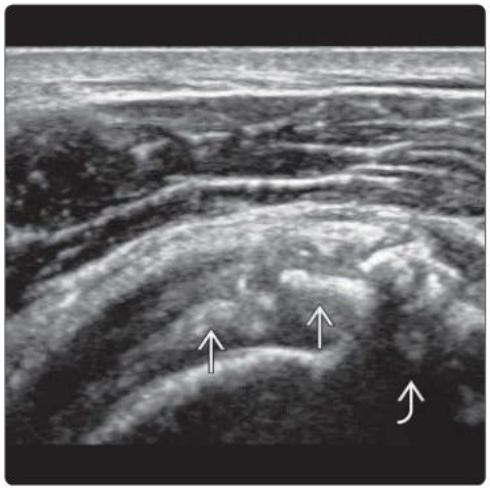

Calcific Tendinitis

(Left) *Longitudinal US shows severe, nonconfluent calcific tendinitis within the supraspinatus tendon obscuring the insertional area.* **(Right)** *Longitudinal US shows severe deposition of hydroxyapatite crystals within the biceps tendon at the proximal end of the bicipital groove. This is soft, amorphous calcification suited to aspiration. Calcific tendinitis tends to affect those tendon areas most affected by tendinosis. Note resultant acoustic shadowing across humeral head.*

Calcification Within Tendinosis

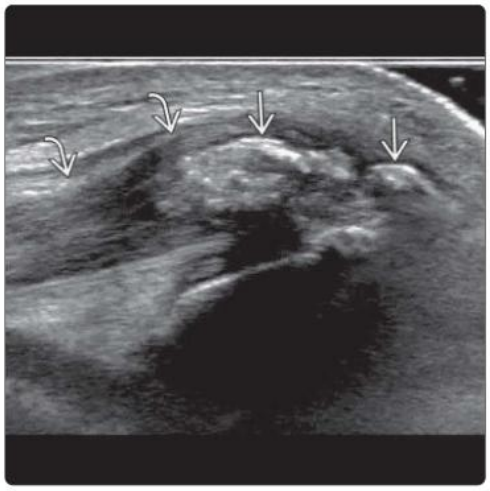

Calcification Within Tendinosis

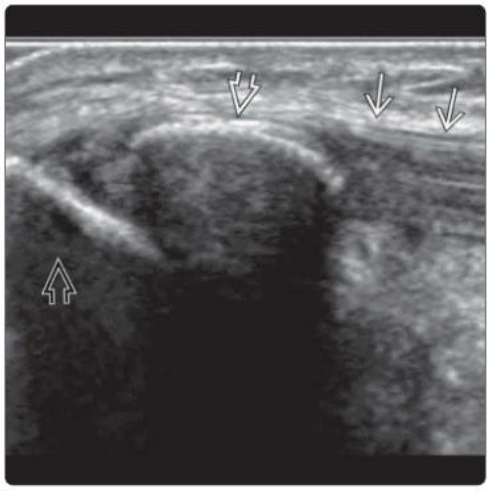

(Left) *Longitudinal US shows a focal area of calcification within the distal part of the quadriceps tendon. Moderate tendinosis is present. Tendinosis is a frequent, though not invariable, accompaniment of intratendinous dystrophic calcification.* **(Right)** *Longitudinal US shows a large area of ossification within the proximal part of the patellar tendon just distal to the patellar bone.*

Gout

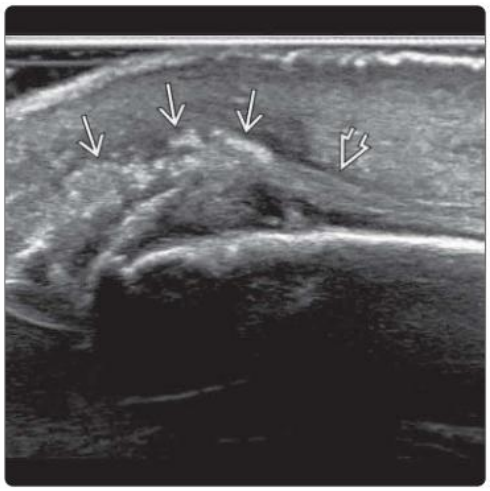

Gout

(Left) *Longitudinal US shows echogenic material encasing and replacing the extensor digitorum tendon, compatible with severe crystal deposition.* **(Right)** *Transverse US shows severe gouty deposition within the tibialis anterior tendon anterior to the ankle joint. This is a soft tophus with no acoustic shadow. There is moderate-severity tendon sheath swelling due to associated tenosynovitis. Gouty deposition within tendons of the feet and hands is not uncommon.*

Tendon Tear

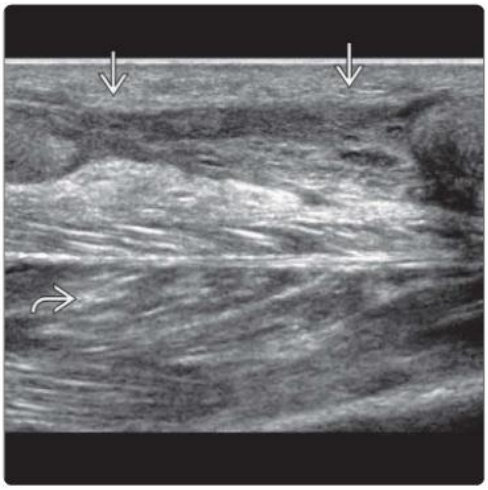

Tendon Tear

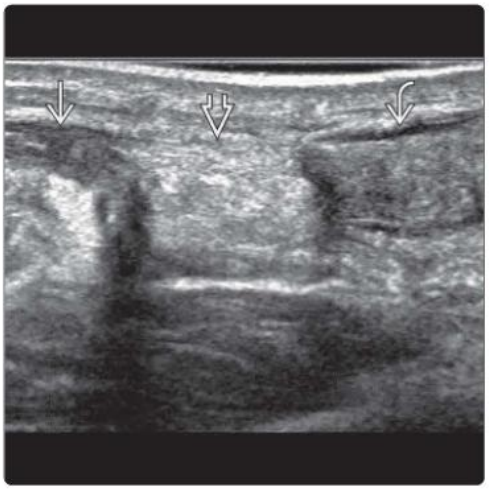

(Left) *Longitudinal US shows a complete chronic rupture of the Achilles tendon. There is a large retraction gap. The chronic tear is filled with slightly echogenic fibrous tissue. The soleus muscle is mildly atrophic.* **(Right)** *Longitudinal US of an acute, full-thickness Achilles tendon tear shows a gap filled with echogenic edematous fat. The swollen proximal and distal ends of the tendon are shown.*

Avulsion Injury of Tendon

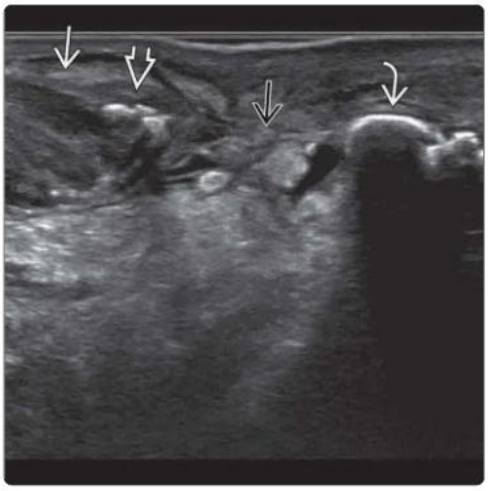

Accessory Ossicle

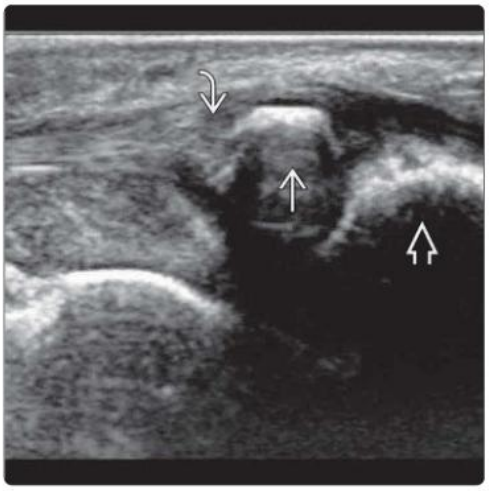

(Left) *Longitudinal US of Achilles tendon shows a fragmented avulsion fracture from the posterior calcaneal tuberosity insertion with proximal retraction. The gap is filled with echogenic hematoma, fat, fluid, and osseous fragments.* **(Right)** *Longitudinal US shows a normal accessory bone near the insertion of the posterior tibialis tendon into the navicular bone. The distal end of the posterior tibialis tendon normally expands close to the bony insertion.*

Foreign Body Within Tendon

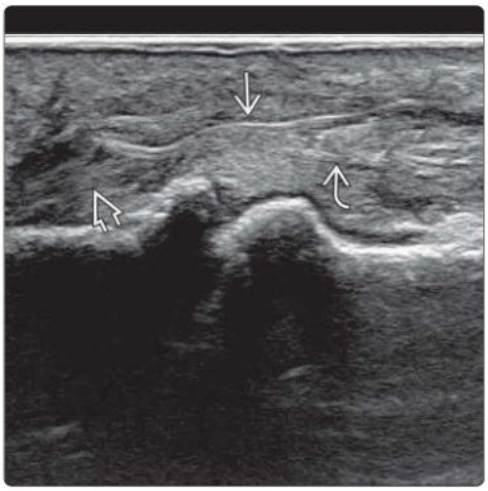

Foreign Body Within Tendon

(Left) *Longitudinal US of the flexor digitorum profundus tendon at the finger shows linear, hyperechoic material between the tendon ends due to surgical suture. There is a wide gap between the proximal and distal tendon ends, compatible with retear.* **(Right)** *Transverse US of middle finger shows a linear, echogenic foreign body lying transversely within the flexor digitorum tendon at the level of metacarpal head. This is associated with a small tendon sheath effusion.*

DIFFERENTIAL DIAGNOSIS

Common

- Tendinosis

Less Common

- Acute Proliferative Tenosynovitis
- Acute Exudative Tenosynovitis
- Chronic Active Tenosynovitis
- Chronic Inactive Tenosynovitis
- Gout/Pseudogout
- Xanthoma
- Amyloidosis

ESSENTIAL INFORMATION

Key Differential Diagnosis Issues

- Determine whether main pathology affects tendon or tendon sheath
- Distinction between tendinosis & tenosynovitis has therapeutic & prognostic implications
  - Tendinosis: Disease of tendon with secondary involvement of peritendinous structures
    - Tenosynovitis: Disease of tendon sheath with secondary involvement of tendon
  - Tendinosis associated with microtears, proteoglycan deposition, & collagen disorganization
    - Tenosynovitis associated with tendon sheath inflammation due to inflammatory mediators, repetitive microtrauma, crystals, or bacteria
  - Tendinosis is not primary inflammatory disease
    - Tenosynovitis is primary inflammatory disease
  - Tendinosis affects any tendon
    - Tenosynovitis only affects tendons with tendon sheath
  - Tendinosis often affects only segment of tendon
    - Tenosynovitis usually affects all of tendon contained by tendon sheath
  - Tendinosis is usually subclinical
    - Tenosynovitis is usually symptomatic
  - Tendinosis frequently predisposes to tendon tear
    - Tenosynovitis infrequently predisposes to tendon tear
  - Tendinosis treated primarily by rest & likely to persist
    - Tenosynovitis treated primarily by antiinflammatory agents & not likely to persist
- Mild tendon & tendon sheath swelling occurs in presence of severe cellulitis or edema as feature of generalized soft tissue swelling
  - Do not misdiagnose as tenosynovitis

Helpful Clues for Common Diagnoses

- **Tendinosis**
  - Tendons affected
    - Rotator cuff: Supraspinatus > infraspinatus > subscapularis > teres minor
    - Long head of biceps near top of bicipital groove (genu of biceps tendon)
    - Upper limbs: Common extensor tendons of elbow, wrist extensors
    - Lower limbs: Hamstrings & adductor, patellar, Achilles, & posterior tibialis tendons
  - US features
    - Focal, nodular, or diffuse tendon enlargement (from mild to severe)
    - Increasing loss of normal fibrillar echotexture
    - Increasing tendon hypoechogenicity
    - Tendon hyperemia
      - Common extensor & flexor tendon origins, patellar, Achilles, & posterior tibialis tendons
    - ± partial tear
      - Intrasubstance, avulsive-type, or full-thickness tears
      - Common in moderate to severe tendinosis
      - Should not be confused with dilated vascular channels within hyperemic tendon
    - ± tendon sheath effusion
    - ± peritendinitis with inflammation of soft tissues around tendon or paratenon
    - ± reactive change at bony insertional area
      - Hyperostotic or resorptive bone change with cortical irregularity
    - ± dystrophic calcification within tendon
    - ± bursitis (Achilles)
  - Calcific tendinosis
    - Calcium hydroxyapatite crystal deposition
    - Rotator cuff > any tendon can be affected
    - Formative & resting phase → early resorptive phase → late resorptive phase

Helpful Clues for Less Common Diagnoses

- **Acute Proliferative Tenosynovitis**
  - Due to rheumatologic disease, gout, or infection
  - Tendons affected
    - Commonly affects common flexor tendon sheath (ulnar bursa) of hand
      - Ulnar bursa extends from just proximal to just distal to carpal tunnel
      - Communicates with flexor digitorum tendon sheath of fingers in 10% of normal subjects & radial bursa in 5% of normal subjects
      - Ulnar bursal infection may also spread to space of Parona (potential space superficial to pronator quadratus muscle)
  - Salient features
    - Distention of tendon sheath with minimal or no tendon swelling
    - Synovial proliferation within tendon sheath > tendon sheath fluid
    - Hyperemia predominates around, rather than within, tendon sheath
- **Acute Exudative Tenosynovitis**
  - Due to acute infection ± foreign body following penetrating trauma
  - Salient features
    - Fluid accumulation within sheath with little or no synovial proliferation
    - Speckled echogenic fluid
      - Speckles due to aggregates of purulent material
    - Mild to moderate tendon swelling
      - ± indistinct tendon margins if infection established & severe
    - Hyperemia around, rather than within, tendon sheath
    - Infection may spread to surrounding tissues

- **Chronic Active Tenosynovitis**
  - Due to rheumatologic disease, gout, or infection
  - Salient features
    - Hyperemia is predominantly within tendon sheath; synovium is visibly hypervascular
      - Synovial proliferation particularly prevalent in tuberculous tenosynovitis
- **Chronic Inactive Tenosynovitis**
  - Salient features
    - Tendon sheath distended with fluid or synovial proliferation, though not hypervascular
    - If adhesions present, tendon sheath may be markedly distended focally & noncompressible
- **Gout/Pseudogout**
  - Tophi are more common with chronic gout
    - Foot > knee > wrist & hand
    - Occur adjacent to bursa/tendon/ligaments & fascia
    - Range from soft to hard tophi
      - Soft tophi: Little mineralized tissue with scattered crystal aggregates & comet-tail artifacts
      - Hard tophi: Heavily mineralized tissue with only superficial margin being seen due to dense posterior acoustic shadowing
    - Acute phase → intercritical phase
  - Salient features
    - Irregular hypovascular mass in & around tendon with echogenic crystalline aggregates
      - Marginal hyperemia during acute phase
- **Xanthoma**
  - Feature of familial hyperlipidemia
    - Accumulation of foamy histiocytes, cholesterol ester, & giant cells within tendons
  - Tendons affected
    - Achilles tendon > patellar tendon > extensor expansions of fingers
  - Salient features of xanthoma
    - Generalized tendon swelling, increased tendon hypoechogenicity, & mild hypervascularity
    - Following US signs help differentiate xanthoma from tendinosis
      - Nodular intratendinous hypoechoic areas (xanthoma)
      - Less insertional cortical irregularity
      - More diffuse dystrophic calcification
      - Less peritendinitis
      - Less tendon tears
      - Less tendon hyperemia
    - Other signs to distinguish from tendinosis
      - Known familial hyperlipidemia
      - Features of atherosclerosis (increased intima-media thickness)
      - Nonpainful tendon swelling
      - Xanthoma will reduce with lipid-lowering treatment
- **Amyloidosis**
  - Accumulation of protein fibrils, which become insoluble & are deposited either in specific tissues (localized amyloidosis) or throughout body (generalized amyloidosis)
  - Extracellular deposition of protein fibrils (amyloid)
    - > 20 different protein fibrils may produce amyloidosis
    - Diagnosis dependent on histology of biopsy specimen (Congo red staining & apple-green birefringence under polarized light)
  - May be primary or secondary
  - **Primary amyloidosis**
    - Genetically inherited disorder of protein metabolism
  - **Secondary amyloidosis**
    - In patients with long-term hemodialysis, myeloma, & chronic inflammatory states
  - Salient features
    - Amyloid deposited in synovium, joint capsule, tendons (supraspinatus, biceps, flexor digitorum tendons), ligaments, nerves, & intervertebral disc
      - Hypoechoic tendon thickening
      - ± tendon sheath or bursal effusion & hypervascularity with hypoechoic, inhomogeneous nodular thickening around tendons

Tendinosis

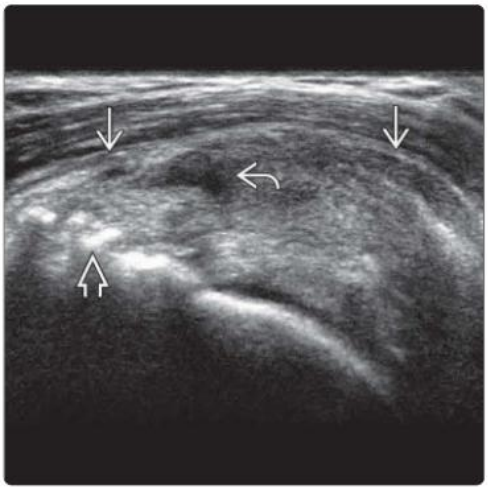

Tendinosis

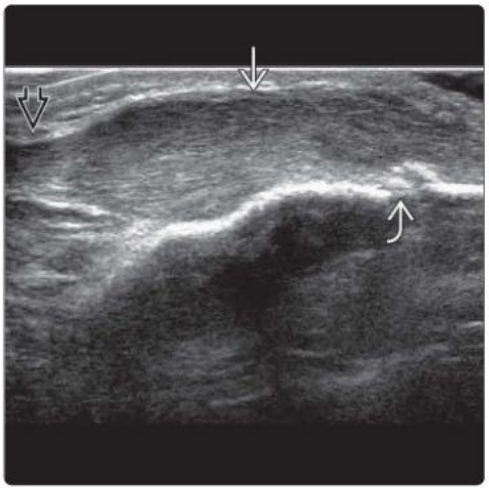

(Left) *Longitudinal US shows a markedly thickened & diffusely hypoechoic supraspinatus tendon ⇨ compatible with severe tendinosis. There is insertional cortical irregularity ⇨, & there are small intrasubstance tears ⇨.* **(Right)** *Longitudinal US of distal patellar tendon shows severe, focal thickening with hypoechogenicity & loss of normal fibrillar pattern ⇨ due to severe tendinosis. Mild cortical irregularity at tibial tuberosity ⇨ & more normal appearance of patellar tendon are seen proximally ⇨.*

(Left) *Graphic shows grades of tendinosis. The severity of tendinosis & the degree of surrounding peritendinitis ➡ should be independently graded. The likelihood of tendon tear increases with severity of tendinosis. Likewise, the likelihood of clinical response to antiinflammatory medication increases with severity of peritendinitis.* **(Right)** *Graphic shows normal tendon structure with tendon sheath ➡ included for illustrative purposes. Most tendons do not have a tendon sheath.*

Tendinosis

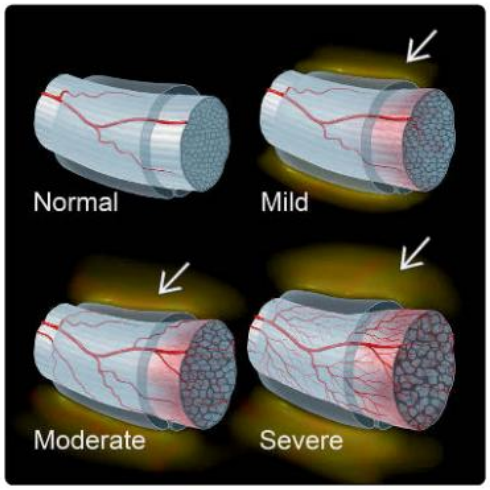

Tendinosis

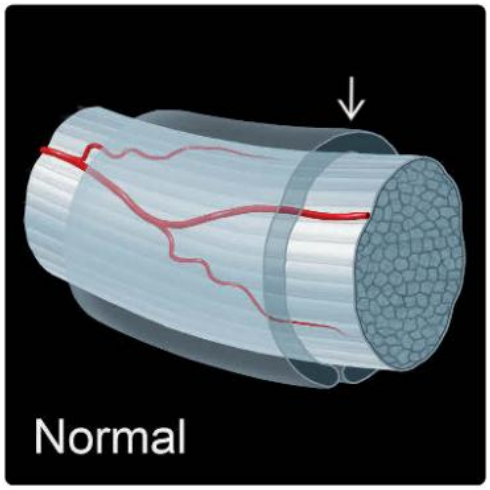

(Left) *Graphic shows mild tendinosis with mild tendon swelling (due to proteoglycan accumulation) & mild intratendinosis hyperemia. Intrinsic vascularity is not a feature of normal tendons.* **(Right)** *Moderate tendinosis with more severe tendon swelling, proteoglycan deposition, & intratendinosis hyperemia is shown. Although tendinosis & peritendinitis (seen as peritendinous edema & hyperemia) ➡ severity are broadly interrelated, both features should be independently graded as mild, moderate, or severe.*

Tendinosis

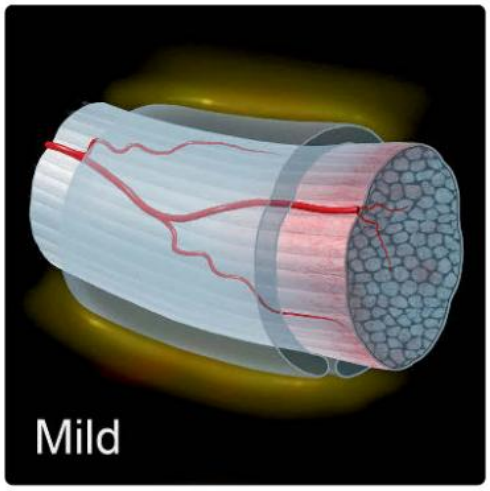

Tendinosis

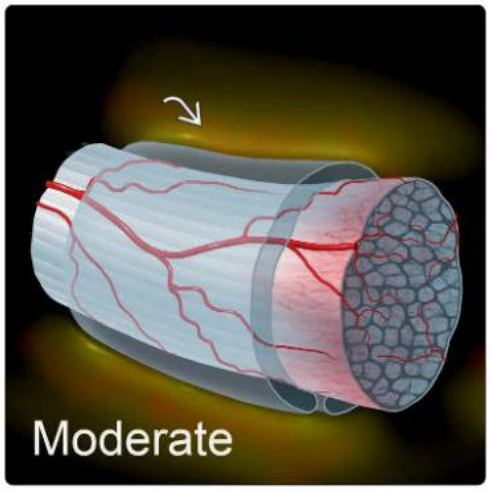

(Left) *Severe tendinosis with more severe tendon swelling & intratendinosis hyperemia ➡ (manifest on US as tendon swelling, tendon hypoechogenicity, loss of fibrillar echo pattern, & ↑ tendon hyperemia) is shown. Mild tendon sheath swelling is usually seen, but this is a manifestation of peritendinitis rather than primary tendon sheath inflammation.* **(Right)** *Photograph shows patellar tendinosis. The normal tendon is glistening white ➡, & the area with severe tendinosis is yellow ➡. (Courtesy C. K. Ming, MD.)*

Tendinosis

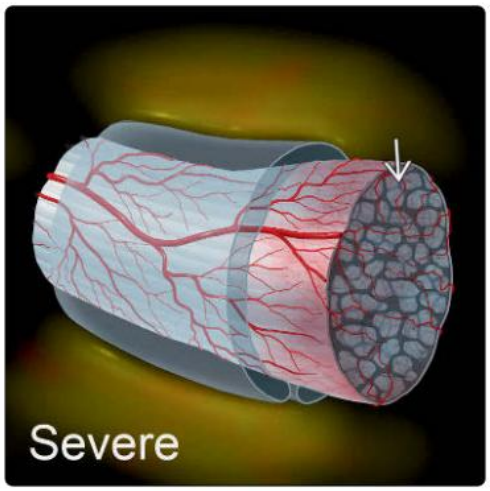

Tendinosis

Tendinosis

Tendinosis

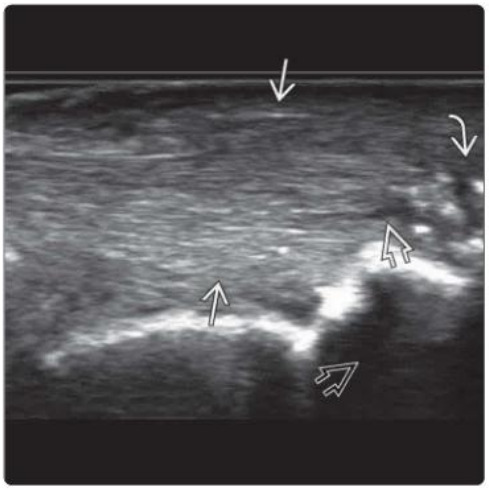

(Left) *Clinical photograph shows severe focal swelling of the posterior heel region, which corresponds to the swollen Achilles tendon.* **(Right)** *Longitudinal US in the same patient shows a diffusely thickened Achilles tendon, indicative of severe tendinosis. The fibrillary pattern is still preserved. Several small areas of dystrophic calcification are present at the insertion with a small intrasubstance tear. There is a prominent posterior calcaneal hyperostotic ridge.*

Tendinosis

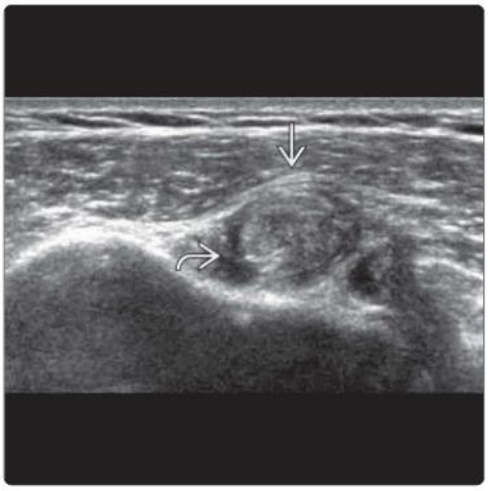

Tendinosis

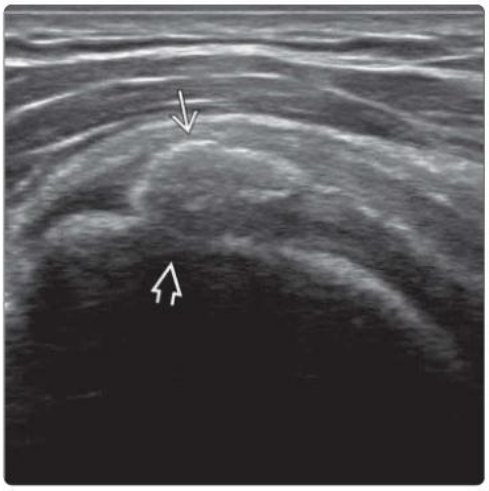

(Left) *Transverse US shows moderate to severe biceps tendinosis at proximal end of bicipital groove. The tendon is rounded & heterogeneous with an irregular margin. There is minimal surrounding synovial proliferation.* **(Right)** *Longitudinal US supraspinatus tendon in a 63-year-old woman shows a medium-sized (11 mm wide), calcific deposition overlying the greater tuberosity insertional area, constituent with calcific tendinosis. Aspiration, dry needling, & steroid injection were performed.*

Acute Proliferative Tenosynovitis

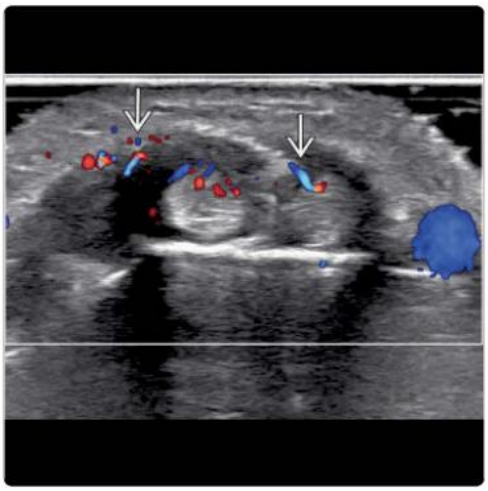

Acute Proliferative Tenosynovitis

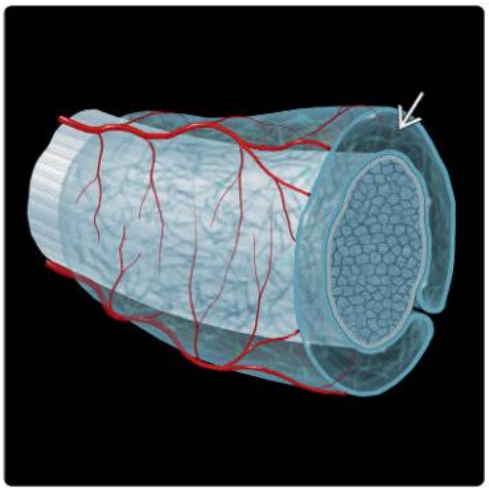

(Left) *Transverse US shows acute tenosynovitis of extensor carpi radialis brevis & longus tendons with tendon sheath distended by fluid & synovial thickening with hyperemia. The tendons are not swollen.* **(Right)** *Graphic shows acute proliferative tenosynovitis, which is usually due to repetitive trauma or a systemic inflammatory disorder. Tendon swelling occurs due to synovial proliferation. Hyperemia is limited to the tendon sheath surface.*

(Left) *Graphic shows different types of tenosynovitis. Tenosynovitis is a disease of the tendon sheath. Unlike tendinosis, which can affect any tendon, tenosynovitis can only affect those tendons with a tendon sheath.* **(Right)** *Graphic shows normal tendon & tendon sheath ➡ for comparative purposes. Most, but not all, of the tendons of the wrist/hand & the ankle/foot have a tendon sheath. The long head of biceps has a tendon sheath. The patellar & Achilles tendons have a paratenon.*

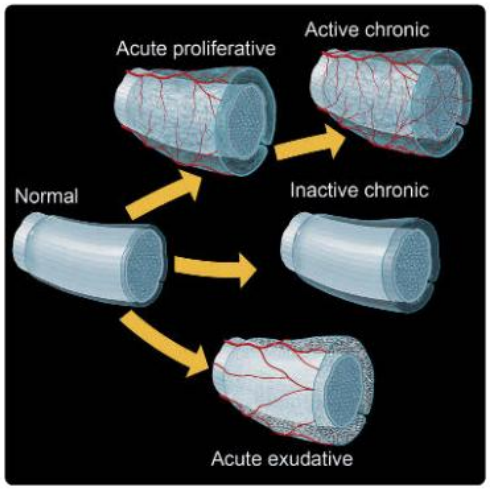

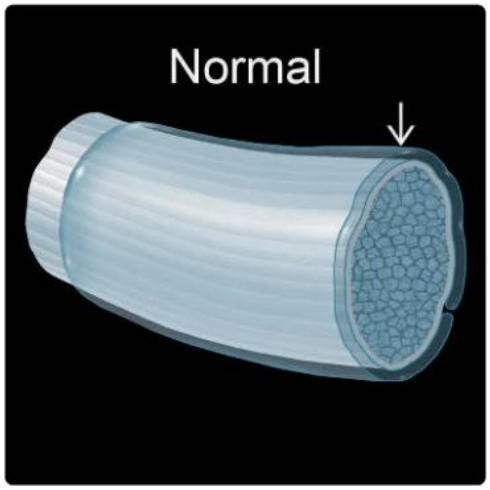

(Left) *Graphic shows acute exudative tenosynovitis, usually secondary to bacterial infection/penetrating trauma & is rapidly progressive. Purulent exudate ➡ can be aspirated. Hyperemia occurs around rather than within the tendon sheath.* **(Right)** *Transverse color Doppler US of extensor digitorum communis tendon at the wrist ⇨ shows moderate tenosynovial proliferation ⇨ as well as synovial hyperemia after a dog bite, compatible with chronic active tenosynovitis.*

Acute Exudative Tenosynovitis

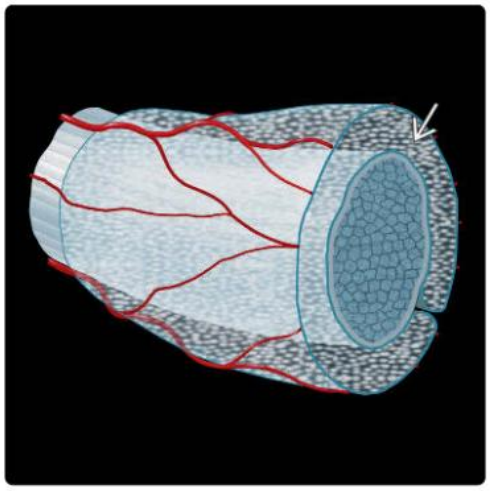

Chronic Active Tenosynovitis

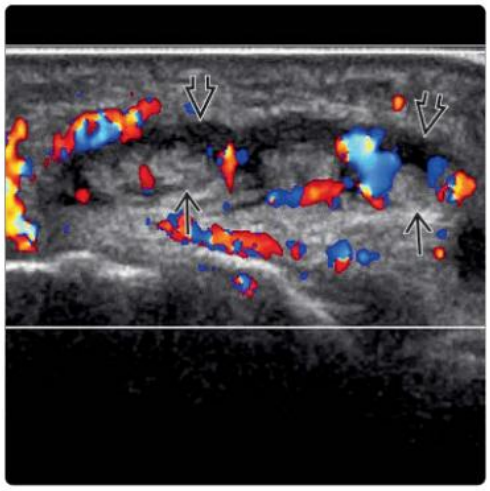

(Left) *Chronic proliferative tenosynovitis shows hyperemic synovial proliferation ➡ that fills distended tendon sheath. Hyperemia may extend into tendon which has normal echogenicity but only slightly enlarged due to edema.* **(Right)** *Transverse US in a patient with wrist swelling for 9 months shows severe extensor digitorum communis tenosynovial proliferation ➡ with small tendon sheath effusion ➡. Mildly swollen extensor tendons ⇨ are a secondary feature of tenosynovitis. Note early rice body formation ➡.*

Chronic Active Tenosynovitis

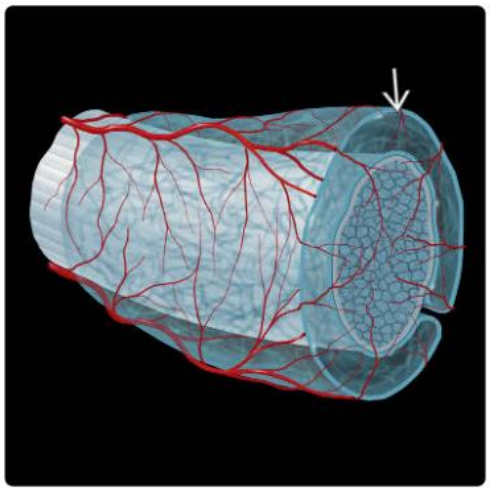

Chronic Active Tenosynovitis

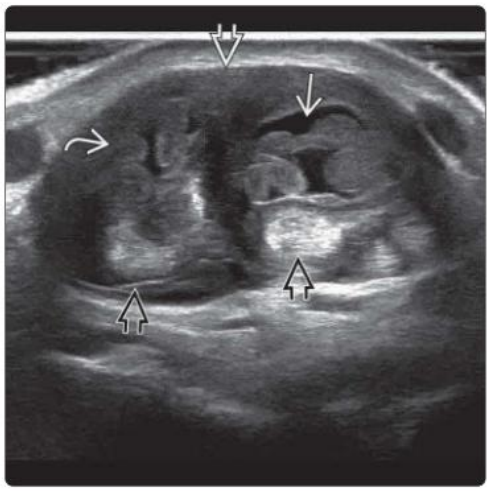

Chronic Active Tenosynovitis

Chronic Inactive Tenosynovitis



(Left) *Color Doppler US in the same patient's wrist shows severe tenosynovial hyperemia compatible with chronic active tenosynovitis. Biopsy revealed chronic necrotizing granulomatous inflammation due to TB.* **(Right)** *Graphic shows chronic inactive tenosynovitis. The tendon sheath is distended with serous fluid ➡. This distention may sometimes be severe & localized due to tendon sheath adhesions. Little or no hyperemia is present.*

Chronic Inactive Tenosynovitis

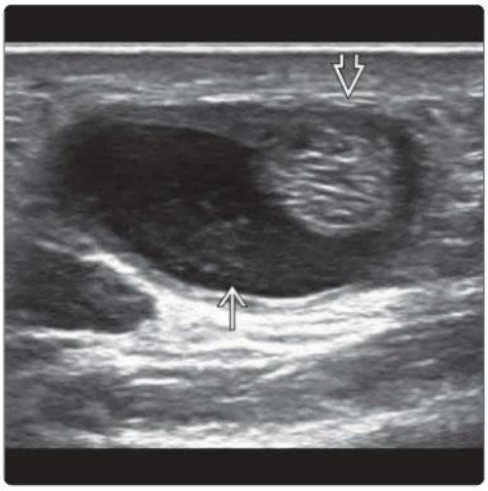

Gout/Pseudogout

(Left) *Transverse US of flexor carpi radialis tendon shows a moderate amount of largely anechoic fluid distending the tendon sheath ➡. The tendon is eccentrically located ➡. No hyperemia was present (not shown), compatible with chronic inactive tendosynovitis.* **(Right)** *Longitudinal US of the wrist in a patient with known gout shows marked distention of the common extensor tendon sheath with small ➡ & large ➡ crystal aggregates (snowstorm appearance) due to a gouty tenosynovitis.*

Gout/Pseudogout

Xanthoma

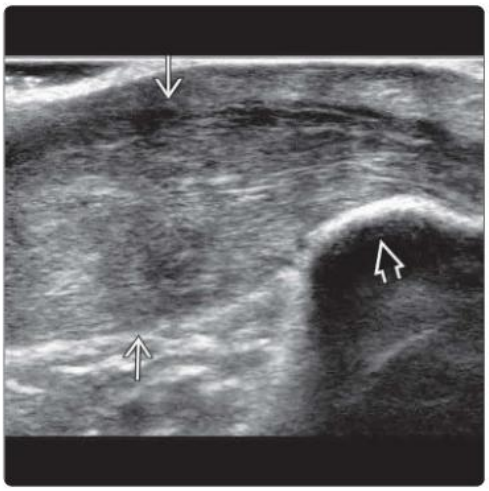

(Left) *Longitudinal US in a 75-year-old man with known gout & dorsal midfoot swelling for 1 year shows speckled gouty crystal deposition ➡ expanding the tibialis anterior tendon ➡ with a mildly distended tendon sheath ➡.* **(Right)** *Longitudinal US of Achilles tendon ➡ in a patient with familial hypercholesterolemia shows diffuse tendon swelling close to the calcaneal insertion ➡ due to deposition of cholesterol-rich lipid within the tendon.*

PART IV
SECTION 3

Nerve, Fascia, and Bone

Swollen Nerve	890
Fascial Lesion	896
Bone Surface Lesion	902

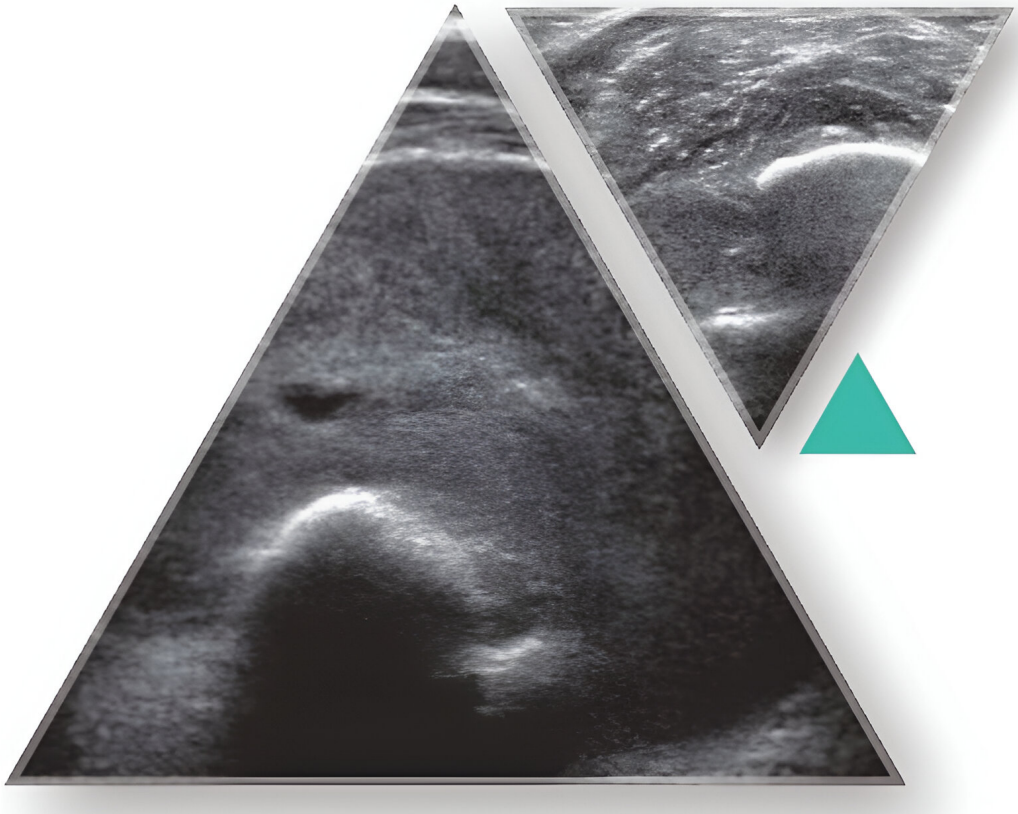

DIFFERENTIAL DIAGNOSIS

Common

- Nerve Entrapment
- Nerve Sheath Tumor

Less Common

- Nerve Injury
- Perineural Fibrosis
- Neuralgic Amyotrophy
- Immune-Mediated Peripheral Neuropathy
- Fibrolipomatous Hamartoma
- Intraneural Lipoma
- Intraneural Ganglion
- Metastases
- Acromegaly
- Charcot-Marie-Tooth Disease
- Leprosy

ESSENTIAL INFORMATION

Key Differential Diagnosis Issues

- Best to identify nerve at specific target point → follow it distally or proximally in transverse plane
  - Longitudinal plane useful when evaluating nerve trauma, tumor, & hourglass constriction
- When assessing nerve compression, important to measure cross-sectional area (CSA) of nerve at specific locations
  - Continuous boundary tracing of nerve provides more accurate CSA measurement than best-fitting ellipse method
  - Contralateral side is unreliable internal reference, as contralateral, subclinical, compressive neuropathy is common
- When assessing noncompressive nerve disorder, comparison with asymptomatic contralateral side is very helpful
- Nerve measurements are ~ 15% smaller on US than MR
  - US measurements do not include epineurium, which is included on MR measurements

Helpful Clues for Common Diagnoses

- **Nerve Entrapment**
  - Site-specific entity
  - Most common sites in upper limb are
    - Median nerve: Carpal tunnel
    - Ulnar nerve: Cubital tunnel
    - Radial nerve: Supinator inlet
  - Most common sites in lower limb are
    - Sciatic nerve: Piriformis
    - Lateral cutaneous nerve of thigh: Inguinal ligament near anterior superior lilac spine
    - Tibial nerve: Tarsal tunnel
    - Peroneal nerve: Fibular head
  - Swelling of nerve proximal to or at site of compression is main sign of nerve compression
  - Infrequently, neural hyperemia may be seen as feature of nerve ischemia
- **Nerve Sheath Tumor**
  - Tumor of peripheral nerve
    - Schwannoma: Tumor of Schwann cells lining axons
    - Neurofibroma: Tumor of connective tissue between axons
  - Hypoechoic, fusiform-shaped tumor of nerve
  - Continuity with entering or exiting nerve seen in 50% ± neural thickening
    - Tumors arising from small nerves may not have visible neural continuity
  - Anechoic areas due to myxoid or fluid accumulation
    - Some schwannomas may be predominantly anechoic & cyst-like ("ancient schwannoma")
  - ± hyperechoic areas due to hemorrhage or calcification
  - Posterior acoustic enhancement
  - Moderately hyperemic on color Doppler US
  - Malignant peripheral nerve sheath tumor is more likely if
    - Patient has neurofibromatosis type 1
    - Tumor is large (> 5 cm), ill defined, heterogeneous ± rapidly growing
  - FDG PET with SUV > 2.0 has quite high (80-90%) sensitivity & specificity for malignant peripheral nerve sheath tumor associated with neurofibromatosis

Helpful Clues for Less Common Diagnoses

- **Nerve Injury**
  - Most nerve injuries are clinically obvious
  - US of nerve injury is used to assess whether nerve is
    - Not torn (neurapraxia), partially torn (axonotmesis), or completely torn (neurotmesis)
  - Swollen nerve caused by
    - Reparative fibrosis at site of tear
    - Traumatic neuroma: Tangled proliferative mass of axons, Schwann cells, & fibrosis
- **Perineural Fibrosis**
  - Common in brachial plexus following radiotherapy for carcinoma of breast or upper aerodigestive tract
  - Following injury to peripheral nerve or following excision of nerve sheath tumor
  - Localized nerve swelling with hyper- to hypoechoic fibrotic tissue surrounding & obscuring nerve outline
- **Neuralgic Amyotrophy**
  - Sudden-onset, idiopathic, unilateral, sensorimotor, peripheral nerve palsy, typically of upper limb
    - Acuteonset, severe, unilateral, neuropathic upper limb pain ≥ focal muscle weakness & atrophy ≥ gradual motor recovery
  - Often multifocal; previously known as Parsonage-Turner syndrome when affecting suprascapular nerve
  - Predominantly clinical diagnosis, as imaging can occasionally be entirely normal
  - US can show swollen nerve ± nerve constriction (hourglass configuration) & fascicular entwinement
  - MR more sensitive in depicting muscle edema ± muscle atrophy
- **Immune-Mediated Peripheral Neuropathy**
  - Chronic inflammatory demyelinating polyneuropathy (CIDP) & multifocal mononeuropathy (MMN) are acquired immune-mediated peripheral neuropathies
    - CIDP affects sensory & motor function bilaterally & all 4 limbs
    - MMN is purely motor & usually affects only upper limbs

  - Neural enlargement seen on US, particularly proximally & in nonentrapment sites
  - Examination of vagus nerve in neck (> 2 mm²), median nerve in midupper arm (> 13.8 mm²), median nerve in midforearm (> 9.1 mm²), ulnar nerve in midupper arm (> 12.1 mm²), & tibial nerve 7 cm above medial malleolus (> 12.2 mm²) are useful screening points
- **Fibrolipomatous Hamartoma**
  - Benign, fibrofatty malformation of peripheral nerve
  - Most cases present before 30 years of age
    - 1/3 associated with finger enlargement or macrodactyly ("macrodystrophia lipomatosa")
  - Majority involve median nerve
  - Soft, slow-growing, fusiform swelling of nerve
  - Markedly swollen nerve with coaxial cable-like appearance
  - All neural elements are swollen to comparable degree with thickened, hypoechoic fascicles embedded in echogenic stroma background
- **Intraneural Lipoma**
  - Arise from adipose tissue embedded in nerve
  - Most commonly of median or ulnar nerve
  - May cause compressive neuropathy
- **Intraneural Ganglion**
  - May be extraneural or intraneural
  - Accumulation of myxoid fluid encased in fibrous capsule within nerve
    - Due to communication between joint & parent nerve via small articular branch
    - Synovial fluid tracts along small articular branch & accumulates in parent nerve
      - Superficial branch of peroneal nerve is most commonly affected
  - Hypoechoic mass within nerve, which can extend longitudinally along nerve
  - Can cause neural compression → pain, paresthesia, weakness, & muscle atrophy
- **Metastases**
  - Brachial plexus is relatively common site of neural metastases, from lung or breast primary
    - Hypoechoic, irregular, hypervascular mass infiltrating brachial plexus
    - Discrete mass, rapid onset & growth, predominant pain symptoms, tumoral hyperemia, & involvement of lower part of plexus all favor metastases over fibrosis
      - Still may need biopsy or fine-needle aspiration for cytology to differentiate from radiotherapy-induced perineural fibrosis
- **Acromegaly**
  - Peripheral nerves ~ 2x as large in acromegalic patients as normal subjects
  - Degree of nerve enlargement related to clinical control, duration, & insulin-like growth factor 1 level
- **Charcot-Marie-Tooth Disease**
  - Heterogeneous group of inherited peripheral nervous system disorders
  - Onset usually before 30 years of age
    - Progressive peripheral weakness, ↓ tendon reflexes, peroneal muscle atrophy, pes cavus, mild sensory loss
  - Examine for swollen vagus nerve at carotid bifurcation, median & ulnar nerves midupper arm, tibial & peroneal nerves at popliteal fossa to distinguish Charcot-Marie-Tooth Type 1 patients from healthy subjects
- **Leprosy**
  - Chronic granulomatous disease by *Mycobacterium leprae*
  - Affects peripheral nerves, upper respiratory tract mucosa, & skin
  - Wide spectrum of US abnormalities, depending on disease duration, activity ± compression
    - Early disease affects intradermal nerves → no visible US abnormality
    - Active disease → swelling of endoneural space, thickening of individual fascicles, & hyperemia
    - Longstanding inactive disease → nerves less swollen than in active disease with overall ↑ echogenicity & ↓ visibility of fascicles

SELECTED REFERENCES

1. Yip SWY et al: Ultrasound accuracy for brachial plexus pathology. Clin Radiol. 79(7):e916-23, 2024

Nerve Entrapment

Nerve Entrapment

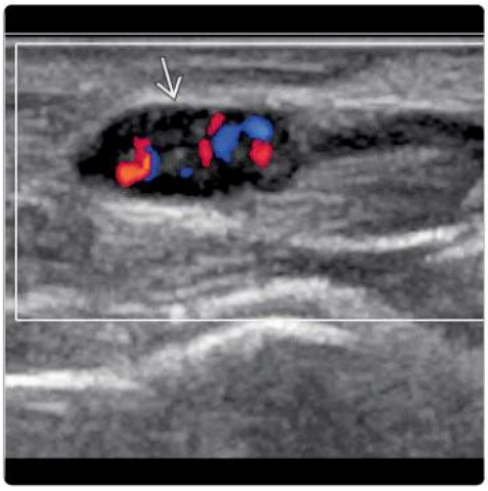

(Left) *Transverse US just proximal to the carpal tunnel shows moderate (16-mm²) swelling of the median nerve ⇨ deep to the palmaris longus tendon ⇨, consistent with carpal tunnel syndrome (CTS). A CSA > 14 mm² is used to diagnose CTS without including the echogenic epineurium ⇨.* **(Right)** *Transverse color Doppler US shows moderate hyperemia of the median nerve ⇨ just proximal to the carpal tunnel. Neural hyperemia is seen in some CTS patients. It has low sensitivity but high specificity for CTS.*

(Left) *Longitudinal US shows moderate swelling of the deep branch of the radial nerve ⇨ just proximal to the supinator tunnel inlet between the superficial ⇨ and deep ⇨ heads of the supinator muscle, compatible with entrapment at the arcade of Frohse.* **(Right)** *Longitudinal US shows a nerve sheath tumor ⇨ of the deep peroneal nerve ⇨ anterior to the ankle joint ⇨. The proximal part of the deep peroneal nerve is markedly thickened.*

Nerve Entrapment

Nerve Sheath Tumor

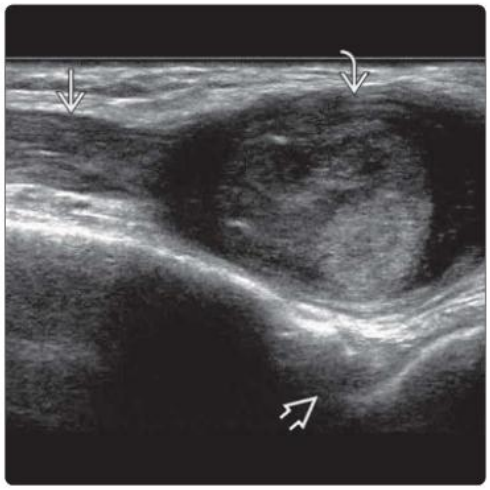

(Left) *Longitudinal US shows a medium-sized, hypoechoic nerve sheath tumor ⇨ of the medial sural cutaneous nerve ⇨ between the medial and lateral heads of the gastrocnemius muscle (not shown). The thickened sural nerve alongside the tumor is visible. An underlying vein ⇨ is moderately compressed.* **(Right)** *Longitudinal color Doppler US in the same patient shows characteristic hyperemia of the nerve sheath tumor.*

Nerve Sheath Tumor

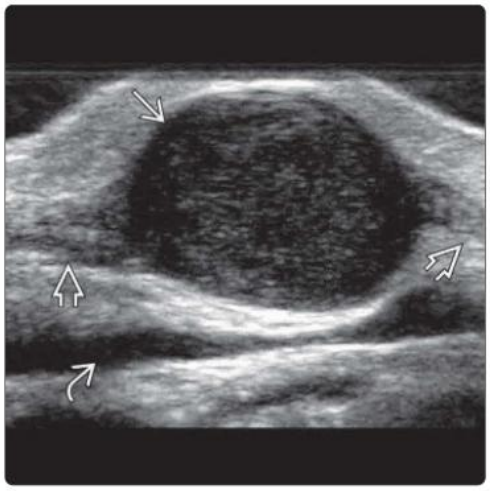

Nerve Sheath Tumor

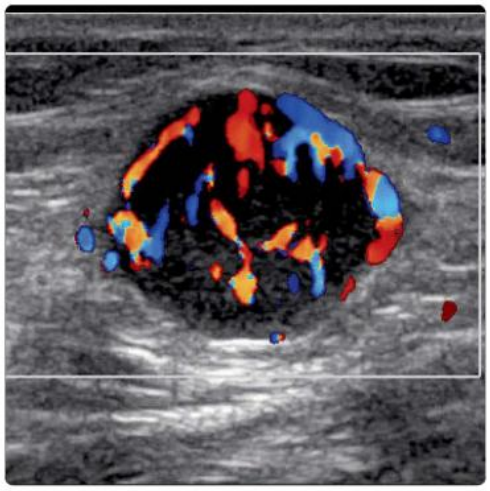

(Left) *Longitudinal US shows a tumor of the median nerve ⇨ with solid ⇨ and myxoid ⇨ areas. The median nerve just distal to the tumor is slightly thickened.* **(Right)** *Photograph of a patient with known neurofibromatosis shows a mass located deep to a large café au lait mark ⇨ on the lower thoracic region posteriorly. This mass was enlarging clinically.*

Nerve Sheath Tumor

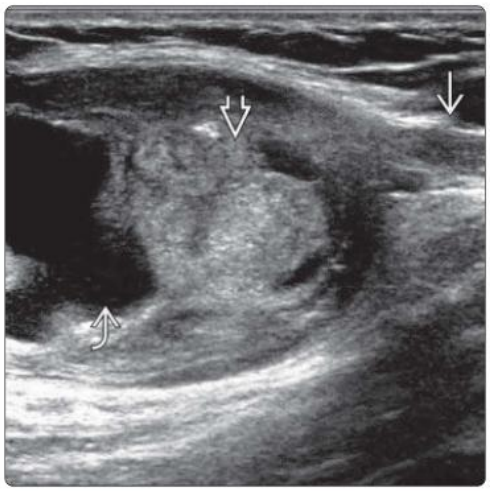

Nerve Sheath Tumor

Nerve Sheath Tumor

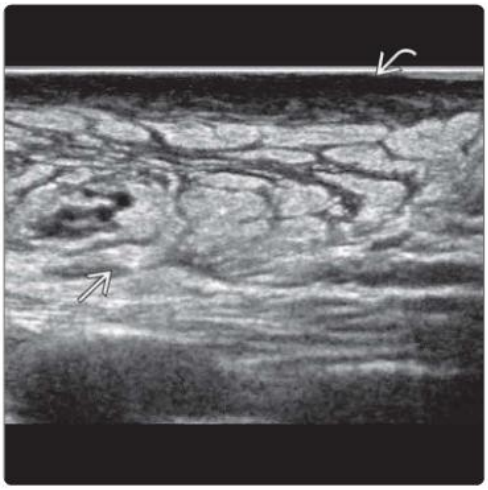

Nerve Sheath Tumor

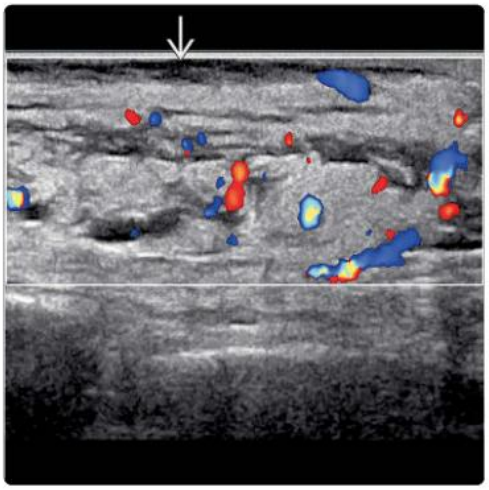

(Left) *Longitudinal US of the same patient shows thickened, hyperechoic subcutaneous tissue ⇨ and hypoechoic dermal and subdermal tissue ⇨. Biopsy revealed a myxoid spindle cell tumor, consistent with a plexiform neurofibroma. There was no evidence of malignancy.* **(Right)** *Longitudinal color Doppler US of the same patient shows moderate hyperemia of the plexiform neurofibroma ⇨.*

Nerve Sheath Tumor

Nerve Sheath Tumor

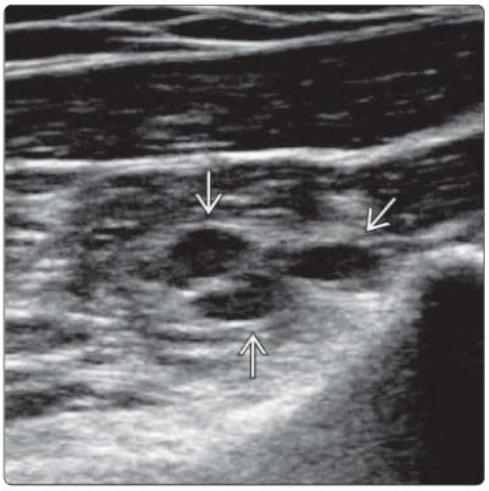

(Left) *Longitudinal US shows an elongated plexiform nerve sheath tumor ⇨ present in the proximal arm. The tumor was located between the brachialis and biceps muscles. The underlying humeral shaft ⇨ is normal.* **(Right)** *Transverse US of the same patient shows the tubular appearance ⇨ of the plexiform neurofibroma. Plexiform neurofibromas occur almost invariably in patients with neurofibromatosis.*

Nerve Sheath Tumor

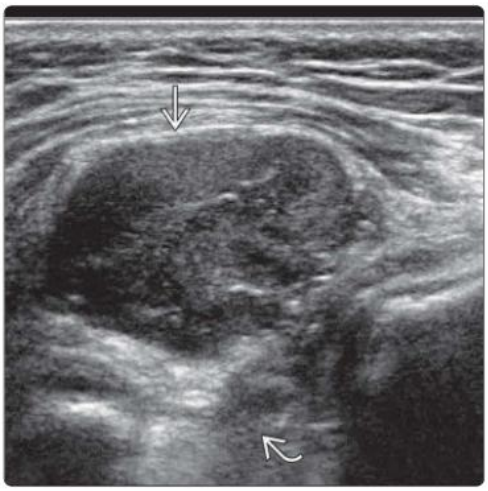

Nerve Sheath Tumor

(Left) *Transverse US in a patient with a 2-month history of lower limb pain and buttock swelling shows a large mass ⇨ just external to the sciatic notch ⇨.* **(Right)** *Longitudinal US in the same patient shows severe swelling of the sciatic nerve ⇨ continuous with the more proximally located mass. US-guided biopsy of the mass revealed a malignant peripheral nerve sheath tumor. This patient did not have neurofibromatosis.*

(Left) *Longitudinal US shows the median nerve ➡ following a dog bite. The nerve is mildly swollen with injury to the more superficial part. The deep fascicles ➡ are intact. The overlying soft tissues ➡ are also swollen.* **(Right)** *Longitudinal US in a patient with a previous knife injury to the volar wrist shows moderate, diffuse swelling ➡ of the median nerve ➡ due to posttraumatic fibrosis. Injury to the underlying flexor tendons is also apparent.*

Nerve Injury

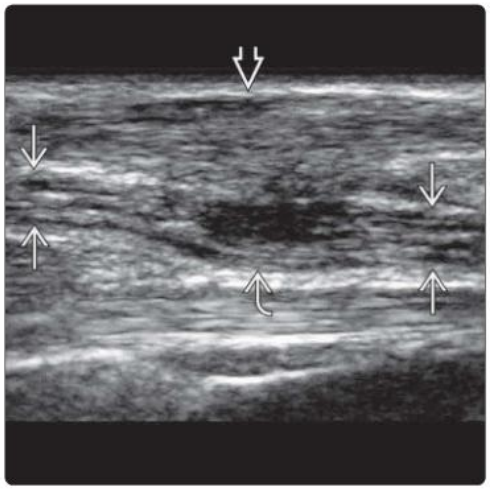

Nerve Injury

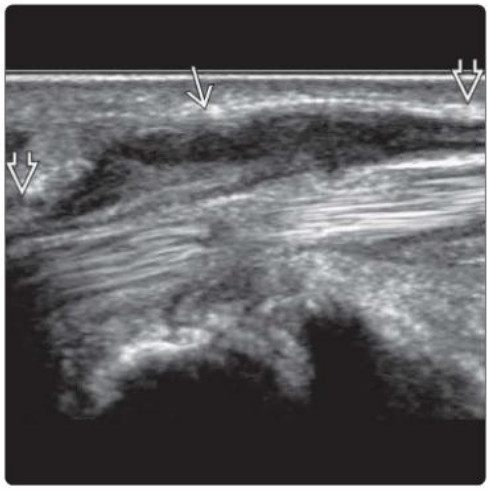

(Left) *Longitudinal US of the brachial plexus shows thickened transected C5 ➡ and C6 ➡ roots with a large amount of bridging fibrosis ➡ between these roots distally.* **(Right)** *Transverse US shows marked swelling of the medial nerve ➡ in the midforearm due to postsurgical fibrosis following previous resection of schwannoma.*

Nerve Injury

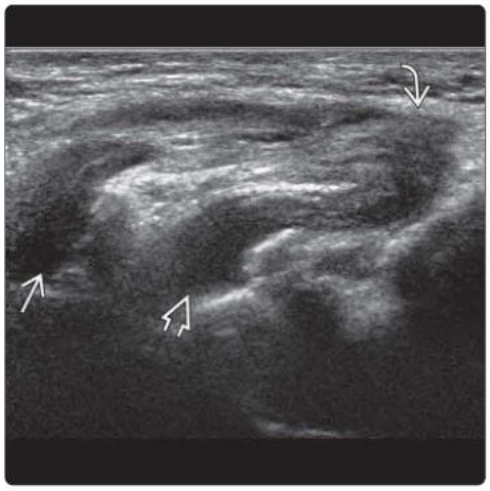

Perineural Fibrosis

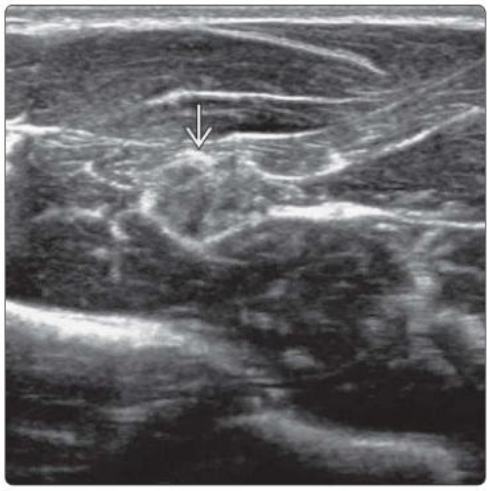

(Left) *Transverse US of the neck in patient who had previous radiotherapy shows severe thickening and clumping of the brachial plexus divisions ➡ superomedial to the subclavian artery ➡ due to irradiation plexopathy.* **(Right)** *Transverse US in a 39-year-old man with acute radial nerve palsy shows enlargement of the radial nerve ➡ (14 mm²) to 3x the normal size posterior to the humeral shaft ➡ due to neuralgic amyotrophy. No hourglass constriction was evident on longitudinal US (not shown).*

Perineural Fibrosis

Neuralgic Amyotrophy

Immune-Mediated Peripheral Neuropathy

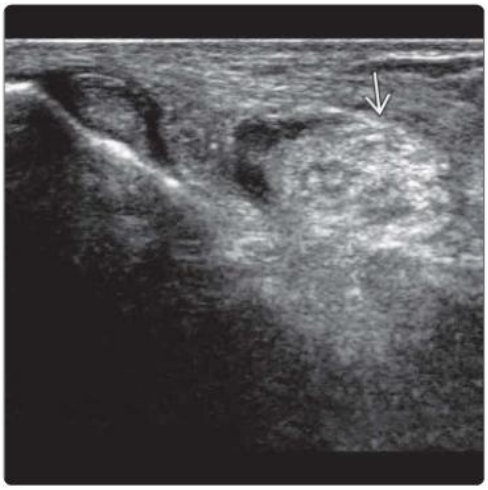

Fibrolipomatous Hamartoma

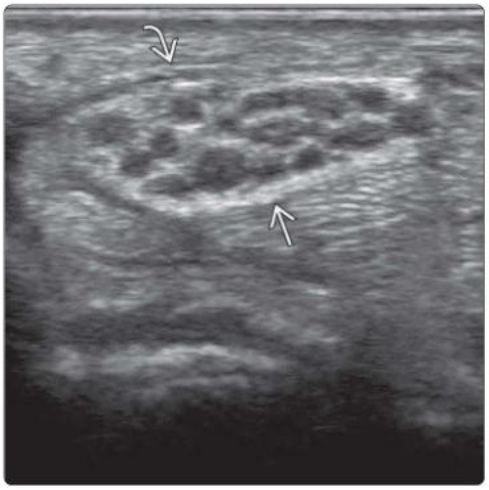

(Left) *Transverse US in a man with polyneuropathy shows a markedly thickened tibial nerve ➡ at the tarsal tunnel. Similar findings were present on the contralateral side. The clinical picture was compatible with chronic inflammatory demyelinating polyneuropathy.* **(Right)** *Transverse US proximal to the carpal tunnel inlet shows an enlarged (72-mm²) median nerve ➡ with thickened, hypoechoic nerve fascicles (coaxial cable appearance) deep to antebrachial fascia ➡ due to a fibrolipomatous hamartoma.*

Intraneural Lipoma

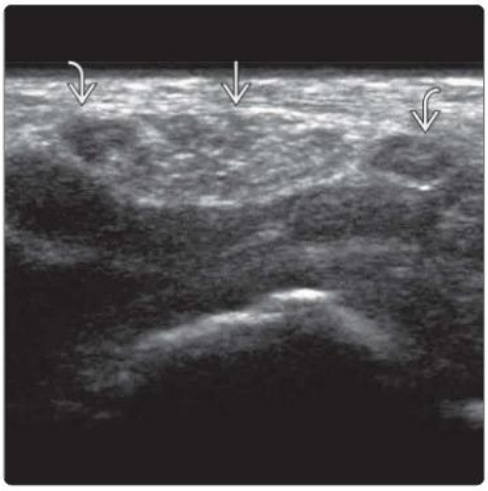

Metastases

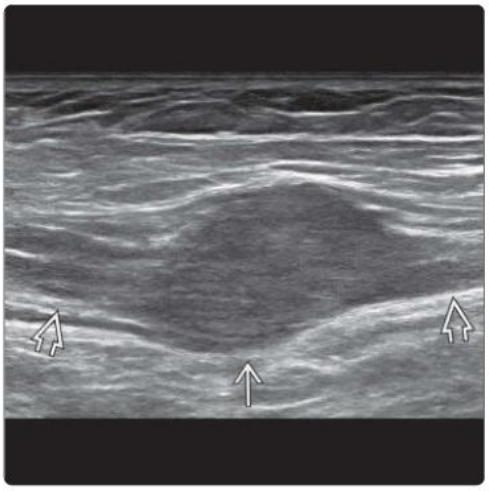

(Left) *Transverse US of the wrist shows a hyperechoic lipoma ➡ located between both components of the bifid median nerve ➡.* **(Right)** *Longitudinal US of the proximal thigh in a man with previously resected high-grade malignant spindle cell sarcoma of the foot shows focal enlargement ➡ of the ipsilateral sciatic nerve ➡. Sciatic nerve metastases were confirmed on US-guided biopsy.*

Metastases

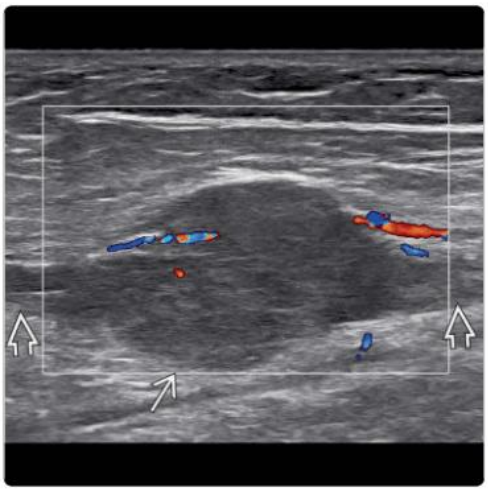

Leprosy

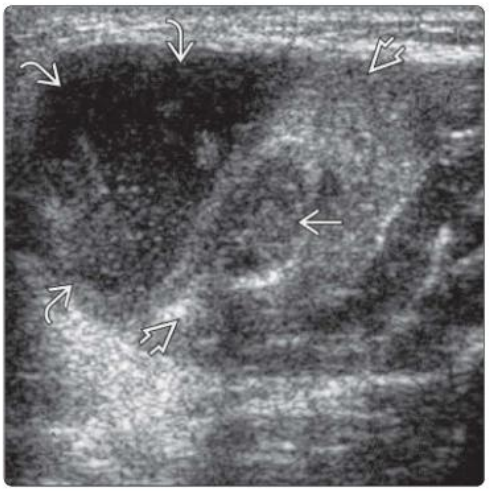

(Left) *Longitudinal color Doppler US of the popliteal fossa in the same patient shows a separate metastasis ➡ in the tibial nerve ➡.* **(Right)** *Transverse US proximal to the elbow shows a thickened ulnar nerve ➡ with marked surrounding edema, echogenic granulation tissue ➡, and abscess ➡ due to leprosy. Perineural abscess is an uncommon feature of leprosy. (Courtesy S. Lodge, MD.)*

DIFFERENTIAL DIAGNOSIS

Common

- Plantar Fasciitis
- Plantar Fibroma

Less Common

- Plantar Fascial Tear
- Enthesopathic Fasciitis
- Investing Fascial Tear
- Nodular Fasciitis
- Chronic Fasciitis
- Infective Fasciitis
- Necrotizing Fasciitis
- Eosinophilic Fasciitis
- Dupuytren Disease
- Tumors Occurring Within Fascia

ESSENTIAL INFORMATION

Key Differential Diagnosis Issues

- Plantar fascia is thin, laminated, echogenic aponeurosis stretching between medial calcaneal tuberosity & plantar plates of metatarsophalangeal joints
  - Maintains medial longitudinal arch during weight bearing
  - Comprises 3 bands: Medial, central, & lateral
    - Central band is strongest & thickest
  - Plantar fascia slightly thinner in patients with pes planus
- Investing fascia is thin, laminated, echogenic tissue enveloping muscles of appendicular skeleton & trunk
- Fascial lesions tend to be site specific
- For most lesions, US is as accurate as MR or CT
- Fascial insertional lesions may be 1st manifestation of enthesopathy associated with peripheral spondylarthritis

Helpful Clues for Common Diagnoses

- **Plantar Fasciitis**
  - Probably caused by repetitive microtrauma ± microvascular injury
  - Common in runners (10%)
    - Other risk factors include faulty shoes, high-arched feet, short Achilles tendon, obesity, prolonged weight bearing, & heel fat pad atrophy
  - Affects central band attachment to medial calcaneal tuberosity
    - Bilateral in 1/3 of patients
  - Thickening of plantar fascia at calcaneal insertion
  - > 4.3-mm thickness considered abnormal
    - Hypoechogenicity & thickening of plantar fascia over short segment (~ 10 mm) at calcaneal insertion
    - ± loss of echogenic laminar pattern of plantar fascia ± perifascial edema
    - 4.0 mm = guideline rather than absolute measurement, as range of plantar fascial thickness in patients & normal subjects overlaps
    - Measurements taken at leading edge of calcaneus
    - The greater the plantar fascial thickening, the more likely the diagnosis of plantar fasciitis
    - Subclinical fascitis may be present on opposite side; therefore, exercise caution in using contralateral side as normal reference
  - ± plantar calcaneal spur
  - Small foci of dystrophic calcification as well as small intrafascial tears can sometimes be seen in thickened fascia at calcaneal insertion
  - ± edema, reduced lobulation, thinning or early fibrosis of overlying subcutaneous heel fat pad
  - Minimal focal hyperemia in < 10% of patients with plantar fasciitis
  - Many different treatments
    - Stretching
    - Massage (e.g., rolling tennis ball under affected area)
    - Orthosis, night splints
    - US-guided steroid injection
      - Risk of fascial rupture & heel fat pad atrophy
      - Inject into perifascial area rather than plantar fascia
    - US-guided platelet-rich plasma injection
    - Low-level laser therapy
    - Combined cryo-US therapy
    - Extracorporal shock wave therapy
    - Radiofrequency ablation of calcaneal branches of inferior calcaneal nerve
    - US-assisted partial plantar fascial release
  - Decrease in plantar fascial thickness occurs with improvement in symptoms following treatment
  - Focal nodular fibroblastic proliferation of plantar fascia away from calcaneal insertion
    - No specific risk factors identified
- **Plantar Fibroma**
  - Plant fibroma preferable term to plantar fibromatosis, which may be confused with desmoid tumor
  - Most commonly affects central band of plantar fascia in midfoot region
    - Often multiple
    - Bilateral in 1/3 of patients
  - Discrete, fusiform-shaded nodule expanding plantar fascia
    - Either hypoechoic (75%) or isoechoic (25%) to plantar fascia
  - Long axis of fibroma usually aligned with long axis of plantar fascia
  - Posterior acoustic enhancement (20%)
  - Internal vascularity (10%)
  - Calcification or visible tears are not feature
  - Does not infiltrate beyond plantar fascia
    - If large & infiltrative in nature, consider aggressive plantar fibromatosis (desmoid tumor)

Helpful Clues for Less Common Diagnoses

- **Plantar Fascial Tear**
  - Affects localized area of fascia rather than extending across width of fascia
  - Typically affects proximal & middle 1/3 of fascia
  - Acute tears characterized by focal disruption of fascia, perifascial edema, & inflammation
  - Chronic tears characterized by focal disruption, tendon thickening, perifascial fibrosis, & hyperemia
- **Enthesopathic Fasciitis**
  - Plantar fascia insertion is common site of enthesopathy, particularly at
    - Central band plantar fascia at calcaneal insertion

  - Lateral band plantar fascia insertion at base of 5th metatarsal bone
  - Plantar fascial thickening, hyperemia with cortical irregularity, osteophytic spurs (enthesophytes), & cortical erosions (entheseal erosions)
- **Investing Fascial Tear**
  - Either complete focal defect in fascia or linear intrasubstance fascial tear
  - Focal defect may result in muscle hernia, accentuated by muscle contraction
    - Often occurs near perforating vessel
  - Often occurs spontaneously in athletic, muscular individuals
- **Nodular Fasciitis**
  - Benign proliferation of fibroblasts & myofibroblasts of investing fascia
    - Lesions generally small & solitary
    - May have fascial tail
    - Usually no traumatic history & no known cause
- **Chronic Fasciitis**
  - Moderate to severe focal thickening of investing fascia, often with mild to moderate hyperemia
  - Adjacent subcutaneous & deep tissues show edema ± mild hyperemia
  - Usually related to chronic low-grade infection or trauma
- **Infective Fasciitis**
  - Infection centered around investing fascia
    - No fulminant necrotic element present
- **Necrotizing Fasciitis**
  - Advancing soft tissue infection characterized by widespread fascial necrosis
  - May occur after trauma or surgery
  - Either monomicrobial or polymicrobial infection can cause necrotizing fasciitis
    - Group A β-hemolytic *Streptococcus* is common causative organism
  - Thickened disrupted fascia with perifascial fluid
  - Severe subcutaneous & muscle edema
  - ± muscle necrosis
  - ± gas locules due to gas-forming organisms
- **Eosinophilic Fasciitis**
  - Disorder characterized by peripheral eosinophilia & fasciitis
    - Investing fascia & intermuscular fascia of forearm & calf are most commonly affected
  - Thickening & hyperemia of muscle fascia on US
  - US-guided fascial biopsy can confirm diagnosis
    - Usually not necessary when eosinophilia present
- **Dupuytren Disease**
  - Fibroproliferative disorder of palmar aponeurosis → ± progressive digital contracture
  - Risk factors are older age, male sex, White patients, positive family history, & diabetes mellitus
  - Disease deteriorates faster in patients with earlier age of onset
  - Associated with fibromatosis affecting back of hands, soles of feet, & penis
  - Predominantly affects little, ring, & middle fingers
    - Generally starts as small lump in palm overlying metacarpophalangeal joint area (stage A)
    - Progressive fibrosis of palmar aponeurosis & fingers with fibrous-type cord becoming evident (stage B)
    - Fibrous cord-like extension from palm into fingers with progressive finger contracture (stage C)
  - US generally useful only in stage A disease to ascertain nature of palmar lump
    - In stage B & C disease, diagnosis is clinically obvious & US not beneficial
    - Fibrinous digitations between palmar aponeurosis & flexor tendons may be seen
  - Treatment: Fasciotomy (simple division) of contracted fascia or limited fasciectomy ± under US guidance
- **Tumors Occurring Within Fascia**
  - Fibroma, lipoma, vascular malformation, fibromatosis may arise within or involve fascia
  - Appearances akin to similar tumors arising beyond fascia

SELECTED REFERENCES

1. Zhuang N et al: Ultrasound features and differential diagnosis for superficial nodular fasciitis. J Clin Ultrasound. 51(8):1370-5, 2023

Plantar Fasciitis

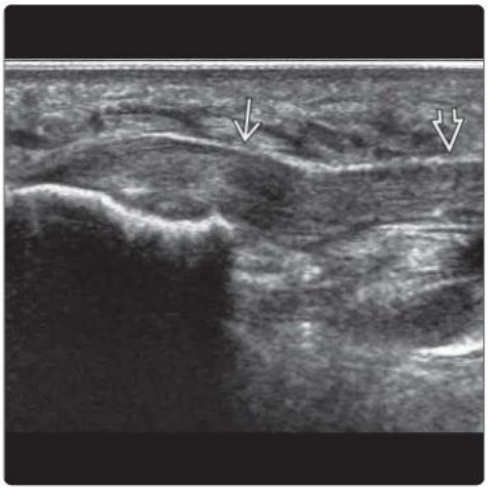

Plantar Fasciitis

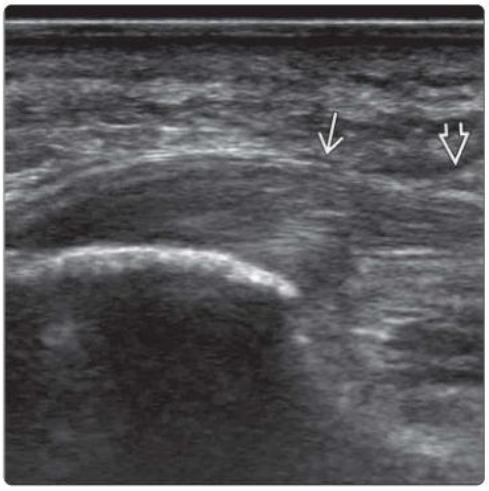

(Left) *Longitudinal US of a 60-year-old man with heel pain shows mild thickening (4.7 mm) ⇨ of the plantar fascia ⇨ at the anteromedial leading edge of the calcaneum (medial calcaneal tuberosity), consistent with mild plantar fasciitis.* **(Right)** *Longitudinal US in another patient with heel pain shows severe (6.7-mm) thickening ⇨ of the plantar fascia ⇨ at the anteromedial leading edge of the calcaneum, consistent with severe plantar fasciitis.*

Plantar Fibroma

Plantar Fibroma

(Left) *Clinical photograph shows a solitary plantar fibroma in the midfoot region ➡. **(Right)** Longitudinal US shows a fibroma ➡ of the more superficial aspect of the plantar fascia ➡. When only part of the plantar fascia is affected, it is usually the more superficial aspect. It is a discrete nodule as opposed to the more diffuse, infiltrative type of nodular fibrosis and tethering seen with Dupuytren disease.*

Plantar Fascial Tear

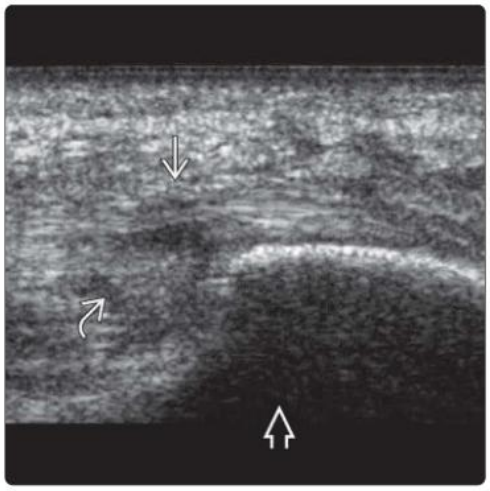

Plantar Fascial Tear

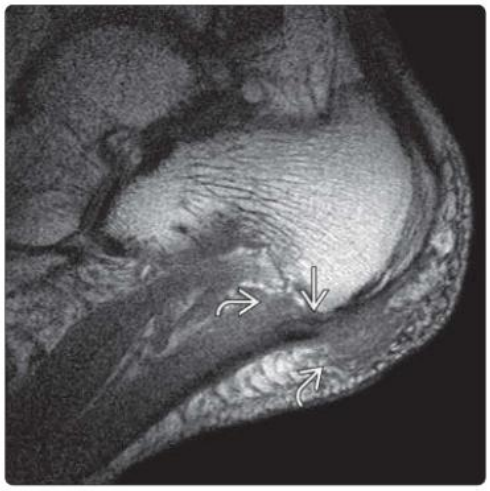

(Left) *Longitudinal US of a 54-year-old woman with heel pain shows localized thinning of the plantar fascia ➡ immediately distal to the calcaneum ➡ due to a partial-thickness tear. There is moderate perifascial edema ➡. The plantar fascia is not thickened, i.e., there is no plantar fasciitis present.* **(Right)** *Sagittal T1WI MR in the same patient shows a plantar fascial tear ➡ just distal to the calcaneal insertion with surrounding fluid and edema ➡.*

Plantar Fascial Tear

Plantar Fascial Tear

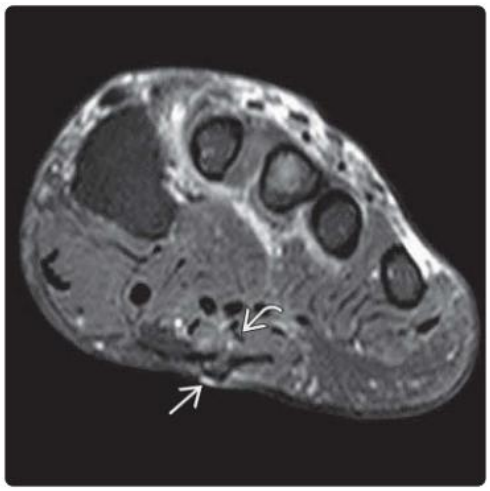

(Left) *Transverse US of the forefoot in a patient with localized trauma to this area 3 months previously shows a slit-like full-thickness tear ➡ with focal discontinuity of the plantar fascia ➡. There is herniation of part of the flexor digitorum brevis muscle ➡ through this fascial defect. The remaining plantar fascia is normal.* **(Right)** *Coronal T2WI FS MR of the same patient shows the plantar fascial tear with herniation of part of the flexor digitorum brevis muscle ➡ through this fascial defect ➡.*

Enthesopathic Fasciitis

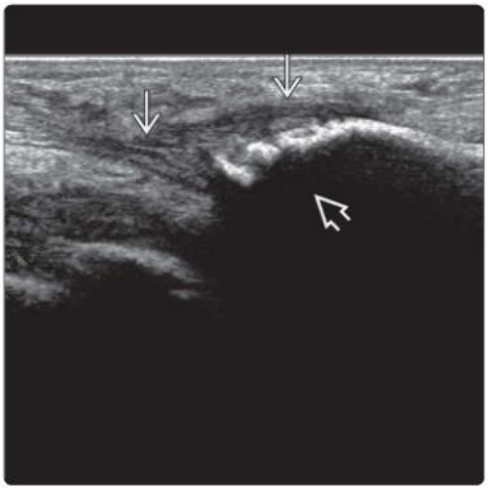

Enthesopathic Fasciitis

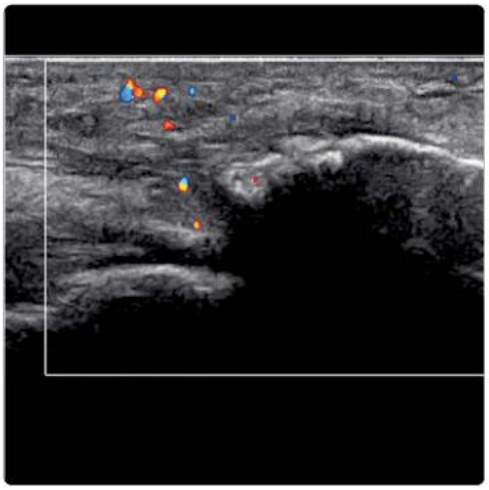

(Left) *Longitudinal US of a 55-year-old woman shows moderate cortical irregularity at the medial aspect of the 5th metatarsal base ⇨ with thickening of the lateral band of the plantar fascia ⇨ just proximal to its 5th metatarsal base insertion, consistent with enthesopathic fasciitis. There were other changes of enthesis elsewhere in the foot. The peroneus brevis insertion more laterally was normal.* **(Right)** *Longitudinal color Doppler US of the same patient shows mild localized hyperemia.*

Investing Fascial Tear

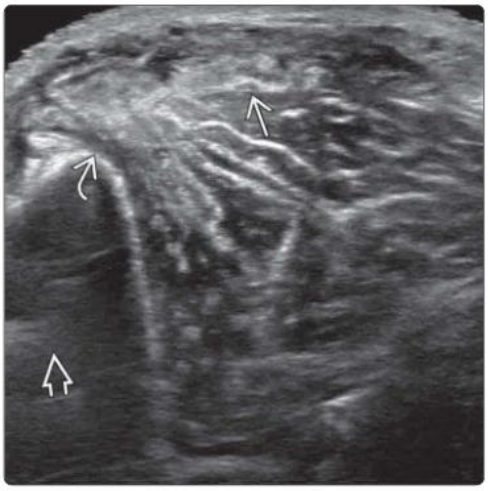

Nodular Fasciitis

(Left) *Transverse US shows herniation ⇨ of the tibialis anterior muscle into the subcutaneous tissues through a defect in the investing fascia ⇨ alongside the tibial shaft ⇨. This patient had point tenderness at this location, which was aggravated by exercise.* **(Right)** *Transverse US in a 45-year-old woman shows a hypoechoic, fusiform-shaped lesion ⇨ along the investing fascia overlying the pubic tubercle ⇨ on the surface of pectineus muscle. PET shows mild increased metabolic activity. Franseen 18-g biopsy confirmed nodular fasciitis.*

Chronic Fasciitis

Chronic Fasciitis

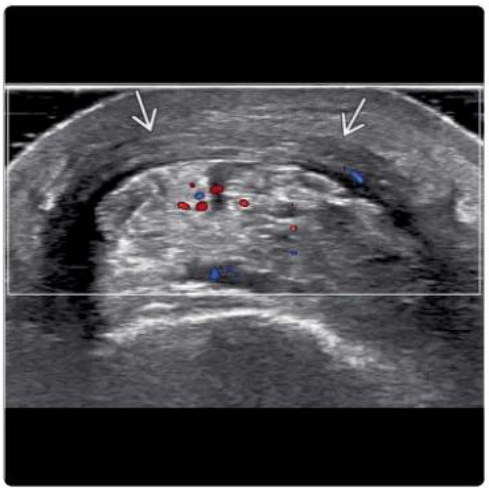

(Left) *A 41-year-old woman presents with pain, swelling, and discoloration over the anterolateral aspect of the distal leg and dorsum of foot for 6 months.* **(Right)** *Transverse Doppler US of the most painful area shows severe thickening of investing fascia ⇨ with mild hyperemia on the anterior aspect of the distal leg. Moderate surrounding soft tissue edema is present. Features are suggestive of chronic fasciitis with overall low-grade inflammatory activity.*

Infective Fasciitis

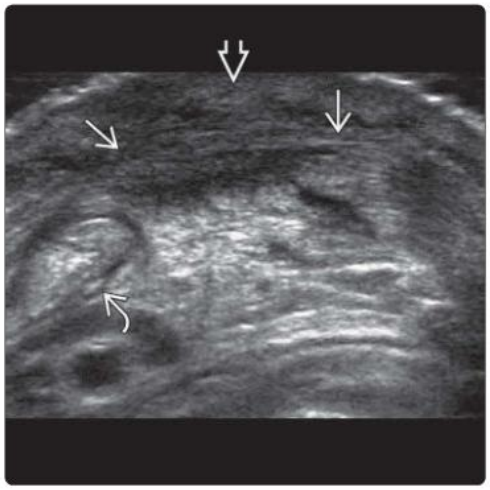

Infective Fasciitis

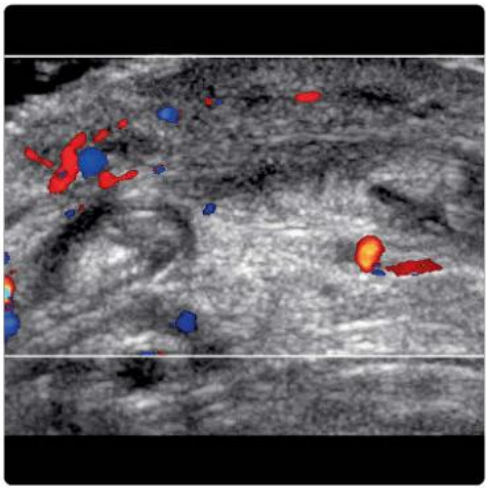

(Left) *Transverse US of the anterior ankle region in a 40-year-old man shows moderate swelling and edema ⇨ both superficial and deep to the investing fascia ⇨ of the leg. No liquefaction is present. The tibialis anterior tendon ⇨ is normal.* **(Right)** *Transverse color Doppler US in the same patient shows moderate surrounding hyperemia. Infective fasciitis is characterized by infection centered around the fascia. Not all infections around a fascia are necrotizing fasciitis.*

Necrotizing Fasciitis

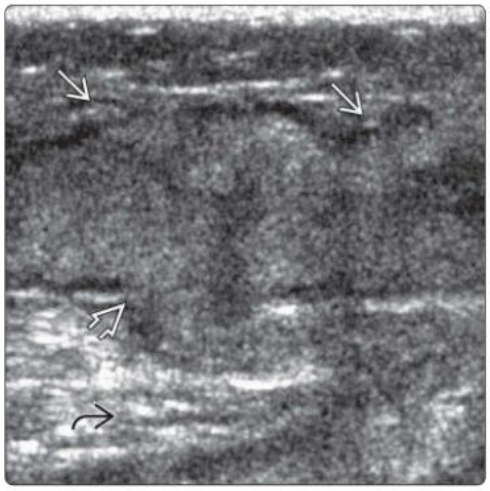

Eosinophilic Fasciitis

(Left) *Longitudinal US of the thigh shows a lobulated abscess ⇨ extending through the investing fascia ⇨ into the vastus lateralis muscle ⇨. Surgery confirmed necrotizing fasciitis due to Group A β-hemolytic Streptococcus.* **(Right)** *Transverse US of the forearm shows thickening of the investing fascia ⇨ and intermuscular fascia ⇨ in a patient with eosinophilia. Echogenic muscle edema ⇨ is also present.*

Eosinophilic Fasciitis

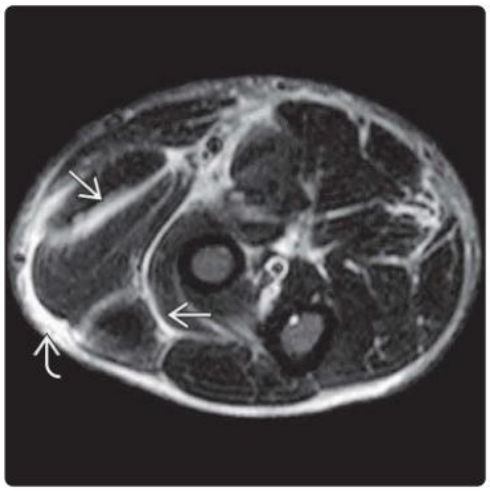

Dupuytren Disease

(Left) *Transverse T2WI FS MR in the same patient shows edema and thickening of the investing fascia ⇨ and intermuscular fascia ⇨. This is characteristic of eosinophilic fasciitis. Biopsy is generally not required.* **(Right)** *Clinical photograph of a 52-year-old man shows an area of nodular thickening ⇨ at the base of the index and middle fingers with peripheral skin tethering. This is consistent with Dupuytren disease. The little and ring fingers are more commonly affected.*

Dupuytren Disease

Tumors Occurring Within Fascia

(Left) *Longitudinal US of the palm in the same patient shows localized, echogenic nodular thickening ⇨ of the palmar aponeurosis in contact with the sheath of flexor digitorum tendon ⇨. This is consistent with early Dupuytren disease.* **(Right)** *Transverse US in a man with a 9-month history of a thigh mass shows a hypoechoic, fibrotic-type mass ⇨ transgressing and probably arising from the investing fascia ⇨. Biopsy revealed a rare primary pigmented villonodular synovitis.*

Tumors Occurring Within Fascia

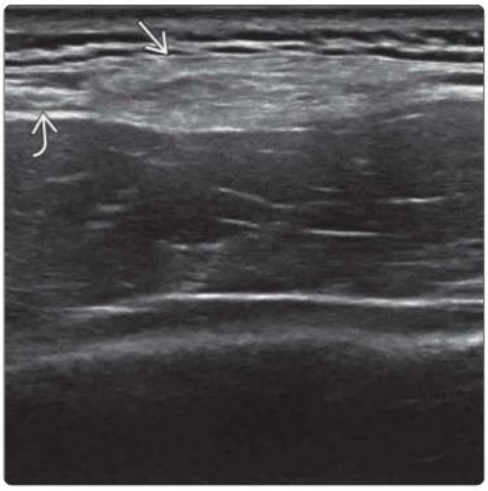

Tumors Occurring Within Fascia

(Left) *Transverse US in a 38-year-old man shows an intrafascial lipoma ⇨ arising from the investing fascia ⇨ overlying the infraspinatus muscle. CT confirmed an intrafascial lipoma. Lipomas may occasionally occur within the investing fascia.* **(Right)** *Clinical photograph of a young patient with a localized firm nodule ⇨ in the midpalm region is shown. There is no skin tethering nor punctum present.*

Tumors Occurring Within Fascia

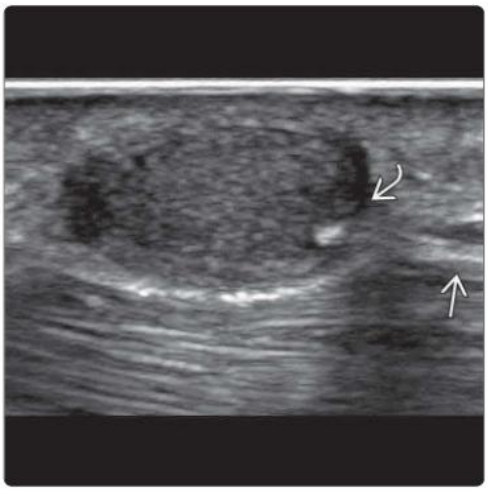

Tumors Occurring Within Fascia

(Left) *Longitudinal US of the same patient shows a discrete, fibrotic-type nodule in continuity with the palmar aponeurosis ⇨, consistent with a palmar aponeurotic fibroma. Mild dystrophic calcification ⇨ is present, which is not uncommon.* **(Right)** *Sagittal T1WI MR of foot shows a large desmoid tumor ⇨ of the sole. This is a relatively common site for this tumor. It most likely arose from the plantar aponeurosis ⇨ initially and, size-wise, can be clearly distinguished from a plantar fibroma.*

DIFFERENTIAL DIAGNOSIS

Common

- Osteochondroma
- Other Benign Bone Tumor
- Malignant Bone Tumor

Less Common

- Metastases
- Bone Tumor Recurrence
- Fracture
- Acute Osteomyelitis
- Chronic Osteomyelitis
- Orthopedic Implant
- Cortical Tug Lesion
- Supracondylar Spur
- Juxtacortical Tumor

ESSENTIAL INFORMATION

Key Differential Diagnosis Issues

- Radiographs or other imaging are very helpful when assessing bone surface lesions on US
- US cannot assess intramedullary extent
- Beware of normal bone irregularity at sites of muscle insertion & previous surgery
- Heavy mineralization may make juxtacortical lesion appear to arise from bone
- Only portion of bony lesion visible with US
  - Angulation of transducer can help provide more comprehensive evaluation
  - MR or CT is often required for complete evaluation
- Determining etiology of surface bone lesions is often helped by clinical features
  - Age of patient
  - Location of lesion
  - Duration & type of symptoms
- US-guided biopsy of bone tumor is possible if extraosseous mass is present
- US-guided biopsy of intramedullary component of bone tumor or infection is possible via cortical breach if present

Helpful Clues for Common Diagnoses

- **Osteochondroma**
  - Most common bone surface tumor
  - Metaphyseal or metadiaphyseal in location
    - Points away from joint
  - Most are solitary
    - If multiple & metaphyseal dysplasia indicates multiple hereditary exostoses (diaphyseal aclasis)
  - Variable thickness in hypoechoic cartilage cap
    - Often not visible or barely visible
    - Cap thickness of ≥ 2 cm or progressive thickening of cartilage cap on serial imaging is indicative of secondary chondrosarcoma
  - Most osteochondromas are asymptomatic
  - Symptoms can be due to several causes
  - Reactive myositis secondary to friction between osteochondroma & adjacent muscle
  - Reactive bursitis
    - Friction between osteochondroma & soft tissue can lead to development of intervening adventitial bursa
  - Pseudoaneurysm
    - Most common vascular complication
    - Characteristic to-&-fro pattern on spectral analysis of narrow neck
    - Characteristic yin-yang bidirectional flow pattern on color Doppler imaging of lumen
  - Bleeding
    - From vascular injury, hemorrhagic bursitis, or myositis
  - Neurologic sequelae
    - May cause compressive neuropathy, radiculopathy, or myelopathy, depending on location
    - Snapping nerve → reactive neuritis
  - Fracture
    - Affects stalk of pedunculated osteochondroma
  - Malignant transformation more common with
    - Diaphyseal aclasis (likelihood < 1%)
    - Increase in age
    - Osteochondromas located in axial skeleton
- **Other Benign Bone Tumor**
  - Most intramedullary benign tumors remain intramedullary
    - May expand bone cortex or fracture → bone surface irregularity
  - Giant cell tumor of bone, not infrequently, has extraosseous soft tissue component
    - Hypervascular ± hemorrhagic cystic areas
  - Other benign juxtacortical tumors
    - Chondroma, fibroma, schwannoma
- **Malignant Bone Tumor**
  - Osteosarcoma is most common malignant bone tumor
  - Most frequently arises at long bone metaphysis
  - Hypoechoic, broad-based tumoral outgrowth from bone
  - Radiating seams of tumoral osteoid deposition
  - Moderately hyperemic

Helpful Clues for Less Common Diagnoses

- **Metastases**
  - Can be detected by US if surface based or cortex disrupted
  - Lung & breast are most common primary sites
  - Predilection for diaphyseal location
- **Bone Tumor Recurrence**
  - US is very useful at screening for bone tumor recurrence
  - Based on premise that most bone tumor recurrences occur in juxtacortical soft tissues rather than in bone
  - Unlike MR, US assessment of juxtacortical soft tissues is not affected by metallic prosthesis
  - Tumor recurrence usually mirrors imaging characteristics of original tumor
  - If recurrence is detected, check regional lymph nodes, as nodal involvement is more frequent with recurrence than with primary bone tumor
- **Fracture**
  - 4 types of fracture
    - Traumatic, stress, insufficiency, & pathologic
  - US is very useful in detecting most radiographically occult traumatic fractures, provided affected bone is assessable to US

  - Also useful in other fracture types, though not as sensitive as in traumatic fractures
  - Acute traumatic fracture
    - Focal cortical disruption
    - ± shadowing artifact (quite common) or reverberation artifact ("light house" or "chimney" phenomenon) (uncommon) at fracture site
    - Juxtacortical soft tissue swelling, edema, or hematoma (common)
  - Healing traumatic fracture
    - Hypoechoic callus bridging fracture site with progressive ossification
- **Acute Osteomyelitis**
  - Most frequently involves metaphyses of long bones in children
  - Fine, lamellar periosteal reaction
  - Anechoic fluid accumulation alongside cortex
  - Subperiosteal accumulation of fluid
  - Subperiosteal abscess
  - Color Doppler imaging shows hyperemia within & around inflamed periosteum
  - ± concurrent septic arthritis
  - US-guided aspiration of subperiosteal fluid or abscess for Gram stain & culture
  - MR is best at assessing acute osteomyelitis
    - Unlike MR, acute osteomyelitis is not excluded by normal US examination
- **Chronic Osteomyelitis**
  - Most frequently involves diaphysis of long bones in young to middle-aged adults
  - Coarse or fine periosteal reaction dependent on activity
    - ± inflammatory cortical defect (cloaca)
    - ± sequestrum within extraosseous tissues
    - ± juxtacortical inflammation or abscess
    - ± sinus tract extending toward skin
  - MR best at assessing activity & extent
    - US cannot evaluate intramedullary disease
    - US is very helpful if metal implant in situ, which limits assessment by CT or MR
- **Orthopedic Implant**
  - Plate & screw fixation, bone-allograft anastomosis, etc. can all give rise to suspicious bone surface appearance on US
    - Can mimic localized cortical bone destruction from tumor or infection
  - Correlation with radiography is very helpful
  - If still in doubt, follow-up US in 2-4 weeks
- **Cortical Tug Lesion**
  - Cortical hyperostosis at site where strong muscle is attached to bone
  - Most commonly seen at aponeurotic attachments of gluteus maximus into femoral shaft & deltoid into humeral shaft
  - May cause both pain & increased activity on isotope bone scanning
  - Do not confuse with more sinister pathology
- **Supracondylar Spur**
  - Congenital, beak-shaped bony process arising on distal anteromedial aspect of proximal humerus
    - Normal variant in 0.5% of population
  - Associated with ligament of Struthers, fibrous connection between supracondylar spur & medial epicondyle
  - Usually asymptomatic; rarely can cause neurovascular compression, a.k.a. supracondylar process syndrome
    - Isolated median nerve compression is most common
- **Juxtacortical Tumor**
  - Soft tissue masses commonly lie against bone, i.e., occur in juxtacortical location
    - Examples: Gouty tophus, vascular malformation, nerve sheath tumor, lipoma, etc.
  - Hard tissue masses also less frequently occur in juxtacortical (periosteal) location
    - Examples: Chondroma, chondromyxoid fibroma, periosteal osteosarcoma, or periosteal chondrosarcoma

SELECTED REFERENCES

1. Bosmans F et al: Ultrasound measurements of the normal peroneal tubercle: validation of the normal anatomical measurements and evaluation of the intra- and interobserver reliability. Pol J Radiol. 89:e187-95, 2024

Osteochondroma

Osteochondroma

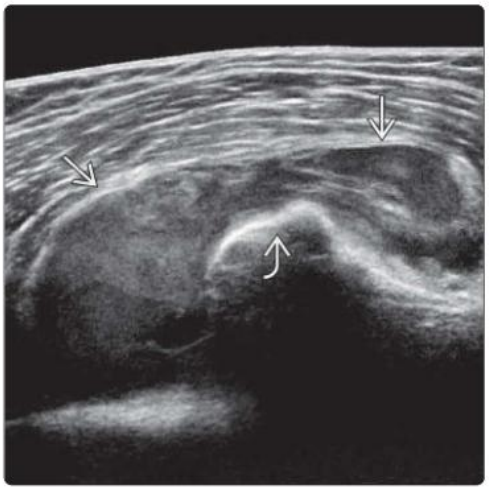

(Left) *Anteroposterior radiograph shows a large, pedunculated osteochondroma ➡ on the medial side of the distal femoral metaphysis. This lesion was symptomatic and referred for US examination.* **(Right)** *Longitudinal US of the same lesion shows bursa distended with hemorrhage ➡ overlying the osteochondroma ➡.*

Osteochondroma

Osteochondroma

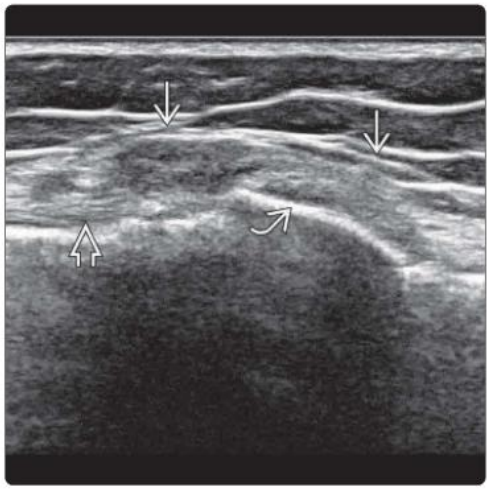

(Left) *Anteroposterior radiograph shows a small, symptomatic sessile osteochondroma ➡ on the medial aspect of the proximal tibial metaphysis.* **(Right)** *Longitudinal US of the same lesion shows a thick-walled chronic bursitis ➡ overlying this osteochondroma. The medial collateral ligament is seen proximally ➡. The very thin hypoechoic layer is due to a thin cartilage cap ➡. Bursa tend to develop in sites of chronic friction. They are lined by synovium.*

Malignant Bone Tumor

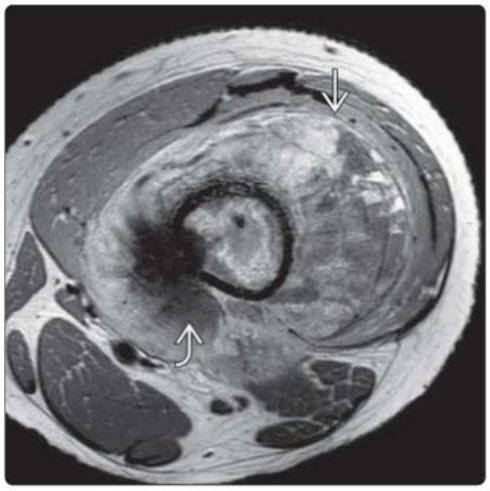

Malignant Bone Tumor

(Left) *Axial PD FSE MR of the femur shows a bone tumor with a large, extraosseous soft tissue component tumor anteromedially with fluid-fluid levels ➡ and dense, spiculated tumoral new bone formation posterolaterally ➡.* **(Right)** *Transverse US of the anteromedial aspect of the same tumor shows dense, spiculated new bone formation posterolaterally ➡ and a large extraosseous soft tissue component ➡ displacing the vastus medialis muscle anteriorly ➡. US-guided biopsy confirmed osteosarcoma.*

Malignant Bone Tumor

Metastases

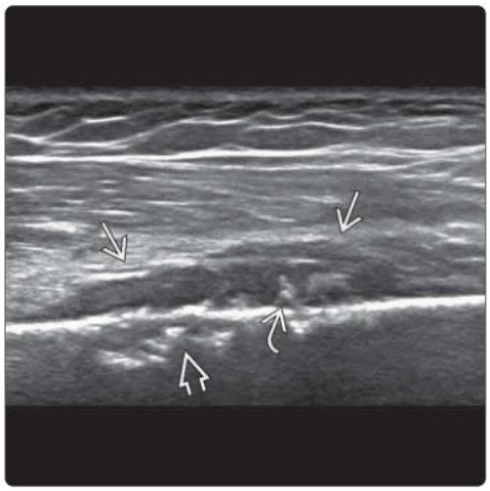

(Left) *Longitudinal US shows a large, hypoechoic osteosarcoma ➡ arising from the distal femur ➡. Note the radiating echogenic seams ➡ of mineralized osteoid within the extraosseous tumor matrix.* **(Right)** *Longitudinal US in a 67-year-old man with good past health with arm pain shows an aggressive lytic lesion ➡ with extraosseous soft tissue infiltration ➡ and spiculated periosteal reaction ➡ in the midhumeral diaphysis. Further work-up revealed new lung cancer metastasis.*

Metastases

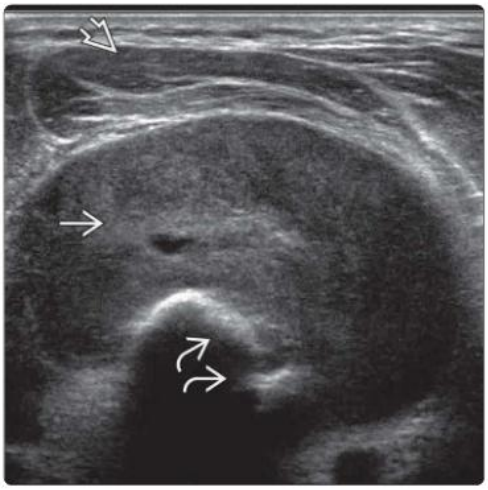

Metastases

(Left) *Transverse US in a patient with known metastatic lung cancer shows a large soft tissue mass surrounding the proximal radial shaft with early cortical infiltration, consistent with a metastatic deposit. The supinator muscle is displaced.* **(Right)** *Longitudinal Doppler US in a 79-year-old man with metastatic lung cancer shows an infiltrative metastatic mass with moderate hyperemia overlying the glenoid process of the scapula. Biopsy confirmed metastatic adenocarcinoma.*

Fracture

Fracture

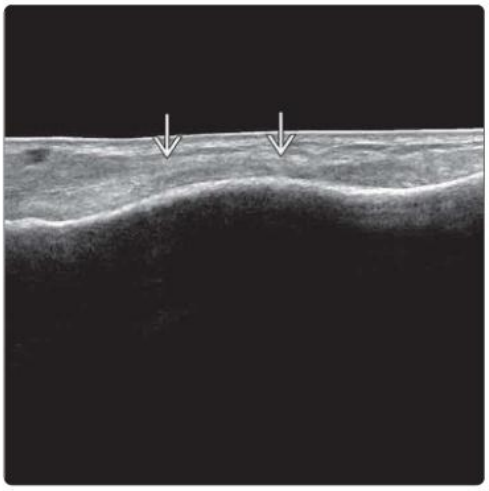

(Left) *Transverse US in a 72-year-old woman with anterior chest pain after a fall shows an acute nondisplaced rib fracture with callus formation. No hematoma is present.* **(Right)** *Extended FOV US shows a healed stress fracture of the 2nd metatarsal bone. There is smooth cortical thickening of the metatarsal shaft with no inflammation or edema of the adjacent soft tissues.*

Fracture

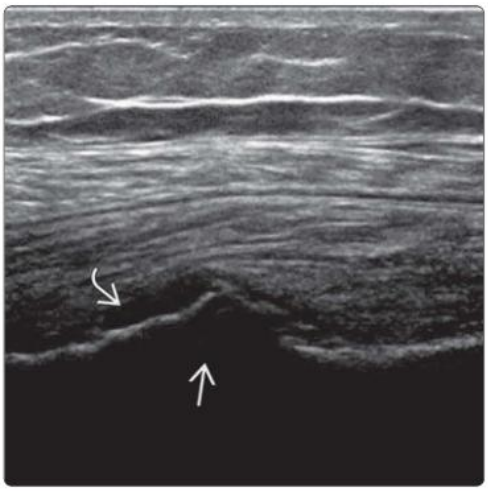

Fracture

(Left) *Longitudinal US in an older adult female osteoporotic patient with hip and thigh pain shows a small, irregular osseous spike on the lateral cortex of the midfemoral shaft. This favors a bisphosphonate-related insufficiency fracture with cortical hyperostosis. There is hypoechoic, poorly mineralized osteoid alongside the area of hyperostosis.* **(Right)** *Subsequent radiography of the same area shows an incomplete cortical insufficiency fracture with cortical hyperostosis in the midfemoral shaft.*

(Left) *Longitudinal US in a neonate with acute osteomyelitis of the femur shows focal cortical irregularity ⇨ at the distal femoral metaphysis. This is associated with moderate periosteal soft tissue thickening and a small amount of subperiosteal fluid ⇨.* **(Right)** *Longitudinal color Doppler US in the same patient shows moderate hyperemia of the thickened periosteal tissues ⇨. The physis and epiphysis ⇨ are normal.*

Acute Osteomyelitis

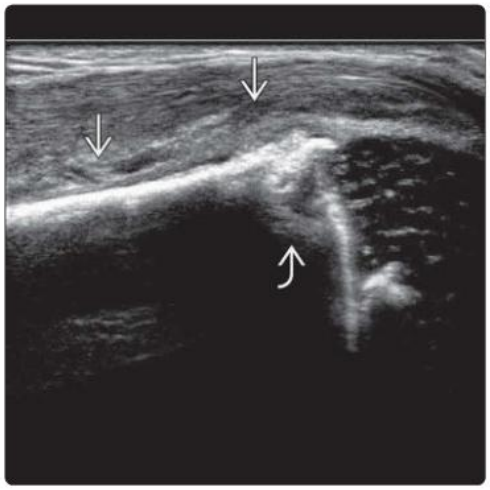

Acute Osteomyelitis

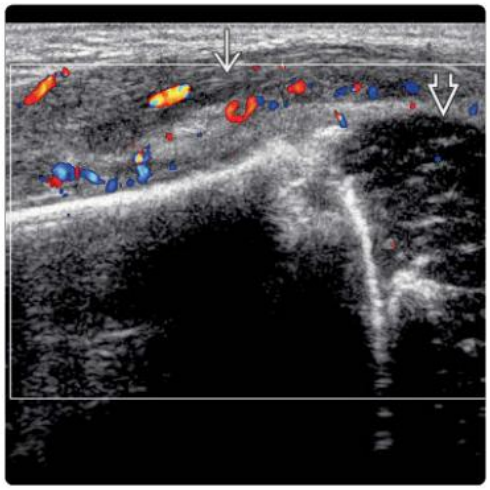

(Left) *Transverse US in a patient with acute exacerbation of chronic osteomyelitis shows an echogenic fluid collection ⇨ alongside a large cortical defect ⇨ on the medial side of the distal femoral cortex.* **(Right)** *Transverse color Doppler US in the same patient shows mild hyperemia ⇨ of the inflamed adjacent soft tissues. US-guided aspiration of the juxtacortical collection yielded Staphylococcus aureus.*

Chronic Osteomyelitis

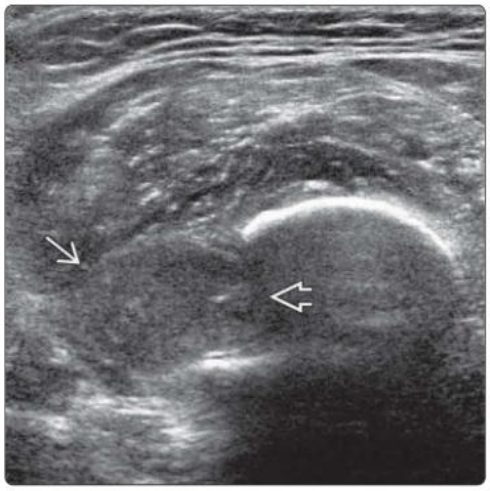

Chronic Osteomyelitis

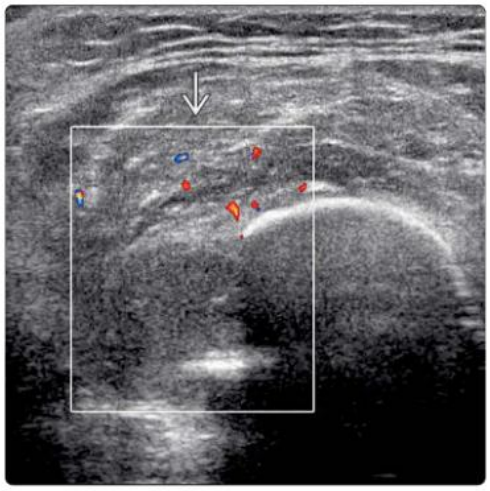

(Left) *Longitudinal US in a patient with an orthopedic implant shows mild reactive new bone formation ⇨ with soft tissue swelling thickening ⇨ at the interface between the prosthesis ⇨ and the bone ⇨.* **(Right)** *Frontal radiograph in the same patient provides an explanation of US findings, which are due to reactive new bone formation at the bone:prosthesis interface ⇨. There is no evidence of tumor recurrence or infection.*

Orthopedic Implant

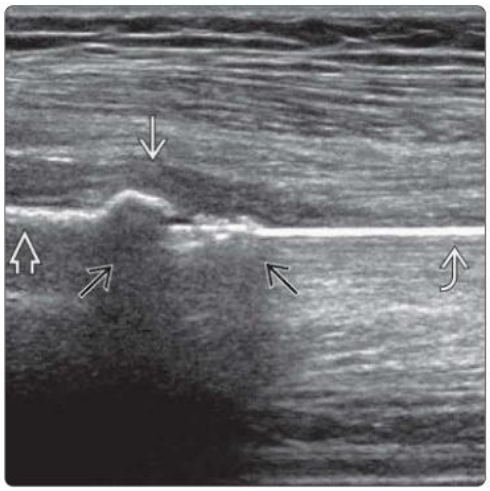

Orthopedic Implant

Orthopedic Implant

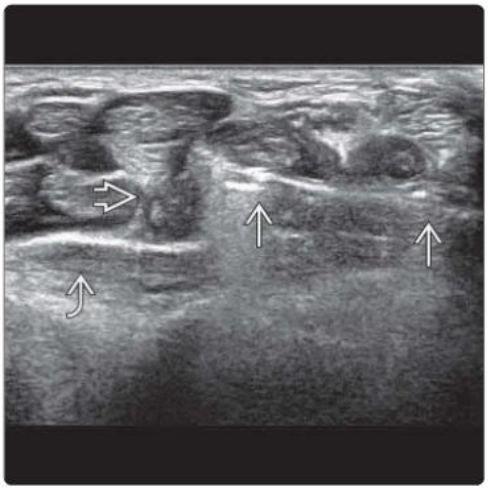

Cortical Tug Lesion

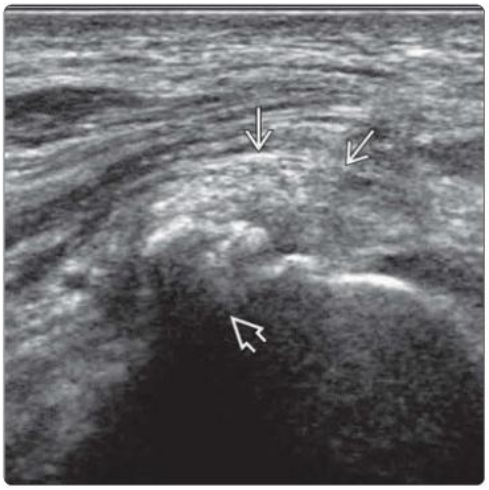

(Left) *Transverse US in a patient shows the medial end of a transverse fixation plate ⇨ impinging onto the flexor digitorum profundus myotendinous junction ⇨. Repeated friction between the tendon and the fixation plate may well lead to tendon attrition and rupture. The radius ⇨ is normal.* **(Right)** *Transverse US shows localized cortical hyperostosis (tug lesion) ⇨ on the posterolateral aspect of the femoral shaft due to insertion of the gluteus maximus tendon ⇨.*

Supracondylar Spur

Juxtacortical Tumor

(Left) *Transverse US shows the median nerve ⇨ and brachial artery ⇨ slightly displaced around a supracondylar spur ⇨, though no neurovascular compression or Struthers ligament was evident.* **(Right)** *Transverse US in a young man with shoulder pain shows a tender mass ⇨ arising from the proximal humerus ⇨ extending into the extraosseous soft tissues just distal to the infraspinatus tendon. US appearances favored a fibrous-type tumor. Biopsy revealed neurofibroma.*

Juxtacortical Tumor

Juxtacortical Tumor

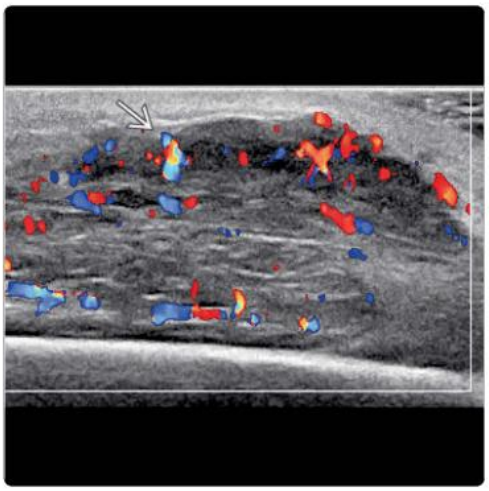

(Left) *Transverse US shows a large pretibial ⇨ hypoechoic soft tissue mass ⇨. Biopsy revealed non-Hodgkin lymphoma (follicular). Although the tibial cortex seems intact, subsequent MR revealed intramedullary extension.* **(Right)** *Longitudinal Doppler US in a 61-year-old man shows a large, pretibial, hypoechoic soft tissue mass with severe hyperemia ⇨. Biopsy revealed non-Hodgkin follicular lymphoma. Most musculoskeletal lymphomas involve either bone or muscle.*

PART IV
SECTION 4

Joint Abnormalities

Paraarticular Cystic Mass 910
Synovial Swelling 916
Joint Effusion 922

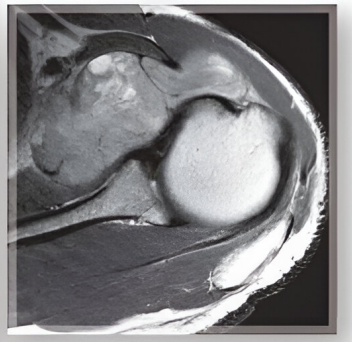

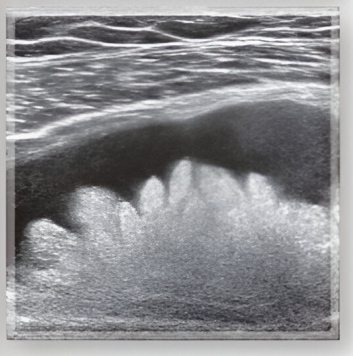

DIFFERENTIAL DIAGNOSIS

Common

- Ganglion Cyst
- Baker Cyst
- Parameniscal Cyst
- Paralabral Cyst
- Bursal Distention
- Liquefied Hematoma
- Abscess or Collection

Less Common

- Cystic-Appearing Soft Tissue Tumors
- Pseudoaneurysm

ESSENTIAL INFORMATION

Key Differential Diagnosis Issues

- Establish whether mass is intra- or extracapsular
  - If extracapsular, does mass communicate with joint?
  - Where does mass communicate with joint?
  - Sometimes, direct continuity with joint is not visible, but mass can be seen pointing toward joint
    - Passive movement of joint may occasionally be helpful
- Consider cyst content & wall
- Check for pericystic fluid leakage & inflammation
- Use color Doppler to help ensure cystic nature of mass & detect adjacent vasculature
- Consider aspiration
- If one cannot confidently diagnose mass as benign, then arrange follow-up US, MR, or biopsy

Helpful Clues for Common Diagnoses

- **Ganglion Cyst**
  - Mucinous fluid contained within fibrous pseudocapsule
    - Not lined by synovial tissue
  - Results from extruded synovial fluid
  - Most common around wrist & hand, ankle & foot
    - Compose 80% of soft tissue masses in these areas
    - Volar wrist ganglia more common than dorsal, but dorsal ganglia more commonly symptomatic
  - Typical sites reflect intrinsic weakness in joint capsule
    - Dorsal radiocarpal joint or scapholunate joint
      - May impinge posterior interosseous nerve
    - Scapho-trapezio-capitate joint
  - Near A1 pulley on middle, index, & ring fingers
    - Does not seem to communicate with metacarpophalangeal joint or flexor tendon sheath
  - Anechoic, well-defined, rounded or irregular mass alongside joint
    - ± comet-tail artifacts due to colloid aggregates
    - Infrequently hyperechoic due to hemorrhage or inflammatory content from joint
      - Joint pathology (e.g., synovitis) can occur within ganglia but uncommon due to closed or narrow neck
  - Typically has neck pointing to particular joint
    - Usually, neck cannot be traced to joint, as too thin
    - Identifying joint origin helps surgical exploration
  - Most ganglia are not painful
    - Pain usually caused by fluid leakage, rarely from mass effect or nerve compression
    - Look for inflammation or free fluid around ganglion suggestive of leakage or rupture
  - 50% of ganglia recur after percutaneous aspiration
    - Not possible to access viscosity of ganglionic fluid
    - Use large-bore needle (16-18 g) ± hyaluronidase to facilitate aspiration
    - Leakage of cyst content can cause pain for 24-36 hours after aspiration
- **Baker Cyst**
  - Semimembranosus-gastrocnemius bursa, which communicates with knee joint
    - Slit-like opening in capsule near posterior root ligament of medial meniscus
  - Classic speech-bubble configuration on transverse US
    - Beak of bubble emerges between semimembranosus tendon & medial head of gastrocnemius muscle
    - Slight knee flexion during scanning can accentuate this communication
    - Often bilateral
  - Usually extends distally over medial head of gastrocnemius muscle belly
    - Less commonly extends proximally, uncommonly into semimembranosus or gastrocnemius muscles
  - Has synovial membrane &, therefore, reflects synovial processes [e.g., synovitis, pigmented villonodular synovitis (PVNS)] affecting knee joint
  - Prone to either leakage or hemorrhage
    - May make Baker cyst symptomatic
  - Leakage or rupture
    - Free fluid around margin of cyst & along fascial planes
    - Angulated arrow-like, rather than rounded, proximal or distal margins of cyst
    - ± pericystic inflammation
  - Hemorrhage
    - Fine, speckled echoes in cyst fluid
- **Parameniscal Cyst**
  - Cyst extending from peripheral aspect of meniscus
  - Strongly associated with horizontal meniscal tear
    - Mucinous synovial fluid content expressed as cyst
  - Occasionally, no meniscal tear visible
    - Tear may have healed
    - Cyst may have arisen from severe meniscal myxoid degeneration without tear
  - US-guided aspiration may help relieve symptoms, though symptoms commonly recur if tear is present
- **Paralabral Cyst**
  - Strongly associated with labral tear
  - Acetabular more common than glenoid
    - Acetabular > anterosuperior
    - Glenoid > posterior
      - If large, can compress suprascapular nerve posteriorly or axillary nerve inferiorly
- **Bursal Distention**
  - **Adventitial bursa**: Nonsynovial-lined bursa acquired due to friction between opposing structures, often against bony prominence
  - **Synovial bursa**: Synovial-lined bursa, which occur at defined anatomic locations

  - Prone to synovial disorders, such as synovitis or synovial osteochondromatosis
- Subacromial-subdeltoid bursa
  - Attached to coracoacromial ligament & greater tuberosity distal to tendon insertions
  - Distention strongly associated with rotator cuff tear
  - If bursal wall thickened ± hyperemia, consider inflammatory arthropathy or infection
- Olecranon bursa
  - Between olecranon process & skin
  - Common site of gouty bursitis
  - Commonly inflamed; not commonly infected
- Iliopsoas bursa
  - Anterior to femoral head between hip capsule & iliopsoas muscle/tendon
  - Communicates with hip joint in 1/6 of patients
  - Consider iliopsoas infection, particularly tuberculous
- Semimembranosus bursa
  - Between anterior arm of semimembranosus tendon complex & posterior oblique ligament
  - Located medial to Baker cyst & proximal to pes anserinus bursa
  - Distended bursa has J-shaped appearance
- Pes anserinus bursa
  - Between pes anserinus tendons anteromedial aspect of knee & medial collateral ligament (MCL)
- Prepatellar, superficial & deep infrapatellar bursae
  - Prepatellar bursa between patella & skin
  - Superficial infrapatellar bursa between tibial tuberosity & skin
  - Deep infrapatellar bursa between distal part of patellar tendon & tibia
    - ≤ 3-mm distention of deep infrapatellar bursa is common & normal finding

- **Liquefied Hematoma**
  - Usually following surgery or trauma
  - Hematoma is solid-appearing when composed of clotted blood and cystic-appearing when liquefied
  - Liquefied component usually anechoic but can have variable echogenicity, depending on content
  - Superadded infection may coexist, especially following surgery or open trauma
    - US alone cannot reliably determine infectivity
      - Infection more likely with greater degree of surrounding inflammation
      - Aspirate if in doubt
- **Abscess or Collection**
  - If any abscess or collection around joint, look carefully for evidence of septic arthritis or osteomyelitis
    - Clinical or laboratory signs of infection
    - Echogenic cyst contents with fine or coarse speckles
    - Thick, irregular wall
    - Marginal hyperemia & edema
    - Communicating with cloaca in osteomyelitis
  - If in doubt, aspirate
    - ± biopsy if aspiration not possible or not fruitful

Helpful Clues for Less Common Diagnoses

- **Cystic-Appearing Soft Tissue Tumors**
  - Lymphangioma
    - Lobulated, usually anechoic, no color flow
  - Vascular malformation
    - Slow or high flow, variable stroma ± phleboliths
  - Cystic schwannoma
    - Visible entering or exiting nerve in 50%
  - Myxoma
    - Intramuscular, anechoic ± echogenic, comet-tail artifacts due to colloid aggregates
  - Cyst-like soft tissue sarcoma
    - e.g., myxoid liposarcoma, synovial sarcoma
    - Usually complex-appearing
  - Cystic metastases
    - Cystic appearance may be due to myxoid component or tumor necrosis
- **Pseudoaneurysm**
  - Usually iatrogenic (e.g., femoral access) or inadvertent arterial injury (intravenous drug user)
  - Yin-yang sign on color Doppler imaging
  - To-&-fro pattern on Doppler spectral analysis
  - Treat with US-guided compression or thrombin injection

Ganglion Cyst

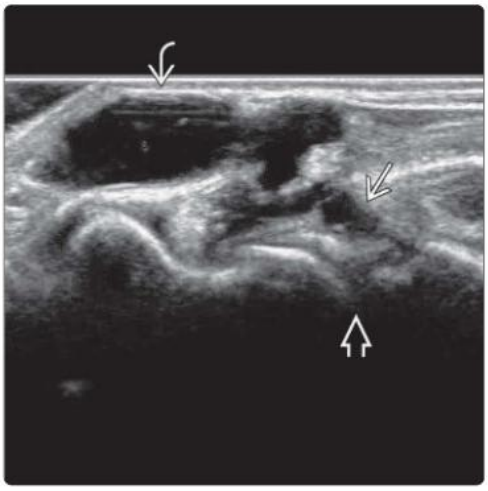

Ganglion Cyst

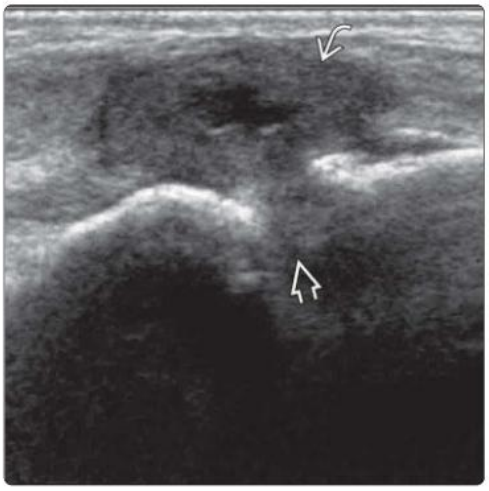

(Left) *Longitudinal US shows a medium-sized ganglion cyst ⇨ with an irregular serpiginous tail ⇨ extending to the dorsal aspect of the radioscaphoid joint ⇨.* **(Right)** *Longitudinal US shows a thick-walled ganglion cyst ⇨ on the dorsum of the navicular-cuneiform joint ⇨. Atypical ganglia occur more commonly in the foot and knee regions.*

(Left) *Transverse US of the posterolateral knee shows a lobulated ganglion cyst ⇨ between the biceps femoris ⇨ and lateral gastrocnemius muscle ⇨. The common peroneal nerve ⇨ is slightly displaced superficially but not compressed. Larger cysts can cause neural compression.* **(Right)** *Transverse US of the anterolateral ankle shows a small ganglion cyst ⇨ arising from the distal tibiofibular joint ⇨. Note the fibula ⇨ and tibia ⇨. Ganglion cysts are more common at the proximal than the distal tibiofibular joint.*

Ganglion Cyst

Ganglion Cyst

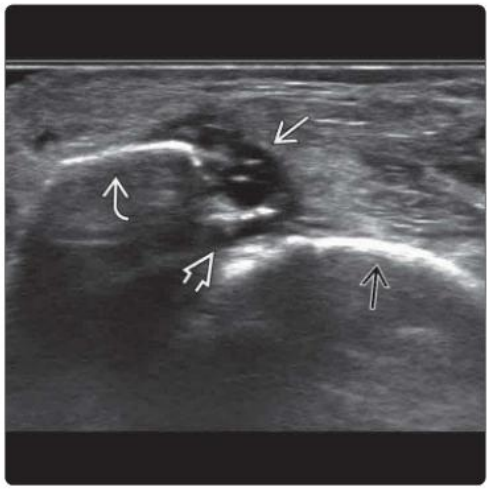

(Left) *Transverse US shows the typical speech-bubble configuration of a Baker cyst ⇨. The beak merges between the medial belly of gastrocnemius muscle ⇨ and the semimembranosus tendon ⇨.* **(Right)** *Transverse US shows many small, echogenic foci ⇨ within a Baker cyst due to small colloid aggregates. Larger echogenic foci may produce comet-tail artifacts.*

Baker Cyst

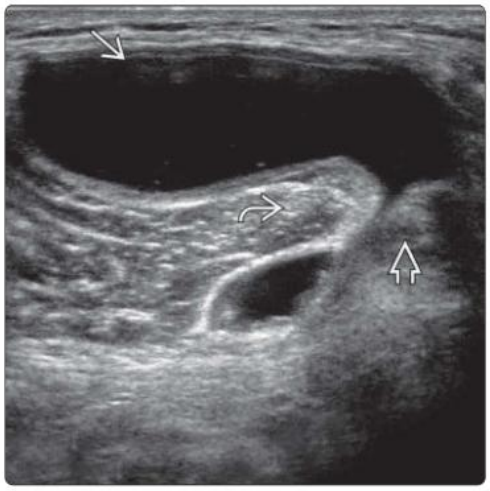

Baker Cyst

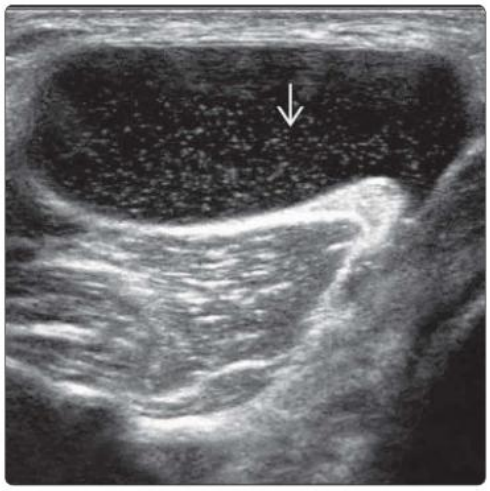

(Left) *Transverse US shows recent hemorrhage within a Baker cyst ⇨ with fine, echogenic fluid ⇨. The small, hyperechoic ring ⇨ may be due to a detached synovial fragment.* **(Right)** *Transverse US shows a Baker cyst containing inflammatory-type synovial proliferation ⇨ with small embedded calcified foci ⇨. This was secondary to an inflammatory knee osteoarthritis with calcified intraarticular debris.*

Baker Cyst

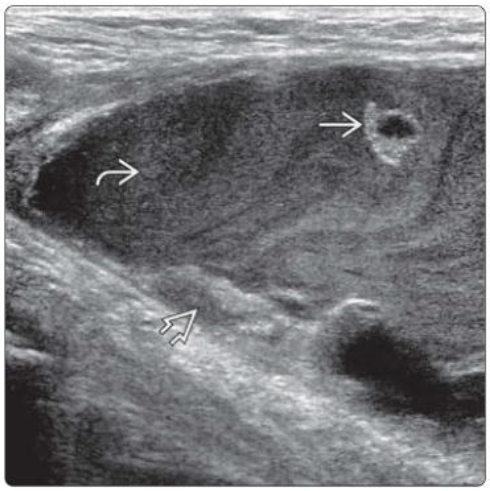

Baker Cyst

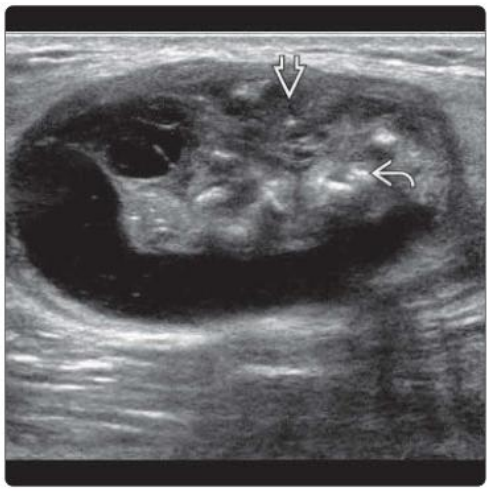

Paramenisical Cyst

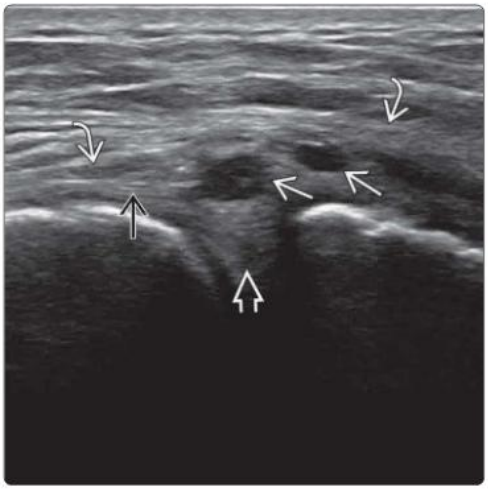

Paramenisical Cyst

(Left) *Longitudinal US shows 2 small paramenisical cysts ⇨ superficial to the medial meniscus body ⇨ and deep to the superficial MCL ⇨. Note the deep MCL ⇨. The meniscus appears intact on US, but MR later revealed a healed small peripheral tear more posteriorly.* **(Right)** *Longitudinal US shows a small paramenisical cyst ⇨ superficial to the MCL ⇨. This extracapsular component communicated more posteriorly with a deeper intracapsular component near the periphery of the medial meniscus ⇨ (not shown).*

Paramenisical Cyst

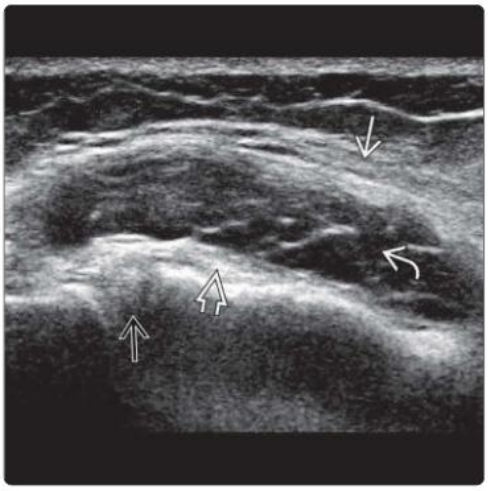

Paralabral Cyst

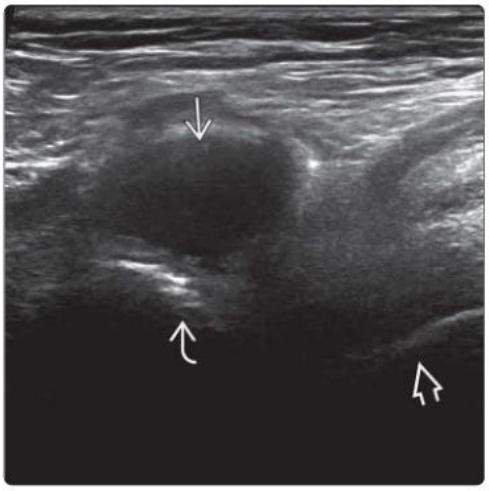

(Left) *Longitudinal US at the medial knee shows a large paramenisical cyst ⇨ located between the MCL ⇨ and investing fascia ⇨. Note the medial meniscus ⇨.* **(Right)** *Longitudinal US of the anterosuperior hip shows a medium-sized acetabular paralabral cyst ⇨. Note the femoral head ⇨ & acetabulum ⇨. Differentiation between a paralabral cyst and iliopsoas bursa can be challenging; the former is more mass-like, non-compressible, and usually occur alongside, rather than deep to, the iliopsoas tendon.*

Bursal Distention

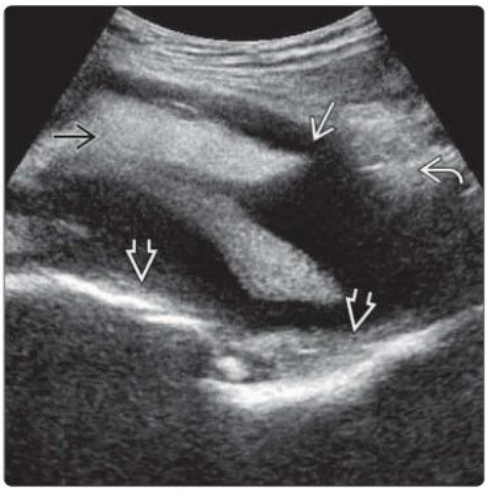

Bursal Distention

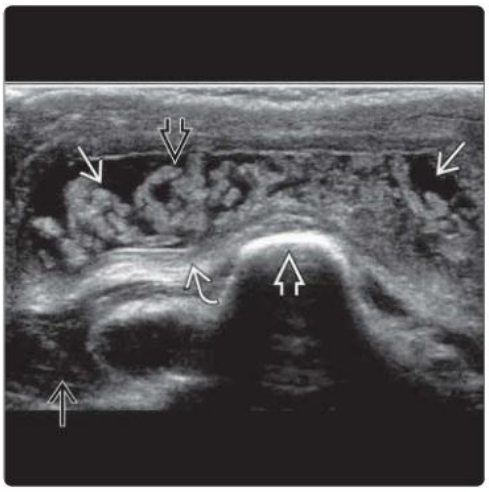

(Left) *Longitudinal US shows a distended iliopsoas bursa ⇨ anterior to a nondistended hip capsule ⇨. The iliopsoas tendon ⇨ is displaced anteriorly. The bursa contains thick strands of blood clot ⇨ and fluid. Aspirate grew Staphylococcus aureus.* **(Right)** *Transverse US shows a moderately distended olecranon bursa ⇨ with frond-like synovial proliferation ⇨ posterior to the olecranon ⇨. The triceps tendon insertion ⇨ with its radial extension and the anconeus muscle ⇨ are normal.*

Bursal Distention

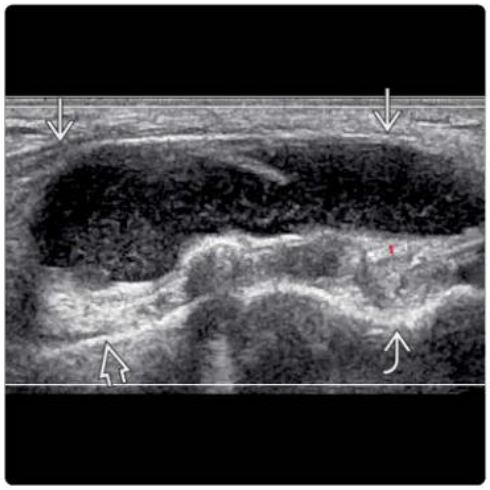

Liquefied Hematoma

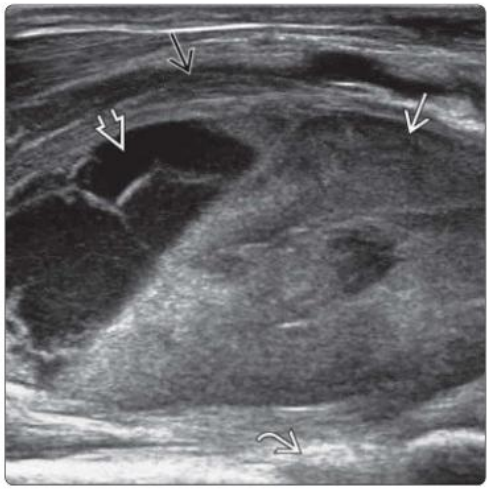

(Left) *Longitudinal color Doppler US shows a subacutely distended adventitial bursa between the iliotibial band, the popliteal groove at the lateral distal femur and proximal tibia. Four mL of blood-stained fluid was aspirated, resulting in bursal collapse.* **(Right)** *Longitudinal US in an older man following venepuncture 1 week earlier shows a large hematoma anterior to the elbow joint, with partial liquefaction, sedimentation, and septation. The brachialis muscle is displaced superficially.*

Liquefied Hematoma

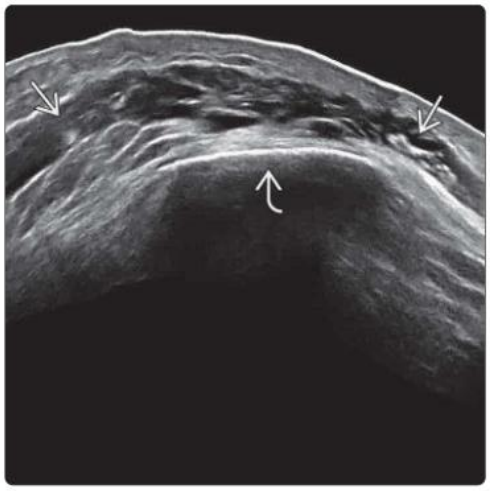

Liquefied Hematoma

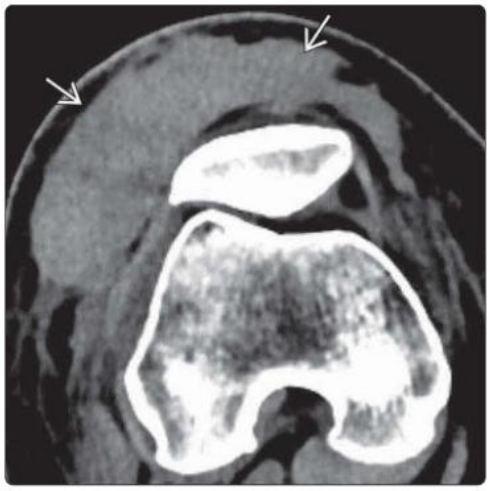

(Left) *Extended FOV transverse US of anterior knee 1 month following a fall shows a septated prepatellar cystic mass, extending far beyond the normal margins of a prepatellar bursa. This favors a liquefied hematoma or Morel-Lavallée lesion. Note the patella.* **(Right)** *Unenhanced axial CT of the same knee collection is shown. The mildly hyperdense nature supports a liquefying hematoma, which was confirmed on aspiration. Its wide coverage and fusiform irregular shape are consistent with a Morel-Lavallée lesion.*

Liquefied Hematoma

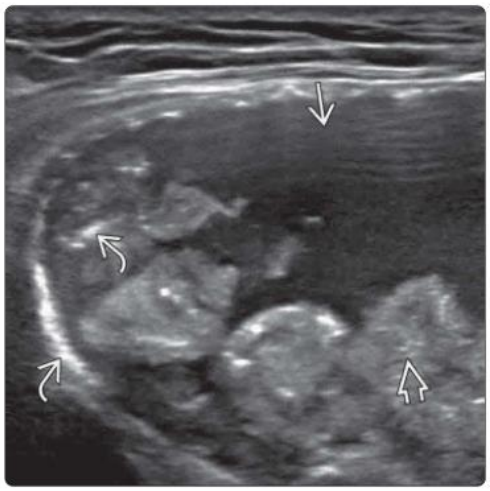

Abscess or Collection

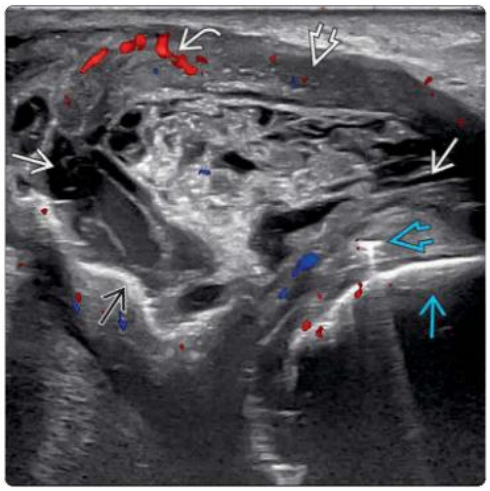

(Left) *Transverse US shows a large, partially liquefied hematoma in the distal thigh. The solid component is an organizing blood clot. This hematoma is chronic with early capsular and internal calcification.* **(Right)** *Transverse US 1 year after hip arthroplasty shows a large chronic seroma seen as a complex mixed solid-cystic mass anterolateral to the proximal femur and surgical femoral cable. Note the thick rim with mild inflammation and early soft tissue calcification.*

Abscess or Collection

Abscess or Collection

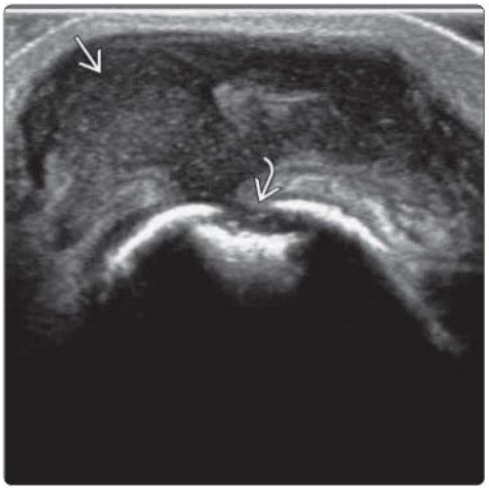

(Left) *Transverse US in an intravenous drug user shows abscesses ➡ superficial to the infected sternoclavicular joint ➡ with medial clavicle osteolysis ➡. Note the thick walls ➡ and debris ➡. Aspirate grew S. aureus.* **(Right)** *Transverse US in a patient with painful elbow swelling shows a posterior elbow abscess ➡ communicating with an olecranon cortical defect ➡, indicative of a cloaca. Subsequent MR and aspiration confirmed olecranon osteomyelitis and abscess.*

Cystic-Appearing Soft Tissue Tumors

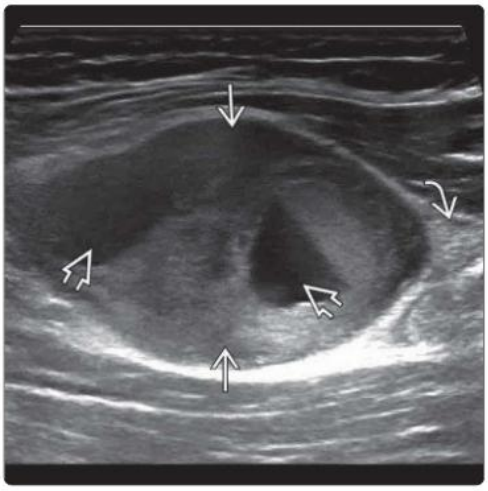

Pseudoaneurysm

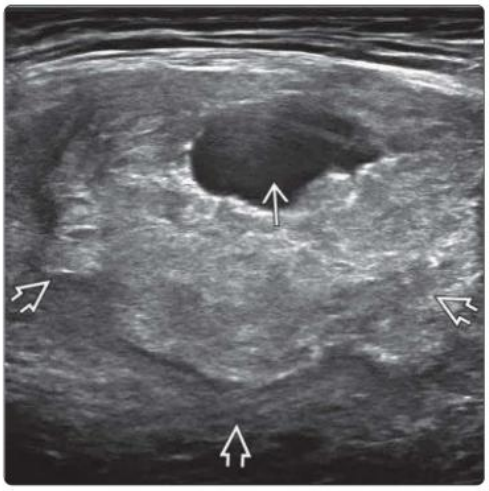

(Left) *Longitudinal US of an ancient schwannoma ➡ shows internal cystic degeneration ➡. The split-fat sign ➡ and continuation with the radial nerve (not shown) are characteristic of a neurogenic tumor.* **(Right)** *Transverse US of a lateral circumflex femoral artery pseudoaneurysm ➡, surrounded by a large hematoma ➡ spanning 19 cm (partially imaged), is shown. This patient presented with a slow-growing anterior upper thigh mass over 4 years following femoral neck ORIF.*

Pseudoaneurysm

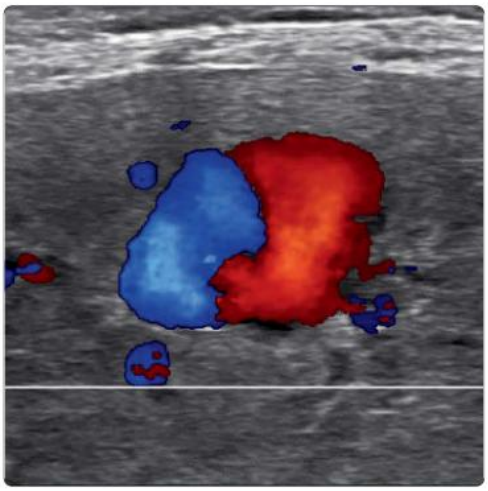

Pseudoaneurysm

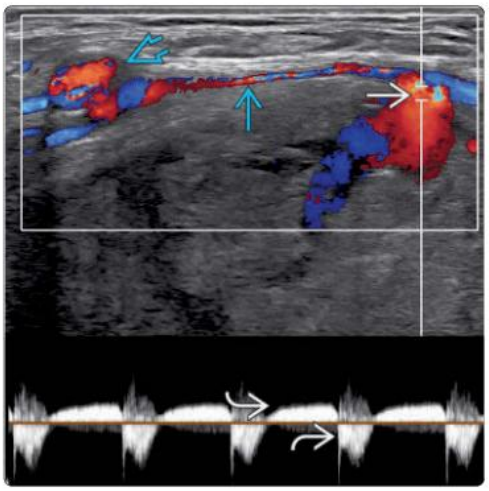

(Left) *Transverse color Doppler US of the same pseudoaneurysm shows the yin-yang sign due to blood swirling within the pseudoaneurysm sac.* **(Right)** *Spectral analysis of the pseudoaneurysm neck ➡ shows the typical to-and-fro spectral pattern ➡. This pattern results from blood flowing inward to the arterial sac during systole and outward to the feeding lateral circumflex femoral artery ➡ during diastole. Note the profunda femoris artery ➡.*

DIFFERENTIAL DIAGNOSIS

Common

- Osteoarthritis-Associated Synovitis
- Inflammatory Synovitis
- Crystal Related: Gout or Pseudogout

Less Common

- Pigmented Villonodular Synovitis
- Focal Nodular Synovitis
- Synovial Osteochondromatosis
- Septic Arthritis
- Prosthetic Synovitis
- Hemosideric Synovitis
- Lipoma Arborescens
- Amyloid Deposition
- Synovial Hemangioma
- Synovial Sarcoma
- Synovial Lymphoma

Rare but Important

- Synovial Chondrosarcoma

ESSENTIAL INFORMATION

Key Differential Diagnosis Issues

- Diagnosis of synovial mass is based on several features in addition to US characteristics
  - Clinical features
    - Age of patient, disease onset, & clinical course
  - Pattern of disease
    - Which joint or joints are affected & which part of these joints are affected
  - Radiographic features
    - Joint space narrowing, osteophytes, erosions, mineralization, juxtaarticular osteopenia
  - US characteristics
    - Intraarticular or extraarticular mass
    - Degree of synovial thickening
    - Localized or diffuse synovial thickening
    - Synovial mineralization or particulate matter
    - Degree & character of joint effusion
    - Features of osteoarthritis
    - Degree of synovial hyperemia
    - Degree of periarticular inflammation
  - Serology: Inflammatory markers, antinuclear factor, rheumatoid factor; CCP antibodies
  - Histology
    - US or other image-guided synovial biopsy for histology, culture, & crystal analysis very useful in differentiating types of synovial overgrowth
    - Cannot distinguish between synovial inflammation secondary to osteoarthritis, inflammatory arthropathy, or nontuberculous infective arthropathy

Helpful Clues for Common Diagnoses

- **Osteoarthritis-Associated Synovitis**
  - Knees, hips, hands, & feet
  - Variable synovial inflammation is more common in osteoarthritis than previously thought
    - Secondary to pathologically damaged bone & cartilage
  - Only modest correlation between severity of osteoarthritis & degree of synovitis
- **Inflammatory Synovitis**
  - Synovial proliferation & inflammation is usually earliest manifestation of inflammatory arthropathy
    - Diffuse synovial proliferation
  - Consider inflammatory synovitis when degree of synovitis is greater than expected for underlying joint pathology, e.g., osteoarthritis
  - Mild to moderate synovial hyperemia is typical
    - Color Doppler more sensitive to synovial hyperemia in more superficial joints
  - Degree of synovial hyperemia provides useful indicator of degree of inflammatory activity present
- **Crystal Related: Gout or Pseudogout**
  - Particularly affects feet, wrists, hands, & knee
    - Gout: Due to urate crystal deposition
    - Pseudogout: Due to calcium pyrophosphate dihydrate deposition (CPPD)
  - Hyperechoic crystal aggregates in synovium & joint fluid
    - Urate sand or snowstorm appearance
  - Gout: Thin echogenic band on cartilage surface ("urate icing")
    - More severe crystal deposition leads to double contour sign of irregular hyperechoic band on hypoechoic cartilage surface
  - Tophi more common in gout than CPPD
    - Tophi seen as hyperechoic inhomogeneous masses surrounded by thin anechoic rim
      - Inflamed tophi have peripheral hyperemia & surrounding soft tissue edema
    - Common in periarticular location
  - CPPD: Thin echogenic band in midzone of articular cartilage

Helpful Clues for Less Common Diagnoses

- **Pigmented Villonodular Synovitis**
  - Benign proliferative synovial disorder
    - Affects synovium of joint, bursa, or tendon sheath
  - Knee > hip > ankle > shoulder
  - However, diffuse synovial involvement may predominate in ≥ 1 areas
  - Usually moderate to high degree of hyperemia
    - Occasionally little or no hyperemia
  - Characteristic MR pattern on gradient-echo imaging due to paramagnetic effect of hemosiderin
    - Hemosiderin is present in 85% of pigmented villonodular synovitis (PVNS) cases (i.e., lack of hemosiderin does not exclude diagnosis)
- **Focal Nodular Synovitis**
  - Localized to single area of synovium
    - Although histologically identical, focal disease behaves differently from diffuse disease
    - Focal nodular synovitis (FNS) contains less hemosiderin, does not have frond-like projections, & becomes more pedunculated rather than more extensive with growth
- **Synovial Osteochondromatosis**
  - Proliferation & metaplastic transformation of synovium

- Affects any synovium, including synovium-lined joint, bursa, or tendon
  - Knee > elbow > hip > shoulder
- Cartilage nodules are hypoechoic; mineralized nodules are hyperechoic
- ± erosion of cartilage & bone
- ± secondary degenerative change

- **Septic Arthritis**
  - Difficult to distinguish between tuberculous & pyogenic infection based on imaging alone
  - With chronic infection, synovial proliferation predominates with little or no synovial fluid
  - US-guided synovial biopsy to identify infection & causative organism
- **Prosthetic Synovitis**
  - Aseptic inflammatory reaction around prosthetic implants a.k.a. adverse local tissue reaction (ALTR)
  - Synovial capsular thickening & effusion, particularly beyond early postoperative period, should raise suspicion of ALTR
  - Metallic debris can be seen on US, radiographs, CT, & MR
    - US: Hyperechoic aggregates within thickened synovium ± hyperechoic line inner margin of synovium; metal-line sign
    - Radiographs, CT: High-density material in joint capsule
    - MR: Foci of low signal on all sequences with blooming artifact on gradient-echo imaging
- **Hemosideric Synovitis**
  - Due to repeated intraarticular hemorrhage
    - Commonest due to hemophilia, which is X-linked autosomal recessive disease
  - Knee > ankle > elbow joints most commonly affected
  - Recurrent episodes of synovial bleeding leads to hyperplastic, hyperemic synovium, which is more susceptible to hemorrhage; this is self-perpetuating cycle
  - US can gauge presence & severity of hemarthrosis, degree of synovial hypertrophy, & synovial hyperemia
- **Lipoma Arborescens**
  - Proliferation of subsynovial fat → villous-like synovial swelling & proliferation
    - Secondary to inflammatory or traumatic stimuli
  - Usually presents around 50 years of age
    - Monoarticular with predilection for suprapatellar recess of knee
  - Hyperechoic, frond-like, synovial mass that bends & waves during joint movement on real-time scanning
- **Amyloid Deposition**
  - Abnormal accumulation of insoluble protein amyloid within tissues
  - Shoulder, hip, knee, & wrist; usually bilateral
    - Shoulder: Tendon & bursal thickening, periarticular hypoechoic nodules ± bony erosions
- **Synovial Hemangioma**
  - Most synovial hemangiomas are vascular malformations
  - Similar to vascular malformations, synovial vascular malformations usually have either predominant vascular or stromal component
    - ± phleboliths (common), ectatic vessels, venous lakes
  - Usually presents in young adulthood leading to repeated hemarthroses, joint pain, & swelling
- **Synovial Sarcoma**
  - Named due to similarity to synovial tissue under light microscopy but does not arise from synovium
  - Arises from primitive mesenchymal cells in extraarticular soft tissues
    - < 5% of synovial sarcomas arise from within joint
  - Calcification in up to 50% of synovial sarcomas
    - ± myxoid areas, cystic areas, or hemorrhage
- **Synovial Lymphoma**
  - Irregular synovial proliferation
  - Focal irregular cortical osteolysis
  - Regional lymphoma-type adenopathy

Helpful Clues for Rare Diagnoses

- **Synovial Chondrosarcoma**
  - May occur de novo or in conjunction with synovial chondromatosis
  - Bony infiltration differentiates from synovial chondromatosis

Osteoarthritis-Associated Synovitis

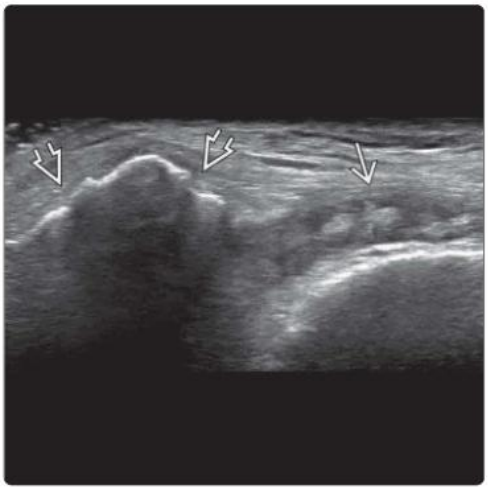

Osteoarthritis-Associated Synovitis

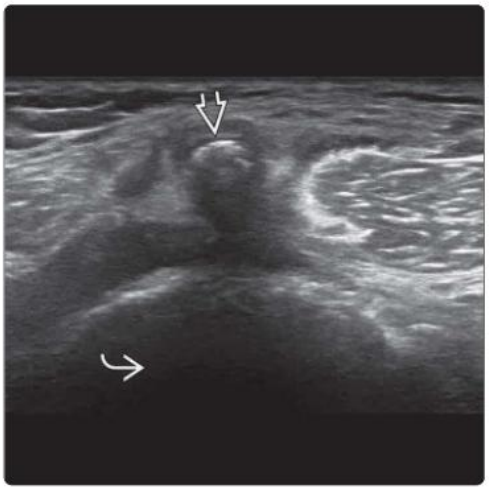

(Left) *Transverse US of the medial parapatellar recess in an 80-year-old man with knee pain shows a large patellar osteophyte ⇨ with moderate synovial proliferation ⇨ and a small effusion. Features are indicative of hypertrophic-type osteoarthritis.* **(Right)** *Longitudinal US of the posterior aspect of the knee joint in the same patient shows a medium-sized intraarticular osseous body ⇨ posterior to the femoral condyle ⇨.*

Inflammatory Synovitis

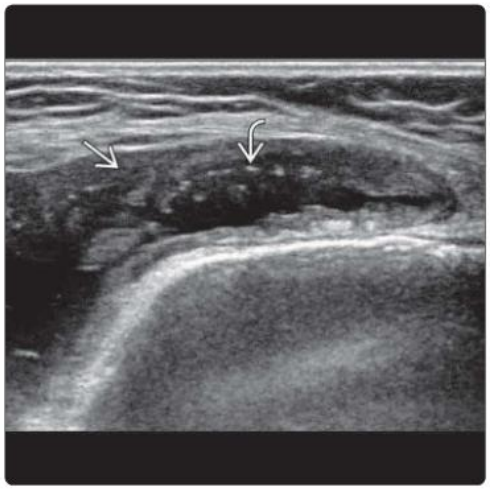

Inflammatory Synovitis

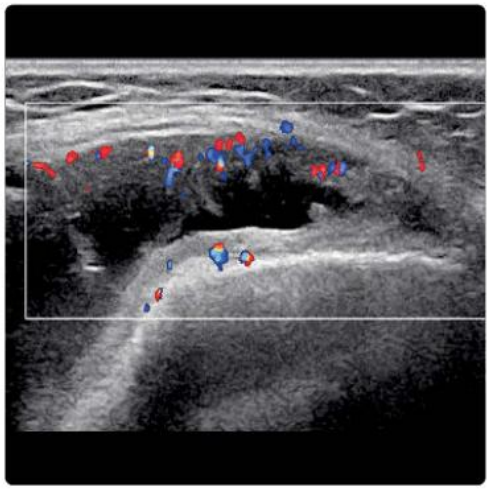

(Left) *Transverse US shows a small effusion with moderate synovitis ➡ of the lateral patellar recess in a patient with known RA. There are some small echogenic foci ➡ present due to either crystal or proteinaceous aggregates. This degree of crystal deposition, which can be seen in & may aggravate either osteoarthritis or RA, is not as pronounced as in a primary crystal arthritis.* **(Right)** *Transverse color Doppler US of the same area shows moderate synovial hyperemia, a direct indicator of synovial inflammatory activity.*

Inflammatory Synovitis

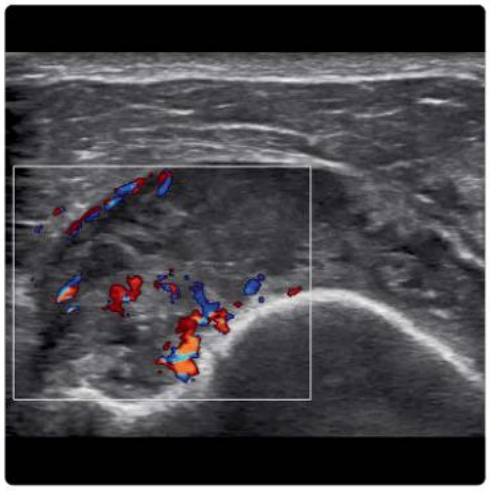

Crystal Related: Gout or Pseudogout

(Left) *Color Doppler US of the same area shows moderate-severity hyperemia within the thickened synovium. Features are indicative of severe bursal inflammation secondary to RA.* **(Right)** *Transverse US of the shoulder in a 72-year-old man with RA shows severe distention of subacromial-subdeltoid bursa with more solid-type severe synovial proliferation ➡ & a small effusion ➡. This tends to be seen with more chronic synovitis.*

Crystal Related: Gout or Pseudogout

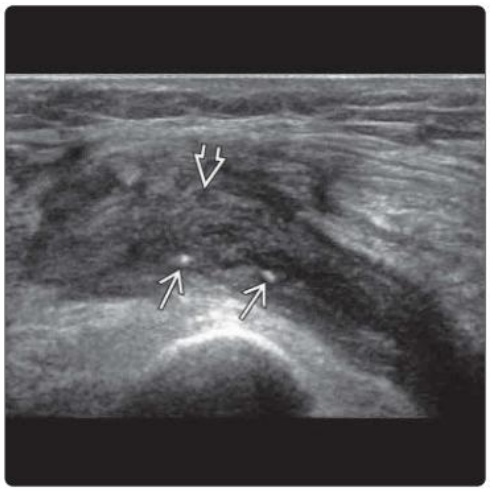

Crystal Related: Gout or Pseudogout

(Left) *Transverse US of medial aspect of knee joint in a 78-year-old man shows moderate synovial proliferation ➡ with multiple small echogenic foci ➡ along synovial surface, suggestive of crystal arthritis.* **(Right)** *Corresponding frontal radiograph of knee joint shows severe medial tibiofemoral joint space narrowing with moderate subchondral bony resorption. Overall, calcium pyrophosphate dihydrate deposition with osteoarthritis is more likely than gout. Gout would tend to have more crystal aggregates within the knee joint.*

Crystal Related: Gout or Pseudogout

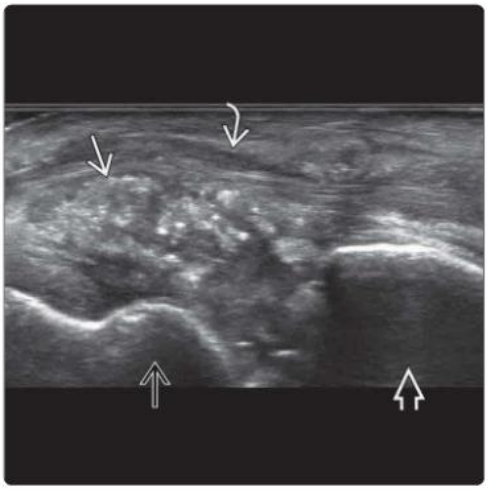

Pigmented Villonodular Synovitis

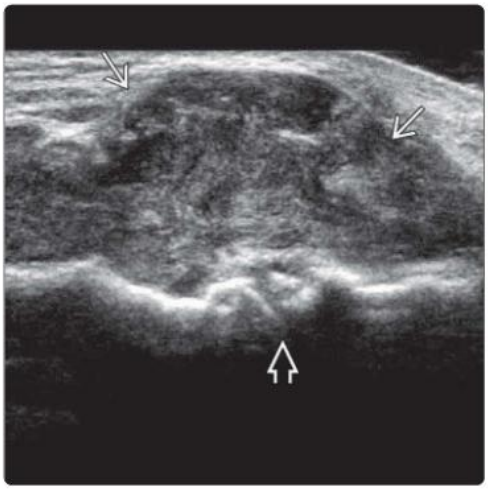

(Left) *Longitudinal US of wrist in man with chronic gout shows severe synovial thickening on dorsum of radiocarpal joint with snowstorm appearance due to crystal aggregates ➡ embedded in synovium. There is also a moderate gouty extensor digitorum tenosynovitis ➡. Distal radius ➡ & capitate ⇨ are normal.* **(Right)** *Longitudinal US of medial hindfoot shows a large, hypoechoic mass ➡ centered on the dorsal aspect of talocalcaneal articulation ➡. Biopsy confirmed pigmented villonodular synovitis (PVNS).*

Pigmented Villonodular Synovitis

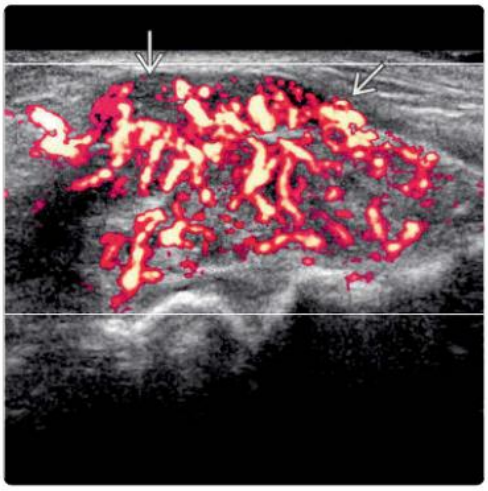

Pigmented Villonodular Synovitis

(Left) *Longitudinal power Doppler US of the same areas shows the mass ➡ to be highly vascular. This level of hyperemia favors PVNS, although not all PVNS tumors are so vascular.* **(Right)** *Clinical photograph of a 41-year-old woman with focal swelling ➡ of the midfoot for 6 months shows mild bluish discoloration possibly due to prior hemorrhage.*

Pigmented Villonodular Synovitis

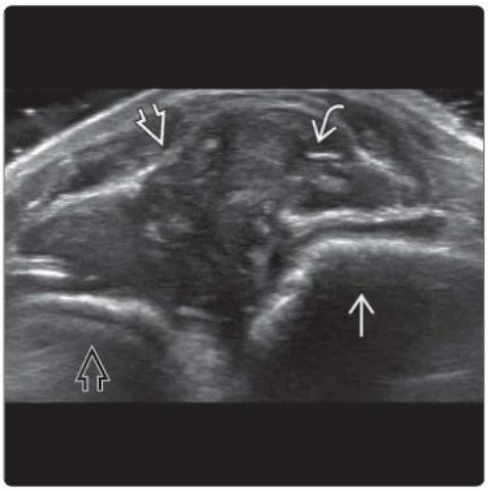

Focal Nodular Synovitis

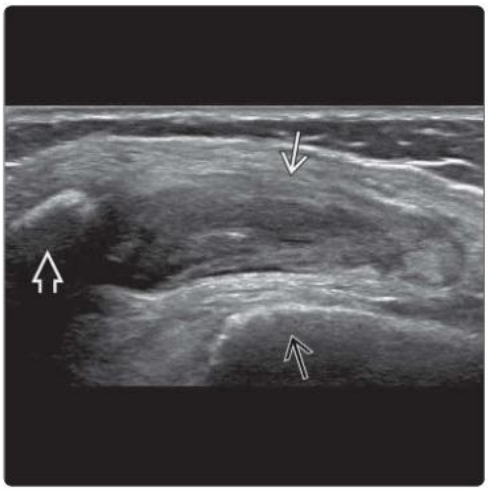

(Left) *Longitudinal US of the same swelling shows a well-defined soft tissue mass ➡ arising between cuboid ➡ & lateral cuneiform bones ⇨. Small echogenic foci within the mass may be due to fibrotic nodules from prior hemorrhage ➡. Biopsy confirmed PVNS.* **(Right)** *Transverse US of the lateral parapatellar recess of the knee in a 45-year-old woman shows a focal, hypoechoic, intraarticular mass ➡ within the lateral patellar recess between the patella ➡ & femur ⇨. The knee joint was otherwise normal.*

(Left) *Color Doppler US of the same mass shows mild hyperemia ➡. Appearances favored focal nodular synovitis, which was confirmed on US-guided biopsy.* **(Right)** *Transverse US of the shoulder shows multiple roundish loose bodies ➡ with moderate surrounding fluid in a distended subacromial-subdeltoid bursa. There is possible early rim ossification. These features favor synovial osteochondromatosis. The nodules are larger than those of rice bodies.*

Focal Nodular Synovitis

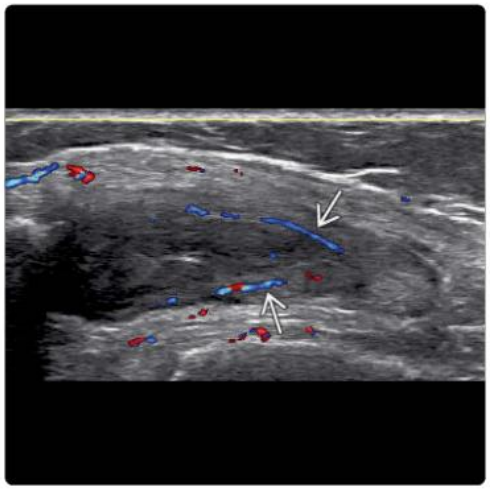

Synovial Osteochondromatosis

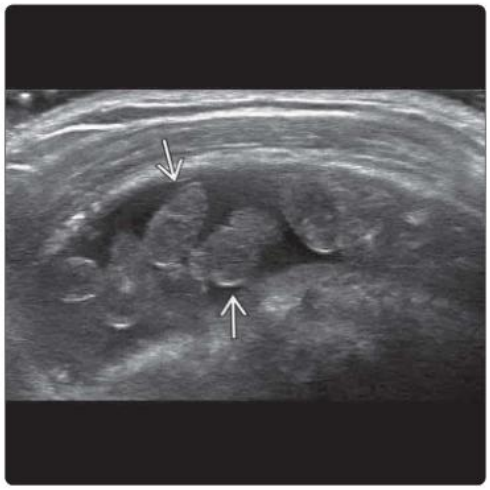

(Left) *Transverse US of a 60-year-old patient with diabetes admitted for fever & painful swelling of the middle finger shows moderate distention of the dorsal recess of the metacarpophalangeal joint ➡ with moderate synovial proliferation ➡.* **(Right)** *Color Doppler US of the same joint shows moderate hyperemia both within the thickened synovium ➡ & in the periarticular soft tissues ➡. US-guided joint aspiration confirmed septic arthritis due to Staphylococcus aureus.*

Septic Arthritis

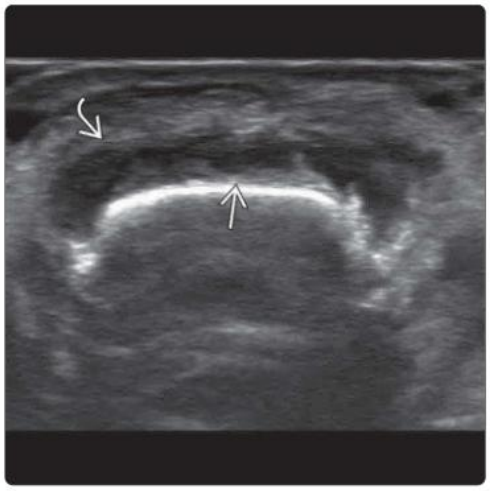

Septic Arthritis

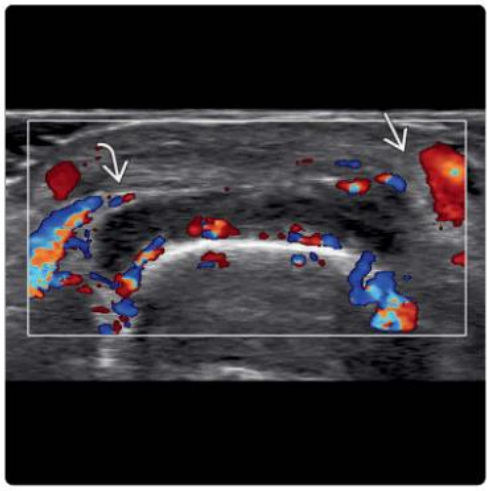

(Left) *Longitudinal US in a patient with chronic knee swelling shows a large effusion ➡ with severe, frond-like, hyperechoic synovial proliferation ➡ on the posterior aspect of the suprapatellar pouch. No free nodules are present. US features were compatible with lipoma arborescens.* **(Right)** *Transverse US shows a well-defined, hypoechoic, lobulated, peritendinous mass ➡ on the medial side of the ankle joint in a patient on hemodialysis. US-guided biopsy specimen revealed amyloid.*

Lipoma Arborescens

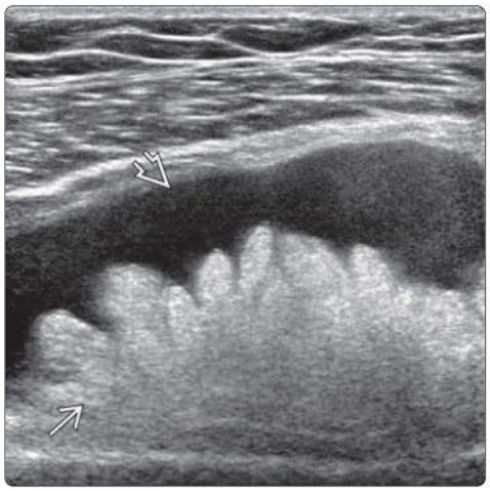

Amyloid Deposition

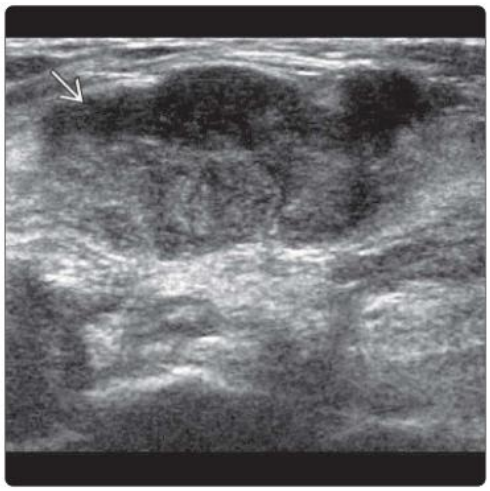

Synovial Sarcoma

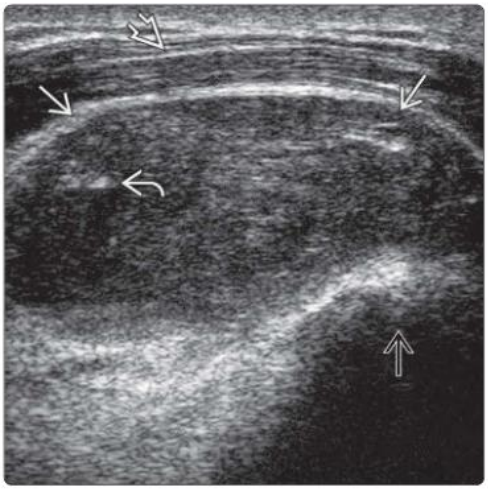

Synovial Sarcoma

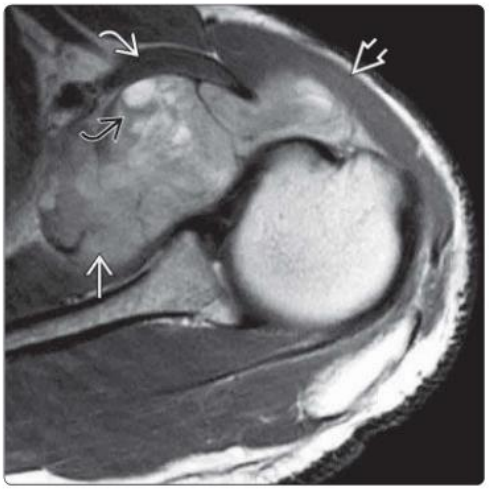

(Left) *Transverse US of the shoulder shows a large, hypoechoic mass ➡ with small echogenic areas ➡, which may represent hemorrhage or fibrotic plaques, between the deltoid muscle ➡ & the humerus ➡.* **(Right)** *Axial T2 MR of the shoulder in the same patient shows a mildly hyperintense mass ➡ with small cyst-like areas ➡, deep to the pectoralis ➡ & deltoid ➡ muscles. US-guided biopsy confirmed synovial sarcoma.*

Synovial Lymphoma

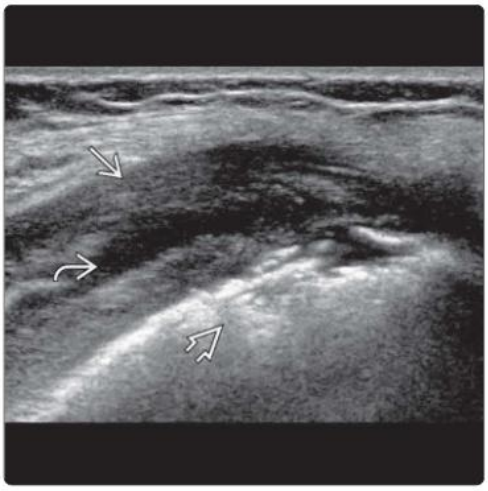

Synovial Lymphoma

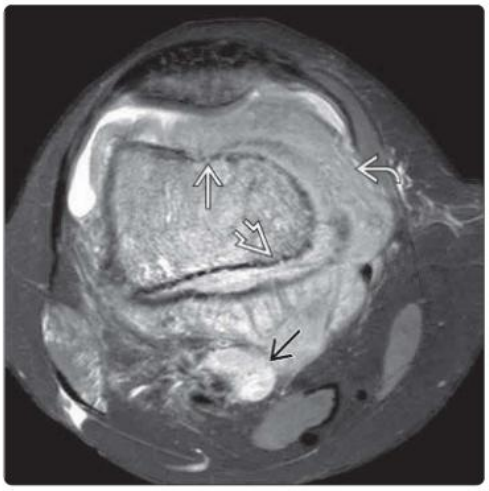

(Left) *Transverse US shows severe synovial thickening ➡ with a small knee joint effusion ➡ & cortical resorption ➡ of the medial femoral condyle. Tuberculosis infection was initially suspected.* **(Right)** *Axial T2 FS MR in the same patient shows the mass extending from the medullary canal of the distal femur with cortical resorption ➡, periosteal thickening ➡, & synovial thickening ➡. There is an enlarged popliteal lymph node ➡. Synovial biopsy revealed B-cell lymphoma.*

Synovial Chondrosarcoma

Synovial Chondrosarcoma

(Left) *Lateral radiograph of the knee in a patient with knee swelling for 20 years shows severe scalloping of the posterior aspect of the lateral femoral condyle & supracondylar area ➡.* **(Right)** *Longitudinal US of the same knee shows a large, lobulated mass ➡ on the posterior aspect of the knee joint with posterior bone scalloping ➡. Some small, calcific-type foci are present ➡. Histology following US-guided biopsy revealed synovial chondrosarcoma.*

DIFFERENTIAL DIAGNOSIS

Common

- Osteoarthritis

Less Common

- Inflammatory Arthropathy
- Crystal Arthropathy
- Infective Arthritis
- Hemarthrosis
- Lipohemarthrosis

ESSENTIAL INFORMATION

Key Differential Diagnosis Issues

- US is helpful in assessing disease activity & characterization
- Joint effusion, in absence of hemarthrosis, is due to synovitis
  - Accompanied by varying degree of synovial proliferation
- Identifying cause of joint effusion depends on disease pattern rather than single US characteristic
  - Speed of onset, severity of effusion & synovitis, associated features, number of joints affected, patient age, radiographic, & clinical picture
  - Involvement of > 1 joint affected is against, but does not exclude, infective etiology
  - Symmetric involvement favors inflammatory, including reactive, arthritis
- Characteristics of joint fluid are useful to note but, other than crystal arthritis, lack specificity
  - Amount & appearance of joint fluid in osteoarthritis (OA), inflammatory arthritis, repeated hemarthrosis, & septic arthritis may appear similar
    - Distinguish among these entities by noting concurrent US features as well as history & clinical presentation
  - Note presence of crystal aggregates, which are suggestive of crystal arthritis
    - Crystal aggregates can also be seen, as manifestation of structural joint damage, in OA, infective arthritis, & inflammatory arthritis
    - High concentration of crystal aggregates favors diagnosis of crystal arthritis
      - Also check for other signs of crystal deposition
      - Uncommonly, acute crystal arthritis may have no demonstrable signs on US other than effusion
    - Any combination of common etiologies of joint effusion can coexist, e.g., OA & infection, inflammatory & infective, crystal & OA
      - Need to ascertain what is dominant etiology
- US-guided fluid aspiration is often necessary & very helpful
  - Send fresh specimen for crystal analysis, as saline or alcohol can dissolve crystals

Helpful Clues for Common Diagnoses

- **Osteoarthritis**
  - Commonly affects knee, hip, interphalangeal, 1st carpometacarpal, triscaphe, wrist, acromioclavicular, & midfoot joints
  - Joint space narrowing, marginal osteophytosis, capsular swelling, synovitis, & effusion are US signs of OA
    - Joint effusion tends to be seen in larger joints with less restrictive capsules
  - US increasingly used to determine inflammatory component of OA & differentiate OA from crystal deposition disease or inflammatory arthropathy
  - Variable reactive-type synovial proliferation
  - ± variable periarticular inflammation
    - Inflammatory component of OA important to note, as this can be treated with antiinflammatory medication
  - Inflammatory element of OA characterized by
    - Joint effusion, capsular thickening, synovial proliferation, synovial, capsular, & pericapsular hyperemia, periarticular soft tissue edema

Helpful Clues for Less Common Diagnoses

- **Inflammatory Arthropathy**
  - Affects any synovial-lined joint
    - Often bilateral & symmetric
  - Polyarthropathy is more common than oligoarthropathy; monoarthropathy is least common
  - Most common finding: Pannus = synovial proliferation
    - Diffusely thickened synovium
    - Frond-like or nodular synovial proliferation
    - May resemble echogenic or hypoechoic synovial fluid
  - Effusion may be anechoic or hyperechoic
  - ± echogenic speckles due to precipitated fibrin, inflammatory debris, or crystals
  - Color Doppler imaging
    - Helpful for estimating level of disease activity & distinguishing synovium from joint fluid
    - Hyperemia is more easily appreciated in smaller joints (e.g., wrist) than larger joints (e.g., hip)
    - Active pannus leads to increased color flow
    - Hyperemia is graded semiquantitatively as high, intermediate, or low/absent vascularity
    - Quantitative analysis of hyperemia is feasible, though semiquantitative analysis is adequate for clinical use
  - Features of structural damage include joint space narrowing, subluxation
    - ± marginal erosions
      - Well-defined, small, periarticular defects which may coalesce to form larger erosions
      - US is more sensitive than radiography & MR at detecting small joint periarticular erosions
  - Coexistent soft tissue features include tenosynovitis, bursitis, & entrapment neuropathy
- **Crystal Arthropathy**
  - Always consider in any acute arthritis
  - Effusion can be anechoic or hyperechoic
  - Gout results from monosodium urate crystal deposition
    - 1st metatarsophalangeal joint is first affected in 50%; can affect any joint, > lower limbs, hands, & wrists
    - Best diagnostic clue: Multiple echogenic foci with comet-tail artifacts within effusion ± synovium
    - ± urate sand (fine echogenic aggregates) or sandstorm (larger echogenic clumps) appearance
    - ± urate deposition on cartilage surface as thin ("urate icing") or thicker ("double contour") echogenic band
    - Soft tophi (no acoustic shadowing) or hard tophi (dense acoustic shadowing) around joint
  - Pseudogout associated with calcium pyrophosphate dihydrate deposition
    - Knee, wrist, triscaphe joints

  - More often associated with OA
  - Crystal deposition in midzone of articular cartilage → more prolific cartilage loss
  - ± chondrocalcinosis of fibrocartilage (menisci, articular disc triangular fibrocartilaginous complex, glenoid or acetabular labrum)
  - Tophi are less common than in gout
- **Infective Arthritis**
  - Gradual-onset joint swelling over 1-2 days
  - Very tender with severe limitation of movement
  - Usually hematogenous spread
  - Joint effusion
    - Cardinal sign of septic arthritis
    - Swirling or moving echoes on real-time imaging
      - Echogenic fluid due to aggregates of inflammatory debris
    - Anechoic joint fluid does not exclude septic arthritis
  - For most joints, no effusion = no septic arthritis
  - 2 exceptions to this rule
    - For nondistensible diarthrodial joints, such as acromioclavicular joint, effusion is minimal
    - If joint capsule is not intact following rupture or recent surgery, no effusion will develop
  - ± periarticular inflammatory soft tissue mass/phlegmon/abscess
  - US-guided joint aspiration for Gram stain, culture, & cell count is helpful
  - Findings in chronic infective arthritis
    - Synovial proliferation > effusion
      - Often little or no joint effusion
    - ± progressive joint space narrowing, marginal erosion, periarticular inflammation
  - Synovial biopsy for culture & histology helpful to confirm or exclude infection in this content with no joint fluid
- **Hemarthrosis**
  - History of trauma ± associated fracture or known coagulopathy
  - Initially, finely speckled echogenic joint fluid
  - After ~ 5 minutes, shows roughly 2-layered appearance of joint effusion
  - Subacute stage
    - Blood clots → discrete echogenic foci within joint
    - Joint fluid is largely anechoic ± fibrinous adhesions
  - Repeated hemarthroses
    - Variable synovial thickening
      - Common & severe in hemophiliac patients with repeated hemarthroses
      - Synovial hyperemia not usually apparent in hemophiliac arthropathy
    - ± bone overgrowth, secondary OA, progressive joint disorganization
- **Lipohemarthrosis**
  - Leakage of marrow fat into joint cavity
    - Presence of lipohemarthrosis implies fracture communicating with joint
  - Initially, finely speckled echogenic joint fluid
  - After 10 minutes, 3-layered appearance of effusion
    - Fat layer: Least dependent layer (fat)
    - Serum layer: Middle layer (supernatant serum)
    - Cellular layer: Most dependent layer (RBC aggregates)
    - ± hypoechoic areas within floating fat due to trapped blood

Consider

- OA if small effusion with mild synovitis
  - Inflammatory OA or calcium pyrophosphate deposition (CPPD) if larger effusion & more severe hyperemic synovitis
- Inflammatory arthritis if synovial proliferation not commensurate with degree of OA
- Crystal arthritis if large number of crystal aggregates in effusion & synovitis
- Acute infective arthritis if large effusion of recent onset
  - Chronic infective arthritis if moderate or severe synovial proliferation with little or no fluid
    - Alternative possibility is "prosthetic synovitis" [metal hypersensitivity or aseptic lymphocyte-dominated vasculitis-associated lesion (ALVAL)]
    - Synovial biopsy to confirm or refute infection

Osteoarthritis

Osteoarthritis

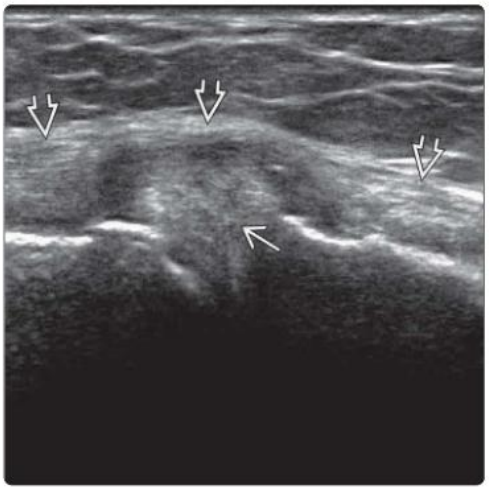

(Left) *Transverse US of the knee shows a mildly distended medial patellar recess ⇨ with mild synovial proliferation extending along a synovial plica ⇨. The patella ⇨ is normal.* **(Right)** *Longitudinal US shows moderate extrusion of the medial meniscal body ⇨, indicative of meniscal degeneration with joint space narrowing due to osteoarthritis. The medial collateral ligament ⇨ is displaced superficially.*

Inflammatory Arthropathy

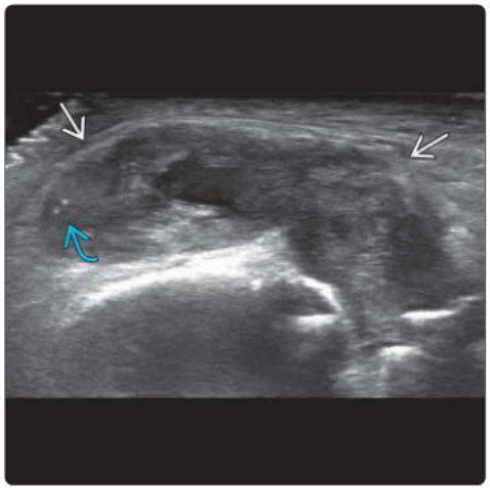

Inflammatory Arthropathy

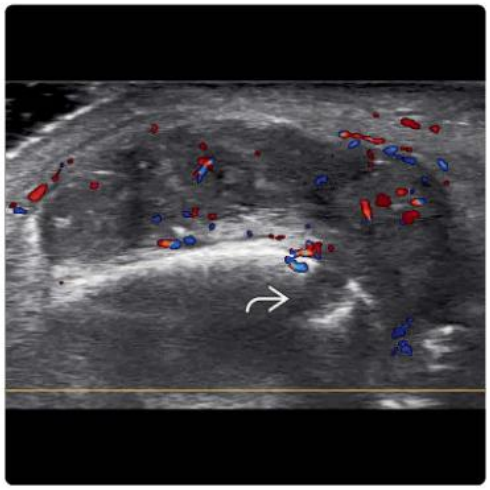

(Left) *Longitudinal US of the elbow shows a severe synovial proliferation distending the ulnohumeral joint in a patient with rheumatoid arthritis. There is small joint effusion. A few echogenic foci can be accepted as a feature of synovial proliferation, per se, and do not indicate crystal arthritis.* **(Right)** *Color Doppler US shows moderate synovial hyperemia. There is an erosion of the olecranon. Features are those of severe established inflammatory synovial hypertrophy with moderate inflammatory activity.*

Crystal Arthropathy

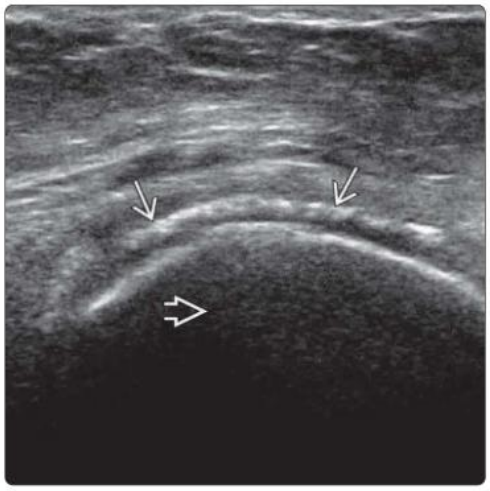

Crystal Arthropathy

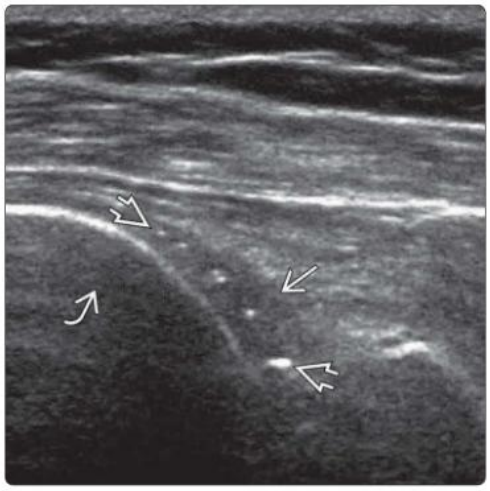

(Left) *Longitudinal US shows an echogenic midzonal band due to calcium pyrophosphate deposition (CPPD) in the articular cartilage of the femoral condyle posteriorly. Medially, there was meniscal chondrocalcinosis present (not shown).* **(Right)** *Transverse US shows gouty arthritis of the glenohumeral joint. There is a small joint effusion with small echogenic crystal deposits on the humeral articular cartilage surface ("urate icing"). Fewer similar echogenic foci may be seen with nitrogen gas bubbles.*

Crystal Arthropathy

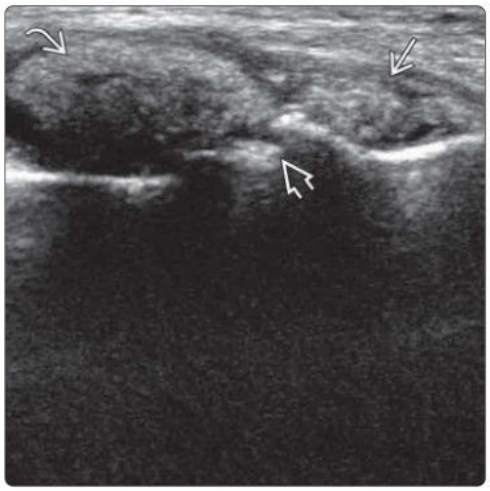

Crystal Arthropathy

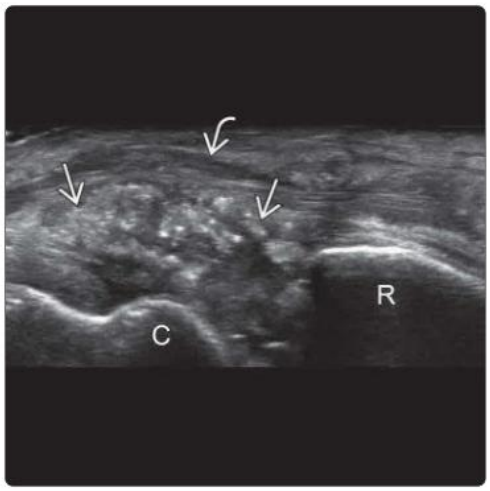

(Left) *Longitudinal US shows an echogenic effusion ("snowstorm") within the 1st metatarsophalangeal joint in a patient with chronic gout. There is also a more well-defined intracapsular soft tophus.* **(Right)** *Longitudinal US of the wrist in a 51-year-old man with chronic gout shows severe synovial thickening on the dorsum of the radiocarpal joint with a snowstorm appearance due to larger crystal aggregates. There is mild extensor tenosynovitis. R= radius; C = capitate.*

Infective Arthritis

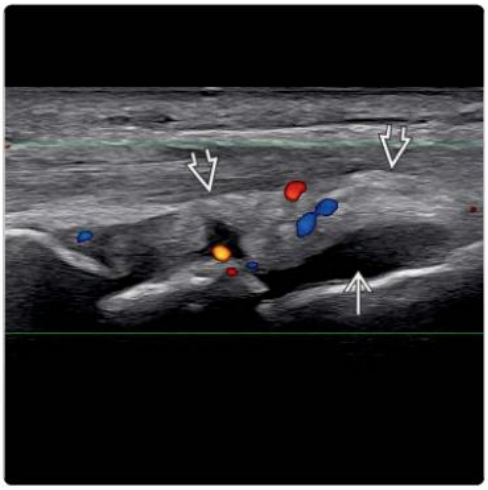

Infective Arthritis

(Left) *Longitudinal US of an intercarpal joint in a 56-year-old man with hand swelling, warmth, and pain for 3 days shows a medium-sized joint effusion* ⇨ *with mild synovial thickening* ⇨ *and midsynovial hyperemia. In this clinical context, this favors acute infective arthritis.* **(Right)** *Needle aspiration* ⇨ *yielded purulent fluid, which grew Staphylococcus aureus.*

Hemarthrosis

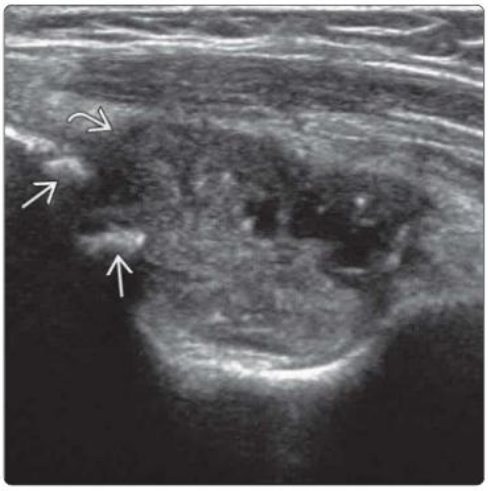

Lipohemarthrosis

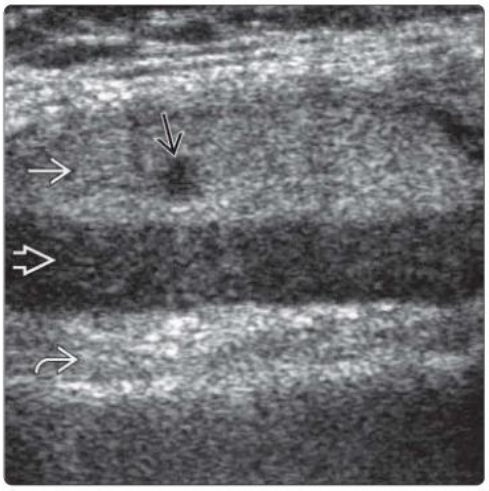

(Left) *Transverse US shows echogenic fluid distending the posterior recess of the elbow joint* ⇨ *due to acute hemarthrosis in a patient with hemophilia. There is also secondary osteoarthrosis with marginal osteophytosis* ⇨*.* **(Right)** *Transverse US of the suprapatellar pouch shows a lipohemarthrosis with fat* ⇨*, serum* ⇨*, and cellular* ⇨ *layers. The hypoechoic area* ⇨ *in the fat layer is due to the entrapped blood. This patient had a fracture of the tibial plateau (not shown).*

Lipohemarthrosis

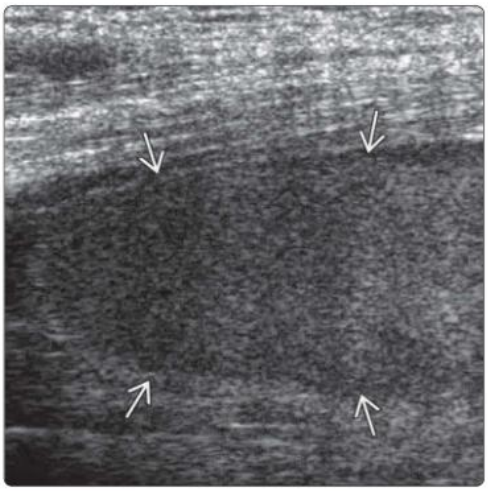

Lipohemarthrosis

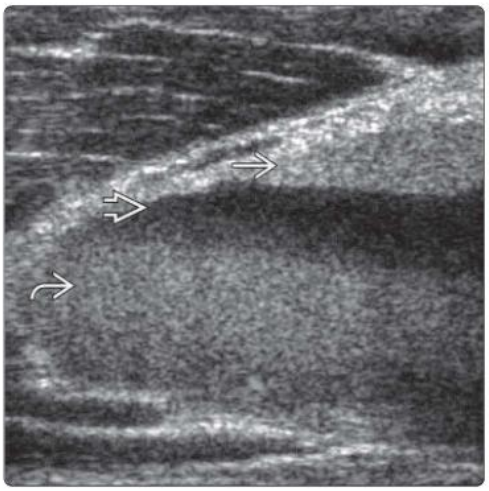

(Left) *Longitudinal US of the knee in a patient with a tibial plateau fracture shows marked distention of the suprapatellar pouch* ⇨ *with echogenic fluid.* **(Right)** *Longitudinal US at the same location, after keeping the joint still for 15 minutes, shows separation of the fluid contents into fatty* ⇨*, serous* ⇨*, and cellular* ⇨ *components. Lipohemarthrosis implies communication between joint and marrow cavity and indicates a bone fracture with leakage of medullary fat into the joint.*

PART IV
SECTION 5

Chest and Abdominal Wall

Chest Wall Lesion 928
Abdominal Wall Lesion 934

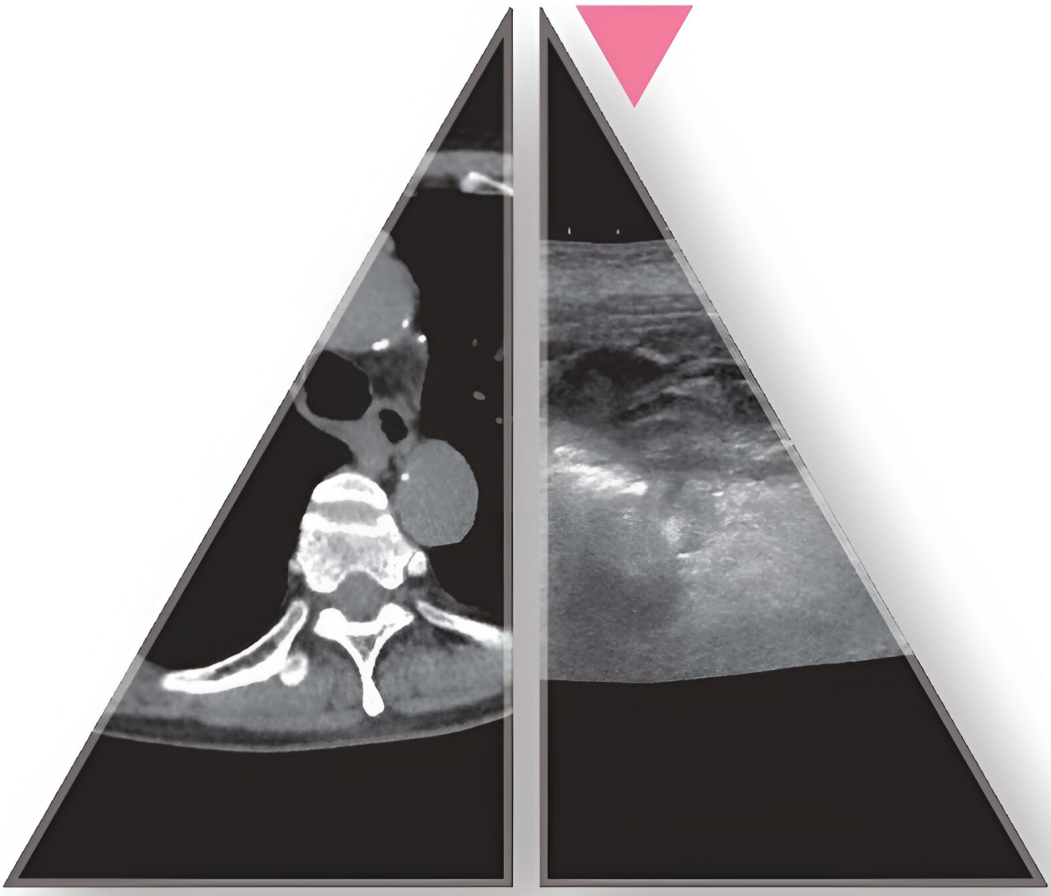

DIFFERENTIAL DIAGNOSIS

Common

- Acute Rib Fracture
- Healing Rib Fracture
- Rib Metastases

Less Common

- Stress Rib Fracture
- Chest Wall Metastases
- Hematoma
- Lipoma
- Gynecomastia
- Accessory Breast
- Carcinoma, Male Breast
- Prominent or Floating Rib
- Prominent Xiphoid Process
- Costochondritis
- Accessory Muscle
- Elastofibroma Dorsi
- Fibroma
- Vascular Malformation
  - Lymphatic Malformation
- Abscess
- Sternoclavicular Joint Arthropathy
- Thyroglossal Duct Cyst

ESSENTIAL INFORMATION

Key Differential Diagnosis Issues

- US is very useful for chest wall lesions, as structures are superficial; retroscapular region is only area not accessible
- For rib fractures, examine around painful area
- Ask patient to place finger over most painful area
  - Caveat: US is less helpful in unconscious, uncooperative patients & young children
- No need to examine all ribs

Helpful Clues for Common Diagnoses

- **Acute Rib Fracture**
  - History of trauma with localized tenderness
  - Sharp break in superficial bone cortex
    - ± displacement or angulation
    - ± adjacent soft tissue swelling or hypoechoic hematoma
    - Wide break in cortex or cortical irregularity suggests pathologic fracture
  - Typically, fractures are vertically aligned to each other
    - Check adjacent ribs alongside rib fracture
  - US will detect 10x more rib fractures than x-ray
    - Also able to accurately detect fractures of costal cartilage or costochondral junction
  - US is more accurate than x-ray at detecting pneumothorax
    - Pneumothorax seen as loss of normal to-&-fro respiratory motion at pleural surface on real-time scanning over least dependent portion of hemithorax
- **Healing Rib Fracture**
  - Fracture margin is less sharp & more rounded
  - Progressive bridging callus
    - Initially hypoechoic mass alongside fracture
    - Progressive ossification of callus with ↑ echogenicity & ↑ acoustic shadowing
    - After ~ 2 months, only ossified cortical bump remains without visible fracture line
    - Cortical contour will take months to years to remodel to normal
  - US can accurately discriminate between acute & nonacute rib fracture
- **Rib Metastases**
  - Common site of skeletal metastases
  - Lung, kidney, hepatocellular carcinoma, & bowel are all common primary sites
  - Usually multiple
    - Randomly located as opposed to linear vertical location of rib fractures
  - Can be detected only if cortex is disrupted
    - Metastases usually originate in medullary canal prior to infiltrating cortices
      - US has low sensitivity for detecting early rib metastases
  - If cortex is disrupted, US is accurate at distinguishing metastatic from traumatic fracture
  - Bone destruction
    - Irregular thinning or loss of echogenic superficial cortex of rib
    - ± soft tissue mass at site of bony destruction

Helpful Clues for Less Common Diagnoses

- **Stress Rib Fracture**
  - US more sensitive than radiography
  - Point-specific pain aggravated by exercise
  - Rowers, some track & field athletes, & golfers
- **Chest Wall Metastases**
  - Feature of advanced malignancy
  - Muscle metastases relatively uncommon, possibly due to
    - Destruction of tumor cells by muscle motion
    - Muscle pH inhospitable to tumor cells
    - Muscle limits accumulation of tumoral lactic acid that induces tumor neovascularity in other tissues
- **Hematoma**
  - Due to trauma, anticoagulation, strenuous & prolonged coughing, vascular malformation
  - Often within pectoralis or intercostal muscles
  - Mildly echogenic mass ± concentric layering liquefaction ± marginal hyperemia
- **Lipoma**
  - Similar appearances to lipoma elsewhere
  - Hypoechoic, well-defined soft tissue mass with fine echogenic striations
- **Gynecomastia**
  - Growth of glandular breast tissue in males
  - Pseudogynecomastia = ↑ fat in male breast
  - Most cases are idiopathic
  - Identifiable causes include
    - Congenital anorchia, Klinefelter syndrome
    - Hermaphroditism, adrenal carcinoma
    - Liver disorders, drugs (spironolactone, cimetidine, estrogen derivatives)
  - Hypoechoic glandular hyperplasia in retroareolar region
    - Branches out in triangular fashion beyond retroareolar region

  - Progressive glandular proliferation → more diffuse echogenic fibrotic proliferation
- **Accessory Breast**
  - Extra breasts may appear ± nipples or areolae
  - Presence of breast tissue outside normal breast contour
  - Mass anywhere along course of embryologic mammary streak (axilla to inguinal region)
- **Carcinoma, Male Breast**
  - Multilobulated cystic pattern more common than mixed cystic-solid pattern
  - Ill-defined more common than well-defined margin
  - Mildly hypervascular, mainly peripheral
- **Prominent or Floating Rib**
  - Prominent rib lies more superficial than the rest
  - Patient may feel lump at end of floating rib, mainly 11th or 12th ribs
- **Prominent Xiphoid Process**
  - Cartilaginous lower end of sternum, which points more forward than usual
    - If large, may be felt as palpable mass
- **Costochondritis**
  - Swelling of chondral part of rib ± adjacent inflammatory change
  - Transducer probe tenderness
- **Accessory Muscle**
  - Pectoralis major muscle: Many variants
    - Aplasia (Poland syndrome), hypoplasia, pectoralis minimus, pectoralis quartus, pectoralis intermedius, pectoralis anomalous
  - Sternalis: Strap-like accessory muscle along sternocleidomastoid-rectus abdominis line
    - Arises from sternum so overlies medial side of pectoralis major
- **Elastofibroma Dorsi**
  - Uncommon; benign, slow-growing, connective tissue tumor
    - Subscapular area (99%); more common in older adults & in females (60%); frequently bilateral
    - More common in individuals who perform manual labor
    - Tumor composed of abnormal elastic fibers
    - Generally regarded as fibroblastic reactive process or pseudotumor
  - Large, well-circumscribed tumor
  - Alternating bands of hypoechoic (fat) & hyperechoic (fibrous) tissue
  - Usually only minimal vascularity
    - Can occasionally be difficult to distinguish from surrounding muscle
- **Fibroma**
  - Hypoechoic subcutaneous nodule with well-defined or ill-defined border
- **Vascular Malformation**
  - Characterized as slow flow or high flow; capillary, venous, lymphatic, arteriovenous, or combined
  - Hypoechoic with heterogeneous echo pattern with dilated vascular channels (± phleboliths in venous type)
  - Slow-moving (to-&-fro) blood with red cell aggregates better seen on grayscale US
  - **Lymphatic malformation**
    - Uni-/multilocular anechoic compressible cystic lesion with thin walls & septa without vascularity
    - Hemorrhage or infection leads to irregular walls, internal debris with fluid-fluid level, & thick septa
- **Abscess**
  - Cystic lesion with posterior acoustic enhancement
  - Adjacent inflammatory change
- **Sternoclavicular Joint Arthropathy**
  - Hypoechoic capsular thickening
  - Check for bone erosion, subluxation, crystals, capsular hyperemia, & pericapsular inflammation or abscess
  - CT usually helpful following initial US assessment
    - Osteoarthritis of sternoclavicular joints is more common than inflammatory, which, in turn, is more common than crystal arthritis or septic arthritis
- **Thyroglossal Duct Cyst**
  - Anywhere along path of thyroglossal duct from tongue base to suprasternal notch
    - Persistence of thyroglossal duct
    - Usually presents in childhood as midline neck mass

Acute Rib Fracture

Healing Rib Fracture

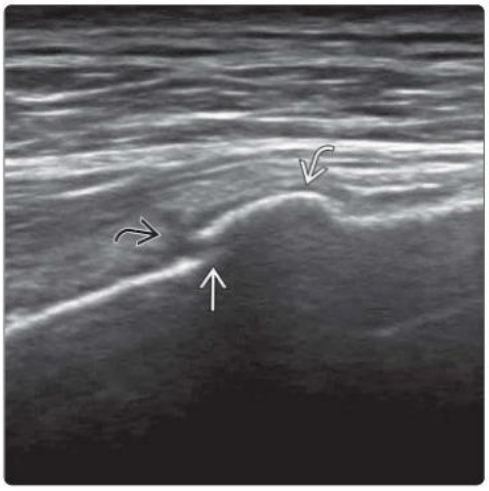

(Left) *Oblique longitudinal US shows an undisplaced acute traumatic fracture ⇨ of the echogenic anterior rib cortex with a small adjacent hematoma ⇨.* **(Right)** *Oblique longitudinal US shows a healing nondisplaced fracture ⇨ of the anterolateral 2nd rib with well-formed echogenic mineralized callus ⇨ surrounded by only a small amount of hypoechoic granulation tissue ⇨.*

(Left) *Clinical photograph of a patient with hepatocellular carcinoma who presented with a painful chest wall mass is shown.* **(Right)** *Transverse US in the same patient shows a hypoechoic metastatic tumor mass completely destroying the 9th rib. There is an extraosseous component abutting onto the adjacent 8th and 10th ribs, which remain intact.*

Rib Metastases

Rib Metastases

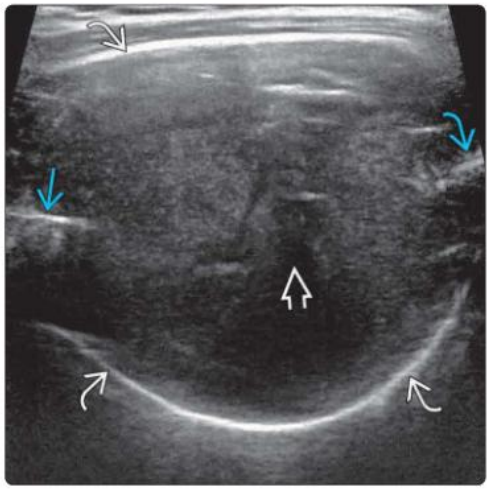

(Left) *Oblique longitudinal US in a patient who developed chest wall pain during intensive training shows a stress fracture of the right 6th rib in the anterior axillary line. There is localized hyperostosis and soft tissue swelling. No cortical fracture is present.* **(Right)** *Transverse US shows a hypoechoic tumor mass in the lateral chest wall muscles. Color Doppler US showed moderate internal vascularity (not shown). The subjacent rib is intact. US-guided biopsy confirmed metastatic carcinoma.*

Stress Rib Fracture

Chest Wall Metastases

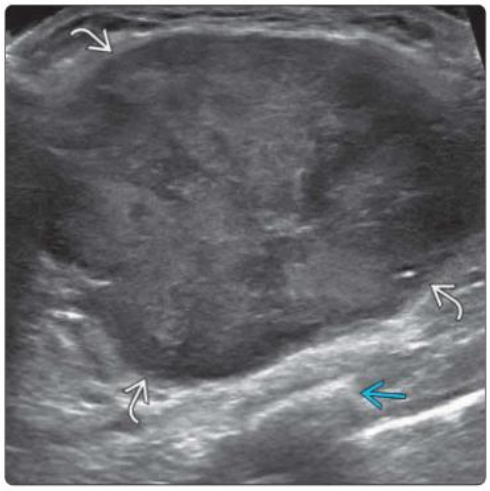

(Left) *Oblique longitudinal US shows a large organizing hematoma within the latissimus dorsi muscle overlying the posterior aspect of a rib. The hypoechoic component of the hematoma is due to early liquefaction.* **(Right)** *Transverse US in a patient on anticoagulation shows a large, heterogenous, subpectoral organizing hematoma. The normal pectoralis major muscle is shown.*

Hematoma

Hematoma

Lipoma

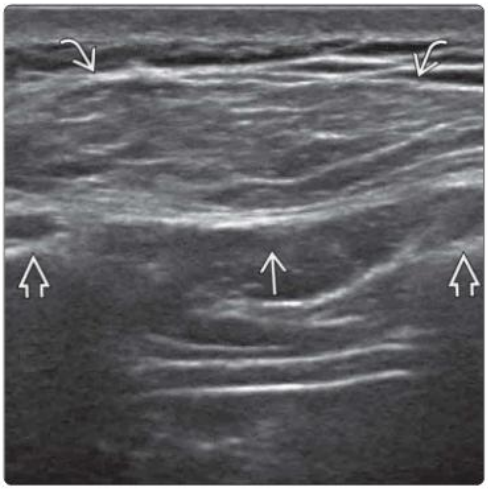

Gynecomastia

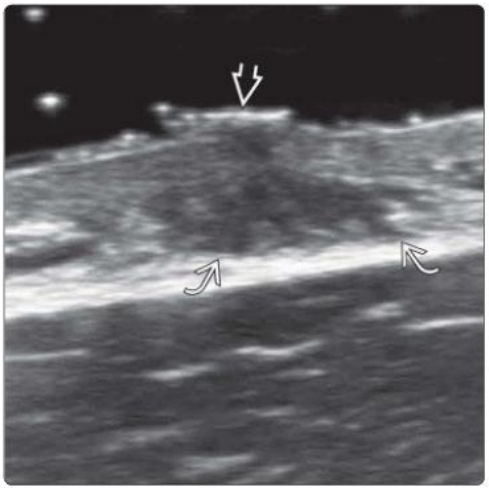

(Left) *Transverse US over the lateral chest wall shows a subcutaneous lipoma. The lesion is well encapsulated and hypoechoic with fine horizontal striations. The subjacent ribs and intercostal muscle are normal.* **(Right)** *Transverse US in a male patient with mild gynecomastia shows orderly, hypoechoic, fibroglandular breast tissue beneath the nipple.*

Gynecomastia

Accessory Breast

(Left) *Transverse US in an 11-year-old boy with moderate gynecomastia shows more discretely seen hypoechoic fibroductal tissue embedded in thickened echogenic fatty stroma.* **(Right)** *Transverse US in a female patient with an axillary mass shows subcutaneous accessory breast tissue at the inferior axilla separate from the normal breast. The mass shows hypoechoic fibroductal tissue interspersed in echogenic fat similar to normal glandular breast tissue.*

Carcinoma, Male Breast

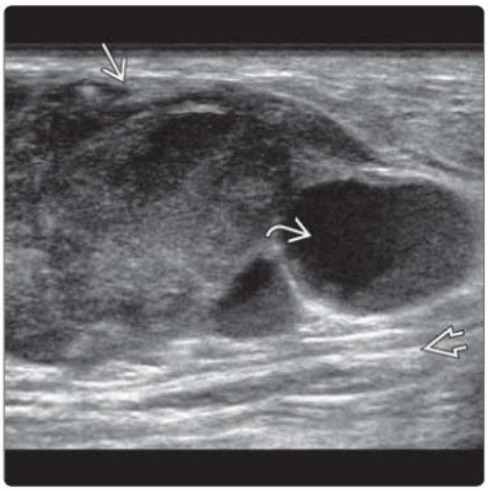

Carcinoma, Male Breast

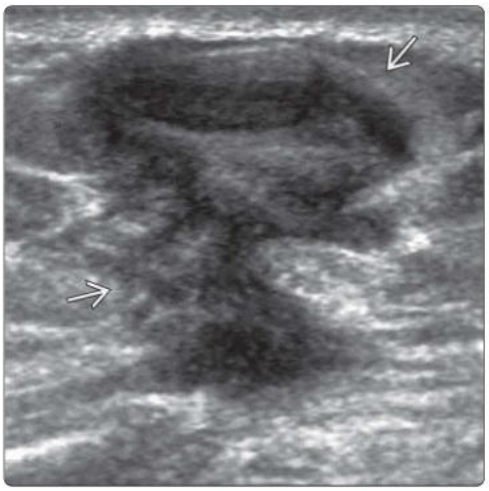

(Left) *Transverse US in a male patient shows a heterogeneous, mixed solid/cystic mass with distinct margins associated with edema and architectural distortion of the surrounding tissue. There is mild posterior acoustic enhancement. Note the cystic component of the mass. Excision confirmed ductal carcinoma.* **(Right)** *Transverse US in a male patient shows a more solid, heterogeneous ductal carcinoma of the male breast with irregular lobulated margins.*

Prominent or Floating Rib

Prominent or Floating Rib

(Left) *Transverse US in a patient with a lower chest wall mass shows a protruding 12th rib ➡, more superficially positioned than the adjacent 11th rib ➡. Both ribs were otherwise normal.* **(Right)** *Longitudinal US in a male patient with a left-side chest wall mass shows a moderately elongated 4th costal cartilage ➡, bulging anteriorly and causing clinical prominence. Adjacent costal cartilages were normal.*

Prominent Xiphoid Process

Costochondritis

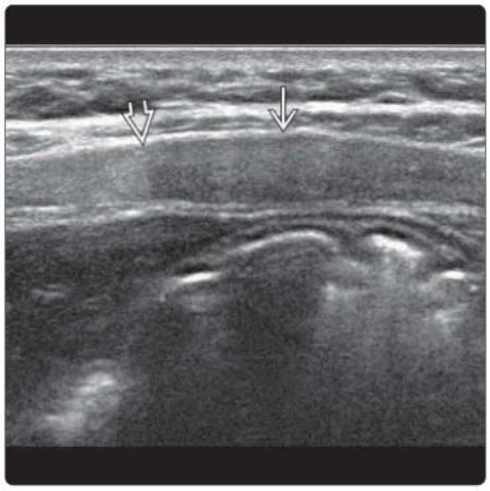

(Left) *Longitudinal US in a young adult with a firm chest lump at the lower sternal area shows a prominent, anteriorly deviated, hypoechoic xiphoid process cartilage ➡ at the distal aspect of the sternal body ➡. This is a normal variant.* **(Right)** *Longitudinal US of the right 2nd rib in a patient with chest wall pain shows mild swelling of the right 2nd costal cartilage ➡ close to the costochondral junction ➡. Although no soft tissue inflammation is evident, there was localized probe tenderness due to costochondritis.*

Elastofibroma Dorsi

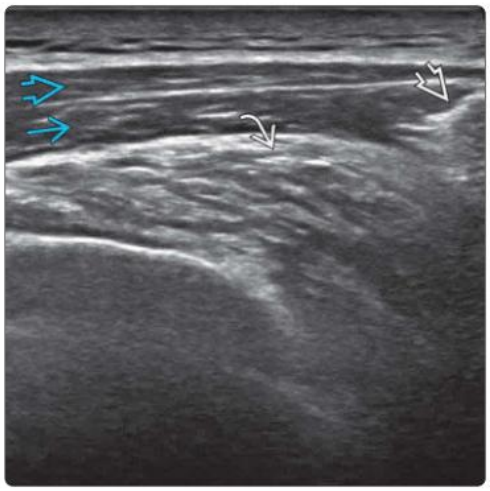

Elastofibroma Dorsi

(Left) *Transverse US of the upper back shows a large layered fibrofatty mass ➡ medial to the scapular tip ➡, consistent with elastofibroma dorsi. The overlying rhomboid ➡ and trapezius ➡ muscles are normal. US appearances in the correct clinical context are diagnostic without the need for biopsy.* **(Right)** *Axial CT in the same patient shows the corresponding right-side elastofibroma dorsi ➡. A smaller lesion ➡ on the left upper back could be easily overlooked as it has similar density to adjacent muscles.*

Fibroma

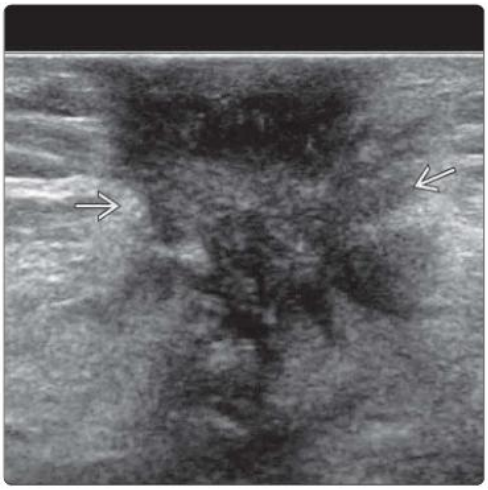

Lymphatic Malformation

(Left) *Transverse US shows a cutaneous and subcutaneous fibroma ➡ in the axillary region. The edges of the typically hypoechoic mass interdigitate with the surrounding fat.* **(Right)** *Longitudinal US shows a poorly defined lymphatic malformation ➡ of the lower anterior chest wall with a prominent cystic component ➡ and poorly defined swollen supporting stroma. The underlying rib is normal ➡. Color Doppler US (not shown) showed no internal vascularity.*

Abscess

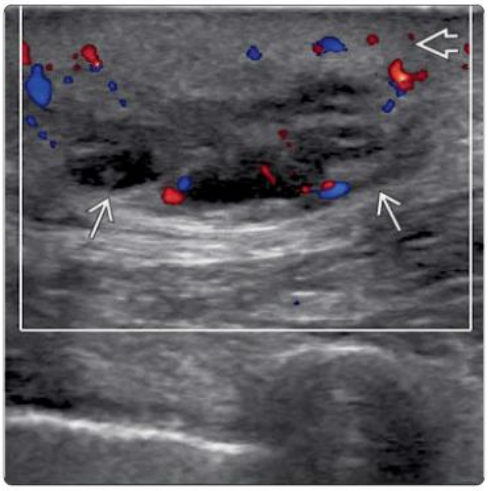

Abscess

(Left) *Transverse color Doppler US of the lower posterior chest wall shows a small, multiloculated, subcutaneous abscess ➡. There is surrounding soft tissue swelling with mild increased vascularity ➡, compatible with surrounding acute cellulitis.* **(Right)** *Transverse US shows a large subpectoral abscess collection ➡ containing mobile low-level echogenicities. The pectoralis major muscle ➡ is normal. The abscess was subsequently aspirated under US guidance.*

Sternoclavicular Joint Arthropathy

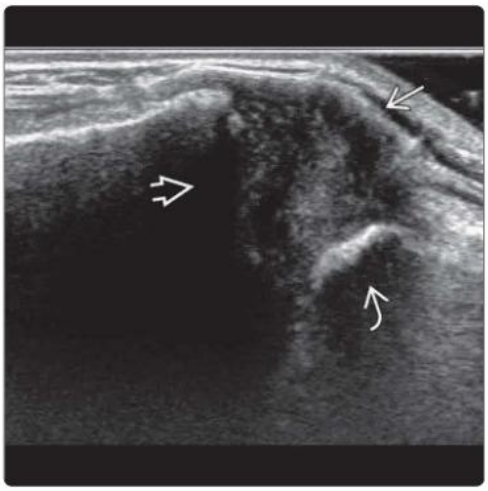

Sternoclavicular Joint Arthropathy

(Left) *Oblique US in a rheumatoid arthritis patient shows moderate inflammatory arthritis of the sternoclavicular joint with prominent capsular thickening ➡ and mild erosion of the medial end of the clavicle ➡. The manubrium ➡ is not eroded. US is good, though CT is better, at discriminating the various forms of sternoclavicular swelling.* **(Right)** *Clinical photograph of the same patient shows how the sternoclavicular joint swelling ➡ is easily visible clinically, as this joint lies just deep to the skin.*

DIFFERENTIAL DIAGNOSIS

Common

- Subcutaneous Lipoma
- Groin Hernia
- Incisional Hernia
- Linea Alba Hernia

Less Common

- Spigelian Hernia
- Paraumbilical Hernia
- Umbilical Hernia
- Lumbar Hernia
- Enlarged Lymph Node
- Endometriosis
- Undescended Testis
- Rectus Sheath/Subcutaneous Hematoma
- Divarication of Rectus Abdominis Muscle
- Fat Necrosis
- Desmoid Tumor
- Muscle Tear
- Abscess
- Granuloma
- Umbilical-Urachal Sinus
- Umbilical Metastasis

ESSENTIAL INFORMATION

Key Differential Diagnosis Issues

- Pay close attention to deep margin of any anterior abdominal wall mass because hernias may masquerade as abdominal wall masses
  - Defect may be small relative to size of mass & potentially overlooked
  - Hernia mass may be fixed & not reducible
  - May look like hypoechoic subcutaneous nodule or lipomatous mass
  - Check for continuity with deeper structures
    - Also check for vascular configuration, peristalsis, & perform Valsalva maneuver
    - ± patient standing upright when suspecting hernia, especially where supine examination is negative & patient symptoms are aggravated by weightbearing
  - If deep border of mass is not seen, reassess with either CT or MR

Helpful Clues for Common Diagnoses

- **Subcutaneous Lipoma**
  - Often multiple & occur in middle age
  - Fusiform mass with thin, horizontal, echogenic, internal striations
    - Compressibility similar to adjacent fat
  - Alternatively, well-defined, rounded or ovoid, encapsulated echogenic mass without clearly definable linear fine striations
- **Groin Hernia**
  - Indirect inguinal hernia is 5x more common than direct inguinal hernia
    - Direct inguinal hernia & femoral hernia have similar prevalence
  - Indirect hernia passes through deep inguinal ring, along inguinal canal, & out of superficial inguinal ring
    - Neck located lateral to inferior epigastric vessels & above inguinal ligament
  - Direct hernia passes through transversalis fascia at Hesselbach triangle
    - Neck located medial to inferior epigastric vessels & above inguinal ligament, usually wide
    - Generally smaller than indirect inguinal hernias
  - Femoral hernia passes through femoral canal
    - Neck located medial to femoral vein & below inguinal ligament, usually narrow
    - More common in women
  - US can accurately identify presence, type, & content of groin hernia
    - Content includes peritoneal fat, fluid, & bowel
- **Incisional Hernia**
  - Can occur after any abdominal operation
    - Presents months to years after surgery
- **Linea Alba Hernia**
  - Usually occurs in young to middle-aged patients
  - Typically midway between xiphisternum & umbilicus
  - Protrusion of extraperitoneal fat through small defect in linea alba
    - Occurs where vessels perforate fascia
  - Hernia through linea alba containing either hypoechoic or echogenic fat in epigastric region
    - Can be very small
    - Often no change with Valsalva, as neck of linea alba hernia is tight
  - Fatty contents can strangulate & infarct

Helpful Clues for Less Common Diagnoses

- **Spigelian Hernia**
  - Defect in transversus abdominis aponeurosis at lateral border of rectus abdominis muscle
    - Between rectus abdominis medially & linea semilunaris laterally
  - Most commonly located in lower abdomen ~ 1/3 of way between umbilicus & pubic crest
  - Usually extends deep to external oblique aponeurosis/muscle & only rarely extends to subcutaneous layer
  - Prone to strangulation, as neck is narrow
- **Paraumbilical Hernia**
  - In adults
  - Protrudes through side of umbilical ring
  - Extraperitoneal fat ± peritoneal contents
- **Umbilical Hernia**
  - In young children
  - 1/3 of umbilical hernias close within 1 month of birth
  - Rarely persists beyond 3-4 years
  - Peritoneal content protrudes through patent umbilical ring
- **Lumbar Hernia**
  - Through defect in posterolateral abdominal wall
  - Spontaneous, postsurgical, or posttraumatic
  - Herniation of retroperitoneal fat ± colon or small bowel
- **Enlarged Lymph Node**
  - Features of reactive or malignant node in groin region

- **Endometriosis**
  - Palpable mass often near caesarean section scar or pelvic surgical scar
  - Pain ± cyclical pain occurring with menses
  - Solid, mainly hypoechoic, heterogeneous nodule
  - Infiltrating margins
  - Anechoic cystic areas infrequent
  - Peripheral hyperechoic ring
  - Mild internal vascularity
- **Undescended Testis**
  - US will locate undescended testis in nearly 90% of patients with cryptorchidism
    - 90% of undescended testes located in inguinal canal
    - Remainder located in abdomen & pelvis
- **Rectus Sheath Hematoma**
  - Due to spontaneous bleeding within rectus sheath from coagulopathy or from injury to superior or inferior epigastric arteries or direct tear of rectus muscle
  - Inferior epigastric artery arises from external iliac artery
    - Ascends between rectus abdominis muscle & posterior rectus sheath
    - Prone to injury during strong muscle contractions
      - Can occur during bouts of coughing
  - Superior epigastric artery originates from internal thoracic artery
    - Descends between rectus abdominis muscle & posterior rectus sheath
- **Subcutaneous Hematoma**
  - Posttraumatic (typical) or spontaneous (uncommon) due to bleeding of subcutaneous vessel
- **Divarication of Rectus Abdominis Muscle**
  - Results from widened linea alba
  - US to exclude presence of true ventral hernia
- **Fat Necrosis**
  - Localized, increased echogenicity of subcutaneous fat
  - Irregular, poorly defined margins without discrete mass
  - ± localized swelling ± lobulation of subcutaneous fat due to edema
  - Injured fat area becomes better defined & more hypoechoic with increasing chronicity
  - ± fluid accumulation within injured fat area
  - ± calcification of injured fat
- **Desmoid Tumor**
  - Benign fibrous tumor (a.k.a. fibromatosis) with predilection for anterior abdominal wall, especially in postpartum women
    - Hypoechoic tumor often with irregular margin
    - Minimal or no internal vascularity
- **Muscle Tear**
  - Affects oblique muscles in lower abdominal quadrants or rectus abdominis muscle
    - Well-localized mechanical pain
    - Affects athletes & patients with chronic cough
- **Abscess**
  - Depending on maturity & content, echogenicity of fluid may vary from hypoechoic to isoechoic to hyperechoic
    - May mimic solid mass if thick fluid/debris is present
  - Posterior enhancement
  - Echo movement on real-time imaging
  - Wall thickness is proportional to chronicity of abscess
  - ± gas locules ± septations ± peripheral hyperemia
- **Granuloma**
  - May arise from retained suture, injection, or chronic infection
  - Hypoechoic mass ± suture material ± mild to moderate vascularity depending on stage
- **Umbilical-Urachal Sinus**
  - Urachus = ductal remnant from involuted embryologic allantois that extends between urinary bladder dome & umbilicus
    - Failure to involute fully → fusiform fluid-filled structure below umbilicus ("urachal cyst")
      - Sinus tract located between transversalis fascia & peritoneum
    - Usually presents in early childhood as umbilical discharge ± mass ± pain
- **Umbilical Metastasis**
  - Typically spreads from gastrointestinal or genitourinary primary via lymphatic, vascular, or embryologic remnant route

Subcutaneous Lipoma

Subcutaneous Lipoma

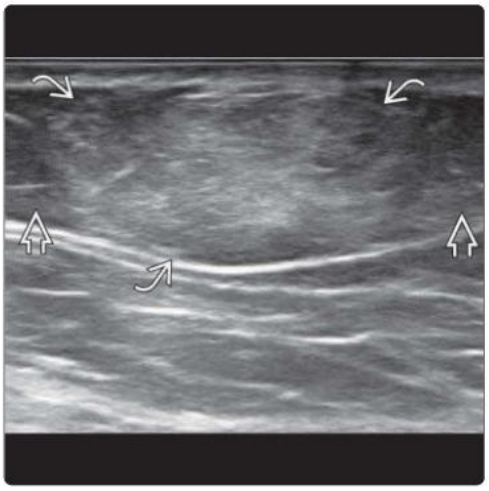

(Left) *Transverse US shows a subcutaneous lipoma ⇨ in the lateral abdominal wall. The external oblique, internal oblique, and transversus abdominis muscles ⇨ are not involved.* **(Right)** *Transverse US of the anterolateral abdominal wall shows an echogenic subcutaneous lipoma ⇨. This lipoma is distinctly echogenic relative to the adjacent hypoechoic subcutaneous fat ⇨.*

(Left) *Transverse US of the right groin shows an indirect inguinal hernia. The hernial neck lies above the inguinal ligament and lateral to the inferior epigastric vessels. The hernial sac contains peritoneal fluid but no bowel.* **(Right)** *Transverse US of the upper abdomen in a patient with previous history of distal pancreatectomy shows an incisional hernia at the lateral aspect of the surgical scar. There is herniation of peritoneal fat through an incisional fascial defect into the hernial sac.*

Groin Hernia

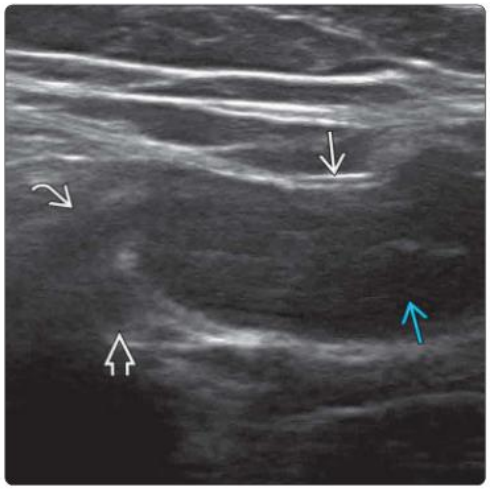

Incisional Hernia

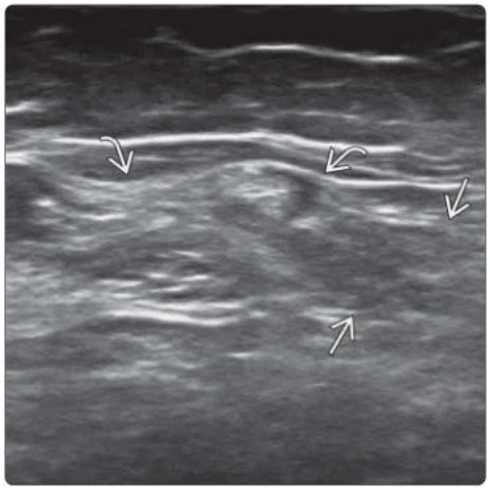

(Left) *Transverse US of the epigastric region shows a small linea alba defect with herniation of extraperitoneal fat. This is called a fatty hernia of linea alba or an epigastric hernia.* **(Right)** *Transverse US of the left lower abdomen shows a spigelian hernia with fat herniation through a fascial defect in the transversus abdominis aponeurosis. The lateral edge of the left rectus abdominis muscle is shown.*

Linea Alba Hernia

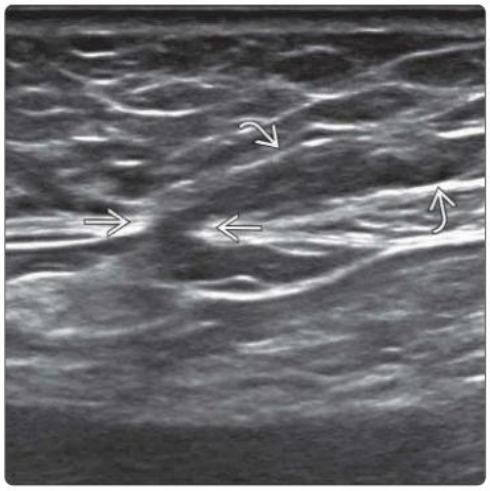

Spigelian Hernia

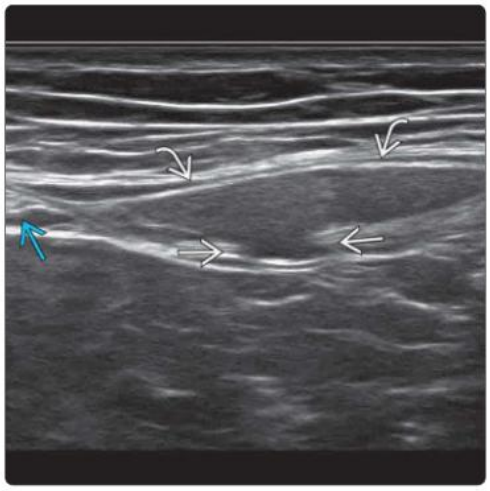

(Left) *Transverse US of the umbilical region shows a paraumbilical hernia with extraperitoneal fat herniation. The location of the umbilicus is shown.* **(Right)** *Transverse US shows bowel protruding through the umbilicus in this newborn with an umbilical hernia. The neck of this type of hernia is wide, allowing the hernia to be easily reduced and not prone to strangulation.*

Paraumbilical Hernia

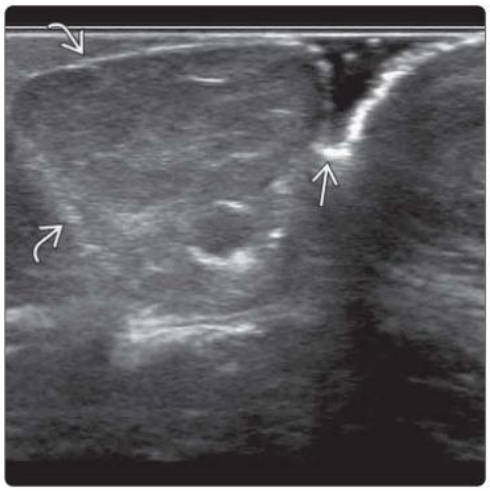

Umbilical Hernia

Lumbar Hernia

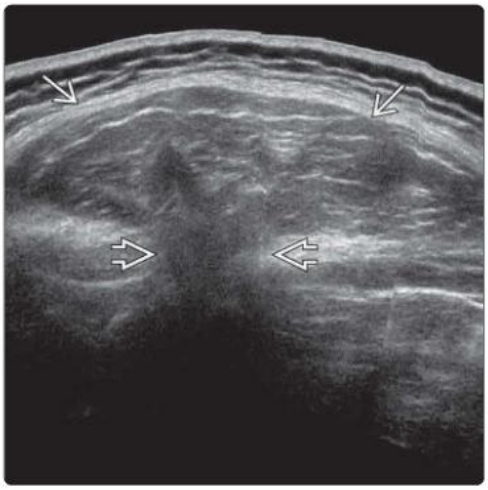

Lumbar Hernia

(Left) *Oblique US shows a lumbar hernia with a wide defect* ➡ *in the fascia of the posterior abdominal wall and herniation of retroperitoneal fat* ➡ *through this defect.* **(Right)** *Axial NECT in the same patient shows the large fascial defect* ➡ *posterior to the left kidney. The hernia sac* ➡ *contains retroperitoneal fat. The defect is bounded by the erector spinae muscle medially* ➡ *and the retracted quadratus lumborum muscle laterally* ➡.

Enlarged Lymph Node

Enlarged Lymph Node

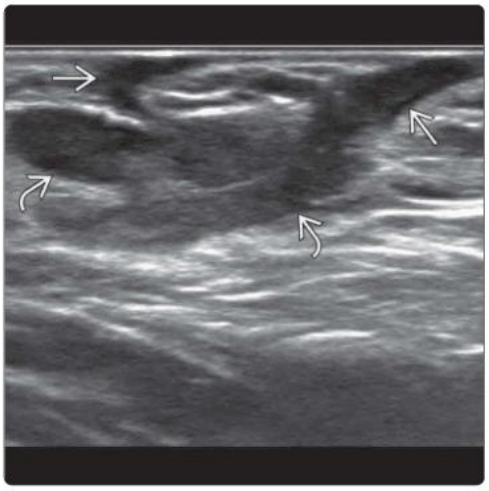

(Left) *Transverse US of the groin in a patient with rectal carcinoma shows an enlarged hypoechoic metastatic node* ➡. *There is severe eccentric cortical thickening with effacement of the hilar fat* ➡. *US-guided biopsy was performed, confirming metastatic carcinoma.* **(Right)** *Transverse US of the groin in a young boy shows matted enlarged lymphadenopathy* ➡. *There was a nodal abscess, which has partially resolved. Two persistent discharging sinuses* ➡ *are present. This pustular discharge grew Mycobacterium tuberculosis.*

Endometriosis

Undescended Testis

(Left) *Transverse US in a middle-aged woman shows an irregular hypoechoic mass* ➡ *involving the subcutaneous tissue* ➡ *and superficial abdominal wall muscle* ➡ *at the site of a lower abdominal surgical scar. The appearances favor endometriosis, which was confirmed by percutaneous biopsy.* **(Right)** *Transverse US shows an oval-shaped, hypoechoic testis* ➡ *within the inguinal canal in a patient with cryptorchidism. Most undescended testes are located in the inguinal canal.*

Rectus Sheath/Subcutaneous Hematoma

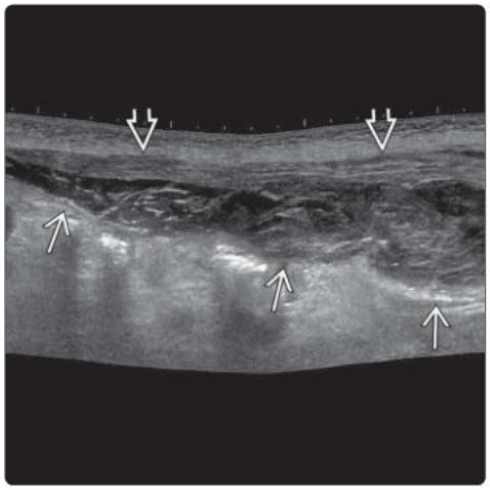

Rectus Sheath/Subcutaneous Hematoma

(Left) *Longitudinal extended field-of-view US of the anterior abdominal wall in a patient on anticoagulation shows a large, extensive hematoma ➡ along the rectus sheath. The hematoma lies posterior to the rectus abdominis muscle ➡ and extends from the subhepatic region down to the pelvis.* **(Right)** *Axial CECT in the same patient shows the corresponding acute hyperdense hematoma ➡ within the left rectus sheath.*

Divarication of Rectus Abdominis Muscle

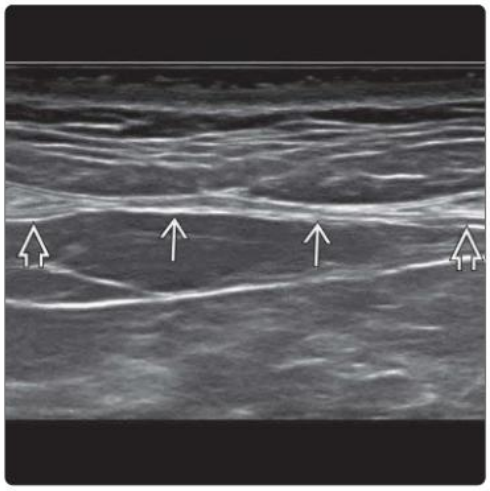

Divarication of Rectus Abdominis Muscle

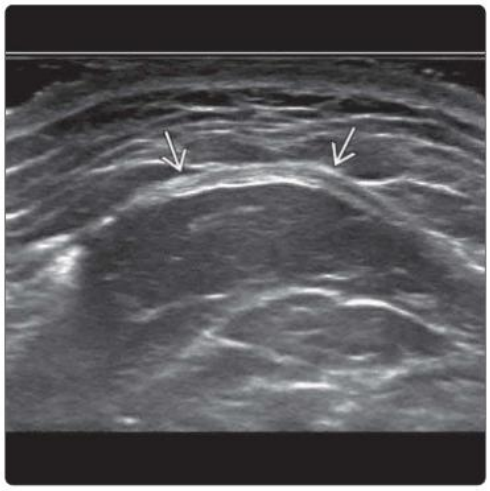

(Left) *Transverse US of the midline of the abdomen at rest shows a widened linea alba ➡ with an interrecti distance of 30 mm. The linea alba is intact. The medial edges of the rectus abdominis muscles ➡ are shown.* **(Right)** *Transverse US of the same site during Valsalva maneuver shows the linea alba ➡ bulging superficially due to divarication of the rectus abdominis muscles. The linea alba remains intact with no actual hernia being present. This condition is also called diastasis recti.*

Fat Necrosis

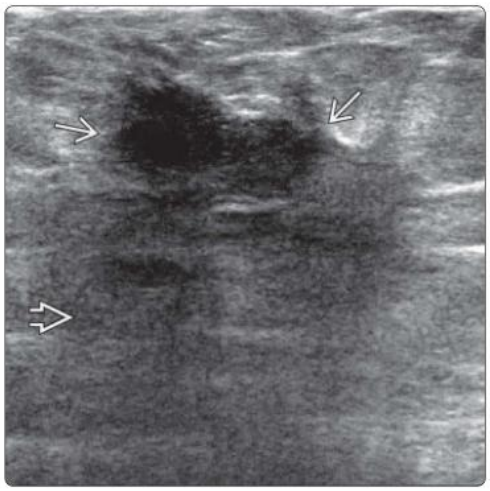

Desmoid Tumor

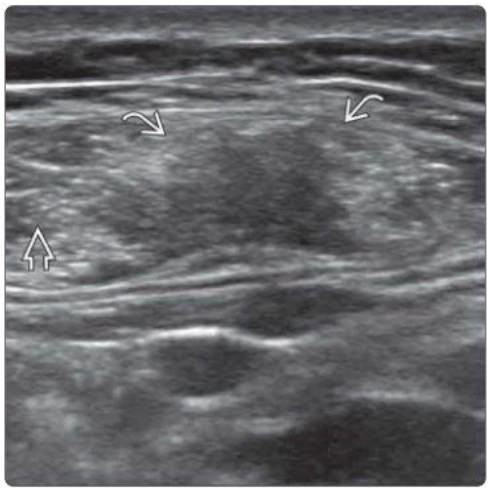

(Left) *Transverse US shows an ill-defined, hypoechoic subcutaneous mass ➡ in the lateral abdominal wall. Mild liquefaction is present. There is posterior acoustic shadowing ➡. Biopsy of the mass confirmed fat necrosis. As is commonly the case, there was no recall of any abdominal trauma.* **(Right)** *Transverse US shows an irregular hypoechoic lesion ➡ within the rectus abdominis muscle ➡. No internal vascularity is detected on color Doppler imaging (not shown). Percutaneous biopsy confirmed fibromatosis.*

Muscle Tear

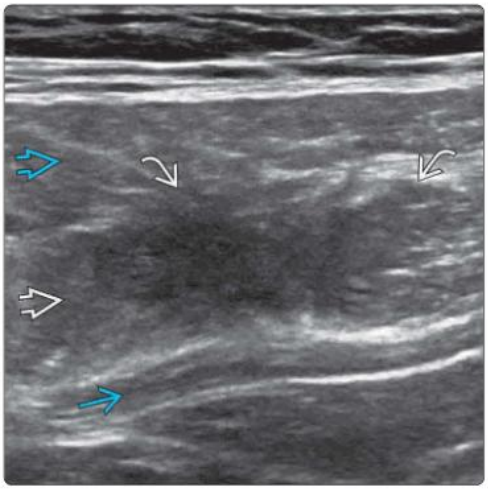

Abscess

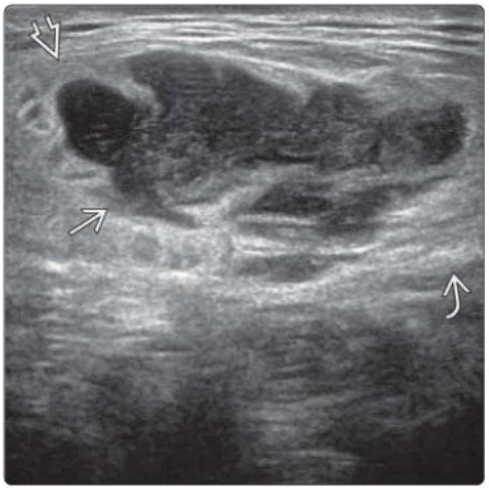

(Left) *Transverse US shows a subacute tear of the internal oblique muscle. The edges of the tear are irregular and less hypoechoic due to presence of granulation tissue. The external oblique and transversus abdominis muscles are intact and unremarkable.* **(Right)** *Transverse US shows a recurrent chronic abscess in the lateral abdominal wall. The abscess wall is thickened with moderate surrounding subcutaneous edema. US-guided aspiration yielded gram-negative bacilli.*

Granuloma

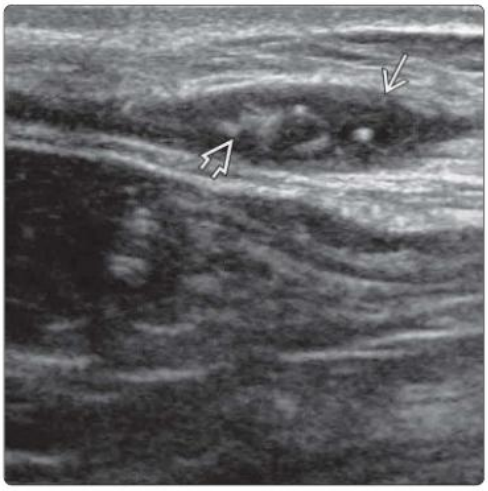

Umbilical-Urachal Sinus

(Left) *Longitudinal US shows a small stitch granuloma in the deep subcutaneous tissue of the anterior abdominal wall. There is curvilinear hyperechoic suture material within the hypoechoic granuloma.* **(Right)** *Longitudinal oblique US in a 2-year-old boy with umbilical discharge shows a fibrotic-type umbilical nodule contiguous with a deeper tract extending toward the pelvis, consistent with umbilical-urachal sinus. Moderate perilesional hyperemia was present (not shown).*

Umbilical Metastasis

Umbilical Metastasis

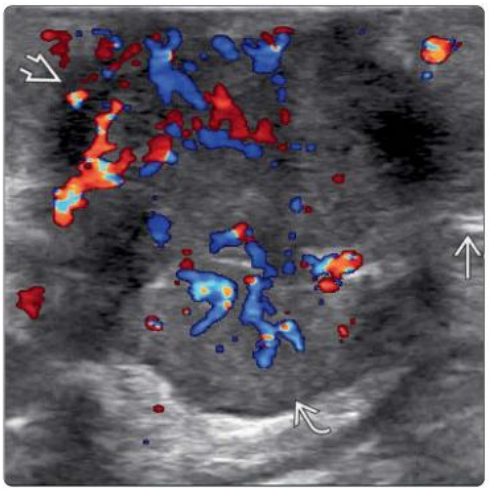

(Left) *Clinical photograph shows a recently apparent umbilical nodule of a 70-year-old woman with an ovarian pelvic mass.* **(Right)** *Transverse color Doppler US (same umbilical nodule) shows a large hypoechoic mass straddling the linea alba. Moderate hyperemia is present. US-guided biopsy revealed metastatic tumor of gynecological origin. Umbilical metastasis is a.k.a. Sister Mary Joseph nodule. Discrete noncontiguous lower margin excludes hernia.*

PART V
SECTION 1

Biopsy

Soft Tissue Biopsy	942
Bone Biopsy	950
Synovial Biopsy	960

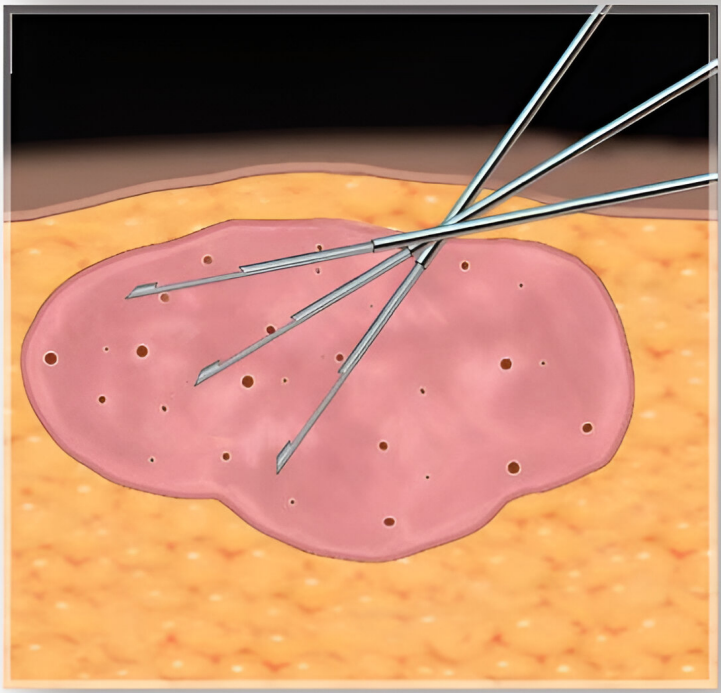

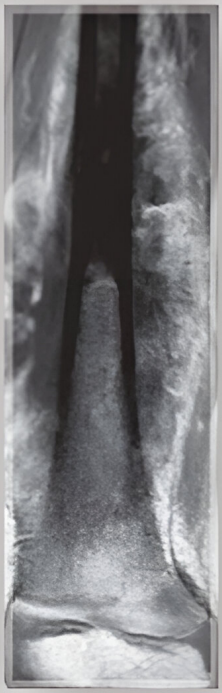

KEY FACTS

TERMINOLOGY

- Percutaneous core needle biopsy of soft tissue lesion under US guidance
  - Accurate, safer, & more cost-effective alternative to open biopsy for tissue diagnosis

PREPROCEDURE

- Review previous imaging
  - To determine location & make diagnosis of soft tissue mass
    - Biopsy not required when confident specific diagnosis can be made by imaging alone
- High-frequency (7- to 12-MHz) linear array transducer
- Coaxial system preferred
  - 15-g coaxial needle with 16-g side-cutting biopsy needle

PROCEDURE

- US area of interest to best assess route & select viable areas of lesion before biopsy
  - Target solid area, preferably with evidence of vascularity on color Doppler US
  - Avoid cystic or necrotic areas
  - Obtain at least 1 biopsy deep to capsular edge of tumor
- Avoid important intervening structures, such as uninvolved compartment, neurovascular bundle, tendon, bowel, spermatic cord, especially in case of pelvic biopsy
- Keep needle path within area of planned surgical resection

POST PROCEDURE

- Adverse effects very uncommon

OUTCOMES

- High diagnostic yield procedure
- Uncommonly, tissue obtained may not be representative of entire tumor
- Theoretical risk of tumor seeding along biopsy pathway
  - Risk much smaller than with open biopsy

Planning of Biopsy Trajectory

Setup for Soft Tissue Biopsy

(Left) *Transverse US of a patient with an anterior thigh mass shows a heterogeneous tumor in the vastus intermedius muscle abutting the femoral shaft. For a heterogeneous tumor, multiple biopsies at different sites of the mass should be taken to obtain adequate representative tissue.* **(Right)** *Clinical photograph of a setup for biopsy of soft tissue lesions shows the Temno core biopsy needle, coaxial needle, syringe for local anesthetic, scalpel for skin incision, disinfectant, and specimen bottle.*

Biopsy of Soft Tissue Tumor

Multiple Biopsies via Coaxial Tract

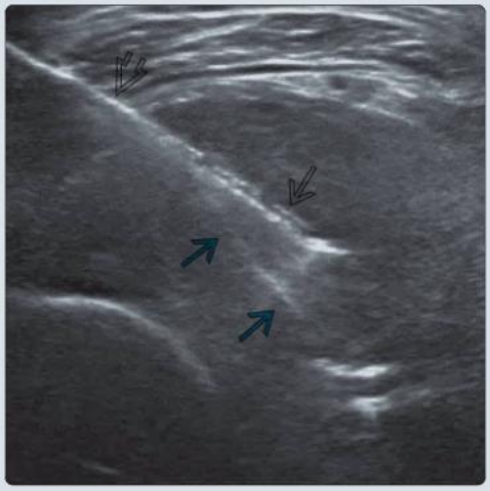

(Left) *Transverse US of the same patient shows placement of a 16-g Temno core biopsy needle via a 15-g coaxial needle into the soft tissue mass in the vastus intermedius muscle.* **(Right)** *Transverse US during the same procedure shows placement of the Temno core biopsy needle via the coaxial needle into a more superficial aspect of the tumor. The gas-filled tract from the previous biopsy is shown. 3-4 nonfriable tissue cores are usually adequate. Histology revealed extraskeletal osteogenic sarcoma.*

TERMINOLOGY

Abbreviations

- Core needle biopsy (CNB) (> 20-g needle)
- Fine-needle aspiration (FNA) (≤ 20-g needles)

Definitions

- Percutaneous CNB of soft tissue lesion under US guidance

PREPROCEDURE

Indications

- Establish specific histologic diagnosis of soft tissue mass with indeterminate imaging findings
- Confirmation & subtyping of suspected soft tissue sarcoma
- Confirm or exclude musculoskeletal metastases in patient with known primary tumor
- Confirm or exclude tumor recurrence in patient with prior tumor resection
- Provide tissue for histologic & microbiologic analysis in patient with suspected soft tissue infection
- Provide tissue for histologic analysis in patient with suspected inflammatory myositis or fasciitis

Contraindications

- Uncooperative patient
- Site inaccessible to US access
- Uncorrected bleeding diathesis, especially in site inaccessible to postbiopsy compression
  - Most highly vascularized tumors can be safely biopsied, provided they are located in areas where adequate percutaneous compression can be applied post biopsy
  - Tract embolization via coaxial needle can aid hemostasis

Getting Started

- Things to check
  - Patient identity, type of procedure, side of procedure, informed consent
  - Optimize clotting profile before procedure, especially for deep-seated lesions
    - Adherence to this guideline depends on perceived difficulty in applying adequate percutaneous compression post biopsy
  - Review prior imaging
    - Accurate specific imaging diagnosis may be made in large number of soft tissue masses, e.g., epidermoid cyst & ganglion & peripheral nerve sheath tumor
      - Biopsy unnecessary if imaging diagnosis is certain
      - Biopsy can be time-consuming, potentially hazardous, painful (e.g., if nerve sheath tumor is biopsied), & add to treatment cost
    - Plan suitable needle path & decide on area to be sampled, particularly targeting viable tumor area & avoiding neurovascular bundle
- Medications
  - Local anesthetic (2-5 mL of 2% lignocaine) to skin
  - Sedation of anxious patient or young children
    - Intravenous midazolam or other benzodiazepine; antidote & resuscitation facilities should be available
- Equipment list
  - High-frequency (7- to 12-MHz) linear-array transducers
  - Sterile biopsy set
  - Biopsy needle type: Spring-loaded, side-cutting needles are most commonly used
    - Side-cutting needles (e.g., Temno) employ inner troughed needle, which is advanced into lesion with outer cylindrical cuff isolating core of tissue
    - End-cutting needles (e.g., Franseen) obtain tissue by isolating core within end of advancing needle cylinder
  - Biopsy needle size
    - Large-bore (14- to 18-g) biopsy needle
      - Larger biopsy needle provides more tissue for histology, ensuring sufficient tissue is available for immunohistochemical staining & molecular studies
      - As risk of bleeding from easily compressible lesions is low, there is no advantage to using smaller needles for most musculoskeletal biopsies
  - Coaxial biopsy technique
    - Larger bore, cannulated needle placed into soft tissue lesion under US guidance
      - Biopsy needle inserted through this outer coaxial needle into mass
    - Coaxial needle 1 g larger than core biopsy needle (e.g., 15-g coaxial needle, 16-g Temno biopsy needle)
    - Ability to obtain multiple cores using only 1 initial puncture
    - Better needle stability & time efficiency when multiple biopsies are taken
    - Reduces trauma to tissues along needle track, reduces likelihood of postbiopsy bleeding, & theoretically reduces risk of tumor seeding along biopsy tract
  - Specimen bottles
    - With formalin fixation in sterile bottle or as fresh specimen

PROCEDURE

Patient Position/Location

- Variable, depending on lesion position
  - Always rest patient on bed during procedure, as some patients may experience vasovagal attack

Procedure Steps

- Carefully scan region of interest to select best possible needle path for biopsy
- Must ensure that, whenever possible, compartmental integrity of tumor is maintained
  - Tissue planes can act as natural barriers to spread of tumor or infection
  - However, some tissue planes have to be disrupted during biopsy, e.g., need to go through subcutaneous compartment to reach subfascial compartment
  - If tumor located in one muscle compartment, avoid transgressing another muscle compartment to reach tumor, whenever possible
- Helpful if orthopedic surgeon can mark planned surgery site on skin
  - Perform biopsy at this site whenever possible
  - Allows biopsy tract to be excised en bloc with tumor during surgery
  - Theoretical risk of seeding of tumor along needle tract
    - With good technique, this risk is very low (much lower than with open biopsy)
- Plan needle path to avoid important intervening structures

  - Any neurovascular bundle or tendon as well as peritoneal cavity (in case of pelvic mass biopsy)
  - Examine adjacent tissue to locate at-risk neurovascular bundles that may not be visible in plane of biopsy
    - Need good knowledge of neural anatomy to avoid smaller less conspicuous nerves
- Select areas representative of viable tumor for tissue sampling
  - Identify solid viable areas using grayscale & color Doppler imaging
    - Tumor margins tend to provide more fruitful material than central area of tumor, which may be necrotic
    - If tumor is hypovascular, be certain to sample tumor margin
  - Avoid cystic or necrotic areas, as yield will be nondiagnostic
  - Hypervascular areas should be targeted, rather than avoided, since these most likely contain most metabolically active viable tumor tissue
    - Risk of bleeding is very low with single puncture & adequate tamponade
- Sterilize skin over planned area of puncture
- Place probe within sterile probe cover
- Inject local anesthetic
- Small stab incision in skin
- Determine biopsy needle set to be used: side cutting (preferred) vs. end cutting (for small lesions)
  - Trajectory of needle should be maintained within lesion to avoid breaching of tumor capsule other than at needle entry site
- **Side-cutting core biopsy needle (e.g., Temno)**
  - Insert coaxial needle so that tip just pierces tumor capsule
  - Remove inner stylet of coaxial needle & replace with biopsy needle
  - Sample suitable areas; change direction of coaxial needle to angle biopsy needle to different suitable areas
  - In general, 3-4 biopsies are adequate
    - Obtain at least 1 core deep to capsular edge of tumor
  - In friable tumors, ≥ 10 biopsies may be required
  - Single intact biopsy core is far better than multiple fragmented cores for pathologic diagnosis
    - Length of specimen more important than width
- **End-cutting core biopsy needle (e.g., Franseen)**
  - Insert needle into tumor, & remove inner stylet
  - Connect needle to extension tube, & empty 10-mL syringe
  - Move needle to and fro within lesion
    - Simultaneous rotational movement to optimize cutting action
  - ± apply gentle suction (2-3 mL)
    - Excessive suction would result in predominant blood aspirate, jeopardizing sample quality
  - Stop needle suction upon removing needle from lesion
- Unload tissue cores into specimen bottle
  - Adequate fixation is essential to preserve optimal histologic features for proper pathologic examination
  - Minimal tissue handling
    - Tissue autolysis, crushing, & drying & handling artifacts may hinder morphologic interpretation & limit certain immunohistochemical stains
- Rinse biopsy needle tip in normal saline before reinserting into coaxial needle or patient
- Once sufficient biopsies have been obtained, remove coaxial needle, & apply local pressure for hemostasis
- If active bleeding from coaxial needle before needle removal, temporary embolic agents (e.g., gelatin foam) can be injected via coaxial needle to seal tract & aid hemostasis
  - Embolic agents should be available in procedure room
- Completed within 30 minutes as outpatient procedure

Alternative Procedures/Therapies

- Surgical
  - Open biopsy (incisional or excisional)
- FNA not recommended
  - Aspirate suited for cytology, not histology
  - Lack of tissue architecture in cellular aspirate precludes accurate histological analysis, especially for sarcoma & lymphoma typing

POST PROCEDURE

Expected Outcome

- Uneventful in most circumstances
- Minimal wound discomfort
- Minimal bleeding curtailed by brief period (15 minutes) of local pressure for hemostasis

Immediate Aftercare

- Apply simple dressing
  - Dressing can be removed by patient following day
- Monitor for 1 hour in department for signs of bleeding (swelling, oozing, bruising)

Subsequent Aftercare

- Avoid immediate strenuous exercise involving biopsied area
- Avoid water contact of biopsy site for 24 hours

OUTCOMES

Problems

- Nonrepresentative tissue samples in case of large tumor
  - Obtain samples from different parts of tumor
- Biopsy may not provide sufficient tissue for cytogenic analysis required to establish treatment protocol
  - Obtain at least 1 sample deep to tumor capsule

Complications

- Most feared complication(s)
  - Neurovascular bundle injury, peritoneal or thoracic cavity penetration
  - Excessive bleeding
- Delayed complication(s)
  - Infection & bleeding
- Risk of seeding of tumor along needle tract
  - Risk negligible with coaxial system

SELECTED REFERENCES

1. Strnad BS et al: Percutaneous core biopsy devices: a detailed review and comparison of different needle designs. Ultrasound Q. 40(1):1-19, 2024
2. Zhang YL et al: Contrast-enhanced ultrasound guided core needle biopsy for soft tissue tumors: accuracy and applicability. Eur J Radiol. 168:111114, 2023

Side-Cutting Core Biopsy Needle

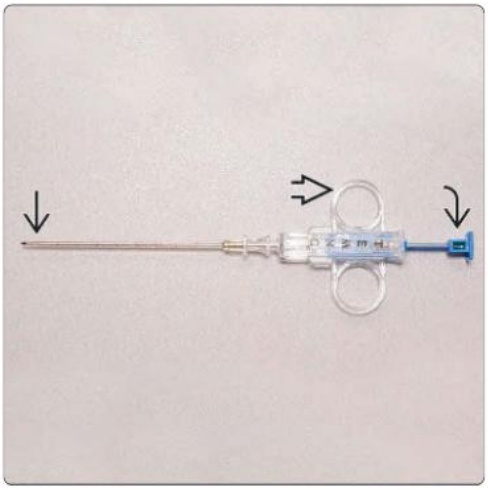

Side-Cutting Core Biopsy Needle



(Left) *Clinical photograph of a Temno core biopsy needle shows a plunger for controlling the spring-activated mechanism, the handle, and the cutting cannula. The needle is in a loaded status.* **(Right)** *Clinical photograph shows an open Temno core biopsy needle. Note the specimen slot and the sharp, beveled needle tip. Pushing the plunger fires the outer cannula over the specimen slot, isolating a tissue sample.*

Coaxial Needle



Coaxial Biopsy Technique

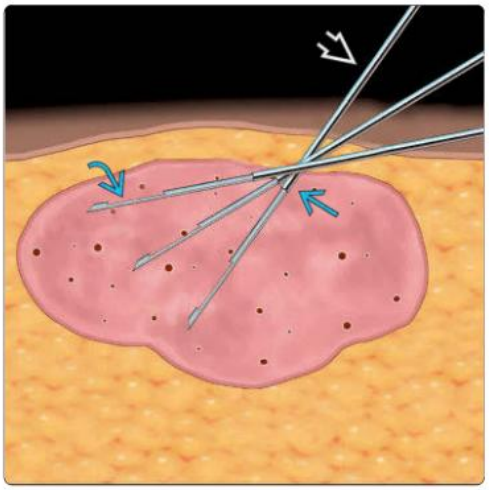

(Left) *Clinical photograph shows a coaxial needle. The outer cannula has a blunted end, and the inner stylet has a sharp beveled tip. The stylet is placed inside the outer cannula during needle insertion.* **(Right)** *Graphic shows the coaxial biopsy technique during soft tissue biopsy. The coaxial needle is inserted with its tip just piercing the lesion, maximizing the ability to angle the biopsy needle to different parts of the lesion. A least 1 biopsy should be obtained from the subcapsular area.*

Planning of Biopsy Trajectory

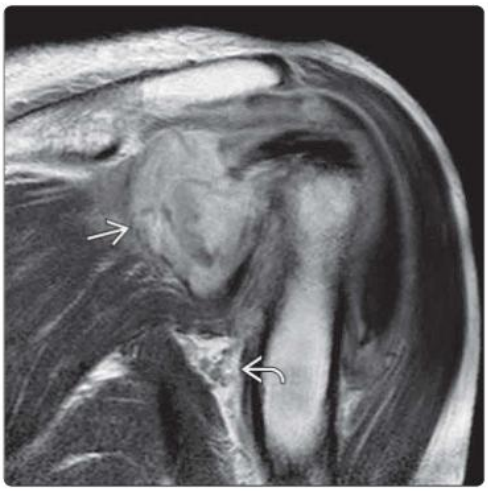

Planning of Biopsy Trajectory

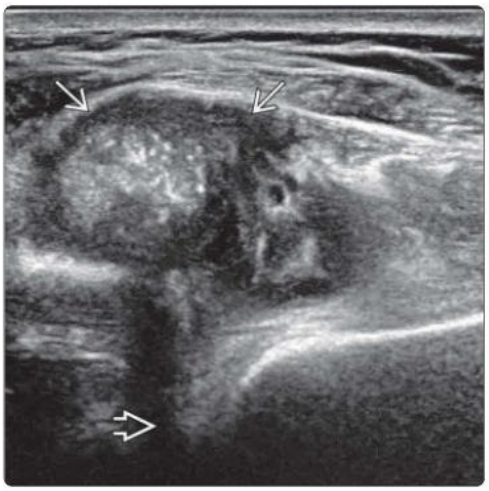

(Left) *Coronal oblique T1 C+ MR shows an enhancing soft tissue lesion within the glenohumeral joint. The enhancing solid component should be targeted, avoiding the neurovascular bundle, which is inferior to the lesion.* **(Right)** *Transverse US of the same lesion shows a heterogeneous soft tissue mass arising from the glenohumeral joint. The biopsy pathway is planned to avoid the axillary neurovascular bundle.*

(Left) *Clinical photograph shows the same patient after skin sterilization and application of sterile drapes. Local anesthetic (3 mL of 1% lignocaine) is infiltrated via a 23-g needle ➡ to the skin and subcutaneous tissue.* **(Right)** *Transverse US of the same patient shows the 23-g needle ➡ for injection of local anesthetic reaching the outer margin of the soft tissue lesion ➡. The pseudocapsule around the lesion can be anesthetized, but the anesthetic needle should not enter the lesion.*

Injection of Local Anesthetic

Injection of Local Anesthetic

(Left) *Clinical photograph shows the same patient after local anesthetic infiltration. A small skin incision is made at the site ➡ of the local anesthetic injection.* **(Right)** *Clinical photograph shows the same patient with a 10-cm, 15-g coaxial needle ➡ introduced under US guidance via the small skin incision ➡ to the soft tissue lesion.*

Skin Incision for Biopsy

Insertion of Coaxial Needle

(Left) *Transverse US of the same patient shows the echogenic tip ➡ of the coaxial needle just piercing the edge of the lesion. The tip of the coaxial system should be left in the outer margin of the lesion to optimize subsequent maneuverability.* **(Right)** *Clinical photograph shows the same patient after removal of the inner stylet of the coaxial needle. A 15-cm, 16-g Temno core biopsy needle ➡ is introduced and locked into the outer cannula of the coaxial needle.*

Insertion of Coaxial Needle

Insertion of Core Biopsy Needle

Insertion of Core Biopsy Needle

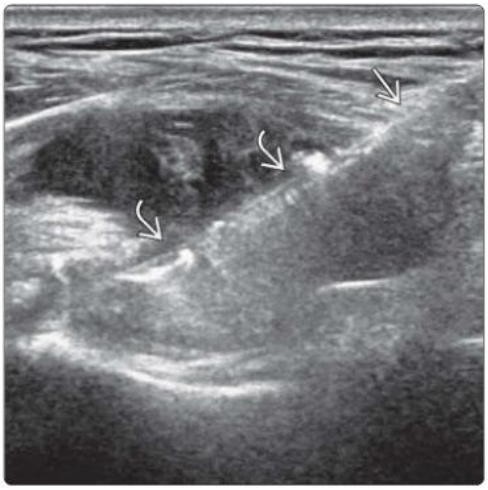

Tissue Core Obtained With Core Biopsy Needle

(Left) *Transverse US of same patient shows advancement of the 20-mm specimen slot ⇄ of the biopsy needle through the coaxial needle ⇄ into the lesion. Biopsy is performed with further pushing of the plunger of the biopsy needle.* **(Right)** *Clinical photograph shows a tissue core ⇄ within the specimen slot of the Temno biopsy needle. The specimen is placed into specimen bottles with a small amount of saline for microscopy and formalin for histology. Histology and microbiology revealed tuberculous infection.*

Planning of Biopsy Trajectory

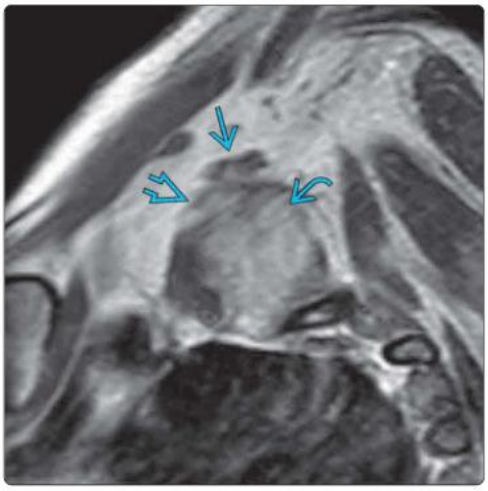

Biopsy Under Real-Time US Guidance

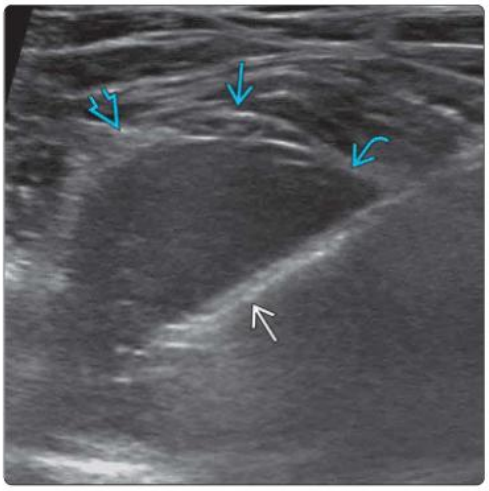

(Left) *Sagittal oblique T1 C+ MR of a patient with a supraclavicular mass shows an enhancing lesion ⇄ among the brachial plexus, probably arising from the C8 nerve root or inferior trunk. The superior (dividing) ⇄ and effaced middle ⇄ trunks are shown.* **(Right)** *Transverse US shows a biopsy of the same lesion ⇄. Needle ⇄ advancement under real-time US guidance allows precise placement to avoid adjacent important structures. The brachial plexus superior ⇄ and middle ⇄ trunks are shown. Biopsy revealed a schwannoma.*

Planning of Biopsy Trajectory

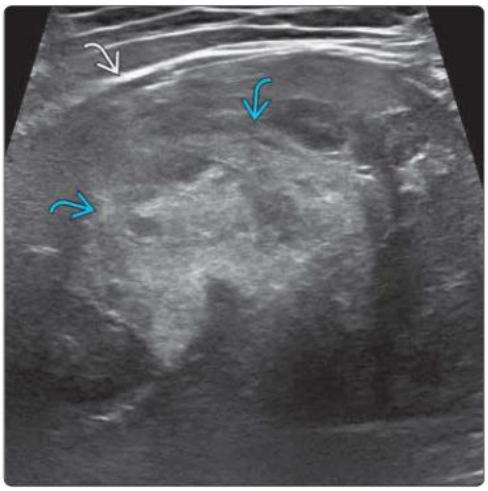

Obtaining Biopsy at Capsular Edge

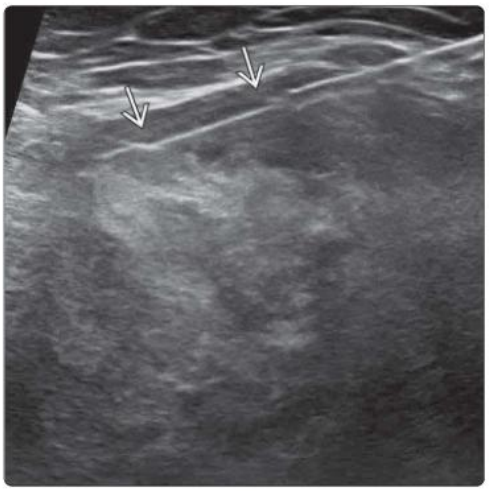

(Left) *Transverse US of a patient with a firm thigh mass shows a heterogeneous mass ⇄ in the vastus medialis muscle. The central echogenic area ⇄ representing hemorrhagic necrosis should be avoided during biopsy.* **(Right)** *Transverse US during a biopsy of same lesion shows the 20-mm specimen slot ⇄ of a Temno needle placed at the capsular edge of the tumor. At least 1 biopsy should be taken from the capsular edge to increase diagnostic yield. Histology revealed a high-grade soft tissue sarcoma.*

(Left) *Longitudinal US of a patient with a distal leg mass shows a lobulated subcutaneous mass with an apparent eccentric cystic area.* **(Right)** *Longitudinal color Doppler US of same lesion shows that the apparent cystic area was in fact a prominent artery. Prominent feeding arteries should be avoided during biopsy. However, areas of intratumoral hyperemia indicative of tumor viability should be targeted. Assessment with color Doppler US is essential in planning the trajectory of the biopsy needle.*

Planning of Biopsy Trajectory

Planning of Biopsy Trajectory

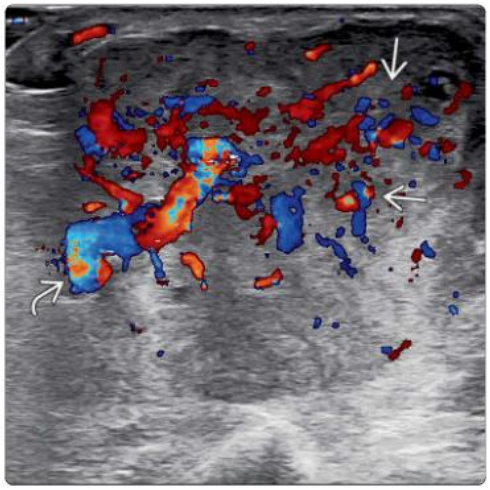

(Left) *Transverse US shows biopsy of the same distal leg lesion with a 16-g Temno biopsy needle via a 15-g coaxial needle, targeting the hyperemic area identified on a prior color Doppler US assessment. Histology revealed an angioleiomyoma.* **(Right)** *Clinical photograph shows a side-cutting core biopsy needle with flexibility of 10- and 20-mm specimen slots for obtaining tissue cores and an end-cutting core biopsy needle (Franseen) with cutting blades at its tip for obtaining tissue cores.*

Obtaining Biopsy From Hyperemia Areas

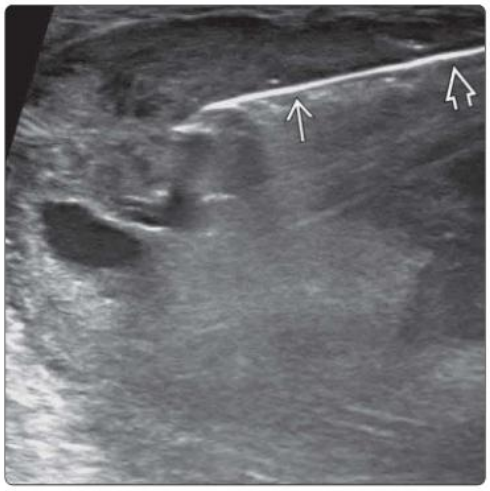

Core Biopsy Needles for Small Lesions

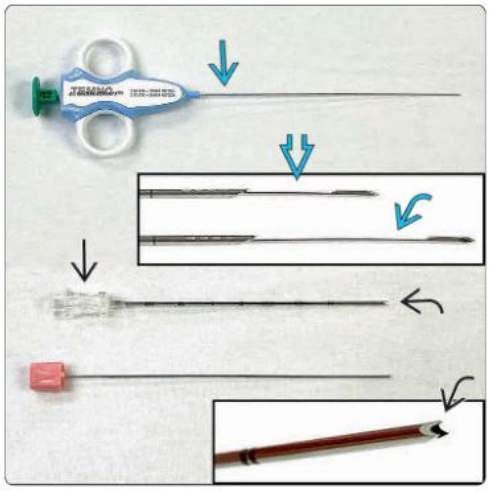

(Left) *Axial T1 MR of a 25-month-old patient with an axillary mass shows a small, irregular T1-hypointense lesion in the axilla. The T1 hypointensity and echogenic appearance on US were suggestive of a fibrous-type lesion.* **(Right)** *Transverse US shows biopsy of the same axillary lesion with an 18-g Temno Evolution needle. This needle has the option of a 10-mm specimen slot, which can be placed entirely within the small lesion. Histology revealed fibrous hamartoma of infancy.*

Core Biopsy of Small Lesion

Core Biopsy of Small Lesion With Side-Cutting Needle

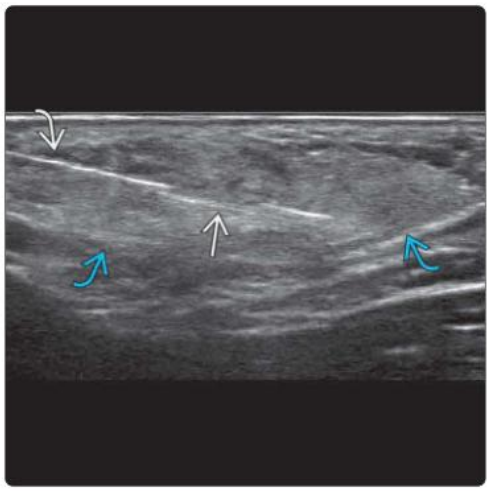

Core Biopsy of Small Lesion With Side-Cutting Needle

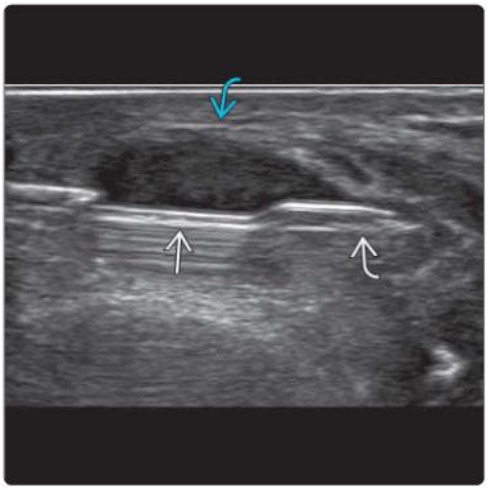

Core Biopsy of Small Lesion With Side-Cutting Needle

(Left) *Transverse US shows a biopsy of a small hypoechoic subcutaneous lesion of the elbow with a 18-g Temno Evolution needle. The 10-mm specimen slot is placed precisely within the lesion.* **(Right)** *Transverse US shows the same needle after the outer cannula has been shot forward, isolating a tissue core. Histology revealed a peripheral nerve sheath tumor. Side-cutting core biopsy needles with a spring-activated mechanism (e.g., Temno, Temno Evolution) are the most commonly used in clinical practice.*

Core Biopsy of Small Lesion With End-Cutting Needle

Core Biopsy of Small Lesion With End-Cutting Needle

(Left) *Color Doppler US of a patient with a small, firm lump on the volar aspect base of the middle finger shows a 9-mm lobulated hypoechoic mass with no internal vascularity superficial to the normal flexor tendons.* **(Right)** *Transverse US shows biopsy of the same lesion with a 18-g Franseen needle. To-and-fro and rotational movement of the needle allows small tissue cores to be obtained by the cutting edges at the crown tip of the needle. Histology revealed a tendon sheath fibroma.*

Core Biopsy of Small Node With End-Cutting Needle

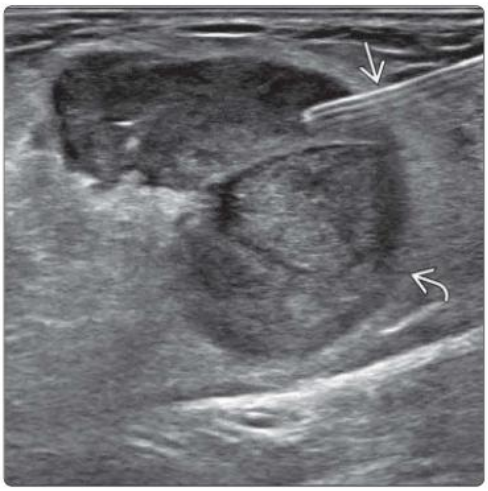

Core Biopsy of Large Node With Side-Cutting Needle

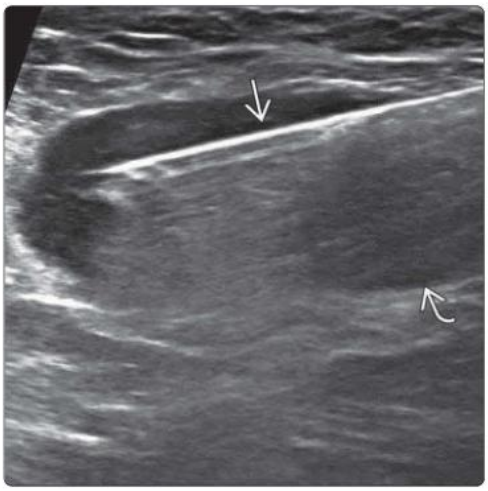

(Left) *Longitudinal US shows a biopsy of a small groin node with cortical thickening in a patient with melanoma using a Franseen needle. Histology revealed metastatic melanoma.* **(Right)** *Longitudinal US shows a biopsy of an enlarged axillary node in a patient with constitutional symptoms using a 16-g Temno needle. Histology revealed follicular lymphoma. Side-cutting needles generally obtain more representative samples than end-cutting needles and are preferred if lesional dimensions allow.*

KEY FACTS

PREPROCEDURE

- 40% of bone tumors that require biopsy are amenable to US-guided percutaneous biopsy
- US-guided needle biopsy of bone tumors has diagnostic accuracy of > 98%

PROCEDURE

- Choose biopsy site bearing in mind site of subsequent surgical excision
  - Can be performed as outpatient procedure
  - If scheduling issues, US-guided core biopsy can be performed prior to MR staging
- Plan approach taking care to avoid neurovascular bundle, other critical structure, or noninvolved compartment
- 3 potential scenarios
  - Bone lesion with extraosseous component: Coaxial needle & core biopsy needle technique are used
  - Lytic lesion with markedly thinned ± disrupted bone cortex: Coaxial needle used to penetrate cortex → biopsy with core biopsy needle via coaxial tract
  - Lytic lesion with thinned cortex not penetrable by standard coaxial needle: Trephine biopsy needle penetrates cortex → insert core biopsy needle along trephine needle
- Color Doppler US helps identify areas of viable tumor
- Obtain some cores from subcapsular margin of tumor
- Usually use 15-cm, 16-g core biopsy needle together with 10-cm, 15-g coaxial needle
- Properly performed percutaneous bone biopsy is safe procedure with few complications
- US fusion-guided biopsy
  - Fuses previously obtained DICOM CT or MR data with real-time US
  - Expands applicability of percutaneous US-guided biopsy to bone lesions not visible on US
  - Diagnostic yield & accuracy of ~ 95%

Bone Tumor With Extraosseous Mass

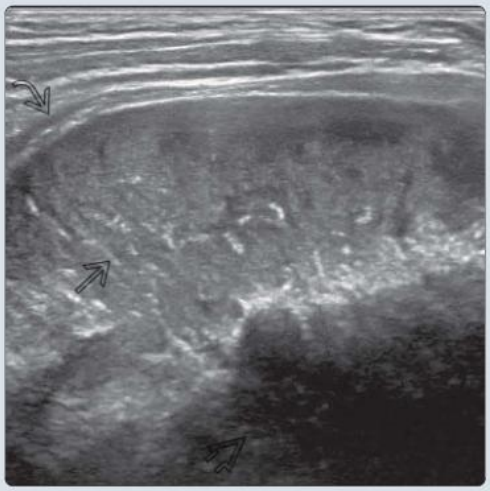

Planning of Biopsy Trajectory

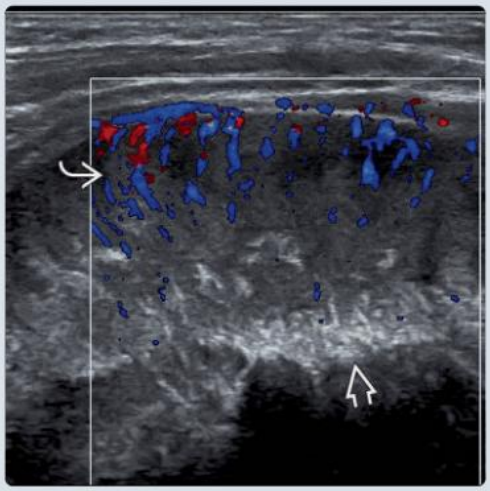

(Left) *Transverse US in 4-year-old boy with a large lytic iliac bone lesion shows a large, extraosseous mass ⇨ extending deep to the iliacus muscle ⇨. There are radiating reams of osteoid tissue ⇨ within the mass. Tumors with extraosseous component can be readily assessed on US.* **(Right)** *Color Doppler US shows marked tumoral hyperemia ⇨, especially toward the tumor periphery. The spiculated tumoral new bone formation ⇨ is clearly seen. Tumoral hyperemia indicates tumor viability and should be targeted for biopsy.*

Setup for Bone Biopsy

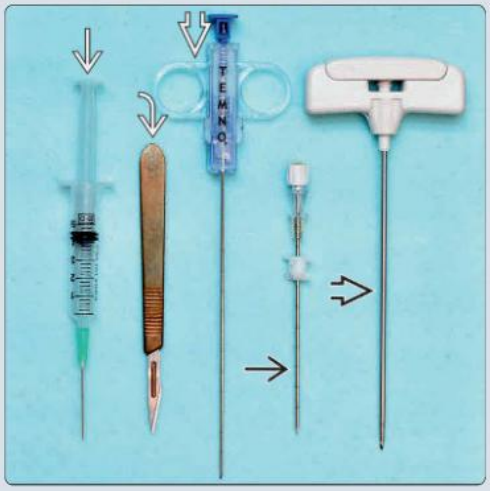

Biopsy of Extraosseous Tumor

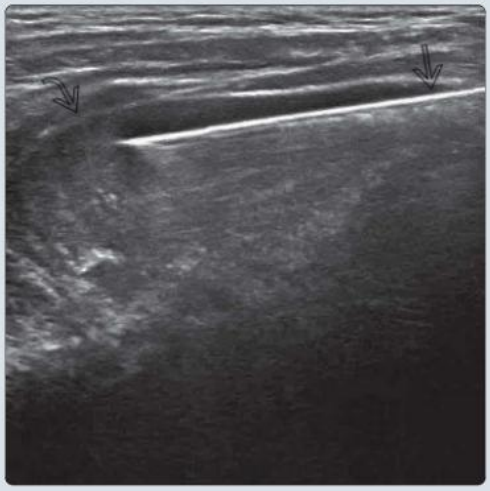

(Left) *Clinical photograph shows setup for US-guided bone biopsy shows local anesthetic ⇨, scalpel ⇨, Temno ⇨, and coaxial ⇨ and trephine ⇨ biopsy needles. Tumor extent and cortical integrity determine type of needle used.* **(Right)** *Longitudinal US shows the biopsy needle path ⇨ in the extraosseous tumor ⇨. At least 3 biopsies should be taken, targeting hypervascular areas. Histology revealed a malignant small round cell tumor, most likely an undifferentiated neuroblastoma.*

TERMINOLOGY

Definitions

- Percutaneous core needle biopsy (CNB) of bone lesions under US guidance using ≥ 20-g needle

PREPROCEDURE

Indications

- Establish histological diagnosis of bone lesion
- 40% of bone tumors requiring biopsy are amenable to US-guided percutaneous biopsy
  - Lesions that are surface based, have extended through cortex, or have intact overlying cortex thin enough for intramedullary lesion to be visible on US are suitable
- US-guided needle biopsy of bone tumors has diagnostic accuracy of > 98%
- Main advantages of US-guided over CT-guided biopsy
  - Continuous real-time visualization of biopsy needle relative to neurovascular structures
  - Areas of viable tissue can be identified & accurately targeted
  - More expeditious & cost effective
  - Does not occupy CT scan time
- Biopsy is best performed in center where definitive management of patient will take place

Contraindications

- Uncooperative patient
- Site of bone lesion inaccessible to US
- Uncorrected bleeding diathesis for tumor in sites inaccessible to postbiopsy compression
  - Tract embolization via coaxial needle can aid hemostasis

Preprocedure Imaging

- Radiography excellent for bone tumor characterization
- CT useful adjunct to radiography
- MR helps identify suitability for US-guided biopsy
  - If scheduling difficulty, US-guided biopsy can be done prior to MR in tumors with large, extraosseous mass
  - Effect of percutaneous biopsy on MR imaging characteristics is minimal
  - Recommendation that MR should always be done before biopsy is carryover from open biopsies in which negative effect on MR imaging was significant

Getting Started

- Things to check
  - Patient identity, type of procedure, side of procedure, informed consent
  - Optimize clotting profile before procedure
    - Optimal level depends on perceived difficulty in applying adequate percutaneous compression post biopsy
    - Bleeding is of greater concern where adequate tamponade is not achievable, e.g., biopsy of inner aspect of iliac bone or deeper areas of spine
  - Review prior imaging to plan suitable needle path & decide on area to be sampled, particularly targeting viable tumor area & avoiding neurovascular bundle
- Medications
  - Local anesthetic (2-5 mL 2% lignocaine) to skin & periosteum
  - Sedation (e.g., intravenous midazolam or other benzodiazepine) for anxious patient or young children
  - Systemic analgesia (e.g., intravenous fentanyl) may be required for some biopsies
    - Tumors at deep-seated location or those associated with pathological fracture tend to be more painful
  - Antidote & resuscitation facilities should be available
- Equipment list
  - High-frequency (7-12 MHz), linear-array transducers
  - Sterile biopsy set
  - Large-bore, spring-loaded, side-cutting needles (14- to 16-g) are most commonly used
  - Coaxial biopsy technique
    - Large-bore cannulated needle, which is placed into tumor under US guidance
    - Coaxial needle 1-g larger than core biopsy needle (e.g., 15-g coaxial needle, 16-g Temno needle)
    - Ability to obtain multiple cores using only 1 initial puncture
  - Trephine needle (8- to 11-g) for lesions with intact bone cortex not penetrable by standard coaxial needle
  - Specimen bottles
    - Specimen can be sent fresh or with formalin fixation in sterile bottle

PROCEDURE

Patient Position/Location

- Patient is placed in either decubitus, supine, or prone position that will allow best access to planned biopsy path
  - Ensure that patient is comfortable
  - Remember that repositioning patient with pathologic fracture is difficult
    - Try to perform biopsy without removing external fixation (backslab) device

Procedure Steps

- Perform preliminary US to ensure that tumor is suitable for US-guided needle biopsy & plan best approach to tumor
- Helpful if orthopedic surgeon can mark planned surgery site on skin
  - Perform biopsy at this site whenever possible
  - Allows biopsy tract to be removed en bloc at time of surgery
  - Theoretical risk of seedling of tumor along needle tract
  - In practice, with good technique, this risk is negligible with percutaneous biopsy
- Plan needle path to avoid any neurovascular bundle, other critical structure (e.g., spermatic cord), or noninvolved compartment
  - Use color Doppler US to identify hypervascular areas within tumor
    - Hypervascular areas contain viable tumor, which should be targeted for biopsy
- Disinfect & drape skin
- Local anesthetic to skin ± periosteum
- Small stab incision in skin
- Use dominant hand to guide biopsy needle whenever possible & nondominant hand to hold transducer

- 3 possible US-guided techniques can be considered, depending on integrity of bone cortex
  - Bone lesions with extraosseous component are biopsied same way as soft tissue biopsy with coaxial needle & core biopsy needle technique
  - For intramedullary lytic lesions with markedly thinned ± disrupted cortex, standard coaxial needle can usually penetrate through cortex, with CNB performed via coaxial tract
  - If intact bone cortex is not thin enough for standard coaxial needle to penentrate through, trephine needle can be used to penetrate bone cortex & serves as coaxial needle for insertion of core biopsy needle
- Check that core biopsy needle is sufficiently long to acquire biopsy once opened within coaxial or trephine needle
  - Normally, 15-cm, 16-g Temno needle is used in conjunction with 10-cm, 15-g coaxial needle or, less commonly, 11-g trephine needle
- Advance coaxial needle into closest margin of tumor under real-time imaging
  - Only advance needle when needle tip is visible on real-time imaging
  - Use slow-rotating/pushing action of coaxial needle rather than pure pushing action to penetrate investing fascia & pseudocapsule of tumor
  - Maintain finger contact with skin when advancing needle to prevent needle from lunging forward
  - If cortex intact, apply further anesthetic to periosteum prior to cortex penetration
- Position coaxial needle tip in outer periphery of tumor
  - Maximizes ability to angle coaxial needle to biopsy different parts of tumor
- Remove inner stylet of coaxial needle & replace with biopsy needle
- Take biopsy only under real-time imaging
- Avoid cystic & necrotic areas, aiming to target viable tumor tissue for biopsy
  - Take some cores from subcapsular margin of tumor
- Sampling different parts of tumor ensures representative biopsy sample
- Number of biopsies taken depends on friability of tumor
  - If tumor is not friable, 3 good biopsy cores from different parts of tumor is adequate
  - If tumor is friable, may need to take > 10 biopsies from different parts of tumor, particularly tumor margins
- Apply direct pressure to biopsy site for 5 minutes after procedure or longer (15 minutes) if tumor hypervascular
- If active bleeding noted from coaxial needle before needle removal, temporary embolic agents, e.g., gelatin foam, can be inserted/injected via needle to seal off tract & aid hemostasis
  - Embolic agents should be available in procedure room
- Apply simple dressing & observe within department for 1 hour after biopsy
- If no signs of bleeding at 1 hour (swelling, bruising, oozing from wound), patient can be discharged

Alternative Procedures/Therapies

- US fusion-guided biopsy
  - Fuses previously obtained DICOM CT or MR data with real-time US & uses navigation system to allow accurate determination of transducer position
    - DICOM CT or MR data loaded onto US system
    - 2 electromagnetic sensors clipped onto bracket placed over US transducer
    - US transducer placed in same imaging plane as uploaded CT or MR data
    - ≥ 1 anatomical landmarks identified on both US & CT/MR
    - Embedded software then fuses US & CT/MR
    - Areas corresponding to those seen on US can be seen on CT or MR
    - Both US & CT/MR data can be viewed side by side or as image overlay where US overlaps CT or MR
- US fusion-guided biopsy is well suited to percutaneous biopsy of bone lesions
  - Suitable for lesions > 1.5 cm in size with < 2 cm transosseous path & without adjacent vulnerable structures
  - Expands applicability for percutaneous US-guided biopsy of bone lesions not visible on US alone
  - Diagnostic yield (adequacy of biopsy specimen) of 94% & diagnostic accuracy (of specimen relative to final diagnosis) of 95%, comparable to CT-guided biopsy

OUTCOMES

Complications

- Most feared complication(s)
  - Neurovascular injury can be avoided by
    - Carefully recalling & identifying all nerves & vascular structures within needle path
    - Large tumors may efface or displace neurovascular bundles, hence must trace proximally or distally from tumor to identify any neurovascular bundle
    - Only advancing biopsy needle under real-time imaging
    - Not allowing biopsy needle to pass into normal tissues beyond tumor
- Immediate/periprocedural complication(s)
  - Bent core biopsy needle due to forceful opening of biopsy needle against bone
    - Can be avoided by gentle steady opening of biopsy needle & planning biopsy tract to avoid any hard bone en route
    - Biopsy needle should open freely without pressure
      - Exception being firm, fibrotic tumors
    - If resistance encountered, alter needle direction & continue opening biopsy needle within tumor
    - Alternatively, unlock coaxial Luer lock & allow biopsy needle to slide backward during biopsy
  - Pain is usually minor &, at most, requires mild analgesia for 24 hours
  - Slight bruising at biopsy site
- Delayed complication(s)
  - Infection & delayed hemorrhage
    - Both complications are interrelated & very rare
  - Properly performed percutaneous bone biopsy is safe procedure with few complications

SELECTED REFERENCES

1. Wong H et al: Diagnostic yield and concordance of image-guided biopsy in musculoskeletal lesions. Skeletal Radiol. 53(1):75-84, 2024
2. Ponti F et al: Ultrasound-guided percutaneous bone biopsy: feasibility, diagnostic yield and technical notes. Diagnostics (Basel). 13(10), 2023

Bone Tumor With Extraosseous Mass

Review of Previous Imaging

(Left) *Frontal radiograph in a skeletally immature patient shows severe, infiltrative-like osteolysis ➡ with extensive tumoral new bone formation ➡ in the midfemoral diaphysis with soft tissue swelling ➡.* **(Right)** *Coronal T1 C+ MR in the same patient more clearly shows the extraosseous tumor extent ➡ and a greater degree of intramedullary tumor spread ➡ than that seen radiographically. MR imaging is usually advisable prior to any US-guided bone tumor biopsy.*

Planning of Biopsy Trajectory

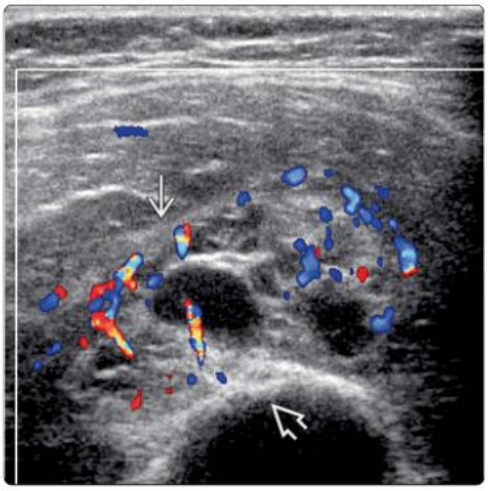

Biopsy of Extraosseous Tumor

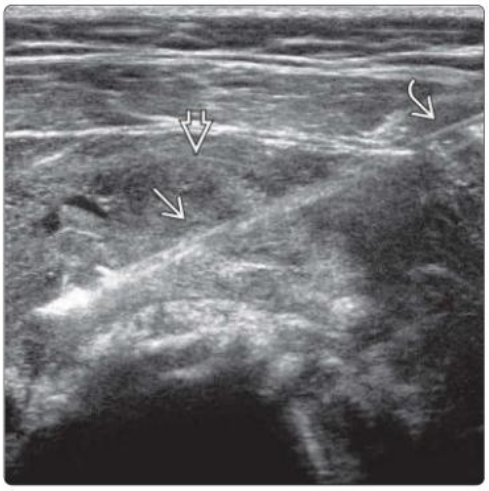

(Left) *Transverse color Doppler US in the same patient shows a moderately hypervascular ➡, mixed solid/cystic extraosseous tumor. The underlying femoral cortex ➡ is largely intact. Biopsy should be aimed at the hypervascular areas and avoid the cystic areas.* **(Right)** *Transverse US during US-guided biopsy shows how the more solid component of the extraosseous tumor ➡ has been selected for biopsy. A 16-g core biopsy needle ➡ has been inserted through a 15-g coaxial needle ➡. Histology revealed osteosarcoma.*

Bone Tumor With Extraosseous Mass

Review of Previous Imaging

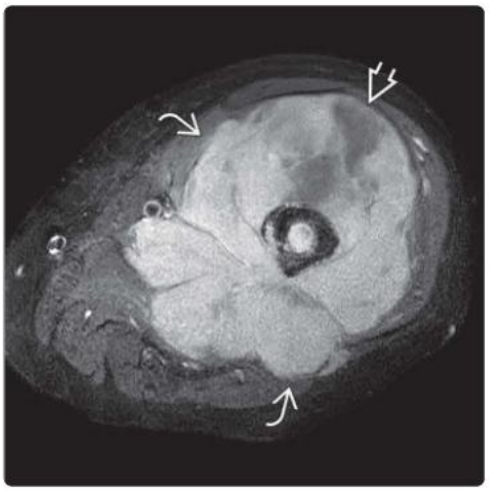

(Left) *Frontal radiograph of a patient with diffuse thigh swelling shows a lobulated cortical thickening ➡ along the femoral shaft with a large soft tissue mass ➡. Note the biopsy-proven enchondroma ➡ in the distal shaft.* **(Right)** *Axial T1 C+ FS MR of the midthigh in the same patient shows an enhancing tumor with a large, extraosseous component ➡. There is cortical and periosteal thickening with no cortical disruption. Irregular, nonenhancing areas ➡ of tumor necrosis should be avoided during biopsy.*

(Left) *Longitudinal color Doppler US of the midthigh in the same patient shows a large, extraosseous tumor. Cystic/necrotic areas on the deep aspect should be avoided. Areas of mild hyperemia more superficially and along septa should be targeted for biopsy to increase diagnostic yield.* **(Right)** *Transverse US of the same lesion shows coaxial needle tip just deep to the capsular edge of the extraosseous component. This maximizes ability to angle biopsy needle to sample different parts of the tumor.*

Planning of Biopsy Trajectory

Insertion of Coaxial Needle Into Extraosseous Mass

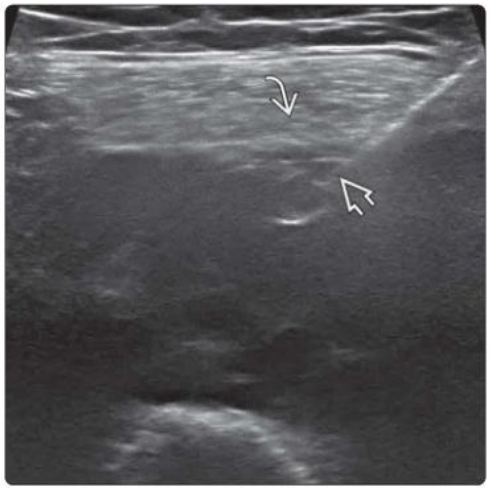

(Left) *Transverse US at the same site shows a 16-g Temno biopsy needle inserted into the extraosseous tumor via the 15-g coaxial needle, targeting the solid tumor component. Histology revealed diffuse large B-cell lymphoma.* **(Right)** *Frontal radiograph in a patient with suspected metastatic renal cell carcinoma shows a destructive lytic lesion in the femoral neck and trochanteric region. There is femoral neck pathological fracture, which limited patient positioning during US assessment and procedure.*

CNB via Coaxial Tract

Bone Tumor With Pathological Fracture

(Left) *Transverse US of the anterior hip in the same patient shows a large, extraosseous tumor, which allows biopsy to be performed while patient lies comfortably in supine position. Note cortical break representing site of pathological fracture.* **(Right)** *Longitudinal US at the same site shows positioning of a 16-g Temno needle, through a 15-g coaxial needle, aiming at the subcapsular margin of the extraosseous tumor to increase diagnostic yield. Histology confirmed metastasis from clear cell renal cell carcinoma.*

Planning of Biopsy Trajectory

CNB at Capsular Edge

Planning of Biopsy Trajectory

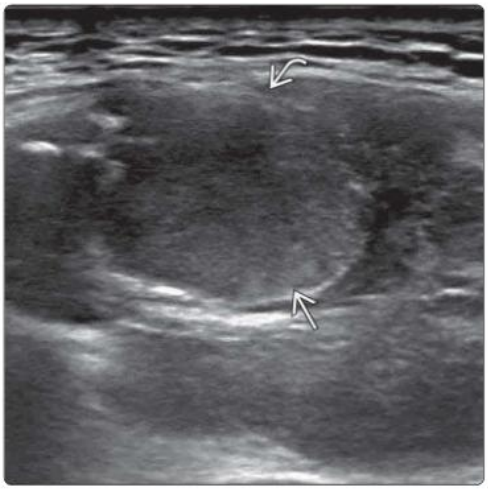

Biopsy Tract Along Long Axis of Tumor

(Left) *Transverse US of the sternal body in a patient with breast carcinoma shows a destructive lesion ➡ with extraosseous extension ⇨. The small lesion size on this plane does not allow complete placement of a Temno biopsy needle within the tumor.* **(Right)** *Longitudinal US at the same site shows a longer dimension of the tumor ➡, which allows placement of the 20-mm sample notch of the biopsy needle ➡ within the lesion. Diagnostic yield is correlated with the length of sampled tissue. Histology confirmed metastasis.*

Assessment of Procedural Risk

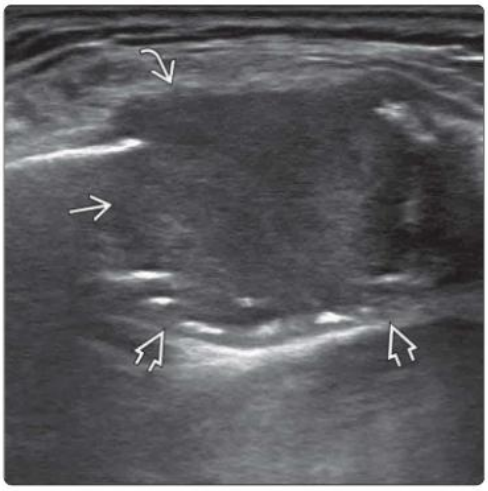

Assessment of Procedural Risk

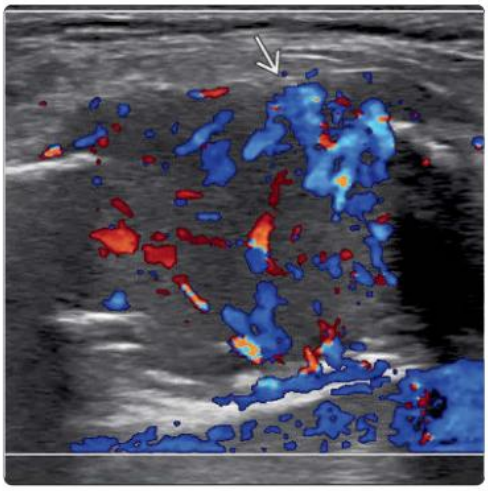

(Left) *Longitudinal US of the sternal body of a patient with nonspecific bone pain shows a destructive lesion ➡ with extraosseous extension ⇨. The deep cortex ➡ is also disrupted.* **(Right)** *Longitudinal color Doppler US at the same site shows marked tumoral hyperemia ➡. The small lesion size, disrupted deep cortex, and hyperemia imply higher procedural risks, including inadvertent deep needle penetration beyond tumor, cardiovascular injury, and hemomediastinum not controllable by local compression.*

Selection of Lesion for Safe Biopsy

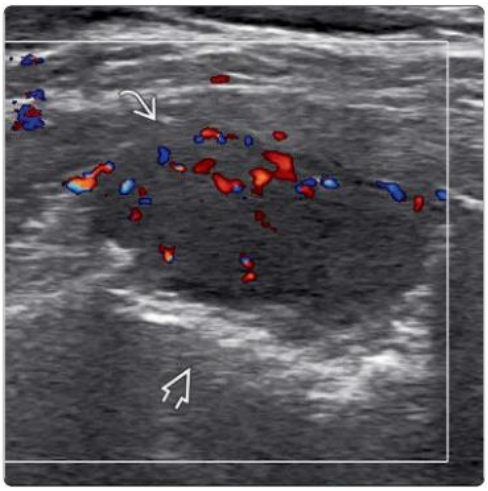

Core Biopsy of Small Lesion

(Left) *Transverse color Doppler US in the same patient shows a destructive, hyperemic lesion ⇨ in the pubic bone ➡. This was noted on prior PET/CT and was selected for biopsy due to lower risk.* **(Right)** *Transverse US at the same site shows a 16-g Temno needle ➡ placed into tumor via a 15-g coaxial needle ➡. Small lesion size precludes complete insertion of biopsy needle. Instead, the Temno was allowed to slide backward into the coaxial needle during biopsy. Histology revealed thyroid metastasis.*

Pathological Fracture With Extraosseous Soft Tissue

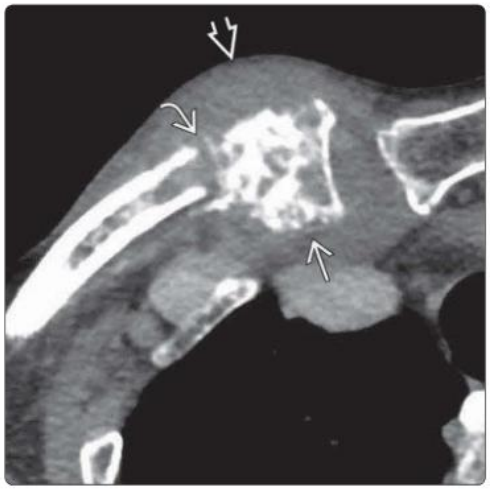

Core Biopsy of Small Lesion

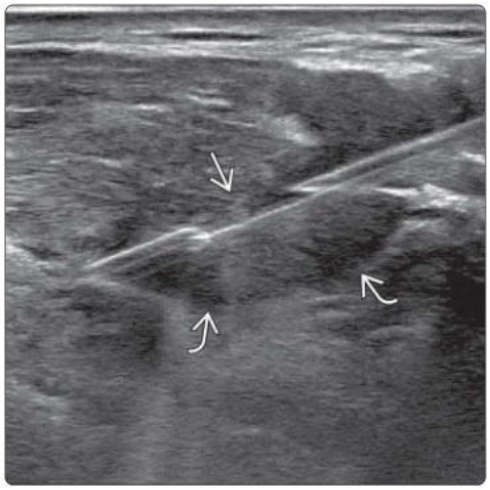

(Left) *Axial CT of the sternoclavicular joint in a patient with localized pain shows a destructive lesion ➡ at the medial end of the clavicle with pathological fracture ➡ & extraosseous soft tissue ➡.* **(Right)** *Transverse US at the same site shows placement of the 10-mm sample notch ➡ of a Temno Evolution biopsy needle into the extraosseous soft tissue ➡. This needle has variable notch sizes (10-20 mm), providing flexibility especially for biopsy of small lesions. Histology showed low-grade follicular lymphoma.*

Tumor With Extraosseous Mass

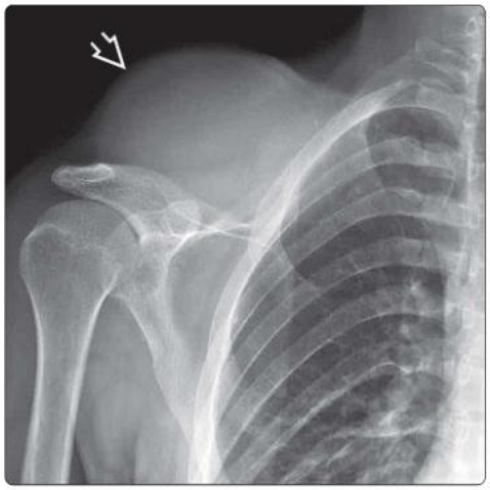

Review of Previous Imaging

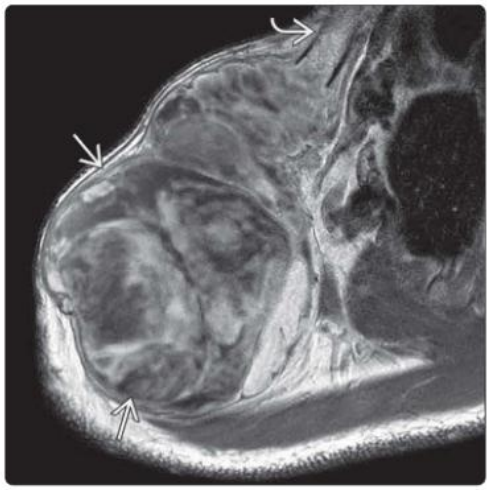

(Left) *Frontal radiograph of the shoulder in a patient with known NF1 shows almost complete osteolysis of the clavicle with a large soft tissue mass ➡.* **(Right)** *Axial T1 C+ MR of the right clavicle shows a very large, heterogeneously enhancing tumor ➡. Only the medial clavicular end ➡ remains. For such a heterogeneous lesion, multiple biopsies from different parts of the tumor are usually required in order to obtain sufficient representative tissue.*

Multiple Core Biopsies via Coaxial Tract

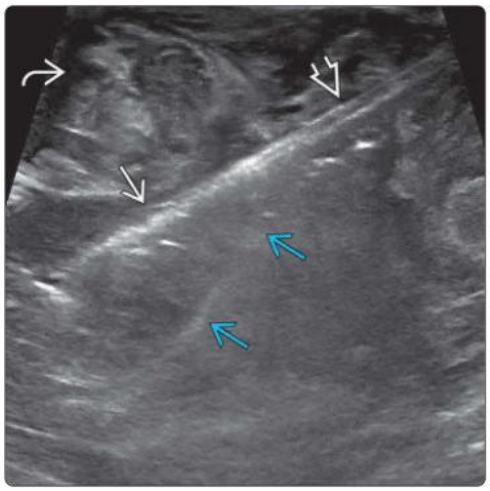

Multiple Core Biopsies via Coaxial Tract

(Left) *Transverse US of the supraclavicular region in the same patient shows placement of a Temno biopsy needle ➡ via a coaxial needle ➡ into the large, heterogeneous tumor mass ➡. A previous biopsy tract ⇨ aiming at the deeper part of the tumor is visible.* **(Right)** *Transverse US during the same procedure shows another biopsy targeting the capsular edge ➡ of the tumor. Histology revealed an intraosseous malignant peripheral nerve sheath tumor.*

Chronic Osteomyelitis

Chronic Osteomyelitis Acute Exacerbation

(Left) *Lateral radiograph of the distal humerus in a young patient with clinically suspected infection shows quite marked expansion of the distal humerus, medullary osteolysis ➡, mature-type periosteal new bone formation ➡, and moderate soft tissue swelling, consistent with chronic osteomyelitis.* **(Right)** *Sagittal T1 C+ FS MR in the same patient shows a medullary sinus tract and abscess ➡ extending to the dorsum of the distal humerus ➡, consistent with acute exacerbation of chronic osteomyelitis.*

Planning of Biopsy Trajectory

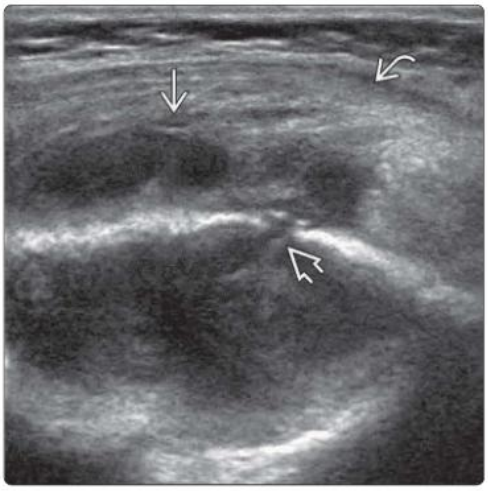

Biopsy of Juxtacortical Inflammatory Tissue

(Left) *Transverse US in the same patient shows thinning and breaching of the distal humeral cortex ➡ with focal juxtacortical edematous inflammatory tissue ➡ deep to an edematous triceps muscle ➡. US can guide biopsy of inflammatory tissue or aspiration of any collection.* **(Right)** *Transverse US shows biopsy of the juxtacortical inflammatory soft tissue ➡ with a 16-g Temno biopsy needle using a coaxial technique with a 15-g coaxial needle ➡. Culture of the biopsy material grew Staphylococcus aureus.*

Chronic Osteomyelitis

Chronic Osteomyelitis

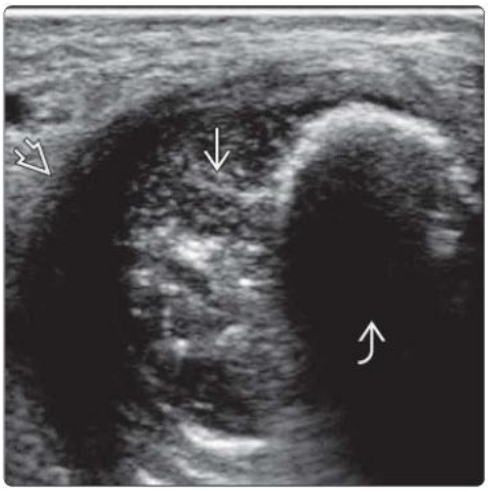

(Left) *Frontal radiograph in a 14-year-old boy with fever and wrist pain shows a lytic lesion with a wide zone of transition in the distal ulnar metaphysis ➡.* **(Right)** *Transverse US in the same patient shows a prominent, solid-appearing, juxtacortical soft tissue mass surrounding the distal ulna ➡ with echogenic seams of new bone formation ➡. An outer hypoechoic area representing fluid or severe edema is present ➡. US-guided biopsy of the juxtacortical soft tissue revealed chronic osteomyelitis, differentiating it from an aggressive bone tumor.*

(Left) *Frontal radiograph in a young man with slowly growing medial forefoot swelling shows a markedly expanded, lytic tumor with thinned but intact overlying cortex ➡ at the proximal part of the 1st metatarsal bone. As cortex is markedly thinned, this tumor is suitable for US-guided biopsy.* **(Right)** *Clinical photograph shows medial forefoot swelling ⇨ in same patient. The foot is rested against a firm surface to limit motion during procedure. This is especially important when inserting coaxial needle through intact cortex.*

Intramedullary Tumor With Intact Cortex

Adequate Patient Positioning

(Left) *Transverse color Doppler US in the same patient shows an expansile tumor of the 1st metatarsal bone. The thinned cortex is still visible ➡, but it causes so little beam attenuation that the intramedullary tumor and its vascularity can still be readily appreciated.* **(Right)** *Transverse US in the same patient during bone biopsy shows a 15-g coaxial needle ➡ just after piercing the thin cortex ➡ overlying the tumor. Gentle sustained pressure/rotation on the coaxial needle allows penetration of the cortex.*

Planning of Biopsy Trajectory

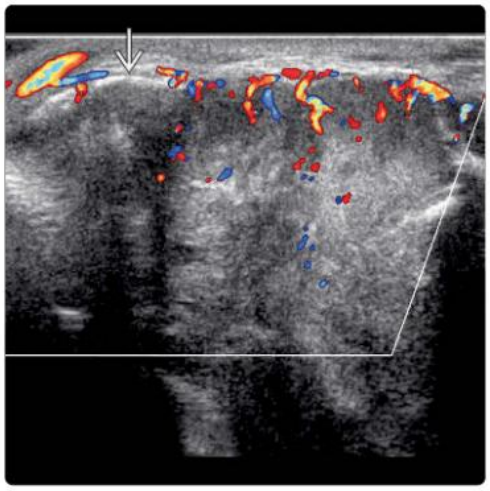

Insertion of Coaxial Needle Through Intact Cortex

(Left) *Transverse US in the same patient shows a 16-g Temno core biopsy needle ➡ inserted though a 15-g coaxial needle ➡ to biopsy the central part of the metatarsal tumor ➡.* **(Right)** *Transverse US of the same tumor shows the 16-g core biopsy needle ➡ and coaxial needle ➡ repositioned to biopsy a more superficial part of the metatarsal bone tumor. At least 3 biopsies from different parts of the tumor should be obtained, with at least one taken from the subcapsular margin. Histology revealed giant cell tumor of bone.*

Biopsy of Intramedullary Tumor via Coaxial Tract

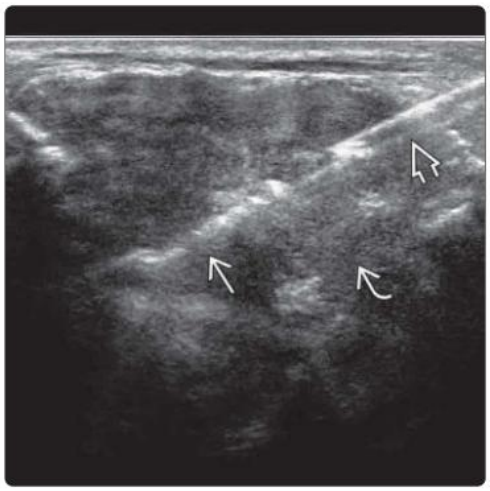

Multiple Biopsies via Coaxial Tract

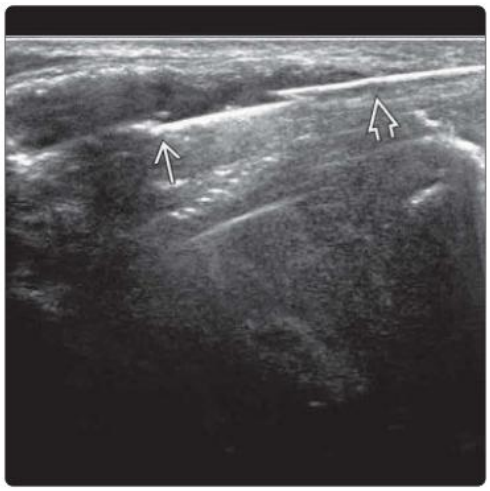

Injection of Local Anesthetic

Insertion of Trephine Needle

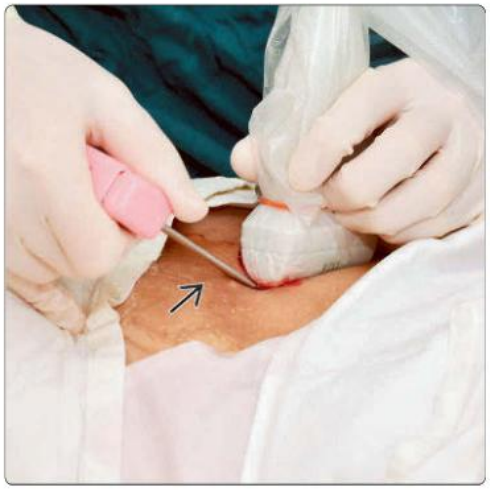

(Left) *Clinical photograph shows injection of local anesthetic ⇨ at chosen site for percutaneous biopsy of a sacral tumor. The dermal and periosteal tissues should be preferentially infiltrated.* **(Right)** *Clinical photograph shows insertion of an 11-g trephine biopsy needle ⇨ following a short stab incision with scalpel. Trephine needle is used when the thinned cortex is not penetrable by standard coaxial needle. Once the cortex is penetrated, the inner stylet is removed from the outer cannulated trephine biopsy needle.*

Insertion of Trephine Needle Through Intact Cortex

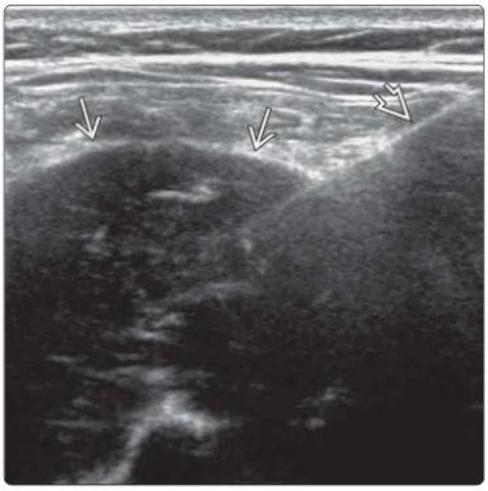

Insertion of Biopsy Needle via Coaxial Tract

(Left) *Longitudinal US in the same patient shows the trephine needle ⇨ piercing the thinned, expanded cortex ⇨ of the hypoechoic sacral tumor. A Temno biopsy needle alone would usually not be able to pierce an intact, albeit thinned, bone cortex.* **(Right)** *Clinical photograph shows a 15-g Temno biopsy needle ⇨ introduced into the tumor via the cannula of the trephine biopsy needle ⇨ following removal of the inner stylet.*

Obtaining CNB

Biopsy of Intramedullary Tumor via Coaxial Tract

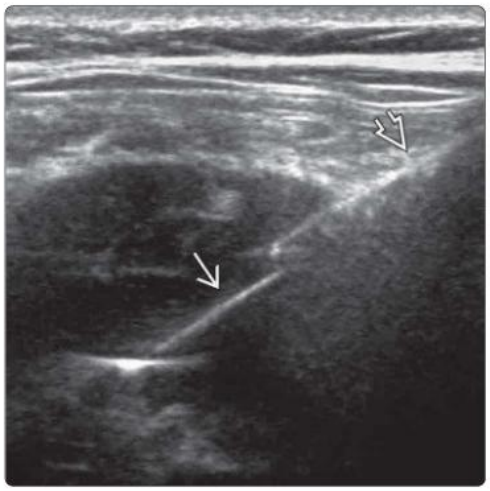

(Left) *Clinical photograph of the same patient during biopsy shows depression of the biopsy needle plunger ⇨ under real-time US guidance. An assistant is often needed to secure the position of the trephine needle ⇨ at this stage.* **(Right)** *Longitudinal US in the same patient shows specimen slot of the Temno biopsy needle ⇨ extending beyond the tip of the trephine biopsy needle ⇨. All needle advancement must be performed under real-time US guidance. Histology revealed a chordoma.*

KEY FACTS

TERMINOLOGY

- Percutaneous biopsy of synovial tissue

PREPROCEDURE

- US usually cannot differentiate different types of synovial tumor or distinguish between inflammatory, prosthetic, or infective synovial proliferation
- US-guided percutaneous synovial biopsy is preferred method for obtaining definitive diagnosis of synovial tumors & confirming or excluding joint infection in both native & prosthetic joints when little or no joint fluid is present
- Determine most suitable & safest needle path for US-guided biopsy

PROCEDURE

- Ideal biopsy path should be from skin to synovium or synovial tumor without intervening nerves, arteries, veins, or infected tissue; avoid tendons whenever possible
  - Carefully planned approach is key to successful biopsy
- Needle path is usually less direct than that used for joint aspiration
- Perform preliminary US to ensure that lesion is suitable for US-guided needle biopsy & plan best approach to lesion
- Needle inserted under real-time US guidance some distance from joint to enable nonobtuse angle with needle aligned along length of synovium
  - Local anesthetic to skin & capsule but not synovium
- Coaxial technique saves time & minimizes tissue damage between skin & joint capsule
  - Tip of coaxial needle should be positioned just beneath joint capsule to allow redirection of biopsy needle
- End-cutting (Franseen) needle technique useful for small or medium-sized joints
- Side-cutting needles with shorter specimen notches are also available

POST PROCEDURE

- Synovial biopsy is well tolerated & safe

Preprocedural Planning

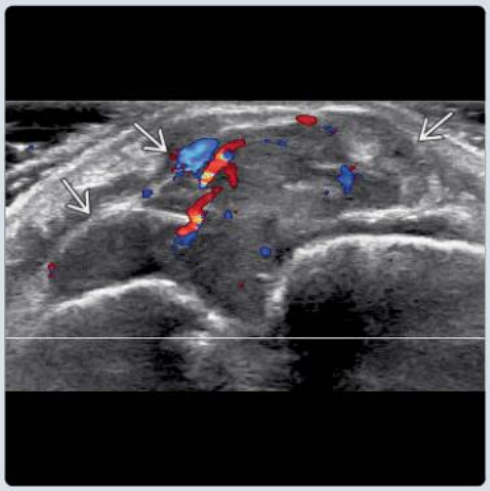

Needle Alignment Along Length of Synovial Tumor

(Left) *Transverse color Doppler US of the hindfoot shows a moderately vascular synovial mass ➡ arising from the calcaneocuboid joint. Preprocedural grayscale and color Doppler US should be performed to plan the biopsy path from skin to synovium or synovial tumor without transgressing nerves, arteries, veins, or infected tissue.* **(Right)** *A 16-g Temno needle is used during biopsy of the same mass. Note the needle angle along the length of synovium with the 2-cm sampling notch ➡ unsheathed and aligned along the length of the tumor.*

Proper Angling of Biopsy Needle

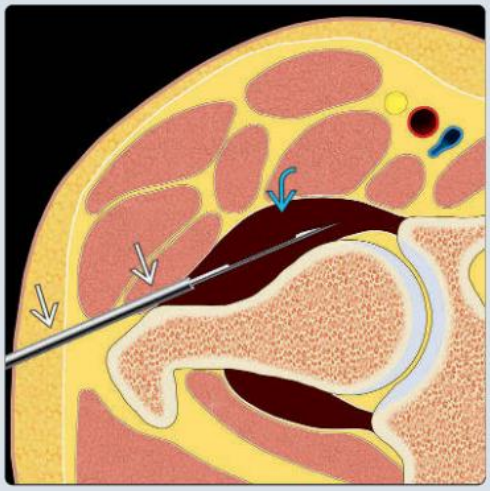

Sampling Needles Used in Synovial Biopsy With or Without Joint Aspiration

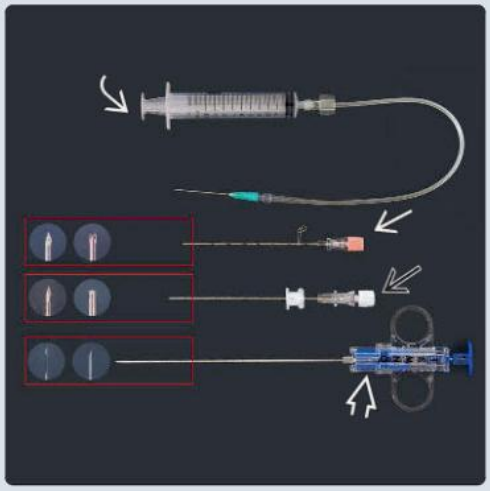

(Left) *Graphic shows the needle path ➡ for hip synovial biopsy. As the biopsy needle must pass though the tumor or synovium ⇨, one must plan an approach with the needle's sampling notch aligned along the long axis of the tumor, unlike the more obtusely angled approach used for joint aspiration.* **(Right)** *Synovial biopsy can be performed using an end-cutting Franseen needle ➡ for small lesions or a side-cutting, e.g., Temno ➡, with a coaxial ⇨ needle for larger lesions. A 21-g hypodermal needle ➡ is for joint aspiration.*

TERMINOLOGY

Definitions

- Percutaneous biopsy of synovial tissue

PREPROCEDURE

Indications

- Establish accurate histologic characterization of synovial lesion to allow definitive treatment
  - Due to high variability in appearance of synovial tumors, biopsy usually recommended to confirm diagnosis
  - Image-guided core needle biopsy of synovial tumors has diagnostic accuracy of 93-100%, which is similar to open surgical biopsy
    - Also useful to confirm or exclude tumor recurrence in patient with prior tumor resection
- Synovial biopsy is very accurate means of confirming or excluding joint infection in patients with moderate to severe synovial thickening & little or no joint fluid present
  - Imaging appearances alone cannot relatively differentiate infective, inflammatory, crystal-related, & prosthetic synovitis
  - If effusion is present, synovial fluid aspiration for microbiologic & crystal analysis should be performed initially
    - Especially in prosthetic joints, ≤ 10 cores should be obtained as bacterial load in synovium may be low
    - Also, consider repeating biopsy if clinical suspicion of injected prosthetic joint is high & initial culture is negative
  - Synovial biopsy should be repeated on 3 separate occasions before prosthetic joint infection can be fully excluded
  - Synovial biopsy culture yield does not seem to be affected by prior antibiotic treatment

Contraindications

- Active skin infection
- Severe bleeding diathesis
- Uncooperative patient
- Joint not optimally visualized by US due to limb contracture, which may be amenable to CT guidance

Preprocedure Imaging

- Helps characterize synovial pathology & provide baseline for follow-up imaging
- Radiographs insensitive to early synovial disease
  - Ossified intraarticular bodies help confirm diagnosis of synovial osteochondromatosis
- US can depict degree of synovial thickening & hyperemia
  - Highly sensitive at revealing synovitis
- MR provides more information in differentiating tumor vs. nontumoral synovial disease
  - Enables fuller appreciation of disease extent
  - May allow definitive diagnosis of lipoma arborescens, synovial lipoma, & synovial vascular malformation & hence negate need for synovial biopsy
- CT generally less useful than MR though may show dystrophic mineralization in crystal arthropathies or metallosis in prosthetic synovitis

Getting Started

- Things to check
  - Patient identity, type of procedure, site of procedure, informed consent
  - Review prebiopsy imaging work-up
  - Determine choice of imaging modality to guide biopsy: US is usually preferable
    - CT-guided synovial biopsy can feasibly be performed for joints less accessible to US such as temporomandibular joint & in deep-seated joints in large patients
- Medications
  - Local anesthetic (3-5 mL 1-2% lignocaine) to skin, subcutaneous layer, & just external to joint capsule
  - Sedation is usually not necessary but can be helpful for anxious patients or young children
- Equipment list
  - Sterile biopsy set
  - Biopsy needle type: Depends on volume of synovial tissue amenable to percutaneous biopsy
    - Side-cutting Tru-Cut needles most commonly used when there is > 2.5 cm of tissue amenable to biopsy
      - Standard Tru-Cut biopsy needle has 2.0-cm sample notch with 0.5-cm dead space between sample notch & needle tip
    - End-cutting needles, e.g., Franseen biopsy, can be used for any lesion & are particularly useful when standard side-cutting needle (e.g., Tru-Cut) biopsy is not feasible, such as for elbow, wrist, or small joints of fingers
      - Use end-cutting tip to obtain tissue cores with no dead space & no firing mechanism
      - Connection to 10-mL syringe via thin extension tubing for gentle aspiration during biopsy helps ensure biopsy yield
  - Biopsy needle size
    - Large-bore (14-g to 18-g) biopsy needle
      - Larger-bore needle best whenever possible to maximize tissue yield
      - Synovial biopsy is low bleeding risk procedure with no advantage to using smaller gauge needles
  - Coaxial biopsy technique for standard side-cutting needle biopsy
    - Coaxial technique uses coaxial needle 1-g larger than Tru-Cut biopsy needle (e.g., 15-g coaxial needle, 16-g Tru-Cut needle)
    - Saves time & minimizes tissue damage between skin & joint capsule

PROCEDURE

Patient Position/Location

- Best procedure approach
  - Patient placed in either semi-supine, decubitus, or prone position to allow best access to synovium & avoid critical structures along needle path
  - Ideal biopsy path should allow passage from skin to synovium without transgressing intervening nerves, arteries, veins, or infected tissue; tendons should also be avoided whenever possible

Equipment Preparation

- Protective sheath for US transducer
- Sterile cleaning solution & sufficient US gel
- 5 mL of lignocaine 1-2% local anesthetic to skin & outer margin of joint capsule
- Biopsy needle: Typical use is 15-g coaxial needle & 16-g Tru-Cut side-cutting biopsy needle, or 18-g Franseen end-cutting needle & syringe with thin extension tubing

Procedure Steps

- Perform preliminary US to plan best approach to lesion
  - Ideal biopsy path requires guiding biopsy needle along length of synovium while passing through synovial lesion
  - Color Doppler US to identify periarticular vessels
- Instill local anesthetic to skin & subcutaneous tissues just external to joint capsule
  - Not to synovium as potentially bactericidal
- Make small stab incision in skin
- Insert needle under real-time US guidance some distance from joint to ensure proper angle such that needle is aligned along length of synovium
  - Carefully planned approach is key to successful biopsy
  - Synovial biopsy needle path usually less direct than that used for joint aspiration
  - Needle path should ideally be kept within synovium to minimize hemarthrosis risk
- Coaxial technique saves time & minimizes tissue damage between skin & joint capsule
  - Coaxial needle tip should be placed just deep to joint capsule to enable angulation of biopsy needle along different trajectories to obtain tissue cores from different parts of lesion
  - Avoid placing coaxial needle too deeply into synovium, which would limit angulation to different parts of lesion
  - Rinse biopsy needle tip in normal saline before reinserting into coaxial needle
- Use end-cutting (Franseen) needle technique with suction for small lesions or those with difficult side-cutting needle access
  - Once end-cutting (Franseen) needle tip is in position, remove inner stylet & connect to 10-ml syringe via thin extension tubing
  - Maneuver Franseen needle from most proximal to most distal aspect of synovium while rotating needle between fingertips to extract cores of synovial tissue using end-cutting tip
  - Repeat this to-and-fro process ~ 10 times while assistant applies continuous 5-mL suction to empty syringe connected via thin extension tubing
- Side-cutting needles with shorter specimen notches are also available
  - e.g., Temno Evolution needle with adjustable 1.0-cm & 2.0-cm specimen notches or Cook needle
- Unload tissue cores into specimen bottle
  - Side-cutting (Tru-Cut) needle: Unsheath fired needle to unload tissue core
  - End-cutting (Franseen) needle: Double flush extension tubing & biopsy needle, first with air directly into specimen bottle, then with formalin (aspirated carefully from specimen container) to ensure that no biopsy material remains within Franseen needle trocar
- Apply local pressure for hemostasis
- Procedure typically completed within 30 minutes as outpatient

Findings and Reporting

- Preliminary US description of lesion & overall impression or differential diagnoses should be provided
- Amount & type of local anesthetic given
- Type & size of biopsy needle used
- Number of tissue cores obtained
- Any immediate periprocedural complication

Alternative Procedures/Therapies

- Radiologic
  - CT-guided synovial biopsy
  - Fine-needle aspiration of joint fluid
    - Effective in excluding joint infection for native joints, but less sensitive for prosthetic joints, which tend to have more synovial proliferation & less joint fluid
    - Uses 21-g hypodermic needle or 20-g diamond needle
    - Send aspirate for culture & sensitivity (standard, TB, fungal culture), cell count, crystal analysis
    - Fluid for crystal analysis should be sent fresh
- Surgical
  - Open biopsy/synovectomy

POST PROCEDURE

Expected Outcome

- Uneventful & well tolerated in most circumstances

Things To Do

- Apply simple dressing
  - Dressing can be removed by patient on following day
- Monitor for ~ 1 hour in department for signs of bleeding (swelling, oozing, bruising)

Things To Avoid

- Immediate strenuous exercise
- Avoid water contact of biopsy site for 6 hours

OUTCOMES

Problems

- Inadequate tissue sampling or nonrepresentative sample
- False-negative result for prosthetic joints
  - If clinical suspicion of prosthetic joint infection is high & initial synovial fluid aspiration or biopsy is negative, biopsy or aspiration should be repeated up to 3 times before infection can be reliably excluded

Complications

- Most feared complication(s)
  - Neurovascular bundle injury
- Immediate/periprocedural complication(s)
  - Vasovagal syncope
- Delayed complication(s)
  - Infection & delayed hemorrhage

SELECTED REFERENCES

1. Yip SWY et al: Image-guided synovial biopsy with a focus on neoplastic lesions. Skeletal Radiol. 52(5):817-29, 2023

Side-Cutting vs. End-Cutting Biopsy Needles

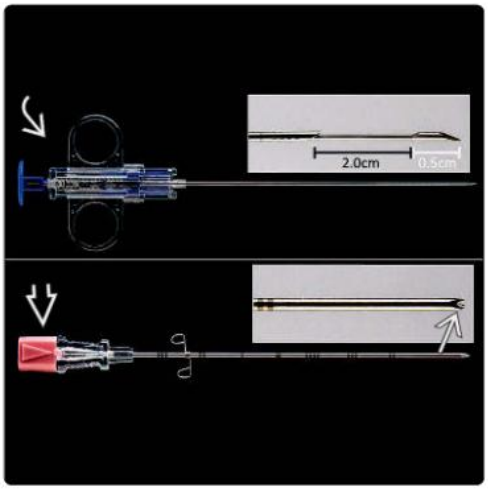

Biopsy Equipment

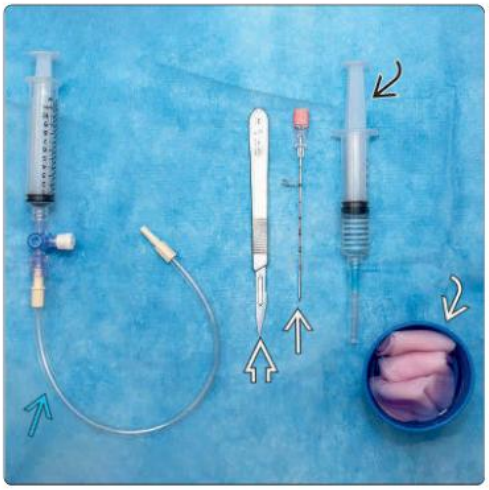

(Left) *Photograph shows a standard side-cutting biopsy needle (e.g., Temno) ⇒ with a standard 2.0-cm sample notch and a 0.5-cm forward dead space. An end-cutting biopsy needle (e.g., Franseen) ⇒ with a serrated, crowned end-cutting tip composed of 3 symmetrical cutting-edge surfaces ⇒ is shown.* **(Right)** *Photograph shows equipment for end-cutting needle biopsy: Antiseptic ⇒, blade ⇒, lignocaine local anesthetic ⇒, 18-g Franseen needle ⇒, & syringe connected to extension tubing ⇒ for suction.*

Injection of Local Anesthesia

Injection of Local Anesthesia

(Left) *After skin sterilization and application of sterile drapes and probe cover, 3-4 ml of local anesthetic (1-2% lignocaine) ⇒ is infiltrated via a 25-g needle to the skin and periarticular region under US guidance.* **(Right)** *Transverse US of the medial knee during injection of local anesthesia shows the 25-g hypodermic needle ⇒ within subcutaneous tissues and lignocaine ⇒ seeping into the periarticular soft tissues. The needle should always be aspirated prior to injection to avoid accidental injection into vessels.*

Insertion of Biopsy Needle

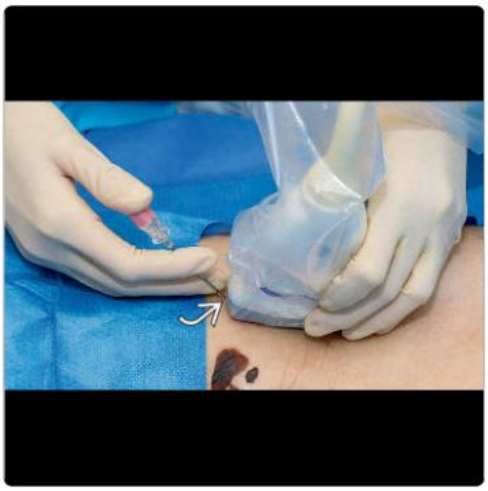

Insertion of Franseen or Coaxial Needle

(Left) *After a small skin incision is made, the biopsy needle ⇒ (either end-cutting, e.g., Franseen, or coaxial needle) is introduced under US guidance to the synovial lesion. The skin incision is often made some distance away from the synovium to allow adequate angulation.* **(Right)** *Transverse US shows the Franseen needle piercing the synovial mass. The needle tip ⇒ should always be visualized, and the needle should be aligned along the probe such that the entire length of the needle ⇒ is also visualized.*

Gentle Suction During Franseen Biopsy

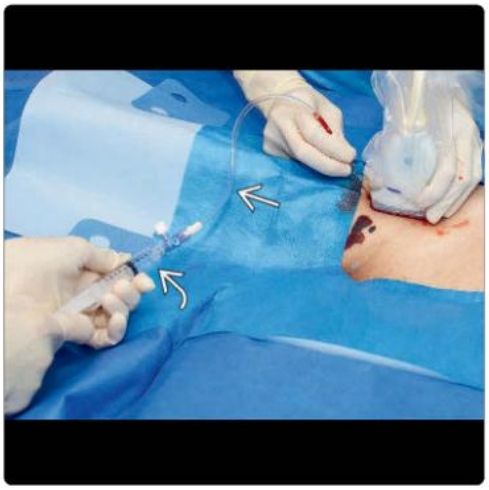

Double Flushing of Franseen Needle

(Left) *For Franseen biopsy, an assistant connects a 10-ml syringe via thin extension tubing ➡ to the needle trocar and applies ~ 5 ml of gentle suction ➡ while the operator makes multiple passes through the tumor, from the proximal to distal ends of the tumor via repeated to-and-fro motion.* **(Right)** *Photograph shows that after removal from the patient, the needle is double flushed, first by air, and second by aspirating some formalin ➡ from specimen container via extension tubing to flush ➡ all remaining tissue into specimen container.*

Specimen Handling

Suspected Focal Nodular Synovitis

(Left) *Photographs show tissue cores ➡ in a formalin container from an 18-g Franseen needle biopsy. The specimens can be more bloodstained than those from a Temno biopsy, but using an end-cutting needle biopsy is ideal for small lesions < 3 cm or in deep-seated locations alongside neurovascular bundles.* **(Right)** *Longitudinal oblique US at anterolateral knee shows a small (1.9 cm) hypoechoic focal mass ➡ inseparable from the synovium in the lateral parapatellar recess of the knee without distinctive features.*

Franseen Biopsy Focal Nodular Synovitis

Color Doppler for Prebiopsy Planning

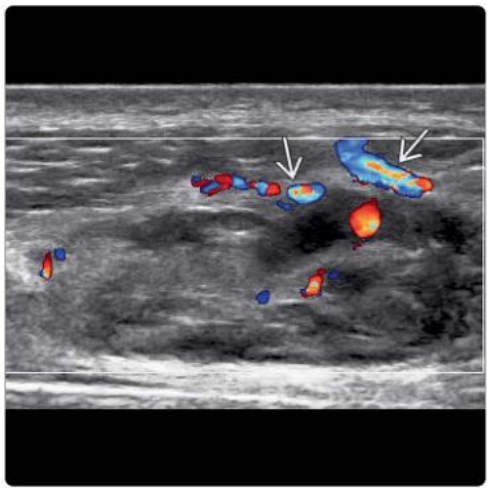

(Left) *Due to small lesion size, a Franseen needle ➡ was used for biopsy. Note the insertion site ➡ of the needle some distance from the joint to enable a proper angle to be achieved for the needle alignment along the length of the synovium. Histology was focal nodular synovitis.* **(Right)** *Doppler US shows a moderately hyperemic focal synovial mass in suprapatellar pouch with prominent veins coursing at its superficial aspect ➡. Note importance of using color Doppler to identify peritumoral vessels that should be avoided.*

Tru-Cut Biopsy of Pigmented Villonodular Synovitis

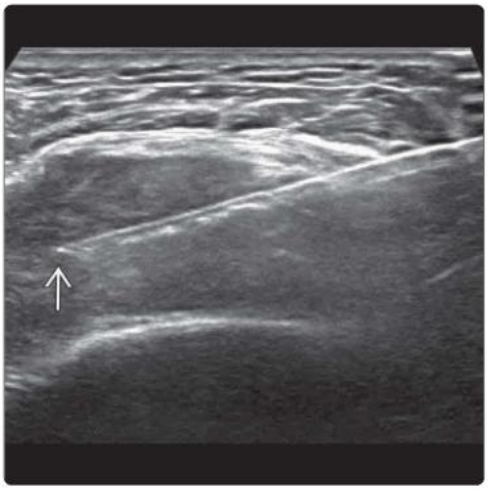

Franseen Biopsy of Elbow

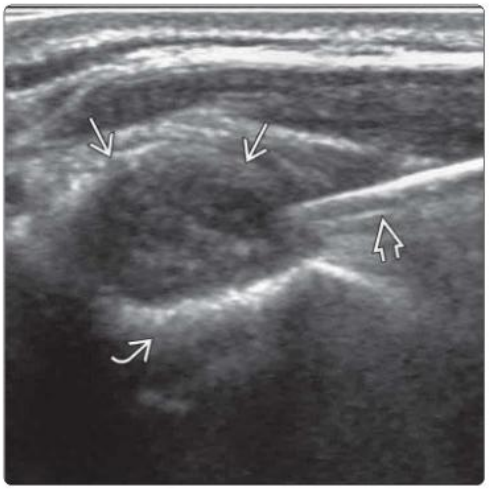

(Left) *Percutaneous biopsy of the same focal synovial thickening using a 16-g Temno needle shows how the needle tip ➡ is kept within the confines of the synovium. Histology was pigmented villonodular synovitis.* **(Right)** *Longitudinal US of the patient's elbow shows use of an 18-g Franseen needle ➡ during biopsy of a small (1.5 cm) synovial mass ➡ alongside the radial neck ➡. A Franseen needle is ideal for small lesions. Histology revealed synovial chondromatosis.*

Coaxial Needle Insertion

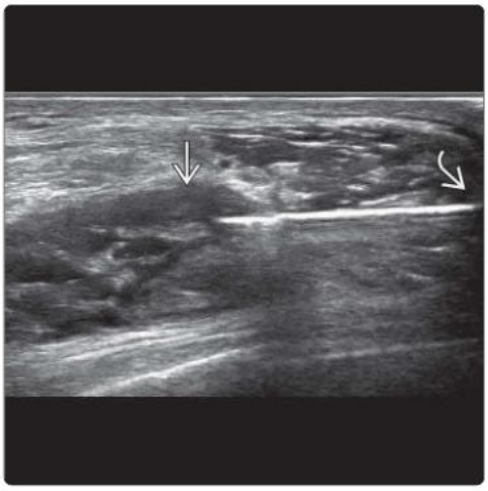

Tru-Cut Biopsy of Synovial Hemangioma

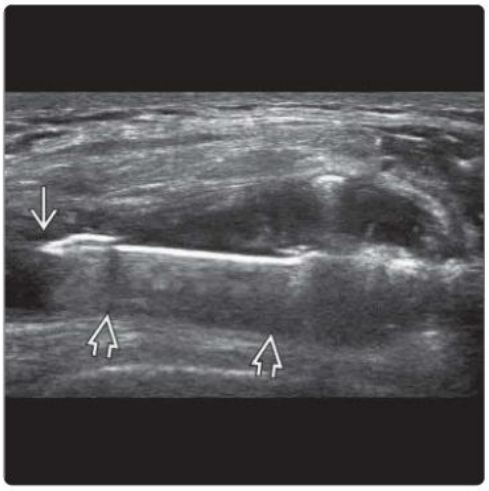

(Left) *A 15-g coaxial needle is inserted some distance away ➡ from the suprapatellar pouch ➡ in this patient with a suspected synovial hemangioma to allow subsequent angulation of the biopsy needle.* **(Right)** *Longitudinal US of the same patient shows the biopsy needle aligned parallel to the synovium ➡ clearly visualizing the needle tip ➡. Histology revealed a diagnosis of synovial cavernous hemangioma.*

Suspected Septic Arthritis

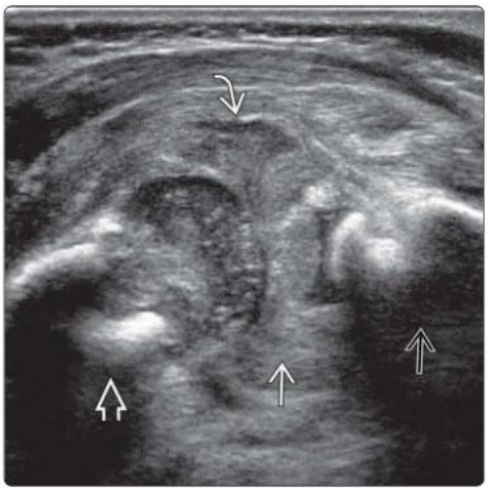

Synovial Biopsy Septic Arthritis

(Left) *Transverse US of a child with fever and shoulder pain shows severe diffuse synovial thickening of the glenohumeral joint ➡. Only minimal fluid ➡ is present. Note the humeral head ➡ and scapula ⇨.* **(Right)** *Longitudinal US of the same area as the previous image shows use of a Temno side-cutting needle ➡ synovial biopsy for histologic and microbiologic analysis. Synovial biopsy grew Staphylococcus epidermis, while histology revealed acute-on-chronic inflammation.*

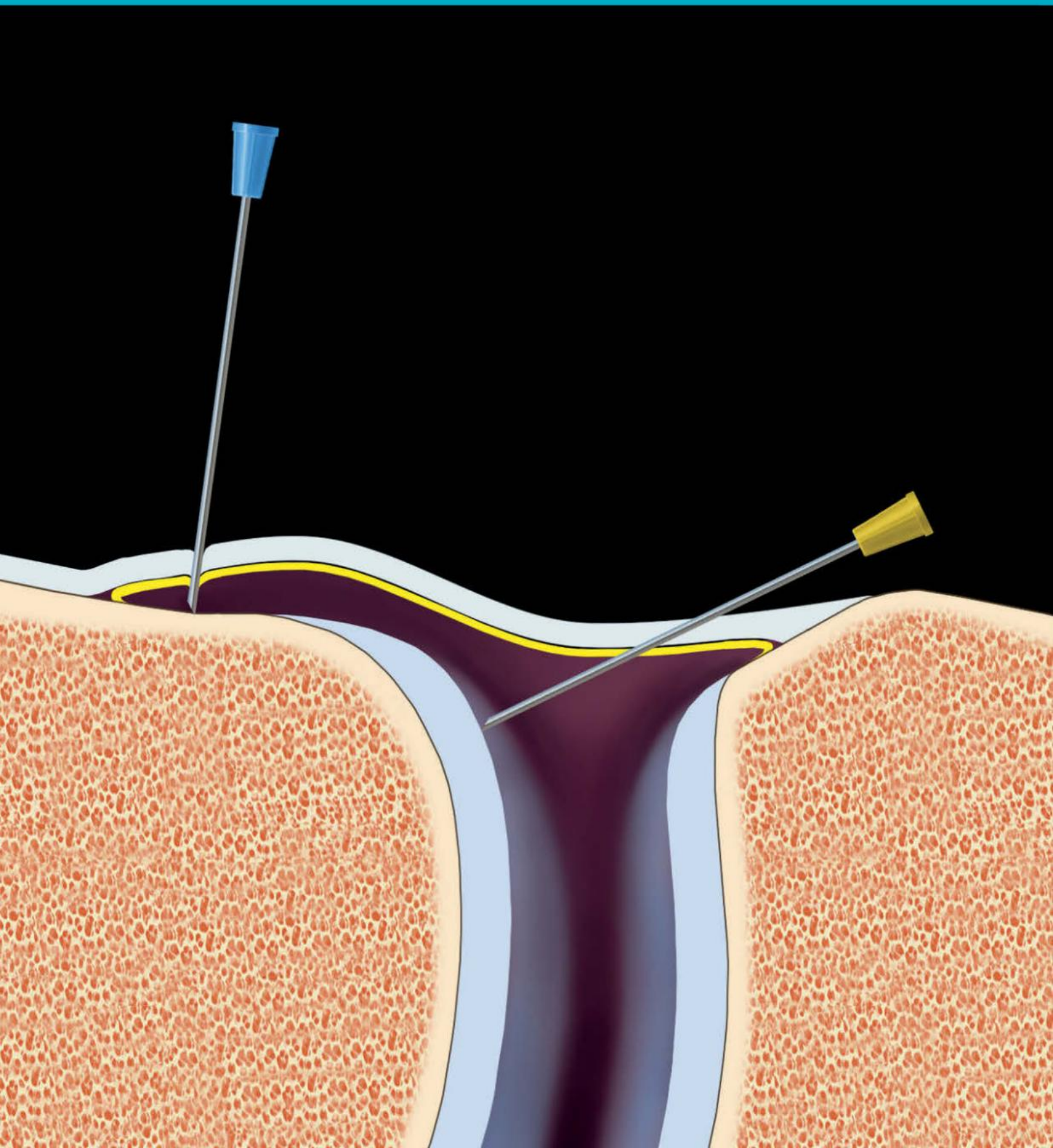

PART V
SECTION 2

Joint Procedures

Joint Injection: Upper Limb	968
Joint Injection: Lower Limb	978
Shoulder Procedures	986
Elbow Procedures	994
Hand and Wrist Procedures	1000
Hip and Pelvis Procedures	1006
Knee Procedures	1014
Ankle and Foot Procedures	1022

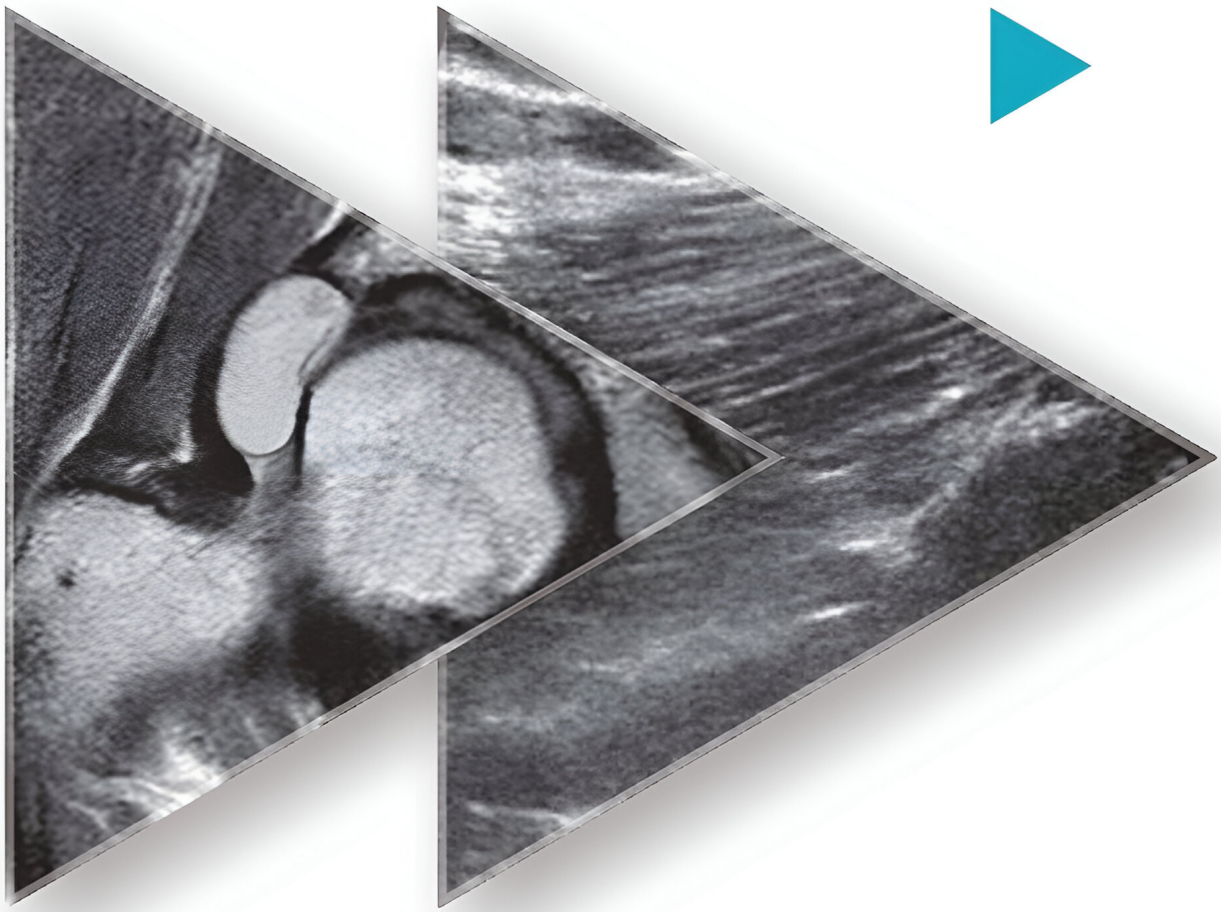

KEY FACTS

PROCEDURE

- Glenohumeral joint injection
  - Anterior (rotator interval) or posterior approach
    - Anterior approach preferable
      - Less painful & more comfortable position for patient
      - Needle tip positioned on superficial aspect of humeral head cartilage in rotator cuff interval
    - Posterior approach
      - Easier to learn & perform
      - Long-axis approach may be either from medial to lateral or from lateral to medial
- Elbow joint injection
  - Posterior or lateral approach
    - Posterior approach preferable as
      - Joint space is larger & easier to perform
      - "Bare area" can be identified for injection
    - Lateral approach is more conventional
      - But joint space is tight laterally
      - "Bare area" can be identified for injection
  - Avoid anterior approach, as there is risk of neurovascular bundle injury
- Wrist joint injection
  - Radiocarpal, distal radioulnar, & midcarpal joints
    - Always dorsal approach
    - Avoid volar approach, as there is risk of neurovascular bundle injury
    - Long axis for radiocarpal & midcarpal joint injections
    - Short axis for distal radioulnar joint injection
    - Try to avoid tendons in radiocarpal & distal radioulnar joint injection
    - Difficult to avoid transversing tendons in midcarpal injection
    - Needle tip positioned on superficial aspect of cartilage
  - Identify & avoid both superficial branch of radial nerve & terminal part of posterior interosseous nerve

Needle Placement for Joint Injection

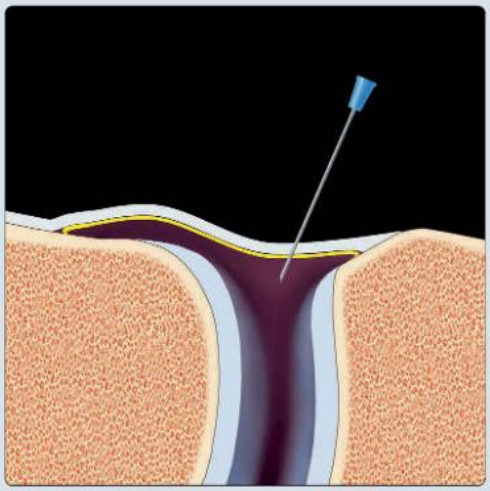

Avoid Cartilage Injury

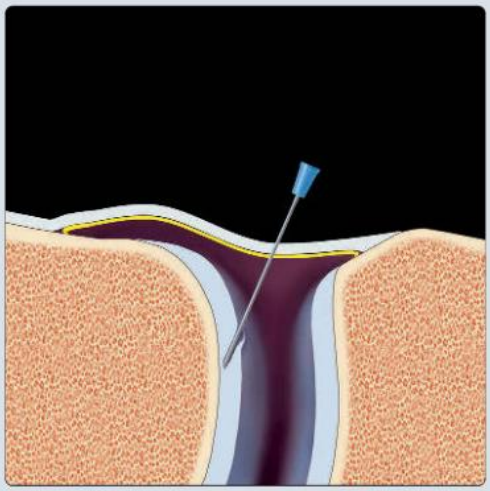

(Left) *Graphic shows the needle tip, which should just pass through the capsule and synovium into the superficial aspect of the joint. The synovium can be difficult to see clearly if the joint is not distended by fluid. Place the needle tip in the joint cavity between the opposing articular cartilage surfaces.* **(Right)** *Graphic illustrates that the needle tip should not be forced deeply into the joint, particularly if the tip is not well seen, as this may cause injury to the articular cartilage, as shown.*

Other Needle Tip Positions

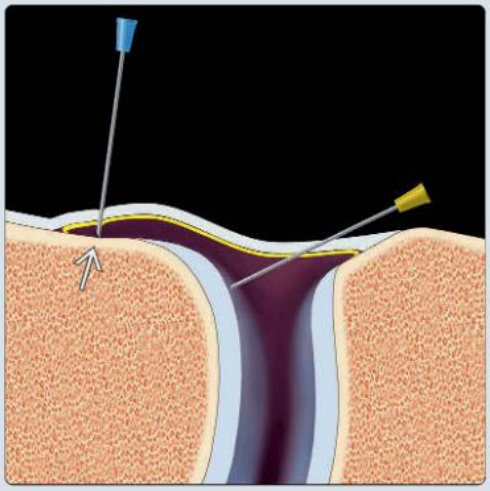

Out of Plane Approach: Practical Tips

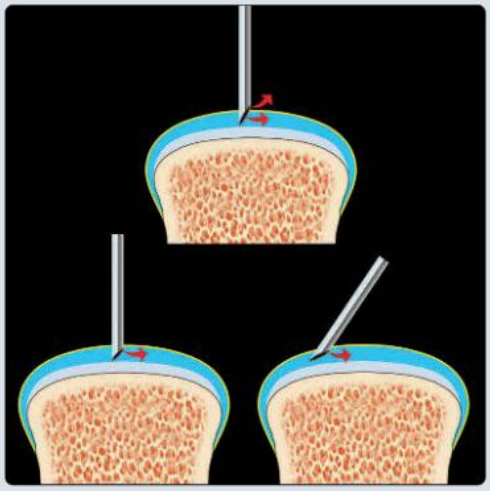

(Left) *One can place the needle tip onto the "'bare area"* ➡ *covered by synovium although it is devoid of articular cartilage (blue needle), as injection can be closely monitored. Not every joint has a "bare area," and, alternatively, place the needle tip just superficial to the articular cartilage (yellow needle).* **(Right)** *For an out-of-plane approach, and to avoid partial leakage of injectant outside the joint (upper diagram), use either a needle with a short bevel (left lower), or the needle can be aligned obliquely (right lower).*

TERMINOLOGY

Definitions

- Percutaneous joint injection for shoulder, elbow, & wrist joints under US guidance

PREPROCEDURE

Indications

- Diagnostic purpose: Injecting contrast for conventional, CT, or MR arthrography
- Therapeutic purpose: Injecting drugs (steroid, hyaluronic acid, platelet-rich plasma, etc.) to relieve pain & reduce inflammation

Contraindications

- Uncorrected bleeding diathesis
- Uncooperative patient
- Active infection in overlying soft tissues

Getting Started

- Medications
  - Local anesthetic is optional & usually not required
  - Sedation of anxious patient or young children rarely required
    - Intravenous midazolam or other benzodiazepine; antidote should be available
  - Contrast
    - Conventional or CT arthrography: Iodinated contrast, e.g., Omnipaque 300
    - MR arthrography: 0.1 mL of diluted gadolinium in 10 mL of normal saline solution
  - Steroid
    - Short (hydrocortisone) or long acting (dexamethasone, methylprednisolone)
  - Hyaluronic acid
  - Platelet-rich plasma
- Equipment list
  - Low- to high-frequency (5-12 MHz) transducers
  - Sterile set
  - Spinal needles
    - 22-g for shoulder & elbow injection
    - 25-g for wrist injection
  - Extension tube (thin, 250-mm long, 8.5-Fr, 0.4 mL of dead space, no Luer lock)
  - 3-way connector
  - Syringes for LA, aspiration, & injection

PROCEDURE

General Steps

- Use free-hand technique to advance needle into joint space under real-time imaging
- Can use long-axis (in-plane) or short-axis (out-of-plane) approaches
  - In-plane approach
    - Easier to learn & perform, as whole needle track can be well seen; longer needle path from insertion site to target
  - Out-of-plane approach
    - More difficult to learn & perform; needle tip can be seen only close to target
    - Useful when intervening structures on in-plane approach, such as nerves, need to be avoided
- Ensure on real-time imaging that needle tip is within joint space
  - Ideally, needle tip should just pass through synovium & be within superficial part of joint
    - This helps minimize injury to articular cartilage, labrum, or intracapsular ligament
  - Synovium is difficult to separate from subsynovial fat if there is no joint effusion
  - Contacting cartilage with needle tip is not harmful
    - Do not force needle tip into cartilage
  - One can often locate "bare area" between capsule & cartilage where needle tip can be positioned
  - If moderate to large effusion present, aspirate joint fluid prior to injection
- Avoid injection of air by flushing syringe & tubing with injectate
- Free flow of fluid into joint with low-pressure injection & minimal patient discomfort helps affirm intraarticular position of needle tip
- Avoid active exercise for 20 minutes following injection to prevent leakage along needle track

Shoulder (Glenohumeral Joint)

- Posterior approach
  - Various positions can be used
    - Lateral decubitus position with arm mildly adducted
    - Prone position with arm in external rotation, palm facing down, & shoulder resting on pillow
    - Sitting position with patient's back facing practitioner & ipsilateral hand resting on contralateral shoulder (be alert for vasovagal syncope)
  - Scan in transverse plane to identify glenoid, labrum, posterior glenohumeral joint, & humeral head deep to infraspinatus
    - Moving arm passively during scanning will help identify glenohumeral joint
  - Either short-axis or long-axis needle approach can be used
    - For long axis, can approach from medial to lateral or from lateral to medial
    - For medial to lateral approach, needle tip is placed deep to posterior labrum in joint cavity
    - For lateral to medial approach, needle tip is positioned on "bare area" of humeral head posteriorly
      - "Bare area" is covered by synovium but not by articular cartilage
      - Lies deep to infraspinatus muscle & tendon
      - "Bare area" lies superficially, allowing needle tip & injection to be monitored throughout procedure & avoiding injury to labrum & cartilage
- Anterior approach (rotator interval approach): Preferred method
  - Less painful, more comfortable position to patient than posterior approach
    - But technically more difficult than posterior approach, as space is smaller
  - Patient in supine position with arm partially externally rotated

  - Avoid extreme external rotation, as it increases tension on anterior shoulder & increases risk of extraarticular leakage
  - Biceps tendon runs in rotator interval between subscapularis & supraspinatus tendons
  - Identify coracoid process, which is medial to rotator interval
  - Needle entry point is just superior to subscapularis tendon, inferior to supraspinatus tendon, & lateral to coracoid process
  - Needle position should be medial to biceps tendon
  - Needle is advanced until tip just superficial to articular cartilage of humeral head
  - Either short-axis or long-axis needle approach can be used

Elbow Joint

- Lateral approach
  - More conventional, classic method & ergonomic in terms of patient positioning but more difficult & time-consuming to locate injection site
    - Potential risk to radial neurovascular bundle
    - Needle tip placed into smaller space & resistance during injection is usually high
  - Patient sits next to table with flexed elbow resting on table & lateral aspect uppermost
  - Position probe longitudinally along lateral part of elbow
    - Landmarks: Radial head & capitellum
  - Needle tip positioned on "bare area" at lateral aspect of radial head
    - "Bare area" covered by synovium but not by articular cartilage
    - "Bare area" lies just deep to lateral joint capsule, radial collateral ligament, & common extensor tendons
- Posterolateral approach: Preferred method
  - Preferred as no major neurovascular structures posterolaterally
  - Patient positioned with elbow flexed to 90° & forearm fully pronated
    - Access via trochlear-olecranon articulation
  - Position probe sagittally along posterior part of elbow
  - Move transducer laterally until triceps just goes out of view
    - Landmarks: Olecranon fossa of humerus, posterior fat pad, olecranon
  - Needle tip is positioned on "bare area" at olecranon fossa
    - "Bare area" is covered by posterior joint capsule, posterior fat pad, & synovium but not articular cartilage
- Other approaches
  - Neurovascular injury risk with anterior or medial approaches

Wrist Joint

- Radiocarpal joint
  - Dorsal approach via radioscaphoid joint space
  - Place probe in sagittal plane at level of Lister tubercle distal radius
    - Usually, area just distal to Lister tubercle is free of transversing extensor tendons
    - This area is ideal for needle insertion & avoids injury to extensor tendons
  - Enter 1 cm distal to radioscaphoid joint space
  - Direct needle proximally toward articular cartilage of distal radius
  - Once radial articular cartilage is contacted, do not advance needle tip any further
  - Avoid superficial branch of radial nerve & its terminal medial & lateral branches
    - Lie superficial to 1st extensor compartment (abductor pollicis longus, extensor pollicis brevis) or between 1st & 2nd extensor compartment (extensor carpi radialis longus & brevis) tendons
  - Avoid posterior interosseous nerve
    - Lies deep in interspace between 3rd (extensor pollicis longus) & 4th extensor compartment (extensor digitorum longus) tendons radial to Lister tubercle before it divides into terminal branches ulnarly
- Distal radioulnar joint
  - Dorsal approach
  - Place probe in transverse plane
  - Insert needle from radial side & direct toward ulnar head
  - Insert needle either between 4th (extensor digitorum longus) & 5th (extensor digiti minimi) or between 5th (extensor digiti minimi) & 6th (extensor carpi ulnaris) extensor compartments
    - Try not to transgress tendon with needle, as this is painful & may cause tendon injury
  - Once ulnar articular cartilage is contacted, do not advance needle tip any further
- Midcarpal joint
  - Dorsal approach via lunocapitate joint
  - Place probe in sagittal plane
  - Usually, traversing needle through extensor digitorum tendons cannot be avoided
- Other approaches
  - Neurovascular injury risk with volar approach

OUTCOMES

Complications

- Most feared complication(s)
  - Infection
- Immediate/periprocedural complication(s)
  - Vasovagal reaction
    - Perform procedures with patient lying down whenever possible
  - Bleeding
    - Avoid vascular injury
    - Check & amend clotting profile if abnormal
    - Use thinnest needle possible & minimalist technique in patients with bleeding diathesis
- Delayed complication(s)
  - Pain 1-2 days after steroid injection due to steroid-related microcrystalline synovitis (10%, steroid flare)
    - Will settle with simple oral analgesia
  - Flushing of skin 2-3 days after steroid injection

SELECTED REFERENCES

1. Flores DV et al: Ultrasound-guided injection and aspiration of small joints: techniques, pearls, and pitfalls. Skeletal Radiol. 53(2):195-208, 2024

Shoulder: Posterior Approach

Shoulder: Posterior Approach

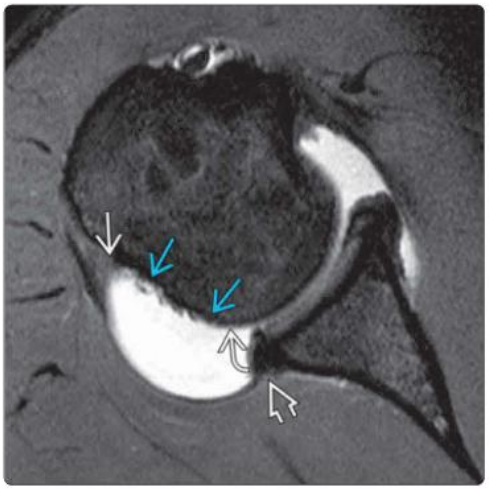

(Left) *Volume-rendered CT shows the bony anatomy of the posterior aspect of the glenohumeral joint between the glenoid ⇨ and humerus ⇨.* **(Right)** *Axial T1 FS MR shows attachment of the posterior capsule to the humeral head ⇨ and glenoid ⇨. There is a quite large "bare area" ⇨ of the humeral head not covered by articular cartilage between the posterior capsular attachment and the posterior margin of humeral head articular cartilage ⇨. The needle tip can be placed against this area.*

Shoulder: Posterior Approach

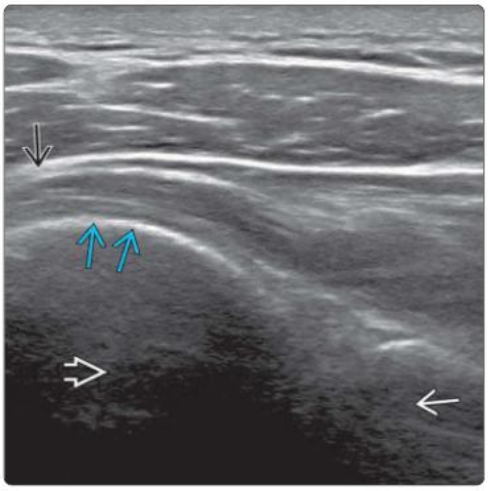

Shoulder: Posterior Approach

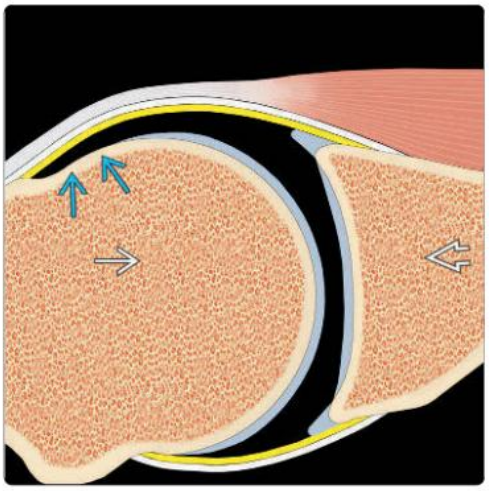

(Left) *Transverse US shows the posterior aspect of the glenohumeral joint between the glenoid ⇨ and humeral head ⇨. The needle tip can be placed against the surface of the "bare area" ⇨ deep to the infraspinatus tendon ⇨ where there is no covering cartilage. This avoids cartilage injury, allows easy monitoring of injection, and reduces procedural pain.* **(Right)** *Graphic shows posterior aspect of shoulder joint between the glenoid ⇨ and humeral head ⇨. There is no articular cartilage or labrum at the "bare area" ⇨.*

Shoulder: Posterior Approach (In Plane)

Shoulder: Posterior Approach (In Plane)

(Left) *Clinical photograph shows how to use the in-plane approach to inject the glenohumeral joint via a posterior approach. The needle is inserted at the medial end of the transducer and directed laterally, as shown.* **(Right)** *Transverse US shows the needle tip ⇨ positioned at the "bare area" of the humeral head posteriorly via an in-plane approach. The needle ⇨ can be seen from the insertion site to the target. There is injected fluid ⇨ distending the shoulder joint.*

(Left) *Clinical photograph shows how to use the out-of-plane approach to inject the shoulder joint via a posterior approach. The needle is entered at the middle of the US probe, as shown.* **(Right)** *Transverse US shows the needle tip ➡ positioned at the "bare area" ⇨ of the posterior humeral head using an out-of-plane approach. Only the tip of the needle can be seen close to the target. There is injected fluid ➡ distending the shoulder joint.*

Shoulder: Posterior Approach (Out of Plane)

Shoulder: Posterior Approach (Out of Plane)

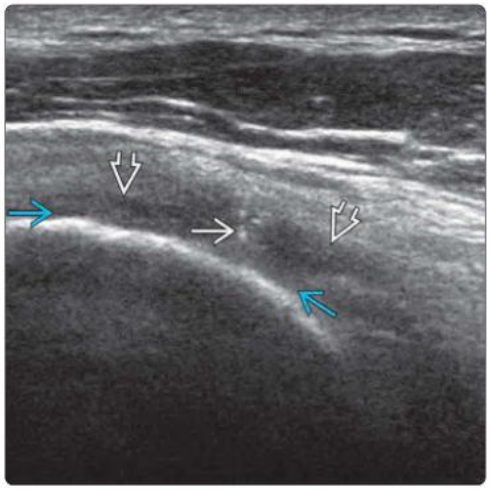

(Left) *Volume-rendered CT shows the bony anatomy of the anterior aspect of the glenohumeral joint between the glenoid ➡ and humerus ➡. The coracoid process ⇨ is also shown.* **(Right)** *Axial T1 FS MR shows the rotator interval ⇨ at the anterior aspect of the shoulder joint on the medial superior aspect of the humeral head ➡. The biceps tendon ➡ lies within the rotator interval. The coracoid process ⇨ and glenoid ➡ are shown.*

Shoulder: Anterior Approach

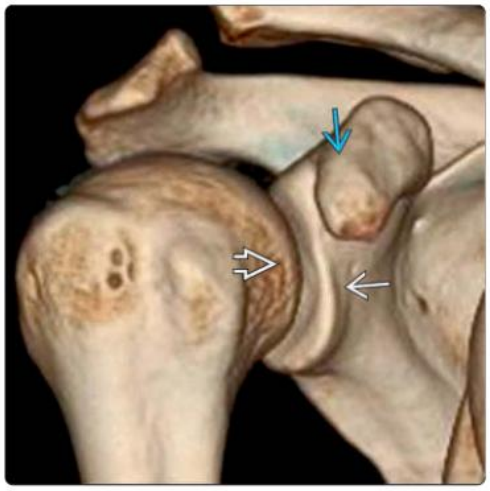

Shoulder: Anterior Approach

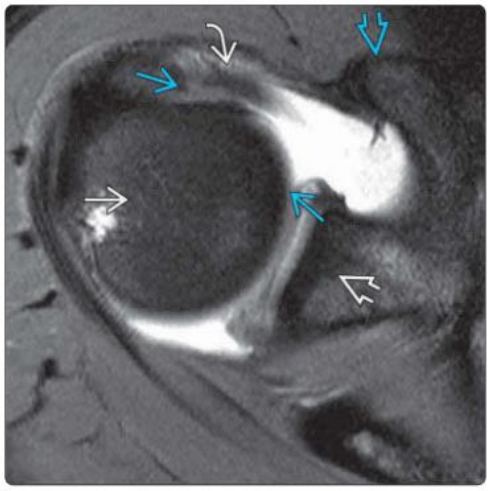

(Left) *Transverse US shows rotator interval area ⇨ at medial superior aspect of humeral head. The biceps tendon ➡ lies laterally and the glenoid ➡ medially with gas in the glenohumeral joint ⇨. Needle tip should be positioned on articular cartilage at rotator interval.* **(Right)** *Graphic shows the anterior aspect of the shoulder between the glenoid ⇨ and humeral head ⇨. The biceps tendon ➡ traverses the rotator interval. The coracoid process ⇨ and area for needle tip positioning ⇨ are shown.*

Shoulder: Anterior Approach

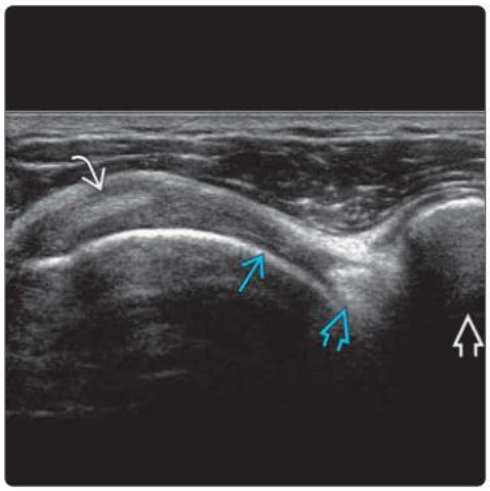

Shoulder: Anterior Approach

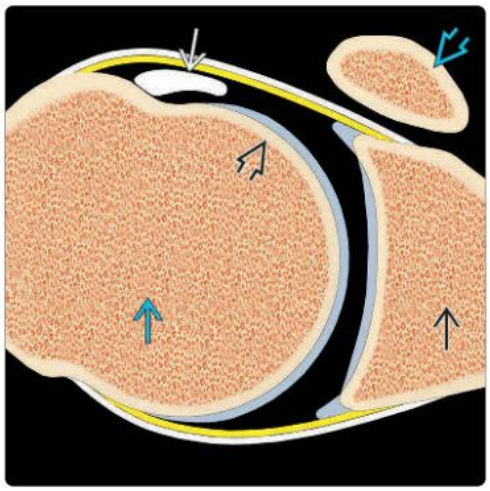

Shoulder: Anterior Approach (In Plane)

Shoulder: Anterior Approach (In Plane)

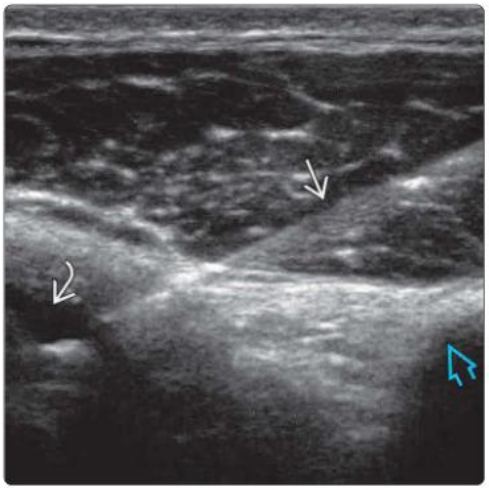

(Left) *Clinical photograph shows an in-plane approach to glenohumeral joint injection via an anterior approach. The needle is inserted at the medial aspect of the transducer and directed laterally, as shown.* **(Right)** *Transverse US shows the needle with the tip positioned at the rotator interval medial to the biceps tendon (not shown) via an in-plane approach. The needle ➡ can be seen from insertion site to target. There is injected fluid ➡ distending the shoulder joint. The needle should be lateral to coracoid process ⇨.*

Shoulder: Anterior Approach (Out of Plane)

Shoulder: Anterior Approach (Out of Plane)

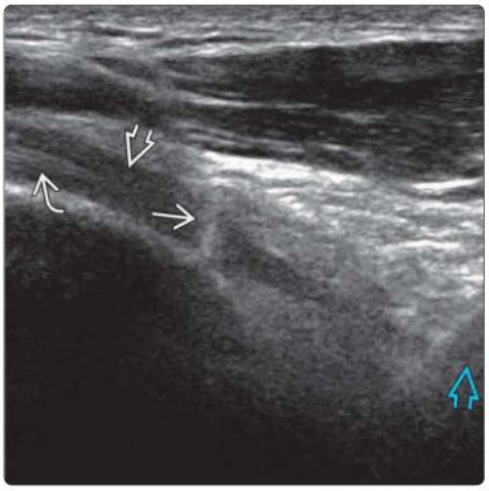

(Left) *Clinical photograph shows an out-of-plane anterior approach to the glenohumeral joint via the rotator interval. The needle is inserted at an angle near the middle of the US transducer, as shown.* **(Right)** *Transverse US shows the needle tip ➡ positioned at the rotator interval medial to the biceps tendon ➡ and lateral to the coracoid process ⇨. Only the tip of the needle can be seen within the joint. There is injected fluid ➡ distending the shoulder joint.*

Elbow: Lateral Approach

Elbow: Lateral Approach

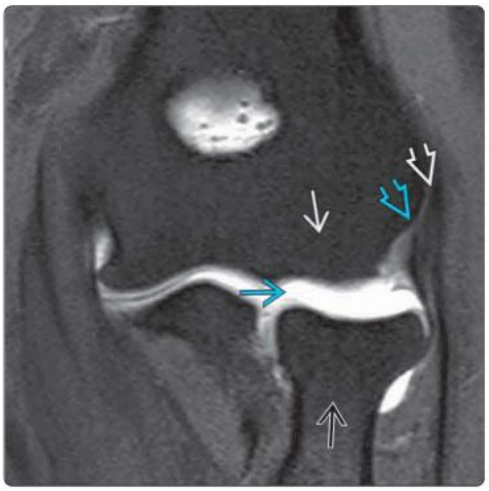

(Left) *Volume-rendered CT shows the bony anatomy at the lateral aspect of the elbow joint (radiocapitellar joint) between the radial head ➡ and the capitellum ➡.* **(Right)** *Coronal T1 FS MR shows the radiocapitellar joint ⇨ at the lateral aspect of the elbow joint between the capitellum ➡ and the radial head ⇨. The radial collateral ligament ⇨ and the common extensor tendon origin ➡ are shown.*

(Left) *Longitudinal US shows the radiocapitellar joint between the capitellum and the radial head. The common extensor tendon and radial collateral ligament lie superficial to the joint. A prominent synovial fold is shown.* **(Right)** *Graphic shows the radiocapitellar joint between the capitellum and radial head. The radial collateral ligament and common extensor tendon origin lie superficial to the joint capsule with a synovial fold more deeply. The annular ligament is also shown.*

Elbow: Lateral Approach

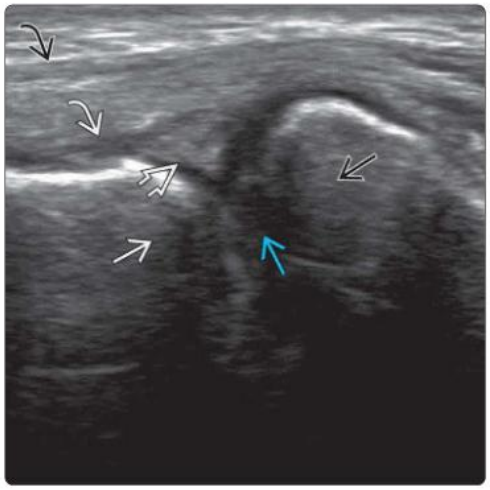

Elbow: Lateral Approach

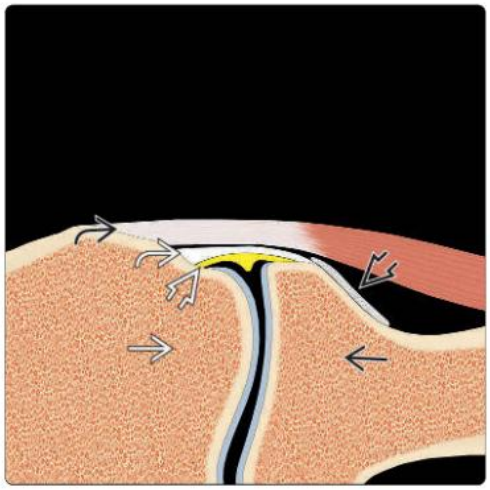

(Left) *Clinical photograph shows an in-plane lateral approach to inject the elbow joint. The needle should be inserted at the distal aspect of the transducer and directed proximally, as shown.* **(Right)** *Longitudinal US shows the needle tip positioned at the "bare area" on the lateral aspect of the radial head where there is no articular cartilage. The needle is seen from insertion site to the target. There is injected fluid distending the elbow joint and outlining a synovial fold.*

Elbow: Lateral Approach

Elbow: Lateral Approach

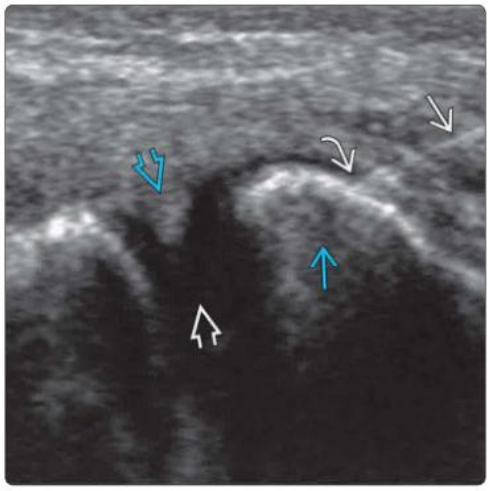

(Left) *Volume-rendered CT shows the bony anatomy of the posterior aspect of the elbow joint (ulnohumeral articulation) between the ulnar olecranon process and the distal humerus. The olecranon fossa of the distal humerus is shown.* **(Right)** *Sagittal T1 FS MR shows the posterior part of the ulnohumeral joint between the olecranon process and the distal humerus. The proximal attachment of the posterior capsule of the elbow joint lies just proximal to the olecranon fossa.*

Elbow: Posterior Approach

Elbow: Posterior Approach

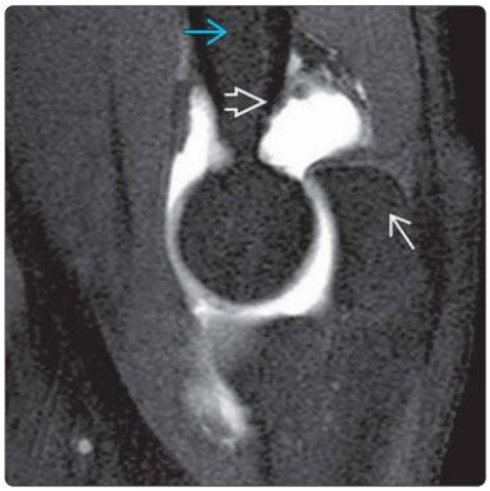

Elbow: Posterior Approach

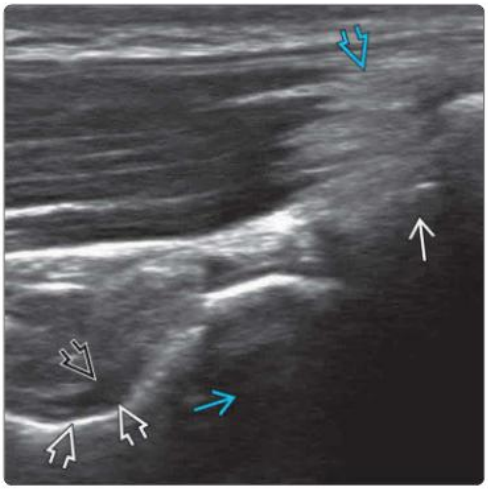

Elbow: Posterior Approach

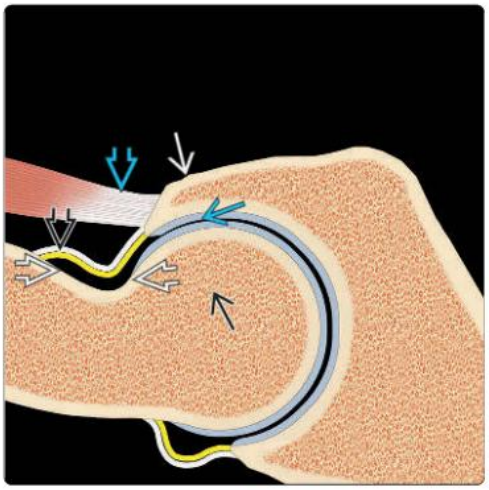

(Left) *Longitudinal US shows the ulnohumeral joint between the olecranon process ➡ and distal humerus ⇨. The olecranon fossa ➡ lies proximal to the joint and is free of cartilage but is covered by synovium. A small amount of physiologic fluid ⇨ is present. Note the triceps tendon ⇨.* **(Right)** *Graphic shows the ulnohumeral joint ⇨ between the olecranon process ➡ and distal humerus ⇨. Olecranon fossa ➡ lies proximal to the joint and is free of cartilage but is covered by synovium ⇨. Note the triceps tendon ⇨.*

Elbow: Posterior Approach

Elbow: Posterior Approach

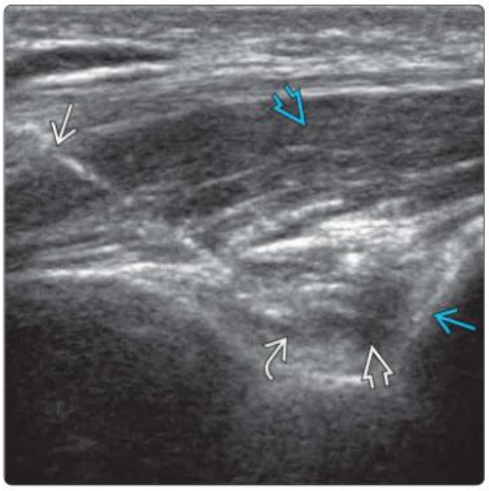

(Left) *Clinical photograph shows how to use the in-plane approach to inject the elbow joint via a posterior approach. The needle should be placed at the proximal end of the probe and directed distally.* **(Right)** *Longitudinal US shows the needle tip ➡ positioned in the olecranon fossa ⇨ where there is no overlying cartilage ("bare area") via an in-plane approach. The whole needle ➡ can be seen from insertion site to target. Injected fluid ➡ partially distends the elbow joint. The needle has transversed the triceps muscle ⇨.*

Wrist Joint: 3 Compartments

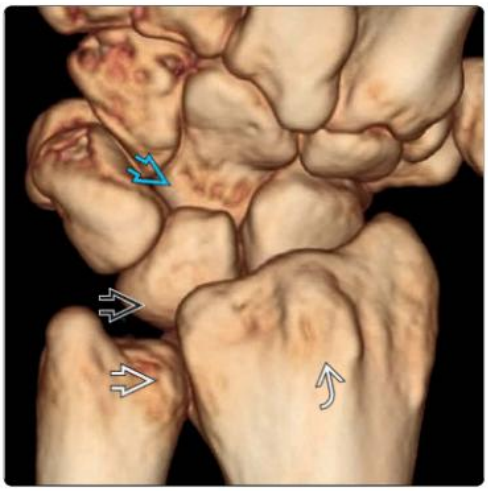

Wrist: Radioscaphoid Joint

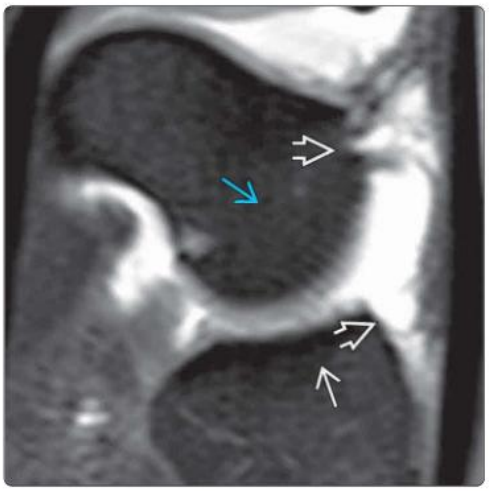

(Left) *Dorsal aspect of the wrist with 3 separate compartments is shown: Radiocarpal joint ⇨, distal radioulnar joint ➡, and midcarpal joint ⇨. Lister tubercle ➡ of the distal radius, which is an important bony landmark for injection, lies just proximal to the scaphoid.* **(Right)** *Sagittal T1 FS MR shows the dorsal aspect of the radioscaphoid joint between the distal radius ➡ and the scaphoid ⇨. The attachments of the dorsal capsule of the radiocarpal joint ➡ are shown.*

Wrist: Radiocarpal Joint

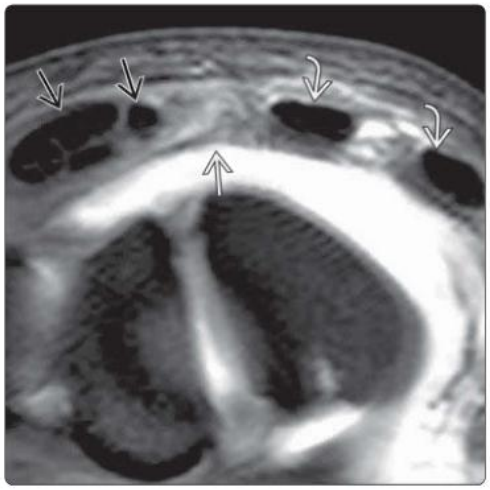

Wrist: Radiocarpal Articulation

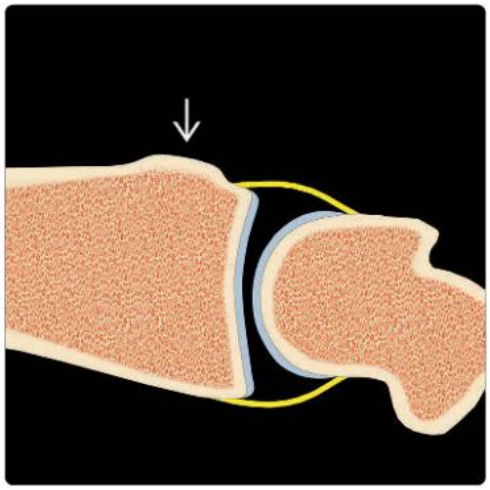

(Left) *Axial T1 FS MR shows the dorsal aspect of the wrist just distal to the radioscaphoid joint. There is no tendon transversing that area just distal to Lister tubercle of the distal radius (not shown). Extensor carpi radialis brevis and longus tendons as well as the extensor pollicis longus and extensor digitorum longus tendons are shown.* **(Right)** *Graphic shows a Lister tubercle of the distal radius. At this plane, there is usually no tendon between the skin to radiocarpal joint. As such, it represents the best place for needle insertion.*

Wrist: Radioscaphoid Joint

Wrist: Radioscaphoid Joint

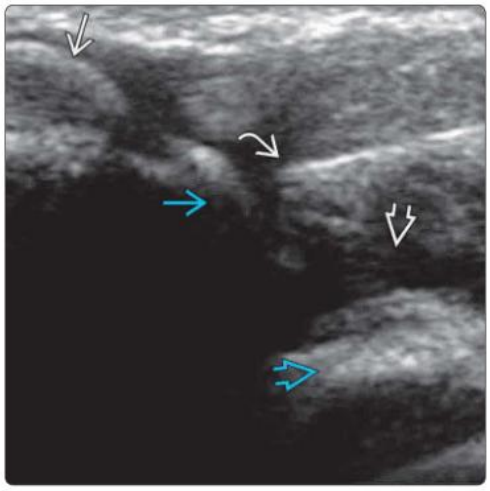

(Left) *Clinical photograph shows the in-plane dorsal approach to inject the radioscaphoid joint. Needle is inserted from the distal aspect of the transducer and directed proximally, as shown.* **(Right)** *Longitudinal US along the plane of Lister tubercle shows the needle tip positioned in the dorsal aspect of the radioscaphoid joint just distal to the radial articulating surface. The needle can be well seen from the insertion site to the joint. There is injected fluid distending the radiocarpal joint overlying the scaphoid.*

Wrist: Distal Radioulnar Joint

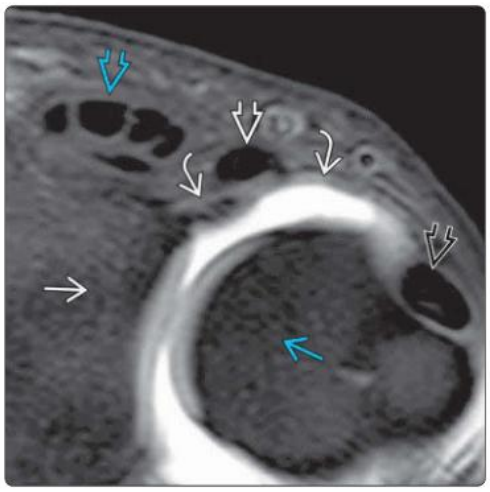

Wrist: Distal Radioulnar Joint

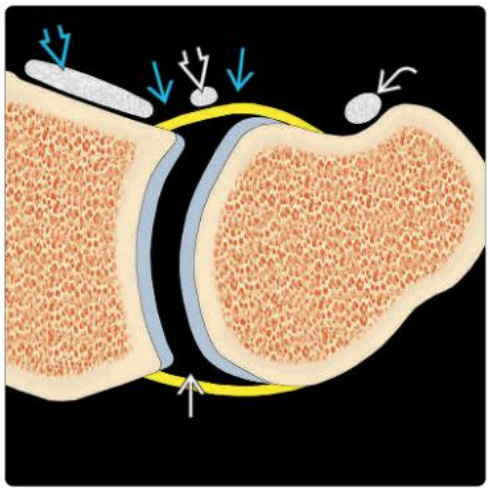

(Left) *T1 FS MR shows the dorsal aspect of the distal radioulnar joint between the distal radius and the ulnar head. The ideal needle path is on either side of the extensor digiti minimi tendon. The extensor digitorum longus and extensor carpi ulnaris tendon are also shown.* **(Right)** *Graphic shows the distal radioulnar joint and preferred paths for needle insertion on either side of the extensor digiti minimi tendon. The extensor digitorum longus and extensor carpi ulnaris tendon are shown.*

Wrist: Distal Radioulnar Articulation

Wrist: Distal Radioulnar Joint

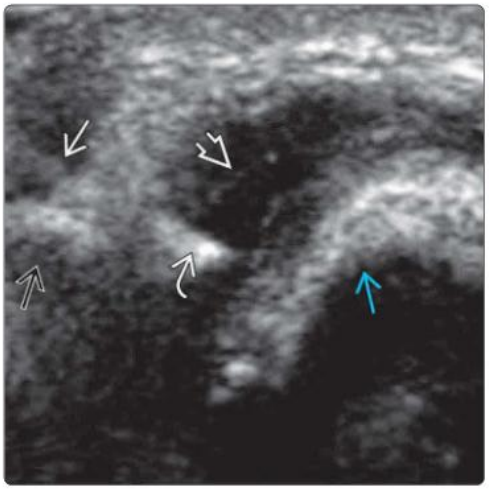

(Left) *Clinical photograph shows an in-plane dorsal approach for distal radioulnar joint injection. The needle should be inserted from the radial side of the transducer and directed in an ulnar direction, as shown.* **(Right)** *Transverse US shows the needle tip ➡ positioned on the surface of the ulnar head ⇨ just ulnar to the distal radius ⇨. The needle ➡ can be seen from the insertion site to the joint. There is injected fluid ➡ distending the distal radioulnar joint. All of the extensor tendons are avoided by using this approach.*

Wrist: Midcarpal Joint

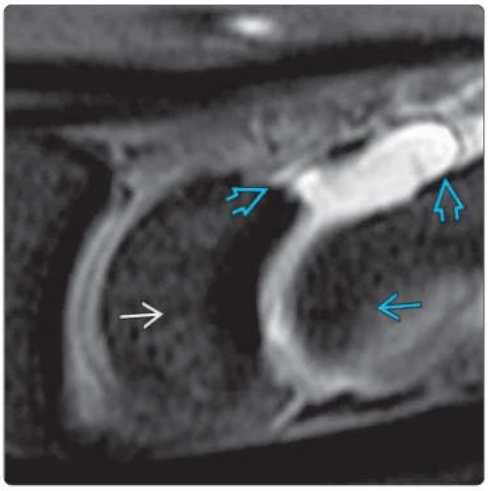

Wrist: Midcarpal Joint

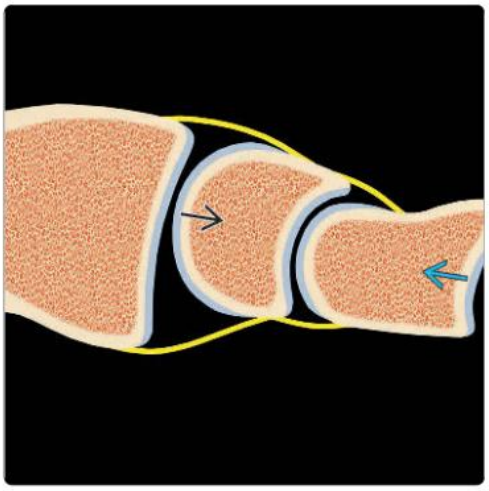

(Left) *Sagittal T1 FS MR shows the dorsal aspect of the lunocapitate joint between the lunate ➡ and the capitate ⇨. The attachments of the dorsal lunocapitate capsule ⇨ are shown.* **(Right)** *Graphic shows the lunocapitate joint for midcarpal injection between the lunate ⇨ and the capitate ⇨. The needle should be inserted dorsally.*

Wrist: Midcarpal Joint

Wrist: Midcarpal Joint

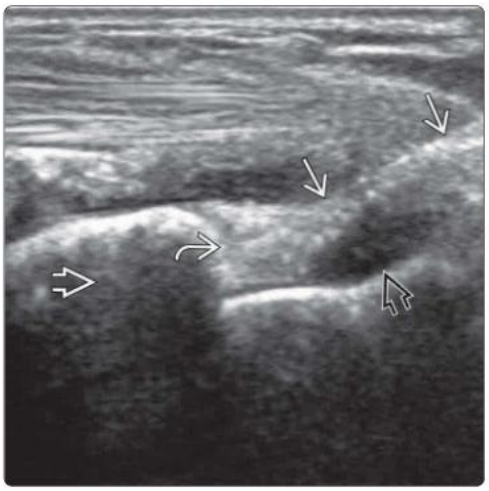

(Left) *Clinical photograph shows an in-plane dorsal approach for a midcarpal joint injection. The needle should be inserted at the distal end of the transducer and directed proximally, as shown.* **(Right)** *Longitudinal US shows the needle tip ➡ positioned at the lunocapitate joint just distal to the lunate ➡. The needle ➡ can be seen from the insertion to the joint. There is injected fluid ⇨ distending the lunocapitate joint.*

KEY FACTS

PROCEDURE

- Hip joint injection
  - Usually anterior approach
    - Longitudinal method: Preferred
      - Needle tip positioned on "bare area" at head-neck junction
    - Transverse approach
      - Needle tip positioned on femoral head cartilage surface
      - Technically more demanding
      - Risk of articular cartilage or labral injury
  - Avoid femoral vessels and nerve, which lie on anteromedial aspect of hip joint
- Knee joint injection
  - Suprapatellar approach: Preferred
    - Needle tip positioned within suprapatellar pouch
      - Can be performed longitudinally or transversely
    - Alternatively, anterolateral or anteromedial parapatellar approaches if lateral or medial patellar recesses contain more fluid than suprapatellar pouch
  - Avoid posterior approach, as risk of popliteal vessel and posterior tibial nerve injury possible
- Ankle joint injection
  - Anterolateral approach: Preferred
    - Needle tip positioned near talar dome cartilage
    - Joint space more capacious in anterolateral than anteromedial aspect of joint
    - Easier to perform, as shorter distance from skin to joint than anteromedial approach
  - Anteromedial approach
    - Needle tip positioned near talar dome cartilage
    - Longer distance from skin to joint than anterolateral approach
  - Avoid dorsalis pedis artery and deep peroneal nerve

Hip: Anterior Approach

Hip: Anterior Approach

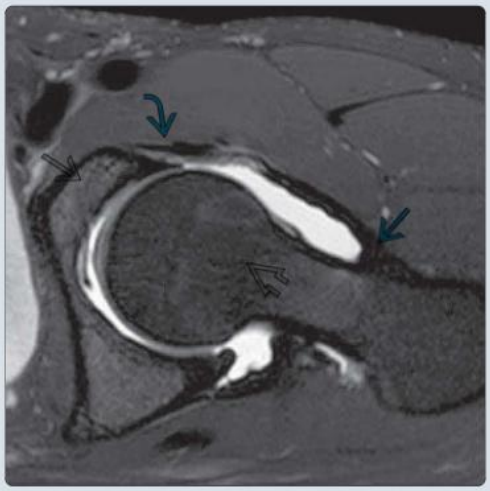

(Left) *CT volume rendering shows bony anatomy on the anterior aspect of the hip joint between the acetabulum and the femoral head.* **(Right)** *Axial T2 FS MR shows the hip joint between the acetabulum and femoral head. The attachments of the anterior capsule to the lip of the acetabulum and to the base of the femoral neck are shown.*

Hip: Anterior Approach

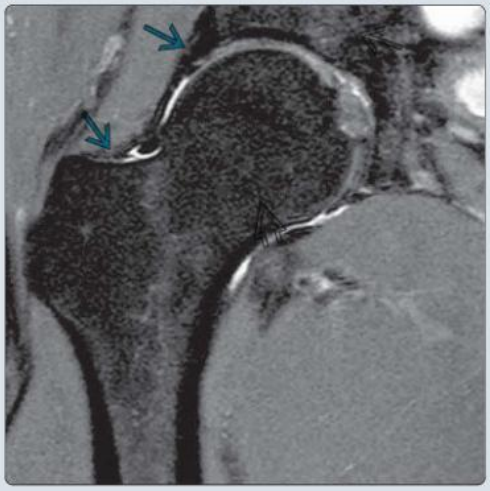

Hip: Anterior Approach

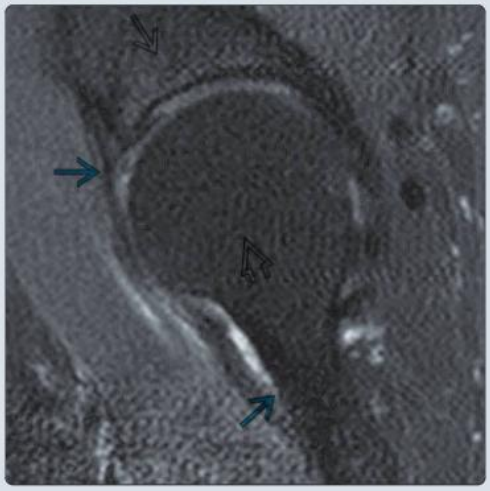

(Left) *Coronal T2 FS MR shows the hip joint between the acetabulum and femoral head. The attachments of the anterior capsule to the lip of the acetabulum and the base of the femoral neck are shown.* **(Right)** *Sagittal T2 FS MR shows the hip joint between the acetabulum and femoral head. The attachments of the anterior capsule to the lip of the acetabulum and the base of the femoral neck are shown.*

TERMINOLOGY

Definitions

- Percutaneous joint injection for hip, knee, and ankle joints under US guidance

PREPROCEDURE

Indications

- Diagnostic purpose: Injection of contrast for conventional, CT, or MR arthrography
- Therapeutic purpose: Injection of medication (steroid, hyaluronic acid, platelet-rich plasma, etc.) to relieve pain and reduce inflammation

Contraindications

- Uncorrected bleeding diathesis
- Uncooperative patient
- Active infection of overlying skin soft tissues

Getting Started

- Things to check
  - Review any previous relevant imaging
  - Time-out procedure (patient identity, type of procedure, side of procedure)
  - Signed informed consent
    - Discuss risk of infection, allergy, and bleeding
  - If patient taking anticoagulants, optimize clotting profile before procedure
    - How stringently this is applied depends on perceived difficulty in applying adequate tamponade
  - Sedation rarely required
- Medications
  - Local anesthetic is optional and usually not required
  - Sedation of anxious patient or young children
    - Intravenous midazolam or other benzodiazepine; antidote should be available
  - Contrast
    - Conventional or CT arthrography: Iodinated contrast, e.g., Omnipaque 300
    - MR arthrography: 0.1 mL of diluted gadolinium in 10 mL of normal saline solution
  - Steroid
    - Short (hydrocortisone) or long acting (dexamethasone, methylprednisolone)
    - Hyaluronic acid
    - Platelet-rich plasma
- Equipment list
  - Low- to high-frequency (5- to 12-MHz) transducers
  - Sterile set
  - Spinal needles
    - 22-g for hip, knee, and ankle injection
  - Extension tube (thin, 250 mm long, 8.5-Fr, 0.4 mL of dead space, no Luer lock)
  - 3-way connector
  - Syringes for local anesthetic, aspiration, and injection

PROCEDURE

Procedure Steps (General)

- Use free-hand technique to advance needle into joint space under real-time imaging
  - Plan approach carefully, always being mindful of intervening neurovascular structures and tendons
  - Use less preferred approaches when preferred approach is not feasible due to intervening soft tissue infection, bandaging, etc.
- Can use long-axis (in-plane) or short-axis (out-of-plane) approach
  - In-plane approach
    - Easier to learn and perform, as whole needle track can be well seen but longer needle path from insertion site to target
  - Out-of-plane approach
    - More difficult to perform, as needle tip can be seen only close to target but shorter needle path from insertion site to target
- Ensure on real-time imaging that needle tip is within joint space
  - Ideally, needle tip should just pass through synovium and be within superficial part of joint
  - Synovium may be difficult to separate from subsynovial fat if there is no joint effusion
  - Inserting needle tip too firmly into joint may damage articular cartilage
    - Position needle tip just on surface of articular cartilage
  - One can often find bare area between cartilage and capsule where needle tip can be positioned
    - Easier to monitor injection at this location
    - However, not every joint has bare area
  - If moderate to large effusion present, aspirate joint fluid prior to injection
- Avoid injection of air by first flushing syringe and tubing with injectate
- Free flow of fluid with low-pressure injection and minimal patient discomfort helps affirm intraarticular position of needle tip
- Avoid strenuous exercise to prevent leakage of solution along needle track for 20 minutes
  - Gentle movement of joint helps ensure good dispersion of contrast medium

Hip Joint

- Anterior longitudinal approach: Preferred method
  - Capsule at neck region thickened by zona orbicularis (circular fibers of capsule blending with deeper fibers of iliofemoral ligament)
  - Capsule less thick at femoral head-neck junction
  - Preferred anterior target point is bare area of femoral head-neck junction
    - Place probe longitudinal to hip joint
      - Slightly turn distal end of probe anticlockwise to align along head-neck junction
    - Bare area is covered by synovium but not articular cartilage
    - Covered more superficially by anterior joint capsule and anterior hip muscles
    - Bare area injection can be monitored by real-time US
    - Needle path avoids labrum and, therefore, minimizes risk of injury
    - Plan approach so as to avoid femoral neurovascular bundle

- Target point for femoral head is superolateral quadrant of femoral head
  - Stop needle tip at surface of articular cartilage to minimize risk of cartilage injury
- Anterior transverse approach
  - Technically more difficult than longitudinal approach
  - Insert needle at lateral aspect of hip joint
    - As entry point is more lateral, this approach carries less risk of femoral neurovascular injury
  - Orientate needle horizontally and insert medially
  - Place needle tip at surface of femoral head or acetabular cartilage
  - Important to avoid injury to labrum, which is close to needle path compared to longitudinal approach
- Other approaches
  - Lateral approach similar to anterior approach, targeting either femoral head or head-neck junction
  - Posterior approach is not advisable, as much deeper than anterior approach
    - Avoid sciatic nerve

Knee Joint

- Suprapatellar approach: Preferred method
  - Usually, small amount of physiological fluid is present aiding injection
    - Needle tip should be positioned centrally within suprapatellar pouch
  - Can use either longitudinal or transverse approach to suprapatellar pouch
  - Lateral approach to suprapatellar pouch is preferred, as there is no overlying vastus lateralis at distal thigh region
  - Medial approach may be more uncomfortable, as overlying vastus medialis muscle needs to be transgressed
- Anteromedial or anterolateral parapatellar approach
  - Preferred when these recesses contain more fluid than suprapatellar recess
  - Place needle into medial or lateral patellar recess
- Other approaches
  - Infrapatellar approach
    - Needle tip positioned on surface of femoral trochlear cartilage
    - Risk of cartilage injury

Ankle Joint

- Anterolateral approach: Preferred method
  - Skin-to-joint distance is shorter laterally than medially
  - Anterolateral approach is further from dorsalis pedis artery than anteromedial approach
    - Avoids deep peroneal nerve, which lies deep to extensor hallucis longus and lateral to dorsalis pedis artery at ankle joint
      - Tends to move more medially with ankle plantar flexion
    - Does not avoid intermediate and medial dorsal cutaneous nerves (terminal branches superficial peroneal nerve) lying between extensor digitorum tendon and lateral malleolus
  - Technically, easier to perform
  - Needle tip positioned just superficial to talar dome articular cartilage
- Anteromedial approach
  - Technically, slightly more difficult, as deeper than anterolateral approach
  - Needle tip positioned just superficial to talar dome articular cartilage
  - Saphenous nerve and long saphenous nerve between medial malleolus and tibialis anterior tendon
- Other approaches
  - Posterolateral and posteromedial approaches are technically feasible but deeper than anterior approach, and needle tip monitoring is more challenging
    - Posteromedial approach: Posterior tibial vessel and tibial nerve injury risk
    - Posterolateral approach: Sural nerve injury risk

POST PROCEDURE

Expected Outcome

- Mild discomfort from joint distension

Immediate Aftercare

- Perform arthrographic study as soon as possible
- Contrast will be largely absorbed by 30 minutes

Subsequent Aftercare

- Avoid exercise for 24 hours after corticosteroid injection
  - Maximize therapeutic effect
  - Reduce spread of steroid into surrounding tissues

OUTCOMES

Complications

- Most feared complication(s)
  - Infection
- Immediate/periprocedural complication(s)
  - Vasovagal reaction
    - Perform procedures with patient lying down whenever possible
  - Bleeding
    - Avoid vascular injury
    - Check and amend clotting if abnormal
    - Use thinnest needle possible and minimalist technique in patients with bleeding diathesis
- Delayed complication(s)
  - Pain 1-2 days after steroid injection due to steroid-related microcrystalline synovitis ("steroid flare" in 10% of cases)
    - Settle with simple oral analgesia
  - Flushing of skin 2-3 days after steroid injection
- Other complications
  - Theoretical risk of joint arthropathy with steroid injection but probably more related to intraarticular lignocaine or excessive use of steroid injection

SELECTED REFERENCES

1. Flores DV et al: Ultrasound-guided injection and aspiration of small joints: techniques, pearls, and pitfalls. Skeletal Radiol. 53(2):195-208, 2024
2. Ruiz Santiago F et al: Ultrasound guided injections in ankle and foot. J Ultrasound. 27(1):153-9, 2024
3. Albano D et al: Imaging-guided musculoskeletal interventions in the lower limb. Radiol Clin North Am. 61(2):393-404, 2023

Hip: Anterior Transverse Approach

Hip: Anterior Transverse Approach

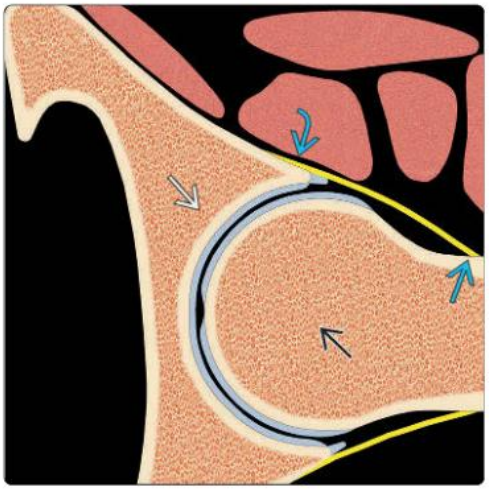

(Left) *Transverse US shows the anterior aspect of the hip joint between the acetabulum ➡ and femoral head ➡. The echogenic labrum ⇨ is shown, which should be avoided during injection. The anterior capsule ⇨ of the hip joint is shown.* **(Right)** *Graphic shows the anterior aspect of the hip joint between the acetabulum ➡ and femoral head ⇨. The attachments of the hip capsule to the lip of the acetabulum ⇨ and the base of the femoral neck ⇨ are shown.*

Hip: Anterior Transverse Approach

Hip: Anterior Transverse Approach

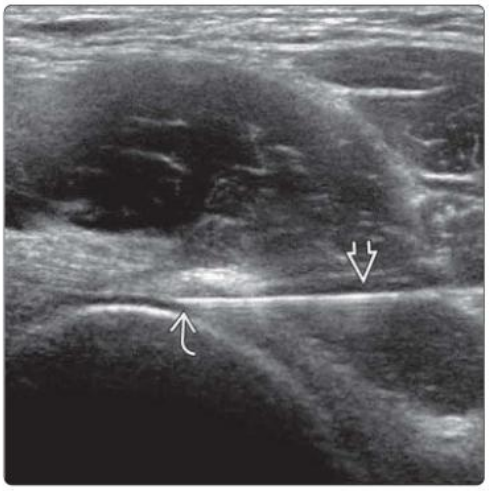

(Left) *Clinical photograph shows needle insertion for the transverse lateral approach to the hip joint. The needle is inserted from lateral to medial along the anterior margin of the hip joint.* **(Right)** *Transverse US shows injection of the hip joint via the transverse approach. The needle tip ➡ is positioned on the surface of the femoral head articular cartilage. The needle ➡ is clearly shown in this in-plane approach, as it lies almost parallel to the probe.*

Hip: Anterior Transverse Approach

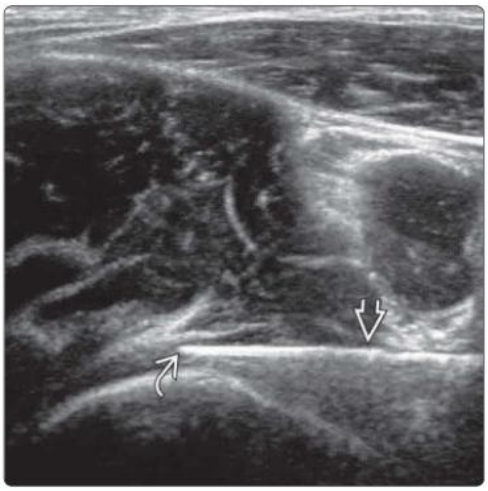

Hip: Anterior Longitudinal Approach

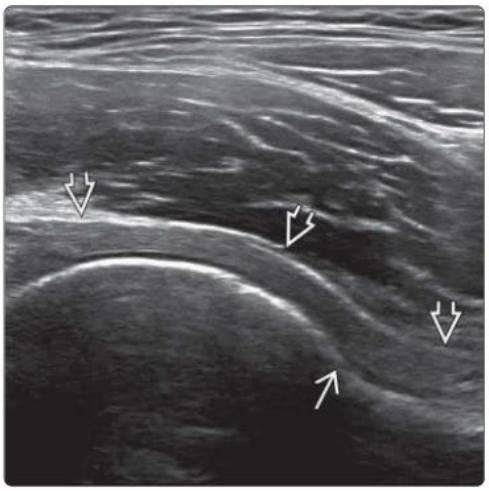

(Left) *Transverse US shows injection of the hip joint via transverse approach. The needle tip ➡ is positioned at the surface of the femoral head articular cartilage. The needle ➡ is clearly shown in the in-plane approach, as it lies almost lying parallel to the probe.* **(Right)** *Longitudinal US shows the anterior aspect of the femoral head-neck junction ➡. The anterior capsule of the hip joint ➡ is shown. The distal end of the anterior capsule is at the base of the femoral neck.*

(Left) *Graphic shows the anterior aspect of the hip joint between the acetabulum ➡ and the femoral head ⇨. The attachment ⇨ of the hip capsule is shown. Distally, the anterior capsule attaches to the base of the femoral neck.* **(Right)** *Clinical photograph shows the needle position for the anterior approach to the hip joint. The needle is inserted from distal to proximal at the anterior aspect of the hip joint.*

Hip: Anterior Longitudinal Approach

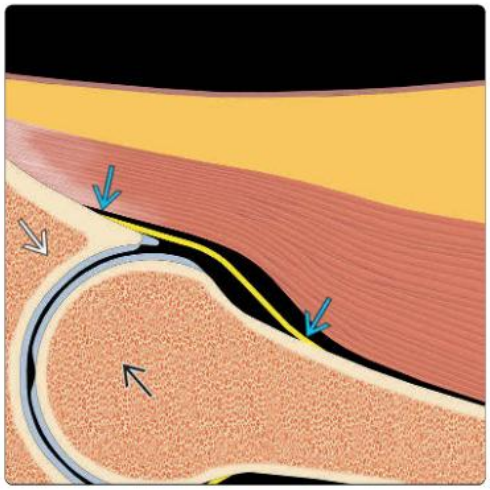

Hip: Anterior Longitudinal Approach

(Left) *Longitudinal US shows injection of the hip joint using an anterior longitudinal approach. The needle tip ➡ is positioned at the femoral head-neck junction ➡. The needle ➡ is less well seen in the anterior approach compared to the transverse approach, as it lies oblique to the US beam.* **(Right)** *Longitudinal US shows injection of the hip joint using an anterior longitudinal approach. The needle tip ➡ is positioned on the femoral head articular cartilage ➡. The needle ➡ is well shown on this in-plane approach.*

Hip: Anterior Longitudinal Approach

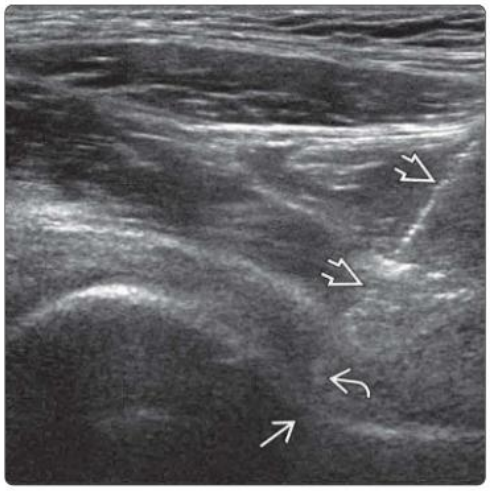

Hip: Anterior Longitudinal Approach

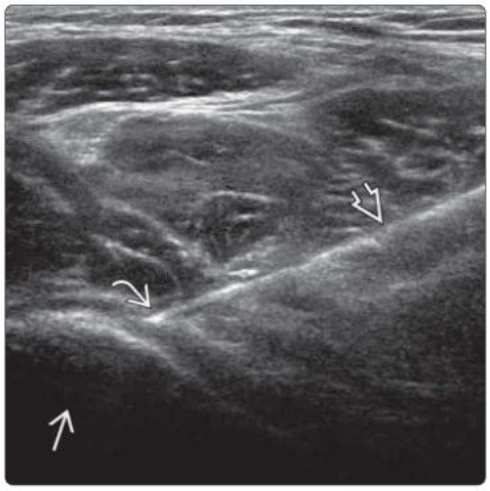

(Left) *Volume-rendered CT shows the bony anatomy of the anterior aspect of the knee joint between the distal femur ➡ and proximal tibia ⇨. The patella ⇨ is also shown.* **(Right)** *Sagittal T2 FS MR shows the knee joint between the distal femur ➡ and the proximal tibia ➡. The suprapatellar pouch ⇨ of the knee joint is shown proximal to the patella ➡.*

Knee: Anterior Suprapatellar Approach

Knee: Anterior Suprapatellar Approach

Knee: Anterior Suprapatellar Approach

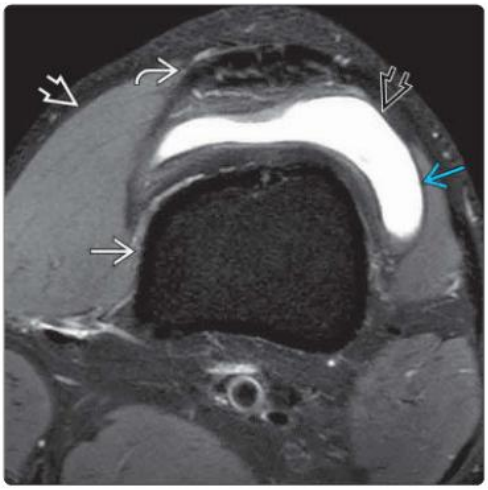

Knee: Anterior Suprapatellar Approach

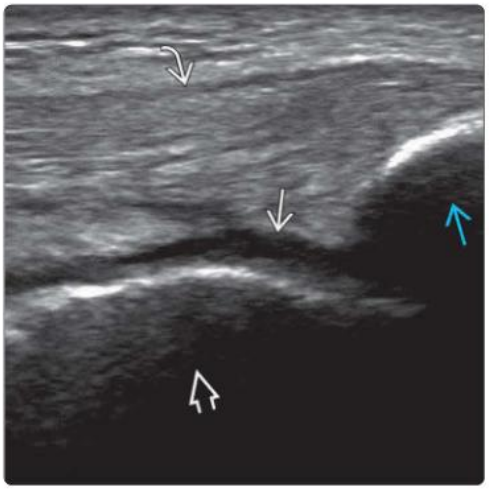

(Left) *Axial T2 FS MR shows the suprapatellar pouch of the knee joint anterior to the distal femur and posterior to the quadriceps tendon. Needle is preferentially inserted anterolaterally, as there is no intervening vastus lateralis muscle. Anteromedially, the vastus medialis muscle covers the suprapatellar pouch.* **(Right)** *Longitudinal US shows a minimally distended suprapatellar pouch posterior to quadriceps tendon, anterior to distal femur, and proximal to the patella.*

Knee: Anterior Suprapatellar Approach

Knee: Anterior Suprapatellar Approach

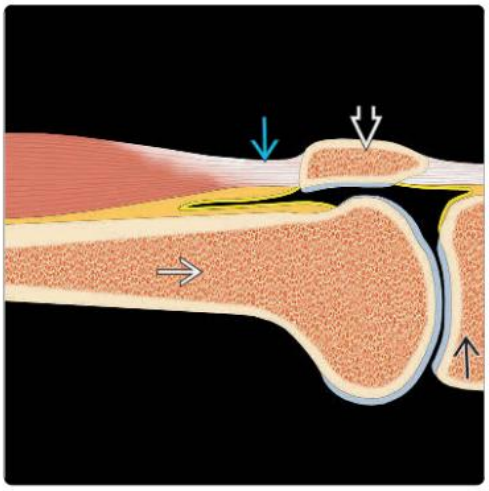

(Left) *Transverse US shows the suprapatellar pouch posterior to the quadriceps tendon and anterior to the distal femur.* **(Right)** *Graphic shows the anterior aspect of the knee joint between the distal femur, patella, and proximal tibia. The suprapatellar pouch lies proximal to the patella and posterior to the quadriceps tendon.*

Knee: Anterior Suprapatellar (Longitudinal)

Knee: Anterior Suprapatellar (Transverse)

(Left) *Clinical photograph shows the approach for an anterolateral injection of the suprapatellar pouch. The needle is inserted from distal to proximal via the anterolateral aspect of the suprapatellar pouch, as there is no overlying vastus lateralis muscle along this path.* **(Right)** *Clinical photograph shows the approach for a transverse injection of the suprapatellar pouch. Needle is inserted from lateral to medial via the anterolateral aspect of suprapatellar pouch, as there is no overlying vastus lateralis muscle along this path.*

Knee: Anterior Suprapatellar Approach

Knee: Anterior Suprapatellar Approach

(Left) *Longitudinal US shows injection of the knee joint via an anterolateral approach to the suprapatellar pouch. The needle tip is positioned within the distended suprapatellar pouch. The needle path is clearly seen on this in-plane approach.* **(Right)** *Longitudinal US of same patient after aspiration of joint fluid and during injection of steroid shows the echogenic appearance of steroid injectate.*

Ankle: Anterior Approach

Ankle: Anterior Approach

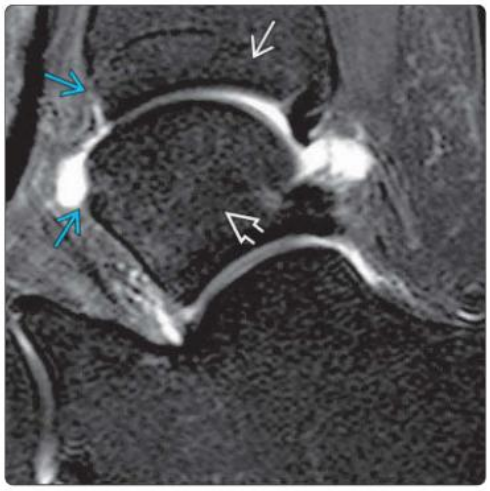

(Left) *Volume-rendered CT shows the bony anatomy of the anterior aspect of the ankle joint between the distal tibia, distal fibula, and talar dome.* **(Right)** *Sagittal T2 FS MR shows the ankle joint between the distal tibia and talar dome. The attachment of the anterior capsule of the ankle joint is shown.*

Ankle: Anterior Approach

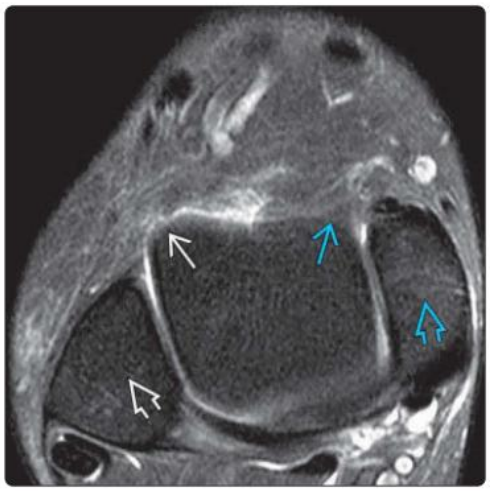

Ankle: Anterior Approach

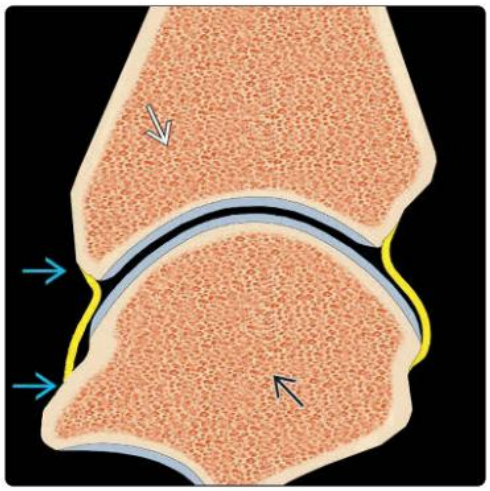

(Left) *Axial T2 FS MR shows the ankle joint just below the joint line. The anterolateral aspect of the ankle joint is closer to the skin than the anteromedial aspect. The lateral and medial malleoli are shown.* **(Right)** *Graphic shows the anterior aspect of the ankle joint between the distal tibia and talar dome. The attachment of the ankle capsule anteriorly is shown.*

Ankle: Anterior Approach

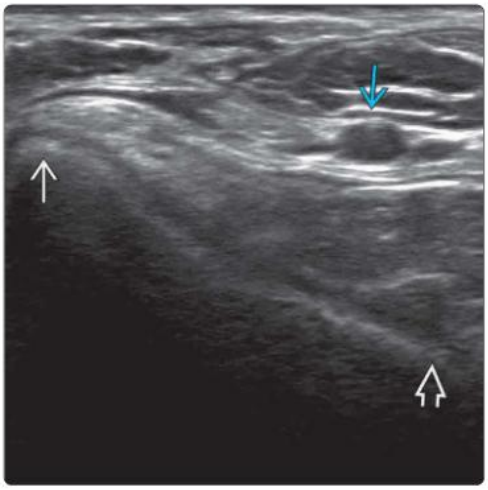

Ankle: Anterior Approach

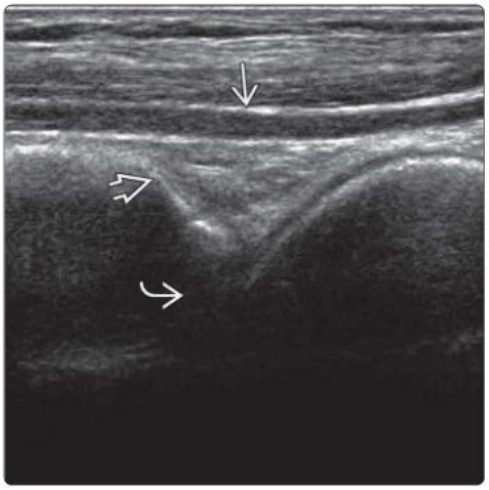

(Left) *Transverse US shows how the anterolateral aspect of the ankle joint/talar dome ➡ is closer to the probe than the anteromedial aspect ➡. Anterolateral approach is thus preferred, avoiding injury to the dorsalis pedis artery ⇨ and the adjacent deep peroneal nerve (not shown).* **(Right)** *Longitudinal US shows the dorsalis pedis artery ➡ anterior to the ankle joint ➡. This, as well as the adjacent deep peroneal nerve (not shown), must be avoided during needle insertion. Note anterior fat pad ➡ of the ankle joint.*

Ankle: Anterolateral Approach

Ankle: Anteromedial Approach

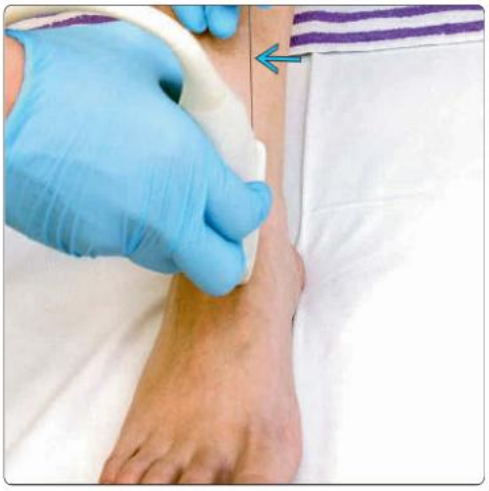

(Left) *Clinical photograph shows needle ⇨ being inserted from proximal to distal at the anterolateral aspect of the ankle joint. The anterolateral aspect of the ankle joint is closer to the skin. This approach is lateral to the dorsalis pedis artery and deep peroneal nerve.* **(Right)** *Clinical photograph shows the needle ⇨ being inserted from proximal to distal at the anteromedial aspect of the ankle joint. This approach is medial to the dorsalis pedis artery and deep peroneal nerve.*

Ankle: Anterolateral Approach

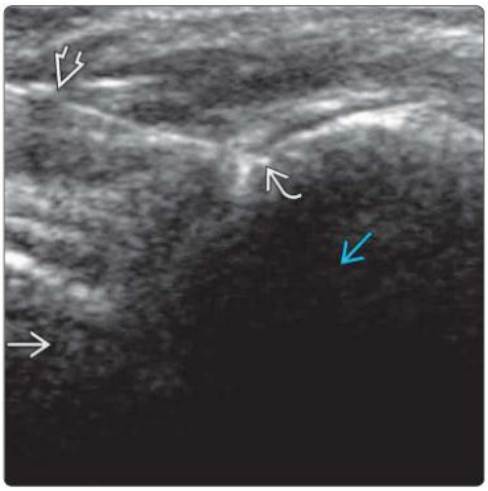

Ankle: Anterolateral Approach

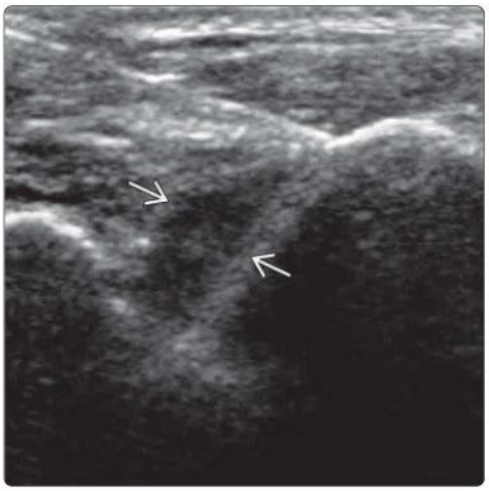

(Left) *Longitudinal US shows injection of the ankle joint via anterolateral approach between the distal tibia ➡ and talar dome ⇨. The needle tip ➡ is positioned on the surface of the talar dome articular cartilage. The needle path ➡ can be clearly seen in this in-plane approach.* **(Right)** *Longitudinal US of the same patient shows good distension of the anterior ankle joint by fluid ➡ after injection of dilute gadolinium saline mixture.*

KEY FACTS

PREPROCEDURE

- Indication
  - Glenohumeral joint aspiration or injection
  - Subacromial-subdeltoid (SA-SD) bursal injection or aspiration
  - Calcific tendinitis
  - Rotator cuff tendinosis or tear
  - Acromioclavicular joint injection
  - Paralabral cyst aspiration
  - Biceps tendon sheath injection
- Short- or long-acting anesthetic for intraarticular injection: 1-2% lignocaine or 0.25-0.5% bupivacaine
- Long-acting steroid (methylprednisolone, dexamethasone)

PROCEDURE

- Glenohumeral joint aspiration or injection
  - Aspiration for infection or crystal analysis
  - Injection for arthrography, osteoarthritis, inflammatory arthropathy, or adhesive capsulitis
- SA-SD bursal injection or aspiration
  - Steroid & long-acting local anesthetic (LA) to SA-SD bursa
- Calcific tendinitis
  - Dry needling & aspiration
  - Percutaneous lavage & aspiration of calcific deposits
  - Steroid & long-acting LA injected to bursa
- Rotator cuff tendinosis or tear
  - Localized dry needling of tendinosis or tear (to promote healing)
  - Platelet-rich plasma (PRP) injection of rotator cuff partial tear (to promote healing)
- Acromioclavicular joint arthropathy
  - Steroid & LA injection into joint
- Paralabral cyst aspiration-injection
  - ± following hyaluronidase injection
  - Steroid-LA injection ± fenestration
- Biceps tendon sheath procedure
  - In-plane injection of steroid-LA, lateral → medial approach

Glenohumeral Joint Injection via Posterior Approach

Glenohumeral Joint Injection via Posterior Approach

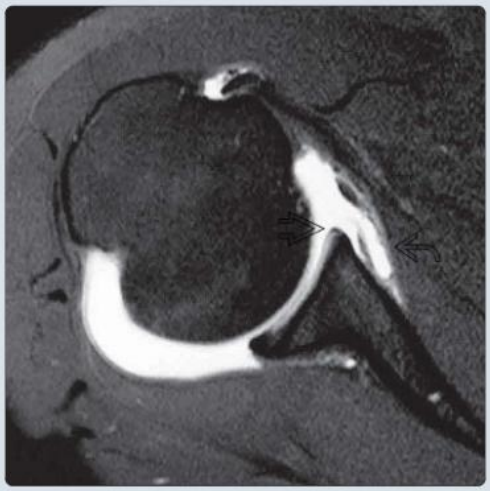

(Left) *Clinical photograph of a patient with shoulder dislocation shows needle (22-g spinal) ⇨ position for lateral long-axis approach to posterior glenohumeral joint recess for contrast injection before MR arthrography.* **(Right)** *Axial T1 FS MR arthrogram in the same patient shows glenohumeral joint distension. Note anterior capsular stripping ⇨ and labral avulsion ⇨. US-guided MR arthrography is a commonly performed procedure.*

Lavage and Aspiration for Calcific Tendinitis by Single-Needle Technique

Lavage and Aspiration for Calcific Tendinitis by Single-Needle Technique

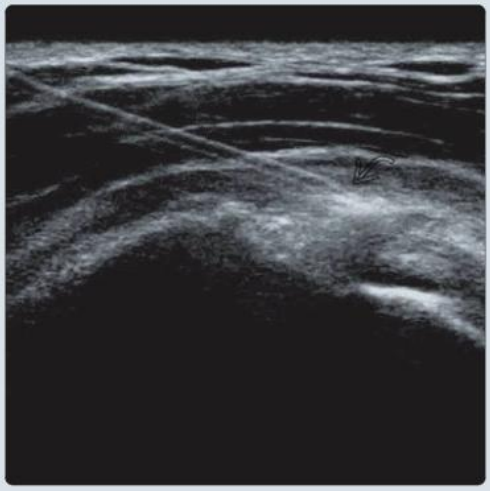

(Left) *Longitudinal US shows moderate-severity calcific tendinitis of the supraspinatus tendon ⇨. The largest calcification ⇨, calcification with the most focal edema, or calcification that most closely correlates with symptoms are best targeted for percutaneous lavage and aspiration.* **(Right)** *Longitudinal US shows aspiration of calcific content ⇨ using an 18-g needle connected to a syringe containing a saline-lignocaine mixture. Lavage and aspiration are performed in series.*

PREPROCEDURE

Indications

- **Glenohumeral joint injection or aspiration**
  - MR or CT arthrography
  - Medication for control of inflammation or pain relief in osteoarthritis, inflammatory arthropathy, or adhesive capsulitis
  - Diagnosis of septic arthritis or crystal arthropathy
- **Subacromial-subdeltoid (SA-SD) bursa hydrodissection & injection**
  - For control of inflammation, disrupt adhesions & symptom relief
- **Calcific tendinopathy therapy/Barbotage procedure**
  - For control of inflammation, symptom relief, & to promote resorption of calcific deposits
- **Rotator cuff tendinosis or partial tear treatment**
  - For control of symptoms & to promote tissue repair
- **Acromioclavicular (AC) joint injection**
  - For control of inflammation & symptom relief
- **Paralabral cyst aspiration-injection**
  - For pain control & cyst decompression
- **Biceps tendon sheath procedure**
  - For control of inflammation & symptom relief

Contraindications

- Local site infection
- Uncorrected severe bleeding diathesis
- Steroids can potentially exacerbate poor diabetic control

Getting Started

- Things to check
  - Patient identity, type of procedure, side of procedure, informed written consent
  - Discuss risk of infection, allergy, bleeding
    - Risk of bursitis when bursa is traversed for treatment of rotator cuff tendinopathy/calcific tendinopathy
  - Sedation is rarely required
- Medications
  - Anesthetic
    - Short-acting local anesthetic (LA) 1-3 mL 1% lignocaine for skin & around fascia
    - Short- or long-acting anesthetic for intraarticular injection: 1-2% lignocaine or 0.25-0.5% bupivacaine
    - Lignocaine & other -caines have dose-dependent low risk of chondral injury
      - When used in much higher doses than those commonly used
      - Negative synergistic effect with steroids
      - Aim for lowest intraarticular LA dose, such as 0.25% bupivacaine
      - Ropivacaine 0.5% is possibly least chondrotoxic but is expensive
  - Steroid
    - Usually long-acting steroid (methylprednisolone, dexamethasone)
  - Contrast
    - CT arthrography: Iodinated contrast, e.g., Omnipaque 300 ± 0.1 mL of 1:1,000 epinephrine
    - MR arthrography: Diluted 0.1 mL gadolinium in 10 mL normal saline solution
- Equipment list
  - Sterile set, sterile specimen bottles
  - Spinal needles
    - 18- to 22-g intravenous or spinal needle
    - Needle size depends on consistency of fluid injected or aspirated
  - Extension tube (thin, 250 mm long, 8.5 Fr, 0.4 mL dead space) & 3-way connector
  - Syringes for LA, aspiration, & injection

PROCEDURE

Procedure Steps

- General preparation for percutaneous intervention
  - Sterile technique (operator, probe, patient)
    - LA to skin at puncture site & around fascia
- **Glenohumeral joint injection or aspiration**
  - Practical points irrespective of anterior (rotator cuff interval) or posterior approach
    - Use free-hand technique to advance needle into joint recess under real-time imaging
      - 18- to 22-g spinal needle for injection or aspiration; larger needle for aspiration of viscous fluid
    - Can use long-axis or short-axis approaches
    - Ensure needle tip is within joint space/recess
      - Aspirate joint fluid prior to injection if moderate to large effusion present
    - Avoid injection of air bubbles by first flushing syringe & tubing with injectate
    - Free flow of fluid with low-pressure injection & minimal patient discomfort helps confirm correct intraarticular needle tip position
    - Avoid active exercise to prevent leakage of solution along needle track for 20 minutes
  - Posterior approach
    - Various positions can be used
      - Lateral decubitus position; arm mildly adducted
      - Prone position with arm in external rotation, palm facing down, & shoulder resting on pillow
      - Sitting position with back toward practitioner, ipsilateral hand resting on contralateral shoulder (best avoided for risk of vasovagal syncope)
    - In longitudinal plane, identify posterior glenohumeral joint, glenoid, labrum, & humeral head deep to infraspinatus musculotendinous junction
      - Slight passive rotation of arm while scanning will help identify glenohumeral joint
    - Either short- or long-axis needle approach can be used
    - Short-axis approach allows joint to be approached more vertically than with long-axis approach
    - Long axis is preferable as needle path easier to see
      - Approaching from lateral side allows direction of needle tip deep to posterior labrum
      - Lateral approach goes through infraspinatus tendon & therefore may be slightly more painful
    - "Pop" felt when needle transverses joint capsule
  - Rotator interval approach
    - Supine position; arm partially externally rotated
      - Avoid extreme external rotation as it increases tension on shoulder & risk of extraarticular leakage

  - Identify coracoid process & adjacent superomedial aspect of humeral head with probe aligned transverse to joint line
  - Needle entry point is just superior to subscapularis tendon & lateral to coracoid process
    - Needle is advanced until tip contacts articular cartilage of humeral head
- **Arthrography**
  - 10-20 mL of contrast solution is injected until joint capsule is well distended
  - Volume of injection is determined by patient's comfort level & resistance to injection
  - Patients with severe adhesive capsulitis feel distension after only small volume (5-10 mL) injected
  - Patients following shoulder dislocation can accommodate larger volumes (15-20 mL)
- **Adhesive capsulitis treatment**
  - To reduce inflammation & relieve pain
    - 10 mL 0.25-0.5% bupivacaine mixed with 1-2 mL 40 mg/mL methylprednisolone
    - Benefit of single bupivacaine injection outweighs theoretical risk of chondrolysis
      - Sodium hyaluronate mixed with anesthetic is alternative if steroids contraindicated
    - Good symptom control with steroid injection, especially of predominant inflammatory, rather than fibrotic, adhesive capsulitis
    - Inflammatory vs. fibrotic component of adhesive capsulitis can be evaluated on MR
      - Benefit from steroid likely to be greater during inflammatory phase
  - Hydrodilatation for capsular distension
    - Potentially more useful in patients with greater fibrotic as opposed to inflammatory component
    - 18-g spinal needle, posterior lateral → medial approach
    - Large volume of saline mixed with 5 mL 0.25% or 0.5% bupivacaine & 1-2 mL 40 mg/mL methylprednisolone/triamcinolone
      - Usually 30-40 mL saline mixture is required for optimal distension/capsular rupture
    - Capsular preservation better patient pain & function outcome than with capsular rupture
      - Stop injection when high level of resistance is felt
      - Sudden loss of resistance indicates capsular rupture
- **SA-SD bursa injection**
  - Approach differs depending on quantity & location of bursal fluid
    - Lateral approach (most popular)
      - Probe positioned parallel to long axis of supraspinatus tendon, needle insertion lateral → medial
    - Anterior approach
      - Probe positioned in sagittal plane in front of shoulder with needle inserted anterior → posterior
  - Steroid injection
    - Bevel of needle faces upward with tip of needle contacting supraspinatus tendon
    - 40mg/mL methylprednisolone or triamcinolone mixed with 8 mL 0.25% or 0.5% bupivacaine
      - Injected fluid disperses real-time within bursa
      - Injectate should flow freely away from needle
      - Localized accumulation within bursa usually indicates bursal adhesions
  - Good short-term symptom relief after steroid injection
- **Calcific tendinitis therapy**
  - Only painful calcific tendinitis should be treated
  - Preliminary US examination to assess size & distribution of calcific deposits
  - Calcifications best targeted
    - Large deposits, symptomatic calcifications, & deposits with most focal edema
  - Position patient so that calcification is well seen & amenable to needle placement
    - Usually supine or lateral decubitus positions
  - Single-needle or double-needle technique
    - 21- to 23-g needle for LA & 18- to 22-g needle for lavage & aspiration of calcium
    - Inject LA (3-5 mL 1% lignocaine) into subcutaneous tissue, SA-SD bursa, & around tendon calcification
    - Avoid introducing air during infiltration of local anesthesia as this will obscure calcification
  - Single-needle technique
    - Introduce lavage needle to center of calcium deposit
      - Needle is connected to syringe containing 5-10 mL sterile saline (70%) & lignocaine 1% (30%)
      - Gentle rotational to-&-fro movement to grind calcification, followed by injection & aspiration
      - Fluid-filled hypoechoic cavity is seen within calcification, expanding when fluid is pushed forward, reducing when pressure is released
      - Calcium is dissolved & cloudy whitish fluid will decompress into syringe when plunger released
      - Repeated short series of press & release
      - Syringe exchange is necessary to keep solution clear during procedure
      - Stop lavage when no more calcium can be retrieved
  - Double-needle technique
    - 2 needles are inserted into calcification
    - Needle tips are positioned very close to each other; not more than 2-3 mm apart
    - Both needles should be inserted along same coronal plane so that both needles & calcification can be seen simultaneously
      - 1st needle tip slightly deeper than 2nd with both needles angulated 25-30°
    - Bevels of needles face each other
      - Bevel of 1st needle faces upward & bevel of 2nd needle faces downward
    - Undertake gentle rotational to-&-fro movement to grind calcification
    - Inject 5-10 mL of sterile saline (70%) & 1% lignocaine (30%) into calcium via one of needles
    - Dissolved calcium content is drained from other (free) needle
    - Syringe exchange is necessary to keep solution clear during procedure
    - Stop lavage when no more calcium can be retrieved
  - Reposition needle to SA-SD bursa after lavage with either technique
    - Inject 1-2 mL of 40 mg/mL methylprednisolone or triamcinolone with 5 mL 0.25% or 0.5% bupivacaine

        - Helps to treat & prevent painful crystal-induced bursitis
    - Clinical success rate is 60-75%
    - Caution patient regarding risk of calcific bursitis after calcific tendinitis therapy, which can be very painful
- **Rotator cuff tendinosis or partial tear therapy**
    - Reduce bursal inflammation
        - Steroid (40 mg methylprednisolone) & LA (5 mL 0.5% bupivacaine) injection to SA-SD bursa
    - Promote healing
        - Localized dry needling of tendinosis or tear
            - 23-g intravenous needle repeatedly moved to-&-fro within tendinosis area
            - Converts area of quiescent tendinosis or tear into injured, functionally stable area
            - Resultant bleeding leads to deposition of blood cells (stem cells) within tendon or tendon tear
            - Reparative response leads to recruitment of reparative growth factors
        - Platelet-rich plasma (PRP) injection
            - Benefit over dry needling not convincingly shown
            - Inject 5 mL PRP concentrate within tendon tear
            - PRP is source of circulating mesenchymal stem cells & reparative growth factors
            - Patient counseled about post PRP pain & advised to rest affected arm for 5 days
            - Active rehabilitation starts 1 week after procedure
- **AC joint injection**
    - For symptomatic relief in AC joint arthropathy
    - Patient in supine position
    - Probe placed sagittally over superior aspect of AC joint
        - Transverse image of AC joint
        - Needle inserted long axis anterior → posterior
    - Probe placed transversely over superior aspect AC joint
        - Short-axis approach from anterior → posterior
        - Anterior approach best as anterior part of joint wider
    - 23-g needle inserted into AC joint deep to superior AC ligament
        - Inject 1 mL 0.25-0.5% bupivacaine & 1 mL 40 mg/mL methylprednisolone
        - Widening of joint space seen during injection
- **Paralabral cyst aspiration-injection**
    - Usually located near suprascapular & spinoglenoid notches
    - Approach depends on cyst location
    - Large-bore (16-g) needle for aspiration ± cavity lavage
        - Aspiration unsuccessful due to viscous cyst content in 50% of cases
            - ± inject hyaluronidase (150U) & reaspirate after 5-20 minutes
            - Cyst wall fenestration still improves symptoms if aspiration unsuccessful
    - Fenestration & steroid-long acting LA injection following cyst aspiration
- **Biceps tendon sheath procedure**
    - Tendon sheath long head biceps brachii targeted in bicipital groove
    - In-plane injection of steroid-LA into tendon sheath
    - Lateral to medial approach, use color Doppler to detect anterior circumflex humeral artery lateral to tendon
    - Limit volume of injectate to < 5 mL to minimize intraarticular flow
        - Doughnut sign signifies successful intrasheath injection

Alternative Procedures/Therapies

- Surgery
    - Repair of full-thickness rotator cuff tear
- Extracorporeal shock wave therapy (calcific tendinitis)

POST PROCEDURE

Expected Outcome

- Mild distension discomfort after joint injection

Immediate Aftercare

- Perform MR or CT arthrography promptly as intraarticular contrast largely absorbed by 20 minutes
- Send aspirate for microbiology, cytology, crystal analysis (need fresh specimen) as appropriate

Subsequent Aftercare

- Avoid shoulder exercise for 24 hours after steroid injection
    - Maximizes therapeutic effect & minimize spread of steroid into surrounding tissues

OUTCOMES

Complications

- Most feared complication(s)
    - Infection
- Immediate/periprocedural complication(s)
    - Vasovagal reaction
        - Undertaking procedures with patient in lying down position reduces risk
    - Bleeding (very uncommon)
- Delayed complication(s)
    - "Steroid flare"
        - Pain 1-2 days after steroid injection (up to 10%) due to steroid-related microcrystalline synovitis
            - Will settle with simple oral analgesia
    - Flushing of skin 2-3 days after steroid injection
        - Settles within 48 hours
    - Tendon rupture
        - Avoid > 3 steroid injections & leave at least 6-week gap between injections
    - SA-SD bursitis due to leakage of crystals into bursa after treatment of calcific tendinitis
        - Can be very painful; patient should be informed of this complication before procedure
        - Routine injection of steroid-lignocaine mixture into bursa after procedure
        - Oral analgesia & antiinflammatory medication

SELECTED REFERENCES

1. Pimenta M et al: Ultrasound-guided hydrodilatation for adhesive capsulitis: capsule-preserving versus capsule-rupturing technique. Skeletal Radiol. 53(2):253-61, 2024
2. Silva FD et al: Tendon injections - upper extremity. Skeletal Radiol. 52(5):979-90, 2023
3. Sconfienza LM et al: Clinical indications for image-guided interventional procedures in the musculoskeletal system: a Delphi-based consensus paper from the European Society of Musculoskeletal Radiology (ESSR)-part I, shoulder. Eur Radiol. 30(2):903-13, 2020

Needles and Syringes for MR Shoulder Arthrography

Glenohumeral Joint Injection via Posterior Approach

(Left) *Clinical photograph shows a 22-g spinal needle for intraarticular puncture and injection, a 1-mL syringe for drawing MR contrast (which is later added to a 10-mL syringe containing saline), and a 5-mL syringe for local anesthesia.* **(Right)** *Clinical photograph shows positioning for posterior glenohumeral joint injection. The patient is lying in a comfortable semiprone position with the arm externally rotated and abducted. The ipsilateral upper chest and arm are resting on a pillow.*

Glenohumeral Joint Injection via Posterior Approach

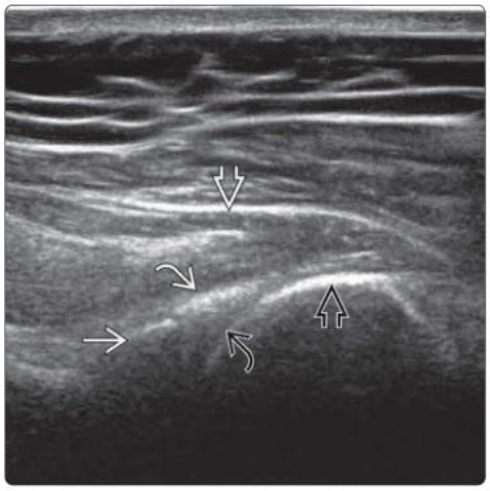

Glenohumeral Joint Injection via Posterior Approach

(Left) *Oblique longitudinal US along the musculotendinous junction of the infraspinatus shows the humeral head, glenohumeral joint, glenoid labrum, and glenoid bone.* **(Right)** *Clinical photograph shows the transducer placed transversely across the posterior glenohumeral joint, along the axis of the infraspinatus musculotendinous junction. The injection needle is being introduced from lateral to medial using a long-axis approach.*

Glenohumeral Joint Injection via Posterior Approach

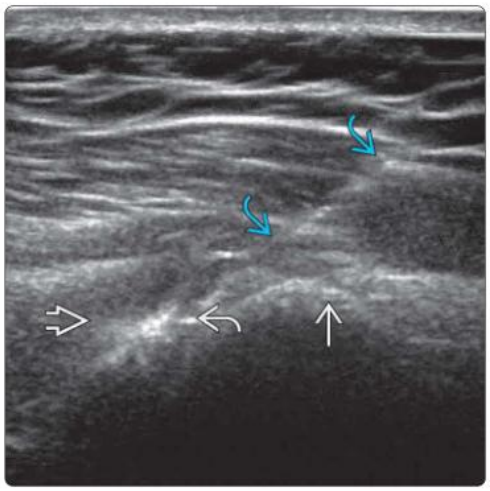

Biceps Tendon Sheath Injection

(Left) *US in the same patient shows the tip of the 22-g spinal needle at the posterior glenohumeral joint between the posterior labrum and the humeral head. The needle is introduced in a longitudinal approach. In general, 10-20 mL of contrast is injected to achieve satisfactory joint distension.* **(Right)** *Transverse grayscale US shows the in-plane needle trajectory with the needle tip within the deep surface of the long head of the biceps tendon sheath.*

Glenohumeral Joint Injection via Rotator Interval Approach

Glenohumeral Joint Injection via Rotator Interval Approach

(Left) *Clinical photograph shows patient positioning for a rotator cuff interval approach to the glenohumeral joint. The patient lies supine with the arm rotated slightly externally and palm facing upward. Avoid extreme external rotation of the arm.* **(Right)** *Clinical photograph shows a transducer placed transversely over the rotator cuff interval. The spinal needle (22-g) is introduced almost perpendicularly into the joint using a short-axis approach.*

Glenohumeral Joint Injection via Rotator Interval Approach

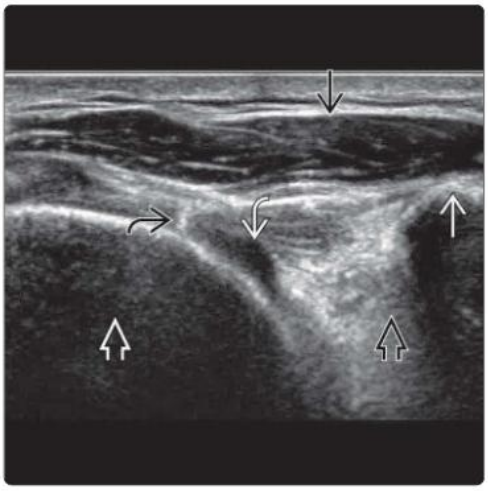

Glenohumeral Joint Injection via Rotator Interval Approach

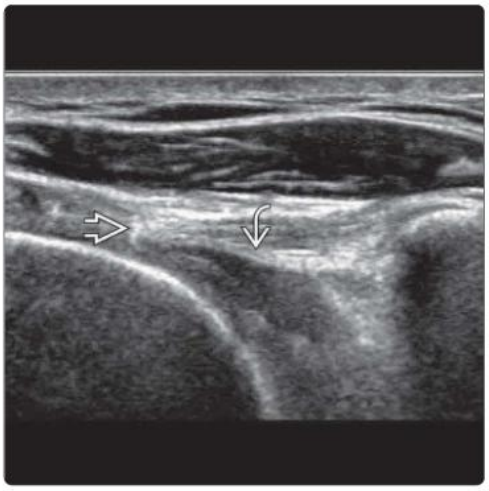

(Left) *Transverse US taken during injection shows the needle tip ⇨ positioned at the superomedial portion of humeral head at the rotator cuff interval. A small amount of contrast has been injected ⇨. Note the coracoid process ⇨, glenoid bone ⇨, humeral head ⇨, and deltoid muscle ⇨.* **(Right)** *Transverse US in the same patient shows the spinal needle tip ⇨ and further distension of the glenohumeral joint ⇨.*

Glenohumeral Joint Injection via Rotator Interval Approach

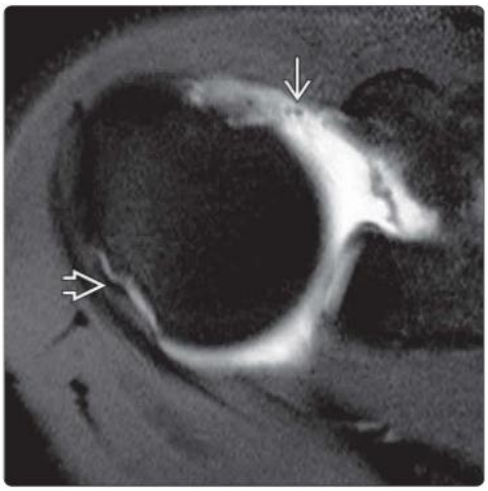

Glenohumeral Joint Injection via Rotator Interval Approach

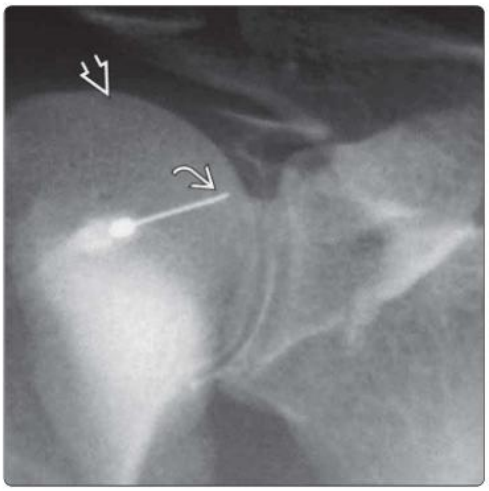

(Left) *Axial T1 FS MR arthrogram in the same patient shows satisfactory glenohumeral joint distension. There is a small Hill-Sachs deformity ⇨. Two tiny air bubbles ⇨ are present in the nondependent portion of the glenohumeral joint.* **(Right)** *Frontal radiograph of the shoulder taken during fluoroscopic-guided contrast injection via rotator interval approach shows a 22-g spinal needle with the needle tip ⇨ contacting the superomedial portion of the humeral head ⇨.*

(Left) *Clinical photograph of a patient with septic arthritis shows aspiration of purulent fluid ⇨ from the glenohumeral joint via an anterior approach. The approach for joint aspiration is similar to that for joint injection.* **(Right)** *Clinical photograph shows positioning for subacromial-subdeltoid bursal injection (lateral approach), which is the most commonly used approach. The probe is positioned along the long axis of the supraspinatus tendon with the needle introduced in a lateral-to-medial direction.*

Glenohumeral Joint Aspiration

Subacromial Subdeltoid Bursa Injection

(Left) *Clinical photograph shows the positioning for subacromial-subdeltoid bursal injection (superior approach). This approach can be used if fluid has been collected mainly in the cranial part of the bursa.* **(Right)** *Clinical photograph shows positioning for subacromial-subdeltoid bursal injection (anterior approach). The transducer is positioned in an axial plane at the front of the shoulder, and the needle is advanced in a lateral-to-medial direction.*

Subacromial Subdeltoid Bursa Injection

Subacromial Subdeltoid Bursa Injection

(Left) *Longitudinal US shows the insertion of a 20-g needle ⇨ into the subacromial-subdeltoid bursa along a pathway almost parallel to the transducer. Note early distension of the bursa during injection ⇨.* **(Right)** *Longitudinal US shows severe calcific tendinitis of the subscapularis tendon with several large clumps of calcification within the more distal fibers ⇨. Note the surrounding soft tissue edema ⇨ due to tendon inflammation.*

Subacromial Subdeltoid Bursa Injection

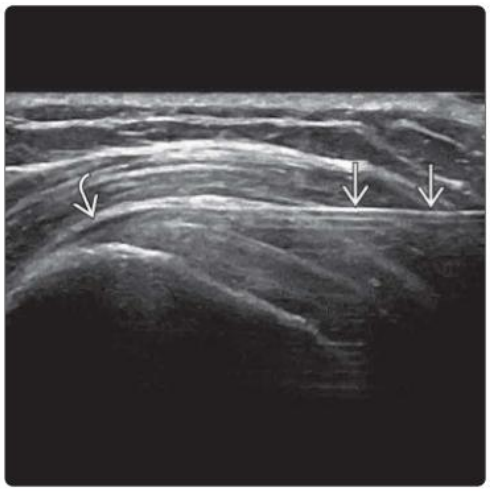

Lavage and Aspiration for Calcific Tendinitis by Single-Needle Technique

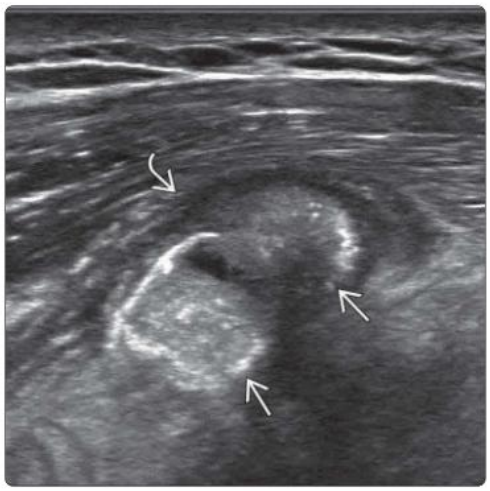

Lavage and Aspiration for Calcific Tendinitis by Single-Needle Technique

Lavage and Aspiration for Calcific Tendinitis by Single-Needle Technique

(Left) *Longitudinal US shows aspiration of the calcific content ➡ by a 16-g needle connected to a syringe containing a saline-lignocaine mixture.* **(Right)** *Longitudinal US shows injection of steroid into peritendinous soft tissue after a series of lavage and aspiration. The tip of the needle ➡ is positioned in the edematous soft tissue ➡ surrounding the calcification to reduce inflammation after the procedure. Although calcific material was aspirated, the calcific shell remains similar after the procedure.*

Spinoglenoid Notch Cyst

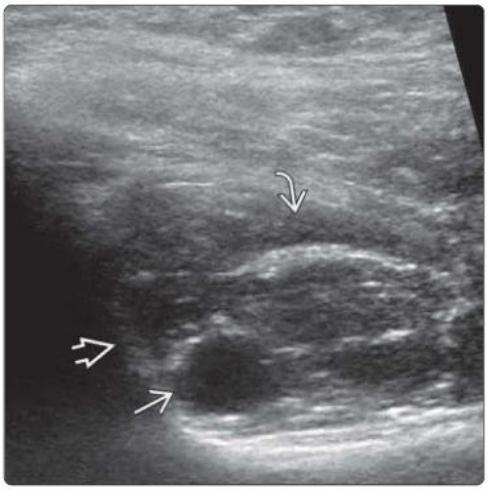

Spinoglenoid Notch Cyst Aspiration

(Left) *Transverse oblique US of the scapular region shows a medium-sized cystic lesion in the region of the spinoglenoid notch ➡ alongside the spine of the scapula ➡. The supraspinatus muscle ➡ is normal.* **(Right)** *Transverse oblique US in the same patient shows aspiration of a spinoglenoid notch cyst using a 22-g spinal needle ➡. The needle tip lies within the cyst ➡. Fenestration (dry needling) of cyst can also be performed following aspiration to disrupt the cyst wall followed by steroid-LA injection.*

Acromioclavicular Joint Injection

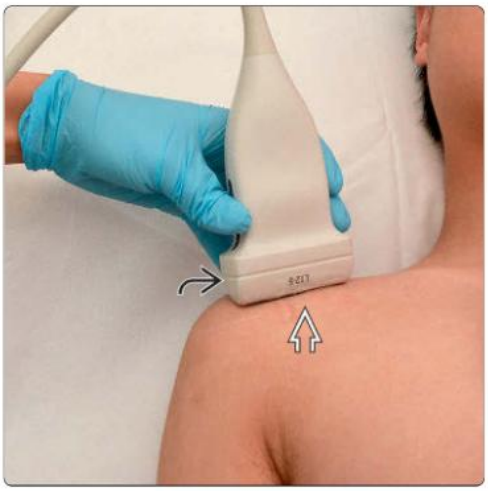

Acromioclavicular Joint Injection

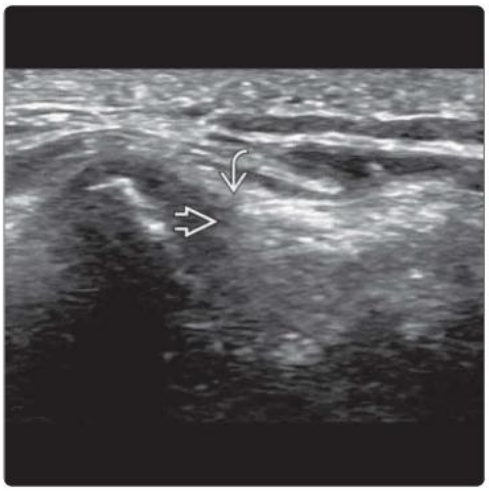

(Left) *Clinical photograph shows transverse positioning of transducer ➡ over superior aspect of acromioclavicular joint. The point of the needle insertion is anterior to the acromioclavicular joint ➡.* **(Right)** *Using a transverse approach, the joint capsule ➡ is identified and a 23-g needle ➡ is inserted anteriorly into the acromioclavicular joint beneath the capsule. 2 mL 0.25-0.5% bupivacaine and 40 mg steroid are injected into the acromioclavicular joint. This is a good treatment for inflammatory-type osteoarthritis.*

KEY FACTS

PREPROCEDURE

- **Indication**
  - Intraarticular joint fluid aspiration or injection of contrast/medication
  - Tendinosis or ligament injury treatment (dry needling, steroid injection, prolotherapy, autologous blood injection, platelet-rich plasma injection)
  - Paraarticular cyst or bursal aspiration/synovial or intraarticular soft tissue mass biopsy

PROCEDURE

- **Intraarticular aspiration or injection**
  - Posterior (trochlear-olecranon) approach (preferable)
    - Position probe sagittally along posterior part of elbow
  - Anterolateral (radiocapitellar) approach
    - Potential risk to radial neurovascular bundle, needle tip placed into smaller space
- **Tendinosis or ligament injection**
  - Identify abnormal hypoechoic area of tendinosis ± anechoic cleft-like intrasubstance tears within area of tendinosis; target most hypoechoic area & interstitial tear
- Dry needling: Repeat to-&-fro movement of needle within area of tendinosis 20-30x
- Autologous blood or platelet-rich plasma injection
  - Platelet-rich plasma of no proven benefit over dry needling or autologous blood injection for tendinosis
- Corticosteroid injection
  - Inject peritendinous tissue rather than tendon substance
  - Reduces peritendinitis but has no therapeutic effect on tendinosis per se/deleterious effect on tendon
- **Paraarticular cyst aspiration**
  - 18-g or larger needle for more viscous content
- **Perineural intervention**
  - Hydrodissection/perineural cyst aspiration-injection

US-Guided Aspiration

US-Guided Aspiration

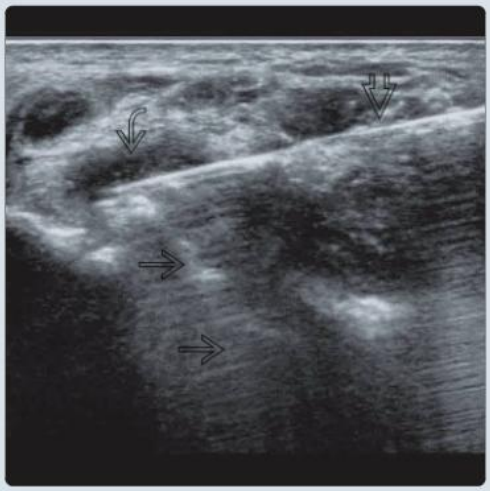

(Left) *Longitudinal US shows the distended posterior elbow recess ⇨ superficial to the humerus ⇨ and olecranon process ⇨. Aspiration was indicated to exclude infection or crystal arthropathy.* **(Right)** *Longitudinal US in the same patient shows an 18-g spinal needle ⇨ with reverberation artifacts ⇨ within the effusion. The posterior recess is partially collapsed ⇨.*

Intraarticular Injection of Contrast

Intraarticular Injection of Contrast

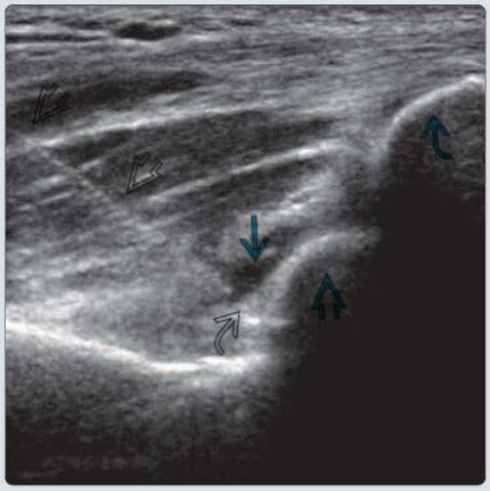

(Left) *Clinical photograph during the US-guided injection of MR contrast into the elbow joint using the posterior approach is shown. The operator is advancing a 25-g spinal needle ⇨ under US guidance using a free-hand technique.* **(Right)** *US during the injection of MR contrast into the elbow joint using the posterior approach is shown. The needle ⇨ can be seen coursing through the triceps muscle with the tip ⇨ at the olecranon fossa where there is fluid ⇨ distention. Distal humerus ⇨ and olecranon process ⇨ are shown.*

PREPROCEDURE

Indications

- Intraarticular aspiration or drainage of fluid
  - Suspected septic arthritis or crystal arthropathy; temporary relief of symptoms due to distention pain
- Intraarticular injection of contrast or medication
  - Arthrography (CT or MR)
  - Medication to relieve pain or inflammation
    - Steroid injection to reduce inflammation in either osteoarthritis or inflammatory arthritis
  - Radiosynovectomy
    - Radioactive isotope (e.g., yttrium-90) injection into joint for radioablation of synovitis in hemophiliac patients or inflammatory joint disease
    - Particularly useful in hemophiliac patients to reduce frequency of joint hemarthroses
      - In hemophilia, synovitis leads to recurrent hemarthroses, which leads to synovial hypertrophy & synovitis; this cycle of progressive deterioration leads to end-stage arthropathy
- Paraarticular aspiration, e.g., ganglion cyst/biopsy of synovium/intraarticular soft tissue mass
- Paraarticular soft tissue injection
  - For common extensor tendon origin (CETO) or common flexor tendon origin (CFTO) tendinosis
  - Dry needling, prolotherapy, steroid injection, autologous blood or platelet-rich plasma (PRP) injection
- **Perineural Interventions**
  - Perineural hydrodissection for control of symptoms; perineural/intraneural cyst aspiration-injection

Contraindications

- Local sepsis

Getting Started

- Things to check
  - Time-out procedure (patient identity, type & side of procedure, allergy status); written informed consent
- Medications
  - Local anesthetic (LA) for skin (3 mL of 1% lignocaine); 1-2% lignocaine or 0.25-0.50% bupivacaine for deeper tissue
  - Steroid: 40 mg/mL of methylprednisolone (Depo-Medrol)
  - Contrast
    - CT arthrogram: 10 mL of iodinated contrast (Omnipaque 300 mg/dL ± 0.1 mL of 1:1,000 epinephrine)
    - MR arthrogram: 10 mL of diluted gadolinium (0.1 mL of gadolinium in 10 mL of normal saline)
- Equipment list
  - Sterile set, 18- to 23-g spinal needle, extension tube, syringes, coaxial needle & biopsy set, specimen bottles

PROCEDURE

Procedure Steps

- **Intraarticular aspiration or injection**
  - General advice irrespective of approach used
    - Flush syringe & injection tubing to avoid injection of air bubbles
    - If needle tip is difficult to see during insertion, move needle slightly in & out under real-time imaging to confirm position of needle tip; aspirate as much fluid as possible for decompression
    - If joint fluid is too viscous, consider using larger bore needle, e.g., 16-g or 18-g
    - If insufficient aspirate despite good needle tip position, rotate needle 180° to change bevel position or else retract slightly & reposition needle tip
      - If still insufficient aspirate, consider saline lavage & aspiration; label it as joint wash
    - Leave needle free in joint or resting on articular cartilage, but do not push needle into articular cartilage
    - Free flow of fluid with low pressure during injection helps confirm intraarticular position of needle tip
  - Posterolateral approach (trochlear-olecranon articulation)
    - Preferable, as no major neurovascular structures posterolaterally
    - Position patient with elbow flexed to 90° & forearm fully pronated
    - Position probe sagittally along posterior part of elbow
    - Move transducer laterally until triceps is just out of view
  - Anterolateral approach (radiocapitellar articulation)
    - More ergonomic & convenient in terms of patient positioning, but more difficult & time consuming
      - Potential risk to radial neurovascular bundle; needle tip placed into smaller space
    - Patient sits next to table with flexed elbow resting on table & lateral aspect uppermost
    - Position probe longitudinally along lateral part of elbow
      - Landmarks: Radial head & capitellum
- **Paraarticular aspiration**
  - Needle advanced into paraarticular cyst or collection under real-time imaging
  - 21-g needle for ganglion cyst aspiration; 18-g or larger needle for more viscous content
  - ± hyaluronidase (150 units in 1 mL) prior to aspiration if too viscous
- **Tendinosis treatment**
  - **Common procedure for anchor tendons** (CETO tendinosis, less common for CFTO tendinosis)
    - Most patients respond to conservative treatment
    - Intervention indicated in patients refractory to conservative treatment with chronic pain & disability
  - Check whether tear is present as this will have bearing on treatment choice
  - Dry needling: Repeated fenestration of tendinosis
    - Initially infiltrate LA around tendon & not within tendon
    - Position 22-g needle tip centrally within most severe area of tendinosis
    - Move needle tip to-&-fro longitudinally within area of tendinosis 20-30x to create fiber disruption & promote internal bleeding
      - 85% of patients improve at 6 months
      - Similar result to open release surgery

  - Often followed by low-volume PRP injection (2-3 mL) within abnormal tendon
- **Corticosteroid injection**
  - Treats peritendinitis associated with tendinosis rather than tendinosis per se
    - Steroid injection generally not recommended now due to deleterious effect on tendon
  - Local infiltration 1 mL of triamcinolone acetonide (10 mg/mL) & 1 mL of 2% lignocaine
    - Inject peritendinous tissues rather than tendon itself
  - Shows good result at 6 weeks for 1st injection, but dry needling or PRP treatment have better results at 3 & 12 months
- **Prolotherapy**
  - Treatment of tendinosis, partial tendon tear, or ulnar collateral ligament tear
  - Irritant solution (e.g., hyperosmolar dextrose) incites inflammatory response with fibroblast proliferation & collagen repair
  - 0.5 mL of dextrose solution (4 mL of 50% dextrose + 4 mL of normal saline) injected into tendon where there are features of tendinosis or tear
  - Additional 2 mL total of solution injected near bone at supracondylar ridge & annular segment
  - Leads to significant improvement in elbow pain score, grip strength, & range of movement at 8 weeks time
- **Autologous blood**
  - Indicated for tendinosis, partial tendon tear, or ulnar collateral ligament tear
  - Identify any discrete tear, focal tendinosis, or discrete area of neovascularity
  - Draw 2 mL of autologous blood from contralateral antecubital vein & gently shake to prevent clotting
  - Infiltrate 2 mL of bupivacaine (0.25%) along surface of tendon or ligament
  - Insert needle into most abnormal site of tendon or ligament
    - Usually preceded by dry needling of tendon or ligament
  - Repeat procedure 1x after 4 weeks time; leads to significant reduction in elbow pain score
- **PRP injection**
  - Indicated for tendinosis, partial tendon tear, or ulnar collateral ligament tear
  - PRP contains fibroblast growth factors, which facilitate healing
  - 2-3 mL of leukocyte-rich PRP injected followed by steroid-LA injection on tendon surface
  - Apply bandage & moist heat packs every 3 hours for 15 minutes duration for first 24 hours after injection
  - Evidence indicates that PRP is no better than dry needling or autologous blood for elbow tendinosis
- **Botox injection for CETO tendinosis or tears**
  - 10-30 U Botox injected → extensor carpi radialis brevis ± extensor digitorum communis ± extensor carpi ulnaris ± extensor digiti minimi muscles
    - At proximal 1/3 forearm
    - Transient middle finger weakness reported
  - ± 2nd treatment in patients with incomplete response
- **Intraarticular soft tissue or synovial biopsy**
  - Use coaxial needle to prevent multiple skin punctures; useful at confirming septic arthritis if no joint fluid
- **Perineural interventions**
  - Perineural hydrodissection for ulnar neuropathy at elbow joint
    - Transverse in plane approach with arm in external rotation & elbow in semiflexed position
    - 10 mL of 5% dextrose along anterior & posterior perineural space
    - Perineural steroid-LA injection if perineuritis is confirmed on US imaging
    - Avoid intraneural injection indicated by increasing pain & nerve expansion during procedure
  - Perineural cyst aspiration-injection
    - Short-/long-axis approach depending on location of cyst
    - Large bore needle to aspirate content followed by injection of steroid ± hyaluronidase (150 IU)

POST PROCEDURE

Aftercare for Diagnostic Procedures

- Perform MR or CT arthrography as soon as possible post injection as contrast will be largely absorbed by 30 minutes
- Send aspirate for microbiology, cytology, & fresh specimen for crystal analysis

Aftercare for Tendon/Ligament Intervention

- Expect increase in pain for first 72 hours
- 1st week, no physical therapy, NSAID, or icing
  - Use analgesia for pain, if required
  - Immobilize elbow with shoulder sling & wrist splint
  - Gentle passive movement or active assisted movement
- After 1 week, discontinue immobilization
  - Allow low-resistance exercise
- After 1 month, continue mobilization to normal range of motion
  - Increase pain-free exercise to moderate level
- After 2 months, undertake follow-up US examination
  - Checking particularly for condition of tendon or ligament, level of residual inflammation, & tears
- After 3 months, aim for pain-free return to sports
  - ± repeat treatment if desired response not achieved

OUTCOMES

Complications

- Most feared complication(s)
  - Infection
  - Extravasation of contrast/medication
    - Steroid/radiosynovectomy: Fat pad atrophy, skin atrophy, skin depigmentation
- Immediate/periprocedural complication(s)
  - Bleeding, especially for those with bleeding diathesis
  - Neurovascular bundle injury (rare)
    - Ulnar nerve injury from posterior approach, radial nerve injury from anterior radiocapitellar approach

SELECTED REFERENCES

1. Tobaly D et al: Assessing the treatment response of lateral elbow tendinopathy using time-dependent ultrasonography, Doppler imaging, and elastography. Insights Imaging. 15(1):113, 2024

Posterior Approach

Posterior Approach

(Left) *Clinical photograph shows a posterior approach with the flexed elbow either resting on a table or lying on a bed. This approach is common and convenient for the patient. However, it provides less space for redirecting the needle position.* **(Right)** *Clinical photograph of a posterior approach shows an alternative palm-down, wrist-extended, and elbow-flexed position. This approach allows a wider space for needle puncture and adjustment. This position requires a high level of patient cooperation.*

Anterolateral Approach

Common Extensor Tendon Origin Injection

(Left) *Clinical photographs shows an anterolateral approach to radiocapitellar articulation with the elbow flexed and resting on a table. This approach is more difficult and time consuming. The joint space is smaller, and the radial nerve and artery are close to the needle path.* **(Right)** *Clinical photograph shows the approach to the common extensor tendon origin (CETO) injection with the elbow slightly flexed and resting on a table under US guidance. The needle is then advanced into the CETO.*

US-Guided Radiosynovectomy

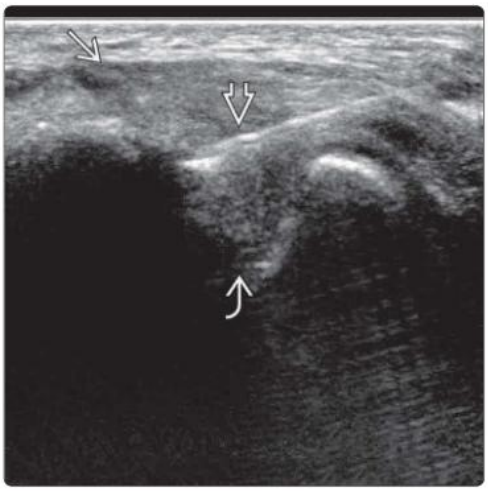

US-Guided Radiosynovectomy

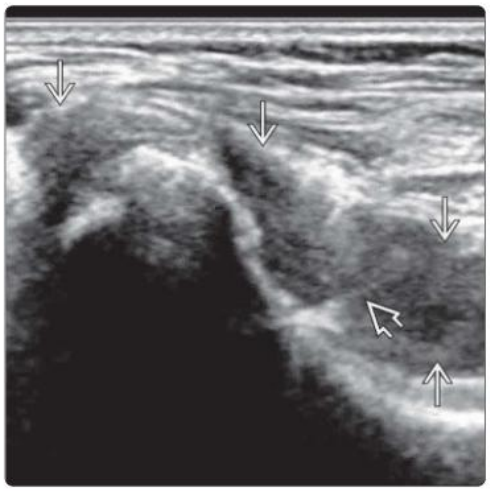

(Left) *US-guided radiosynovectomy of a hemophiliac joint is shown using a 23-g spinal needle ➡ within the moderately eroded lateral radiocapitellar joint ➡ for radioactive yttrium injection. Moderate synovial proliferation ➡ is present.* **(Right)** *US-guided radiosynovectomy of a hemophiliac patient is shown with the tip of the 23-g spinal needle at the posterior aspect of the mildly eroded distal humerus ➡. The posterior recess is distended with thickened hypoechoic synovium ➡.*

US-Guided Aspiration/Injection Sterile Set

Needle Used for Drainage



(Left) *Clinical photograph of set-up used for injection of contrast or medication shows a syringe with 3-way connector and extension tubing, specimen bottle, syringe with local anesthetic, forceps, sterile solution, and a 22-g spinal needle.* **(Right)** *Clinical photograph shows a commonly used spinal needle with a sharp, beveled edge used to puncture skin and soft tissue. The stylet is removed from the outer sheath only in the joint or cyst.*

US-Guided Aspiration

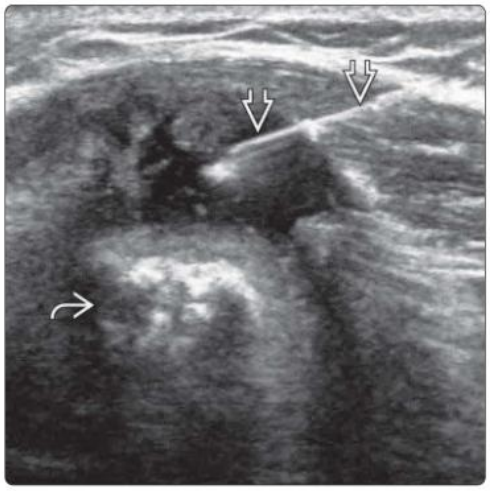

US-Guided Synovial Biopsy

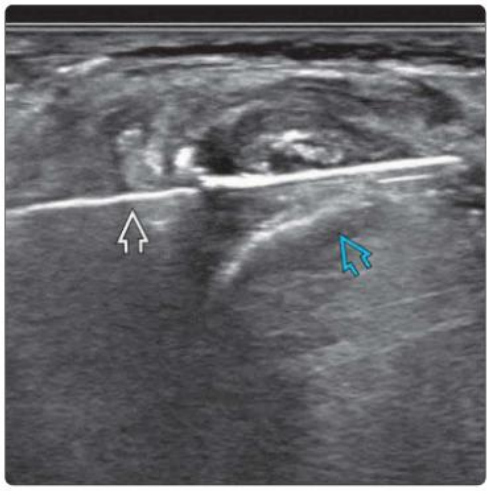

(Left) *Transverse US shows aspiration of a posterior elbow recess in a rheumatoid patient. The recess has been punctured with a 21-g spinal needle under real-time imaging. There is some cortical erosive change at the olecranon tip.* **(Right)** *Transverse US during biopsy of a patient with suspected septic arthritis is shown. The biopsy needle courses through the thickened synovium of the distended posterior recess alongside the olecranon. Culture of the synovium was negative. The final diagnosis was inflammatory arthritis.*

US-Guided Aspiration

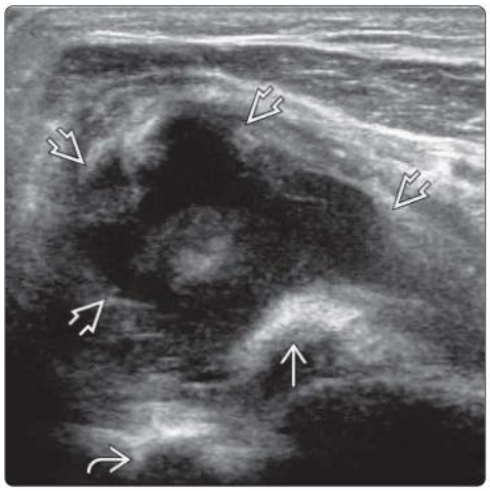

US-Guided Aspiration

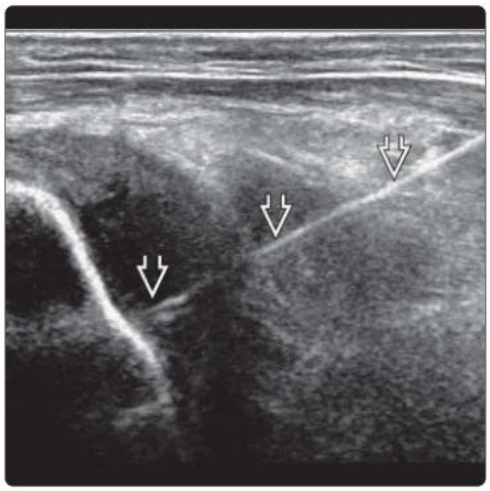

(Left) *US shows a distended anterior elbow recess superficial to the proximal ulna and radius in a rheumatoid patient with suspected superimposed infection.* **(Right)** *US-guided aspiration of the anterolateral aspect of the same elbow with the 21-g spinal needle is shown. Most of the fluid could be aspirated. Microbiology culture showed no bacterial growth.*

US-Guided Aspiration and Injection

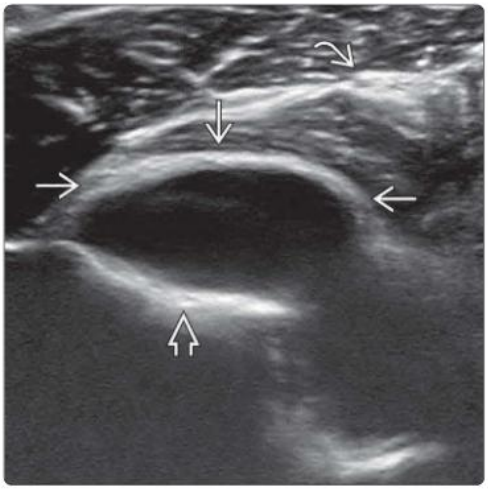

US-Guided Aspiration and Injection

(Left) *US shows a loculated ganglion cyst ➡ anterior to the radial neck ➡. The posterior interosseous nerve (PIN) ➡ at this level is immediately alongside the supinator muscle lying above the ganglion cyst. (Courtesy S. James, MD.)* **(Right)** *US during injection of steroid using a 22-g spinal needle ➡ is shown. The needle path has been selected to avoid injury to the PIN ➡. Steroid injection helps decrease pericystic inflammation and reduces the likelihood of ganglion cyst recurrence. (Courtesy S. James, MD.)*

US-Guided Injection

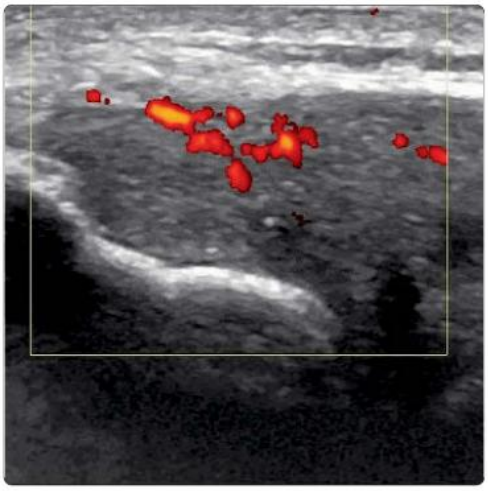

US-Guided Injection

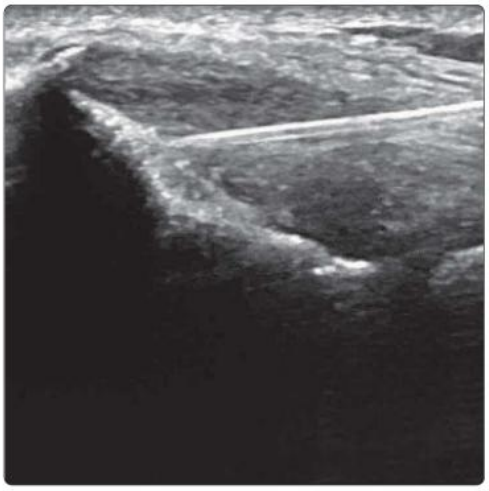

(Left) *Preliminary longitudinal power Doppler US shows severe tendinosis with hyperemia at the CETO.* **(Right)** *Longitudinal US shows US-guided injection of 1 mL (40 mg/mL) methylprednisolone with 0.5 mL (1%) lignocaine deep to the CETO using a 22-g spinal needle after dry needling for 1 minute. Dry needling helps to create fenestrations, disrupts tendon fibrillar structure, and promotes internal bleeding.*

US-Guided Injection

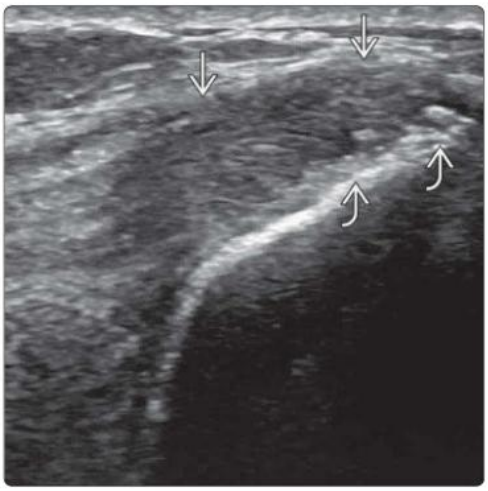

US-Guided Injection

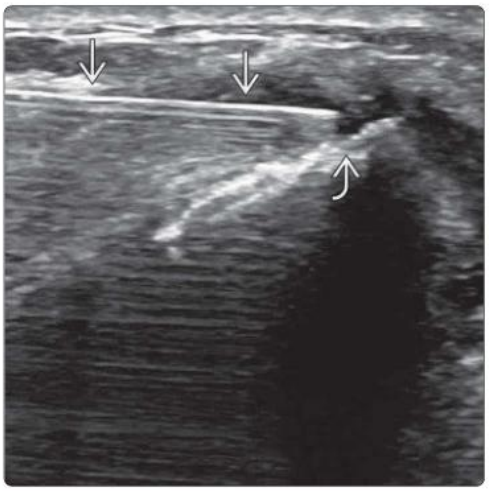

(Left) *Preliminary longitudinal US shows severe common flexor tendon origin (CFTO) tendinosis with severe hypoechoic changes and loss of the normal fibrillation ➡ with insertional bony irregularity ➡ at the CFTO.* **(Right)** *Longitudinal US shows US-guided injection of 1 mL (40 mg/mL) methylprednisolone with 0.5 mL (1%) lignocaine deep to the CFTO ➡ using a 23-g spinal needle ➡ after dry needling for 1 minute. Dry needling creates a controlled tendon injury in order to stimulate a healing response.*

KEY FACTS

PREPROCEDURE

- **Indication**
  - Aspiration of joint fluid or intraarticular injection of medication/contrast agent
  - US therapy of ganglion cyst, tendon disease, trigger finger, carpal tunnel syndrome, Raynaud phenomenon, & Dupuytren contracture

PROCEDURE

- Joint aspiration or injection
  - Radiocarpal, midcarpal, distal radioulnar joints: Dorsal approach
  - Scaphotrapeziotrapezoid or trapeziometacarpal joints: Dorsoradial approach
- Ganglion cyst aspiration
  - ≥ 19-g needle for more viscous content
- Tendon disease
  - Approach depends on site of disease; steroid injection: More commonly used for inflammatory tenosynovitis
  - Tendon fenestration/platelet-rich plasma (PRP) injection: Less commonly used
- De Quervain disease
  - Dorsoradial approach; steroid injection ± partial release for retinacular disease
- Trigger finger
  - Palmar approach, short or long axis
  - Steroid injection ± percutaneous pulley release
- Carpal tunnel syndrome
  - Steroid injection or perineural hydrodissection with 5% dextrose
  - US-guided flexor retinaculum release as alternative to surgery in recurrent severe cases
- Raynaud phenomenon
  - Botox injection to perineurovascular region
- Dupuytren contracture
  - Needle aponeurosis release ± hyaluronidase injection

Botox Injection for Raynaud Phenomenon

Botox Injection for Raynaud Phenomenon

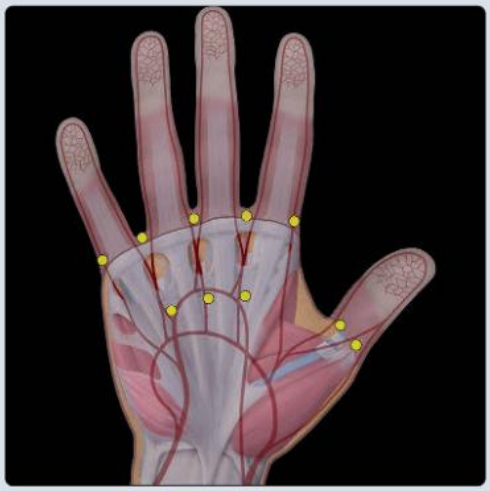

(Left) *Transverse US-guided injection of Botox alongside the digital neurovascular bundle ➡ on ulnar side base of the little finger is shown. A 25-g needle ➡ is positioned alongside the neurovascular bundle and Botox is injected ➡. The flexor tendons ➡ of the little finger are seen alongside the neurovascular bundle.* **(Right)** *Ten target point injections (yellow dots) are performed alongside the radial and ulnar neurovascular bundles at the base of the 5 fingers (7 injection points) and also in the midpalm region (3 injection points).*

Botox Injection for Raynaud Phenomenon



Botox Injection for Raynaud Phenomenon

(Left) *Clinical photograph of a patient with Raynaud phenomenon before Botox injection is shown. There is dry gangrene ➡ of the index finger tip and a generalized dusky discoloration of the fingers, particularly the little finger.* **(Right)** *Clinical photograph of the same patient with Raynaud phenomenon several months after Botox injection is shown. The dry gangrene ➡ of the index finger tip has healed. The skin coloration is now normal.*

PREPROCEDURE

Indications

- Intraarticular aspiration or injection
  - Suspected septic arthritis or crystal arthropathy
  - Medication for control of inflammation or symptom relief
  - Prior to MR or CT arthrography
- Ganglion cyst
  - Aspiration ± steroid injection
- Tendon disease
  - Aspiration for suspected infective tenosynovitis
  - Injection of steroid for peritendinitis
- De Quervain disease: Injection or partial tenotomy
- Trigger finger: Pulley injection or percutaneous pulley release
- Carpal tunnel syndrome: Perineural injection, hydrodissection, or retinacular release
- Dupuytren contracture: Aponeurosis injection or release

PROCEDURE

Joint Aspiration or Injection

- General clues irrespective of joint aspirated or injected
  - Sterile technique: Skin & underlying soft tissues anesthetized at puncture site
  - Plan best approach that will avoid neurovascular or tendon injury
  - Long-axis (preferable) or short-axis approach
  - Free-hand US technique to guide needle into joint space; 25-g or larger needle (19-g) for fluid aspiration
  - Free flow of fluid with low-pressure injection confirms intraarticular position of needle tip
  - If free-fluid flow is not present, rotate or slightly realign needle
  - Post injection, apply pressure & avoid exercise for 10 minutes to prevent leakage of solution along needle track
- Intraarticular injection of wrist joint
  - 25-g intravenous or spinal needle is used
  - Radiocarpal joint
    - Dorsal approach via radioscaphoid joint space with probe in sagittal plane to joint
    - Enter 1 cm distal to radioscaphoid joint space, directing needle into dorsal recess
    - Direct needle proximally toward articular cartilage of distal radius
    - Once cartilage is contacted, tilt needle vertically to enter center of radioscaphoid joint
  - Midcarpal joint
    - Dorsal approach, place probe in sagittal or transverse plane
    - Target either scaphocapitate or triquetrohamate interspaces
  - Distal radioulnar joint
    - Dorsal approach, place probe in transverse plane
    - Position needle alongside radial border of ulnar head a few mm proximal to distal articular surface & directed toward ulnar head
    - When needle contacts ulnar head, angle it more vertically to insert deeper into joint space
  - Scaphotrapeziotrapezoid or trapeziometacarpal joints
    - Dorsoradial approach: Place probe in sagittal plane
    - Angle needle 30-45° relative to transducer
  - Carpometacarpal joint thumb
    - Flex thumb toward palm to open joint dorsoradially

Ganglion Cyst Aspiration

- 21-g needle advanced real-time into ganglion
  - 16-g or 18-g needed for more viscous content
  - US appearances generally cannot predict viscosity of content
    - Though comet-tail artifacts suspended in matrix generally implies viscous content
  - Always check with color Doppler US before needle insertion to identify surrounding vasculature
- Saline lavage can loosen cyst contents if initial aspirate is dry due to viscous contents
- ± hyaluronidase preaspiration (150 units in 1-2 mL of normal saline)
  - Hyaluronidase degrades hyaluronic acid, which is macromolecular component of ganglion cyst matrix
  - Inject hyaluronidase to ganglion cyst, leave needle in cyst for 5-15 minutes, & then aspirate
- ± intracystic injection of steroid (4-10 mg methylprednisolone) following aspiration
- ± fenestration (dry needling) of cyst wall following aspiration
  - Disrupts ganglion cyst wall, reducing likelihood of recurrence

Tendon Disease

- Approach is tailored according to tendon pathology
  - Dorsal or palmar approach
  - Probe usually in sagittal plane, avoiding excessive probe pressure, which may efface tenosynovial fluid
- Needle (21-g) advanced in real time to tendon margin
  - Can enter periphery of tendon substance & slowly withdraw needle, gently injecting fluid
- Dry needling or platelet-rich plasma (PRP, 3 mL) injection are treatment options for tendinosis

De Quervain Disease

- Stenosing tendinosis of 1st extensor compartment
  - De Quervain disease is tendinosis rather than tenosynovitis
  - Thickening & inflammation of extensor retinaculum limit tendon movement
- US-guided steroid injection deep to retinaculum ± partial needle release of retinaculum
  - Axial approach for steroid injection
    - Steroid-local anesthetic is injected with 23-g needle into 1st extensor compartment tendon sheath
    - If septum is present (40%), inject tendon sheaths of both subcompartments
    - Risk of skin hypopigmentation/subcutaneous fat atrophy & tendon rupture
    - Using nonparticulate steroid & flushing needle with local anesthetic prior to withdrawal minimizes local adverse effects of steroid injectant
  - Proximal intersection syndrome occurs at distal forearm ~2 cm proximal to Lister tubercle

- Distal to proximal for release, patient holding rolled towel with radial side up & ulnar side slightly ulnar deviated
  - Partial release of 1st extensor compartment retinaculum
    - Patients with recurrent symptoms lasting for > 4 months & positive Finkelstein test
    - Bevel of bent needle is facing sideways perpendicular to retinacular fibers
    - Alternative treatment to surgery: Less risk of infection/minimal scar tissue & early return to work
    - Risk of injury to superficial branch of radial nerve
  - Percutaneous dry needling/PRP injection for coexistent tendinosis

Trigger Finger

- Steroid injection or percutaneous release of annular pulley are potential treatment options
  - Hand flat on table, palm upward
  - Palmar approach: Both axial (best for thumb) & sagittal (best for other fingers) planes are used
  - 23-g needle is placed deep to annular pulley & 10 mg of methylprednisolone is injected
- Percutaneous release of annular pulley
  - Longitudinal approach
  - Insert curved 19-g intravenous needle deep to annular pulley
    - Needle bent to 15-20° close to hub prior to insertion, rotate bevel sideways to facilitate cutting action
    - Using skin as pivot & downward pressure on attached syringe, cut annular pulley from deep to superficial (i.e., away from tendon)
  - Outcome is comparable to that of surgical release & non-image-guided percutaneous release
  - Mean procedure time is < 15 minutes; much shorter recovery time than surgical release

Carpal Tunnel Syndrome

- Steroid injection or perineural hydrodissection targeting median nerve at carpal tunnel inlet & outlet
  - Best to target either inlet or outlet where median nerve is seen to be most swollen
- Approach
  - Transverse ulnar route at distal palmar crease (carpal tunnel inlet)
  - Longitudinal palmar to wrist route (carpal tunnel outlet)
- Using 23-g or 25-g needle, steroid (10 mg of methylprednisolone) injected around median nerve
- Using 23-g perineural hydrodissection with 10 mL of 5% dextrose, 6 mL in short axis followed by 4 mL longitudinal injection
- 60% of patients get moderate to near-complete symptom relief after single injection
  - Symptom relief sustained for short (6 weeks) to medium term (6 months)
  - 60% of patients require retreatment within 1 year
- US-guided release of transverse carpal ligament
  - Alternative to surgery in patients with severe carpal tunnel syndrome with motor & sensory symptoms

Raynaud Phenomenon

- Total of 10 points of injection: Base of 5 fingers & midpalmar region

Dupuytren Contracture

- US-guided needle aponeurotomy ± hyaluronidase (1 mL of 150 IU) injection
  - Indicated for fixed flexion deformity > 20° at metacarpophalangeal & > 30° at proximal interphalangeal joints

POST PROCEDURE

Aftercare

- MR or CT arthrography should be performed as soon as possible after arthrography, as contrast will have largely absorbed in 30 minutes
- Avoid exercise for 24 hours after corticosteroid injection to maximize therapeutic effect & reduce speed of steroid into surrounding tissues
- After tendon therapy, such as dry needling, refrain from tendon-loading activity for 1 week
  - Avoid taking antiinflammatory medication, which may theoretically impair healing process
- For more specific tendon intervention, such as PRP injection or autologous blood injection
  - Rest for 2 weeks with no return to sports activity/training for 6 weeks

OUTCOMES

Complications

- Most feared complication(s)
  - Infection, e.g., septic arthritis
  - Neurovascular bundle injury
    - De Quervain disease
      - Medial branch of superficial branch of radial nerve typically passes superficial to 1st extensor compartment
      - Lateral branch passes volar to 1st extensor compartment
      - Deep branch of radial artery passes deep to 1st extensor compartment
      - Cephalic vein passes superficial & close to 1st extensor retinaculum
    - Wrist joint injection
      - Terminal part of posterior interosseous nerve between 3rd & 4th extensor compartments
  - Leakage of steroid medication
    - Fat & skin atrophy, skin depigmentation
- Immediate/periprocedural complication(s)
  - Bleeding, especially if bleeding diathesis
    - Apply local pressure
  - Extravasation of contrast or medication
    - Apply local pressure & rest joint for 10 minutes
  - Capsular rupture
  - Allergy to injectate
  - Steroid flare (within 24 hours)

SELECTED REFERENCES

1. Flores DV et al: Diagnostic and interventional US of the wrist and hand: quadrant-based approach. Radiographics. 43(8):e230046, 2023
2. Kumar N et al: Ultrasound-guided interventions in primary carpal tunnel syndrome: perineural injection to threat carpal tunnel release. Br J Radiol. 96(1150):20230552, 2023
3. Vuillemin V et al: Musculoskeletal interventional ultrasonography: the upper limb. Diagn Interv Imaging. 93(9):665-73, 2012

De Quervain Disease Injection

De Quervain Disease Injection

(Left) *Clinical photograph shows the longitudinal approach for injection of de Quervain disease. The wrist is resting on a towel wedge with slight ulnar deviation. The superficial branch of the radial nerve and its branches should be first identified.* **(Right)** *Clinical photograph shows the axial approach for injection of de Quervain disease. If there is a septum present in the 1st extensor compartment (as seen in 40% of subjects), both subcompartments should be injected.*

De Quervain Disease Injection

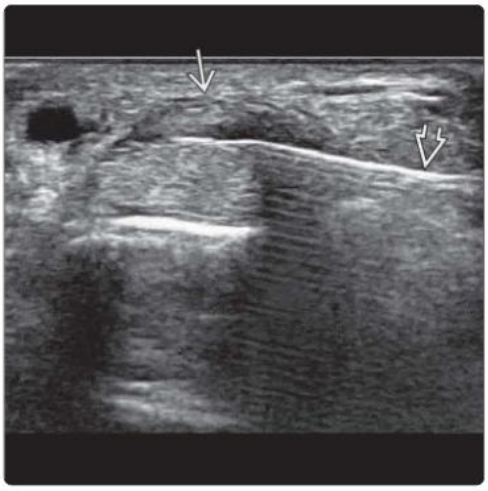

De Quervain Disease Injection

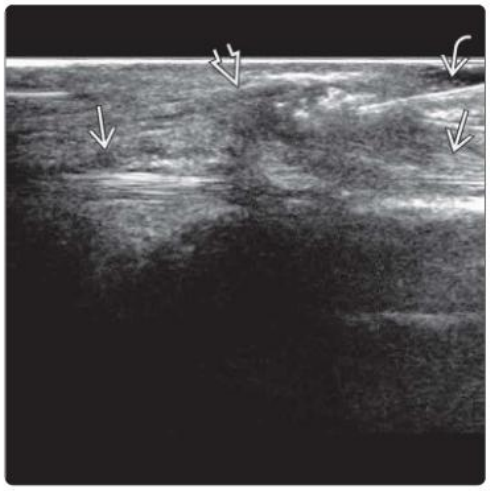

(Left) *Transverse US in a patient with de Quervain disease shows moderate thickening of the extensor retinaculum ⇨ of the 1st extensor compartment. A 23-g intravenous needle ⇨ is inserted into the tendon sheath just deep to the retinaculum, and 10 mg of methylprednisolone is injected.* **(Right)** *Longitudinal US shows steroid (10 mg of methylprednisolone) being injected into the tendon sheath of the 1st extensor compartment ⇨ tendons deep to the retinaculum ⇨ via a 23-g needle ⇨.*

Carpal Tunnel Injection

Carpal Tunnel Injection

(Left) *Transverse US of the wrist at the level of the distal palmar crease shows a needle tract ⇨ with the tip of the needle ⇨ deep to the median nerve.* **(Right)** *Clinical photograph shows steroid (10 mg of methylprednisolone) injection treatment for carpal tunnel syndrome using a transverse approach. The needle (21- or 23-g) is inserted on the ulnar side. An ulnar approach is more commonly performed than a radial approach.*

(Left) *Clinical photograph shows the longitudinal palmar approach for annular pulley injection. This is the most commonly used approach, as access to the area between the pulley and the flexor tendons is easiest. It is also the preferred approach for the pulley-cutting procedure. Placing the wrist on a pad allows the finger to be hyperextended, facilitating needle access.* **(Right)** *Clinical photograph shows the transverse oblique palmar approach for annular pulley injection to treat the trigger finger.*

Trigger Finger Injection

Trigger Finger Injection

(Left) *Longitudinal US shows steroid (10 mg of methylprednisolone) injection to treat the trigger finger. A 23-g needle ⇨ is placed within the tendon sheath just deep to the mildly thickened A1 pulley ⇨.* **(Right)** *Transverse US shows a mild, possibly infective, flexor tenosynovitis of the index finger overlying the proximal phalanx. Fluid from the small tendon sheath effusion ⇨ was aspirated using a 21-g needle ⇨ for culture. Fluid culture was sterile.*

Trigger Finger Injection

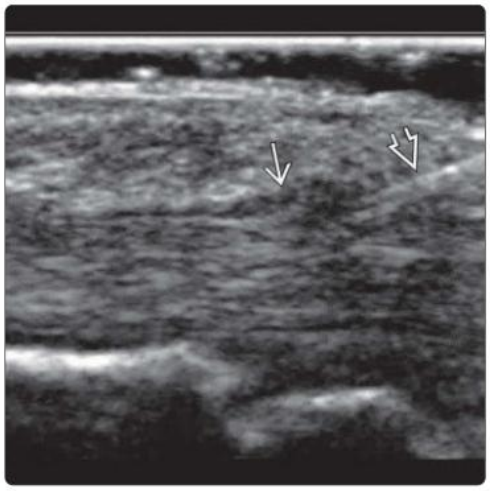

Tenosynovitis Aspiration

(Left) *Transverse US of the dorsal wrist shows a small ganglion ⇨ superficial to the scaphoid ⇨. A 21-g needle is inserted into this ganglion via a dorsal approach. The needle tip ⇨ lies within the ganglion.* **(Right)** *Oblique US of the palm shows a large ganglion ⇨ within the thenar muscle. A 21-g needle is inserted via a palmar approach. The needle tip ⇨ lies within the ganglion. It is difficult to ascertain the viscosity of ganglion contents with US prior to aspiration.*

Ganglion Aspiration

Ganglion Aspiration

Radiocarpal Joint Injection

Radiocarpal Joint Injection

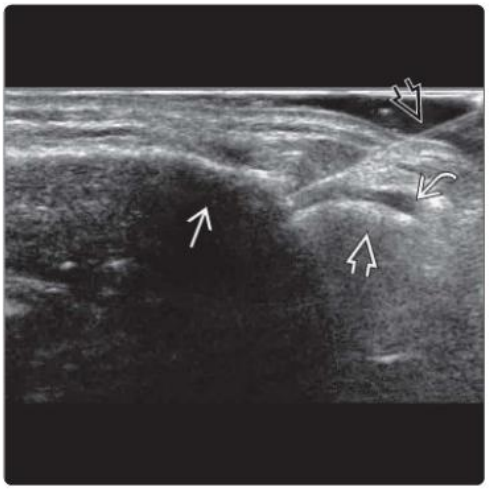

(Left) *Clinical photograph shows a longitudinal dorsal approach for injection of the radiocarpal articulation.* **(Right)** *Longitudinal US shows US-guided contrast injection of the radiocarpal articulation. A 25-g spinal needle ⇨ lies within the joint space between the distal radius ⇨ and the proximal pole of the scaphoid ⇨. A small amount of contrast ⇨ has been injected into the joint.*

Radiocarpal Joint Injection

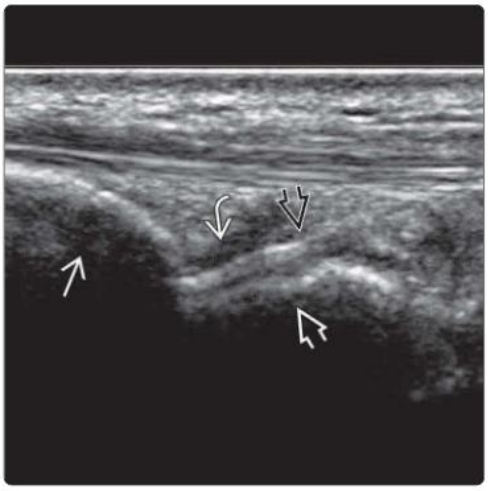

Radiocarpal Joint Injection

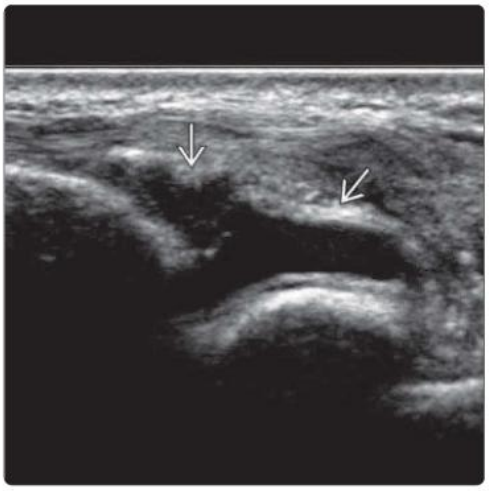

(Left) *Longitudinal US shows US-guided contrast injection into the radiocarpal articulation for MR arthrography. A 25-g spinal needle ⇨ lies within the joint space between the distal radius ⇨ and the proximal pole of scaphoid ⇨. A small amount of contrast ⇨ has been injected into the joint.* **(Right)** *Longitudinal US in the same patient shows fluid distention ⇨ of the radiocarpal joint after the injection has been completed.*

Distal Radioulnar Joint Injection

Distal Radioulnar Joint Injection

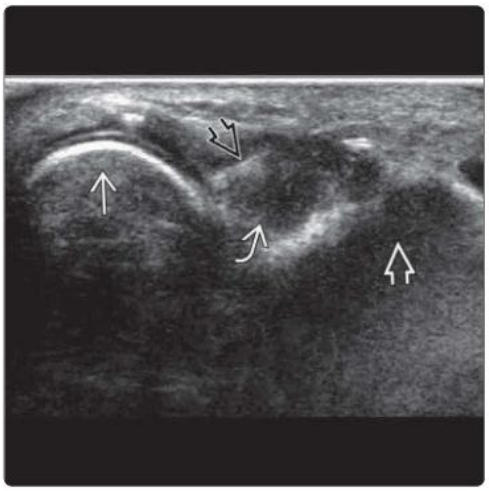

(Left) *Clinical photograph shows the transverse dorsal approach for injection of the distal radioulnar joint.* **(Right)** *Axial US shows US-guided contrast injection for MR arthrography into the distal radioulnar joint. A 25-g spinal needle ⇨ lies within the joint space between the distal ulna ⇨ and the distal radius ⇨. A small amount of contrast ⇨ has been injected into the joint.*

KEY FACTS

PREPROCEDURE

- Common procedures are joint injection/aspiration, treatment of tendinosis, paralabral cyst aspiration, perineural hydrodissection, synovial biopsy, & iliolumbar ligament & pyriformis muscle injection
- Local anesthetic, steroid, hyaluronic acid, platelet-rich plasma (PRP), autologous blood injection (ABI), iodinated contrast, & diluted gadolinium are common medications

PROCEDURE

- US-guided joint injection more efficient than fluoroscopic-guided joint injection
- For hip joint injection & aspiration, use anterior longitudinal approach, targeting femoral head or femoral neck
- For sacroiliac (SI) joint injection, patient lies prone with joint identified at level of S1 & S2 foramina
- Fenestration as good as PRP for tendinosis treatment
- Paraarticular cyst or bursal aspiration ± hyaluronidase preaspiration ± steroid post aspiration
- Biopsy of synovial tissue for infection, inflammation, or synovial tumor
- Nerve block or neural hydrodissection, diagnostic or therapeutic treatment for lateral femoral cutaneous, ilioinguinal, iliohypogastric, genitofemoral, obturator, pudendal, & sciatic nerves
- Iliolumbar ligament injection & pyriformis muscle injection for pain relief

POST PROCEDURE

- Send aspirate for microbiology, cytology, crystal analysis (need fresh specimen) as appropriate
- Perform MR or CT arthrography within 20 min of contrast injection, as contrast will absorb
- After tendinosis treatment, avoid strenuous hip activity for 1 week, gradually building up to normal training activity after 6 weeks

Hip Aspiration

Hip Aspiration

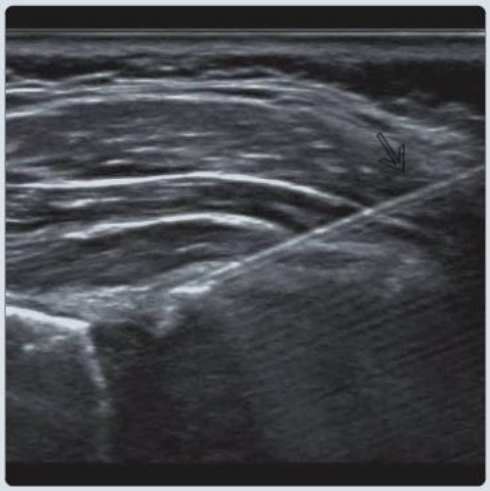

(Left) *Longitudinal US in 3-month-old boy with fever, limited movement, and clinically suspected septic arthritis shows a small hip effusion ⇨. The femoral head ⇨ is, as yet, not ossified.* **(Right)** *US-guided percutaneous aspiration ⇨ yielded a small amount of purulent fluid. This grew Staphylococcus aureus. No sedation was required. US-guided aspiration allows an early and accurate diagnosis of joint infection. Occasionally, septic arthritis is associated with only a small joint effusion.*

Tendinosis Treatment

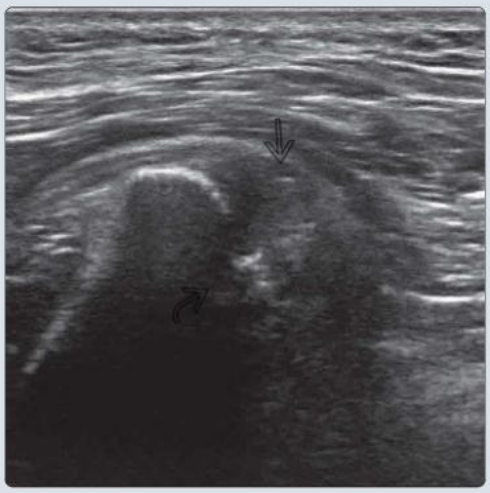

Tendinosis Treatment

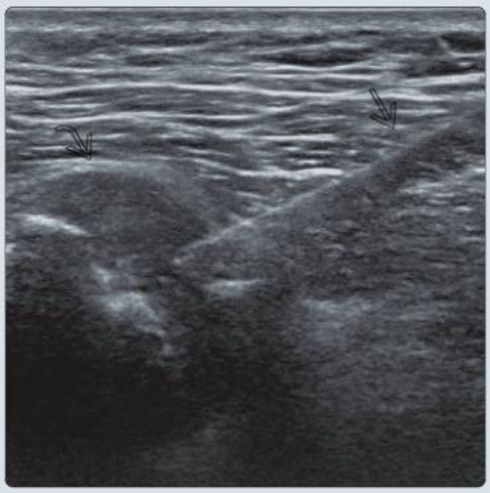

(Left) *Longitudinal US shows moderate to severe tendinosis of the hamstring attachment to the ischial tuberosity. There is thickening of the hamstring tendons ⇨ with irregularity of the ischial tuberosity ⇨ attachment area.* **(Right)** *Longitudinal US shows 20-g spinal needle ⇨ within hamstring tendons ⇨ during injection of 8 mL of platelet-rich plasma (PRP). Prior to PRP injection, the hamstring tendons were fenestrated for 1 minute by moving the spinal needle to and fro through the tendon substance.*

PREPROCEDURE

Indications

- Aspiration or drainage of hip joint fluid
  - Suspected infective or crystal arthropathy
- Hip injection of contrast medium
- Hip or sacroiliac (SI) joint injection for relief of pain or inflammation
  - Steroid, hyaluronic acid injection for painful osteoarthritis or inflammatory arthritis
  - Radiosynovectomy (e.g., yttrium-90, half-life 2.7 days) for chronic synovitis, such as hemophiliac arthropathy
- Tendinosis treatment
  - Tendinosis & partial tears of gluteus medius & minimus, adductor, hamstring, & psoas tendons
  - Fenestration (dry needling), autologous blood injection (ABI), platelet-rich plasma (PRP) injection to stimulate healing response
    - Prior to tendinosis treatment, refrain from antiinflammatory drugs for 2 weeks so as not to limit inflammatory phase of early tissue healing
- Paraarticular cyst or bursal aspiration ± injection
  - Symptomatic or large paralabral cyst or paraarticular ganglion cyst may benefit from aspiration, followed by fenestration & injection of steroid
  - Most clinical "trochanteric bursitis" due to gluteus medius/minimus tendinosis with peritendinitis rather than bursitis; injection of steroid in trochanteric bursa
- Biopsy of synovial tissue for infection, inflammation, or synovial tumor
- Nerve block or neural hydrodissection, diagnostic or therapeutic
  - Lateral femoral cutaneous nerve, ilioinguinal, iliohypogastric, genital branch of genitofemoral nerve, obturator nerve, & pudendal & sciatic nerves
- Iliolumbar ligament injection for relief of pain
- Pyriformis muscle injection
  - For extraspinal sciatica due to compression of sciatic nerve by hypertrophied pyriformis or pyriformis muscle spasm

Getting Started

- Things to check
  - Time-out procedure (patient identity, type, & side of procedure)
  - Discuss risk of infection, allergy, bleeding, neurovascular injury, &, if necessary, tendon rupture
  - Ensure consent form signed
- Medications
  - Local anesthetic for skin: 2-3 mL of 1% lignocaine (optional)
  - Local anesthetic for joint injection: 1% or 2% lignocaine or 0.25-0.50% bupivacaine (Marcaine)
  - Steroid: 40 mg/mL of methylprednisolone (Depo-Medrol), 40mg/mL of triamcinolone
  - Hyaluronic acid: 150 IU (viscosupplementation)
  - CT arthrogram: 10 mL of iodinated contrast (Omnipaque 300 mg/dL ± 0.1 mL1:1,000 epinephrine)
  - MR arthrogram: 10 mL of diluted gadolinium solution (0.1 mL of gadolinium in 10 mL of normal saline solution)
  - PRP: 20-60 mL of blood withdrawn from arm vein & centrifuged for 20 min to separate platelets
  - ABI: 5 mL of blood withdrawn from antecubital vein & injected directly
    - Blood & platelets are rich sources of growth factors for tendon healing
- Equipment list
  - Sterile set, sterile bottles, & specimen bottles
  - 18- to 22-g (3.5") spinal needle, depending upon type of procedure & viscosity of fluid if aspiration undertaken
    - If viscous aspirate expected, use larger bore needle (e.g., 16 or 18 g)
  - Extension tube, 250 mm 8.5F, 0.4 mL of dead space
  - Syringes for local anesthetic, injection, & aspiration
  - Coaxial needle & biopsy needle

PROCEDURE

Procedure Steps

- US-guided joint injection is quicker & as effective as fluoroscopic-guided joint injection
  - **Hip joint injection**
    - Patient lies supine with hip in neutral alignment ± pillow beneath knee to relax anterior part of hip capsule
    - Anterior longitudinal lateral to medial approach usually used, targeting either superolateral quadrant of femoral head or femoral head-neck junction
    - Capsule at neck region thickened by zona orbicularis
    - Use either 5- to 10-MHz linear-array transducer (smaller patient) or 3- to 5-MHz curved array transducer (larger patient)
    - Align transducer parallel to femoral neck
    - Use 3.5", 22-g spinal needle & free-hand technique under real-time US guidance
    - Insert needle until bony contour of proximal femur is contacted; may feel distinct pop as capsule is punctured
    - Relax downward pressure on needle & start injection, turning bevel until free flow of injectate occurs from needle tip
    - Needle tip embedded in reflected synovium at femoral neck may impede fluid flow
      - May need to withdraw needle tiny fraction into anterior synovial recess
    - For osteoarthritis, inject 1 mg (40 mg) of triamcinolone & 4 mL of 0.5% bupivacaine
  - **SI joint injection**
    - Patient lies prone, & 5.0- to 7.5-MHz linear- or curved array transducer is used
    - Distal end of SI joint is slightly easier to see & access than proximal end of SI joint
      - Nevertheless, both proximal or distal ends can be successfully cannulated in most patients
    - Proximal end of SI joint lies at level of S1 foramen
      - With transducer transverse, first identify posterior superior iliac spine laterally & transverse process L5 medially
      - Move transducer caudally, depicting medial & lateral sacral crests
      - At level of S1 foramen, hypoechoic cleft laterally represents SI joint

- Distal end of SI joint lies at level of S2 foramen
  - Move transducer caudally in transverse plane until S2 foramen visualized
  - At level of S2 foramen, hypoechoic cleft laterally represents SI joint
- Use 21-g spinal needle (9 cm)
- Needle orientation almost vertical & same as hypoechoic SI joint cleft
- Transverse transducer approach for initial skin puncture
- Then longitudinal position used to guide needle toward SI joint
- Switch back to transverse transducer position when needle tip reaches entrance to SI joint
- Concentrate on contacting hypoechoic cleft of SI joint & avoiding bony spurs
- Once SI joint contacted, needle can be inserted ~ 1 cm further into joint
- Inject 1 mg (40 mg) of triamcinolone & 5 mL of 0.5% bupivacaine

- **Treatment of tendinosis & tears**
  - Most common indication for pelvic/hip US-guided intervention
    - Gluteus medius tendinosis more common (4x) than gluteus minimus tendinosis
    - Also hamstring, adductor, & psoas tendinosis
  - Fenestration
    - 20-g spinal needle; 1 mL of lignocaine injected over tendon surface
    - Pass needle 20-40x through tendon until tendon softened
  - PRP
    - Undertake tendon fenestration
    - Insert needle to deepest, distal part of tendon, & inject 3 mL of PRP as needle is withdrawn
    - Repeat until PRP injection is complete
  - ABI
    - Undertake tendon fenestration
    - Immediately after fenestration, withdraw 5 mL of blood from antecubital vein & inject into tendon, following similar technique as for PRP
  - Steroid injection
    - 1 mL of 30-40 mg/mL of methylprednisolone or triamcinolone mixed with 8 mL of 0.5% bupivacaine
      - Inject around, rather than within, tendon, as steroid treats peritendinitis rather than tendinosis per se
      - Only repeat 2x after 3 weeks or more
      - Good short-term, but poor long-term, clinical effect
  - Fenestration is as effective as PRP overall for chronic gluteal & hamstring tendinosis
    - PRP may be more effective than ABI, while steroids are least effective, especially in mid- to long term
- **Paraarticular labral/ganglion cyst or bursal aspiration**
  - 21-g needle for cyst aspiration or > 19-g needle for more viscous content
  - ± hyaluronidase (150 U in 2 mL of saline) preaspiration
    - Hyaluronidase is naturally occurring enzyme that degrades hyaluronic acid in paralabral or ganglion cyst
      - Hyaluronic acid (hyaluronan) is glycosaminoglycan, which is major component of extracellular matrix
    - Inject hyaluronidase into cyst; leave needle tip within cyst for 15 min, then aspirate
- **Nerve block & neural hydrodissection**
  - Inject 5 mL of short- or long-acting anesthetic around nerve under direct US guidance
  - For neural hydrodissection, 1-2 mL of triamcinolone or dexamethasone, 1 mL of lignocaine, 7 mL of normal saline ± 1 mL of 5% dextrose
    - Low-concentration (5%) dextrose can reduce neuropathic inflammation
- **Pyriformis muscle injection**
  - 22-g spinal needle through gluteus maximus into pyriformis muscle from lateral to medial approach
  - Inject 1-2 mL of triamcinolone & 3 mL of 1% lignocaine
  - In steroid unresponsive cases, inject botulinum toxin-A 100 U diluted in 2 mL of normal saline
- **Iliolumbar ligament injection**
  - Inject 1-2 mL of triamcinolone/dexamethasone + 2 mL of 1% lignocaine into iliolumbar ligament from medial to lateral approach, targeting posterior superior iliac spine

POST PROCEDURE

Expected Outcome

- Mild discomfort 1-2 days after contrast or medication injection or cyst aspiration

Immediate Aftercare

- Send any aspirate for microbiology, cytology, crystal analysis (need fresh specimen) as appropriate
- Perform MR or CT arthrography within 20 min of contrast injection, as contrast will absorb

Subsequent Aftercare

- After tendinosis treatment, avoid strenuous hip activity for 1 week, gradually building up to normal training activity after 6 weeks

OUTCOMES

Complications

- Most feared complication(s)
  - Infection, e.g., septic arthritis: Avoid traversing infected tissues between skin & joint
  - Extravasation of steroid or radiosynovectomy agent: Fat pad atrophy, skin atrophy, skin depigmentation
- Immediate/periprocedural complication(s)
  - Neurovascular injury, particularly femoral nerve paraesthesia after hip joint injection (2%)
  - Bleeding, capsular rupture, allergic reaction
- Delayed complication(s)
  - Pain for 1-2 days after steroid injection due to steroid-related microcrystalline synovitis
  - Following cyst aspiration, leakage of cyst contents can induce transient chemical cellulitis
  - Mild transient numbness of lower limb for 2-3 days after pyriformis muscle injection

SELECTED REFERENCES

1. Correia R et al: Ultrasound-guided radiofrequency ablation for chronic hip pain due to osteoarthritis. Cureus. 16(2):e53743, 2024

US of Hip

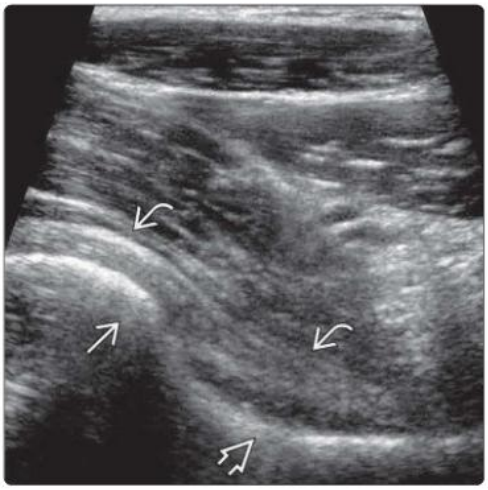

Hip Joint Injection

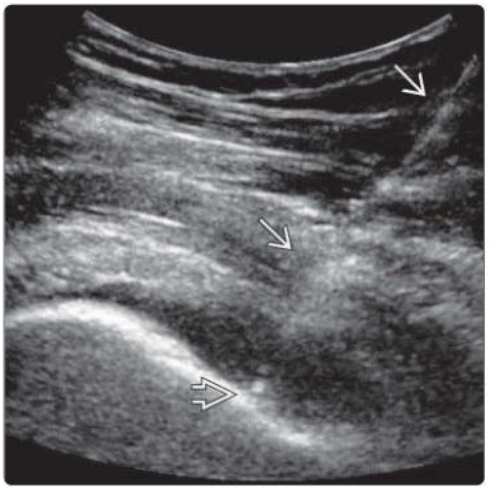

(Left) *Longitudinal oblique US shows a normal femoral head ➡ and neck ➡ with the hip capsule ➡. The capsule is attached to the acetabular rim and the intertrochanteric area. There is a synovial reflection, not seen on US, along the femoral neck.* **(Right)** *Longitudinal oblique US shows a 22-g spinal needle ➡ during contrast injection for hip MR arthropathy. The needle tip contacts the head-neck junction ➡, which is flattened in this patient with femoroacetabular impingement.*

Hip Joint Injection

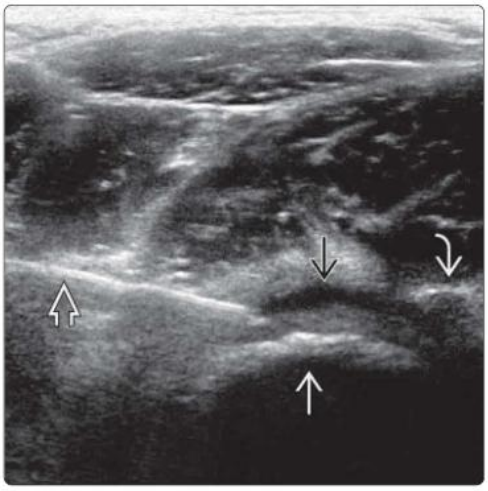

Hip Joint Injection

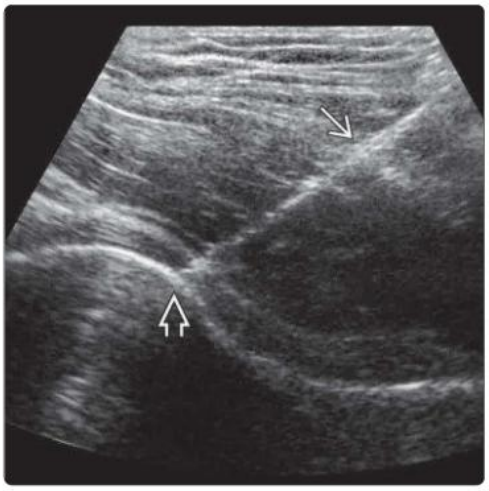

(Left) *Longitudinal oblique US shows an 18-g spinal needle ➡ inserted longitudinally from lateral to medial along the line of the femoral neck. The needle tip lies in the partially distended hip joint ➡. Part of the femoral neck ➡ and the acetabulum ➡ are seen.* **(Right)** *Longitudinal oblique US shows the position of a 22-g spinal needle ➡ for contrast injection prior to hip MR arthropathy. The needle tip contacts the superolateral aspect of the femoral head ➡.*

MR Arthrography of Hip

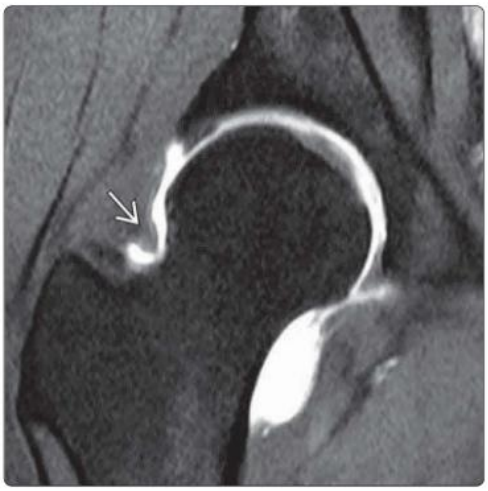

MR Arthrography of Hip

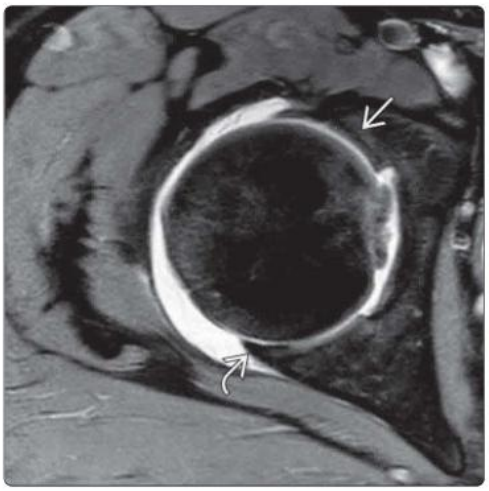

(Left) *Coronal oblique T1 FS MR shows a distended hip capsule following a US-guided injection of 10 mL of contrast medium/normal saline mixture. Note the zona orbicularis ➡ (from circular fibers of the hip capsule), which limits the amount of joint space in this area for US-guided hip injection.* **(Right)** *Axial T1 FS MR arthrography shows the normal acetabular labrum ➡ and the articular cartilage ➡. MR arthrography is particularly useful for revealing chondral injury.*

(Left) *Photograph shows steroid injection preparation prior to either periarticular or articular injection. Typical injection would be 1 mL (40 mg) of triamcinolone, usually mixed with 2-4 mL of 0.5% bupivacaine (long-acting local anesthetic).* **(Right)** *Photograph shows a typical setup with steroid ⇨ and long-acting local anesthetic ⇨ injection. Sterile US gel ⇨ and spinal needle ⇨ (18-22 g with larger needle for aspiration rather than injection) are used. Local anesthetic ⇨ is applied to the skin.*

Steroid Injection

Setup for Hip Joint Injection

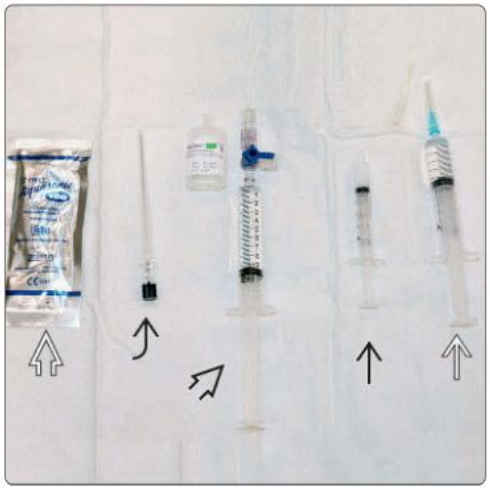

(Left) *Clinical photograph shows skin being cleaned ⇨ with the injection site draped. Always clean from proposed skin entry site to the more peripheral areas rather than vice versa. The US transducer is covered with a sterile probe cover ⇨.* **(Right)** *Clinical photograph in the same patient shows infiltration of local anesthetic ⇨ to the skin. One can also infiltrate anesthetic more deeply around the intended site of the hip capsule puncture.*

Site Preparation

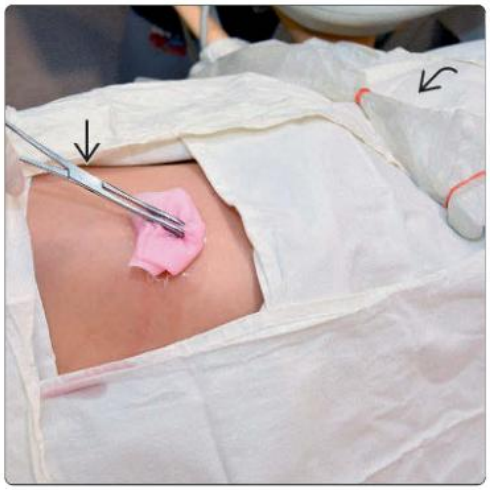

Anesthetic Infiltration

(Left) *Clinical photograph in the same patient shows a 22-g spinal needle ⇨ being guided toward the hip joint under US guidance. Keep the advancing needle in view on US at all times.* **(Right)** *Longitudinal oblique US shows a faint needle track ⇨ with the needle tip ⇨ contacting the midpoint of the femoral neck. About 5 mL of contrast medium ⇨ has been injected, resulting in mild distention of the hip capsule.*

Hip Joint Injection

Hip Joint Injection

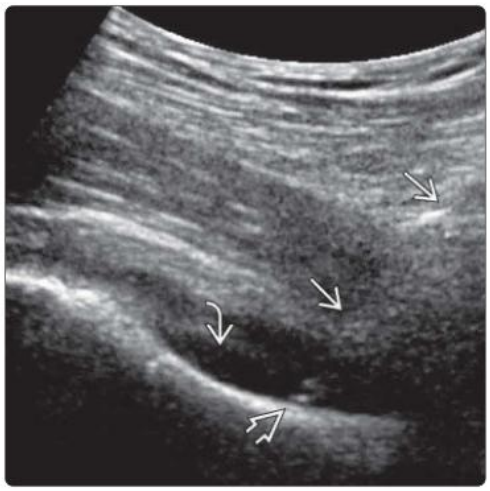

Labral Cyst

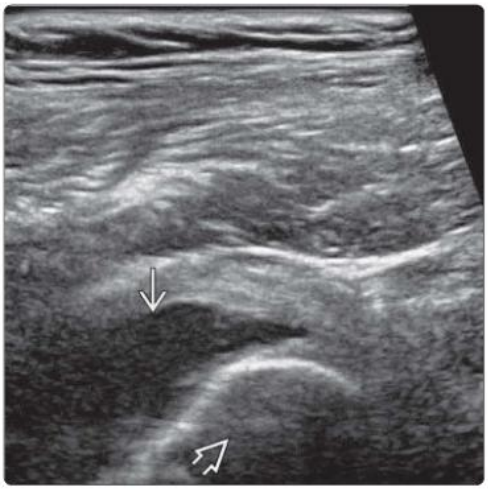

Labral Cyst

(Left) *Longitudinal US shows a quite large hypoechoic intracapsular labral cyst ⇨ at the anterosuperior aspect of the hip joint in a patient with hip pain aggravated by abduction for 3 months. The femoral head ⇨ is normal.* **(Right)** *Coronal oblique intermediate-weighted MR in the same patient shows the large intracapsular labral cyst ⇨. In this case, the cyst lies deep to the hip capsule ⇨. In view of troublesome symptoms, US-guided aspiration was arranged.*

Labral Cyst Aspiration

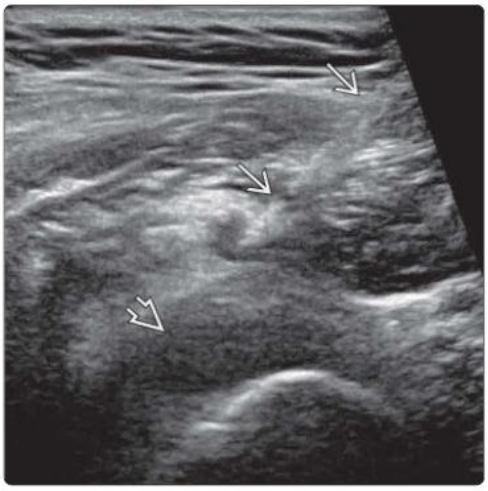

Post Labral Cyst Aspiration

(Left) *Longitudinal US in the same patient shows an 18-g spinal needle ⇨ approaching the labral cyst ⇨ prior to cyst aspiration. Only 1 mL of thick, gelatinous fluid could be aspirated from the cyst.* **(Right)** *Coronal oblique PDWI MR in the same patient 2 weeks following a US-guided labral cyst aspiration shows the cyst ⇨ has markedly reduced in size. Although only 1 mL of fluid could be aspirated from the cyst, it reduced to a greater degree as a result of postprocedure leakage of cyst content.*

Pyriformis Muscle

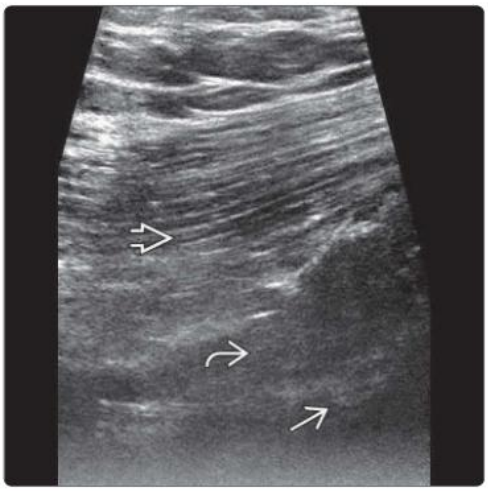

Pyriformis Muscle Injection

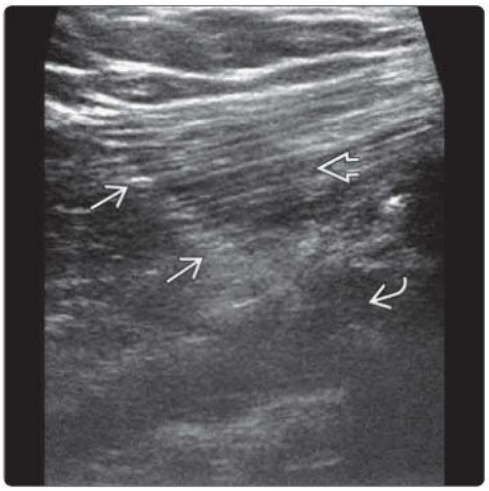

(Left) *Transverse oblique US of gluteus region at level of greater sciatic notch shows the pyriformis muscle ⇨ beneath the gluteus maximus muscle ⇨. Sciatic nerve ⇨ is located deep to the pyriformis muscle.* **(Right)** *Transverse oblique US shows a 22-g spinal needle ⇨ during pyriformis muscle injection. The needle traverses the gluteus maximus muscle ⇨ with the tip of the needle located in the pyriformis muscle ⇨. A mixture of 1 mL of triamcinolone and 3 mL of 1% lignocaine were injected into the pyriformis muscle.*

Gluteus Minimus Tendinosis and Tear

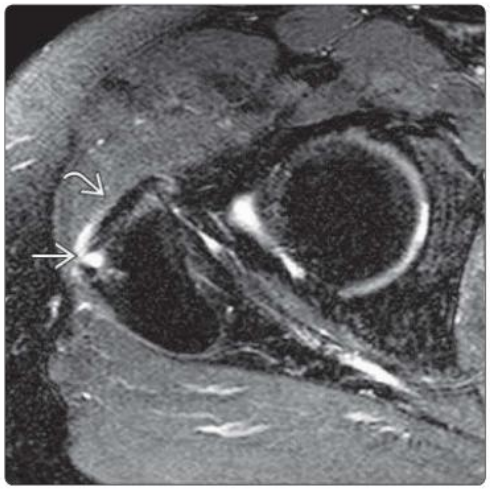

Gluteus Minimus Peritendinitis

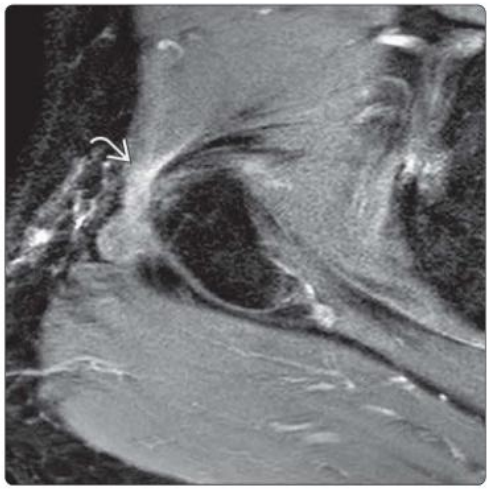

(Left) *Axial T2 FS MR shows mild tendinosis of the gluteus minimus tendon near its insertion into the anterior facet of the greater trochanter. A small avulsive-type tear filled with fluid is also present more laterally.* **(Right)** *Axial T2 FS MR in the same patient shows moderate peritendinitis with edema surrounding the gluteus minimus tendon just proximal to the insertional area. Peritendinitis is a common accompaniment of active tendinosis.*

Gluteus Minimus Tendon Injection

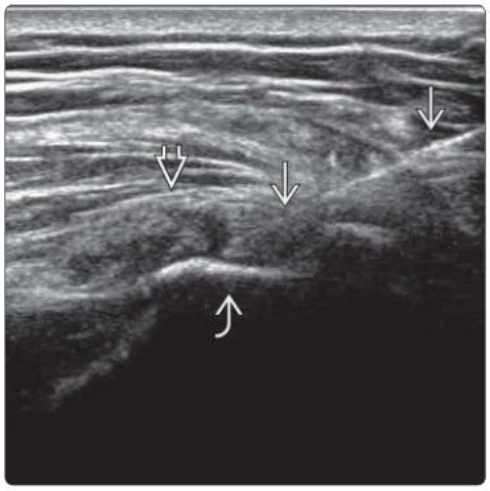

Gluteus Minimus Tendon Injection

(Left) *Transverse US shows moderate gluteus minimus tendinosis with thickening and hypoechogenicity at the greater trochanteric insertional area. A 20-g spinal needle has been inserted deep to the tendon for steroid (1 mL/40 mg of triamcinolone) and long-acting local anesthetic (1 mL of 0.5% bupivacaine) injection.* **(Right)** *Transverse US in the same patient shows an echogenic air loculus at the intratendinous injection site immediately following needle removal.*

Gluteus Medius Tendinosis

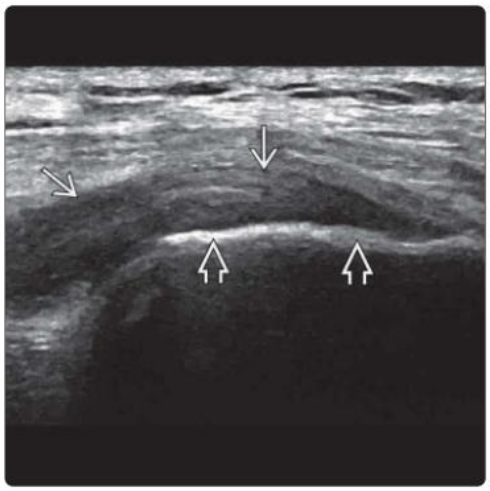

Gluteus Medius Tendon Injection

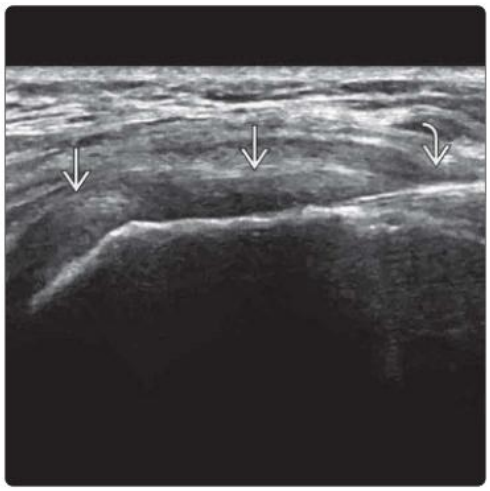

(Left) *Transverse US shows moderate-severity gluteus medius tendinosis with thickening and hypoechogenicity of tendon near the insertional area into lateral and superoposterior facets of greater trochanter. No tendon tear is evident.* **(Right)** *Transverse US in the same patient shows a 20-g spinal needle inserted deep to the peripheral part of the gluteus medius tendon prior to injection of steroid (1 mL/40 mg of triamcinolone) and long-acting local anesthetic (1 mL 0.5% bupivacaine).*

Sacroiliitis

3D CT of Sacrum

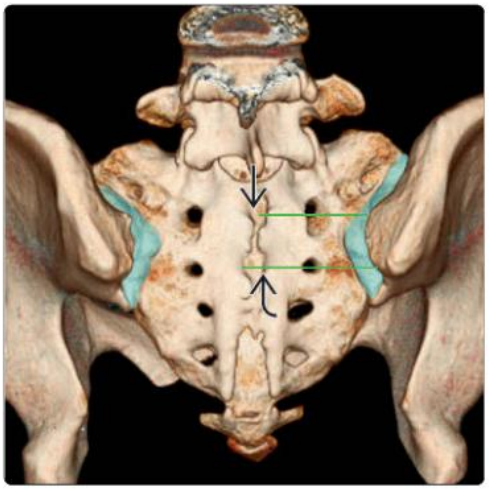

(Left) *Frontal radiograph shows moderate-severity bilateral sacroiliitis. US-guided steroid and long-acting local anesthetic injection is a useful treatment for inflammatory sacroiliitis.* **(Right)** *Coronal 3D CT of the sacrum shows regions of sacroiliac joints (shaded green). The proximal end of the sacroiliac joint is level with the S1 foramen. The distal end of the sacroiliac joint is level with the S2 foramen.*

Upper Aspect of Sacroiliac Joint

Lower Aspect of Sacroiliac Joint

(Left) *Transverse CT shows the proximal end of the sacroiliac joints at the level of the 1st sacral foramen. Note the lateral needle angulation required to enter the dorsal aspect of the sacroiliac joints.* **(Right)** *Transverse CT shows the distal end of the sacroiliac joints at the level of the 2nd sacral foramen. Note the lateral needle angulation required to enter the dorsal aspect of the sacroiliac joint. Either CT, US, or US-CT/MR fusion imaging can be used for needle insertion to the sacroiliac joint.*

Proximal Part of Sacroiliac Joint

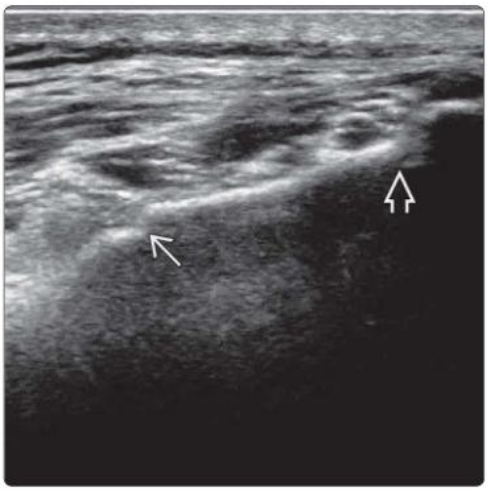

Distal Part of Sacroiliac Joint

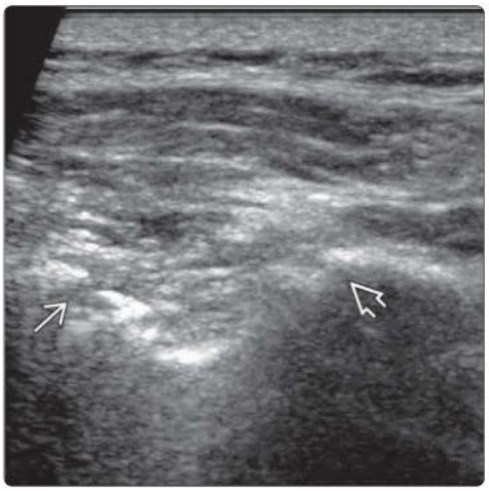

(Left) *Transverse US shows the normal proximal part of the left sacroiliac joint. The S1 neural foramen centrally and the sacroiliac joint peripherally are shown.* **(Right)** *Transverse US shows the normal distal part of the left sacroiliac joint. The S2 neural foramen centrally and the sacroiliac joint peripherally are shown. The lower part of the sacroiliac joint is generally slightly easier to access with US guidance than the upper part.*

KEY FACTS

PREPROCEDURE

- Common indications are joint fluid aspiration, injection of contrast or steroid into joint, tendinosis treatment, cyst or bursal aspiration, anterior cruciate ligament (ACL) ganglion cyst aspiration, barbotage of calcific tendinitis, synovial biopsy, intra- or paraarticular soft tissue mass biopsy

PROCEDURE

- Intraarticular aspiration/drainage of joint fluid or injection
  - Lateral, medial, or suprapatellar recess
  - If no fluid can be aspirated
    - Change position of bevel or reposition needle tip
    - Lower pressure on skin
    - Massage joint fluid toward needle tip
    - Consider changing to larger bore needle
    - ± irrigate with saline solution, then aspirate (joint wash)
- Tendinosis treatment
  - Identify most severe area of tendinosis as this will benefit most from percutaneous intervention
  - Dry needling
  - Peritendinous steroid injection: Good short-term but limited long-term benefit
  - Prolotherapy: Reduces pain severity & area of visible tendinosis on US
  - Autologous blood injection (ABI) or platelet-rich plasma (PRP) injection: PRP has no proven benefit over dry needling or ABI for tendinosis
- Intraarticular & extraarticular soft tissue biopsy
  - Use coaxial needle to prevent multiple punctures

POST PROCEDURE

- Perform MR or CT arthrography within 30 min of contrast injection
- After tendinosis treatment, avoid taking antiinflammatory medication & rest for 2 weeks; gradual building up to normal sporting activity at 6 weeks

US-Guided Aspiration and Steroid Injection

Needle Tip Confirmation

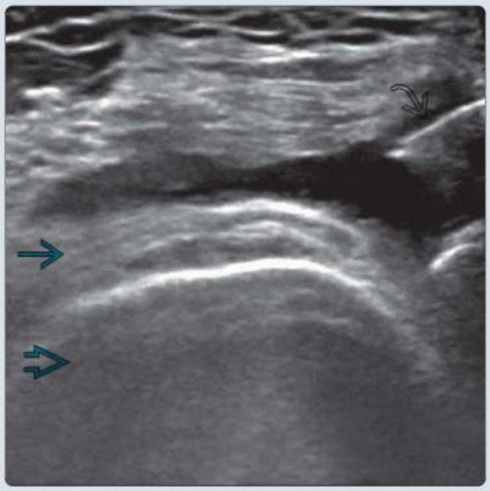

(Left) *Clinical photograph shows a US-guided aspiration of knee joint effusion in a patient with chronic swelling and pain due to severe osteoarthritis shows a 23-g spinal needle ➡ inserted into the medial patellofemoral recess under US guidance.* **(Right)** *Transverse US shows the tip of the needle ➡ within the effusion distending the medial parapatellar recess prior to aspiration. The distal femoral shaft ⇨ and prefemoral subsynovial fat ⇨ are shown.*

Aspiration of Joint Fluid

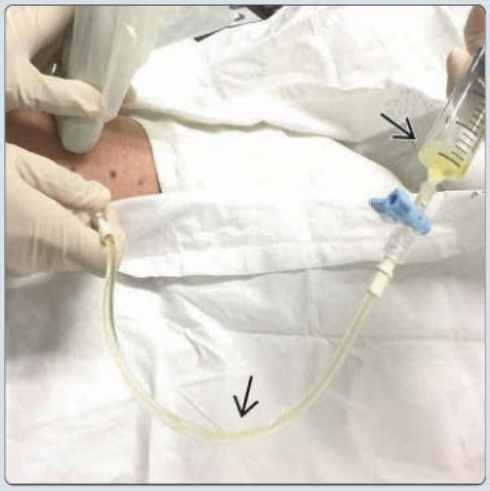

Steroid Injection

(Left) *Clinical photograph of the knee in the same patient during joint aspiration shows straw-colored nonpurulent fluid ⇨ being aspirated from the joint.* **(Right)** *Clinical photograph during injection of steroid ⇨ and local anesthetic into the knee joint following fluid aspiration is shown. The injectate mixture contains methylprednisolone, bupivacaine, and lignocaine.*

PREPROCEDURE

Indications

- Aspiration or drainage of joint fluid
  - Suspected infective or crystal arthropathy
- Intraarticular injection of contrast medium or medication
  - Medication for relief of pain or inflammation
    - Steroid or hyaluronic acid injection for painful inflammatory osteoarthritis or inflammatory arthritis
  - Radiosynovectomy for chronic synovitis, such as hemophiliac arthropathy & inflammatory arthritis
    - Reduces frequency of recurrent clinical & subclinical hemarthroses in patients with hemophilia
      - Decreases likelihood of developing osteoarthritis
    - Decreases intensity of pain & degree of synovial proliferation
  - Arthrography (conventional, CT, or MR)
    - Stability of osteochondral lesion: Contrast insinuating between native bone & osteochondral fragment indicates instability, which may need surgery
    - Evaluation of postoperative meniscus
- Cyst aspiration
  - Symptomatic or large Baker cyst or parameniscal cyst
    - Baker cyst is often due to knee arthropathy & tense knee effusion
      - Reducing size of effusion by intraarticular aspiration can also help reduce size of Baker cyst
    - Parameniscal cyst is usually secondary to horizontal meniscal tear
    - Follow cyst aspiration with intracystic steroid injection
    - Recurrence of Baker cyst more common than parameniscal cyst
- Paraarticular tendon injection
  - Patellar/semimembranosus/quadriceps/pes anserinus tendinosis injection to stimulate healing
  - Dry needling, steroid injection, prolotherapy, autologous blood injection (ABI), platelet-rich plasma (PRP) injection
- Biopsy of synovial tissue for suspected infection, inflammation, or synovial tumor
- Anterior cruciate ligament (ACL) ganglion cyst aspiration
  - Often treated by arthroscopic debridement
  - Can be aspirated under US guidance
- Barbotage
  - US-guided irrigation & aspiration of soft calcium deposits within tendon

Getting Started

- Things to check
  - Time-out procedure (patient identity, type & side of procedure, allergy status)
  - Risk of infection, allergy, bleeding, vascular & nerve injury ± tendon rupture, unsuccessful outcome discussed
  - Informed consent form signed
- Medications
  - Local anesthetic for skin: 2-3 mL of 1-2% lignocaine
  - Local anesthetic for intraarticular injection: 1-2% lignocaine or 0.25-0.5% bupivacaine (Marcaine)
  - Steroid: 40 mg/mL of methylprednisolone (Depo-Medrol), 40 mg/mL of triamcinolone
  - 150 units of hyaluronic acid ("viscosupplementation")
  - Contrast
    - CT arthrogram: 40 mL of iodinated contrast [iohexol (Omnipaque) 300 mg/dL]
    - MR arthrogram: 40 mL of diluted gadolinium solution (0.1 mL of gadolinium in 10.0 mL of normal saline solution)
- Sterile set; spinal or intravenous needle 18- to 23-g; extension tubing; syringes; ± coaxial needle & biopsy needle; sterile specimen bottles, sterile drapes & probe cover

PROCEDURE

Procedure Steps

- **Intraarticular aspiration of joint fluid or injection of medication or contrast medium**
  - Can aspirate either medial or lateral parapatellar recess or suprapatellar recess
    - Patient lies supine, knee flexed slightly (small pillow behind knee)
    - For suprapatellar pouch, probe is placed in sagittal plane superior to patella medial or lateral to quadriceps tendon or in transverse plane superior to patella with quadriceps tendon seen in center of field
    - Flush needle & tubing with injectate beforehand to avoid bubbles being injected
    - Using free-hand technique, advance needle (18- to 23-g) into joint space under real-time imaging
    - If needle tip not seen, move transducer ± jiggle needle to help confirm needle tip position
    - Should be free flow of fluid during aspiration or injection
  - Aspirate as much as possible for decompression
    - If effusion is too thick, consider changing to larger bore needle, e.g., 15- or 16-g
    - If insufficient aspirate, rotate needle to change position of bevel or reposition needle tip
      - Use minimal probe pressure as pressure can displace fluid away from needle
      - Use free hand to massage joint fluid from other parts of joint toward needle tip
    - If still insufficient for sampling, consider irrigating joint with saline solution, then aspirate saline wash & label as joint wash
- **Paraarticular cyst aspiration**
  - Probe placed longitudinally on cyst; larger bore for more viscous content
  - ± hyaluronidase (150 units in 2 mL saline) prior to aspiration
    - Hyaluronidase is human enzyme that degrades hyaluronic acid
    - Inject into cyst, leave needle tip within cyst for 15 min, then aspirate
- **Treatment of tendinosis**
  - Probe positioned over area of most severe tendinosis: Most pronounced loss of fibrillation, tendon thickening, & hyperemia
    - Prone position for semimembranous tendon
    - Knee semiflexed for patellar tendon
  - **Dry needling**
    - Infiltrate local anesthetic (3-5 mL of 1-2% lignocaine) around tendon
    - Position needle tip within area of tendinosis

  - Move needle tip to & fro through tendinosis area for 1 minute
  - May undertake ABI or PRP injection following dry needling
- **Peritendinous steroid injection**
  - 1 mL of 30-40 mg/mL methylprednisolone or triamcinolone mixed with 1 mL of 1% lignocaine ± 1 mL of 0.25% bupivacaine
  - Aimed at peritendinous tissue adjacent to tendinosis area
  - Usually can only be repeated 1x or 2x after several weeks
  - Good short-term but poor long-term clinical effect
  - Helps to treat peritendinitis associated with tendinosis but no known effect on tendinosis per se
- **Prolotherapy (or regenerative injection therapy)**
  - Prolotherapy (proliferative therapy) based on proliferant, such as dextrose → tissue injury → inflammation → accelerated tissue healing
  - 1 mL of 2% lignocaine (20 mg/mL) & 1 mL of 50% dextrose (25 g/50 mL) injected into tendinosis area
    - 4-6 prolotherapy treatments required on average
- **ABI or PRP injection**
  - For ABI: Blood withdrawn from arm vein & injected directly into tendon after dry needling
    - Amount of blood varies with tendon size
    - 2-3 mL of blood is injected for patellar tendon
  - For PRP: Larger amount of blood (usually 20-30 mL) withdrawn from arm vein
    - Blood placed into tube & centrifuged for 20 min to separate platelets from white cells & red cells
    - 3-4 mL of PRP is injected into tendon
  - Use Luer lock syringe for injection into tendon
    - Protects against explosive leakage from syringe due to back pressure during injection
    - Gentle controlled pressure & release technique on syringe plunger during injection will also help prevent syringe leakage
  - May require 2 interventions around 4-6 weeks apart
  - No clear benefit of PRP over ABI or dry needling alone for treatment of tendinosis
    - May hasten recovery period of quadriceps tendon tear
- **Soft tissue mass biopsy**
  - Use coaxial needle to prevent multiple joint punctures
  - For suspected malignant tumor, biopsy should be performed at site of subsequent surgery (tumor surgeon marks likely surgical incision site on skin)
  - For mobile intraarticular lesions
    - Fix lesion with free hand
    - If lesion in suprapatellar recess, flex knee to fix lesion by tightening surrounding structures
- **ACL ganglion cyst aspiration**
  - Patient lying prone, knee extended (small pillow below ankle)
  - Transducer placed transversely over femoral intercondylar region
  - 18-g spinal needle from medial to lateral aspect targeting lateral wall of intercondylar notch at femoral attachment of ACL
  - ± hyaluronidase preaspiration ± steroid injection post aspiration
  - Recommended for well-localized, unilocular cyst near femoral attachment; for poorly localized cyst, arthroscopic excision is recommended
- **Barbotage for calcific tendinitis**
  - For calcific patellar tendinitis associated with soft deposits of calcium
  - 18-g needle into core of calcium & 10-15 mL of warm normal saline + 1% lignocaine pushed into core & aspirated
  - Repeated until most of soft calcium is aspirated
  - Similar to technique used for rotator cuff calcific tendinitis

POST PROCEDURE

Expected Outcome

- Mild discomfort due to reactive synovitis 1-2 days after contrast or medication injection

Immediate Aftercare

- Perform MR or CT arthrography within 20 min of contrast injection
- Send aspirate for microbiology, cytology, crystal analysis (need fresh specimen) as appropriate

Subsequent Aftercare

- Avoid knee exercise for 24 hours after steroid injection to maximize therapeutic effect & reduce spread of steroid into surrounding tissues
- After tendon intervention
  - Avoid taking antiinflammatory medication, which may theoretically impair healing process
  - Rest for 2 weeks, gradually building up to normal training activity after 6 weeks

OUTCOMES

Complications

- Most feared complication(s)
  - Infection (septic arthritis): Avoid traversing infected tissues during joint injection
  - Extravasation of contrast or medication: Steroid or radiosynovectomy agent may cause fat pad atrophy, skin atrophy, skin depigmentation
- Immediate/periprocedural complication(s)
  - Bleeding: Especially in bleeding disorders, e.g., hemophiliac arthropathy being treated with radiosynovectomy
  - Neurovascular injury
- Following ganglion or parameniscal cyst aspiration, leakage of cyst contents through puncture site into surrounding soft tissues can induce chemical-type cellulitis, which lasts ~ 48 hours
- Patellar or quadriceps tendon rarely rupture post-PRP intervention

SELECTED REFERENCES

1. D'Agostino V et al: Ultrasound imaging in knee osteoarthritis: current role, recent advancements, and future perspectives. J Clin Med. 13(16), 2024
2. Bouzid YB et al: Anterior cruciate ligament cysts: about a rare condition. Radiol Case Rep. 18(9):3309-16, 2023

Aspiration of Baker Cyst

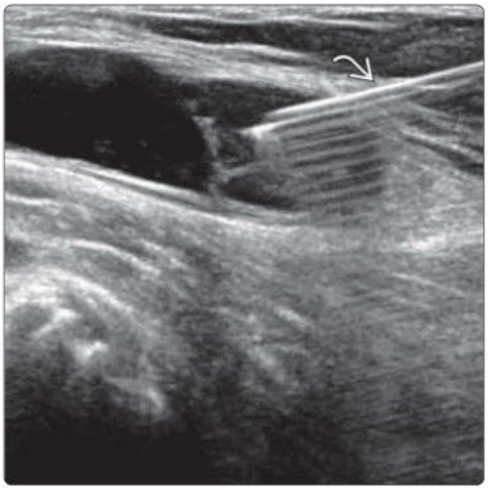

Aspiration of Baker Cyst

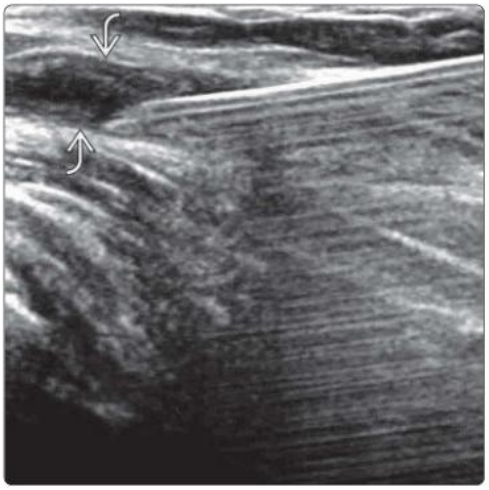

(Left) *Longitudinal US shows a Baker cyst prior to aspiration using an 18-g spinal needle ➡. It is not possible to predict the viscosity of periarticular knee cysts based on US appearances.* **(Right)** *Longitudinal US of the same Baker cyst following aspiration shows almost complete collapse of the cyst. The bursal wall ➡ can still be appreciated.*

US-Guided Aspiration

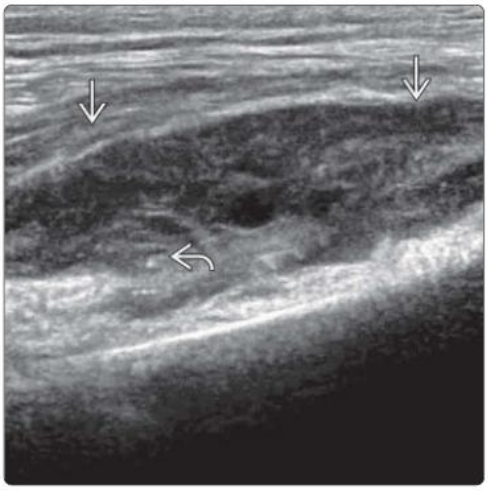

US-Guided Aspiration

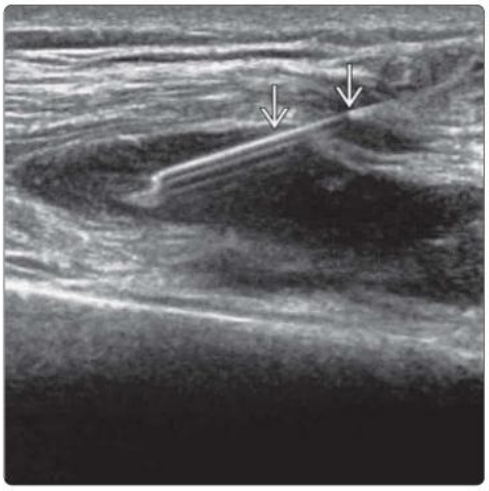

(Left) *Longitudinal US prior to US-guided aspiration of the lateral patellar recess shows severe synovial proliferation ➡ with some small, echogenic foci ➡.* **(Right)** *Longitudinal US shows the same recess during aspiration using an 18-g spinal needle ➡ for culture, crystals, and cytology. This revealed monosodium urate crystals, consistent with gouty arthritis. No bacterial growth was obtained.*

US-Guided Biopsy

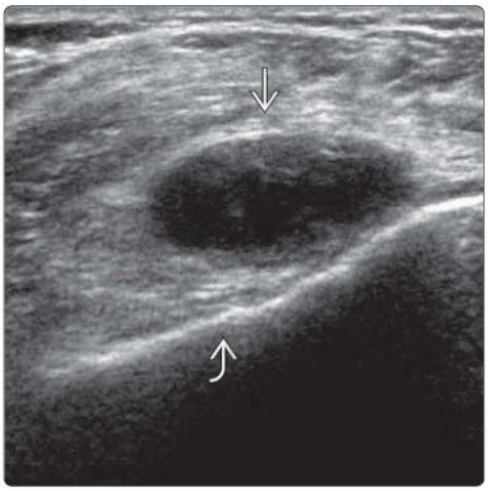

US-Guided Biopsy

(Left) *Longitudinal US prior to biopsy shows an oval-shaped, hypoechoic, intraarticular mass ➡ in the suprapatellar pouch superficial to the distal femur ➡.* **(Right)** *Longitudinal US of the same tumor during US-guided biopsy shows a 16-g biopsy needle ➡ that has been inserted through a 15-g coaxial needle. The needle is positioned in the center of the hypoechoic tumor. Histology confirmed localized pigmented villonodular synovitis (focal nodular synovitis).*

(Left) *Preliminary longitudinal US in a hemophiliac patient shows hemarthrosis of the suprapatellar pouch ⇨ with fine echogenicity of joint fluid.* **(Right)** *Longitudinal US during aspiration shows a 20-g spinal needle ⇨ inserted into the hemorrhagic knee effusion ⇨. Radioactive yttrium was then injected to reduce synovial proliferation. US-guided injection prevents inadvertent extraarticular injection.*

Radiosynovectomy

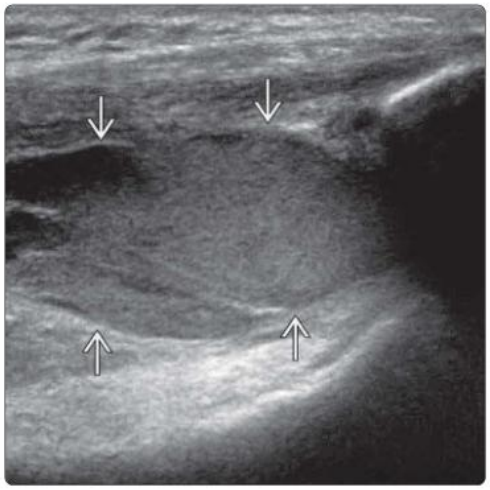

Radiosynovectomy

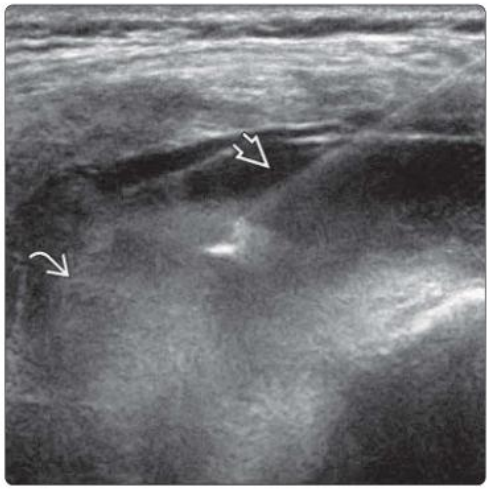

(Left) *Transverse US during dry needling treatment of semimembranosus tendinosis shows a 23-g needle ⇨ present within the hypoechoic semimembranosus tendon ⇨ close to the tibial insertion ⇨. (Courtesy S. James, MD.)* **(Right)** *Transverse US shows dry needling treatment of the distal patellar tendon using a 21-g needle ⇨ inserted into the tendon close to the tibial insertion ⇨. The distal patellar tendon ⇨ is moderately thickened and hypoechoic due to tendinosis. (Courtesy S. James, MD.)*

Dry Needling

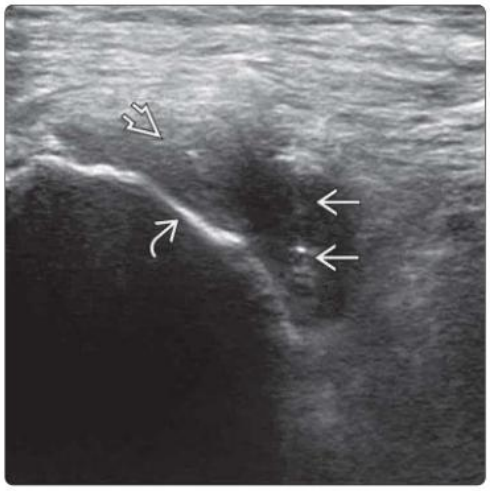

Dry Needling

(Left) *Longitudinal power color Doppler US shows moderate to severe patellar tendinosis with hyperemia, indicative of active disease.* **(Right)** *Longitudinal US shows the knee in the same patient during dry needling using a 21-g needle ⇨. Note the thin rim of anesthetic fluid (1% lignocaine) on the tendon surface ⇨.*

Before Dry Needling and ABI

Dry Needling and ABI

MR of Patellar Tendinosis

Patellar Calcific Tendinitis

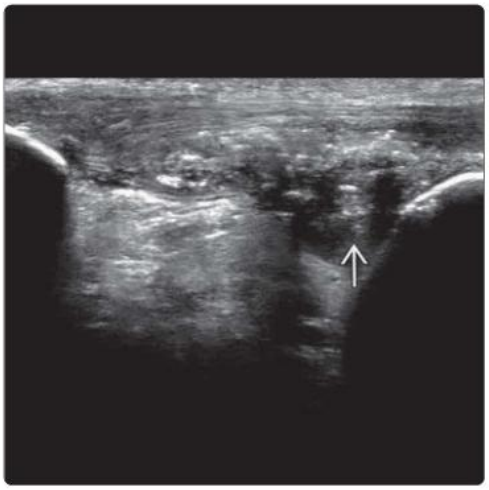

(Left) *Sagittal T2 fat-suppressed MR of the knee shows severe fusiform enlargement of the patellar tendon with intrasubstance T2 hyperintensity ⇨, indicative of patellar tendinosis.* **(Right)** *Longitudinal US of the knee shows thickening of the patellar tendon and soft calcium deposition ➡ on the deeper mid- to distal aspect of the tendon.*

Barbotage Patellar Calcific Tendinitis

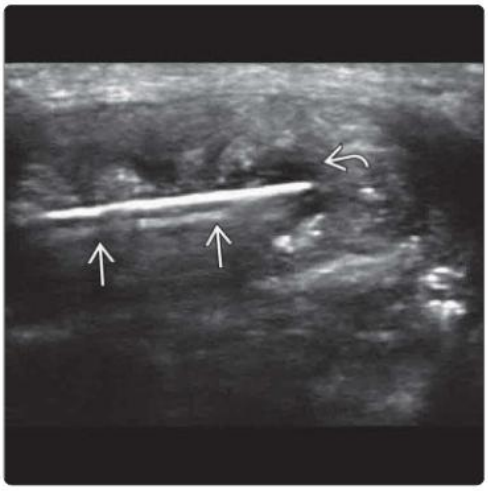

Post Barbotage of Patellar Tendon

(Left) *Transverse US of the knee in the same patient shows an 18-g needle ➡ in the patellar tendon with the tip in the core of calcium. Distention of this core ➡ is evident during push of warm saline and 1% lignocaine.* **(Right)** *Longitudinal US of the knee 6 weeks post barbotage shows near-complete resolution of calcific tendinitis ➡ and normal thickness of the patellar tendon.*

ACL Ganglion Cyst

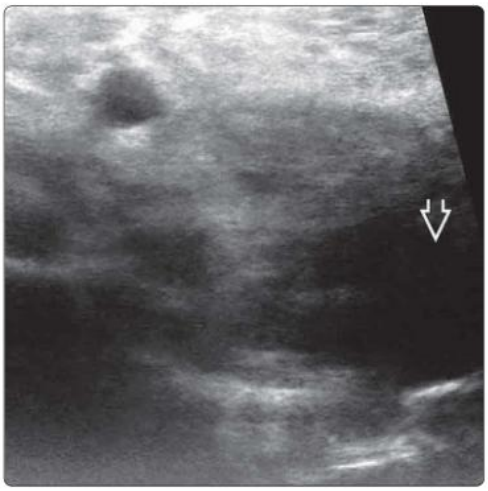

ACL Ganglion Cyst Aspiration

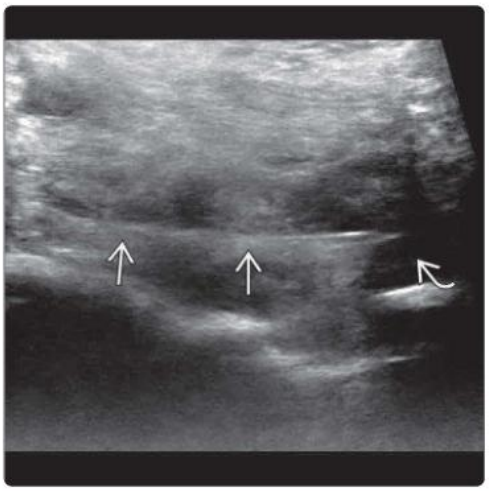

(Left) *Transverse oblique US of the femoral intercondylar region shows anterior cruciate ligament (ACL) ganglion cyst ➡ at the femoral attachment of the ACL.* **(Right)** *Transverse oblique US of the femoral intercondylar region shows an 18-g needle ➡ inserted into the cyst using a medial to lateral approach with the tip in the ACL ganglion cyst ➡.*

(Left) *Photograph shows the setup used for knee joint drainage procedure includes drainage bag ⇨, sutures, pigtail catheter ⇨, dilator ⇨, guidewire ⇨, syringe for aspiration, diamond needle ⇨, scalpel, syringe for local anesthetic, forceps, and cotton buds.* **(Right)** *Clinical photograph shows the preparation of the sterile field at the puncture site with chlorhexidine solution, which minimizes the risk of infection. Sterile drapes are then placed around the puncture site.*

Drainage Set

Prepping Site

(Left) *Clinical photograph shows the suitable puncture site (determined by a prior preliminary US). The puncture site is anesthetized with local anesthetic (3 mL of 1% lignocaine) using a 23-g hypodermic needle. A sterile probe cover is placed around the transducer. Sterile US gel is used during US scanning.* **(Right)** *Clinical photograph shows a stab incision ⇨ of the skin at the anesthetized puncture site. A sharp, small, deep stab incision ensures adequate incision of the subdermal fascia with only a small cutaneous scar.*

Local Anesthetic Applied

Stab Incision

(Left) *Clinical photograph shows the Seldinger technique being used to drain a chronic knee effusion due to low-grade septic arthritis. An 18-g sheathed needle ⇨ is used to puncture the knee capsule under US guidance.* **(Right)** *Clinical photograph shows how needle position can be confirmed by free aspiration of fluid ⇨ from needle. The 1st fluid specimen aspirated is saved and sent for culture, crystals, and cytology. Try not to aspirate all of the effusion since this fluid facilitates subsequent guidewire and catheter insertion.*

Seldinger Technique

Needle Position Confirmed by Aspiration

Guidewire Insertion

Tract Dilatation

(Left) *Clinical photograph after puncture of the knee capsule and US confirmation of needle tip position shows a guidewire ⇨ inserted through the needle into the knee joint. At this stage, the needle should be kept stable and straight to prevent kinking of the guidewire.* **(Right)** *Clinical photograph shows the needle being removed slowly, leaving the guidewire in situ. The tract is serially dilated with a 6-Fr followed by an 8-Fr dilator ⇨. The guidewire should be kept stable to prevent it from slipping out.*

Catheter Insertion

Catheter Fixation

(Left) *Clinical photograph shows that after the tract is fully dilated, an 8-Fr side-hole catheter (pigtail catheter) ⇨ is inserted over the guidewire into the knee joint. US is used to confirm the catheter position within the knee joint. Larger catheters are used for effusions with more complex, viscous fluid.* **(Right)** *Clinical photograph shows the guidewire is gently pulled out, and the catheter is secured by sutures to the skin. Gauze and plastic tape provide additional catheter protection.*

Confirmation by Aspiration

Confirmation by US

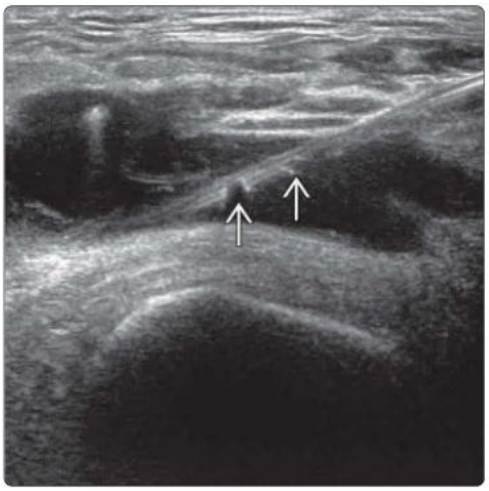

(Left) *Clinical photograph shows a syringe connected to the catheter through a 3-way stopcock with aspiration of as much fluid as possible. The 8-Fr catheter is then connected to a drainage bag for further gravity-assisted drainage.* **(Right)** *Transverse US after the procedure confirms the position of the catheter within the suprapatellar pouch of the knee joint. The catheter side holes ➡ through which knee joint fluid can freely drain are visible.*

KEY FACTS

PREPROCEDURE

- Aspiration or injection of joint fluid, paraarticular (paratenon, Morton neuroma, forefoot bursitis, sinus tarsi) injection, Baxter nerve hydrodissection, & ganglion cyst aspiration are common indications

PROCEDURE

- Joint aspiration or injection
  - Diagnostic to determine site of pain or therapeutic to relieve pain
  - Anterolateral approach to ankle preferred
- Ganglion cyst aspiration
  - 18-g needle for more viscous contents
  - Steroid injection after aspiration is useful even if there is limited content aspirated
- Peritendon injection: Approach depends on site of tendon disease
  - Steroid injection to peritendon region
  - Platelet-rich plasma (PRP) within tendon substance
- For Achilles tendinosis, various treatments & approaches are possible
  - Stimulate healing response: Dry needling, autologous blood, PRP, or prolotherapy
  - Reduce neovascularity: Sclerotherapy, electrocoagulation, or brisement
  - Reduce inflammation: Steroid
- Plantar fasciitis: Medial approach preferable
  - Dry needling, steroid (short acting, preferably)
  - Baxter nerve hydrodissection in refractory heel pain
- Ligament injection: PRP within & around ligament substance
- Morton neuroma: Steroid ± alcohol/radiofrequency ablation (if not responsive)
- Forefoot bursitis: Steroid injection via plantar approach

POST PROCEDURE

- Complete rest for 5 days, then light sports for 3 weeks followed by normal sports in 3 months for Achilles tendon

Plantar Fasciitis Injection

Plantar Fasciitis Injection

(Left) *Clinical photograph shows transverse approach for injection of plantar fasciitis. The patient lies prone on the examination table. The needle ➡ is inserted medially, almost horizontally.* **(Right)** *Transverse US shows steroid injection for plantar fasciitis. A 23-g intravenous needle ➡ is inserted medially. Short-acting steroid (40 mg of hydrocortisone) ➡ is injected superficial to the plantar fascia ➡.*

US-Guided Foot Ganglion Steroid Injection

US-Guided Foot Ganglion Steroid Injection

(Left) *Transverse US shows steroid injection of the ganglion ➡. An 18-g intravenous needle ➡ is inserted into the ganglion. Although no fluid could be aspirated, steroid (20 mg of Depo-Medrol) ➡ was injected.* **(Right)** *Clinical photograph of the same patient shows complete resolution of the ganglion after steroid injection, although no fluid could be aspirated before the steroid injection. The site of previous swelling ➡ is noted.*

PREPROCEDURE

Indications

- Aspiration or intraarticular injection
  - Suspected septic arthritis or crystal arthropathy
  - Therapeutic for control of inflammation or pain relief
  - MR, CT, or conventional arthrography
- Ganglion cyst aspiration: Pain relief
  - ± preaspiration hyaluronidase ± steroid injection post aspiration
- Peritendon therapy: Pain relief
  - Mainly to Achilles, posterior tibialis, & peroneal tendons
- Plantar fasciitis injection: Pain relief
  - Helpful in cases resistant to standard treatment
- Ligament therapy: Pain relief
- Morton neuroma injection: Pain relief
- Forefoot bursal injection: Relief of pain due to submetatarsal or intermetatarsal bursitis
- Sinus tarsi injection: Pain relief
- Baxter nerve hydrodissection: Pain relief
  - Nerve entrapment at tarsal tunnel with refractory heel pain

Getting Started

- Things to check
  - Patient identity & type & side of procedure
  - Signed informed consent
    - Achilles tendon intervention: Risk of tendon rupture
    - Plantar fascia injection: Risk of fascial rupture & heel pad atrophy
    - Superficial steroid injection: Skin depigmentation change, particularly in patients who have had multiple injections & those with darker skin
  - Discuss risk of infection, allergy, & bleeding

PROCEDURE

Procedure Steps

- US-guided procedures are quicker & more effective than fluoroscopic-guided procedures

Joint Aspiration or Injection

- Tibiotalar joint injection
  - Anterior approach: Patient supine, probe in sagittal plane
    - Avoid anterior tibial neurovascular bundle located just medial to midline
    - Anterolateral approach preferred over anteromedial approach as joint laterally is more superficial, capacious, & removed from neurovascular bundle
- Subtalar joint injection
  - Lateral approach: Anterior or posterior, needle passing deep to fibula
  - Posterior approach: Patient in prone position
    - Sweep off Achilles tendon
    - Visualize posterior recess of subtalar joint
    - Posteromedial approach preferred to avoid sural nerve
  - Other approach: Medial approach

Ganglion Cyst Aspiration

- 21-g needle advanced into ganglion
  - 18-g for more viscous content
- ± hyaluronidase injection before treatment
- ± steroid injection post aspiration
- ± fenestration of cyst walls with needle several times during procedure
  - Potentially allows cyst fluid to escape & reduces chance of recurrence

Achilles Tendinosis Treatment

- Patient in prone position with ankle & foot hanging over edge of bed
  - Medial axial approach to avoid sural nerve, which lies in subcutaneous tissues anterior & lateral to Achilles tendon
  - Longitudinal approach
- Stimulate healing response in refractory tendinosis
  - Dry needling: Repeated fenestration of area of localized tendinosis (80% improvement)
    - Often followed by autologous blood injection (ABI) or platelet-rich plasma (PRP) injection
  - ABI or PRP injection: ~ 3 mL injected into area of tendinosis
    - Multiple injections every 2 weeks for 6 weeks seem better than single injection
      - Also, well-vascularized tendons may respond better
    - Followed by complete rest for 5 days, light sports for 3 weeks & normal sports in 3 months
  - Prolotherapy (or regenerative injection therapy) : Local inflammatory response induces stem cell deposition & vascular sclerosant effect
    - 0.5-1.5 mL of hyperosmolar 15-25% dextrose water injected into tendinopathic area following up to 50 fenestrations
    - 2- to 3-week intervals up to 6x
      - Variable response
    - Practical tips for ABI, PRP, or high-volume stripping
      - Use Luer lock syringes for ABI/PRP/saline injection into tendon to guard against explosive leakage due to excessive back pressure
      - Inject blood/PRP/saline using gentle pressure push/release technique to prevent excessive back pressure
- Reduce inflammation
  - Peritendinous injection of 20-40 mg of methylprednisolone or triamcinolone mixed with lignocaine ± bupivacaine
    - 21- or 23-g needle is used for injection
      - High frequency of relapse
- Reduce tendon & paratenon neovascularity
  - Sclerotherapy: Polidocanol (2-4 mL at 5 mg/mL) into peritendinous (not tendon) tissue near vessels
    - Good short-term results
    - Multiple treatments often necessary
  - Electrocoagulation (at 20-25 W): Needle placed against vessels (arteries or veins) entering tendon
    - Effect may be short term
  - Brisement: High-volume (20-40 mL) injection of normal saline, local anesthetic solution (10 mL 0.5% bupivacaine), & steroid (25 mg hydrocortisone) between Achilles paratenon & Kager fat pad
    - Aim is to strip paratenon & Kager fat pad & to clear adhesions

  - Mechanical effect ruptures neovasculature
  - Neural ingrowth accompanying neovessels is also potentially damaged
  - Reduces pain & improves function in both short & long term

Treatment of Other Tendons & Ligaments

- Approach tailored according to particular tendon & ligament segment injected
- ATFL most commonly torn ligament
  - Sprain or partial tear managed conservatively by antiinflammatory medication & immobilization
  - Dry needling: 1-2 mL PRP injection for refractory cases

Plantar Fasciitis Injection

- Refractory plantar fasciitis
- Patient prone with foot hanging over edge of bed
  - Medial axial approach allows local anesthetic to be injected into skin to reduce overall pain of procedure
    - Medial side selected as plantar fasciitis usually affects central band of plantar fascia insertion into medial calcaneal tuberosity
  - Plantar longitudinal approach more painful (thick plantar skin)
- 23-g needle for dry needling ± 2-3 mL PRP injection
- Steroid & local anesthetic mixture then injected deep or superficial to fascia but not into fascia
  - Not possible to inject into fascia
  - Reposition needle during injection to disperse injectate over fascial surface, particularly over medial aspect of fascia close to attachment
- Short-acting (such as hydrocortisone) rather than long-acting steroid preferred in total dose of ~ 40 mg to reduce risk of heel fat pad atrophy
- Baxter nerve entrapment: Refractory heel pain mimicking plantar fasciitis
  - Transducer in oblique coronal plane below medial malleolus
  - 21G needle proximal to distal between adductor hallucis & quadratus plantae muscles
  - 10 mL normal saline + 3 mL 1% lignocaine + 2 mL methylprednisolone for perineural hydrodissection
  - Alternatively, 10 mL 5% dextrose water for perineural hydrodissection reduces neuropathic pain & clear adhesions

Morton Neuroma Injection

- Main bulk of neuroma mass lies plantar to metatarsal heads
- Dorsal (web space) or plantar approaches
  - Dorsal approach preferable
    - Aim to puncture between toes above skin fold in longitudinal plane
    - Transducer is positioned either dorsal or plantar to web space, depending on which is easier, & aligned parallel to needle (longitudinal)
    - Needle inserted into web space almost parallel to transducer
  - Plantar approach
    - Transverse or longitudinal, more painful than dorsal web space approach
- 23-g needle; steroid injection; typically 40 mg of methylprednisolone along with bupivacaine is used
- Provides several months of pain relief
- After 3 months, if good symptomatic relief from 1st injection, 2nd steroid injection can be given
- If neuroma is large (> 5 mm wide) or does not respond to steroid injection
  - Neuroablative therapy with alcohol injection or radiofrequency ablation will help to relieve symptoms

Forefoot Bursal Injection

- Usually plantar approach, rarely dorsal or intermetatarsal approach
- 23-g needle is used for aspiration or steroid injection

Sinus Tarsi Injection

- Probe in coronal oblique plane spanning from anterior process of calcaneus to talar neck, then move probe proximally with rotation & tilting to best see sinus tarsi
- Out-of-plane approach to insert needle to depth of subtalar joint

POST PROCEDURE

Immediate Aftercare

- Joint aspirate should be sent, where appropriate, for
  - Cytology, Gram stain, microscopy & culture (aerobic & anaerobic), & sensitivity; fresh specimen for crystal analysis
- Following tendon injection or fenestration
  - Complete rest for 5 days then light sports for 3 weeks followed by normal sports in 3 months for Achilles tendon
  - Modify rehabilitation plan according to treatment site, type, & frequency

OUTCOMES

Problems

- Discomfort for 1-2 days after intraarticular injection of contrast or steroid, as this can induce chemical synovitis

Complications

- Most feared complication(s)
  - Infection (septic arthritis): Do not inject joint if overlying tissue infected
  - Steroid-induced fat pad atrophy, skin atrophy, or depigmentation
  - Tendon or fascial rupture following steroid, PRP, or ABI
- Immediate/periprocedural complication(s)
  - Bleeding, especially for those with bleeding diathesis
  - Capsular rupture
  - Allergy to injectate
  - Injury to neurovascular bundle
- Delayed complication(s)
  - Delayed allergic reaction (uncommon)
  - Tendon or fascia rupture

SELECTED REFERENCES

1. Kaur H et al: Plantar fasciitis with chronic Baxter's neuropathy causing hindfoot pain - a case report. J Orthop Case Rep. 14(2):150-4, 2024
2. Huang D et al: Effectiveness of platelet-rich plasma in the treatment of Achilles tendon disease. World J Orthop. 14(6):485-501, 2023

Achilles Tendon Injection

Achilles Tendon Injection

(Left) *Clinical photograph shows longitudinal approach for injection of the Achilles tendon. The patient lies prone on the examination table.* **(Right)** *Clinical photograph shows transverse approach for injection of the Achilles tendon. The needle is inserted medially to avoid the sural nerve, which runs superficial and lateral to the Achilles tendon.*

Achilles Tendon Dry Needling

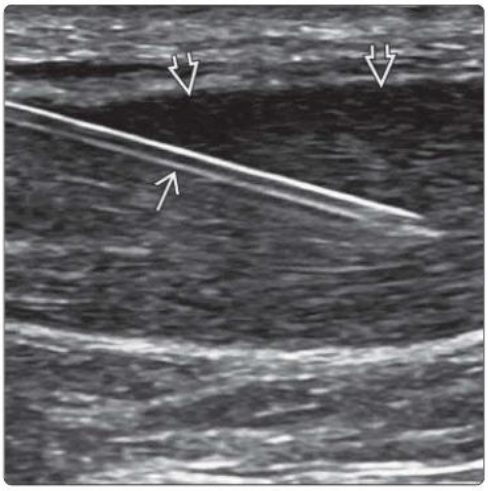

Achilles Tendon PRP Injection After Dry Needling

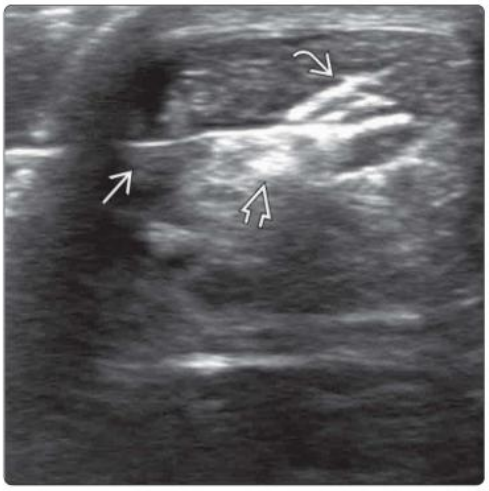

(Left) *Longitudinal US shows dry needling of Achilles tendinosis using a 21-g needle ➡. The hypoechoic rim ➡ superficially is from 1% lignocaine instilled deep to the paratenon prior to dry needling to reduce discomfort during the procedure.* **(Right)** *Transverse US shows platelet-rich plasma (PRP) ➡ injection to Achilles tendinosis using a 21-g needle ➡. The echogenic tracks ➡ are the result of dry needling, which was performed prior to the injection.*

Achilles Tendon High-Volume Injection (Brisement)

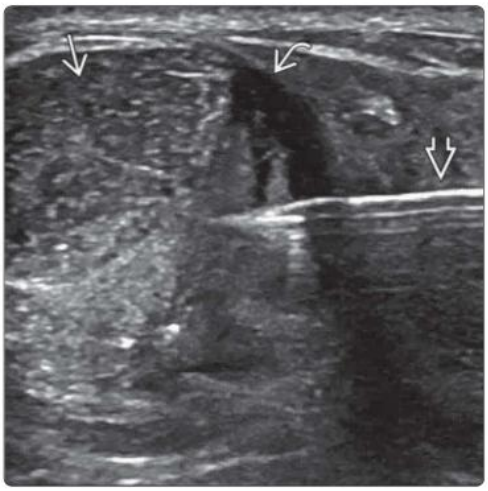

Achilles Tendon High-Volume Injection (Brisement)

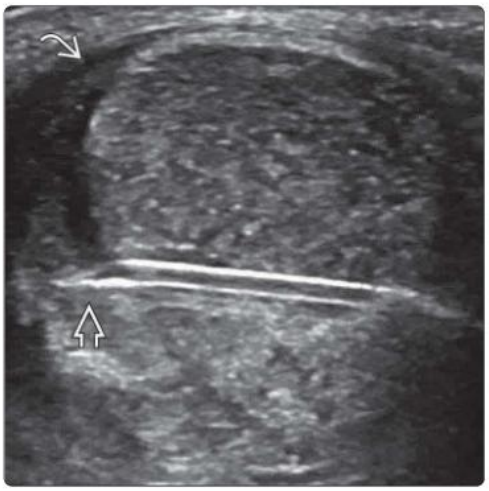

(Left) *Transverse US shows stripping ➡ of the Achilles paratenon ➡ by high-volume injection of a mixture of 10 mL of 0.5% bupivacaine and 40 mL of normal saline using a 21-g intravenous needle ➡.* **(Right)** *Transverse US in the same patient shows advancement of the needle around the tendon to ensure thorough stripping of the paratenon. The bevel ➡ has been turned to face upward to ensure the injection is deep to the paratenon ➡.*

Morton Neuroma Injection

Morton Neuroma Injection

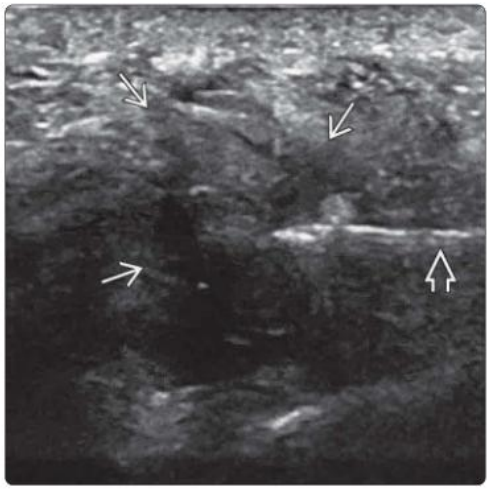

(Left) *Clinical photograph shows dorsal web space approach for injection of Morton neuroma. Patient lies supine on the exam table. The needle is placed between the toes puncturing above the skin fold in a longitudinal plane. The transducer is placed parallel to the needle (longitudinal) either dorsal or plantar to the web space.* **(Right)** *Longitudinal US shows steroid injection of Morton neuroma ➡ via digital web space dorsally. A 23-g needle ➡ is inserted almost parallel to the probe. (Courtesy S. James, MD.)*

Morton Neuroma Injection

Morton Neuroma Injection

(Left) *Clinical photograph shows plantar longitudinal approach for injection of Morton neuroma. Patient lies prone on the examination table.* **(Right)** *Longitudinal US shows a large Morton neuroma ➡. Steroid (40 mg of methylprednisolone) and local anesthetic (5 mL of 0.5% bupivacaine) injection was performed longitudinally on the plantar side via a 23-g needle ➡. (Courtesy S. James, MD.)*

Plantar Fascia PRP Injection

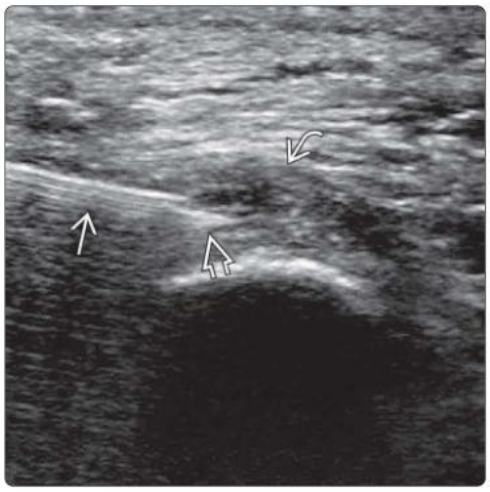

Baxter Nerve Hydrodissection

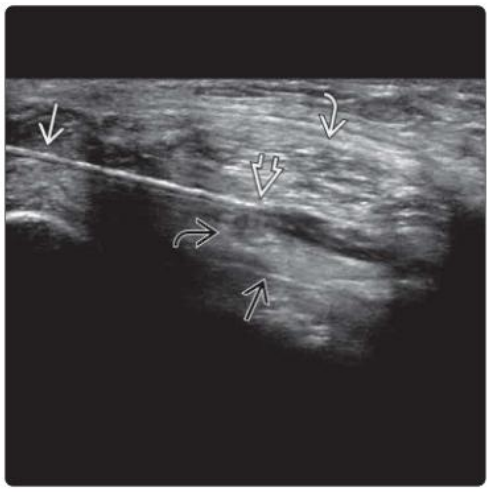

(Left) *Transverse US of plantar fascia shows a 21-g needle ➡ during PRP injection. The needle tip is located in plantar fascia ➡ with fluid cleft ➡ due to PRP injection. The PRP was injected after dry needling.* **(Right)** *Transverse oblique US at the level of tarsal tunnel shows a 21-g needle ➡ in the fascial plane between adductor hallucis ➡ and quadratus plantae muscles ➡. The needle tip ➡ is at the superficial aspect of Baxter nerve during hydrodissection ➡.*

Peroneal Tendon Injection

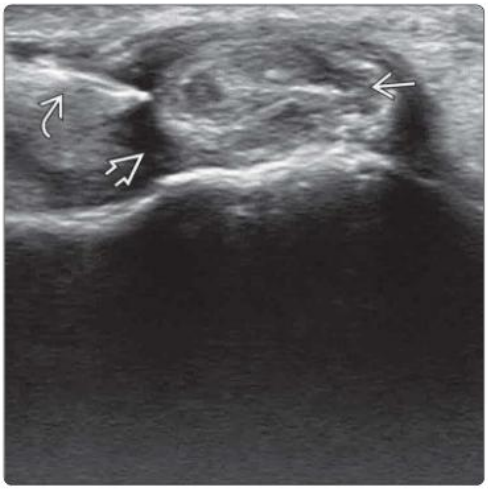

Anterior Talofibular Ligament PRP Injection

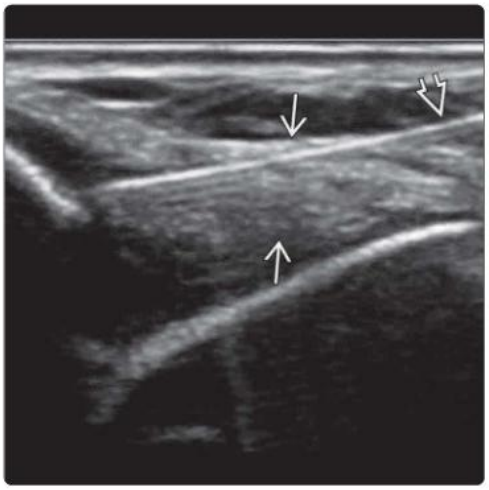

(Left) *Transverse US shows steroid injection (40 mg of methylprednisolone) to the common tendon sheath of the retromalleolar peroneal tendons ⇨ via a 23-g intravenous needle ⇨. The steroid injectate ⇨ will disperse proximally and distally along the tendon sheath. (Courtesy S. James, MD.)* **(Right)** *Transverse US shows chronic thickening of the anterior talofibular ligament ⇨. US-guided PRP injection is performed via a 22-g spinal needle ⇨ into the ligament.*

Ankle Joint Aspiration and Injection

Ankle Joint Aspiration and Injection

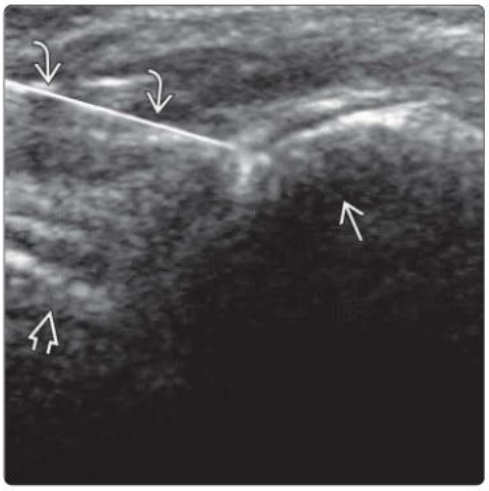

(Left) *Clinical photograph shows longitudinal anterior approach for tibiotalar joint injection or aspiration. Care must be taken to avoid the neurovascular bundle and particularly the deep peroneal nerve, which lies just lateral to the anterior tibial artery at the ankle.* **(Right)** *Longitudinal US shows US-guided injection of tibiotalar articulation. The needle ⇨ as simulated is inserted between the distal tibia ⇨ and talus ⇨ at the talar head-neck junction region.*

Subtalar Joint Injection

Subtalar Joint Injection

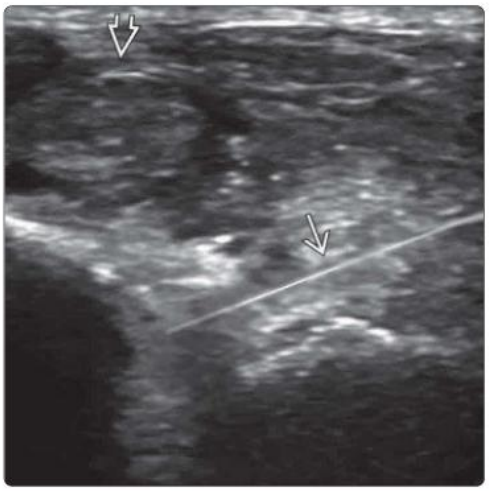

(Left) *Clinical photograph shows longitudinal lateral approach for subtalar joint injection or aspiration. Care must be taken to avoid the peroneal tendons and sural nerve, which lie adjacent to the subtalar articulation laterally. The sural nerve lies deep to the peroneal tendons.* **(Right)** *Longitudinal US shows subtalar joint injection. A simulated 23-g needle ⇨ is present at the anterior edge of the subtalar joint. The peroneal tendons ⇨ are seen lying on the left side.*

This page intentionally left blank

INDEX

A

A1 pulley, **89, 102, 105, 110, 111, 113, 114**
A2 pulley, **89, 102, 110, 111, 112**
A3 pulley, **89, 110, 111**
A4 pulley, **89, 110**
A5 pulley, **89, 110**
Abdomen, **174, 182**
Abdominal obesity, gout and pseudogout, **566**
Abdominal wall, **174–181**
- anterior, **174, 175, 178, 183, 190**
- anterolateral, **179**
- inferior epigastric artery, **180**
- muscles
  anterior, **182**
  of back in situ, **177**
  posterior, **182**
- oblique musculature, **181**
- posterior, **174, 176, 184**

Abdominal wall abscess, abdominal wall hernia vs., **814**
Abdominal wall hernia, **812–819**
- diagnostic checklist, **814**
- differential diagnosis, **814**
- prognosis, **814**

Abdominal wall lesion, **934–939**
- differential diagnosis, **934**

Abdominal wall muscle, **203, 207**
Abdominal wall muscle atrophy, abdominal wall hernia vs., **814**
Abdominal wall seroma, abdominal wall hernia vs., **814**
Abdominal wall tumor, abdominal wall hernia vs., **814**
Abductor digiti minimi muscle, **81, 87, 89, 90, 91, 95, 96, 164, 261, 326, 333**
- fingers, **110**
- foot, **327, 329, 330**
- forefoot, **339**
- forming lateral band, median nerve, **155**
- medial and coronal ankle, **303**
- median nerve, **155**
- thumb, **99**

Abductor digiti minimi tendon, **75, 110**
Abductor hallucis insertion, foot, **327**
Abductor hallucis muscle, **261, 324, 333**
- foot, **327, 329, 330, 331**
- forefoot, **335, 336, 339, 340**
- medial and coronal ankle, **303**
- oblique head, **331, 336**

Abductor hallucis tendon, **331, 336**
Abductor pollicis brevis muscle, **81, 89, 91, 93**
- median nerve, **155**
- oblique head, **99**
- thumb, **98, 99, 100, 103**
- transverse head, **99**

Abductor pollicis longus muscle, **62, 64, 65, 70, 71, 72, 383**
Abductor pollicis longus tendon, **72, 74, 75, 76, 77, 81, 90, 96, 106**
Abductor pollicis muscle, **88, 94**
- thumb, **98, 100**
- transverse head, **100**

Abscess, **637**
- abdominal wall lesion vs., **935**
- chest wall lesion vs., **929**
- cystic soft tissue mass vs., **852**
- hyperechoic subcutaneous mass vs., **835**
- hypoechoic muscle mass vs., **840–841**
- hypoechoic subcutaneous mass vs., **829**
- low-grade, hematoma/seroma vs., **520**
- muscle, muscle infarction vs., **505**
- paraarticular cystic mass vs., **911**
- soft tissue, epidermoid cyst vs., **736**
- soft tissue sarcoma vs., **782**

Accessory axillary vein, **32**
Accessory breast, chest wall lesion vs., **929**
Accessory cephalic vein, **64, 128**
Accessory collateral ligament
- fingers, **114**
- forefoot, **335**

Accessory lateral gastrocnemius slips, **282–283**
Accessory medial gastrocnemius slips, **282–283**
Accessory muscle, chest wall lesion vs., **929**
Accessory ossicle, tendon hyperechogenicity vs., **879**
Accessory soleus muscle, **283**
Acetabular labral junction, anterior hip US, **403**
Acetabular labrum, **234, 235**
Acetabular roof, **234**
Acetabulum, **226, 229, 232**
- anterior column, **227**
- anterior rim, **227**
- medial wall of, **227**
- posterior column, **227**
- posterior pillar, **217, 219, 220, 225, 233**
- posterior rim, **227**

Achilles paratenon, **315**
Achilles tendinosis treatment, procedure, **1023–1024**
Achilles tendon, **260, 299, 313, 321**
- anterior and posterior leg nerves, **295**
- axial, **315**
- lateral ankle, **309**
- leg, **283, 285, 288, 291, 293**
- longitudinal, **314**
- nonrotator cuff tendinosis, **455**
- peroneal nerve, **297**
- posterior ankle US, **420**

INDEX

Acoustic shadowing artifact (posterior acoustic shadowing), **351**
Acoustic-enhancement artifact (increased through transmission), **351**
Acromegaly, swollen nerve vs., **891**
Acromial plexus, **119**
Acromioclavicular (AC) joint, **4–9, 7, 8, 11, 13, 364**
- capsular attachments, **7**
- injection
  - indications, **987**
  - procedure, **989**
- ligaments of, **4**
- muscle attachments of, **4**

Acromioclavicular ligament, **25**
Acromion, **7, 8, 17, 25, 40, 140**
Acromion process, **8, 12, 13, 25, 31**
Active tenosynovitis, chronic, **477**
Acute exudative tenosynovitis, **477**
- peritendinous mass vs., **870**
- tendon swelling vs., **882**

Acute hematoma, **519**
Acute nonexudative tenosynovitis, peritendinous mass vs., **870**
Acute osteomyelitis, **645**
- bone surface lesion vs., **903**

Acute proliferative tenosynovitis, **477**
- tendon swelling vs., **882**

Acute rib fracture, chest wall lesion vs., **928**
Acute seroma, **519**
Acute traumatic fracture, bone surface lesion vs., **903**
Adductor aponeurosis, **105**
Adductor brevis muscle, **192, 194, 197, 199, 208, 218, 236, 238, 240, 242, 245**
Adductor (subsartorial or Hunter) canal, **237**
Adductor hallucis muscle, **340, 341**
- foot, **328**
- oblique head, **332, 335, 340**
- transverse head, **335, 336, 340**

Adductor hallucis tendon, **340**
Adductor hiatus, **244, 255**
Adductor longus muscle, **191, 192, 194, 199, 208, 218, 221, 236, 238, 240, 241, 242, 244, 245, 252, 253**
Adductor magnus muscle, **192, 194, 199, 208, 211, 218, 221, 236, 238, 239, 242, 244, 245, 246, 247, 255**
- ischiocondylar portion, **237, 244**

Adductor pollicis muscle, **88, 89, 91, 94, 100, 105**
- median nerve, **155**
- oblique head, **92, 101, 102, 103**
- transverse head, **92, 94, 101, 102, 103**

Adductor pollicis tendon, insertion, **101**
Adductor tendons and muscles, medial hip US, **403–404**
Adenocarcinoma, hypervascular soft tissue mass vs., **863**
Adenopathy. *See* Lymph node abnormality.
Adhesive capsulitis
- rotator cuff/biceps tendon tear, **448**
- treatment, shoulder, **988**

Adventitial bursae, **679**
AFCN. *See* Anterior femoral circumflex nerve.
Alcock canal region, **210**
Aliasing artifact, **352**
Allograft, bone, bone fracture vs., **536**
Alveolar soft part sarcoma, vascular anomaly vs., **760**
Amyand hernia, **822**
Amyloid, synovial swelling vs., **917**
Amyloidosis
- tendon hypoechogenicity vs., **875**
- tendon swelling vs., **883**

Amyotrophy, neuralgic, swollen nerve vs., **890**
Anconeus epitrochlearis muscle, **158**
Anconeus muscle, **34, 40, 45, 46, 52, 54, 62, 64, 66, 71, 140**
Aneurysm
- cystic soft tissue mass vs., **853**
- hematoma/seroma vs., **520**

Angioleiomyoma. *See* Vascular leiomyoma.
Angiolipoma, **725**
Angiolymphoid hyperplasia, vascular dilatation or inflammation vs., **628**
Angiomyoma. *See* Vascular leiomyoma.
Angiosarcoma, vascular dilatation or inflammation vs., **628**
α angle, **234**
β angle, **234**
Anisotropy, **11, 350**
- ligament injury vs., **528**
- rotator cuff/biceps tendinosis vs., **436**
- tendon hypoechogenicity vs., **874**

Ankle, **298–315**
- Achilles tendon
  - axial, **315**
  - longitudinal, **314**
- anatomy imaging issues, **299**
- anterior, **300, 301**
- anterolateral ligaments, **308**
- coronal, **303**
- deltoid ligament, **307**
- gross anatomy, **298–299**
  - ligaments, **298**
  - osseous anatomy, **298**
  - retinacula, **298**
  - tendons, **298–299**
- lateral, **309, 310–311**
- medial, **303, 304–305**
- medial and posterior ligaments, **306**

Ankle and foot procedures, **1022–1027**
- Achilles tendinosis treatment, procedure, **1023–1024**
- forefoot bursal injection
  - indications, **1023**
  - procedure, **1024**
- ganglion cyst aspiration
  - indications, **1023**
  - procedure, **1023**
- joint aspiration or injection
  - indications, **1023**
  - procedure, **1023**
- Morton neuroma injection
  - indication, **1023**
  - procedure, **1024**
- outcomes, **1024**
- peritendon therapy, indication, **1023**
- plantar fasciitis injection
  - indication, **1023**
  - procedure, **1024**

INDEX

- post procedure, **1024**
- preprocedure, **1023**
- procedure, **1023–1024**
- sinus tarsi injection
  - indication, **1023**
  - procedure, **1024**
- tendons and ligaments, treatment
  - indication, **1023**
  - procedure, **1024**

Ankle (talocrural) joint, **298**
- joint injection, lower limb, **980**
- longitudinal anterior ankle, **302**
- posterior recess, **321**

Ankle US, **418–425**
- anterior, **419**
  - anterior ankle tendons, **419**
  - anterior recess ankle joint, **419**
  - deep peroneal nerve (DPN), **419**
  - extensor digitorum longus (EDL) tendon, **419**
  - extensor hallucis longus tendon, **419**
  - superior and inferior extensor retinacula, **419**
  - tibialis anterior tendon, **419**
- clinical indications, **419**
- lateral, **420**
  - anterior talofibular ligament, **420**
  - anterior tibiofibular ligament, **420**
  - calcaneofibular ligament, **420**
  - peroneal tendons, **420**
  - superficial peroneal nerve, **420**
- medial, **419–420**
  - deltoid ligament, **420**
  - flexor digitorum tendon, **420**
  - flexor hallucis longus tendon, **420**
  - tibial nerve and tarsal tunnel, **419**
  - tibialis posterior (TP) tendon, **419–420**
- posterior, **420**
  - Achilles tendon, **420**
  - plantaris tendon, **420**
  - sural nerve, **420**

Annular ligament, **42, 43, 45, 47, 50, 54**
- lateral elbow US, **376**

Annular pulley thickening, peritendinous mass vs., **870–871**

Antebrachial fascia, **82, 127, 163**

Anterior abdominal wall, groin, **190**

Anterior and posterior divisions, **29**

Anterior ankle, **300, 301**
- US, **419**

Anterior ankle tendons, anterior ankle US, **419**

Anterior aspect of hip joint, anterior hip US, **403**

Anterior circumflex humeral artery, **119**

Anterior compartment
- ankle, **298–299**
- leg, **239, 282, 285**

Anterior cruciate ligament, **278**
- anterior knee US, **411**

Anterior elbow US, **375**
- anterior aspect of elbow joint, **375**
- brachialis, **375**
- distal biceps tendon, **375**
- median nerve, **375**
- radial nerve, **375**

Anterior facet, **222**

Anterior fat pad, **44, 47**
- longitudinal anterior ankle, **302**

Anterior femoral circumflex nerve (AFCN), **200**

Anterior gluteal line, **218**

Anterior hip capsule, **199, 229**

Anterior hip US, **403**

Anterior interosseous artery, **65, 70, 123**

Anterior interosseous nerve, **55, 63, 65, 70, 132, 147, 148, 151**

Anterior interosseous neurovascular bundle, **151**

Anterior interosseous vein, **65, 70**

Anterior knee, US, **411**

Anterior layer of rectus, **183**

Anterior longitudinal ligament, **176**

Anterior longitudinal spinal ligament, **184**

Anterior oblique ligament, **107**

Anterior recess ankle joint, anterior ankle US, **419**

Anterior recurrent tibial artery, **257, 295**

Anterior recurrent tibial nerve, **295**

Anterior superior iliac spine (ASIS), **190, 195, 203, 214, 241, 244, 403**

Anterior suprapatellar (quadriceps) fat pad, **266**

Anterior talofibular ligament, **308**
- lateral ankle, **309, 420**

Anterior tibial artery, **248, 255, 258, 260**
- anterior and posterior leg nerves, **295**
- anterior ankle, **301**
- dorsal foot, **338**
- leg, **284, 285, 287, 290**
- peroneal nerve, **297**

Anterior tibial tuberosity, **269**

Anterior tibial vein, **248, 258, 262**
- anterior ankle, **301**
- leg, **284, 285, 290**

Anterior tibiofibular ligament
- anterolateral ligaments, **308**
- lateral ankle, **309, 420**

Anterior tibiotalar band
- deep deltoid ligament, **307**
- superficial deltoid, medial and posterior ligaments, **306**

Anterior ulnar recurrent artery, **123**

Anteromedial bare area tibia, **286**

Aorta, **178**

AP. *See* Abductor pollicis.

APB. *See* Abductor pollicis brevis.

Apical pulp space, **114**

APL. *See* Abductor pollicis longus.

Aponeurosis, **175, 183, 317**

Apophysitis, traction, ligament injury vs., **528**

Approach to musculoskeletal US. *See* Musculoskeletal US, approach to.

Arcade of Fröhse, radial nerve, **145**

Arcuate artery, **260, 338**

Arcuate ligament, **60**

Arm, **34–41**
- anterior aspect, transverse US, **38**
- anterior compartment, **34, 38**
- anteromedial aspect, transverse US, **37**
- arteries, **122**

- axial, **35, 36**
- coronal, **35**
- fascia, **34**
- median nerve, **146, 147, 149**
- posterior, **40**
  - radial nerve, **140**
  - transverse and longitudinal US, **41**
- posterior compartment, **34, 38**
- posterolateral aspect, transverse US, **39**
- proximal, arteries, **119**
- radial nerve, **138, 141**
- ulnar nerve, **156, 157, 159**
- veins, **122**

Arteries
- chest wall, **168**
- foot, **260**
- hindfoot and midfoot, **318**
- lower limb, **248–263**
- thigh, **249**

Arteriovenous fistula, **627, 628**
Arteriovenous malformation, **759**
Arthritis
- infective, joint effusion vs., **923**
- inflammatory
  - joint infection vs., **656**
  - osteoarthritis vs., **548**
- rheumatoid, gout and pseudogout vs., **566**
- septic
  - gout and pseudogout vs., **566**
  - hemarthrosis and lipohemarthrosis vs., **670**

Arthrography, shoulder, **988**
Arthropathies
- crystal, joint effusion vs., **922–923**
- developmental hip dysplasia, **572–577**
- gout and pseudogout, **564–571**
- hemophilic, synovial tumor vs., **706**
- inflammatory, joint effusion vs., **922**
- inflammatory arthritis, **554–563**
- osteoarthritis, **546–553**

Articular and paraarticular masses
- Baker cyst, **672–677**
- bursitis, **678–689**
- ganglion cyst, **690–699**
- hemarthrosis and lipohemarthrosis, **668–671**
- parameniscal cyst, **700–703**
- synovial tumor, **704–715**

Articular cartilage, **15, 16, 18, 23, 24, 48, 80, 84, 227, 280**
- fingers, **113, 114, 117**
- forefoot, **337**
- posterior talar dome, **321**
- talar dome, **322**

Articular disc, **5, 84**
Aseptic myonecrosis. *See* Muscle infarction.
ASIS. *See* Anterior superior iliac spine.
Attenuation error, artifact due to, **351**
- acoustic shadowing artifact (posterior acoustic shadowing), **351**
- acoustic-enhancement artifact (increased through transmission), **351**

Av pulley, **89**
Avulsion, **527**
Avulsion fracture of medial humeral condyle, ligament injury vs., **528**
Avulsion injury of tendon, tendon hyperechogenicity vs., **879**
Axilla, **28–33**
- arteries, **30**
- brachial plexus, **29**
- lymph node, **33**
- quadrilateral space, **28, 31, 33**

Axillary artery, **28, 29, 32, 119, 120, 136, 137**
Axillary fat, **33**
Axillary nerve, **12, 28, 29, 31, 32, 33, 40, 130, 131, 165**
- radial nerve, **139, 140**

Axillary neurovascular bundle, **29**
Axillary veins, **28, 29, 32, 121, 137**
Axonotmesis, **581, 582**
Azygos vein, **168**

B

Bacteroides, postoperative infection, **662**
Baker cyst, **672–677**
- associated abnormalities, **674**
- cystic soft tissue mass vs., **852**
- diagnostic checklist, **674**
- differential diagnosis, **673–674**
- paraarticular cystic mass vs., **910**
- parameniscal cyst vs., **702**
- prognosis, **674**

Base, axilla, **28**
Basilic vein, **35, 36, 44, 56, 64, 70, 118, 122, 128**
Beam characteristic artifacts, **350**
- anisotropy, **350**
  - ligament injury vs., **528**
  - rotator cuff/biceps tendinosis vs., **436**
  - tendon hypoechogenicity vs., **874**
- beam-width, **350**
- off-axis lobe, **350**
- slice-thickness, **350**

Beam-width artifact, **350**
Benign bone tumor, bone surface lesion vs., **902**
Benign neurogenic tumor, **603**
Benign peripheral nerve sheath tumor, vascular leiomyoma vs., **749**
Benign soft tissue tumor, soft tissue sarcoma vs., **782**
Benign tumor, **789**
Bible bump. *See* Ganglion cyst.
Biceps aponeurosis, **45**
Biceps brachii muscle
- long head, **173**
- median nerve, **147, 149**
- radial nerve, **141, 145**

Biceps femoris muscle, **211, 216, 221, 237, 238, 246, 247, 281**
- conjoint tendon, **220, 238**
- long head, **218, 239, 265**
- short head, **239, 244, 265**

INDEX

Biceps femoris tendon, **257, 274, 288**
- anterior and posterior leg nerves, **295**
- lateral knee US, **412**

Biceps muscle, **36, 37, 38, 44, 52, 57, 63, 66, 132, 137**
- long head, **12, 34, 35, 246**
- medial head, **32**
- median nerve, **148**
- short head, **29, 34, 35, 246**

Biceps tendinosis, **434–445**
- calcific tendinosis, **435**
- diagnostic checklist, **436**
- differential diagnosis, **435–436**
- genetics, **436**
- rotator cuff/biceps tendon tear vs., **448**
- staging, grading, & classification, **436**

Biceps tendon, **14, 15, 16, 17, 18, 19, 20, 37, 42, 44, 45, 46, 47, 48, 49, 50, 55, 57, 63, 64, 68**
- entering shoulder joint, **20**
- insertions, **49**
- intraarticular portion, **20**
- long head, **10, 11, 12, 29, 363**
- longitudinal & transverse US, **49**
- median nerve, **148**
- radial nerve, **145**
- at rotator interval, **8**
- sheath
  - fluid in, **11, 20**
  - procedure, **989**
- short head, **12, 20**
  - acromioclavicular joint, **7**
- tear, **11**
- transverse US, **50**

Biceps tendon tear, **446–453**
- associated abnormalities, **448**
- complete, **447**
- diagnostic checklist, **448**
- differential diagnosis, **448**
- full-thickness, **447**
- massive, **447**
- partial, **447**
- partial-thickness, **447**
- prognosis, **448**

Bicipital aponeurosis, **34, 48, 50, 55, 63, 68, 150**
- median nerve, **147, 148**
- radial nerve, **145**

Bicipital groove, **8, 19**
- lateral lip, **19, 21, 173**

Bicipitoradial bursa, **42**

Bifurcate ligament, **318**
- dorsal foot, **319**
- lateral ankle, **309**

Biopsy
- bone, **950–959**
  - outcomes, **952**
  - preprocedure, **951**
  - procedure, **951–952**
- soft tissue, **942–949**
  - outcomes, **944**
  - post procedure, **944**
  - preprocedure, **943**
  - procedure, **943–944**
- synovial, **960–965**
  - outcomes, **962**
  - post procedure, **962**
  - preprocedure, **961**
  - procedure, **961–962**

Bleeding, bone surface lesion vs., **902**

Blooming artifact ("color bleed"), **352**

Bone biopsy, **950–959**
- outcomes, **952**
- preprocedure, **951**
- procedure, **951–952**

Bone fracture, **534–543**
- diagnostic checklist, **536**
- differential diagnosis, **536**
- prognosis, **536**
- staging, grading, & classification, **536**

Bone infection, **644–653**
- diagnostic checklist, **646**
- differential diagnosis, **646**
- prognosis, **646**

Bone sarcoma, bone infection vs., **646**

Bone surface lesion, **902–907**
- differential diagnosis, **902**

Bone tumor, **788–799**
- diagnostic checklist, **790**
- differential diagnosis, **790**
- local tumor recurrence, **800–809**
  - diagnostic checklist, **802**
  - differential diagnosis, **802**
  - prognosis, **802**
- prognosis, **790**
- recurrence, bone surface lesion vs., **902**
- staging, grading, & classification, **790**

Bone-allograft, bone fracture vs., **536**

Bone-prosthetic junction, bone fracture vs., **536**

Brachial artery, **30, 31, 35, 36, 37, 38, 44, 45, 46, 48, 50, 55, 63, 64, 118, 119, 122, 123, 124, 159**
- bifurcation, **123**
- deep branch, **123**
- median nerve, **148, 149, 150, 151**

Brachial fascia, **34**

Brachial muscle, **64**

Brachial plexus, **29, 130–137**
- axilla, **28**
- axillary area, **130**
- divisions, **131, 371**
- extraforaminal area, **130**
- infraclavicular area, **130**
- interscalene area, **130**
- lateral cord, **131, 147, 165**
- medial cord, **131, 147, 157, 165**
- overview, **133**
- pathology, **602–607**
  - diagnostic checklist, **604**
  - differential diagnosis, **604**
  - prognosis, **604**
- posterior cord, **131, 165**
- supraclavicular area, **130**
- terminal branches, **132, 137**
- transverse US cords, **137**
- transverse US divisions, **136**

- transverse US roots, **134**
- transverse US trunks, **135**
- trunks, **29, 131**
- US, **370–373**
  - benefits, **371**
  - indications for, **371**
  - limitations, **371**

Brachial plexus cord, **29**
Brachial vein, **35, 36, 37, 44, 50, 64, 118, 122, 129, 159**
- median nerve, **149**
- radial nerve, **141**

Brachialis muscle, **34, 36, 37, 38, 39, 41, 44, 45, 47, 48, 49, 50, 51, 52, 55, 57, 63, 66, 125, 132**
- anterior elbow US, **375**
- median nerve, **149, 150**
- radial nerve, **142**

Brachialis tendon, **45, 68**
- muscular part, **47**
- tendinous part, **47**

Brachioradialis muscle, **35, 36, 39, 44, 45, 46, 50, 51, 55, 62, 63, 64, 65, 67, 70, 125**
- radial nerve, **140, 142, 143**

Brodie abscess, **645**
Bursae, **318, 679**
- cystic collection adjacent, bursitis vs., **680**

Bursal distension
- cystic soft tissue mass vs., **852**
- paraarticular cystic mass vs., **910–911**

Bursitis, **678–689**
- diagnostic checklist, **680**
- differential diagnosis, **680**
- parameniscal cyst vs., **702**
- peritendinous mass vs., **871**
- plantar, plantar fasciitis and fibromatosis vs., **720**
- prognosis, **680**
- rotator cuff/biceps tendon tear vs., **448**
- synovial tumor vs., **706**

Bursopathy. *See* Bursitis.

C

C1 pulley, **89, 110**
C2 pulley, **89, 110**
C3 pulley, **89, 110**
C5, **29, 134**
- root, **133**
- spinal nerve, **165**

C6, **29, 134**
- root, **133**
- spinal nerve, **165**

C7, **29, 134**
- root, **133**
- spinal nerve, **165**

C8, **29**
- spinal nerve, **165**
- ventral rami, **157**

Calcaneal insertion, **315**
Calcaneal spur syndrome. *See* Plantar fasciitis and fibromatosis.
Calcaneal tuberosity, **314**
Calcaneocuboid ligament, **323**
- dorsal foot US, **427**

Calcaneofibular ligament
- anterolateral ligaments, **308**
- lateral ankle, **309, 311, 420**
- medial and posterior ligaments, **306**

Calcaneus, **321, 324, 326**
- distal aspect, **323**
- foot, **329**
- lateral ankle, **309**
- lateral border, **308**
- lateral cortex, **311**
- lateral tuberosity, **332**
- lateral wall, **311**
- posterior aspect, **321**

Calcific myonecrosis, calcified soft tissue mass vs., **859**
Calcific tendinitis. *See also* Rotator cuff/biceps tendinosis.
- barbotage for, **1016**
- rotator cuff/biceps tendon tear vs., **448**
- tendon hyperechogenicity vs., **878**
- therapy
  - indications, **988**
  - procedure, **988–989**

Calcific tendinosis, rotator cuff/biceps tendinosis, **435**
Calcification within tendinosis, tendon hyperechogenicity vs., **878**
Calcified soft tissue mass, **858–861**
- differential diagnosis, **858**

Calcifying aponeurotic fibroma, calcified soft tissue mass vs., **858–859**
Calcifying epithelioma of Malherbe. *See* Pilomatricoma.
Calcium pyrophosphate dihydrate (CPPD) arthropathy. *See* Gout and pseudogout.
Canal of Nuck encysted hydrocele, groin hernia vs., **822**
Capillary malformation, **759**
Capitate, **72, 73, 80**
Capitellum, **47, 48**
Capsular ligaments, **13**
- sternoclavicular joint, **4**

Capsule
- anterior, **229**
- fingers, **115, 117**
- knee, **264**
- shoulder, **25**

Carpal bones, **73, 76**
Carpal tunnel, **72, 83, 384**
- median nerve, **146, 153**
- tendons outside, **384**

Carpal tunnel syndrome (CTS), **146, 590–597**
- diagnostic checklist, **592**
- differential diagnosis, **592**
- indications, **1001**
- procedures, **1002**
- prognosis, **592**
- staging, grading, & classification, **592**

Carpometacarpal joint, **106**
- 1st, **73, 106**
- thumb, **391**

INDEX

Carpus, extrinsic ligament dorsum of, **79**
CDH (congenital dysplasia of hip). *See* Developmental hip dysplasia.
Cellulitis, **637**
- hyperechoic subcutaneous mass vs., **834**
- tenosynovitis vs., **478**
Central band, plantar fascia, **329**
Central tendon, of diaphragm, **176, 184**
Cephalic vein, **29, 35, 36, 44, 45, 46, 50, 64, 65, 70, 118, 122, 128, 129, 144**
Cervical radiculopathy, brachial plexus pathology vs., **604**
CETO. *See* Common extensor tendon origin.
CFTO. *See* Common flexor tendon origin.
Charcot-Marie-Tooth disease, swollen nerve vs., **891**
Chest wall, **168–173**
- intercostal spaces, **169, 172**
- lesion, **928–933**
  differential diagnosis, **928**
- pectoralis major muscle, **173**
- ribs, **169, 171**
- sternum, **170**
Chondral injury, focal, osteoarthritis vs., **548**
Chondroid lipoma, **725**
Chondrosarcoma, extraskeletal myxoid, paraarticular cystic mass vs., **911**
Chondrosternal junction, **170, 171**
Chronic active tenosynovitis, **477**
- peritendinous mass vs., **870**
- tendon swelling vs., **883**
Chronic fasciitis, fascial lesion vs., **897**
Chronic hematoma, **519**
Chronic inactive tenosynovitis, **477**
- peritendinous mass vs., **870**
- tendon swelling vs., **883**
Chronic inflammatory demyelinating polyneuropathy (CIDP), swollen nerve vs., **890–891**
Chronic joint deformity, nonrotator cuff tendon tears, **466**
Chronic osteomyelitis, **645**
- bone surface lesion vs., **903**
Chronic seroma, **519**
CIDP. *See* Chronic inflammatory demyelinating polyneuropathy.
Circumflex humeral artery, **30**
Circumflex scapular artery, **119**
Clavicle, **5, 25, 27, 136, 173**
- acromioclavicular joint, **8, 9**
- distal, acromioclavicular joint, **7**
- lateral end of, acromioclavicular joint, **7**
- medial end of, **5, 6**
Cloaca, **645**
Cloquet node, **191**
Collateral branches, **169**
Collateral ligaments
- fingers, **114**
- injury, elbow epicondylitis vs., **488**
Collection, paraarticular cystic mass vs., **911**
Common adductor tendon, **199**
Common carpometacarpal joint, **73**
Common digital artery, **93**
Common digital nerve, **93, 94**
- dorsal foot, **338**
- forefoot, **335**
- plantar foot, **338**
- to thumb, **100**
Common digital tendon sheath, **89**
- fingers, **110**
- thumb, **99**
Common extensor tendon, **42, 43, 45, 53, 66**
Common extensor tendon origin (CETO), **52, 53**
- lateral elbow US, **376**
Common femoral artery, **191, 199, 242, 248, 249, 251, 252**
Common femoral vein, **191, 250, 251, 253, 254**
Common flexor muscle, median nerve, **148**
Common flexor origin, cubital tunnel, **158**
Common flexor sheath, **88, 89, 91**
- fingers, **109**
Common flexor tendon, **42, 43, 44, 45, 63, 68, 158**
- median nerve, **148**
Common flexor tendon origin (CFTO), **56, 57, 59**
- longitudinal & transverse US, **56**
- medial elbow US, **375–376**
- tendinosis with peritendinitis, cubital tunnel syndrome vs., **600**
Common iliac artery, **249, 255**
Common iliac vein, **250**
Common interosseous artery, **123**
Common palmar digital arteries, **126, 127**
Common peroneal artery, anterior and posterior leg nerves, **295**
Common peroneal nerve, **239, 277, 278, 281, 294**
- anterior and posterior leg nerves, **295**
- leg, **284, 289**
Compartment syndrome, muscle infarction vs., **506**
Complete tear
- nonrotator cuff tendon tears, **465**
- rotator cuff/biceps tendon, **447**
Congenital dysplasia of hip. *See* Developmental hip dysplasia.
Congenital hemangioma, **759**
Conjoint biceps femoris-semitendinosus tendon, **209**
- origin, **233**
Conjoint tendon, **90, 115, 221, 246, 247**
Conoid ligament, **9**
Contrast-enhanced US, **347**
Coracoacromial ligament, **7, 11, 12, 17, 25**
Coracobrachial bursa, **10**
Coracobrachialis muscle, **20, 32, 34, 35, 37, 38, 122, 137**
- radial nerve, **141**
- short head, **29**
Coracoclavicular ligaments, **4, 9**
Coracohumeral ligament, **7, 8, 9, 17, 18, 25**
- cable merging with medial limb, **15**
- lateral band, **18**
- lateral limb, **15**
- medial band, **18**
Coracoid process, **8, 9, 10, 12, 17, 22, 35**
- acromioclavicular joint, **7**
Coronoid process, **43, 47, 56, 58**
Cortical irregularity, physiological, bone fracture vs., **536**
Cortical tug lesion, bone surface lesion vs., **903**

Costal cartilage, **169, 170**
- 1st, **5**
- 2nd, **171**
- 4th, **172**
- 5th, **172**

Costochondral junction, **171**
Costochondritis, chest wall lesion vs., **929**
Costoclavicular ligaments, **4, 5, 6**
Cruciate ligament
- anterior, **278**
- knee, **265**

Crural fascia, **221**
Crutch syndrome. *See* Nerve injury.
Crystal arthropathy. *See also* Gout and pseudogout.
- joint effusion vs., **922–923**
- joint infection vs., **656**

Crystal deposition disease
- inflammatory arthritis vs., **556**
- osteoarthritis vs., **548**

Crystalline arthropathy. *See* Gout and pseudogout.
CTS. *See* Carpal tunnel syndrome.
Cubital fossa, median nerve, **148**
Cubital retinaculum, **44, 158**
Cubital tunnel
- longitudinal US, **60**
- medial elbow US, **376**
- transverse US, **59, 60**
- ulnar nerve, **156, 158, 160**

Cubital tunnel syndrome (CUTS), **598–601**
- diagnostic checklist, **600**
- differential diagnosis, **600**
- elbow epicondylitis vs., **488**

Cuboid bone, **316, 322, 324, 333**
- foot, **330**
- proximal aspect, **323**

Cuneiform bones, **316–317, 320, 330**
Cuneiform-cuboid ligament, dorsal foot, **319**
CUTS. *See* Cubital tunnel syndrome.
Cyst
- epidermoid, **734–739**
  - diagnostic checklist, **736**
  - differential diagnosis, **736**
  - hypoechoic subcutaneous mass vs., **830**
  - prognosis, **736**
- trichilemmal
  - epidermoid cyst vs., **736**
  - pilomatricoma vs., **741**

Cystic metastases, paraarticular cystic mass vs., **911**
Cystic periarticular tumor, Baker cyst vs., **674**
Cystic schwannoma
- ganglion cyst vs., **692**
- paraarticular cystic mass vs., **911**

Cystic soft tissue mass, **852–857**
- differential diagnosis, **852**

Cystic-appearing soft tissue tumors, paraarticular cystic mass vs., **911**

D

DDH. *See* Developmental hip dysplasia.
de Quervain disease injection or tenotomy
- indications, **1001**
- procedures, **1001–1002**

Dedifferentiated liposarcoma, **725**
Deep brachial artery, **12, 28, 35, 119**
- ascending branch, **119**

Deep circumflex artery, **249**
Deep circumflex iliac vein, **250**
Deep femoral vein, **250**
Deep gluteal space, hip US, **404**
Deep inferior epigastric artery, **180**
Deep inguinal lymph nodes, **190**
Deep inguinal ring, **190, 196, 395**
Deep palmar arch, **126**
Deep peroneal nerve, **260, 294, 313, 319**
- anterior and posterior leg nerves, **295**
- anterior ankle, **300, 301, 419**
- dorsal foot, **338**
- lateral branch, **319**
- leg, **287, 290**
- medial branch, **319**
- nerves of ankle, **312**

Deep posterior (flexor) compartment, ankle, **299**
Deep transverse metacarpal ligament, **89, 93, 110, 112, 116**
Deep veins, **118, 248**
Deep venous thrombosis
- muscle infarction vs., **505**
- postoperative infection vs., **662**

Deep volar compartment, **65**
Defocusing artifact (edge shadowing artifact), **351**
Delayed-onset muscle soreness. *See* Muscle injury.
Deltoid ligament, **325**
- ankle, **298**
- deep tibiotalar fibers, **321**
- medial ankle US, **420**
- posterior tibiotalar fibers, **321**
- superficial fibers, **323**
- superficial talocalcaneal fibers, **321**

Deltoid muscle, **8, 9, 12, 13, 14, 15, 16, 17, 18, 19, 20, 21, 22, 23, 24, 25, 26, 27, 28, 29, 31, 35, 38**
- anterior aspect, **29**
- posterior aspect, **29**
- radial nerve, **140, 141**

Dermatofibrosarcoma protuberans, **744–747**
- differential diagnosis, **745**
- hypoechoic subcutaneous mass vs., **829**
- prognosis, **745**

Dermatomyositis
- calcified soft tissue mass vs., **859**
- fat injury vs., **498**

Dermoid/implantation dermoid, cystic soft tissue mass vs., **852**
Descending genicular artery, **249**
Desmoid tumor, abdominal wall lesion vs., **935**

INDEX

Developmental hip dysplasia (DDH), **572–577**
- diagnostic checklist, **574**
- differential diagnosis, **574**
- prognosis, **574**

DFSP. *See* Dermatofibrosarcoma protuberans.
Diabetes mellitus
- gout and pseudogout, **566**
- muscle infarction, **506**

Diabetic muscle infarction. *See also* Muscle infarction.
- hypoechoic muscle mass vs., **841**

Diabetic myonecrosis. *See* Muscle infarction.
Diastasis recti, abdominal wall hernia vs., **814**
Digital arteries, **118**
- fingers, **109**
- thumb, **126, 127**

Digital mucous cyst. *See* Ganglion cyst.
Digital nerves
- fingers, **109, 111**
- forefoot, **334**
- hindfoot and midfoot, **318**

Direct inguinal hernia, **821**. *See also* Groin hernia.
Directional ambiguity/indeterminate flow direction artifact, **352**
Distal biceps tendon, anterior elbow US, **375**
Distal carpal row, **72, 93**
Distal humerus, **44**
Distal iliotibial band, lateral knee US, **412**
Distal interphalangeal joint, **113, 114**
Distal phalanx
- fingers, **113, 114**
- thumb, **99, 101**

Distal radial fracture, nonrotator cuff tendon tears, **466**
Distal radioulnar joint, **73, 79, 82, 97**
Distal radius, **72, 76, 77, 78, 79, 80, 82, 86, 97, 127, 144**
Distal tibia, **263, 308**
- anterior surface, anterior ankle, **301**
- lateral aspect, longitudinal anterior ankle, **302**
- medial aspect, longitudinal anterior ankle, **302**
- nerves of ankle, **312**

Distal ulna, **59, 72, 76**
Divarication of rectus abdominis muscles (diastasis recti), abdominal wall hernia vs., **814**
DOMS (delayed-onset muscle soreness). *See* Muscle injury.
Doppler imaging, artifacts in, **351–352**
- aliasing artifact, **352**
- blooming ("color bleed"), **352**
- directional ambiguity/indeterminate flow direction artifact, **352**
- edge, **352**
- flash, **352**
- improper Doppler angle with no-flow artifact, **352**
- mirror (or ghost) image, **352**
- motion artifact, **352**
- noise, **352**
- pseudoflow, **352**
- range ambiguity, **352**
- transducer pressure, **351**
- twinkling, **352**

Dorsal carpal arch, **129**
Dorsal carpal ligament, **322**
Dorsal compartment, **65**
Dorsal digital nerve, 1st toe, **260**
Dorsal digital veins, **128**
Dorsal foot, **319**
- arteries and nerves, **338**
- US, **427**
  - calcaneocuboid ligament, **427**
  - dorsal muscles, **427**
  - dorsal talonavicular ligament, **427**
  - extensor tendons, **427**
  - Lisfranc ligament, **427**
  - 1st metatarsophalangeal joint, **427**
  - subtalar joints, **427**

Dorsal hand US, **391**
- extensor tendon of thumb, **391**
- extensor tendons of fingers, **391**
- ulnar collateral ligament of metacarpophalangeal joint of thumb, **391**

Dorsal intermetatarsal ligament, **319**
Dorsal interossei muscle, **88, 93, 94, 95, 97, 100**
- 1st, **94, 96, 100, 105**
- 2nd, **96**
- 3rd, **96**
- 4th, **90, 96**
- fingers, **105, 108, 114**
- forefoot, **343**

Dorsal interosseous tendon, **115**
Dorsal Lisfranc ligament, **319**
Dorsal metacarpal artery, **129**
Dorsal metacarpal veins, **128**
Dorsal metatarsal arteries, **260**
Dorsal muscles, dorsal foot US, **427**
Dorsal radial ligament, **106**
Dorsal radiocarpal joint space, **80**
Dorsal radioulnar ligament, **84**
Dorsal root ganglion, **133**
Dorsal rootlet, **133**
Dorsal scapular artery, **119, 135**
Dorsal scapular nerve, **29, 165**
Dorsal talonavicular ligament
- dorsal foot, **319, 427**
- lateral ankle, **309**
- medial and posterior ligaments, **306**

Dorsal tarsometatarsal ligament, **319**
Dorsal ulnar cutaneous nerve, **384**
Dorsal venous arch, **128**
Dorsal venous plexus tributary, **129**
Dorsal wrist joint, **383**
Dorsal wrist tendons, **383**
Dorsal wrist US, **383–384**
- 1st extensor compartment [abductor pollicis longus (APL) and extensor pollicis brevis (EPB)], **383**
- 2nd extensor compartment (extensor carpi radialis longus and extensor carpi radialis brevis), **383**
- 3rd extensor compartment [extensor pollicis longus (EPL)], **383**
- 4th [extensor digitorum (ED), extensor indicis proprius (EIP) and 5th [extensor digitorum minimi (EDM)] extensor compartments, **383**
- 6th extensor compartment [extensor carpi ulnaris (ECU)], **383**

- dorsal ulnar cutaneous nerve, **384**
- dorsal wrist joint, **383**
- dorsal wrist tendons, **383**
- posterior interosseous nerve, **383–384**

Dorsalis pedis artery, **257, 260, 261, 320**
- anterior and posterior leg nerves, **295**
- anterior ankle, **301**
- longitudinal anterior ankle, **302**

Dorsum hand, **96, 97**
Double hernia, **821**
DPN. *See* Deep peroneal nerve.
Drug hypersensitivity, fat injury vs., **498**
Dupuytren contracture
- indications, **1001**
- procedures, **1002**

Dupuytren disease, fascial lesion vs., **897**

E

ECRB. *See* Extensor carpi radialis brevis muscle.
ECRL. *See* Extensor carpi radialis longus muscle.
ECU. *See* Extensor carpi ulnaris.
ED. *See* Extensor digitorum muscle.
EDC. *See* Extensor digitorum communis.
Edema
- severe, tenosynovitis vs., **478**
- subcutaneous, soft tissue infection vs., **638**

Edge artifact, **352**
Edge shadowing artifact, **351**
EDL. *See* Extensor digitorum longus.
EDM. *See* Extensor digiti minimi.
Effusions, associated with intraarticular pathology, Baker cyst, **674**
Elastofibroma dorsi, chest wall lesion vs., **929**
Elastography, **347**
- shear wave, **347**

Elbow, **42–61**
- anatomy imaging issues, **42**
- anterior
  - longitudinal US, **47**
  - transverse US, **48**
- anterior aspect of, **375**
- anterolateral, transverse and longitudinal US, **51**
- capsule, **47**
- common extensor tendon origin, **52**
- coronal, **43**
- distal, cross section, **46**
- gross anatomy
  - bursae, **42**
  - joint capsule attachments, **42**
  - ligaments, **42**
  - tendons, **42**
- joint, **47**
- lateral, **52**
- median nerve, transverse US, **150**
- mid, cross section, **45**
- posterior, longitudinal & transverse US, **61**
- proximal, cross section, **44**
- radial nerve, **145**
- transverse anteromedial, **55**

Elbow epicondylitis, **486–493**
- differential diagnosis, **488**
- prognosis, **488**
- staging, grading, & classification, **488**

Elbow joint area, **59**
Elbow joint space, **53**
Elbow procedures, **994–999**
- intraarticular aspiration or injection
  - indications, **995**
  - procedure, **995**
- outcomes, **996**
- paraarticular aspiration
  - indication, **995**
  - procedure, **995**
- post procedure, **996**
- preprocedure, **995**
- procedure, **995–996**
- tendinosis treatment
  - autologous blood, **996**
  - corticosteroid injection, **996**
  - dry needling, **996**
  - indications, **995**
  - platelet-rich plasma, **996**
  - procedure, **995–996**
  - prolotherapy, **996**

Elbow US, **374–381**
- anterior, **375**
  - anterior aspect of elbow joint, **375**
  - brachialis, **375**
  - distal biceps tendon, **375**
  - median nerve, **375**
  - radial nerve, **375**
- clinical indications for, **375**
- lateral, **376**
  - annular ligament, **376**
  - common extensor tendon origin, **376**
  - lateral ulnar collateral ligament, **376**
  - radial collateral ligament, **376**
  - synovial fold, **376**
- medial, **375–376**
  - common flexor tendon origin (CFTO), **375–376**
  - cubital tunnel, **376**
  - medial collateral ligament complex, **376**
- posterior, **376**
  - triceps tendon, **376**

Encysted hydrocele, canal of Nuck, groin hernia vs., **822**
Endometriosis, abdominal wall lesion vs., **935**
Endothoracic fascia, **169**
Enlarged lymph node, abdominal wall lesion vs., **934**
Enterobacter, bone infection, **646**
Enterococcus, postoperative infection, **662**
Enthesopathic fasciitis, fascial lesion vs., **896–897**
Eosinophilic fasciitis, fascial lesion vs., **897**
EPB. *See* Extensor pollicis brevis muscle.
Epicondyle-olecranon groove. *See* Cubital tunnel syndrome.
Epicondylitis
- elbow, **486–493**
  - differential diagnosis, **488**
  - prognosis, **488**

INDEX

staging, grading, & classification, **488**
- ligament injury vs., **528**
Epidermal cyst. *See* Epidermoid cyst.
Epidermal inclusion cyst. *See* Epidermoid cyst.
Epidermoid cyst, **734–739**
- diagnostic checklist, **736**
- differential diagnosis, **736**
- hyperechoic subcutaneous mass vs., **834**
- hypoechoic subcutaneous mass vs., **828**
- lipoma vs., **726**
- pilomatricoma vs., **741**
- prognosis, **736**
Epigastric hernia, **813**
EPL. *See* Extensor pollicis longus muscle.
Equipment-generated artifact, **351**
Erector spinae muscles, **169, 171, 174, 178, 181, 182, 185**
Erosive osteoarthritis, inflammatory, inflammatory arthritis vs., **556**
Escherichia coli
- joint infection, **656**
- postoperative infection, **662**
Esophagus, **176, 184**
Extended field-of-view imaging, **347**
Extensor apparatus, **103**
Extensor carpi brevis tendon, **77**
Extensor carpi radialis brevis muscle, **45, 46, 51, 52, 62, 64, 65, 66, 70, 71, 72, 125, 383**
Extensor carpi radialis brevis tendon, **70, 72, 74, 75, 76, 80, 97**
Extensor carpi radialis longus muscle, **36, 44, 45, 46, 52, 53, 62, 64, 65, 66, 70, 71, 72, 383**
Extensor carpi radialis longus tendon, **70, 72, 74, 75, 76, 77, 97**
Extensor carpi ulnaris muscle, **46, 52, 62, 64, 65, 66, 70, 71, 72, 79, 84, 383**
Extensor carpi ulnaris tendon, **74, 75, 76, 79, 80, 84, 90, 96**
Extensor compartments, dorsal wrist US
- 1st, **383**
- 2nd, **383**
- 3rd, **383**
- 4th, **383**
- 5th, **383**
- 6th, **383**
Extensor digiti minimi muscle, **62, 64, 65, 70, 71, 72, 108**
Extensor digiti minimi tendon, **72, 74, 75, 76, 79, 90, 96, 97, 108**
Extensor digitorum brevis muscle, **322**
- anterior ankle, **300**
- dorsal foot, **319**
Extensor digitorum communis tendon, **90, 97**
- 2nd digit, **96**
- 4th, **96**
- 5th digit, **96**
- fingers, **108, 109, 114, 115**
Extensor digitorum longus muscle
- anterior ankle, **301**
- forefoot, **343**
- leg, **282, 284, 286, 288, 289, 290**
- tibial nerve, **296**
Extensor digitorum longus tendon, **299, 322**
- anterior ankle, **300, 301, 419**
- forefoot, **335**
- leg, **284, 286, 288**
Extensor digitorum minimi (EDM), **383**
Extensor digitorum muscle, **45, 46, 52, 62, 64, 65, 66, 70, 71, 72, 78, 383**
- leg, **290**
- peroneal nerve, **297**
Extensor digitorum superficialis muscle, **82**
Extensor digitorum superficialis tendon, **82**
Extensor digitorum tendon, **74, 76, 78, 79, 80, 97, 117, 321, 322, 325**
- fingers, **114, 115, 116, 117**
- insertional area, **117**
- leg, **285**
- slips, **75, 116**
Extensor expansion
- fingers, **116**
- hand, **88**
- thumb, **98**
Extensor hallucis brevis muscle, **322**
- anterior ankle, **300**
- dorsal foot, **319**
Extensor hallucis longus muscle
- anterior ankle, **301**
- leg, **284, 285, 286, 290**
Extensor hallucis longus tendon, **322**
- anterior ankle, **300, 301, 419**
- leg, **286**
- longitudinal anterior ankle, **302**
Extensor hallucis muscle, **282**
Extensor hood, **90, 103, 104, 105, 114, 115**
Extensor indicis muscle, **62, 65, 70, 71, 72, 108**
Extensor indicis proprius (EIP), **383**
Extensor indicis tendon, **74, 75, 78, 90, 96, 108**
Extensor minimi muscle, **52, 66**
Extensor pollicis brevis muscle, **62, 70, 72, 98, 383**
Extensor pollicis brevis tendon, **72, 74, 75, 76, 77, 81, 90, 96, 103, 104**
Extensor pollicis longus muscle, **62, 64, 65, 70, 71, 72, 98, 383**
Extensor pollicis longus tendon, **72, 74, 75, 76, 77, 78, 79, 90, 96, 97, 103, 104, 107**
- distal insertion, **103**
- insertion, **103**
Extensor retinaculum, **72, 74, 76, 77, 78, 79, 80, 84, 90, 322**
- anterior and posterior leg nerves, **295**
- thickening, peritendinous mass vs., **871**
Extensor tendons
- dorsal foot US, **427**
- fingers, **109, 391**
- forefoot, **343**
- thumb, **391**
External iliac artery, **180, 193, 194, 196, 204, 255**
External iliac vein, **180, 193, 194, 204**
External iliac vessels, groin, **190**
External intercostal muscle, **169, 172**
External oblique aponeurosis, **203**

External oblique muscle, **174, 175, 177, 178, 181, 182, 183, 185, 190, 192, 194, 202, 203, 218**
External pudendal artery, **249**
Extraskeletal myxoid chondrosarcoma, paraarticular cystic mass vs., **911**
Extrinsic carpal ligament, **76, 153**
Extrinsic ligaments, wrist, **72**
Exudative tenosynovitis, acute, **477**

F

Fabella, **279**
Fabellofibular ligament, **274**
Facet joint, **169**
False aneurysm. *See* Vascular dilatation or inflammation.
False ribs, **168**
Fascia lata, **239**
Fascial lesion, **896–901**
- differential diagnosis, **896**

Fascial tear
- investing, fascial lesion vs., **897**
- plantar
  - fascial lesion vs., **896**
  - plantar fasciitis and fibromatosis vs., **720**

Fasciitis
- chronic, fascial lesion vs., **897**
- enthesopathic, fascial lesion vs., **896–897**
- eosinophilic, fascial lesion vs., **897**
- infective, **637**
  - fascial lesion vs., **897**
- necrotizing, **637**
  - fascial lesion vs., **897**
- nodular, fascial lesion vs., **897**

Fat injury, **496–503**
- diagnostic checklist, **498**
- differential diagnosis, **498**
- prognosis, **498**

Fat necrosis
- abdominal wall lesion vs., **935**
- calcified soft tissue mass vs., **859**
- cystic soft tissue mass vs., **853**
- hyperechoic subcutaneous mass vs., **835**
- hypoechoic subcutaneous mass vs., **829**
- of newborn, subcutaneous, fat injury vs., **498**

Fat pads, knee, **264**
Fat trauma, lipoma vs., **726**
Fatty replacement, hyperechoic muscle mass vs., **846**
Fatty tumor. *See* Lipoma.
FB. *See* Foreign body and injection granuloma.
FCR. *See* Flexor carpi radialis muscle.
FCU. *See* Flexor carpi ulnaris muscle.
FDP. *See* Flexor digitorum profundus muscle.
FDS. *See* Flexor digitorum superficialis muscle.
Femoral artery, **193, 197, 205, 206, 227, 232, 238, 239, 251**
Femoral canal, **191, 237, 395**
- groin hernia, **821**

Femoral condyle, **256**
- lateral, **275, 276, 278**
- medial, **271, 272, 273, 279**

Femoral head, **199, 226, 229, 232, 233, 234**
- ossification center of, **235**
- posterior aspect, **220, 233**

Femoral hernia, **237, 821**. *See also* Groin hernia.
Femoral neck, **229, 232, 239**
Femoral nerve, **191, 193, 197, 200, 204, 205, 206, 227, 229, 232, 242**
- genital branch, **204**
- region of, **251**

Femoral neurovascular bundle, **238**
Femoral shaft, **234, 241, 242, 243, 247**
Femoral sheath, **237**
Femoral triangle, **191, 197, 237**
Femoral trochlear cartilage, anterior knee US, **411**
Femoral vein, **195, 197, 203, 205, 206, 227, 229, 238, 239, 242, 251**
Femur, **238, 239**
- base of greater trochanter, **221**
- distal, **264, 268, 296**

Fibrocartilage, **84**
Fibrocartilaginous gliding zone, **323**
Fibrocartilaginous insertion, shoulder, **11**
Fibrocartilaginous lip, **311**
Fibrohistiocytic synovial tumors, **705**
Fibrolipomatous hamartoma, swollen nerve vs., **891**
Fibroma
- calcified soft tissue mass vs., **858**
- chest wall lesion vs., **929**
- hyperechoic subcutaneous mass vs., **835**
- hypoechoic subcutaneous mass vs., **828**
- plantar, fascial lesion vs., **896**
- subcutaneous, foreign body and injection granuloma vs., **768**

Fibromatosis
- hyperechoic muscle mass vs., **847**
- hypervascular soft tissue mass vs., **863**
- hypoechoic muscle mass vs., **840**
- nerve sheath tumors vs., **616**
- plantar fasciitis and, **718–723**
  - associated abnormalities, **720**
  - diagnostic checklist, **720**
  - differential diagnosis, **720**
  - prognosis, **720**
- soft tissue sarcoma vs., **782**

Fibrous hamartoma of infancy, hyperechoic subcutaneous mass vs., **835**
Fibula, **259, 263, 289, 290, 292, 308**
- anterolateral ligaments, **308**
- foot, **329**
- lateral ankle, **309, 310**
- leg, **284, 285, 287**
- medial and coronal ankle, **303**
- proximal, **264**

Fibular cortex, anterior ankle, **301**
Fibular head, **257**
- anterior and posterior leg nerves, **295**

Field-of-view imaging, extended, **347**
Fine-needle aspiration for cytology, **943, 944**

INDEX

Fingers, **108–117**
- extensor apparatus, transverse, **116**
- extensor digitorum tendon, longitudinal, **117**
- flexor pulleys, **111**
- flexor tendons
  longitudinal, **113**
  tendon sheaths, and pulleys, **110**
  transverse, **112**
- metacarpophalangeal joint, **114**
- tendon sheaths, **109**

1st extensor compartment, **144**
Flash artifact, **352**
Flexor carpi radialis muscle, **35, 46, 56, 57, 62, 64, 65, 67, 70, 72, 151, 152**
Flexor carpi radialis tendon, **72, 75, 76, 81, 82, 86, 152**
Flexor carpi ulnar tendon, **87**
Flexor carpi ulnaris muscle, **45, 46, 57, 60, 62, 64, 65, 68, 69, 70, 72, 75, 125, 157, 158, 161, 162, 163**
- humeral head, **160, 161**
- median nerve, **152**
- radial nerve, **140**
- ulnar head, **160**

Flexor carpi ulnaris tendon, **72, 81, 162**
Flexor digital sheaths, **88**
Flexor digiti minimi brevis muscle, **81, 164, 330**
Flexor digiti minimi muscle, **89, 91, 92, 95, 333**
- fingers, **109, 110**
- foot, **327, 328**
- median nerve, **155**
- thumb, **99**

Flexor digitorum accessorius longus muscle, **283**
Flexor digitorum brevis muscle, **261, 324, 326, 332, 333**
- foot, **327, 329, 330, 331**
- forefoot, **339**
- hindfoot, **325**
- medial and coronal ankle, **303**

Flexor digitorum brevis tendon
- foot, **327**
- lateral head, **340**
- medial head, **340**

Flexor digitorum longus muscle, **283, 332**
- foot, **327**
- leg, **287**

Flexor digitorum longus tendon, **257, 299, 324**
- anterior and posterior leg nerves, **295**
- deltoid ligament, **307**
- foot, **327, 329**
- forefoot, **335, 337, 339**
- hindfoot, **325**
- leg, **285**
- medial ankle, **304, 305**
- nerves of ankle, **312**

Flexor digitorum profundus muscle, **46, 62, 64, 69, 70, 72, 82, 88, 161, 162**
- fingers, **108**
- median nerve, **151**

Flexor digitorum profundus tendon, **70, 72, 75, 81, 89, 91, 112, 113**
- fingers, **109, 110, 114**
- insertion, **113**
- median nerve, **152**

Flexor digitorum superficialis muscle, **45, 46, 56, 57, 62, 64, 67, 68, 69, 70, 72, 88, 161**
- fingers, **108**
- median nerve, **151, 152**
- radial nerve, **144**

Flexor digitorum superficialis tendon, **72, 75, 81, 89, 109, 110, 112, 114, 162**
Flexor digitorum tendon, **75, 113, 127, 332**
- fingers, **114**
- medial ankle US, **420**

Flexor digitorum tenosynovitis, carpal tunnel syndrome, **591**
Flexor hallucis brevis muscle
- foot, **327, 328, 330**
- lateral head, **335, 336, 339, 340**
- medial head, **335, 336, 339, 340**

Flexor hallucis longus muscle, **259, 283, 284, 321, 341**
- Achilles tendon
  axial, **315**
  longitudinal, **314**
- leg, **285, 287, 293**
- medial ankle, **304**
- nerves of ankle, **312**

Flexor hallucis longus tendon, **257, 299, 325, 331, 342**
- anterior and posterior leg nerves, **295**
- foot, **327, 328, 329**
- forefoot, **336, 339**
- medial ankle, **303, 304, 305, 420**

Flexor pollicis brevis muscle, **81, 89, 91, 92, 94**
- deep belly, **94, 100, 101**
- insertion, **100**
- superficial belly, **94, 100, 101**
- thumb, **98**

Flexor pollicis brevis tendon, **102**
- insertion, **101**

Flexor pollicis longus muscle, **62, 64, 65, 72, 81, 127**
- radial nerve, **144**
- thumb, **98**

Flexor pollicis longus tendon, **72, 75, 76, 81, 82**
- forefoot, **340**
- thumb, **100, 101, 102, 105**

Flexor pollicis longus tendon sheath, **88, 89, 91, 109**
Flexor pulleys
- forefoot, **342**
- thumb, **98, 102**

Flexor retinaculum, **72, 75, 81, 83, 87, 89, 91, 92, 95, 126, 163, 260**
- medial ankle, **304**
- median nerve, **153, 154, 155**
- nerves of ankle, **312**
- thumb, **99, 101**

Flexor tendon pulleys
- foot, **327**
- forefoot, **334**
- volar hand US, **391**

Flexor tendon sheath, **99**
- foot, **327**

Flexor tendons, **89, 91, 93**
- within carpal tunnel, **93**
- fingers, **109, 111**
- index finger, **94, 100**

- median nerve, **153, 154**
- middle finger, **93**
- plantar foot US, **427**
- of thumb, volar hand US, **391**

Flexor-pronator muscle, **56, 58**
Flexor-pronator sprain. *See* Elbow epicondylitis.
Floating ribs, **168**
FNAC. *See* Fine-needle aspiration for cytology.
Focal chondral injury, osteoarthritis vs., **548**
Focal myositis, hypervascular soft tissue mass vs., **863**
Focal nodular synovitis
- synovial swelling vs., **916**
- synovial tumor vs., **706**

Foot arches, **316**
- longitudinal, **316**
- transverse, **316**

Foot arteries, **260, 261**
Foot US, **426–431**
- dorsal, **427**
  - 1st metatarsophalangeal joint, **427**
  - calcaneocuboid ligament, **427**
  - dorsal muscles, **427**
  - dorsal talonavicular ligament, **427**
  - extensor tendons, **427**
  - Lisfranc ligament, **427**
  - subtalar joints, **427**
- plantar, **427**
  - flexor tendons, **427**
  - plantar fascia, **427**
  - plantar muscles, **427**
  - toe web spaces, **427**

Forearm, **62–71**
- anatomy, **70**
- anterolateral anatomy, **66–67**
- anteromedial anatomy, **69**
- arteries, **125**
- axial anatomy, **63–65**
- common flexor tendon, **68**
- dorsal compartment, **62**
- lateral compartment, **62**
- median nerve, **146, 147, 151**
- posterior anatomy, **71**
- radial nerve, **138, 144**
- superficial veins, **128**
- ulnar nerve, **156, 157, 161, 162**
- volar compartment, **62**

Forefoot, **334–343**
- dorsal aspect, **343**
- muscles, **335**
- plantar muscles, **336**

Forefoot bursal injection
- indications, **1023**
- procedure, **1024**

Foreign body
- hyperechoic muscle mass vs., **846–847**
- within tendon, tendon hyperechogenicity vs., **879**

Foreign body and injection granuloma, **766–773**
- diagnostic checklist, **768**
- differential diagnosis, **768**
- hypoechoic subcutaneous mass vs., **829**
- prognosis, **768**

FPB. *See* Flexor pollicis brevis.
FPL. *See* Flexor pollicis longus.
FR. *See* Flexor retinaculum.
Fracture, **535**
- bone surface lesion vs., **902–903**
- healing insufficiency, bone tumor vs., **790**

Full-thickness tear
- nonrotator cuff tendon tears, **465**
- rotator cuff/biceps tendon, **447**
- tendon hyperechogenicity vs., **879**
- tendon hypoechogenicity vs., **875**

Fusion imaging, **347**

G

Gamekeeper's thumb. *See* Ligament injury.
Ganglion
- carpal tunnel syndrome, **591**
- intraneural, swollen nerve vs., **891**

Ganglion cyst, **690–699**
- aspiration
  - indications, **1001, 1023**
  - procedure, **1001, 1023**
- associated abnormalities, **692**
- cystic soft tissue mass vs., **852**
- diagnostic checklist, **692**
- differential diagnosis, **692**
- paraarticular, parameniscal cyst vs., **702**
- paraarticular cystic mass vs., **910**
- peritendinous mass vs., **870**
- prognosis, **692**
- synovial tumor vs., **706**

Gastrocnemius muscle, **282**
- ankle, **314**
- lateral, **274, 277, 296**
- lateral belly, **256, 284**
- lateral head, **281, 284, 288, 291, 292**
- medial, **286, 291, 292, 296**
- medial belly, **256, 280, 292, 293**
- medial head, **277, 284**

Gastrocnemius muscle tear, muscle injury, **509**
Gastrocnemius musculotendinous junction, **313**
Gastrocnemius tendon, **272**
- leg, **285**

Gastrocnemius-semimembranosus (Baker cyst), posterior knee US, **412**
Gemelli muscle, **210**
Gemellus inferior muscle, **220, 227, 233**
Gemellus superior muscle, **233**
General lumps and bumps
- calcified soft tissue mass, **858–861**
- hypervascular soft tissue mass, **862–867**

Geniculate vessels, **276**
Genitofemoral nerve, **200, 202**
- femoral branch, **193, 202, 205**
- femoral nerve, **205**
- general branch, **204**
- genital branch, **202, 203, 204**

Gerdy tubercle, **275**

INDEX

Geyser lesion, cystic soft tissue mass vs., **853**
Ghost image artifact, **352**
Giant cell tumor
- bone surface lesion vs., **902**
- of tendon sheath
  - ganglion cyst vs., **692**
  - hypervascular soft tissue mass vs., **863**
  - nerve sheath tumors vs., **616**
  - peritendinous mass vs., **870**

Gideon disease. *See* Ganglion cyst.
Glenohumeral joint, **11, 13, 364**
- capsule, **9**
- injection or aspiration
  - indications, **987**
  - procedure, **987**
- posterior, **27**

Glenoid, **18, 29**
Glenoid fossa, **14**
Glenoid labrum, **11, 13, 27, 364**
Gliding zone, medial ankle, **305**
Glomus tumor
- hypervascular soft tissue mass vs., **862**
- hypoechoic subcutaneous mass vs., **828–829**

Gluteal muscles, **207, 214–225**
- bursa, **214–215**
- iliotibial tract, **214**
- ischial tuberosity, **215**
- lateral hip US, **404**
- nerves & arteries, **215**
- rotator cuff of hip, **214**
- sacroiliac joint, **215**
- sciatic nerve, **216–217**

Gluteofemoral bursa, **215**
Gluteus maximus muscle, **210, 211, 214, 216, 217, 218, 219, 220, 221, 222, 223, 224, 225, 227, 230, 231, 233, 235, 238, 243, 244**
Gluteus medius muscle, **214, 216, 217, 218, 219, 222, 223, 230, 231, 234, 235, 243, 244**
Gluteus medius tendon, **223, 230, 243**
- anterior band, **223, 230**
- lateral hip US, **404**
- posterior band, **223, 230**

Gluteus minimus muscle, **214, 216, 218, 219, 222, 234, 235, 244**
- musculotendinous junction, **222, 231**

Gluteus minimus tendon, **222, 230, 231, 243**
- lateral hip US, **404**

Golfer's elbow. *See* Elbow epicondylitis.
Gorham-Scott syndrome, vascular anomaly, **760**
Gout and pseudogout, **564–571**
- associated abnormalities, **566**
- calcified soft tissue mass vs., **858**
- diagnostic checklist, **566**
- differential diagnosis, **566**
- hemarthrosis and lipohemarthrosis vs., **670**
- prognosis, **566**
- tendon hyperechogenicity vs., **878–879**
- tendon swelling vs., **883**
- tophus
  - carpal tunnel syndrome, **591**
  - hyperechoic subcutaneous mass vs., **835**
  - peritendinous mass vs., **871**
  - synovial swelling vs., **916**

Gouty arthropathy. *See* Gout and pseudogout.
Gouty tophi. *See* Gout and pseudogout.
Gracilis muscle, **190, 191, 192, 218, 236, 238, 239, 240, 244, 247, 277, 280**
- medial knee US, **412**

Gracilis tendon, **244, 267, 278, 291**
Granulation tissue, hypervascular soft tissue mass vs., **862**
Granuloma
- abdominal wall lesion vs., **935**
- calcified soft tissue mass vs., **858**
- hyperechoic subcutaneous mass vs., **835**
- hypoechoic muscle mass vs., **841**

Greater saphenous vein, **250**
- leg, **285**

Greater sciatic foramen, **215**
Greater trochanter, **217, 219, 227, 240**
- anterior facet, **230, 231, 243**
- lateral facet, **223, 230, 231, 243**
- posterosuperior facet, **223, 230**

Greater tuberosity, **15, 23, 25, 140**
Groin, **190–199**
- adductor musculature, **190**
- anterior abdominal wall, **190**
- deep and superficial inguinal rings, **196**
- femoral triangle, **191**
- inguinal canal, **190**
- inguinal ligament, **190**
- muscles, **192**
- nerves, **193–194**
- nodes, **190**
- osseous anatomy, **190**
- spermatic cord, **190, 198**

Groin hernia, **820–825**
- abdominal wall lesion vs., **934**
- diagnostic checklist, **822**
- differential diagnosis, **822**
- prognosis, **822**

Groin hernia US, **394–401**
- deep inguinal ring, **395**
- femoral canal, **395**
- Hesselbach triangle, **395**
- inferior epigastric vessels, **395**
- spermatic cord (in males), **395**

Guyon canal, **72, 76, 87**
- ulnar nerve, **156, 163, 164**

Guyon tunnel, **384**
Gynecomastia, chest wall lesion vs., **928–929**

H

Haemophilus, bone infection, **646**
Hallux
- dorsal aspect, **343**
- plantar aspect, **342**

Hamartoma, fibrolipomatous, swollen nerve vs., **891**

Hamartomatous fibrolipoma of median nerve, carpal tunnel syndrome, **591**
Hamate, **72, 73, 93, 95**
- hook of, **87**
Hamstring tendon attachment, **225**
Hamstring tendon origins, hip US, **404**
Hamstrings, **237**
Hand, **88–97**
- arteries, **126**
- deep dissection of, thumb, **99**
- dorsal aspect, **90**
- dorsum, **96, 97**
- hypothenar eminence, **88, 95**
- median nerve, **146**
- palm, **91, 93**
- palmar aspect, **89**
- radial nerve, **138**
- tendons, **88**
  - extensor expansion (or extensor hood), **88**
  - tendon sheath, **88**
- thenar eminence, **88, 94**
- ulnar nerve, **156, 157**
Hand and wrist procedures, **1000–1005**
- aftercare, **1002**
- carpal tunnel syndrome
  - indications, **1001**
  - procedures, **1002**
- de Quervain disease
  - indications, **1001**
  - procedures, **1001–1002**
- ganglion cyst aspiration
  - indications, **1001**
  - procedures, **1001**
- joint aspiration or injection
  - indications, **1001**
  - procedure, **1001**
- outcomes, **1002**
- preprocedure, **1001**
- procedure, **1001–1002**
- tendon disease
  - indications, **1001**
  - procedure, **1001**
- trigger finger
  - indications, **1001**
  - procedures, **1002**
Hand US, **390–393**
- clinical indications for, **391**
- dorsal, **391**
  - extensor tendon of thumb, **391**
  - extensor tendons of fingers, **391**
  - ulnar collateral ligament of metacarpophalangeal joint of thumb, **391**
- volar, **391**
  - carpometacarpal joint of thumb, **391**
  - flexor tendon pulleys, **391**
  - flexor tendons of thumb, **391**
  - metacarpophalangeal and interphalangeal joints, **391**
Healing insufficiency fracture, bone tumor vs., **790**
Healing rib fracture, chest wall lesion vs., **928**
Heel fat pad atrophy, plantar fasciitis and fibromatosis vs., **720**
Heel spur syndrome. *See* Plantar fasciitis and fibromatosis.
Hemangioma
- hyperechoic muscle mass vs., **846**
- hyperechoic subcutaneous mass vs., **834**
- pilomatricoma vs., **741**
- synovial, **705**
  - synovial swelling vs., **917**
  - synovial tumor, **706**
Hemarthrosis, **668–671**
- diagnostic checklist, **670**
- differential diagnosis, **670**
- joint effusion vs., **923**
- joint infection vs., **656**
- prognosis, **670**
- staging, grading, & classification, **670**
Hematoma, **518–525**
- acute, **519**
- calcified soft tissue mass vs., **859**
- chest wall lesion vs., **928**
- chronic, **519**
- cystic soft tissue mass vs., **852**
- diagnostic checklist, **520**
- differential diagnosis, **520**
- hyperechoic muscle mass vs., **846**
- hyperechoic subcutaneous mass vs., **835**
- hypoechoic muscle mass vs., **840**
- hypoechoic subcutaneous mass vs., **829**
- intravascular organized, **627, 628**
- liquefied, paraarticular cystic mass vs., **911**
- muscle
  - soft tissue infection vs., **638**
  - soft tissue sarcoma vs., **782**
- organizing, **519**
  - hypervascular soft tissue mass vs., **863**
- postoperative, local tumor recurrence vs., **802**
- postoperative infection vs., **662**
- prognosis, **520**
- rectus sheath, **519**
  - abdominal wall hernia vs., **814**
  - abdominal wall lesion vs., **935**
- subacute, **519**
- superficial metastases, melanoma, and lymphoma vs., **754**
Hemophilia A or B, hemarthrosis and lipohemarthrosis, **670**
Hemophiliac arthropathy. *See* Hemarthrosis.
Hemophiliac pseudotumor, **519**
Hemophilic arthropathy, synovial tumor vs., **706**
Hemosideric synovitis, synovial swelling vs., **917**
Hernia
- abdominal wall, **812–819**
  - diagnostic checklist, **814**
  - differential diagnosis, **814**
  - prognosis, **814**
- groin, **820–825**
  - diagnostic checklist, **822**
  - differential diagnosis, **822**
  - prognosis, **822**
- groin US, **394–401**
  - deep inguinal ring, **395**
  - femoral canal, **395**

Hesselbach triangle, **395**
inferior epigastric vessels, **395**
spermatic cord (in males), **395**
Hesselbach triangle, **395**
Heterotopic ossification, calcified soft tissue mass vs., **859**
Hibernoma, **725**
- hyperechoic muscle mass vs., **847**
High-grade partial tear, nonrotator cuff tendon tears, **465**
Hindfoot, **316–333**
- bones, **320**
- central plantar muscles, **332**
- dorsum foot, **322**
- joints, **321**
- lateral plantar muscles, **333**
- ligaments, **323**
- medial plantar muscles, **331**
- muscles
  1st & 2nd layers, **327**
  3rd & 4th layers, **328**
  coronal, **329–330**
- peroneal tendons, **324**
- plantar aponeurosis, **326**
- tarsal tunnel, **325**
Hip, **226–235**
- anterior, **229**
- axial and sagittal sections, **227**
- coronal sections, **228**
- developmental dysplasia, **572–577**
  diagnostic checklist, **574**
  differential diagnosis, **574**
  prognosis, **574**
- ligaments, **228**
- overview, **226**
- pediatric, **234, 235**
- posterior, **233**
- short external rotators, **220**
Hip and pelvis procedures, **1006–1013**
- hip or sacroiliac joint injection
  indications, **1007**
  procedures, **1007–1008**
- nerve block & neural hydrodissection
  indications, **1007**
  procedures, **1008**
- outcomes, **1008**
- paraarticular labral/ganglion cyst or bursal
  indications, **1007**
  procedures, **1008**
- post procedure, **1008**
- preprocedure, **1007**
- procedure, **1007–1008**
- tendinosis and tears
  indications, **1007**
  procedures, **1008**
Hip joint, **229**
- anterior aspect of, anterior hip US, **403**
Hip joint injection
- indications, **1007**
- lower limb, **979–980**
- procedures, **1007**
Hip US, **402–409**
- anterior, **403**
  acetabular labral junction, **403**
  anterior aspect of hip joint, **403**
  anterior superior iliac spine region, **403**
  dynamic examination for snapping iliopsoas tendon, **403**
  iliopsoas tendon, **403**
  rectus femoris tendon, **403**
- clinical indications for, **403**
- lateral, **404**
  gluteus minimus and medius tendons, **404**
  tensor fascia lata, iliotibial tract, and gluteal muscles, **404**
- medial, **403–404**
  adductor tendons and muscles, **403–404**
- posterior hip and deep gluteal space, **404**
  deep gluteal space proximal to ischial tuberosity, **404**
  ischial tuberosity and hamstring tendon origins, **404**
  posterior thigh musculature, **404**
Hoffa fat pad, **270**
Honeymoon syndrome. *See* Nerve injury.
Hook of hamate, **87, 93, 95, 164**
Humeral head, **8, 15, 16, 17, 18, 19, 20, 21, 22, 23, 24, 27, 29, 33, 55, 60, 125**
Humeral shaft, **20, 37, 38, 39, 41, 159**
- radial nerve, **141, 142**
Humerus, **36, 47, 48, 61, 160**
- capitellum, **47**
- distal, **44**
- lateral epicondyle, **43**
- medial epicondyle, **43**
- supracondylar portion of, **39**
- trochlear process, **41**
Hyaline articular cartilage, **268**
Hyperechoic muscle mass, **846–851**
- differential diagnosis, **846**
Hyperechoic subcutaneous mass, **834–839**
- differential diagnosis, **834**
Hyperemia, tendon hypoechogenicity vs., **874**
Hyperlipidemia, gout and pseudogout, **566**
Hypertension, gout and pseudogout, **566**
Hypertrophy of radiohumeral synovial flange, elbow epicondylitis vs., **488**
Hypervascular soft tissue mass, **862–867**
- differential diagnosis, **862**
Hypoechoic muscle mass, **840–845**
- differential diagnosis, **840**
Hypoechoic subcutaneous mass, **828–833**
- differential diagnosis, **828**
Hypogastric hernia, **813**
Hypothenar eminence, **81, 88, 95**
Hypothenar muscle, **164**

I

IFCN. *See* Intermediate femoral cutaneous nerve.
Iliac blade, **195**

Iliac bone, **181, 203, 234**
Iliac crest, **177, 185, 244**
Iliac spine, anterior inferior, **226, 228**
Iliacus fascia, **205**
Iliacus muscle, **174, 176, 180, 181, 182, 184, 191, 192, 193, 195, 203, 204, 205, 207, 229, 232, 240, 241, 243, 244**
Iliocostalis lumborum muscle, **188, 189**
Iliocostalis muscle, **177, 185, 186**
Iliocostalis thoracis muscle, **186**
Iliofemoral ligament, **218, 228**
Iliohypogastric nerves, **181, 194, 200, 202, 203**
Ilioinguinal nerve, **181, 194, 200, 202, 203**
Iliopsoas bursa, **679**
Iliopsoas muscle, **182, 204, 205, 226, 232, 237, 238**
- insertion, **176, 184**
Iliopsoas tendon, **199, 227, 229, 232**
- anterior hip US, **403**
- deep to inguinal ligament, **228**
Iliotibial band, **222, 223, 230, 231, 240, 265, 274, 275**
Iliotibial tract, **216, 217, 238, 239, 243, 257**
- anterior and posterior leg nerves, **295**
- lateral hip US, **404**
Ilium, **227**
Immature hip, physiological, developmental hip dysplasia vs., **574**
Immune-mediated peripheral neuropathy, swollen nerve vs., **890–891**
Improper Doppler angle with no-flow artifact, **352**
Improper machine setting, artifacts due to, **351**
- equipment-generated, **351**
- range ambiguity, **351**
Inactive tenosynovitis, chronic, **477**
Incisional hernia, **813**
- abdominal wall lesion vs., **934**
Indirect inguinal hernia, **821**. *See also* Groin hernia.
Infantile hemangioma, **759**
Infection
- bone, **644–653**
  diagnostic checklist, **646**
  differential diagnosis, **646**
  prognosis, **646**
- joint, **654–659**
  diagnostic checklist, **656**
  differential diagnosis, **656**
  prognosis, **656**
- postoperative, **660–665**
  diagnostic checklist, **662**
  differential diagnosis, **662**
  prognosis, **662**
- soft tissue, **636–643**
  bone infection vs., **646**
  differential diagnosis, **638**
  prognosis, **638**
Infective arthritis. *See also* Joint infection.
- joint effusion vs., **923**
Infective fasciitis, **637**
- fascial lesion vs., **897**
Infective myositis, muscle infarction vs., **505**
Infective osteitis, **645**
Infective phlegmon, muscle infarction vs., **505**
Inferior calcaneal nerve, **303, 318**
Inferior epigastric artery, **180, 193, 196, 204, 249**
Inferior epigastric vein, **180, 196, 250**
Inferior epigastric vessels, **395**
Inferior extensor retinaculum
- anterior ankle, **300, 419**
- dorsal foot, **319**
Inferior fascicle, **274**
Inferior gemellus muscle, **214, 216, 217, 218, 224, 244**
Inferior glenohumeral ligament, **14, 25**
Inferior gluteal artery, **211, 215, 220, 225, 249**
Inferior gluteal line, **218**
Inferior gluteal nerve, **215**
Inferior gluteal vein, **250**
Inferior lateral genicular artery, **249, 255**
Inferior medial genicular artery, **249, 255, 256**
Inferior patellar tendon, **295**
Inferior peroneal retinaculum, **324**
- lateral ankle, **309, 311**
Inferior pubic ramus, **190, 199, 208**
Inferior retinaculum, **301**
Inferior thyroid artery, **119**
Inferior tibiofibular joint recess, **303**
Inferior transverse ligament, **306**
Inferior ulnar collateral artery, **123**
Inferior vena cava, **178**
Inferolateral genicular artery, **249**
Inferomedial genicular artery, **249**
Inflammatory arthritis, **554–563**
- diagnostic checklist, **556**
- differential diagnosis, **556**
- joint infection vs., **656**
- osteoarthritis vs., **548**
- prognosis, **556**
Inflammatory arthropathy
- joint effusion vs., **922**
- nonrotator cuff tendon tears, **466**
- synovial swelling vs., **916**
Inflammatory erosive osteoarthritis, inflammatory arthritis vs., **556**
Inflammatory mass
- hypervascular soft tissue mass vs., **862**
- soft tissue sarcoma vs., **782**
Inflammatory myositis, muscle infarction vs., **505**
Inflammatory plexopathy, **603**
Inflammatory synovitis
- carpal tunnel syndrome vs., **592**
- hemarthrosis and lipohemarthrosis vs., **670**
Infrapatellar bursa, **269, 679**
Infrapatellar bursitis (preacher's knee). *See* Bursitis.
Infrapatellar (Hoffa) fat pad, **266, 269**
Infraspinatus muscle, **10, 12, 13, 23, 24, 25, 26, 27, 29, 31, 33**
- central tendon of, **26**
- radial nerve, **140**
Infraspinatus tendon, **10, 12, 13, 14, 15, 16, 23, 25, 26, 31, 363**
- insertional area, **23**
- musculotendinous junction, **10**
Infundibular cyst. *See* Epidermoid cyst.

Inguinal canal, **395**
- groin, **190**
- groin hernia, **821**
Inguinal hernia. *See* Groin hernia.
Inguinal ligament, **175, 176, 183, 184, 190, 191, 195, 196, 198, 205, 206, 207, 218, 240, 243, 395**
Inguinal lymph nodes
- deep, **190**
- superficial, **190**
Inguinal ring, deep, **190**
Innermost intercostal muscle, **169**
Insertional area, **15, 16**
Insufficiency fracture, **535**
Insulin-dependent diabetes, longstanding, muscle infarction, **506**
Interclavicular ligament, **4, 5**
Intercostal artery, **169**
Intercostal muscles, **168, 172**
Intercostal nerves, **168, 169**
Intercostal spaces, **169, 172**
- skeletal structures, **168**
- vessels and nerves, **168**
Intercostal vein, **169**
Intermediate cuneiform, **322**
Intermediate cuneiform bone, **261**
Intermediate dorsal cutaneous nerve, **313**
Intermediate femoral cutaneous nerve (IFCN), **200**
Intermetacarpal ligament, **106, 107**
Intermetatarsal ligament, **335**
Intermuscular lipoma, hyperechoic muscle mass vs., **846**
Internal iliac artery, **249, 255**
Internal iliac vein, **250**
Internal intercostal muscle, **169, 172**
Internal mammary artery, **169, 171**
Internal mammary lymph node, **169**
Internal mammary vein, **169, 171**
Internal oblique muscle, **174, 175, 177, 178, 181, 182, 185, 190, 192, 194, 202, 203, 218**
Internal pudendal artery, **227**
Internal pudendal vein, **227**
Internal thoracic artery, **119, 168**
Interosseous membrane, **71, 257**
- anterior and posterior leg nerves, **295**
- lateral ankle, **309**
- leg, **282, 284**
- medial and coronal ankle, **303**
- medial and posterior ligaments, **306**
Interosseous muscle
- fingers, **109**
- foot, **328**
- forefoot, **335**
Interosseous recurrent artery, **123**
Interphalangeal joint, **101**
- hallux, **343**
- ossicle, **342**
- volar hand US, **391**
- volate plate, **342**
Intersesamoid ligament, **340, 341**
Intertrochanteric line, **228**
Interventional procedures
- ankle and foot procedures, **1022–1027**
  Achilles tendinosis treatment, procedure, **1023–1024**
  outcomes, **1024**
  peritendon therapy, indication, **1023**
  post procedure, **1024**
  preprocedure, **1023**
  procedure, **1023–1024**
- bone biopsy, **950–959**
  outcomes, **952**
  preprocedure, **951**
  procedure, **951–952**
- elbow procedures, **994–999**
  intraarticular aspiration or injection
    indications, **995**
    procedure, **995**
  outcomes, **996**
  paraarticular aspiration
    indication, **995**
    procedure, **995**
  post procedure, **996**
  preprocedure, **995**
  procedure, **995–996**
  tendinosis treatment
    autologous blood, **996**
    corticosteroid injection, **996**
    dry needling, **996**
    indications, **995**
    platelet-rich plasma, **996**
    procedure, **995–996**
    prolotherapy, **996**
- hand and wrist procedures, **1000–1005**
  carpal tunnel syndrome
    indications, **1001**
    procedures, **1002**
  de Quervain disease
    indications, **1001**
    procedures, **1001–1002**
  ganglion cyst aspiration
    indications, **1001**
    procedures, **1001**
  joint aspiration or injection
    indications, **1001**
    procedure, **1001**
  outcomes, **1002**
  preprocedure, **1001**
  procedure, **1001–1002**
  tendon disease
    indications, **1001**
    procedure, **1001**
  trigger finger
    indications, **1001**
    procedures, **1002**
- hip and pelvis procedures, **1006–1013**
  hip or sacroiliac joint injection
    indications, **1007**
    procedures, **1007–1008**
  nerve block & neural hydrodissection
    indications, **1007**
    procedures, **1008**
  outcomes, **1008**

paraarticular labral/ganglion cyst or bursal
indications, **1007**
procedures, **1008**
post procedure, **1008**
preprocedure, **1007**
procedure, **1007–1008**
tendinosis and tears
indications, **1007**
procedures, **1008**
- joint injection
lower limb, **978–985**
outcomes, **980**
post procedure, **980**
preprocedure, **979**
procedure, **979–980**
upper limb, **968–977**
outcomes, **970**
preprocedure, **969**
procedure, **969–970**
- knee procedures, **1014–1021**
intraarticular injection of contrast medium or medication
indications, **1015**
procedure, **1015**
outcomes, **1016**
paraarticular tendinosis treatment, indications, **1015**
paraarticular tendinosis treatment, procedure, **1015**
ABI or PRP injection, **1016**
ACL ganglion cyst aspiration, **1016**
barbotage for calcific tendinitis, **1016**
dry needling, **1015–1016**
peritendinous steroid injection, **1016**
prolotherapy, **1016**
soft tissue mass biopsy, **1016**
post procedure, **1016**
preprocedure, **1015**
procedure, **1015–1016**
- shoulder procedures, **986–993**
acromioclavicular joint injection
indications, **987**
procedure, **989**
calcific tendinitis therapy
indications, **987**
procedure, **988–989**
glenohumeral joint injection or aspiration
indications, **987**
procedure, **987**
preprocedure, **987**
procedure, **987–989**
rotator cuff tendinosis
indications, **987**
procedure, **989**
subacromial-subdeltoid bursa injection
indications, **987**
procedure, **988**
- soft tissue biopsy, **942–949**
outcomes, **944**
post procedure, **944**
preprocedure, **943**
procedure, **943–944**
- synovial biopsy, **960–965**
outcomes, **962**
post procedure, **962**
preprocedure, **961**
procedure, **961–962**
Intraabdominal extraperitoneal fat, **179**
Intraarticular aspiration or injection, elbow
- indications, **995**
- procedure, **995**
Intraarticular disc, **4**
Intramuscular extension of Baker cyst, hypoechoic muscle mass vs., **841**
Intramuscular ganglion cyst, hypoechoic muscle mass vs., **841**
Intramuscular lipoma, hyperechoic muscle mass vs., **846**
Intraneural ganglion, swollen nerve vs., **891**
Intraneural lipoma, swollen nerve vs., **891**
Intrasubstance tendon tears, rotator cuff/biceps tendinosis vs., **435**
Intratendinous vessel, tendon hypoechogenicity vs., **875**
Intravascular angiomatosis. *See* Vascular dilatation or inflammation.
Intravascular organized hematoma, **627, 628**
Intravascular papillary endothelial hyperplasia (IPEH), **627, 628**. *See also* Vascular dilatation or inflammation.
Intrinsic ligaments, **72**
Investing fascial tear, fascial lesion vs., **897**
Involucrum, **645**
IPEH. *See* Intravascular papillary endothelial hyperplasia.
Ischemic myonecrosis. *See* Muscle infarction.
Ischial spine, **210, 225, 244**
Ischial tuberosity, **211, 215, 220, 225, 227, 233, 238, 245**
- deep gluteal space proximal to, **404**
- posterior hip US, **404**
Ischial tuberosity bursa, **679**
Ischial tuberosity (ischiogluteal) bursitis. *See* Bursitis.
Ischiofemoral ligament, **228**
Ischiogluteal bursa, **215**
Ischium, **219, 220, 225, 233, 238**

J

Jogger's heel. *See* Plantar fasciitis and fibromatosis.
Joint abnormalities
- joint effusion, **922–925**
- paraarticular cystic mass, **910–915**
- synovial swelling, **916–921**
Joint aspiration or injection
- indications, **1023**
- procedure, **1023**
Joint capsule, **5, 13, 27, 31, 226**
- acromioclavicular joint, **9**
- fingers, **115, 117**
Joint deformity, chronic, nonrotator cuff tendon tears, **466**
Joint effusion, **922–925**
- crystal arthropathy, **922**
- differential diagnosis, **922**

- hemarthrosis, **923**
- infective arthritis, **923**
- inflammatory arthropathy, **922**
- lipohemarthrosis, **923**
- osteoarthritis, **922**

Joint infection, **654–659**
- diagnostic checklist, **656**
- differential diagnosis, **656**
- prognosis, **656**

Joint injection
- lower limb, **978–985**
  - outcomes, **980**
  - post procedure, **980**
  - preprocedure, **979**
  - procedure, **979–980**
- upper limb, **968–977**
  - outcomes, **970**
  - preprocedure, **969**
  - procedure, **969–970**

Joint procedures
- ankle and foot procedures, **1022–1027**
- elbow procedures, **994–999**
- hand and wrist procedures, **1000–1005**
- hip and pelvis procedures, **1006–1013**
- joint injection
  - lower limb, **978–985**
  - upper limb, **968–977**
- knee procedures, **1014–1021**
- shoulder procedures, **986–993**

Joplin neuroma, **334**

Junctura tendinum, **90, 96**
- fingers, **115**

Juvenile inflammatory arthropathy. *See* Inflammatory arthritis.

Juxtacortical tumor, bone surface lesion vs., **903**

K

Kager fat pad, **321**

Kaposi sarcoma, vascular dilatation or inflammation vs., **628**

Kimura disease, **627, 628**

Kingella kingae, joint infection, **656**

Klebsiella, postoperative infection, **662**

Klippel-Trenaunay-Weber syndrome, vascular anomaly, **760**

Knee, **264–281**
- extensor mechanism, **266**
- lateral, **274–276**
- medial, **272–273**
- parapatellar ligaments & retinacula, **271**
- paratenon, **270**
- patellar tendon, **269, 270**
- pes anserinus, **267**
- posterior, **277–281**
- quadriceps tendon, **268**

Knee joint
- anterior knee US, **411**
- joint injection, lower limb, **980**

Knee procedures, **1014–1021**
- intraarticular injection of contrast medium or medication
  - indications, **1015**
  - procedure, **1015–1016**
- outcomes, **1016**
- paraarticular aspiration
  - indications, **1015**
  - procedure, **1015**
- paraarticular tendinosis treatment
  - indications, **1015**
  - procedure, **1015**
    - ABI or PRP injection, **1016**
    - ACL ganglion cyst aspiration, **1016**
    - barbotage for calcific tendinitis, **1016**
    - dry needling, **1015–1016**
    - peritendinous steroid injection, **1016**
    - prolotherapy, **1016**
    - soft tissue mass biopsy, **1016**
- post procedure, **1016**
- preprocedure, **1015**
- procedure, **1015–1016**

Knee US, **410–417**
- anterior, **411**
  - anterior cruciate ligament, **411**
  - femoral trochlear cartilage, **411**
  - knee joint, **411**
  - patellar bone and patellar tendon, **411**
  - patellar retinacula, **411**
  - quadriceps tendon, **411**
- clinical indications for, **411**
- lateral, **412**
  - biceps femoris tendon, **412**
  - distal iliotibial band, **412**
  - lateral collateral ligament, **412**
  - popliteus tendon, **412**
- medial, **411–412**
  - body of medial meniscus, **412**
  - medial collateral ligament, **411–412**
  - pes anserinus tendons (semitendinosus, gracilis, and sartorius), **412**
  - semimembranosus tendon, **412**
- posterior, **412**
  - gastrocnemius-semimembranosus (Baker cyst), **412**
  - posterior cruciate ligament, **412**
  - posterolateral corner structures, **412**
  - tibial and peroneal nerves, **412**

Knot of Henry, **303**

L

Labrum, **226, 229**
- anterior, **29, 227**
- hip, paraarticular labral/ganglion cyst or bursal aspiration
  - indication, **1007**
  - procedures, **1008**

- posterior, **29, 227**
- superior, **228**
Lamina, **187**
Lateral ankle, US, **420**
Lateral antebrachial cutaneous nerve, **35, 36, 70, 384**
Lateral arcuate ligament, **176, 184**
Lateral bands, **90**
- attachments to, **96**
- fingers, **108, 114, 115, 116**
- insertion, **92**
- plantar fascia, **329**
Lateral calcaneal cortex, **311**
Lateral calcaneal tuberosity, **333**
Lateral circumflex femoral artery, **249**
- descending branch, **249**
Lateral circumflex femoral vein, **250**
Lateral collateral ligament, **276**
- lateral knee US, **412**
Lateral compartment
- ankle, **299**
- leg, **285**
- leg muscles, **282**
Lateral cutaneous nerve, forearm, median nerve, **147**
Lateral elbow US, **376**
- annular ligament, **376**
- common extensor tendon origin, **376**
- lateral ulnar collateral ligament, **376**
- radial collateral ligament, **376**
- synovial fold, **376**
Lateral epicondylalgia. *See* Elbow epicondylitis.
Lateral epicondyle, **43, 52, 53, 61**
Lateral epicondylitis. *See* Elbow epicondylitis.
Lateral facet, **222**
Lateral femoral condyle, **275**
Lateral femoral condyle, tibial nerve, **296**
Lateral femoral cutaneous nerve (LFCN), **200, 205, 206, 207, 243**
Lateral gastrocnemius muscle, **288**
Lateral hip US, **404**
Lateral intermuscular septum, **38, 39, 142**
Lateral knee, US, **412**
Lateral malleolar artery, **260**
Lateral malleolar tip, **311**
Lateral malleolus, **308, 310**
Lateral meniscus, **274**
Lateral patellar retinaculum, **240, 271**
Lateral pectoral nerve, **28, 165**
Lateral plantar artery, **260, 261, 333, 338**
Lateral plantar muscles, **333**
Lateral plantar nerve, **260, 313, 330, 333**
- deep branch, **260**
- foot, **329**
- hindfoot, **325**
- medial ankle, **303**
- plantar foot, **338**
- superficial branch, **260**
Lateral retinaculum, **264**
Lateral sesamoid, **340, 341**
- 1st toe, **328**
Lateral sesamoid-phalangeal ligament, **340**
Lateral tarsal artery, **257, 260**
- anterior and posterior leg nerves, **295**
Lateral thoracic artery, **30, 119**
Lateral tibial condyle, **275**
Lateral trochlear facet, **271**
Lateral ulnar collateral ligament (LUCL), **45, 54**
- lateral elbow US, **376**
Latissimus dorsi muscle, **12, 13, 24, 25, 31, 35, 140, 169, 186, 218**
Latissimus dorsi tendon, **12, 35**
Ledderhose disease. *See* Plantar fasciitis and fibromatosis.
Left crus of diaphragm, **176, 184**
Leg muscles, **282–293**
- anatomy imaging issues, **283**
- anterior compartment, **282, 286–287**
- anterior tibial artery, **258**
- arteries, **257**
- axial anatomy, **284–285**
- deep and superficial veins, **262**
- gross anatomy, **282–283**
- interosseous membrane, **282**
- lateral compartment, **282**
- peroneal artery and vein, **259**
- peroneal compartment, **288–289**
- posterior compartment, **282–283, 291–293**
- superficial peroneal nerve, **290**
- superficial veins, **263**
Leg nerves, **294–297**
- anatomy imaging issues, **294**
- anterior & posterior leg nerves, **295**
- gross anatomy, **294**
- peroneal nerve, **297**
- tibial nerve, **296**
Leiomyoma, vascular, **748–751**
- diagnostic checklist, **749**
- differential diagnosis, **749**
- genetics, **749**
- hypoechoic subcutaneous mass vs., **828**
- prognosis, **749**
Leprosy, swollen nerve vs., **891**
Lesser metatarsophalangeal joint, **335**
Lesser MTP joints
- forefoot, **334**
- plantar plate injury, **334**
Lesser sciatic foramen, **215**
Lesser trochanter, **208, 240**
Lesser tuberosity, **21, 22, 232**
Leukemia
- bone infection vs., **646**
- fat injury vs., **498**
Levator ani muscle, **176, 184**
LFCN. *See* Lateral femoral cutaneous nerve.
Ligament, **527**
Ligament injury, **526–533**
- diagnostic checklist, **528**
- differential diagnosis, **528**
- prognosis, **528**
- staging, grading, & classification, **528**
- thumb, **98**
Ligament sprain, **527**. *See also* Ligament injury.
Ligament strain. *See* Ligament injury.

Ligament tear, **527**
Ligamentum teres, **227, 228**
Linea alba, **170, 174, 175, 178, 179, 182, 183, 190**
Linea alba hernia, abdominal wall lesion vs., **934**
Linea semilunaris, **174, 175, 178**
Lipoblastoma, **725**
Lipohemarthrosis, **668–671**
- diagnostic checklist, **670**
- differential diagnosis, **670**
- joint effusion vs., **923**
- prognosis, **670**
- staging, grading, & classification, **670**

Lipohypertrophy, **834**
Lipohypertrophy, lipoma vs., **726**
Lipoma, **724–733**
- carpal tunnel syndrome, **591**
- chest wall lesion vs., **928**
- diagnostic checklist, **726**
- differential diagnosis, **726**
- epidermoid cyst vs., **736**
- hyperechoic subcutaneous mass vs., **834**
- hypoechoic subcutaneous mass vs., **828**
- intraneural, swollen nerve vs., **891**
- prognosis, **726**
- of spermatic cord, groin hernia vs., **822**
- subcutaneous, fat injury vs., **498**

Lipoma arborescens, **705, 725**
- synovial swelling vs., **917**
- synovial tumor, **706**

Lipomatosis, **725**
- of nerve, **725**

Liposarcoma, myxoid, paraarticular cystic mass vs., **911**
Liquefied hematoma, paraarticular cystic mass vs., **911**
Lisfranc ligament, dorsal foot US, **427**
Lister tubercle, **76, 78, 97**
Little league elbow syndrome, ligament injury vs., **528**
Littre hernia, **822**
Local tumor recurrence, **800–809**
- diagnostic checklist, **802**
- differential diagnosis, **802**
- hyperechoic muscle mass vs., **847**
- hypoechoic muscle mass vs., **841**
- prognosis, **802**

Long plantar ligament, **318, 333**
- foot, **328**
- forefoot, **339**
- lateral ankle, **309**
- medial and posterior ligaments, **306**

Long saphenous vein, **191, 238, 239, 248, 262, 263, 277, 322**
- anterior ankle, **301**
- valves of, **254**

Long thoracic nerve, **29, 165**
Longissimus thoracis muscle, **177, 185, 186, 187, 189**
- lumbar part, **188**

Longitudinal capsular fibers, **227**
Lower limb
- ankle, **298–315**
- arteries, **248–263**
- forefoot, **334–343**
- gluteal muscles, **214–225**
- hindfoot, **316–333**
- hip, **226–235**
- joint injection, **978–985**
  - outcomes, **980**
  - post procedure, **980**
  - preprocedure, **979**
  - procedure, **979–980**
- knee, **264–281**
- leg, **282–293**
- leg nerves, **294–297**
- midfoot, **316–333**
- thigh, **236–247**
- veins, **248–263**

Low-grade abscess, hematoma/seroma vs., **520**
Lumbar hernia, **813**
- abdominal wall lesion vs., **934**

Lumbosacral plexus, **209**
Lumbrical muscle, **88, 91, 93, 94, 112**
- 3rd, **96**
- 4th, **96**
- fingers, **108, 109, 111, 114**
- 1st, **91**
- foot, **327, 339**
- 4th, **91**
- lateral band, **91**
- 2nd, **91**
- 3rd, **90, 91**

Lumbrical tendon, **91, 115**
Lunate, **72, 73, 79, 80, 82**
Lung, **169**
Lymph node abnormality, **774–779**
- diagnostic checklist, **776**
- differential diagnosis, **776**

Lymph node enlargement. *See* Lymph node abnormality.
Lymph nodes, **28, 33, 232**
- cortex, **33, 197**
- cystic soft tissue mass vs., **853**
- groin, **197**
  - inguinal, superficial, **190**
- hilum, **33, 197**
- hypervascular soft tissue mass vs., **863**
- hypoechoic subcutaneous mass vs., **829**
- malignant, nerve sheath tumors vs., **616**
- subcutaneous, **197**

Lymphadenitis. *See* Lymph node abnormality.
Lymphadenopathy. *See* Lymph node abnormality.
Lymphangioma
- hypoechoic muscle mass vs., **841**
- paraarticular cystic mass vs., **911**

Lymphatic malformation, **759**
- chest wall lesion vs., **929**
- cystic soft tissue mass vs., **853**

Lymphatics, **191**
Lymphocele, **519**
Lymphoma
- fat injury vs., **498**
- hypervascular soft tissue mass vs., **863**
- hypoechoic subcutaneous mass vs., **829**
- synovial swelling vs., **917**

M

Maffucci syndrome, vascular anomaly, **760**
Main collateral ligament, fingers, **114**
Malaligned fracture, nonrotator cuff tendon tears, **466**
Male breast carcinoma, chest wall lesion vs., **929**
Malignant bone tumor, bone surface lesion vs., **902**
Malignant infiltration, **603**
Malignant lymph node, nerve sheath tumors vs., **616**
Malignant skin lesions, dermatofibrosarcoma protuberans, **745**
Malignant transformation, bone surface lesion vs., **902**
Malignant tumor, **789**
Mammary glands and ducts, **169**
Manubrium, **5, 6, 170**
Massive tear, rotator cuff/biceps tendon, **447**
Masson hemangioma. *See* Vascular dilatation or inflammation.
Masson tumor. *See* Vascular dilatation or inflammation.
Medial ankle, US, **419–420**
Medial antebrachial cutaneous nerve, **70**
Medial arcuate ligament, **176, 184**
Medial calcaneal nerve, **318**
- medial and coronal ankle, **303**
Medial circumflex artery, ascending and descending branches, **249**
Medial circumflex femoral artery, **249**
Medial circumflex femoral vein, **250**
Medial collateral bursa, **272**
Medial collateral ligament
- complex, **376**
- medial knee US, **411–412**
- superficial fibers, **273**
Medial compartment, **239**
Medial cuneiform, **320, 322**
Medial cutaneous nerve, axilla, **28**
Medial dorsal cutaneous nerve, **313**
Medial elbow US, **375–376**
- common flexor tendon origin (CFTO), **375–376**
- cubital tunnel, **376**
- medial collateral ligament complex, **376**
Medial epicondylalgia. *See* Elbow epicondylitis.
Medial epicondyle, **43, 44, 54, 56, 58, 59, 60, 61, 160**
Medial epicondylitis. *See* Elbow epicondylitis.
Medial femoral circumflex artery, **249**
Medial femoral condylar cartilage, **271**
Medial femoral condyle, **271, 272, 273, 279, 280**
Medial femoral cutaneous nerve (MFCN), **200**
Medial hip US, **403–404**
Medial humeral condyle, avulsion fracture of, ligament injury vs., **528**
Medial intermuscular septum, **38**
- anterior and posterior layers, **38**
- radial nerve, **140**
Medial knee, US, **411–412**
Medial malleolus, **321, 325**
- deltoid ligament, **307**
- medial ankle, **304, 305**
Medial meniscus, **273**
- body, **273**
  medial knee US, **412**
Medial parapatellar joint recess, **271**
Medial patellar retinaculum, **240, 244**
Medial patellofemoral ligament (MPFL), **264, 267, 271, 273**
Medial pectoral nerve, **28, 165**
Medial plantar artery, **260, 261, 331, 338**
Medial plantar muscles, **331**
Medial plantar nerve, **260, 261, 313, 325, 331**
- foot, **329, 330**
- medial ankle, **303, 305**
- plantar foot, **338**
Medial retinaculum, **264**
Medial sesamoid, **341**
- 1st toe, **327, 328**
- forefoot, **336, 340**
Medial sesamoid-phalangeal ligament, **340, 341**
Medial tennis elbow. *See* Elbow epicondylitis.
Medial thigh, **199**
Medial tibial condyle, **273**
Medial trochlear facet, **271**
Median antebrachial vein, **128**
Median arcuate ligament arches, **176**
Median basilic vein, **128**
Median calcaneal nerve, **313**
Median crest (crista), 1st metatarsal head, **340**
Median cubital vein, **64**
Median nerve, **29, 32, 35, 36, 37, 38, 44, 45, 46, 48, 50, 55, 63, 64, 65, 67, 69, 70, 75, 76, 82, 83, 93, 122, 126, 127, 130, 131, 132, 137, 146–155, 159, 165, 384**
- anterior elbow US, **375**
- arm, transverse US, **149**
- branches, **154**
- carpal tunnel, transverse US, **153**
- compression, potential sites, **146**
- course and distribution, **147**
- cubital fossa, **148**
- digital branches, **147**
- elbow, transverse US, **150**
- forearm, transverse US, **151**
- longitudinal US, **154**
- muscular branches, **126**
- nerves, **154**
- palmar cutaneous branch, **126**
- palmar nerves, **155**
- radial nerve, **141**
- superficial branches, **93**
- transverse US, **154**
- wrist, transverse US, **152**
Median nerve edema, carpal tunnel syndrome, **591**
Median patellofemoral ligament, **273**
Meniscal cyst. *See* Parameniscal cyst.
Meniscal homologue, **84**
Meniscal tear, **701**
Meniscofemoral ligament, **272, 273**
Meniscotibial ligament, **272, 273**
Meniscus
- cyst, **701**
- knee, **265**

INDEX

Metabolic arthritis. *See* Gout and pseudogout.
Metabolic syndrome, gout and pseudogout, **566**
Metacarpal base
- 1st, **107**
- 2nd, **107**

Metacarpal bone
- 1st, **73, 94, 99, 100, 106**
- 2nd, **93, 94, 97, 100**
- 3rd, **94, 100**
- 4th, **93, 97**
- 5th, **95**
- base, **106**
- fingers, **114**

Metacarpal head, **101, 103, 104, 105**
- 1st, **105**
- 3rd, **97**
- 4th, **97**
- fingers, **111, 112, 113, 116**

Metacarpal shaft
- 2nd, **97**
- 4th, **97**
- fingers, **115**

Metacarpophalangeal (MCP) joint
- fingers, **108, 114, 117**
- thumb, ulnar collateral ligament of, dorsal hand US, **391**
- volar hand US, **391**

Metastases
- bone surface lesion vs., **902**
- cystic soft tissue mass vs., **852**
- hypoechoic muscle mass vs., **841**
- hypoechoic subcutaneous mass vs., **829**
- muscle
  - chest wall lesion vs., **928**
  - hyperechoic muscle mass vs., **847**
  - soft tissue sarcoma vs., **782**
- rib metastases, chest wall lesion vs., **928**
- swollen nerve vs., **891**

Metastatic infiltration, bone infection vs., **646**
Metastatic tumor. *See* Superficial metastases, melanoma, and lymphoma.
Metatarsal bones, **317**
- 1st, **324, 331, 336**
  - base of, **86, 320**
- 2nd, **330**
  - head, **335, 337**
- 3rd, **330**
- 4th, **330**
- 5th, **309, 330**
  - base of, **324**
- forefoot, **334**

Metatarsal fat pad, **337**
Metatarsophalangeal (MTP) joint
- 1st, **340**
  - dorsal foot US, **427**
  - forefoot, **334**
  - plantar aspect, **341**
- 2nd, **337**

MFCN. *See* Medial femoral cutaneous nerve.
Midcarpal compartment, **73**
Middle collateral artery, **140**
Middle facet, **15**
Middle glenohumeral ligament, **14, 25**
Middle phalangeal shaft, **117**
Middle phalanx, **113**
Midfoot, **316–333**
- bones, **320**
- central plantar muscles, **332**
- dorsum foot, **322**
- joints, **321**
- lateral plantar muscles, **333**
- ligaments, **323**
- medial plantar muscles, **331**
- muscles
  - 1st & 2nd layers, **327**
  - 3rd and 4th layers, **328**
  - coronal, **329–330**
- peroneal tendons, **324**
- plantar aponeurosis, **326**
- tarsal tunnel, **325**

Mirror image artifacts, **351, 352**
MMN. *See* Multifocal mononeuropathy.
Mobile wad compartment, **65**
Morel-Lavallée lesion, **497**
Morphea, fat injury vs., **498**
Morton neuroma, **334**
- injection
  - indication, **1023**
  - procedure, **1024**

Motion artifact, **352**
Multifidus muscle, **188, 189**
Multifidus thoracis muscle, **186, 187**
Multifocal mononeuropathy (MMN), swollen nerve vs., **890–891**
Multiple echoes, artifacts due to, **350–351**
- mirror image, **351**
- reverberation, **350–351**
- ring-down (resonance), **350**

Muscle abscess, muscle infarction vs., **505**
Muscle atrophy, abdominal wall hernia vs., **814**
Muscle contusion. *See* Muscle injury.
Muscle edema, hyperechoic muscle mass vs., **846**
Muscle hematoma. *See also* Muscle injury.
- soft tissue infection vs., **638**
- soft tissue sarcoma vs., **782**

Muscle hernia. *See* Muscle injury.
Muscle infarction, **504–507**
- associated abnormalities, **506**
- diagnostic checklist, **506**
- differential diagnosis, **505–506**
- prognosis, **506**
- soft tissue infection vs., **638**

Muscle injury, **508–517**
- diagnostic checklist, **510**
- differential diagnosis, **510**
- prognosis, **510**
- staging, grading, & classification, **510**

Muscle innervation, **317**
Muscle metastases
- chest wall lesion vs., **928**
- hyperechoic muscle mass vs., **847**
- soft tissue sarcoma vs., **782**

Muscle strain. *See* Muscle injury.

Muscle tear. *See also* Muscle injury.
- abdominal wall lesion vs., **935**
- hypoechoic muscle mass vs., **840**

Muscles of back in situ, **177, 185**
Muscular branches, **249**
Musculocutaneous nerve, **29, 32, 35, 36, 37, 38, 63, 122, 130, 131, 132, 137, 165**
- axilla, **28**
- median nerve, **147**

Musculoskeletal artifacts, **350–357**
- attenuation error, artifact due to, **351**
  - acoustic shadowing artifact (posterior acoustic shadowing), **351**
  - acoustic-enhancement artifact (increased through transmission), **351**
- beam characteristic artifacts, **350**
  - anisotropy, **350**
    - ligament injury vs., **528**
    - rotator cuff/biceps tendinosis vs., **436**
    - tendon hypoechogenicity vs., **874**
  - beam-width, **350**
  - off-axis lobe, **350**
  - slice-thickness, **350**
- Doppler imaging, artifacts in, **351–352**
  - aliasing, **352**
  - blooming ("color bleed"), **352**
  - directional ambiguity/indeterminate flow direction artifact, **352**
  - edge, **352**
  - flash, **352**
  - improper Doppler angle with no-flow artifact, **352**
  - mirror (or ghost) image, **352**
  - motion, **352**
  - noise, **352**
  - pseudoflow, **352**
  - range ambiguity, **352**
  - transducer pressure, **351**
  - twinkling, **352**
- improper machine setting artifacts, **351**
  - equipment-generated, **351**
  - range ambiguity, **351**
- multiple echo artifact, **350–351**
  - mirror image, **351**
  - reverberation, **350–351**
  - ring-down (resonance), **350**
- technological aspects, **350**
- velocity error artifacts, **351**
  - defocusing (edge shadowing), **351**
  - refraction, **351**
  - velocity error, **351**

Musculoskeletal US, approach to, **346–349**
- clinical implications, **347**
- getting started, **346**
- machine setup and scanning, **346**
- other techniques, **347**
- recognizing pathology, **346–347**
- US machine, **346**

Musculotendinous junction, **11, 17, 21, 22, 23, 53, 173**
Mycobacterium, bone infection, **646**
Mycobacterium tuberculosis, joint infection, **656**
Myeloproliferative disorder, fat injury vs., **498**
Myolipoma, **725**
Myonecrosis, aseptic. *See* Muscle infarction.
Myositis
- hyperechoic muscle mass vs., **847**
- infective or inflammatory, muscle infarction vs., **505**

Myositis ossificans, calcified soft tissue mass vs., **859**
Myxofibrosarcoma, paraarticular cystic mass vs., **911**
Myxoid liposarcoma, **725**
- paraarticular cystic mass vs., **911**

Myxoid sarcoma, paraarticular cystic mass vs., **911**
Myxoma
- cystic soft tissue mass vs., **853**
- hypoechoic muscle mass vs., **840**
- paraarticular cystic mass vs., **911**

N

Nail, fingers, **117**
Nail bed, fingers, **117**
Nasal bone fracture, **536**
Navicular bone, **261, 316, 320, 322**
- accessory, **316**
- foot, **329, 330**
- medial and posterior ligaments, **306**
- medial ankle, **305**
- proximal aspect, **323**

Navicular cuneiform joint, **320**
Naviculocuneiform joint, **320**
Necrotizing fasciitis, **637**
- fascial lesion vs., **897**

Necrotizing vasculitis, fat injury vs., **498**
Neisseria gonorrhoea, joint infection, **656**
Nephropathy, muscle infarction, **506**
Nerve entrapment
- nerve injury vs., **582**
- radial nerve, **138**
- swollen nerve vs., **890**

Nerve injury, **580–589**
- diagnostic checklist, **582**
- differential diagnosis, **582**
- prognosis, **582**
- staging, grading, & classification, **582**
- swollen nerve vs., **890**

Nerve sheath tumors, **614–625**
- benign peripheral, vascular leiomyoma vs., **749**
- calcified soft tissue mass vs., **858**
- diagnostic checklist, **616**
- differential diagnosis, **616**
- epidermoid cyst vs., **736**
- hypervascular soft tissue mass vs., **862**
- hypoechoic muscle mass vs., **840**
- lymph node abnormality vs., **776**
- nerve injury vs., **582**
- peripheral
  - hyperechoic muscle mass vs., **847**
  - hypoechoic subcutaneous mass vs., **828**
- peritendinous mass vs., **871**
- staging, grading, & classification, **616**

- superficial metastases, melanoma, and lymphoma vs., **754**
- swollen nerve vs., **890**
Neural tumor, carpal tunnel syndrome vs., **592**
Neuralgic amyotrophy, **603**
- swollen nerve vs., **890**
Neurapraxia, **581, 582**. *See also* Nerve injury.
Neurofibroma, swollen nerve vs., **890**
Neurofibromatosis type 1, nerve sheath tumors, **615**
Neurological sequelae, bone surface lesion vs., **902**
Neuropathy, muscle infarction, **506**
Neurotmesis, **581, 582**
Neurovascular abnormalities
- brachial plexus pathology, **602–607**
- carpal tunnel syndrome, **590–597**
- cubital tunnel syndrome, **598–601**
- nerve injury, **580–589**
- nerve sheath tumors, **614–625**
- tarsal tunnel syndrome, **608–613**
- vascular dilatation or inflammation, **626–633**
Nipple, **169**
Nodular fasciitis, fascial lesion vs., **897**
Noise artifact, **352**
Noninfectious fasciitis, soft tissue infection vs., **638**
Nonrotator cuff tendinosis, **454–463**
- diagnostic checklist, **456**
- differential diagnosis, **456**
- prognosis, **456**
Nonrotator cuff tendon tears, **464–475**
- complete, **465**
- diagnostic checklist, **466**
- differential diagnosis, **466**
- full-thickness, **465**
- high-grade partial, **465**
- partial-thickness, **465**
- prognosis, **466**
Normal lymph node, hyperechoic subcutaneous mass vs., **835**

O

OA. *See* Osteoarthritis.
Obesity, abdominal, gout and pseudogout, **566**
Oblique muscles, **176, 184**
Oblique musculature, **181**
Oblique pulley, **89, 102**
Obturator artery, **249**
Obturator externus muscle, **192, 214, 218, 236, 238**
Obturator foramen, **228**
- pubic aspect of, **228**
Obturator internus muscle, **210, 214, 216, 217, 224, 225, 238, 244**
Obturator internus tendon, **217**
Obturator membrane, **244**
Obturator nerve, **201, 208**
- anterior branch, **194, 208, 242, 245**
- posterior branch, **194, 199, 208, 242, 245**
Obturator vein, **250**
Off-axis lobe artifact, **350**
Olecranon, **58, 158**
Olecranon bursa, **42, 679**
Olecranon fossa, **61**
- posterior fat pad in, **41**
Olecranon process, **41, 45, 59, 61**
Opponens digiti minimi muscle, **81, 89, 91, 92, 95**
- thumb, **99**
Opponens pollicis muscle, **94**
- thumb, **98, 100**
Organizing hematoma, **519**
Orthopedic implant, bone surface lesion vs., **903**
Osborne ligament, **59, 60**
Osler-Weber-Rendu syndrome, vascular anomaly, **760**
Osteoarthritis, **546–553**
- diagnostic checklist, **548**
- differential diagnosis, **548**
- inflammatory arthritis vs., **556**
- joint effusion vs., **922**
- prognosis, **548**
- staging, grading, & classification, **548**
- synovial swelling vs., **916**
Osteochondroma, bone surface lesion vs., **902**
Osteochondromatosis, synovial, synovial swelling vs., **916–917**
Osteomyelitis, **645**
- acute, **645**
- bone tumor vs., **790**
- chronic, **645**
Osteosarcoma, bone surface lesion vs., **902**

P

Palm, **93**
Palmar brevis muscle, **88**
Palmar digital veins, **128**
Palmar interossei muscles, **88, 92, 93, 94, 95, 100**
- fingers, **108, 114**
Palmar nerves, median nerve, **155**
Palmar ulnar cutaneous nerve, **384**
Palmaris longus muscle, **46, 56, 57, 62, 64, 65, 67, 68, 70**
Palmaris longus tendon, **70, 72, 75, 76, 82**
- median nerve, **152**
Pancreatic carcinoma, fat injury vs., **498**
Pancreatic disease, fat injury vs., **498**
Pancreatitis, fat injury vs., **498**
Panniculitis
- calcified soft tissue mass vs., **859**
- hyperechoic subcutaneous mass vs., **835**
- hypervascular soft tissue mass vs., **863**
- subcutaneous, fat injury vs., **498**
Pantaloon hernia, **821**
Paraarticular aspiration, elbow
- indication, **995**
- procedure, **995**
Paraarticular cystic mass, **910–915**
- differential diagnosis, **910–911**
  abscess or collection, **911**
  Baker cyst, **910**

bursal distension, **910–911**
cystic-looking soft tissue tumors, **911**
ganglion cyst, **910**
liquefied hematoma, **911**
parameniscal cyst, **910**
pseudoaneurysm, **911**
Paraarticular ganglion cyst
- Baker cyst vs., **674**
- parameniscal cyst vs., **702**
Paralabral cyst aspiration-injection
- indications, **987**
- procedure, **989**
Parameniscal cyst, **700–703**
- Baker cyst vs., **673**
- cystic soft tissue mass vs., **852**
- diagnostic checklist, **702**
- differential diagnosis, **702**
- paraarticular cystic mass vs., **910**
Parapatellar fat, **271**
Parapatellar ligaments, knee, **271**
Parasitic infection, hypoechoic muscle mass vs., **841**
Parasitic infestation, calcified soft tissue mass vs., **859**
Paraspinal muscles, **174, 182–189**
- lumbar, **188–189**
- thoracic, **186–187**
Paratendinous ganglion, tenosynovitis vs., **478**
Paratenon, axial Achilles tendon, **315**
Paraumbilical hernia, abdominal wall lesion vs., **934**
Parietal pleura, **169**
Partial tear, rotator cuff/biceps tendon, **447**
Partial-thickness tear
- nonrotator cuff tendon tears, **465**
- rotator cuff/biceps tendon, **447**
- tendon hyperechogenicity vs., **879**
Partial-thickness tear
- tendon hypoechogenicity vs., **874–875**
Patella, **264**
- anterior knee US, **411**
- lateral aspect, **271**
- medial aspect, **271**
- upper pole, **268**
Patellar bone, **269**
Patellar paratenon, **270**
Patellar retinaculum, **271**
- anterior knee US, **411**
- lateral, **271**
Patellar tendon, **257, 264, 266, 267, 269, 270**
- anterior knee US, **411**
- leg, **286, 288**
- nonrotator cuff tendinosis, **456**
Pathologic fracture, **535**
Pecten, pubis, **190**
Pectineus muscle, **191, 192, 193, 194, 195, 196, 199, 205, 208, 218, 236, 238, 240, 245**
Pectoralis major muscle, **6, 29, 35, 38, 137, 168, 171, 172, 173**
- clavicle head, **173**
- sternal head, **173**
Pectoralis major tendon, **20, 35, 38**
Pectoralis minor muscle, **29, 133, 137, 168, 173**
Pelvic nerves, **200–211**
Pelvis
- lateral aspect of, muscular attachments, **218**
- posterior sacroiliac ligaments of, **215**
Perforating artery, **249**
Perforating branch peroneal artery, **295**
Perforating vein, **128, 250**
Perforating vessels, **249**
Periarticular tumor, cystic, Baker cyst vs., **674**
Peribursal fat, **15, 16, 17, 22, 23**
Perineural fibrosis, swollen nerve vs., **890**
Peripheral nerve sheath tumor
- hyperechoic muscle mass vs., **847**
- hypoechoic subcutaneous mass vs., **828**
Peripheral neuropathy, immune-mediated, swollen nerve vs., **890–891**
Peritendinitis
- nonrotator cuff tendinosis, **455**
- tendinosis with, nonrotator cuff tendon tears vs., **466**
- tendon hyperechogenicity vs., **879**
Peritendinous mass, **870–873**
- differential diagnosis, **870**
Peritoneal cavity, **178, 179, 181**
Peroneal artery, **248, 255, 257, 259**
- anterior and posterior leg nerves, **295**
- lateral ankle, **310**
- leg, **285, 289**
- perforating branch, **257**
Peroneal nerve, **282, 297**
- deep, **318, 322**
- posterior knee US, **412**
- superficial, **318**
Peroneal tendons
- hindfoot, **324**
- lateral ankle US, **420**
- midfoot, **324**
Peroneal trochlea, lateral ankle, **311**
Peroneal tubercle, **311, 324**
Peroneal tunnel, **257**
Peroneal vein, **248, 259, 262**
- lateral ankle, **310**
- leg, **285**
Peroneocalcaneus internus muscle, **283**
Peroneus brevis muscle, **259, 263**
- lateral ankle, **310**
- leg, **282, 284, 285, 288, 289, 290**
- nerves of ankle, **312**
- tibial nerve, **296**
Peroneus brevis tendon, **263, 299, 324**
- anterolateral ligaments, **308**
- lateral ankle, **309, 310, 311**
- medial and coronal ankle, **303**
Peroneus digiti minimi muscle, **282**
Peroneus longus muscle, **257, 259**
- anterior and posterior leg nerves, **295**
- lateral ankle, **311**
- leg, **282, 284, 286, 288, 289**
Peroneus longus tendon, **257, 263, 299, 324**
- anterior and posterior leg nerves, **295**
- anterolateral ligaments, **308**
- lateral ankle, **309, 310**
- leg, **288, 289**

- medial and coronal ankle, **303**
Peroneus quartus muscle, **282**
Peroneus tertius muscle, **282**
Peroneus tertius tendon, **299**
Peroneus tunnel, **295**
Persistent median artery, **118**
- MR angiography, **127**
Pes anserine bursa, **679**
Pes anserinus, **237, 244**
- tendon, **240, 264**
  medial knee US, **412**
PFCN. *See* Posterior femoral cutaneous nerve.
Phalangeal base, **113**
Phalanges, forefoot, **334**
Phalanx, **109**
Phlegmon, **637**
Physiologic fluid, **47, 117, 341**
Physiological immature hip, developmental hip dysplasia vs., **574**
Physis, bone fracture vs., **536**
Pigmented villonodular synovitis (PVNS)
- joint effusion vs., **916**
- synovial swelling vs., **916**
Pilomatricoma, **740–743**
- calcified soft tissue mass vs., **858**
- differential diagnosis, **741**
- genetics, **741**
- hyperechoic subcutaneous mass vs., **835**
- hypervascular soft tissue mass vs., **862–863**
- hypoechoic subcutaneous mass vs., **828**
- prognosis, **741**
Pilomatrixoma. *See* Pilomatricoma.
Piriformis muscle, **176, 184, 209, 214, 216, 217, 218, 219, 224, 244**
- inferior margin, **224**
Pisiform, **72, 73, 82, 83, 87, 95, 163**
Pisohamate ligament, median nerve, **155**
Pisotriquetral compartment, **73**
Plantar aponeurosis, **326**
Plantar arch, **260**
Plantar arterial arch, **338**
Plantar bursitis, plantar fasciitis and fibromatosis vs., **720**
Plantar calcaneonavicular (spring) ligament, **318**
Plantar compartment
- central, **317–318**
- dorsal, **318**
- interosseous, **318**
- lateral, **318**
- medial, **317**
Plantar digital nerves, **260**
Plantar fascia, **317**
- central band, **317, 326, 330, 332**
- lateral band, **317, 330, 333**
- medial band, **317, 330**
- plantar foot US, **427**
Plantar fascial tear
- fascial lesion vs., **896**
- plantar fasciitis and fibromatosis vs., **720**
Plantar fasciitis and fibromatosis, **718–723**
- associated abnormalities, **720**
- diagnostic checklist, **720**
- differential diagnosis, **720**
- fascial lesion vs., **896**
- prognosis, **720**
- tarsal tunnel syndrome vs., **610**
Plantar fasciitis injection
- indication, **1023**
- procedure, **1024**
Plantar fasciopathy. *See* Plantar fasciitis and fibromatosis.
Plantar fibroma. *See also* Plantar fasciitis and fibromatosis.
- fascial lesion vs., **896**
Plantar fibromatosis. *See* Plantar fasciitis and fibromatosis.
Plantar foot, arteries and nerves, **338**
Plantar foot US, **427**
- flexor tendons, **427**
- plantar fascia, **427**
- plantar muscles, **427**
- toe web spaces, **427**
Plantar ligament, **326**
Plantar muscles, **317**
- central, **317**
- dorsal, **317**
- with flexor tendons, **339**
- lateral, **317**
- medial, **317**
- plantar foot US, **427**
Plantar nerve
- lateral, **318, 330**
- medial, **318**
Plantar plate, **335, 341**
- forefoot, **334, 337, 340**
Plantar veins, median & lateral, **248**
Plantar venous arch, **248**
Plantaris muscle, **278, 283, 291, 293**
Plantaris tendon, **291, 299, 314**
- posterior ankle US, **420**
Pleomorphic liposarcoma, **725**
Pleura, **170, 171, 172**
Podagra. *See* Gout and pseudogout.
Polyarteritis nodosa, fat injury vs., **498**
Popliteal artery, **248, 249, 255, 256, 257, 281, 292, 295, 296**
Popliteal artery aneurysm, Baker cyst vs., **674**
Popliteal cyst. *See* Baker cyst.
Popliteal hiatus, **274**
Popliteal muscle, **257, 292, 295**
Popliteal synovial cyst. *See* Baker cyst.
Popliteal vein, **248, 250, 256, 262, 281, 292, 296**
Popliteofibular ligament, **274**
Popliteomeniscal fascicle, **274**
Popliteus muscle, **255, 283**
Popliteus tendon, **274, 275, 276**
- insertional area, **276**
- lateral knee US, **412**
Posterior ankle, US, **420**
Posterior antebrachial cutaneous nerve, **140**
Posterior capsule, **272, 274**
Posterior circumflex humeral artery, **12, 28, 31, 40, 119, 140**
Posterior compartment, leg muscles, **239, 291–293**
- deep muscles, **283**
- superficial muscles, **282–283**

Posterior cord, radial nerve, **139**
Posterior cruciate ligament, **272**
- posterior knee US, **412**
Posterior cutaneous branch, radial nerve, **145**
Posterior cutaneous nerve
- knee, **277**
- thigh, **215, 216**
Posterior elbow US, **376**
- triceps tendon, **376**
Posterior facet, **222**
Posterior fat pad, **44, 61**
- in olecranon fossa, **41**
Posterior femoral cutaneous nerve (PFCN), **200–201**
Posterior glenohumeral joint, **27**
Posterior gluteal line, **218**
Posterior hip, US, **404**
Posterior horn medial meniscus, **272**
Posterior interosseous artery, **64, 65, 70, 71, 123, 129**
Posterior interosseous nerve, **46, 51, 64, 65, 70, 71, 78, 79, 139, 143, 383–384**
Posterior interosseous vein, **64**
Posterior knee, US, **412**
Posterior labrum, **27**
Posterior oblique ligament, **106, 272, 273**
Posterior recurrent ulnar artery, **125**
Posterior sacroiliac ligament, **217**
Posterior spinous process, **169**
Posterior suprapatellar (prefemoral) fat pad, **266**
- synovium, **266**
Posterior talar tubercle, **321**
Posterior talocalcaneal articulation, **321**
Posterior talofibular ligament
- lateral ankle, **309**
- medial and posterior ligaments, **306**
Posterior thigh musculature, hip US, **404**
Posterior tibial artery, **255, 257, 260, 325**
- anterior and posterior leg nerves, **295**
- leg, **284, 285**
- medial ankle, **304, 305**
Posterior tibial disorders, tarsal tunnel syndrome vs., **610**
Posterior tibial vein, **248, 262, 325**
- leg, **284, 285**
- medial ankle, **304, 305**
Posterior tibialis tendon, **321, 323**
- foot, **329**
- insertion, **331**
- medial ankle, **305**
- nonrotator cuff tendinosis, **456**
Posterior tibiofibular ligament
- lateral ankle, **309**
- medial and posterior ligaments, **306**
Posterior tibiotalar band
- deep deltoid, medial and posterior ligaments, **306**
- deep deltoid ligament, **307**
- medial and coronal ankle, **303**
- superficial deltoid, medial and posterior ligaments, **306**
Posterior tubercle, **134**
Posterior ulnar recurrent artery, **45, 123, 158**
Posterolateral corner structures, posterior knee US, **412**
Posterosuperior facet, **222**
Posterosuperior internal impingement, rotator cuff/biceps tendon tear, **448**
Postoperative fibrosis/granulation tissue, local tumor recurrence vs., **802**
Postoperative infection, **660–665**
- diagnostic checklist, **662**
- differential diagnosis, **662**
- prognosis, **662**
Postoperative inflammation, postoperative infection vs., **662**
Postoperative seroma/hematoma, local tumor recurrence vs., **802**
Postradiation plexopathy, **603**
Posttraumatic hemarthrosis or lipohemarthrosis. *See* Hemarthrosis.
Pre-Achilles fat pad, **288**
Prefemoral fat pad, **268**
Prepatellar bursa, **679**
Prepatellar bursitis (housemaid's knee). *See* Bursitis.
Prepatellar quadriceps continuation, **269**
Primary amyloidosis, tendon swelling vs., **883**
Primary bone tumor, **789**
Princeps pollicis artery, **94, 126**
Probable vas deferens, **198**
Profunda brachii artery, **122**
- radial nerve, **141**
Profunda brachii vein, radial nerve, **141**
Profunda brachii vessels, radial nerve, **142**
Profunda femoral artery, **238, 249**
Profunda femoral vein, **238**
Profunda femoris artery, **199, 252, 253, 254, 255**
Profunda femoris vein, **253, 254**
Proliferative tenosynovitis, acute, **477**
Prolotherapy, **996**
Prominent xiphoid process, chest wall lesion vs., **929**
Prominent/floating rib, chest wall lesion vs., **929**
Promontory, **234, 235**
Pronator flexor carpi radialis muscle, **68**
Pronator quadratus muscle, **62, 64, 69, 70, 71, 81, 82, 151, 152, 154**
Pronator teres carpi radialis muscle, **68**
Pronator teres muscle, **35, 44, 45, 46, 49, 50, 55, 56, 57, 62, 63, 64, 124, 160, 161**
- humeral head, **148**
- median nerve, **147, 150**
Proper digital nerve
- dorsal foot, **338**
- plantar foot, **338**
Proper palmar digital arteries, **126, 127**
Prosthetic synovitis, synovial swelling vs., **917**
Proteus, postoperative infection, **662**
Proximal carpal row, **72**
Proximal femur, **231, 251**
Proximal humerus, **25, 33**
Proximal interphalangeal joint
- capsule, **90, 96, 111, 115, 117**
- fingers, **117**
Proximal phalanx, **112, 113**
- base, **101, 103, 337**
- fingers, **111, 114**

- hallux, **341, 342, 343**
- head, **103, 111**
- thumb, **99, 101, 104, 105**
Proximal radioulnar joint, **43**
Proximal radius, **49, 67, 71**
Proximal ulna, **49, 54, 60, 69, 125**
Pseudoaneurysm, **627, 628**. *See also* Vascular dilatation or inflammation.
- bone surface lesion vs., **902**
- cystic soft tissue mass vs., **853**
- paraarticular cystic mass vs., **911**
Pseudoflow artifact, **352**
Pseudogout, **564–571**
- associated abnormalities, **566**
- diagnostic checklist, **566**
- differential diagnosis, **566**
- prognosis, **566**
Pseudomonas
- bone infection, **646**
- postoperative infection, **662**
Pseudomonas aeruginosa, joint infection, **656**
Psoas major muscle, **176, 184, 192, 202**
Psoas minor muscle, **176, 184**
Psoas muscle, **174, 182, 188, 189, 191, 232, 240, 244**
Psoriatic arthropathy. *See* Inflammatory arthritis.
Pubic body, **195, 199**
Pubic bone, **190, 225**
Pubic crest, **190**
Pubic ligament, superior, **195**
Pubic symphysis, **190, 195**
Pubic tubercle, **190, 195, 196**
Pubofemoral ligament, **228**
Pudendal artery, **210, 225**
Pudendal nerve, **201, 209, 210, 215, 224, 225**
- in Alcock canal, **209, 210, 224**
- region of, **225**
"Pulled muscle." *See* Muscle injury.
Pulp space, tendon, **114**
Pulvinar, **228**
Pyomyositis, **637**

Q

Quadratus femoris muscle, **211, 214, 216, 217, 218, 220, 221, 224, 233, 238, 244**
Quadratus femoris tendon, **221**
Quadratus lumborum muscle, **174, 176, 178, 181, 182, 184, 188, 189**
Quadratus plantae muscle, **261, 324, 325, 326, 332, 333**
- foot, **327, 329, 330, 331**
- forefoot, **339**
- medial and coronal ankle, **303**
Quadriceps, **264**
Quadriceps femoris, **236**
Quadriceps tendon, **240, 268, 271**
- anterior knee US, **411**
Quadrilateral space, **28, 31, 33, 40**
Quadrilateral space syndrome, **28**

R

Radial artery, **46, 63, 64, 67, 70, 82, 83, 118, 123, 124, 126, 127, 129**
- contribution to superficial palmar arch, **126**
- deep palmar arch, **129**
- palmar cutaneous branch, **126**
- radial nerve, **144**
Radial bursa, **89, 91**
- fingers, **109**
- thumb, **99**
Radial collateral artery, **36**
- radial nerve, **140**
Radial collateral ligament, **42, 43, 45, 85**
- lateral elbow US, **376**
- longitudinal US, **54**
Radial digital nerve, **116**
Radial head, **43, 45, 47, 48, 49, 50, 53, 54**
- radial nerve, **142**
Radial limb arcuate ligament, **85**
Radial neck, **51**
Radial nerve, **12, 29, 32, 35, 36, 37, 39, 40, 44, 45, 63, 64, 65, 122, 130, 131, 132, 137, 138–145, 149, 159, 165**
- anterior elbow US, **375**
- arm, transverse US, **141**
- axilla, **28**
- deep branch, **46, 51, 63, 67, 132, 143, 145**
- dorsal digital branches, **145**
- elbow and wrist, **145**
- forearm, transverse US, **144**
- at lateral intermuscular septum, **41**
- posterior arm, **140**
- posterior cutaneous branch, **145**
- posterior interosseus branch, **145**
- radial tunnel, transverse US, **142**
- in spiral groove, **41**
- superficial branch, **46, 51, 63, 67, 77, 125, 132, 144, 145**
- superficial terminal branch, **139**
- supinator tunnel, transverse US, **143**
Radial neurovascular bundle, **39**
Radial recurrent artery, **67, 71, 123, 125, 143**
Radial recurrent vein, **125**
Radial sagittal band, **116**
Radial sesamoid bone, **94, 100, 102**
Radial shaft, **144**
Radial styloid process, **73**
Radial tubercle of trapezium, **106**
Radial tuberosity, **49**
Radial tunnel, radial nerve, **142**
Radial vein, **70, 128**
Radialis indicis artery, **126**
Radiocarpal joint, **73**
Radiohumeral synovial flange, hypertrophy of, elbow epicondylitis vs., **488**
Radiolunotriquetral ligament, **85**
Radioscaphocapitate ligament, **85**
Radioscaphoid ligament, **85**
Radiosynovectomy, indications, **995**

Radioulnar bursa, **42**
Radius, **46, 64, 65, 67, 70, 71, 80, 82, 125**
- head of, **64**
- median nerve, **151, 152, 154**
- neck of, **143**
- radial nerve, **143, 144**
Range ambiguity artifact, **351, 352**
Raynaud phenomenon, procedures, **1002**
Reactive bone change at resection margin, local tumor recurrence vs., **802**
Reactive bursitis, bone surface lesion vs., **902**
Reactive lymph node, superficial metastases, melanoma, and lymphoma vs., **754**
Reactive myositis, bone surface lesion vs., **902**
Rectum, **176, 184**
Rectus abdominis muscle, **174, 178, 179, 180, 182, 190, 196**
- divarication of, abdominal wall lesion vs., **935**
Rectus femoris muscle, **191, 192, 236, 238, 239, 240, 241, 243, 244**
Rectus femoris tendon, **239, 241, 266**
- anterior hip US, **403**
- direct head, **241**
- indirect head, **241**
Rectus muscle, **175, 178, 183**
Rectus sheath, **175, 178, 183, 196**
Rectus sheath aponeurosis, **195**
Rectus sheath hematoma, **519**
- abdominal wall hernia vs., **814**
- abdominal wall lesion vs., **935**
Recurrent articular branch, **294**
Refraction artifact, **351**
Renal stones, gout and pseudogout, **566**
Retinopathy, muscle infarction, **506**
Retrocalcaneal bursa, **679**
- longitudinal Achilles tendon, **314**
Retrocondylar bursa, **272**
"Retrocondylar groove." *See* Cubital tunnel syndrome.
Retroperitoneal fat, **189**
Reverberation artifact, **350–351**
Rhabdomyolysis, hyperechoic muscle mass vs., **847**
Rheumatic fever, fat injury vs., **498**
Rheumatoid arthritis. *See also* Inflammatory arthritis.
- gout and pseudogout vs., **566**
Rheumatoid nodule
- gout and pseudogout vs., **566**
- hypoechoic subcutaneous mass vs., **829**
Rhomboid muscle, **169**
Rib, **168, 169, 171**
- 1st, **5, 6**
- 4th, **172**
- 5th, **172**
- ossified portion, **171**
- posterior aspect, **171, 187**
Rib fracture, **536**
- healing, chest wall lesion vs., **928**
- stress, chest wall lesion vs., **928**
Rib metastases, chest wall lesion vs., **928**
Richter hernia, **822**
Right crus of diaphragm, **176, 184**
Ring-down (resonance) artifact, **350**
Rotator cable, **10, 15, 18**
- rotator cuff/biceps tendinosis vs., **436**
- rotator cuff/biceps tendon tear vs., **448**
Rotator crescent, **15**
Rotator cuff, **10**
- cable, imaging pitfalls, **11**
- interval, **10, 18**
  tendinous interspace, **11**
- tendon insertion, **14**
Rotator cuff arthropathy, rotator cuff/biceps tendon tear, **448**
Rotator cuff musculature, **364**
Rotator cuff tendinopathy. *See* Rotator cuff/biceps tendinosis.
Rotator cuff tendon, blood supply, **10**
Rotator cuff/biceps tendinosis, **434–445**
- calcific tendinosis, **435**
- diagnostic checklist, **436**
- differential diagnosis, **435–436**
- genetics, **436**
- procedures
  indications, **987**
  procedure, **989**
- rotator cuff/biceps tendon tear vs., **448**
- staging, grading, & classification, **436**
Rotator cuff/biceps tendon tear, **446–453**
- associated abnormalities, **448**
- complete, **447**
- diagnostic checklist, **448**
- differential diagnosis, **448**
- full-thickness, **447**
- massive, **447**
- partial, **447**
- partial-thickness, **447**
- prognosis, **448**
Rotator interval, **363**
Rotator thoracis muscle, **186**
Ruptured Baker cyst, muscle injury vs., **510**

S

Sacroiliac joint, **215**
Sacroiliac joint injection
- indications, **1007**
- procedures, **1007–1008**
Sacroiliac ligaments, **215**
Sacrospinous ligament, **209, 217, 224, 244**
Sacrotuberous ligament, **217, 244**
Saddlebag hernia, **821**
Sagittal bands, **90, 96, 97, 103, 109**
- fingers, **109, 114, 115**
Saphenous nerve, **239, 242, 245, 277, 278, 280, 281, 294, 297**
Saphenous opening, **191**
Saphenous vein, **297**
Sarcoidosis, fat injury vs., **498**
Sarcoma
- alveolar soft part, vascular anomaly vs., **760**

- angiosarcoma, vascular dilatation or inflammation vs., **628**
- bone, bone infection vs., **646**
- calcified soft tissue mass vs., **858**
- cystic soft tissue mass vs., **853**
- hypoechoic subcutaneous mass vs., **829**
- Kaposi, vascular dilatation or inflammation vs., **628**
- myxoid, paraarticular cystic mass vs., **911**
- soft tissue
  - hematoma/seroma vs., **520**
  - superficial metastases, melanoma, and lymphoma vs., **754**
- synovial chondrosarcoma, synovial swelling vs., **917**
- synovial sarcoma, synovial swelling vs., **917**

Sartorius muscle, **191, 192, 206, 207, 218, 236, 238, 239, 240, 241, 242, 243, 244, 245, 252, 253, 267, 277, 278, 280, 281**
- medial knee US, **412**

Sartorius tendon, **291**
SA-SD. *See* Subacromial-subdeltoid bursa injection.
Saturday-night palsy. *See* Nerve injury.
Scalenus anterior muscle, **133, 135, 136**
Scalenus medius muscle, **133, 135**
Scalenus posterior muscle, **136**
Scaphoid, **72, 73, 79, 80, 86**
- distal pole of, **106**

Scapholunate ligament, dorsal component of, **79**
Scapula, **24, 25, 26, 27, 169**
- inferior tip, **26**
- spine, **23, 25, 26, 29, 31**
- supraspinous fossa, **26**

Scarred tissue, nonrotator cuff tendon tears vs., **466**
Schwannoma
- cystic, paraarticular cystic mass vs., **911**
- cystic soft tissue mass vs., **853**
- swollen nerve vs., **890**

Sciatic nerve, **201, 208, 209, 211, 215, 216, 217, 219, 220, 221, 224, 225, 233, 238, 245, 246, 247, 294**
- with overlying inferior gluteal artery, **233**

Sclerodactyly, calcified soft tissue mass vs., **859**
Sebaceous cyst. *See* Epidermoid cyst.
2nd extensor compartment, **144**
Secondary amyloidosis, tendon swelling vs., **883**
Secondary bone tumor, **789**
Secondary deposits. *See* Superficial metastases, melanoma, and lymphoma.
Semimembranosus aponeurosis, **211**
Semimembranosus bursae, **272**
Semimembranosus membrane, **221, 246, 247**
Semimembranosus muscle, **216, 218, 237, 239, 244, 245, 246, 247, 265, 272, 277, 281**
Semimembranosus tendon, **209, 220, 221, 238, 272, 278, 279, 280**
- medial knee US, **412**
- origin, **233**

Semimembranous bursa, **679**
Semispinalis muscle, **186, 187**
Semitendinosus muscle, **211, 216, 218, 221, 237, 238, 239, 244, 246, 247, 277**
- conjoint tendon of, **238**
- medial knee US, **412**

Semitendinosus tendon, **211, 247, 267, 272, 278, 291**
- conjoint biceps femoris, **211**

Septic arthritis. *See also* Joint infection.
- bone infection vs., **646**
- gout and pseudogout vs., **566**
- hemarthrosis and lipohemarthrosis vs., **670**
- inflammatory arthritis vs., **556**
- synovial swelling vs., **917**

Sequestrum, **645**
Seroma
- abdominal wall hernia vs., **814**
- acute, **519**
- chronic, **519**
- cystic soft tissue mass vs., **852**
- diagnostic checklist, **520**
- differential diagnosis, **520**
- postoperative, local tumor recurrence vs., **802**
- prognosis, **520**
- subacute, **519**

Serratus anterior, **168, 169**
Serratus posterior inferior muscle, **177, 185, 186, 187, 188**
Serratus posterior superior muscle, **177, 185**
Sesamoid bones, **334**
Severe edema, tenosynovitis vs., **478**
Sharpey fibers at insertional site, **15**
Shear wave elastography, **347**
Short plantar ligament, **318**
- forefoot, **339**
- medial and posterior ligaments, **306**

Short radiolunate ligament, **85**
Short saphenous vein, **248, 263, 277, 278, 281, 322**
- leg, **284, 285, 292**
- nerves of ankle, **312**

Shoulder, **10–27**
- arteries, **119**
- biceps tendon, **19, 20**
- coracoacromial and coracohumeral ligaments, **17**
- deep structures, **13**
- infraspinatus tendon & muscle, **23**
- muscles & ligaments, **12**
- parascapular muscles, **26**
- pectoralis major tendons, **20**
- posterior aspect, **25**
- posterior glenohumeral joint, **27**
- rotator cable, **15**
- rotator interval, **18**
- scapular notches, **27**
- shoulder capsule, **14, 25**
- subscapularis muscle, **21**
- subscapularis tendon, **22**
- supraspinatus insertional area, **15, 16**
- teres minor tendon & muscle, **24**

Shoulder procedures, **986–993**
- acromioclavicular joint injection
  - indications, **987**
  - procedure, **989**
- calcific tendinitis therapy
  - indications, **987**
  - procedure, **988–989**

- glenohumeral joint injection or aspiration
  indications, **987**
  procedure, **987**
- preprocedure, **987**
- procedure, **987–989**
- rotator cuff tendinosis
  indications, **987**
  procedure, **989**
- subacromial-subdeltoid bursa injection
  indications, **987**
  procedure, **988**

Shoulder US, **362–369**
- acromioclavicular joint, **364**
- biceps tendon, long head of, **363**
- clinical indications, **363**
- glenohumeral joint, **364**
- glenoid labra, **364**
- infraspinatus tendon, **363**
- rotator cuff musculature, **364**
- rotator interval, **363**
- subacromial impingement, dynamic assessment of, **364**
- subacromial-subdeltoid and subcoracoid bursae, **364**
- subscapularis tendon, **364**
- suprascapular/spinoglenoid notches, **364**
- supraspinatus tendon, **363**
- symptomatic area, **364**
- teres minor tendon, **363**

Sinus tarsi, **309**
- injection
  indication, **1023**
  procedure, **1024**
- medial and coronal ankle, **303**

Skier's thumb. *See* Ligament injury.
Skin, **169**
Skin metastasis. *See* Superficial metastases, melanoma, and lymphoma.
Slice-thickness artifact, **350**
Sliding hernia, **822**
Slow-flow vascular anomaly, epidermoid cyst vs., **736**
Slow-growing subdermal cyst, **735**
Small ossicle, **101**
Small saphenous vein, **262**
Snapping iliopsoas tendon, dynamic examination for, anterior hip US, **403**
Soft tissue abscess, epidermoid cyst vs., **736**
Soft tissue chondroma, calcified soft tissue mass vs., **858**
Soft tissue ganglia, ganglion cyst, **692**
Soft tissue infection, **636–643**
- bone infection vs., **646**
- differential diagnosis, **638**
- prognosis, **638**

Soft tissue injuries
- fat injury, **496–503**
- hematoma/seroma, **518–525**
- ligament injury, **526–533**
- muscle infarction, **504–507**
- muscle injury, **508–517**

Soft tissue mass, hematoma/seroma vs., **520**
Soft tissue metastases
- calcified soft tissue mass vs., **858**
- hypervascular soft tissue mass vs., **863**

Soft tissue sarcoma, **780–787**
- differential diagnosis, **782**
- hematoma/seroma vs., **520**
- hyperechoic muscle mass vs., **847**
- hypervascular soft tissue mass vs., **862**
- hypoechoic muscle mass vs., **840**
- prognosis, **782**
- staging, grading, & classification, **782**
- superficial metastases, melanoma, and lymphoma vs., **754**

Soft tissue tumor
- biopsy, **942–949**
  outcomes, **944**
  post procedure, **944**
  preprocedure, **943**
  procedure, **943–944**
- dermatofibrosarcoma protuberans, **744–747**
- epidermoid cyst, **734–739**
- foreign body and injection granuloma, **766–773**
- lipoma, **724–733**
- local tumor recurrence, **800–809**
- lymph node abnormality, **774–779**
- muscle injury vs., **510**
- pilomatricoma, **740–743**
- plantar fasciitis and fibromatosis, **718–723**
- soft tissue sarcoma, **780–787**
- superficial metastases, melanoma, and lymphoma, **752–757**
- vascular anomaly, **758–765**
- vascular leiomyoma, **748–751**

Soleus muscle, **257, 260**
- Achilles tendon
  axial, **315**
  longitudinal, **314**
- anterior and posterior leg nerves, **295**
- leg, **283, 284, 285, 288, 289, 291, 292, 293**
- nerves of ankle, **312**

Soleus musculotendinous junction, **313, 314**
Spermatic cord
- groin, **196, 198**
- groin hernia, **395**

Spermatid cord, groin hernia vs., **822**
Spigelian hernia, **813**
- abdominal wall lesion vs., **934**

Spinalis thoracis muscle, **177, 185**
Spindle cell lipoma, **725**
Spinoglenoid notch, **27, 29, 364**
- imaging approaches, **11**

Spinous process, **171, 177, 185, 187, 189**
Spiral groove, radial nerve, **140**
Spondyloarthropathy. *See* Inflammatory arthritis.
Spontaneous hemarthrosis. *See* Hemarthrosis.
Spring ligament
- deltoid ligament, **307**
- foot, **328**
- medial ankle, **305**
- superomedial band, medial and posterior ligaments, **306**
- superomedial fibers, **323**

Staphylococcus aureus
- bone infection, **646**

INDEX

- joint infection, **656**
- postoperative infection, **662**

Stener lesion, **98**. *See also* Ligament injury.
Stenosing tenosynovitis, **477**
Sternal body, **170, 171**
Sternalis muscle, **168**
Sternoclavicular (SC) joint, **5, 6**
- arthropathy, chest wall lesion vs., **929**
- ligaments of, **4**
  anterior, **4**
- muscle attachments, **4**

Sternocleidomastoid muscle, **6, 134, 135**
- clavicular head, **6**

Sternomanubrial junction, **170**
Sternothyroid, tendon, **6**
Sternum, **6, 168, 169, 170**
Strangulated hernia, **822**
Streptococcus, bone infection, **646**
Streptococcus infection, fat injury vs., **498**
Streptococcus pyogenes, joint infection, **656**
Stress fracture, **535**
Stress reaction of bone, **535**
Stress rib fracture, chest wall lesion vs., **929**
STS. *See* Soft tissue sarcoma.
Student's elbow (olecranon bursitis). *See* Bursitis.
Subacromial impingement, dynamic assessment of, **364**
Subacromial-subdeltoid bursa, **10, 11, 18, 364, 679**
- imaging approaches, **11**

Subacromial-subdeltoid bursa injection
- indications, **987**
- procedure, **988**

Subacute hematoma, **519**
Subacute seroma, **519**
Subclavian artery, **6, 119, 120, 136**
Subclavian vein, **6, 121, 136, 173**
Subclavius muscle, **136**
Subcoracoid bursa, **10, 364**
Subcutaneous edema, soft tissue infection vs., **638**
Subcutaneous fat, **20, 169, 178, 180, 189, 219, 293**
Subcutaneous fat necrosis
- foreign body and injection granuloma vs., **768**
- of newborn, fat injury vs., **498**

Subcutaneous fibroma, foreign body and injection granuloma vs., **768**
Subcutaneous hematoma, abdominal wall lesion vs., **935**
Subcutaneous lipoma
- abdominal wall lesion vs., **934**
- fat injury vs., **498**

Subcutaneous mass
- hyperechoic, **834–839**
- hypoechoic, **828–833**

Subcutaneous metastasis. *See also* Superficial metastases, melanoma, and lymphoma.
- foreign body and injection granuloma vs., **768**

Subcutaneous olecranon bursa, **42**
Subcutaneous panniculitis, fat injury vs., **498**
Subcutaneous tissue, **39, 159**
Subdeltoid bursa, **13**
Subdeltoid peribursal fat, **15, 16, 17, 22, 23**
Subgastrocnemius bursa, **272**
Subgluteus medius bursa, **228, 679**
Subgluteus minimus bursa, **679**
Subinguinal space, groin, **190**
Sublime tubercle, **58**
Subpectoralis space, brachial plexus US, **371**
Subscapular nerve, **27, 28**
Subscapularis muscle, **10, 12, 19, 21, 29, 169**
Subscapularis recess, **10–11**
Subscapularis subtendinous bursa, **10**
Subscapularis tendon, **11, 14, 18, 19, 21, 22, 27, 364**
- musculotendinous junction, **11**

Subtalar joint
- dorsal foot US, **427**
- injection, **1023**

Subtendinous olecranon bursa, **42**
Superb microvascular imaging, **347**
Superficial calcaneal bursitis, **679**
Superficial circumflex iliac artery, **249**
Superficial deltoid ligament, medial and coronal ankle, **303**
Superficial epigastric artery, **249**
Superficial femoral artery, **199, 239, 242, 245, 249, 252, 253, 254, 255**
Superficial femoral neurovascular bundle, **238**
Superficial femoral vein, **239, 242, 245, 250, 252, 253, 254**
- valves of, **253**

Superficial inguinal ring, groin, **190, 196**
Superficial metastases, melanoma, and lymphoma, **752–757**
- diagnostic checklist, **754**
- differential diagnosis, **754**
- prognosis, **754**

Superficial palmar arch, **126, 127**
Superficial peroneal nerve, **294**
- anterior and posterior leg nerves, **295**
- lateral ankle US, **420**
- lateral branch, **260, 338**
- leg, **290**
- medial branch, **260, 338**
- tibial nerve, **296**

Superficial posterior compartment, ankle, **299**
Superficial radial nerve, **384**
Superficial talocalcaneal fibers, **321**
Superficial thrombophlebitis, **627, 628**
- fat injury vs., **498**

Superficial vein, **118, 248**
Superficial volar compartment, **65**
Superior acromioclavicular ligament, **4, 7**
Superior extensor retinaculum, **257, 260**
- anterior ankle, **300, 301**
  US, **419**
- dorsal foot, **319**

Superior facet, **16**
Superior gemellus muscle, **214, 216, 217, 218, 220, 225, 244**
Superior glenohumeral ligament, **14, 18, 25**
Superior gluteal artery, **215, 249**
Superior gluteal nerve, **215**
Superior gluteal vein, **250**
Superior labrum anterior to posterior tears, rotator cuff/biceps tendon tear, **448**
Superior lateral genicular artery, **249, 255**
Superior medial genicular artery, **249, 255, 256**

Superior peroneal retinaculum, lateral ankle, **309, 310**
Superior popliteomeniscal fascicle, **274**
Superior pubic ramus, **190, 195, 196**
Superior scapular transverse ligament, **12**
Superior thoracic artery, **30, 119**
Superior transverse scapular ligament, **12, 13, 25, 31**
Superior ulnar collateral artery, **122, 123**
Superolateral genicular artery, **249**
Superomedial genicular artery, **249**
Supinator crest, **54**
Supinator muscle, **46, 49, 62, 64, 67, 71**
- deep head, **51, 143**
- radial nerve, **139, 145**
- superficial head, **51, 143**
Supinator tunnel inlet, **51**
Suprapatellar bursa, **266**
Suprapatellar fat pad, **268**
Suprapatellar recess, **268**
Suprascapular artery, **28, 30, 31, 119**
- infraspinatus branch, **28, 119**
Suprascapular nerve, **13, 29, 31, 130, 135, 165**
- brachial plexus US, **371**
- branch and vessels, **29**
- infraspinatus branch in spinoglenoid notch, **13**
Suprascapular notch, **7, 9, 27, 29, 364**
Supraspinatus muscle, **8, 10, 12, 13, 25, 26, 31**
- central tendon, **26**
- insertional area, **15**
- musculotendinous junction, **17**
- radial nerve, **140**
Supraspinatus tendon, **11, 12, 13, 14, 15, 16, 17, 18, 25, 31, 363**
- aponeurotic expansion, **19**
Supraspinatus-infraspinatus junction, focal, **11**
Sural nerve, **260, 277, 294, 313, 318**
- ankle, **312**
- dorsal foot, **338**
- leg, **284, 292**
- peroneal nerve, **297**
- posterior ankle US, **420**
Sustentaculum tali, **321, 325**
- deltoid ligament, **307**
- medial ankle, **304, 305**
Suture material within tendon, tendon hyperechogenicity vs., **879**
Sweat gland tumor, hypoechoic subcutaneous mass vs., **829**
Swollen nerve, **890–895**
- differential diagnosis, **890**
Symmetric polyarthropathy, gout and pseudogout vs., **566**
Symptomatic area, **364**
Synovial biopsy, **960–965**
- outcomes, **962**
- post procedure, **962**
- preprocedure, **961**
- procedure, **961–962**
Synovial bursae, **679**
Synovial chondrosarcoma, **705**
- synovial swelling vs., **917**
Synovial fold, lateral elbow US, **376**
Synovial hemangioma, **705**
- synovial swelling vs., **917**
- synovial tumor, **706**
Synovial lipoma, **705**
- synovial tumor, **706**
Synovial malignant infiltration, **705**
Synovial osteochondromatosis, **705**
- synovial swelling vs., **916–917**
- synovial tumor, **706**
Synovial recesses, **103**
Synovial sarcoma, **705**
- paraarticular cystic mass vs., **911**
- peritendinous mass vs., **871**
- synovial swelling vs., **917**
Synovial swelling, **916–921**
- differential diagnosis, **916**
Synovial tumor, **704–715**
- diagnostic checklist, **706**
- differential diagnosis, **706**
Synovitis
- focal nodular, synovial swelling vs., **916**
- hemosideric, synovial swelling vs., **917**
- hip, transient, joint infection vs., **656**
- pigmented villonodular
  joint effusion vs., **916**
  synovial swelling vs., **916**
- prosthetic
  postoperative infection vs., **662**
  synovial swelling vs., **917**
- synovial tumor vs., **706**
Systemic inflammatory disorder, fat injury vs., **498**
Systemic lupus erythematosus. *See also* Inflammatory arthritis.
- fat injury vs., **498**

T

T1, **29**
- spinal nerve, **165**
- ventral rami, **157**
Takayasu arteritis, fat injury vs., **498**
Talar bone, **325**
Talar dome
- articular cartilage, **302, 320**
- lateral aspect, anterior ankle, **301**
- longitudinal anterior ankle, **302**
Talocalcaneal articulation
- middle, **321**
- posterior, **321**
Talofibular ligament, medial and coronal ankle, **303**
Talonavicular articulation, **320**
Talonavicular joint, **320**
- medial ankle, **305**
Talonavicular ligament, dorsal, **323**
Talus
- deltoid ligament, **307**
- foot, **329**
- head, **320, 321, 323**
  deltoid ligament, **307**

longitudinal anterior ankle, **302**
medial ankle, **305**
medial aspect, **323**
- medial ankle, **305**
- middle facet, **321**
- neck, **320**
longitudinal anterior ankle, **302**
- posterior aspect, **321**

Tarsal bones, **332**
Tarsal coalition, tarsal tunnel syndrome vs., **610**
Tarsal tunnel
- hindfoot, **325**
- medial ankle US, **419**

Tarsal tunnel syndrome (TTS), **608–613**
- differential diagnosis, **610**

Tarsometatarsal joint, **320**
Tendinitis. *See* Tenosynovitis.
Tendinopathy. *See* Tendinosis.
Tendinosis
- bursitis vs., **680**
- of common extensor tendon origin, **487, 488**
- of common flexor tendon origin, **487, 488**
- nonrotator cuff, **454–463**
diagnostic checklist, **456**
differential diagnosis, **456**
prognosis, **456**
- with peritendinitis, nonrotator cuff tendon tears vs., **466**
- rotator cuff/biceps, **434–445**
calcific tendinosis, **435**
diagnostic checklist, **436**
differential diagnosis, **435–436**
genetics, **436**
rotator cuff/biceps tendon tear vs., **448**
staging, grading, & classification, **436**
- tendon hypoechogenicity vs., **874**
- tendon swelling vs., **882**
- tenosynovitis vs., **478**

Tendinous inscription, **175, 179, 183**
Tendon abnormalities
- peritendinous mass, **870–873**
- tendon hyperechogenicity, **878–881**
- tendon hypoechogenicity, **874–877**
- tendon swelling, **882–887**

Tendon disorders
- elbow epicondylitis, **486–493**
- nonrotator cuff tendinosis, **454–463**
- nonrotator cuff tendon tears, **464–475**
- rotator cuff/biceps tendinosis, **434–445**
- rotator cuff/biceps tendon tear, **446–453**
- tenosynovitis, **476–485**

Tendon edges, **11**
Tendon hyperechogenicity, **878–881**
- differential diagnosis, **878**

Tendon hypoechogenicity, **874–877**
- differential diagnosis, **874**

Tendon injury, nerve injury vs., **582**
Tendon pulley system, **108, 110**
- annular pulley, **108**
- extensor expansion, **108**

Tendon rupture. *See* Nonrotator cuff tendon tears.
Tendon sheath fluid, **304**
Tendon sheaths
- fingers, **108, 110**
- hand, **88**

Tendon sprain. *See* Nonrotator cuff tendon tears.
Tendon strain. *See* Nonrotator cuff tendon tears.
Tendon swelling, **882–887**
- differential diagnosis, **882**

Tendon tear
- bursitis vs., **680**
- intrasubstance, rotator cuff/biceps tendinosis vs., **435**
- muscle injury vs., **510**
- nonrotator cuff, **464–475**
complete, **465**
diagnostic checklist, **466**
differential diagnosis, **466**
full-thickness, **465**
high-grade partial, **465**
partial-thickness, **465**
prognosis, **466**
- rotator cuff/biceps tendon. *See* rotator cuff/biceps tendon tear.
- tendon hyperechogenicity vs., **879**
- tendon hypoechogenicity vs., **874–875**

Tendon thickening, tendon hypoechogenicity vs., **874**
Tendonitis. *See* Tenosynovitis.
Tennis elbow. *See* Elbow epicondylitis.
Tennis heel. *See* Plantar fasciitis and fibromatosis.
"Tennis leg." *See* Muscle injury.
Tenosynovial giant cell tumor, **705**
Tenosynovitis, **476–485**
- acute exudative, **477**
- acute proliferative, **477**
- carpal tunnel syndrome vs., **592**
- chronic active, **477**
- chronic inactive, **477**
- diagnostic checklist, **478**
- differential diagnosis, **478**
- nonrotator cuff tendinosis vs., **456**
- peritendinous mass vs., **870**
- prognosis, **478**
- stenosing, **477**

Tensor fascia lata muscle, **191, 192, 194, 206, 207, 214, 216, 217, 218, 236–237, 238, 240, 243**
- lateral hip US, **404**

Teres major muscle, **12, 13, 25, 28, 31, 32, 33, 35, 37, 40, 122, 140, 169**
Teres minor muscle, **10, 12, 13, 14, 24, 25, 26, 28, 31, 33, 40**
- insertional area of, **24**
- musculotendinous junction, **24**
- radial nerve, **140**

Teres minor tendon, **11, 12, 14, 16, 24, 25, 31, 363**
Terminal tendon, **90**
- fingers, **115**

Thenar eminence, **81, 88, 94, 99**
- thumb, **100**

Thenar muscle, **83**
- median nerve, **147, 153, 154**
- thumb, **98**

Thigh muscle, **236–247**
- anterior, **240, 241**
  compartment, **236–237**
- anterolateral, **243**
- anteromedial, **242**
- arteries, **249**
- axial anatomy, **238–239**
- common and superficial femoral vessels, **252**
- common femoral vessels, **251**
- medial, **245**
  compartment, **236**
- medial and posterior, **244**
- posterior, **246, 247**
  compartment, **237**
- proximal, **221**
- saphenofemoral venous junction, **254**
- superficial femoral artery and vein, **253**
- veins, **250**

Thigh nerves, **200–211**
Thoracic outlet syndrome, **603**
Thoracic spinal nerves, **168**
Thoracoacromial artery, **30, 119**
- acromial branch, **30, 119**
- clavicular branch, **119**
- deltoid branch, **119**
- pectoral branch, **30, 119**

Thoracodorsal artery, **30, 119**
Thoracodorsal nerve, **28, 130**
3D US, **347**
Thrombophlebitis, superficial, fat injury vs., **498**
Thumb, **98–107**
- carpometacarpal joint, **106**
- dorsal hand US
  extensor tendon of, **391**
  flexor tendons of, **391**
  ulnar collateral ligament of metacarpophalangeal joint of, **391**
- extensor apparatus, **103**
- extensor aspect, **104**
- flexor pulleys, **102**
- flexor tendons, **101**
- thenar eminence, **99, 100**
- ulnar collateral ligament, **105**
- volar ligaments, **107**

Thyrocervical trunk, **30, 119**
Thyroglossal duct cyst, chest wall lesion vs., **929**
Tibia, **284, 285, 287, 292**
- foot, **329**
- medial and coronal ankle, **303**
- medial and posterior ligaments, **306**
- peroneal nerve, **297**
- proximal, **264**

Tibial artery
- anterior, **257**
- posterior, **248, 255, 257, 260**

Tibial nerve, **239, 256, 277, 278, 281, 292, 294, 296, 313, 318, 325**
- anterior and posterior leg nerves, **295**
- leg, **284**
- medial ankle, **303, 304, 305**
- medial ankle US, **419**
- nerves of ankle, **312**
- posterior knee US, **412**

Tibial plafond, longitudinal anterior ankle, **302**
Tibialis anterior artery, **322**
Tibialis anterior muscle
- leg, **282, 284, 285, 286, 287, 288**
- peroneal nerve, **297**

Tibialis anterior tendon, **263, 322**
- ankle, **298–299**
  anterior, **300, 301**
  longitudinal anterior, **302**
  medial, **303**
- anterior ankle US, **419**
- leg, **286**

Tibialis anterior veins, **322**
Tibialis posterior muscle, **255, 259, 283, 284, 287**
Tibialis posterior tendon, **257, 299, 325**
- anterior and posterior leg nerves, **295**
- deltoid ligament, **307**
- foot, **328**
- leg, **285**
- medial ankle, **303, 304**
  US, **419–420**
- nerves of ankle, **312**

Tibiocalcaneal band, superficial deltoid, **306**
Tibiocalcaneus internus muscle, **283**
Tibiofibular joint, **264**
Tibiofibular trunk, **255**
Tibionavicular band, superficial deltoid, **306**
Tibioperoneal trunk, **248, 257**
Tibiospring band, superficial deltoid ligament, **306, 307**
Tibiotalar joint injection, **1023**
Toe web spaces, plantar foot US, **427**
Tophaceous gout. *See* Gout and pseudogout.
Trabecular microfracture, **535**
Traction apophysitis, ligament injury vs., **528**
Transducer pressure artifact, **351**
Transient synovitis of hip, joint infection vs., **656**
Transversalis fascia, **174, 182**
Transverse abdominis muscle, **182, 190, 192, 194**
Transverse cervical artery, **30, 119**
Transverse ligament, **12, 19, 228**
Transverse muscles, **176, 184**
Transverse process, **171, 189**
Transverse spinous process, **169**
Transverse thoracic muscle, **169**
Transversus abdominis muscle, **174, 177, 178, 181, 183, 185, 202, 203**
Transversus thoracis muscle, **172**
Trapezium, **72, 73, 86**
- radial tubercle of, **106**
- thumb, **104, 106, 107**

Trapezius muscle, **26, 169, 186, 187**
Trapezoid, **9, 72, 73**
Trauma, fat, lipoma vs., **726**
Traumatic fat necrosis, **497**
Traumatic plexopathy, **603**
Triangular fibrocartilage, **84**
Triangular fibrocartilaginous complex, articular disc of, **80**
Triangular ligament, **90, 115**
Triangular space, **31**

Triceps muscle, **12, 36, 44, 61, 141, 142, 149, 158, 159, 160**
- lateral head, **13, 31, 34, 35, 36, 39, 40, 41, 61**
- long head, **31, 34, 36, 39, 40, 41, 140, 159**
- medial belly, **58, 59**
- medial head, **34, 36, 39, 41, 61**
- short head, **159**

Triceps tendon, **12, 36, 41, 42, 44, 59, 61, 158**
- lateral head, **13, 25, 31**
- long head, **25, 31**
- medial head, **25**
- posterior elbow US, **376**

Trichilemmal cyst
- epidermoid cyst vs., **736**
- pilomatricoma vs., **741**

Trichomatricoma. *See* Pilomatricoma.
Trigger finger injection or percutaneous release
- indications, **1001**
- procedures, **1002**

Trigger thumb, **98**
Triquetral bone, **80, 84**
Triquetrocapitate ligament, **85**
Triquetrohamate ligament, **85**
Triquetrum, **72, 73, 84, 163**
Triradiate cartilage, **234**
Triscaphe joint, **86, 106**
Trochanteric bursa, **228, 679**
Trochanteric (hip) bursitis. *See* Bursitis.
Trochlear process, **47, 48, 61**
- humerus, **41**

True ribs, **168**
Trunk
- abdominal wall, **174–181**
- chest wall, **168–173**
- groin, **190–199**
- paraspinal muscles, **182–189**
- pelvic and thigh nerves, **200–211**

TTS. *See* Tarsal tunnel syndrome.
Tuberculosis, fat injury vs., **498**
Tuberculosis abscess, calcified soft tissue mass vs., **859**
Tuft toe, **334**
Tumor
- benign neurogenic, **603**
- bone, **788–799**
  - diagnostic checklist, **790**
  - differential diagnosis, **790**
  - prognosis, **790**
  - staging, grading, & classification, **790**
- occurring within fascia, fascial lesion vs., **897**
- soft tissue, muscle injury vs., **510**
- synovial, **704–715**
  - diagnostic checklist, **706**
  - differential diagnosis, **706**

Tumoral calcinosis, calcified soft tissue mass vs., **859**
Twinkling artifact, **352**

U

Ulna, **45, 46, 47, 56, 58, 61, 64, 65, 69, 70, 71, 73**
- distal, **59**
- median nerve, **152**
- olecranon process of, **160**
- radial notch, **45**

Ulnar artery, **46, 63, 64, 65, 69, 70, 82, 83, 87, 93, 95, 118, 123, 124, 126, 127, 161, 162, 163, 164**
- contribution to deep palmar arch, **126**

Ulnar bursa, **89, 91**
- fingers, **109**
- thumb, **99**

Ulnar collateral artery, **59, 161**
Ulnar collateral ligament (UCL), **42, 43, 45, 58, 84**
- anterior band, **56, 58**
- of metacarpophalangeal joint of thumb, dorsal hand US, **391**
- posterior band, **58, 68**
- thumb, **98, 105**
  - injury. *See* Ligament injury.
  - proximal retraction. *See* Ligament injury.
- transverse band, **57, 58, 68, 160**

Ulnar digital nerve, **116**
Ulnar head, **55, 60, 79, 80, 84, 124, 125**
- groove, **79**

Ulnar lateral slip, **116**
Ulnar neck, **82**
Ulnar nerve, **29, 32, 35, 36, 37, 44, 45, 46, 58, 59, 60, 64, 65, 69, 70, 75, 82, 83, 87, 95, 122, 125, 130, 131, 132, 137, 145, 156–165, 384**
- arm, **156, 157, 159**
- cubital tunnel, **156, 158, 160**
- deep branch, **87, 95, 126, 157, 164, 165**
- digital branches, **157**
  - palmar, **165**
- divided, **87**
- dorsal branch, **145**
- dorsal digital branches, **145**
- forearm, **156, 157, 158, 161, 162**
- Guyon canal, **163, 164**
- hand, **156**
- hypothenar eminence, **157**
- median nerve, **155**
- palmar branch, **157**
- palmar cutaneous branch, **83, 165**
- proximal and distal, **165**
- radial nerve, **141**
- superficial branch, **93, 95, 126, 164, 165**
- wrist, **162**

"Ulnar neural groove." *See* Cubital tunnel syndrome.
Ulnar neuropathy at elbow. *See* Cubital tunnel syndrome.
Ulnar recurrent artery, **44**
Ulnar sagittal band, **116**
Ulnar sesamoid bone, **102**
Ulnar shaft, **58, 124**
Ulnar styloid process, **80**
Ulnar vein, **64, 65, 70, 87, 163**

Ulnocapitate ligament, **85**
Ulnolunate ligament, **84, 85**
Ulnotriquetral ligament, **85**
US machine, **346**
US report, writing, **358–359**
- differential diagnosis, **358**
- grading severity of disease, **358**
- measurements, **358**
- terminology, **358**
Umbilical hernia, **813**
- abdominal wall lesion vs., **934**
Umbilical metastasis, abdominal wall lesion vs., **935**
Umbilical-urachal sinus, abdominal wall lesion vs., **935**
Umbilicus, **175, 183**
Undescended testis, abdominal wall lesion vs., **935**
Unossified greater trochanter, **235**
Upper limb
- arm, **34–41**
- arteries, **118–129**
- axilla, **28–33**
- brachial plexus, **130–137**
- elbow, **42–61**
- fingers, **108–117**
- forearm, **62–71**
- hand, **88–97**
- joint injection, **968–977**
  - outcomes, **970**
  - preprocedure, **969**
  - procedure, **969–970**
- median nerve, **146–155**
- radial nerve, **138–145**
- shoulder, **10–27**
- sternoclavicular and acromioclavicular joints, **4–9**
- thumb, **98–107**
- ulnar nerve, **156–165**
- veins, **118–129**
- wrist, **72–87**
Upper pole patella, **268**
Urethra, **176, 184**
Urinary bladder, **196**

V

Variable pulley, **102, 105**
Vas deferens, **198**
Vascular anomaly, **758–765**
- associated abnormalities, **760**
- clinical issues, **760**
- cystic soft tissue mass vs., **852–853**
- diagnostic checklist, **760**
- differential diagnosis, **760**
- ganglion cyst vs., **692**
- hyperechoic subcutaneous mass vs., **834**
- hypervascular soft tissue mass vs., **862**
- hypoechoic subcutaneous mass vs., **828**
- lymph node abnormality vs., **776**
- prognosis, **760**
Vascular dilatation or inflammation, **626–633**
- diagnostic checklist, **628**
- differential diagnosis, **628**
Vascular leiomyoma, **748–751**
- diagnostic checklist, **749**
- differential diagnosis, **749**
- genetics, **749**
- hypervascular soft tissue mass vs., **862**
- hypoechoic subcutaneous mass vs., **828**
- lymph node abnormality vs., **776**
- nerve sheath tumors vs., **616**
- prognosis, **749**
Vascular malformation
- chest wall lesion vs., **929**
- hyperechoic muscle mass vs., **846**
- hyperechoic subcutaneous mass vs., **834**
- hypervascular soft tissue mass vs., **862**
- hypoechoic muscle mass vs., **841**
- lipoma vs., **726**
- paraarticular cystic mass vs., **911**
Vascular tumor, hypervascular soft tissue mass vs., **862**
Vastus intermedius muscle, **236, 238, 239, 240, 241, 247, 268**
Vastus intermedius tendon, **266**
Vastus lateralis muscle, **236, 238, 239, 240, 241, 243, 244**
Vastus lateralis tendon, **266**
Vastus medialis muscle, **236, 238, 239, 240, 241, 242, 243, 244, 245, 247, 252, 267, 268, 271**
Vastus medialis tendon, **266**
Vegetant intravascular hemangioendothelioma. *See* Vascular dilatation or inflammation.
Veins
- chest wall, **168**
- lower limb, **248–263**
- thigh, **250**
Velocity error artifact, **351**
- defocusing (edge shadowing), **351**
- refraction, **351**
- velocity error, **351**
Venous dilatation, hyperechoic muscle mass vs., **847**
Venous malformation, **759**
Venous varix, **627, 628**
- cystic soft tissue mass vs., **853**
Venous vascular malformation, calcified soft tissue mass vs., **858**
Ventral rami, **133**
Ventral rootlet, **133**
Vertebral artery, **30, 119, 133, 134**
Vertebral body, **169**
Visceral pleura, **169**
Volar carpal ligament, **75, 87, 126**
Volar hand US, **391**
- carpometacarpal joint of thumb, **391**
- flexor tendon pulleys, **391**
- flexor tendons of thumb, **391**
- metacarpophalangeal and interphalangeal joints, **391**
Volar ligaments, **85**
Volar plate, **101, 112, 113**
- fingers, **111, 114**
  - membranous portion, **114**
  - thick portion, **114**
Volar radioulnar ligament, **84, 85**
Volar ulnolunate ligament, **85**

Volar ulnotriquetral ligament, **85**
Volar wrist, **81, 82, 86, 384**
- tendons, **75**
Volar wrist US, **384**
- lateral antebrachial cutaneous nerve, **384**
- median nerve (MN) and carpal tunnel, **384**
- palmar ulnar cutaneous nerve, **384**
- superficial radial nerve, **384**
- tendons outside carpal tunnel, **384**
- ulnar nerve and Guyon tunnel, **384**
- volar wrist joint, **384**
von Recklinghausen disease, nerve sheath tumors, **615**

W

Weber-Christian disease, fat injury vs., **498**
Well-differentiated liposarcoma (WDL), **725**
Wheelchair syndrome. *See* Nerve injury.
Wrist, **72–87**
- anatomic spaces, **72**
- carpal bones & wrist compartments, **73**
- carpal tunnel, **83**
- dorsal, **80**
  ligaments, **85**
- dorsal tendons & tendon sheaths, **74**
- dorsum, **77**
- extensor compartments
  carpal tunnel, **76**
  dorsoulnar aspect, **79**
  dorsum, **78**
- ligaments, **72**
- median nerve, **146, 152**
- muscles and tendons, **72**
- osseous structures, **72**
- radial nerve, **145**
- retinacula, **72**
- tendons of dorsal & volar, **75**
- triangular fibrocartilage, **84**
- ulnar nerve, **162**
- volar, **81, 82, 86**
Wrist US, **382–389**
- clinical indications for, **383**
- dorsal, **383–384**
  1st extensor compartment [abductor pollicis longus (APL) and extensor pollicis brevis (EPB)], **383**
  2nd extensor compartment (extensor carpi radialis longus and extensor carpi radialis brevis), **383**
  3rd extensor compartment [extensor pollicis longus (EPL)], **383**
  4th [extensor digitorum (ED), extensor indicis proprius (EIP) and 5th [extensor digitorum minimi (EDM)] extensor compartments, **383**
  6th extensor compartment [extensor carpi ulnaris (ECU)], **383**
  dorsal ulnar cutaneous nerve, **384**
  dorsal wrist joint, **383**
  dorsal wrist tendons, **383**
  posterior interosseous nerve, **383–384**
- volar, **384**
  lateral antebrachial cutaneous nerve, **384**
  median nerve (MN) and carpal tunnel, **384**
  palmar ulnar cutaneous nerve, **384**
  superficial radial nerve, **384**
  tendons outside carpal tunnel, **384**
  ulnar nerve and Guyon tunnel, **384**
  volar wrist joint, **384**

X

Xanthoma
- nonrotator cuff tendinosis vs., **456**
- plantar fasciitis and fibromatosis vs., **720**
- tendon swelling vs., **883**
Xanthomatosis, tendon hypoechogenicity vs., **875**
Xiphisternal junction, **170**
Xiphoid process, **170**
- prominent, chest wall lesion vs., **929**

Z

Zona orbicularis, **227, 228**

This page intentionally left blank